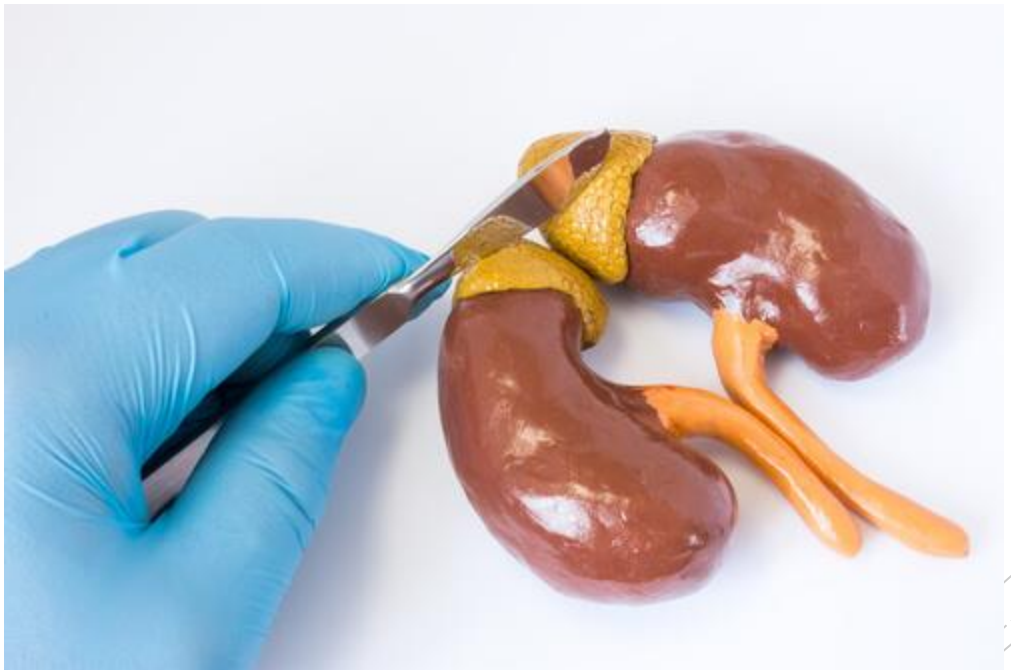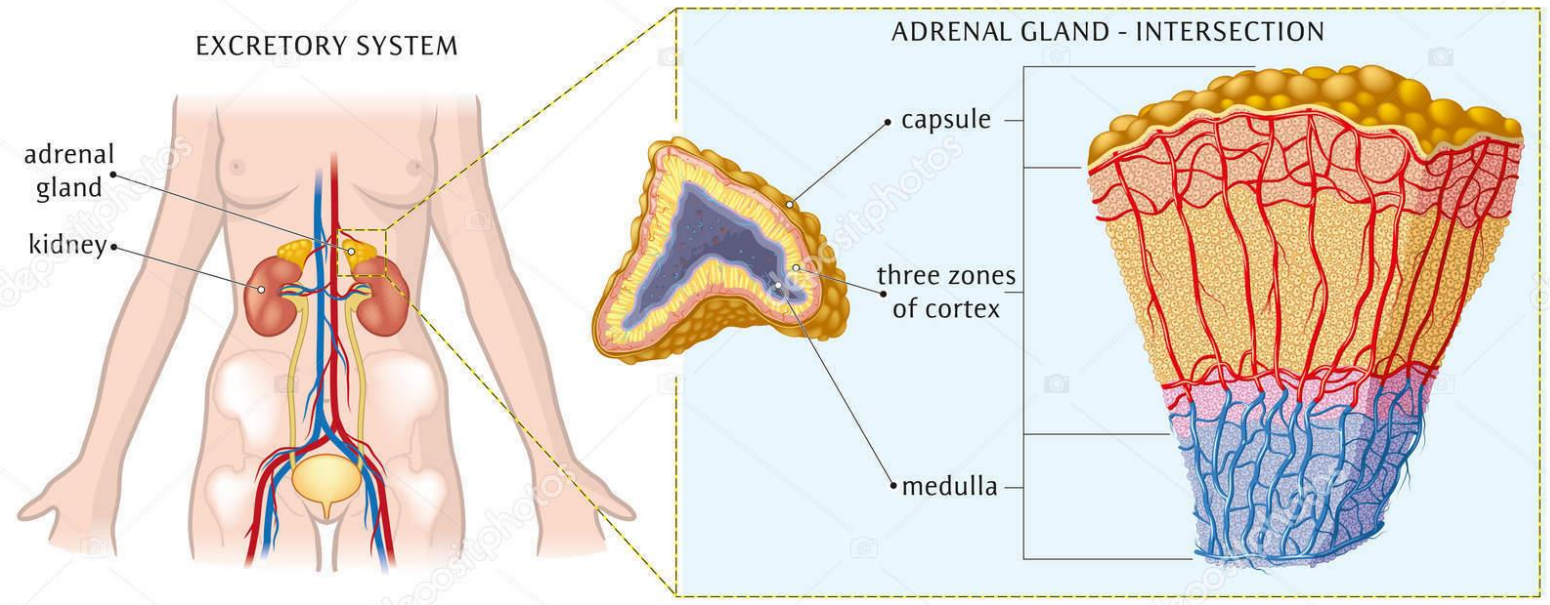


Endocrine system pathology- ADRENAL GLAND

Dr. Omar Hamdan

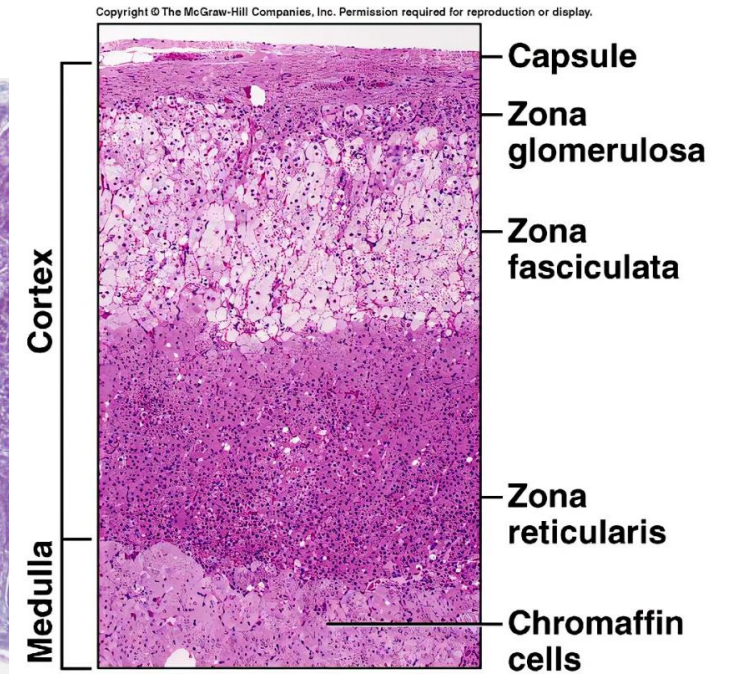
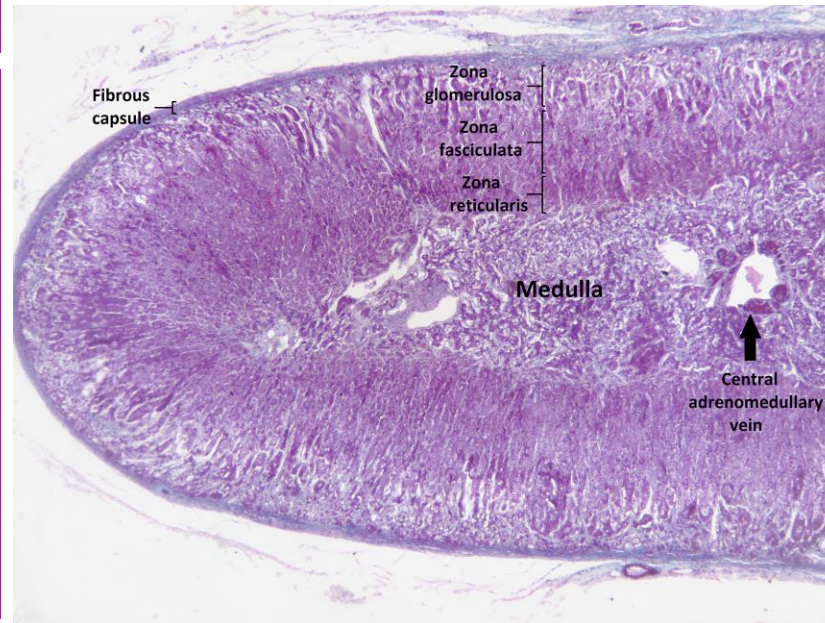
2026.

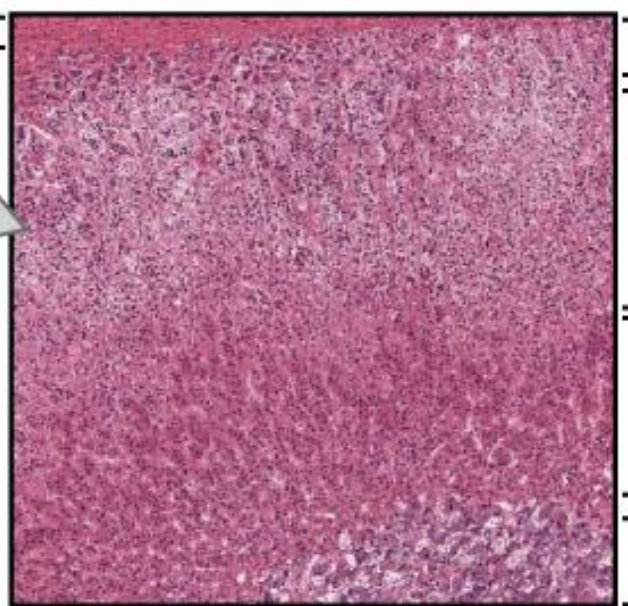
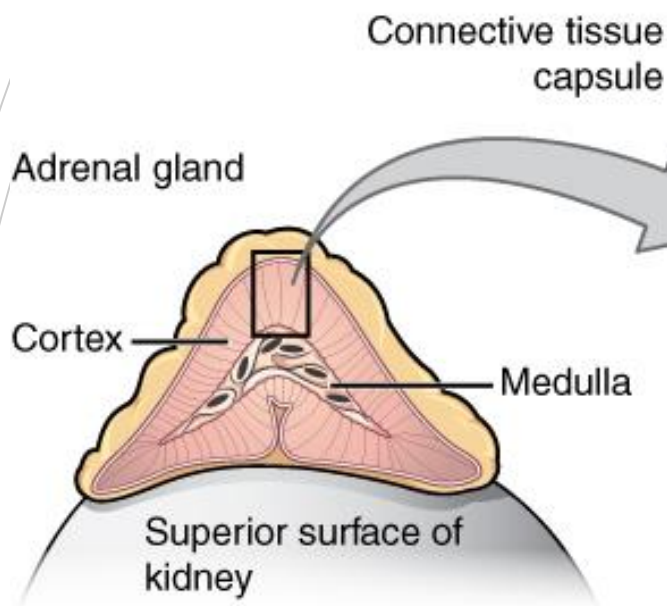
Anatomy



G.F.R

Histology





Tissue area	Hormones released	Examples
Zona glomerulosa (adrenal cortex)	Mineralcorticoids (regulate mineral balance)	Aldosterone
Zona fasciculata (adrenal cortex)	Glucocorticoids (regulate glucose metabolism)	Cortisol Corticosterone Cortisone
Zona reticularis (adrenal cortex)	Androgens (stimulate masculinization)	Dehydroepiandrosterone
Adrenal medulla	Stress hormones (stimulate sympathetic ANS)	Epinephrine Norepinephrine

Adrenal disorders

■ Non-neoplastic:

❖ Adrenal insufficiency:

➤ Acute Adrenocortical Insufficiency.

➤ Chronic Adrenocortical Insufficiency: Addison Disease.

❖ Adrenal hyperfunction:

➤ Cushing Syndrome.

➤ Hyperaldosteronism.

➤ Adrenogenital Syndromes

■ Neoplastic:

❖ Adrenalcortical tumors.

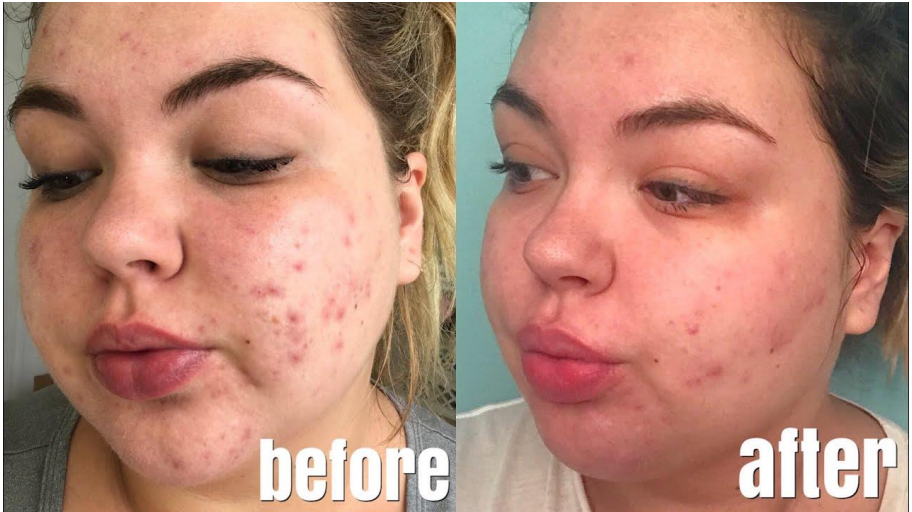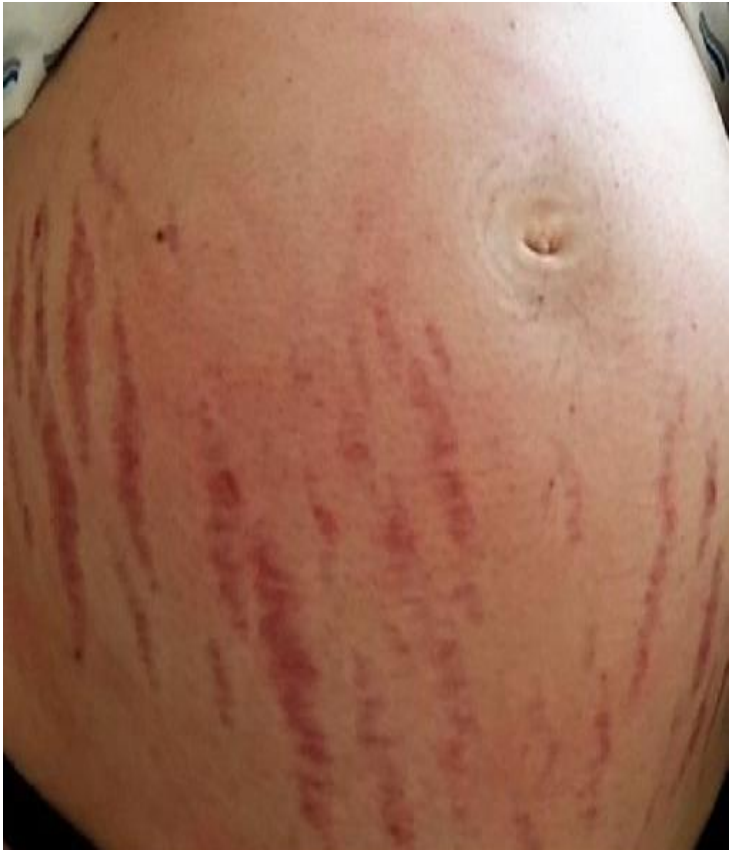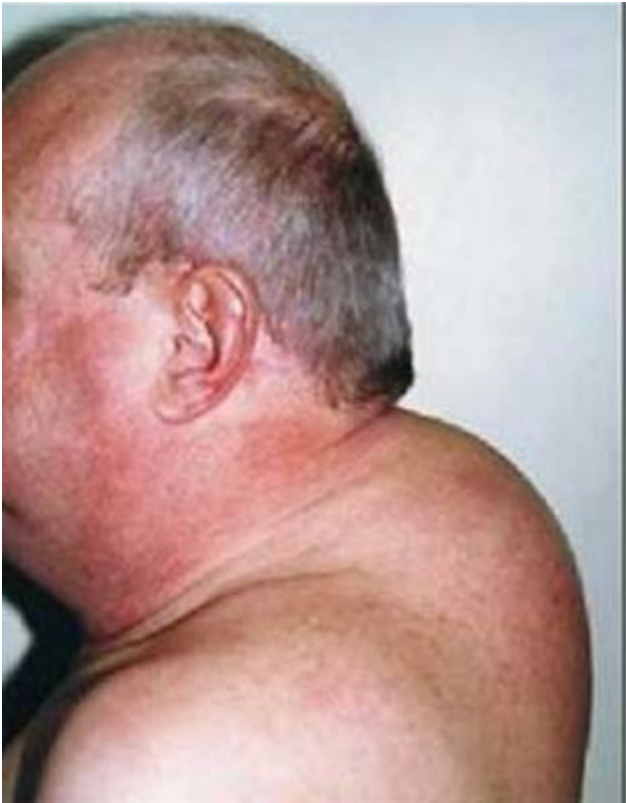❖ Adrenal medulla tumor

Cushing syndrome.

- Hypercortisolism (Cushing syndrome) is caused by elevated glucocorticoid levels.
- Endogenous causes :
 - Hypothalamic/ pituitary hypersecretion ACTH.
 - Paraneoplastic syndrome (lung CA).
 - Adrenal tumor or hyperplasia .
- Exogenous cause :
 - Steroid Therapy.

Signs and symptoms

- high blood pressure.
- abdominal obesity but with thin arms and legs.
- reddish stretch marks.
- round red face.
- fat lump between the shoulders.
- weak muscles and weak bones.
- acne and fragile skin



Morphology

- Morphologic changes in the adrenal glands depend on the cause of the hypercortisolism and include:

(1) cortical atrophy:

exogenous glucocorticoids, suppression of endogenous ACTH.

(2) diffuse hyperplasia:

ACTH dependent Cushing syndrome

(3) macronodular or micronodular hyperplasia:

primary cortical hyperplasia.

(4) an adenoma or carcinoma.

Hyperaldosteronism.

- Hyperaldosteronism is the generic term for a group of closely related conditions characterized by chronic excess aldosterone secretion.
- A-primary hyperaldosteronism are:
 - Bilateral idiopathic hyperaldosteronism, characterized by bilateral nodular hyperplasia of the adrenal glands.
 - Adrenocortical neoplasm, either an aldosterone-producing adenoma (the most common cause) or, rarely, an adrenocortical carcinoma.
 - familial hyperaldosteronism may result from a genetic defect that leads to overactivity of the aldosterone synthase gene, CYP11B2.
- B- Secondary causes :
 - Due to decreased renal perfusion (heart failure), activation of the renin - angiotensin system .

Adrenogenital syndromes

- Adrenogenital syndromes refer to a group of disorders caused by androgen excess, which may stem from a number of etiologies, including primary gonadal disorders and several primary adrenal disorder.

□ Could be caused by :

- 1 - Primary gonadal disorders (increase gonadal androgen).
- 2 -Acquired :Adrenocortical Neoplasms. can occur at any age, frequently malignant .

CLINICAL FEATURES

- Virilization in female or precocious puberty in male.
- Patients have ↑ risk for acute adrenocortical insufficiency.
- Note :Adrenal androgen formation is regulated by ACTH , thus increase androgen can occur as apure syndrome or as a component of cushing syndrome.

ADRENOCORTIC AL INSUFFICIENCY

- May be **primary adrenal(disease affecting the adrenal gland)** :
 - acute (called adrenal crisis).
 - chronic (Addison disease).
- **secondary to destruction of the pituitary as in SHEEHAN's syndrome or non functional pituitary adenoma**

Table 20.7 Causes of Adrenal Insufficiency

Acute
Waterhouse-Friderichsen syndrome
Sudden withdrawal of long-term corticosteroid therapy
Stress in patients with underlying chronic adrenal insufficiency
Chronic
Autoimmune adrenalitis (60%–70% of cases in developed countries)— includes APS1 (AIRE mutations) and APS2 (polygenic)
Infections Tuberculosis Acquired immunodeficiency syndrome Fungal infections
Hemochromatosis
Sarcoidosis
Systemic amyloidosis
Metastatic disease

WATERHOUSE-FRIDERICHSEN SYNDROME

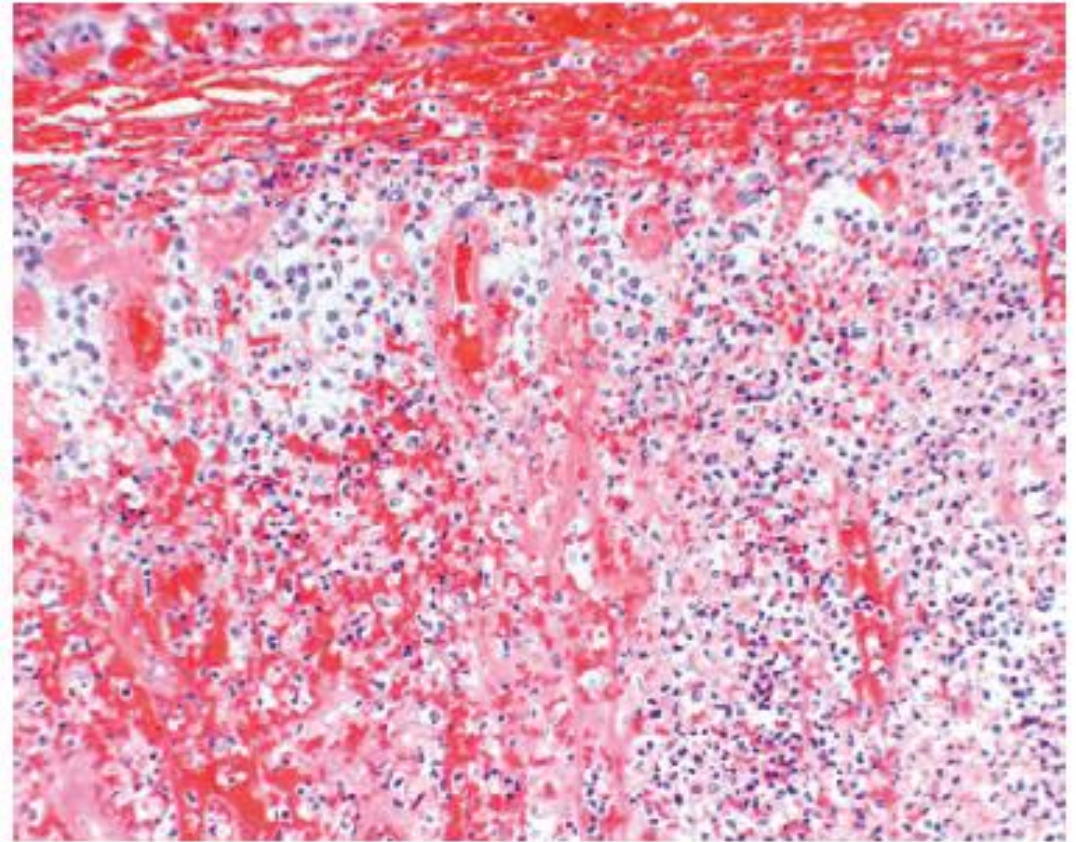
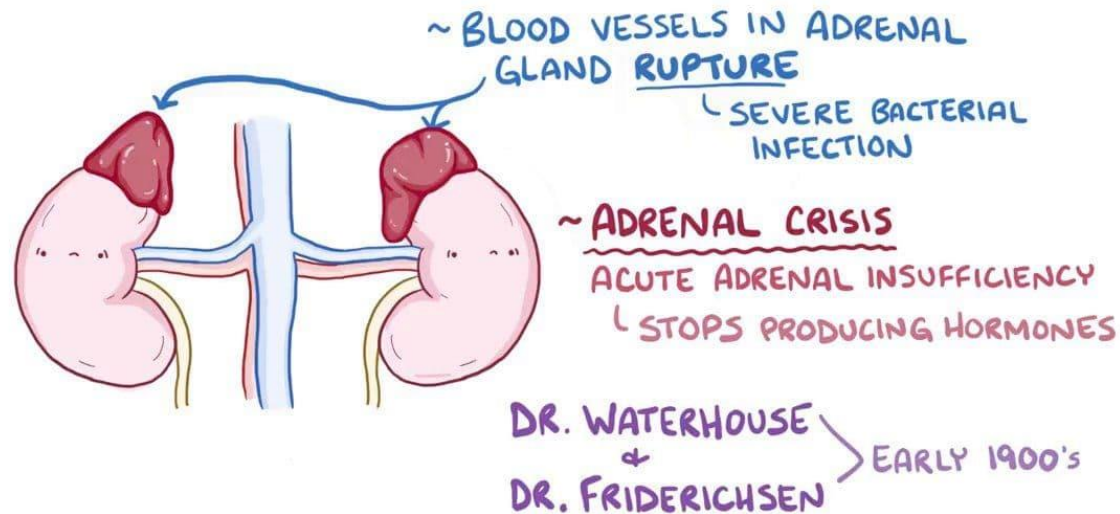


Figure 19-39 Waterhouse-Friderichsen syndrome. Bilateral adrenal hemorrhage in an infant with overwhelming sepsis, resulting in acute adrenal insufficiency. At autopsy, the adrenals were grossly hemorrhagic and shrunken; in this photomicrograph, little residual cortical architecture is discernible.

Addison's disease.

-Chronic adrenal cortical insufficiency , required immediate therapy .

-Progressive destruction of the adrenal gland.

******Causes include:**

1- Autoimmune cause: 60-70 % , may be sporadic or familial, linked to HLA-B8 or DR3 ,often multisystem involvement.

2- Infections e.g. Tuberculosis , fungi .

3- Metastatic tumors destroying adrenal e.g. lung ,breast , ...others

4- AIDS.

Morphology & Clinical features in Chronic Adrenal Insufficiency :

- Morphology depends on cause :

Autoimmune shows irregular small glands, with cortex heavily infiltrated by lymphocytes, medulla normal.

In T.B. → Caseating Granuloma

In metastatic CA → Type of primary tumor

In secondary to pituitary cause, the adrenal is shrunken

- In general, clinical manifestations of adrenocortical insufficiency do not appear until at least 90% of the adrenal is destroyed.

Adrenal tumor:

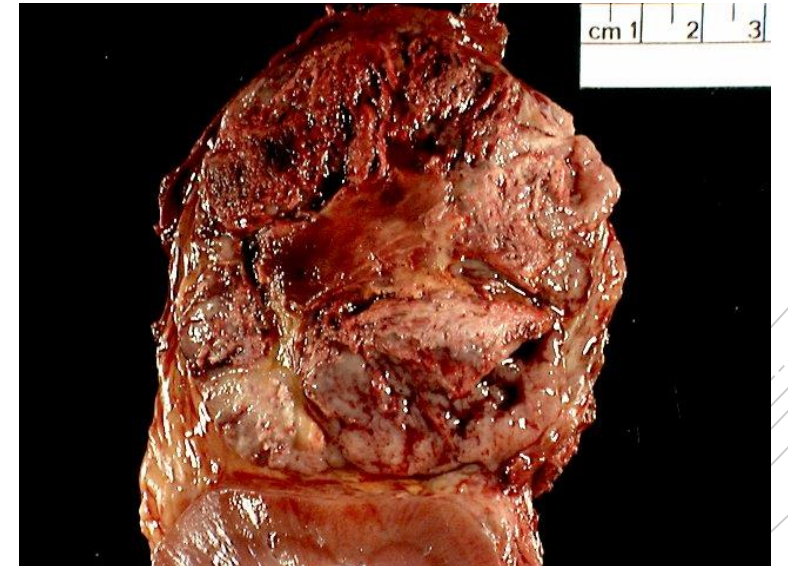
- ✓ **ADRENAL CORTICAL TUMORS**
- ✓ **ADRENAL MEDULLA TUMOR**

adrenalcortical tumors

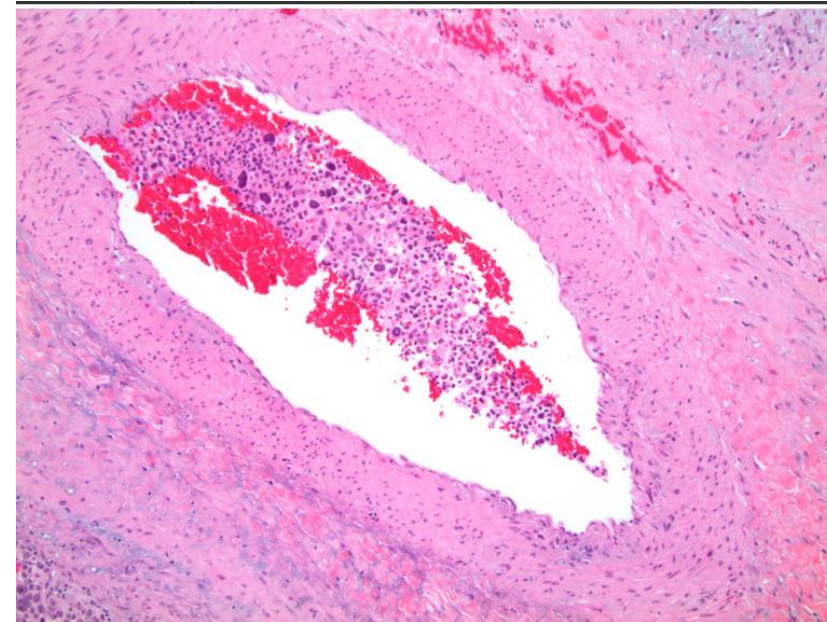
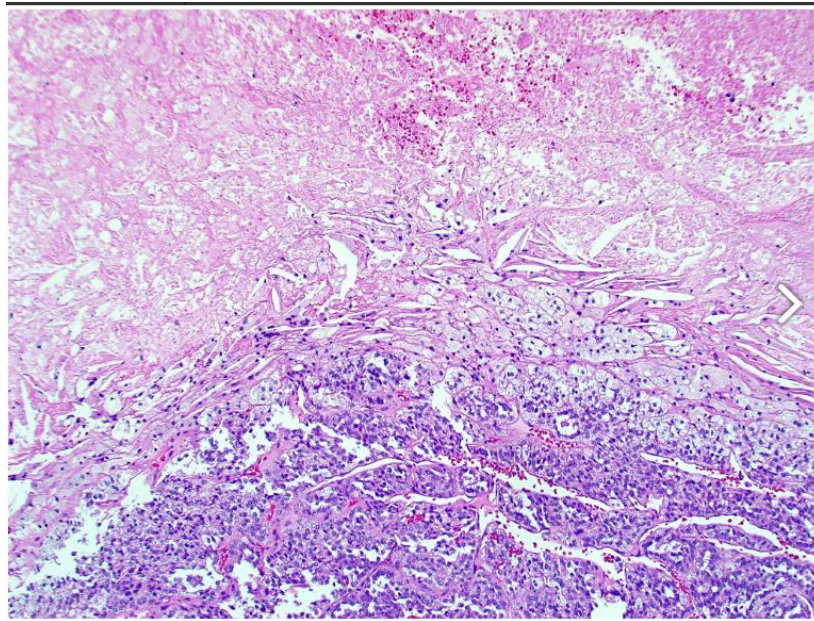
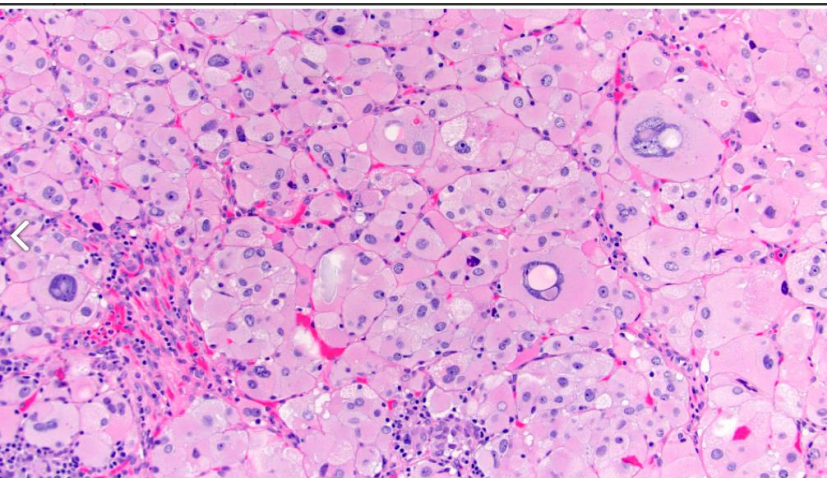
- Malignant epithelial tumor of adrenal cortical cells
- Adrenocortical carcinoma (ACC) is a rare endocrine tumor with high mortality
- More often involves left adrenal: left to right ratio = 1.2:1
- Functional adrenal cortical carcinomas have the following symptoms related to hormone production:
 - ❖ 50% cortisol excess (Cushing syndrome, rapid onset)
 - ❖ 20% sex hormone secretion (mainly androgens causing hirsutism, virilization and menstrual irregularities)
 - ❖ 8% aldosterone (hypertension, hypokalemia)

Morphology

- Encapsulated , usually yellow color: single or multiple.
- Size variable 1-2 cm, up to large tumors
- Malignant tumors may show necrosis, hemorrhage and are usually larger.



- Histology:
- Large cells with granular clear to eosinophilic cytoplasm, often pleomorphic.
- Invasion of thick fibrous capsule
- Lymphovascular invasion.
- Areas of necrosis, hemorrhage, degeneration are common

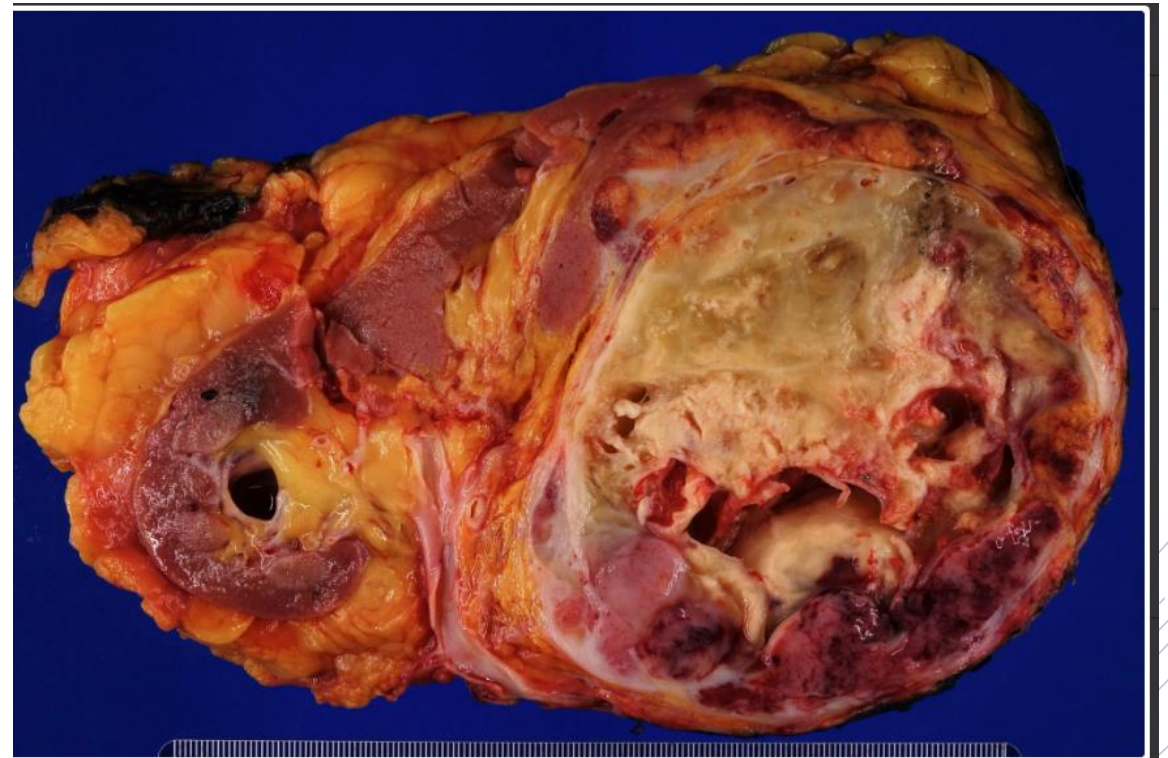

Tumor of the adrenal
medulla
pheochromocytoma

- Pheochromocytomas are neoplasms composed of chromaffin cells, which, like their nonneoplastic counterparts, synthesize and release catecholamin.
- Sometimes described as Rule of 10% Tumor because :
 - * 10% bilateral.,
 - 10 % multiple,
 - 10% non functional
 - * 10% familial, may be part of MEN syndrome.
 - * 10% Malignant.
 - * 10% extraadrenal site.
 - *25% associated with genetic mutation.

Morphology

- **well circumscribed, small to large in size**



Histology

- **Nested (zellballen), trabecular patterns.**
- Nests of cells (Zellballen) with abundant cytoplasm filled with granules containing catecholamine.
- Malignancy confirmed by METASTASES

