

QUIZ TIME ARCHIVE

Subject:

Anatomy

Done by

AYA ABU SAMRA

♡ (وَأَخِرُ دَعْوَاهُمْ أَنْ الْكَمْدُ لِلَّهِ رَبِّ الْعَالَمِينَ) ♡
♡ جَعَلَ اللَّهُ الْخِتَامَ مِسْكَ ♡

Lec 1

1) All the following statements are true EXCEPT : Select one:

- a . The false pelvis forms part of the abdominal cavity
- b . The pelvic outlet is diamond shaped
- c . The bony pelvis is composed by the two hip bones and the sacrum only
- d . The pelvic cavity lies between the inlet and the outlet
- e . The pelvic inlet synonym the pelvic brim

ans: c

2)The pelvic walls . Which is wrong :

- a . The piriformis muscles..... Posterior wall
- b . The obturator membrane Posterior wall .
- c . Levatores ani muscles inferior wall
- d . The pubic rami Anterior wall
- e . The sacrotuberous and sacrospinous ligaments ... Lateral wall

ans: b

Lec 2

1)All the following are posterior relation to the right kidney Except:

- a.The diaphragm
- b.The 11th rib
- c.12th rib
- d.The costodiaphragmatic recess of the pleura
- e. Quadratus lumborum

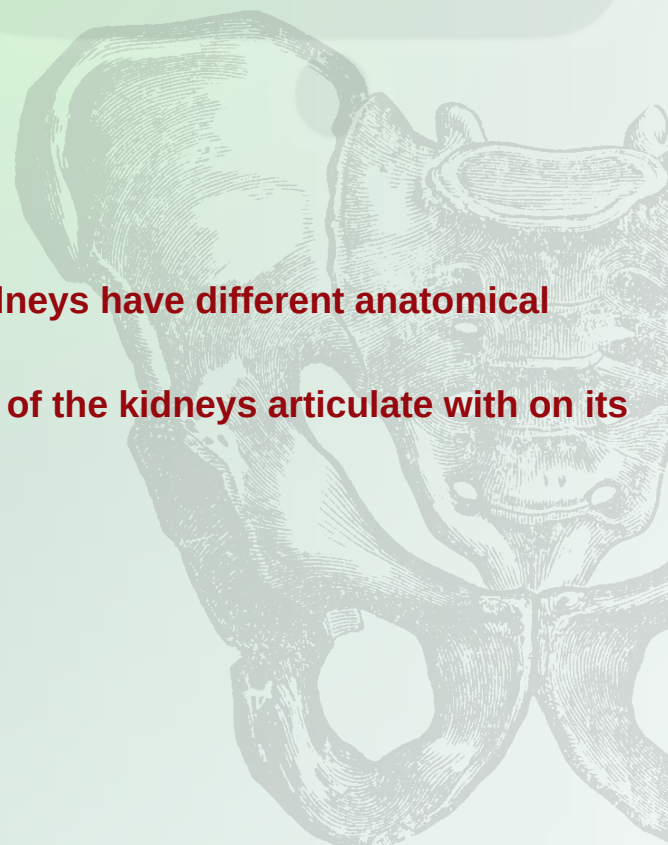

ans:b

2) Due to the asymmetry of the body, the two kidneys have different anatomical relations

Which of the following structures does only one of the kidneys articulate with on its respective : side ? Select one

- a . Diaphragm
- b. Rib 11
- c. Psoas major
- d . Quadratus lumborum
- e . Transversus abdominis

Ans:b



3) One of the following is not true regarding the relations to anterior wall of the left kidney :

- A- coils of small intestine related to lower medial part
- B- body of pancreas to middle part
- C- descending colon to lower medial part
- D- stomach between left suprarenal gland and spleen
- E- spleen related to upper lateral part

Ans : c



Lec 3

1) Regarding the Ureter, one of the following statements is incorrect : Select one :

- a. ureter lies posterior to parietal peritoneum
- b. Crosses bifurcation of aortic artery
- c. lies anterior to sacro -iliac joint.
- d. lies on Lateral wall of pelvis towards ischial spine.
- E. Enter inferior surface of bladder at trigone

Ans : b *Crossing bifurcation of common iliac artery*

2) The muscle of the bladder wall is called :

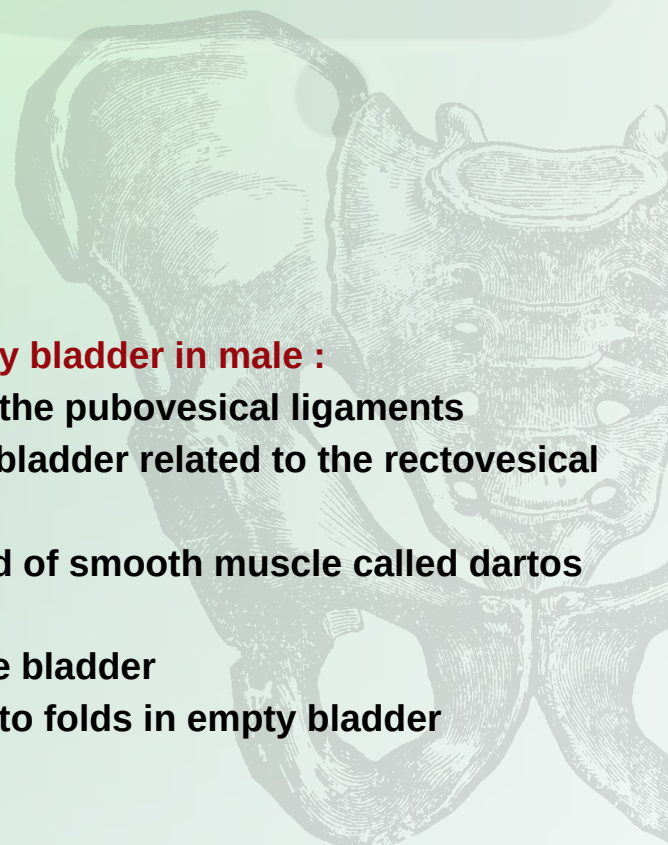
- a. Detrusor muscle
- b. Dartos
- c. Trigon muscle
- d. Rugae
- e. sphincter muscle

Ans : a

3) Select the true statement regarding the urinary bladder in male :

- a. The neck of the bladder is held in position by the pubovesical ligaments
- b. The lower part of the posterior surface of the bladder related to the rectovesical pouch
- c. The muscular coat of the bladder is composed of smooth muscle called dartos muscle
- d. The sphincter vesicae found in the neck of the bladder
- e. The mucous membrane of trigon is thrown into folds in empty bladder

Ans: d

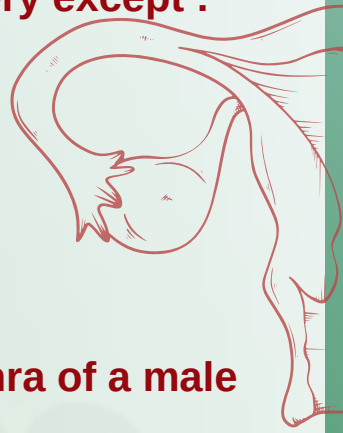


Lec 4

1) All of the followings are branches of internal pudendal artery except :

- A- Perineal artery
- B- Inferior rectal artery
- C- Middle rectal
- D- Artery of the bulb
- E- Deep artery of the clitoris.

Ans: c



2) All of the following statements are True related to the urethra of a male except : Select one :

- a . The prostatic urethra It is about 1.25 inches long .
- b. The membranous urethra is about 1.25 cm long.
- c . . The external meatus is the widest part of the entire urethra .
- d. The part of the urethra that lies within the glans penis is dilated to form the fossa terminalis.
- e. It is approximately 20 cm long in an adult .

Ans : c

2) Regarding the female urethra, the following statements are INCORRECT, EXCEPT :

- a. Is about 1.5 cm long
- .b. It extends from the neck of the bladder to the external meatus
- .c. It opens into the vestibule about 1cm below the clitoris
- .d. It lies immediately dorsal to the vagina
- .e. The ducts of the paraurethral glands at the sides of the neck of bladder

Ans: b

Lec 5

1) The Male superficial perineal pouch contains which of the following structures ?

- a . Prostate
- b . Bulbourethral glands
- c . Membranous urethra
- d . Ischiocavernosus muscle
- e . Deep transverse perineal muscles

ans: d

2) All the following statements are true regarding the male perineum EXCEPT ?

- a . Ischiocavernosus muscle assist in the process of erection of the penis
- b . Sphincter urethrae muscle surrounds urethra in the deep perineal pouch
- c . The bulb of penis situated in the midline the urogenital diaphragm

