

Anal and perianal conditions

Dr.Mahmoud Awaysheh
General & Colorectal Surgery.

proctitis :- inflammation of Rectum

Typhlitis :- inflammation of Cecum

Objectives

- Understand the **anatomy** of the anus and anal canal and their relation to common perianal pathologies
- Know well the common anal and **perianal pathologies**, their diagnosis and treatment
- Know the differential diagnosis of common perianal pathological presentations
- Have an idea about the less frequent perianal pathologies

Anal canal

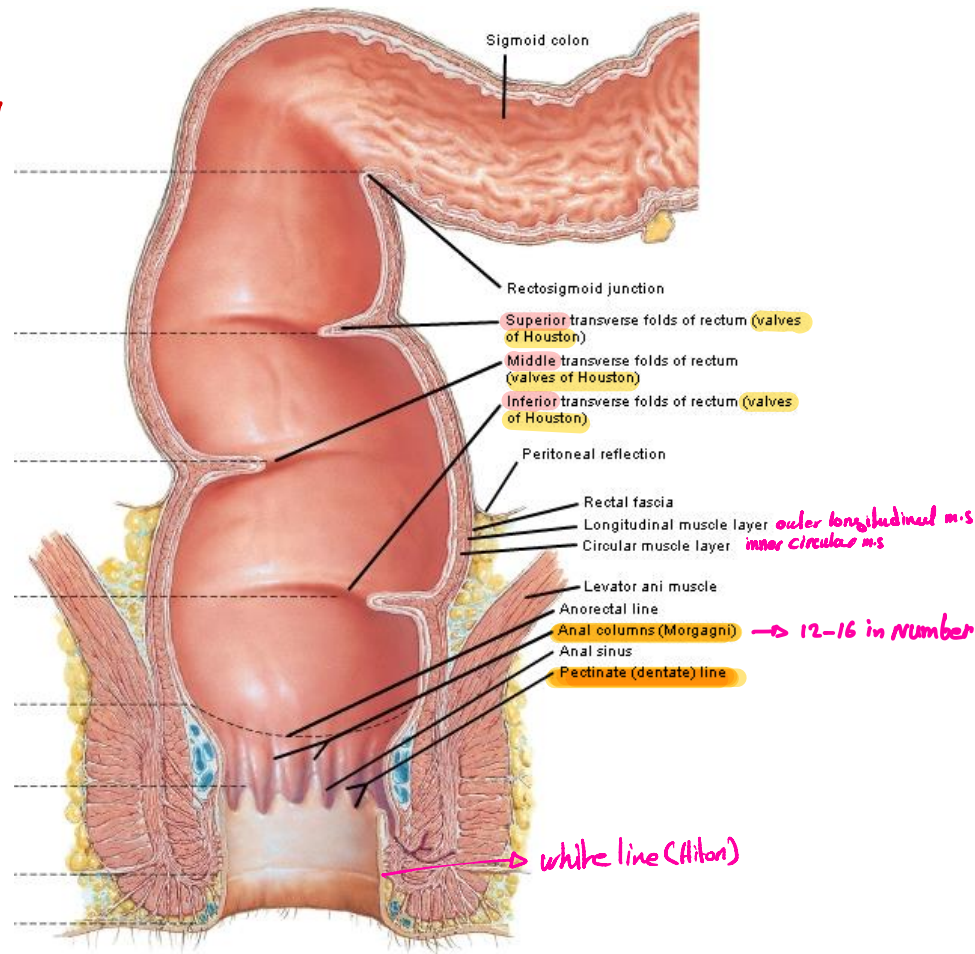
- **Beginning:** 2.5 cm below and anterior to the tip of the coccyx at the recto-anal junction.
- **Length:** 4 cm long
- **Course:** It runs down and backwards.
- **Termination:** It ends at the anus.
- **Relations:**
 - **Laterally:** Ischioanal fossae.
 - **Posteriorly:** Anococcygeal raphe between it and tip of coccyx.
 - **Anteriorly:** Perineal body between it and bulb of penis in males.
Perineal body between it and vagina in females.

Rectum Long :- 20cm

Surgery for Rectum

- High Ant Resection { sigmoid + upper Rectum resection }
- Low Ant Resection { sigmoid + Rectum resection }
- Rectoperineal Resection { sigmoid + Rectum + perineum resection }

layer of serosa in Rectum and esophagus
is not other site Bcz of This layer
Anastomosis Failure is common in
Both of These ① Rectum
② Esophagus



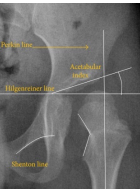Anal sphincters:

Internal anal sphincter:

- It is the thickened inner involuntary circular muscle layer of the anal canal.
- Surrounds** the upper 3/4th of the anal canal, extending from ano-rectal junction till the white line (Hilton's line).

في البيسك كان $\frac{2}{3}$ upper

Nerve supply: autonomic *Not shendon line which used in DDH in Radiology* *في الال احنا في الاشعة*



External anal sphincter:

- Striated voluntary muscle fibers.
- Surrounds** the **whole length** of the anal canal **outside** the internal anal sphincter.

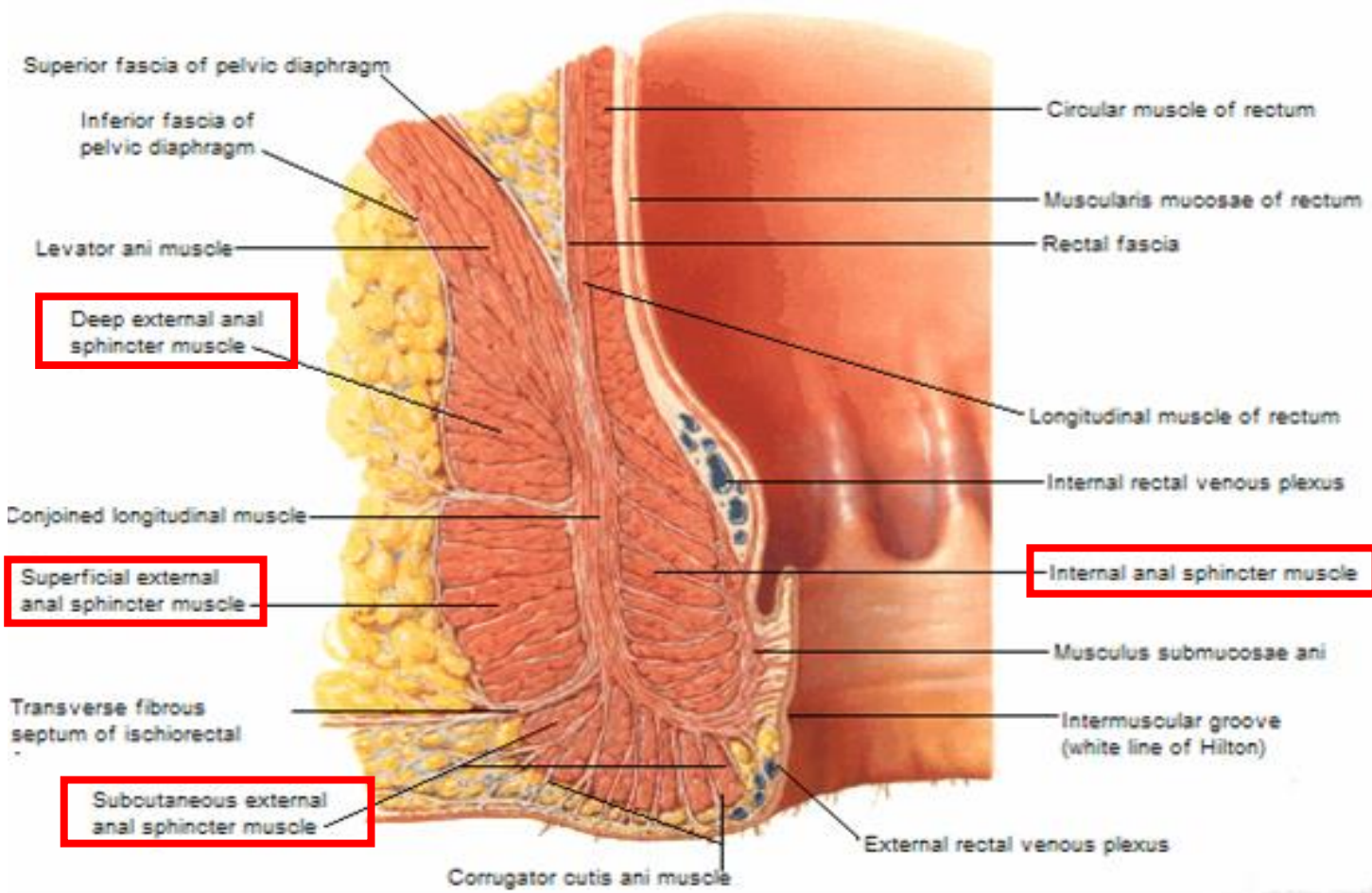
-Parts: I) Subcutaneous Part:

- Surrounds the anus just under the perianal skin.
- Attached to perineal body & anococcygeal raphe.

II) Superficial Part:

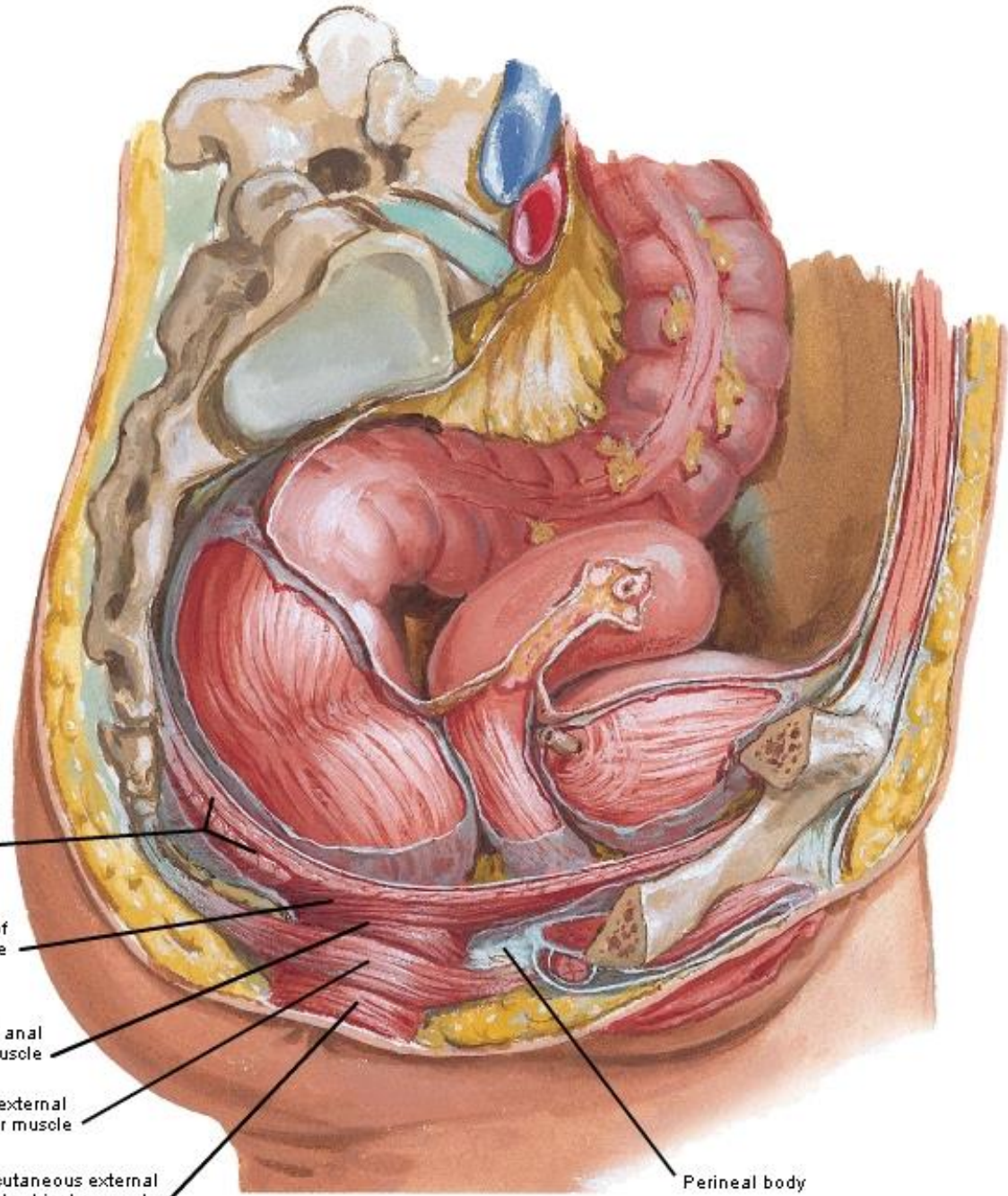
- Surrounds the lower part of the internal sphincter above the subcutaneous part.

III) Deep Part



{ 2 }

{ 1 }



Coccyx

Levator ani
muscle
(pelvic
diaphragm)

Puborectalis part of
levator ani muscle

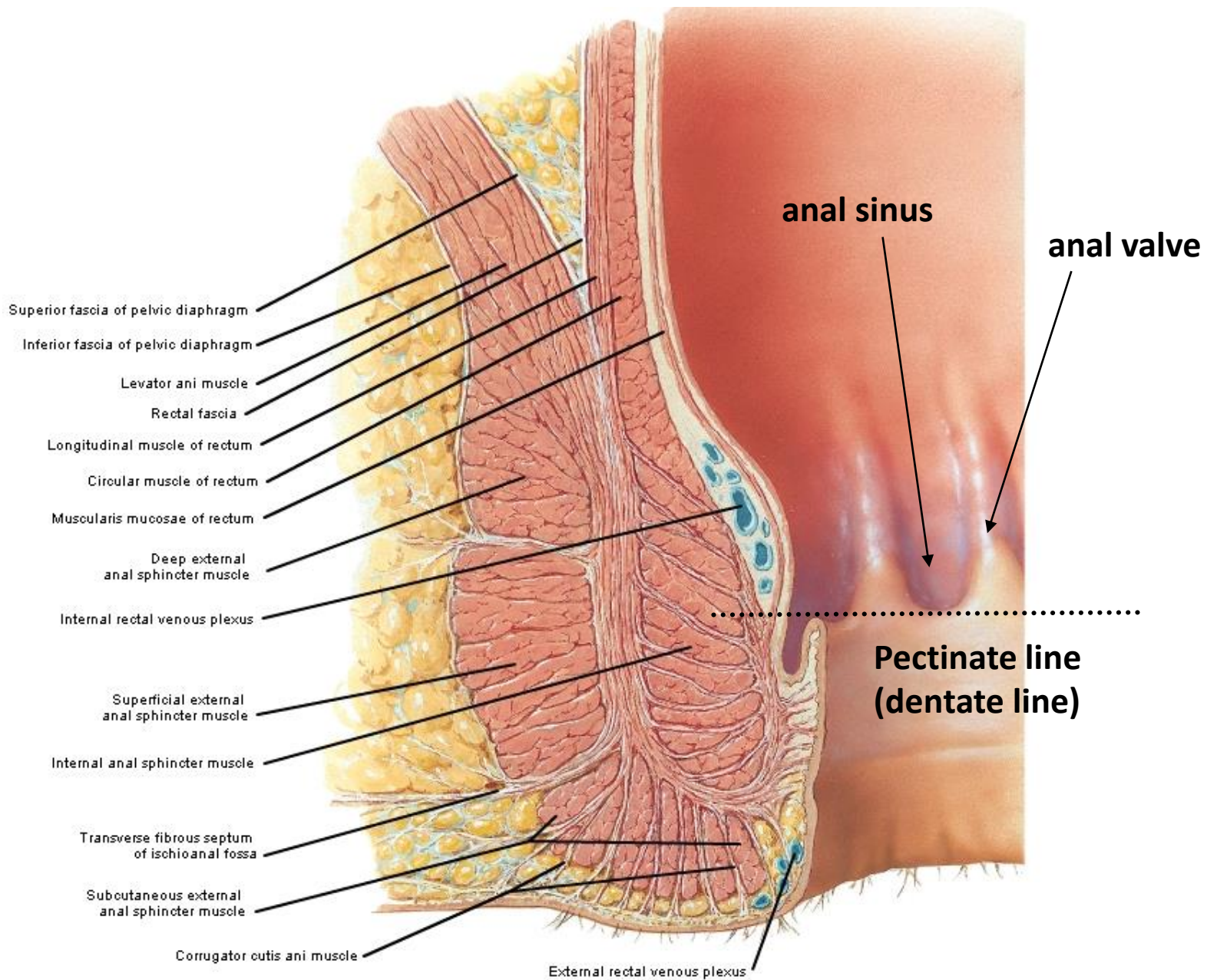
Deep external anal
sphincter muscle

Superficial external
anal sphincter muscle

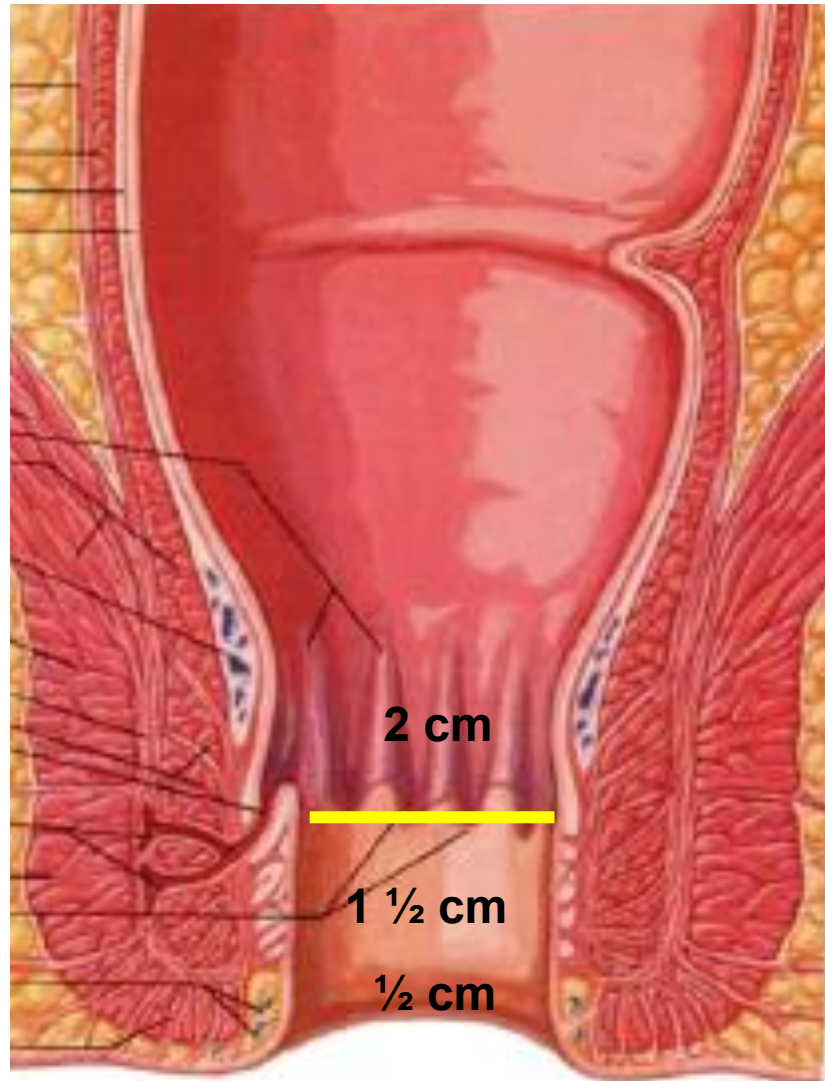
Subcutaneous external
anal sphincter muscle

Perineal body

**The external sphincter
(voluntary)**



Vessels and nerves of the anal canal



internal Hemorrhoids common in 3, 7, 11 o'clock

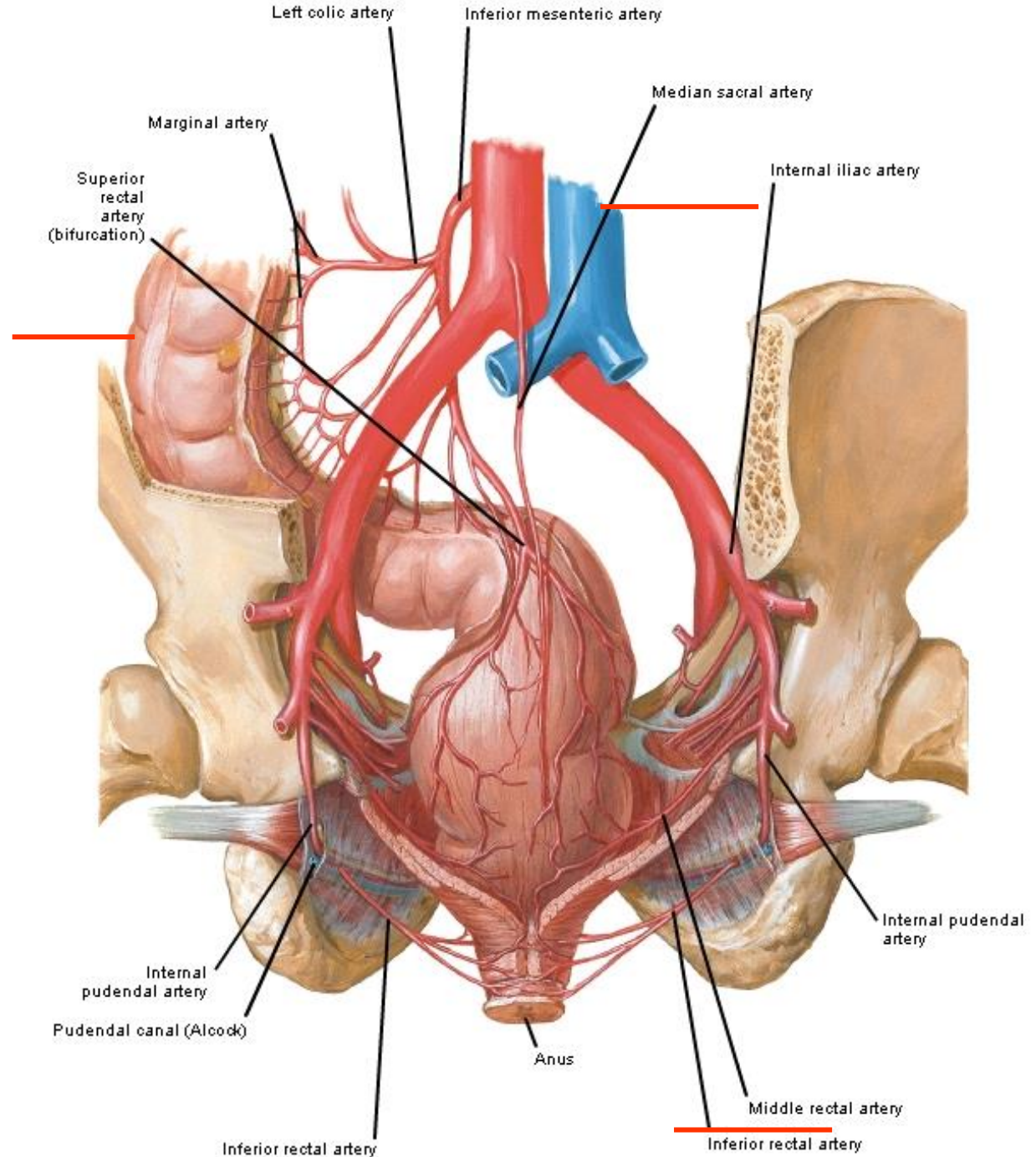


Blood supply, nerve supply and lymph drainage of anal canal:

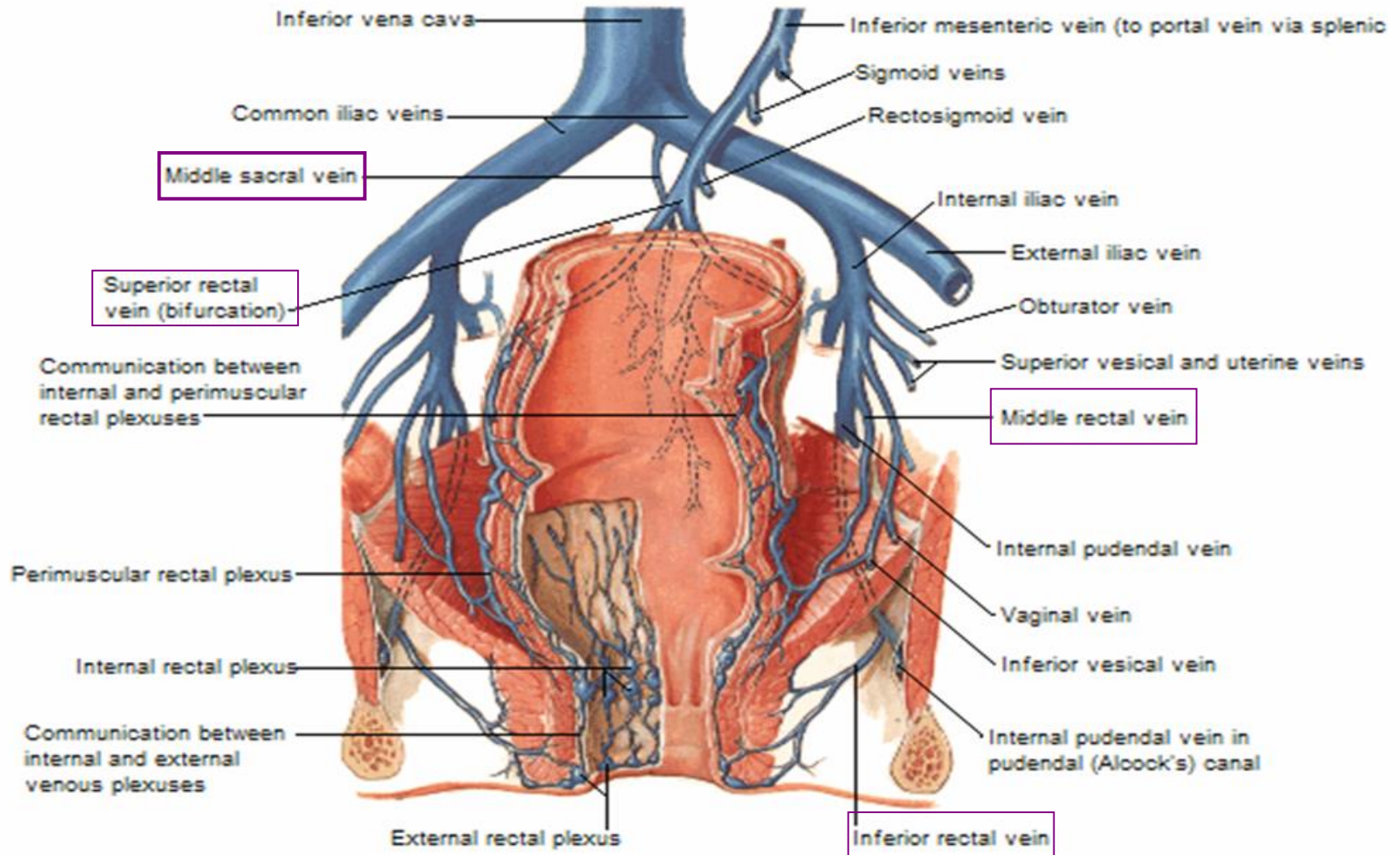
	Upper part	Lower part
Blood supply	<p>-It is supplied by <u>superior rectal artery</u>. of <i>inferior mesenteric Art</i></p> <p>- It is drained by superior rectal vein (portal circulation).</p>	<p>-It is supplied by:</p> <ol style="list-style-type: none">1- <u>Middle rectal artery</u> of <u>internal iliac artery</u>.2. <u>Inferior rectal artery</u> of <u>internal pudendal artery</u>. of <i>internal iliac</i> <p>-The corresponding veins drain into internal iliac vein (systemic circulation.)</p>
Nerve supply	<p><u>Above pectinate line by autonomic nerve fibers.</u></p>	<p><u>Below pectinate line by inferior rectal nerve</u> (Sensitive to pain & touch).</p>
Lymphatic drainage	<p>Above pectinate line into <u>internal iliac LNs</u>.</p>	<p>Below the pectinate line into <u>superficial inguinal LNs</u>.</p>

Arterial supply of the rectum and anal canal

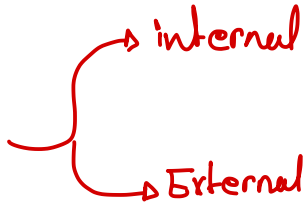
- superior rectal artery (inferior mesenteric)
- middle rectal artery (internal iliac)
- inferior rectal artery (internal pudendal)

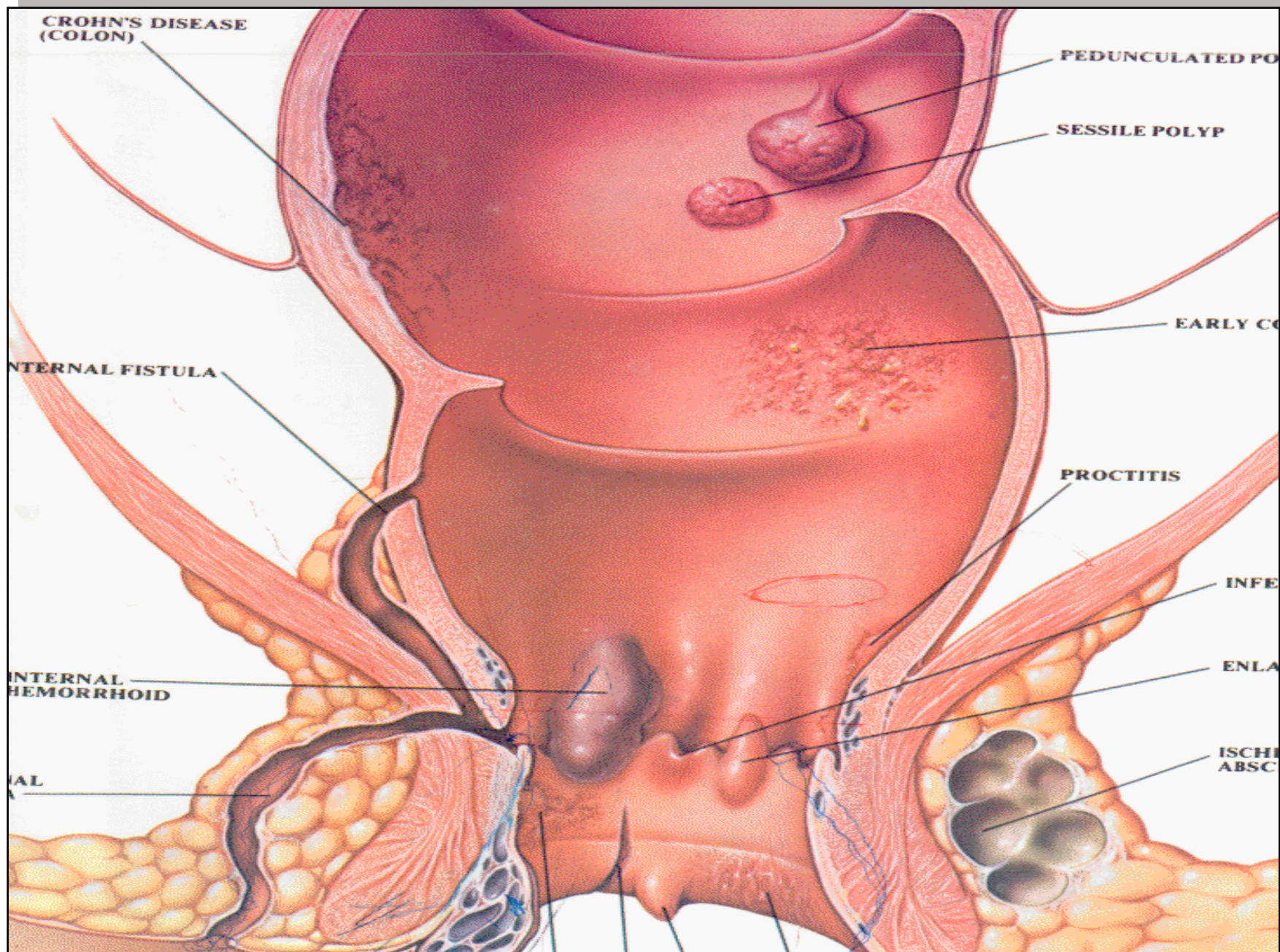


Veins of the rectum



Common anal and perianal conditions

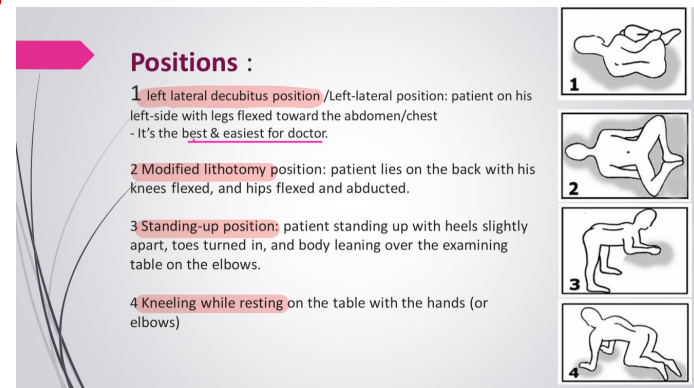
- Hemorrhoids 
 - ↳ internal
 - ↳ External
 - Perianal abscesses and fistulas
 - Anal fissure
- 4 grades of Hemorrhoid*



EXAMINATION OF THE ANUS

- ✱ inspection
- ✱ digital examination with index finger
- ✱ proctoscopy
- ✱ sigmoidoscopy

↓
position for DRE to examine Hemorrhoid



HAEMORRHOIDS

Piles may be internal or external according to whether they are internal or external to anal orifice.

The internal Haemorrhoids: most common in 3, 7, 11 o'clock

They are dilation of the superior haemorrhoidal veins above the dentate line each pile consists of mass of dilated ¹vein, ²artery, some ³connected tissues and mucosal investment.

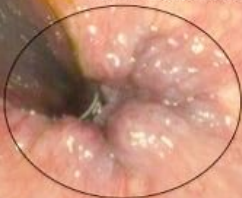- Asymptomatic تكون Asymptomatic و بتشكل نسبة 10%
• may confused with Malignant Melanoma
so when we resect Hemorrhoid usually we do Biopsy to Distinguish it from malignant Melanoma

External Haemorrhoids: (Perianal Haematoma)

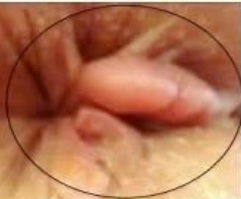due to rupture of dilated anal vein as result of sever straining.

- ✱ sudden onset of painful lump at the anus.
- ✱ swelling tense & tender, bluish in colour covered with smooth shining skin.
- ✱ Treatment: LA evacuation if the patient come within 48h⁰, if patient come late conservative treatment.
- ✱ if untreated the haematoma undergoes:
 - resolution
 - ulceration
 - supporation
 - fibrosis which give rise to skin tag

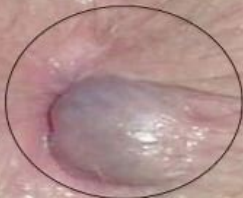Internal Hemorrhoids



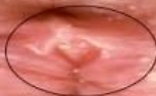Skin Tag



External Hemorrhoids



Anal Fissure

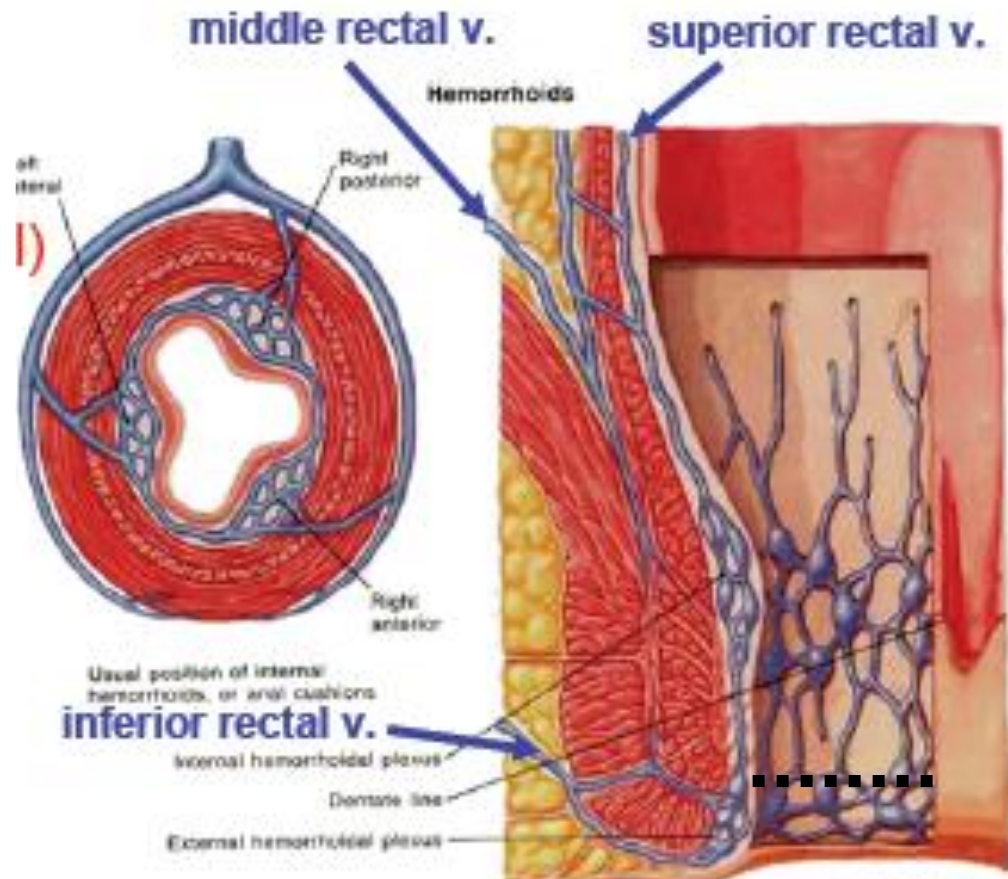


Internal hemorrhoids

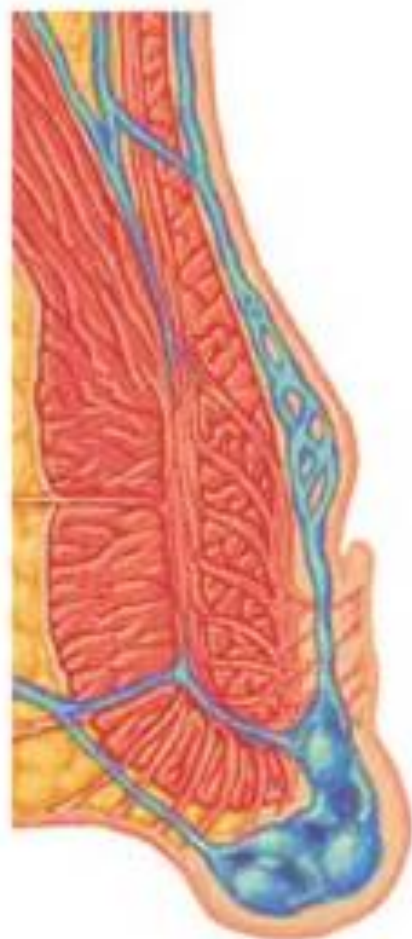- Tributary of sup rectal
- Above white line
- Generally painless

External hemorrhoids

- Tributary of inf rectal
- Below white line
- Generally painful

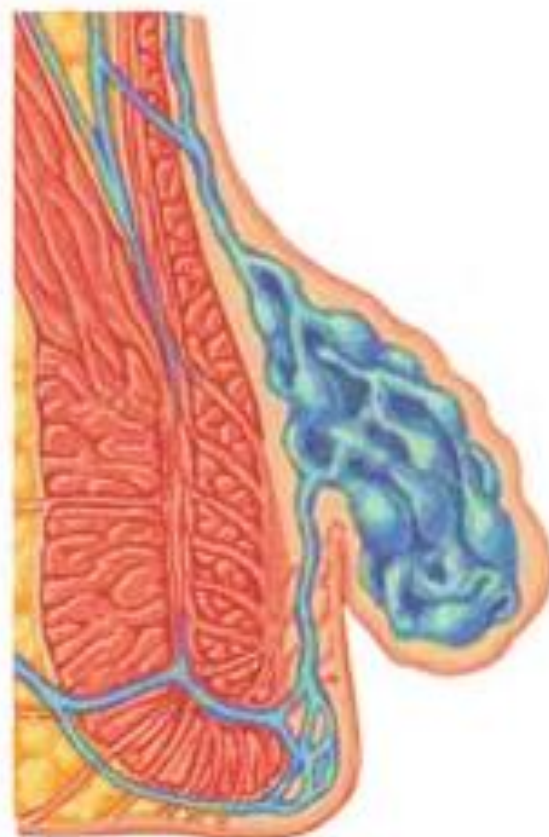

External hemorrhoid



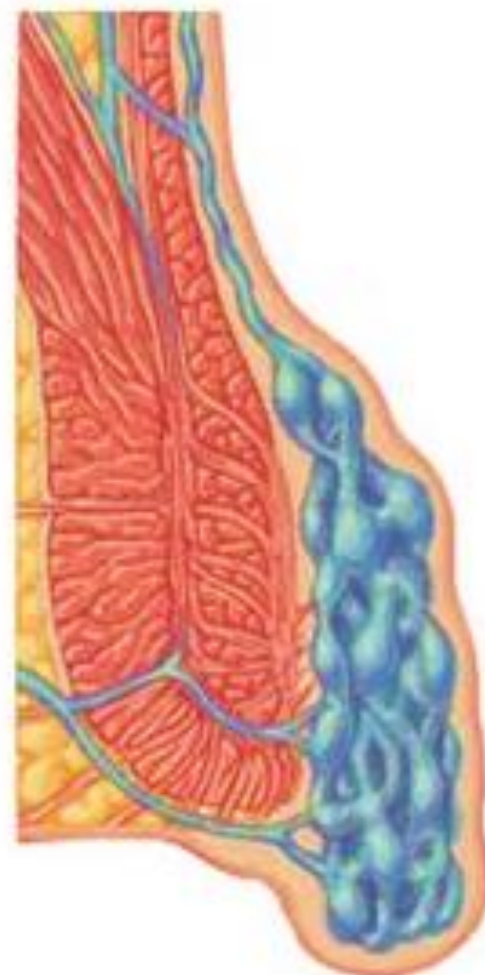
Origin below dentate line
(external rectal plexus)

Internal hemorrhoid



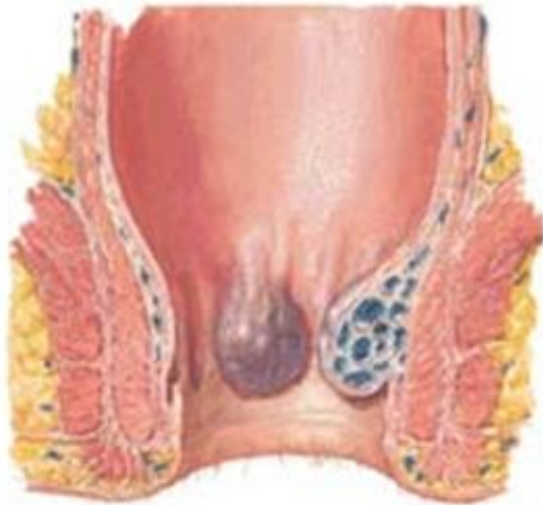
Origin above dentate line
(internal rectal plexus)

Mixed hemorrhoid

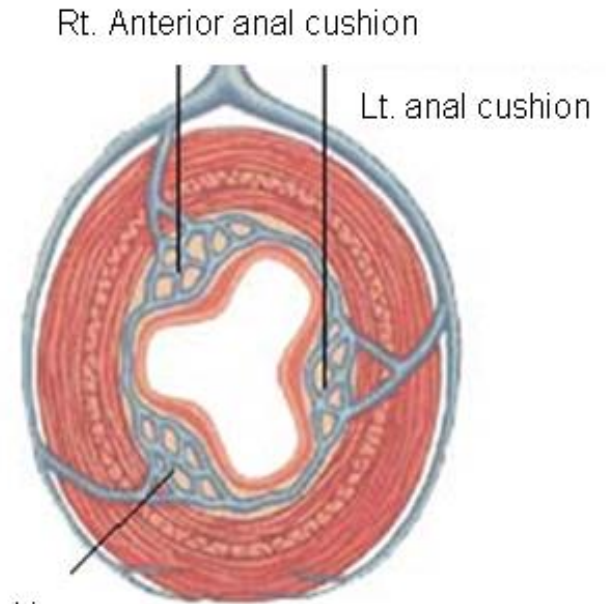


Origin above and below dentate line
(internal and external rectal plexus)

location of piles

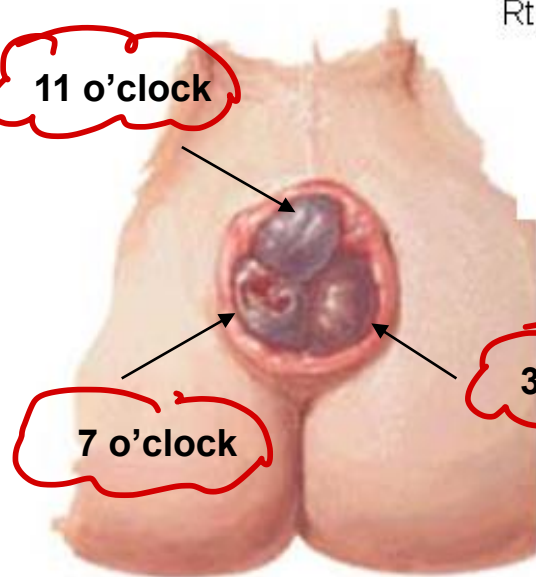


Enlarged anal cushions



Rt. Posterior anal cushion

11 o'clock



7 o'clock

3 o'clock

**Usual position of anal cushions and sites
of prolapse for internal hemorrhoids**

Prolapsed "rosette" of internal hemorrhoids

Internal Hemorrhoids

F. Netter
©Novartis

John A. Craig
©Novartis

Grades

T_x

- I- Hemorrhoids only bleed → spontaneous Disappear
 - II- Prolapse and reduce spontaneously
 - III- Require replacement
↳ prolapse and Reduce By Hands
 - IV- Permanently Prolapsed
- ↳ injection of phenol + Alkamouth oil
if Not works → surgery
- Hemorrhoidectomy

most common complication of Hemorrhoidectomy is ??

- Urinary Retention

Other Complication:-

- Bleeding \approx 1000 After 4 hr post-op
- Stricture
- Recurrence

Aetiology of Haemorrhoids






• Primary Causes:

These are attributed to several predisposing causes:

- ◆ Hereditary factors e.g, structural weakness of the vein.
- ◆ Anatomical factors.
- ◆ Partial congestion.
- ◆ Chronic constipation.
- ◆ Sphincteric relaxation.

• Secondary Causes

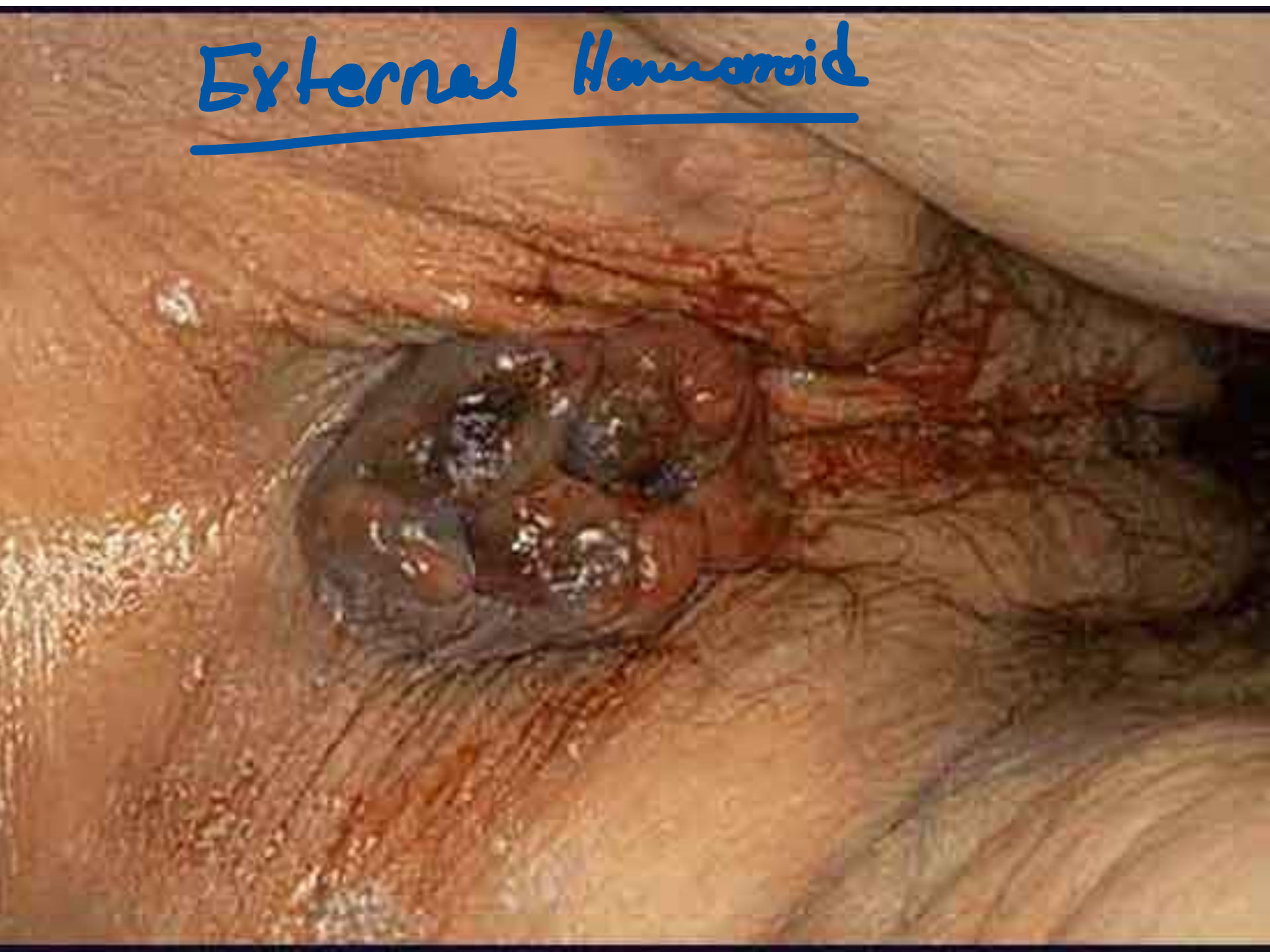These are due to underlying organic cause such as;

-  pregnancy
-  venous obstruction
-  straining on micturation
-  venous congestion
-  carcinoma of the rectum

Symptoms

- Rectal Bleeding
- Red blood in stool
- Pain during bowel movements
- Anal Itching
- Rectal Prolapse
- Thrombus

External Hemorrhoid



Prevention

- High fiber diet
- Drink Plenty of Liquids
- Fiber Supplements
- Exercise
- Avoid long periods of standing or sitting
- Don't Strain
- Go as soon as you feel the urge *go to Defecate*

TREATMENT

- varies from simple reassurance to operative hemorrhoidectomy.
- Treatments are classified into three categories:
 - 1) Dietary and lifestyle modification.
 - 2) Non operative/office procedures.
 - 3) Operative hemorrhoidectomy.

Treatment Non-surgical

- Mild cases (GI & II) are controlled by:
 - Preventing constipation
 - Drinking Fluids
 - High-fiber diet
 - Use of Fiber supplements
 - Stool softeners

Treatments

- For painful or persistent hemorrhoids: (III & IV)
 - Tying off a hemorrhoid
 - Sclerotherapy
 - Infrared Light
 - Laser Therapy
 - Freezing
 - Electrical Current
 - Surgery (hemorrhoidectomy)

ANORECTAL ABSCESSES AND FISTULA-IN-ANO

INTRODUCTION

- Both abscess and fistula-in-ano can be considered simultaneously.
- The abscess is an acute manifestation, and the fistula is a chronic condition.

ETIOLOGY

- Nonspecific :
Cryptoglandular in origin.
- Specific :
Crohn's
Ulcerative colitis
TB
Actinomycosis
Carcinoma
Trauma
Radiation
Foreign body
Lymphoma
Pelvic inflammation
Leukemia

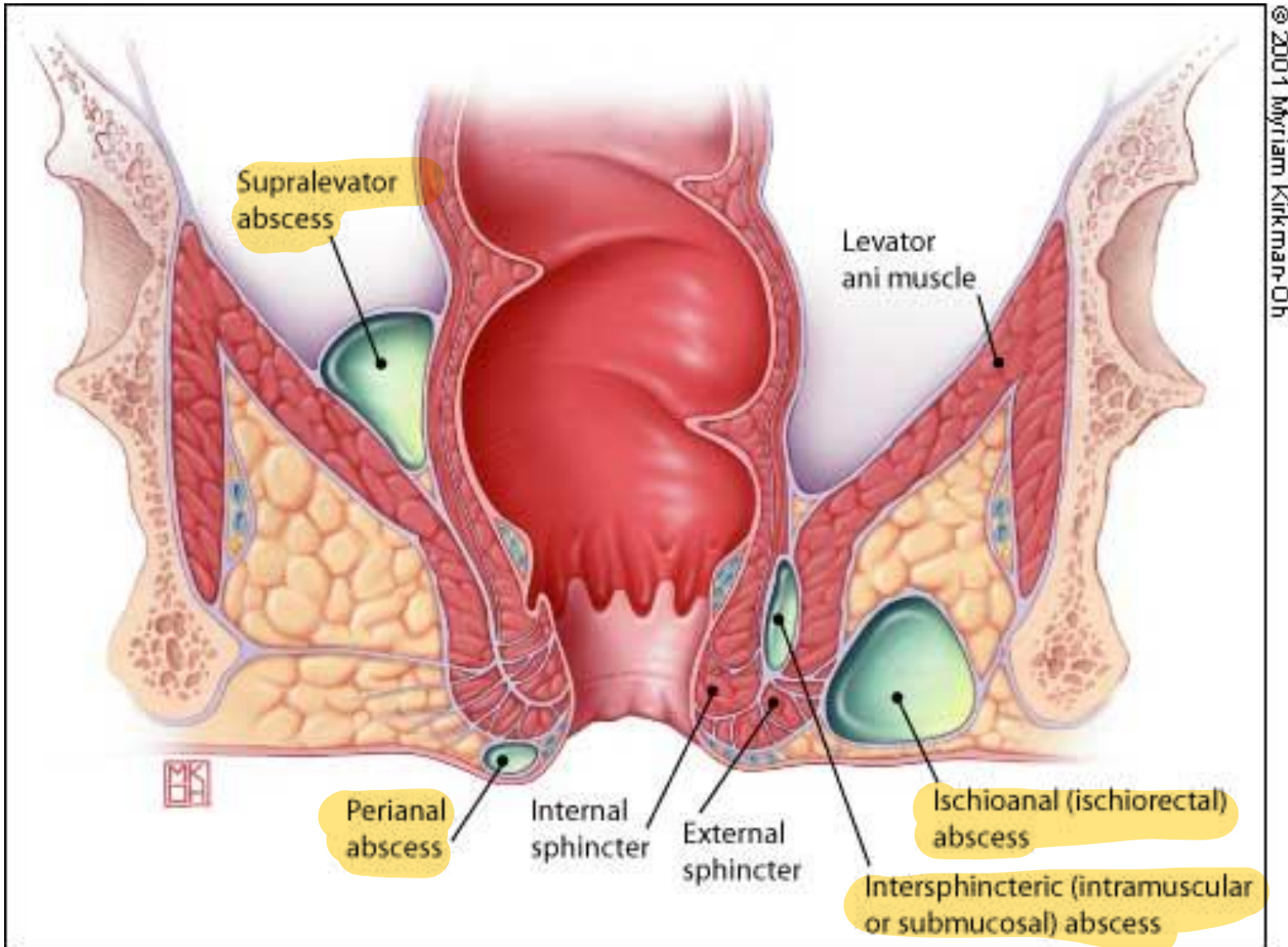
PATHOGENESIS

- The *cryptoglandular* hypothesis states that infection of the anal glands associated with the anal crypts is the primary cause of anal fistula and abscess.

Perianal Abscess

- Remains one of the more common anorectal conditions encountered in practice
- Abscesses are classified into:
 - Perianal 60%
 - Ischiorectal 20%
 - Intersphincteric
 - Supralevator

CLASSIFICATION



TREATMENT

- Incision and drainage. دايما هاد العلاج
- Determine the most tender point, a 2 cm area of skin is injected with local freezing.

incision

- Eliptical or cruciate incision.

Drainage

- Drainage of pus. Destroy all loculations.

ANTIBIOTICS

indication of Antibiotic!:-

- Immunosuppression.
- Valvular disease.
- Diabetics.
- Extensive disease
- Systemic manifestation.

→ Abnormal communication BTW 2 epithelial surface

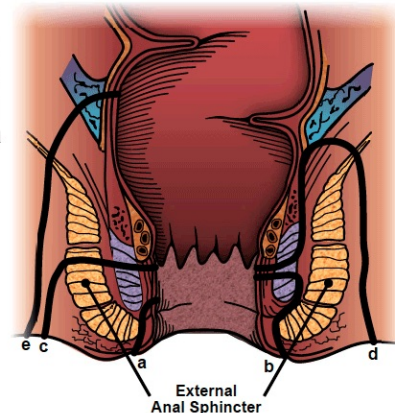
Fistula-in-Ano

p.t with DM or immunocompromized if they have Abscess this will lead to fistula in 60% of p.t (more liable)

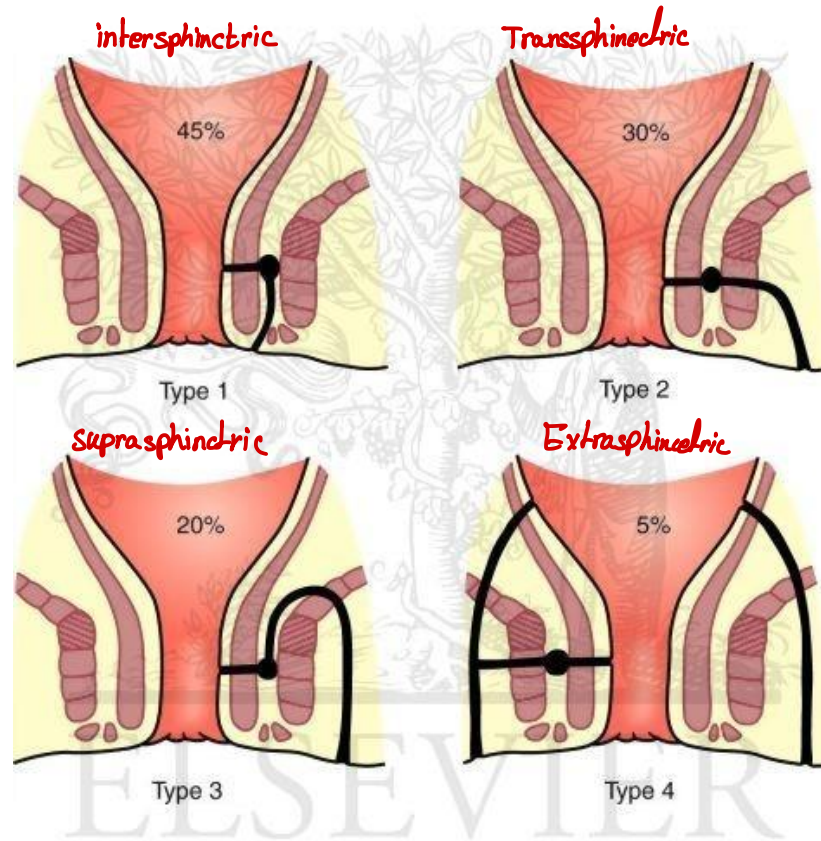
- In approximately 30% to 50% of patients with an anorectal abscess fistula-in-ano, develops
- No definitive way to predict:
 - Who will develop one
 - Or how to prevent one
- Fistulas are categorized based on their anatomical course relative to the sphincter complex: (Parks)

- Intersphincteric
- Transsphincteric
- Suprasphincteric
- extrasphincteric

a: superficial fistula
b: intersphincteric fistula
c: transsphincteric fistula
d: suprasphincteric fistula
e: extrasphincteric fistula

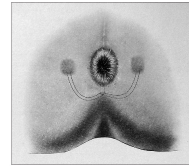


Anatomical Classification



©ELSEVIER, INC. – ELSEVIERIMAGES.COM

Fistula-in-Ano

- Fistulas can also be classified as “simple” or “complex”
- **Simple fistulas includes:**
 - Low transsphincteric
 - Intersphincteric fistulas that cross 30% of the external sphincter
- **Complex fistulas includes:**
 - High transsphincteric fistulas with or without a high blind tract
 - Suprasphincteric
 - Extrasphincteric fistulas
 - Horseshoe fistulas → 
 - Associated with inflammatory bowel disease, radiation, malignancy, preexisting incontinence, or chronic diarrhea
 - Fistulas in the anterior sphincter complex in women may be considered complex as well.

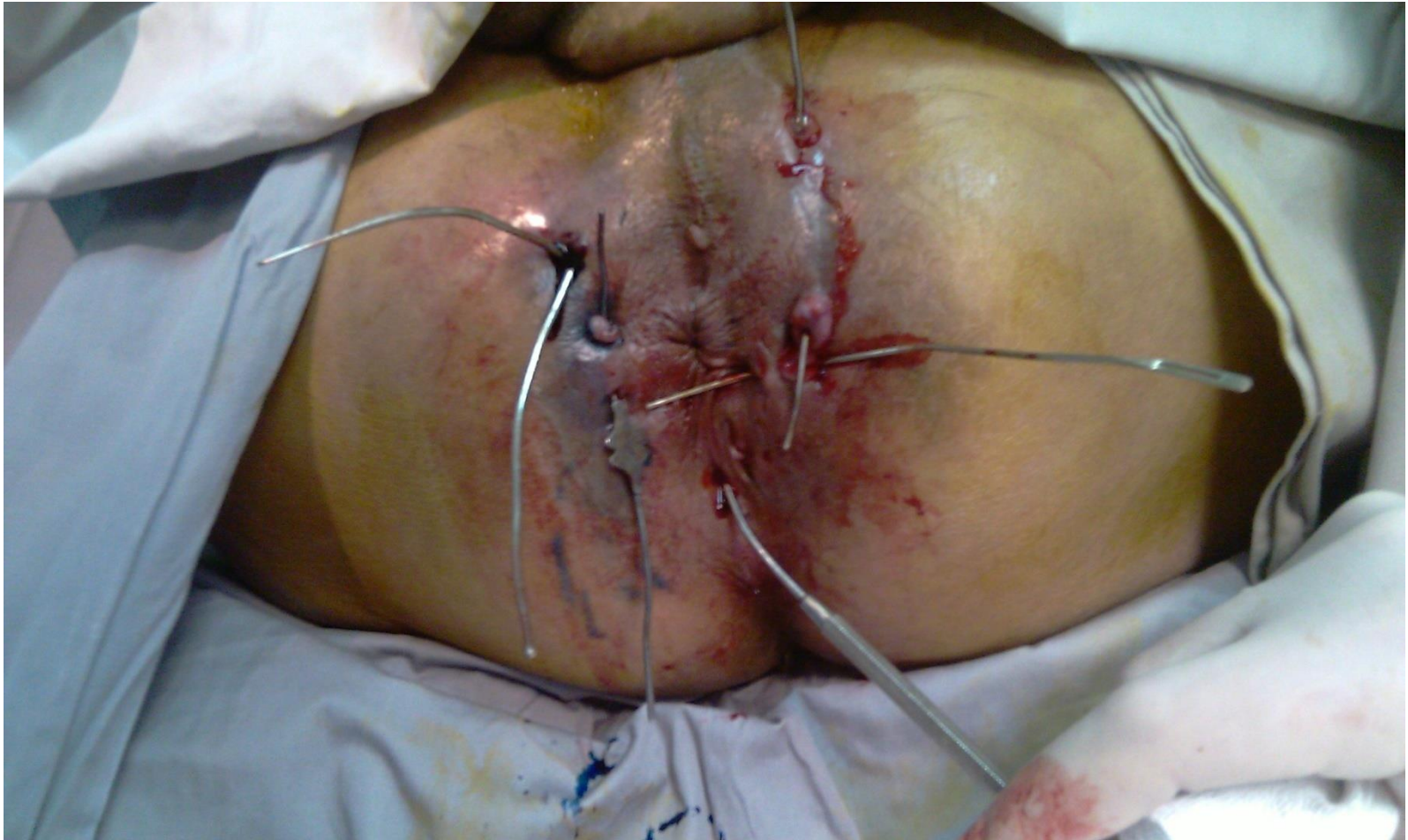- Types of Anal Fistulas


According to whether their natural opening is below or above the **anorectal ring**

Low level e.g., subcutaneous, low anal, sub mucous.

High level – open into anal canal at or above the anorectal ring e.g., high anal, pelvirectal

Complex Fistula Malignancy

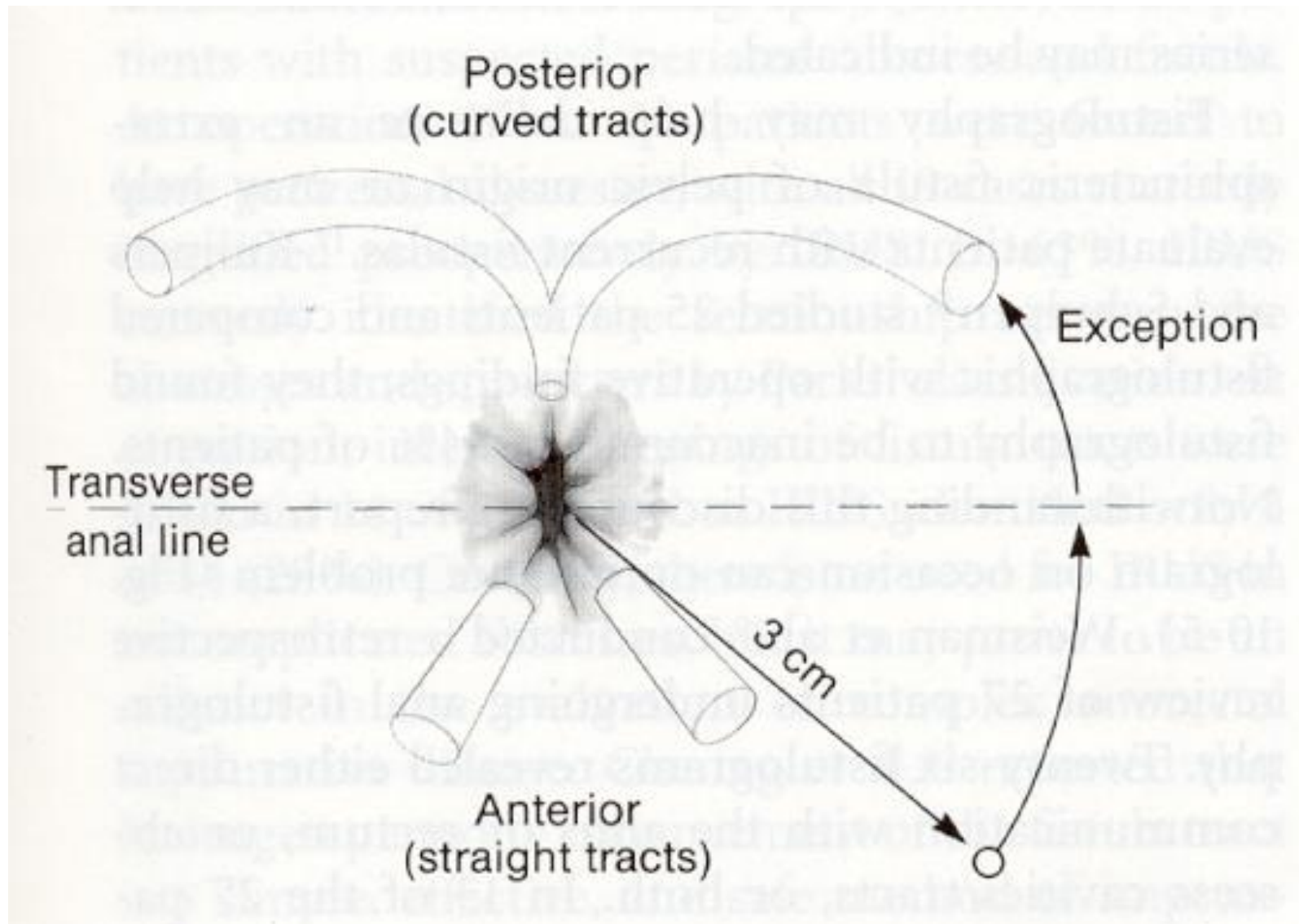




Evaluation of Anal Fistula

- An accurate preoperative assessment of the *anatomy* of an anal fistula is very important.
- *Five essential points* of a clinical examination of an anal fistula :
 - (1) location of the *internal* opening.
 - (2) location of the *external* opening.
 - (3) location of the *primary* track .
 - (4) location of any *secondary* track.
 - (5) determination of the presence or absence of underlying disease .

Goodsall's rule



TREATMENT

- The objective is to cure with lowest possible recurrence rate and minimal, if any, alteration in continence, shortest period.
- The principles are:
 - 1- Identification of the primary opening.
 - 2- Relationship to puborectalis
 - 3- Least amount of muscles should be divided.
 - 4- Side tracts should be sought,
 - 5- Presence of underlying disease.

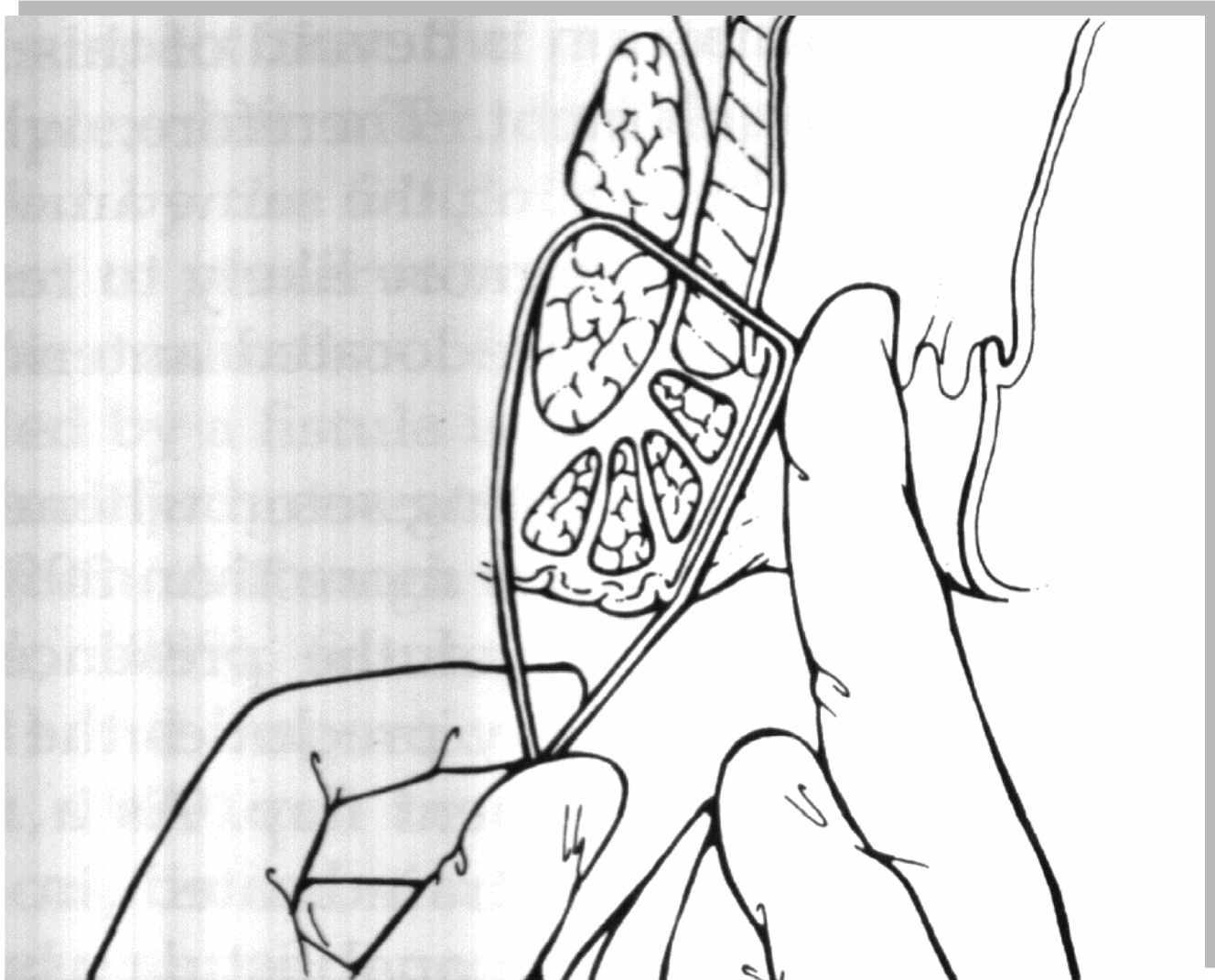
Fistulotomy/fistulectomy

Fistulotomy → بنحیدر ال internal and External opening وبعدين ما بنخيطه بنحليقة الة يلتأم بال 2ry Healing ع

- The laying-open technique (fistulotomy) is useful for 85-95% of primary fistulae .
- Curettage is performed to remove granulation tissue.
- Marsupialization of the edges to improve healing times.

Setons in the Management of Difficult Fistulas

Cotton post



Anal fissure

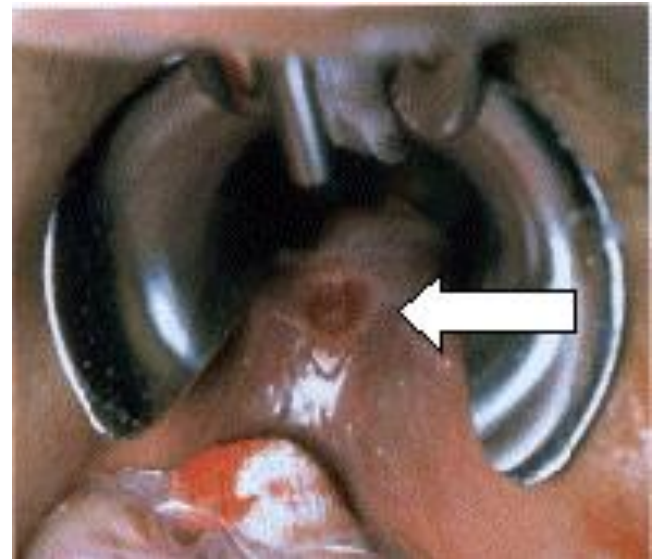
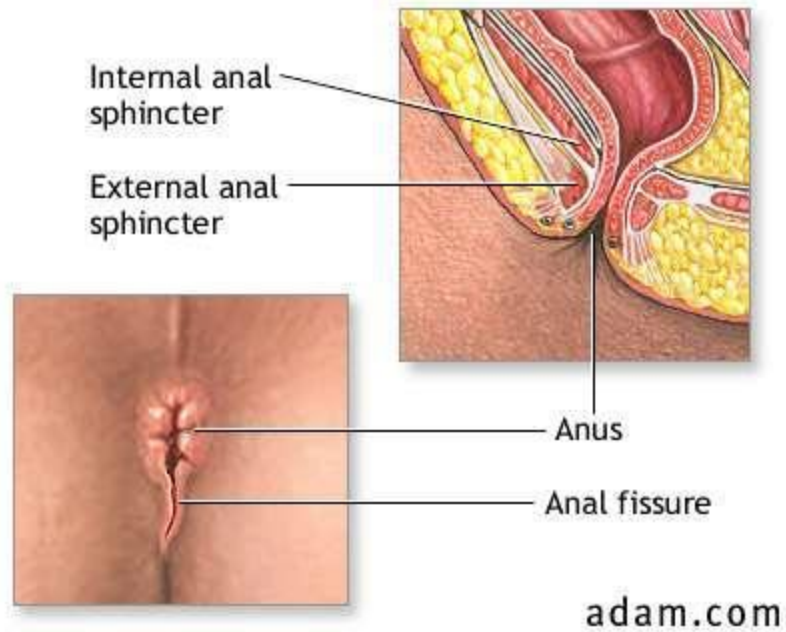
Anal Fissure

- usually located posteriorly *↪ Bcz Blood supply is less*
- usually extending from The anal opening

- an unnatural crack or longitudinal tear in the mucosa and skin of the anal canal, usually extending from the anal opening and located posteriorly in the midline.

(This location is probably because of the relatively unsupported nature of the rectal wall in that location.)

↪ Lateral fissures are so rare their presence suggest specific lesions such as, Crohn's disease, UC, TB or malignancy.



Etiology / Pathophysiology

- Most anal fissures are **caused by stretching** of the anal mucosa beyond its capability. Various causes of this fissure include: بشدة حالة بالحمام
- **Straining to defecate**, especially if the stool is hard and dry
- **Severe and chronic constipation**
- **Severe and chronic diarrhea**

Etiology / Pathophysiology

- Crohn's disease and Ulcerative colitis
- Anal sex
- Anal stretching
- Insertion of foreign objects into the anus
- Tight sphincter muscles
- Excessive anal probing

Clinical Manifestations

pain, constipation, bleeding → Fissure

- Pain during, and even hours after, defecation
- Visible tear in the anus
- Blood on the stool or on toilet paper or toilet bowl
- Constipation
- Burning, possibly painful, itch

Medical Management

- Most anal fissures are shallow or superficial. These fissures self-heal within 2 weeks.
topical or suppository containing anti-inflammatory agents and local anesthetic can be used.
high-fiber diet, using stool softener, taking pain killer and having a sitting bath
- 95% of Anal Fissure Responds to Medical Tx


Medical Management

- Painful deep fissures, on the other hand cut through the sphincter muscle thus making it prone to spasm, which exacerbates the fissure and aborts the healing process. Medications such as nitroglycerine and nifedipine ointments can relax the sphincter muscle } For 6 weeks
side effect is
headache
- Surgical intervention anal fissures unresponsive to the above conservative measures. Procedures include: Internal lateral sphincterotomy ~~~~~

What is the differential diagnoses for each of the following common anal symptoms ?

- Anal bleeding
- Anal pain and discomfort
- Perianal itching and irritation
- something coming down
- perianal discharge

Other anal conditions

- **Rectal prolapse** *more common in female Due to pregnancy*
 - partial only mucosa involved (2cm in long)*
 - complete All layers involved (12-16cm in long)*
- PNS
- Congenital abnormalities
- Anal incontinence
- **Pruritus ani** *most common cause of it is idiopathic* 
- Non malignant strictures
- Anal neoplasms

Thank you

