

Box 2.2 Zsigmondy-Palmer tooth notation system

Permanent teeth

Right	8 7 6 5 4 3 2 1	1 2 3 4 5 6 7 8	Left
	8 7 6 5 4 3 2 1	1 2 3 4 5 6 7 8	

Primary teeth

Right	E D C B A	A B C D E	Left
	E D C B A	A B C D E	

Examples:
 Permanent upper right central incisor = 1
 Primary lower left second molar = E

Box 2.1 Universal tooth notation system

Permanent teeth

Right	1 2 3 4 5 6 7 8	9 10 11 12 13 14 15 16	Left
	32 31 30 29 28 27 26 25	24 23 22 21 20 19 18 17	

Primary teeth

Right	A B C D E	F G H I J	Left
	T S R Q P	O N M L K	

Examples:
 Upper right permanent central incisor = # 8
 Lower left primary second molar = # K

Box 2.3 FDI tooth notation system

Permanent teeth

Right	18 17 16 15 14 13 12 11	21 22 23 24 25 26 27 28	Left
	48 47 46 45 44 43 42 41	31 32 33 34 35 36 37 38	

Primary teeth

Right	55 54 53 52 51	61 62 63 64 65	Left
	85 84 83 82 81	71 72 73 74 75	

Examples:
 Permanent upper right central incisor = 11, pronounced "one-one"
 Primary lower left second molar = 75, pronounced as "seven-five"

Table 2.3 Various tooth identification systems

		Universal		Zsigmondy/Palmer notation		International (FDI)		
		Tooth	Right	Left	Right	Left	Right	Left
Deciduous dentition	Maxillary teeth	Central incisor	E	F	A	A	51	61
		Lateral incisor	D	G	B	B	52	62
		Canine	C	H	C	C	53	63
		1st molar	B	I	D	D	54	64
		2nd molar	A	J	E	E	55	65
	Mandibular teeth	Central incisor	P	O	A	A	81	71
		Lateral incisor	Q	N	B	B	82	72
		Canine	R	M	C	C	83	73
		1st molar	S	L	D	D	83	74
		2nd molar	T	K	E	E	85	75
Permanent dentition	Maxillary teeth	Central incisor	8	9	1	1	11	21
		Lateral incisor	7	10	2	2	12	22
		Canine	6	11	3	3	13	23
		1st premolar	5	12	4	4	14	24
		2nd premolar	4	13	5	5	15	25
		1st molar	3	14	6	6	16	26
		2nd molar	2	15	7	7	17	27
		3rd molar	1	16	8	8	18	28
	Mandibular teeth	Central incisor	25	24	1	1	41	31
		Lateral incisor	26	23	2	2	42	32
		Canine	27	22	3	3	43	33
		1st premolar	28	21	4	4	44	34
		2nd premolar	29	20	5	5	45	35
		1st molar	30	19	6	6	46	36
	2nd molar	31	18	7	7	47	37	
	3rd molar	32	17	8	8	48	38	

The Permanent Maxillary Incisors

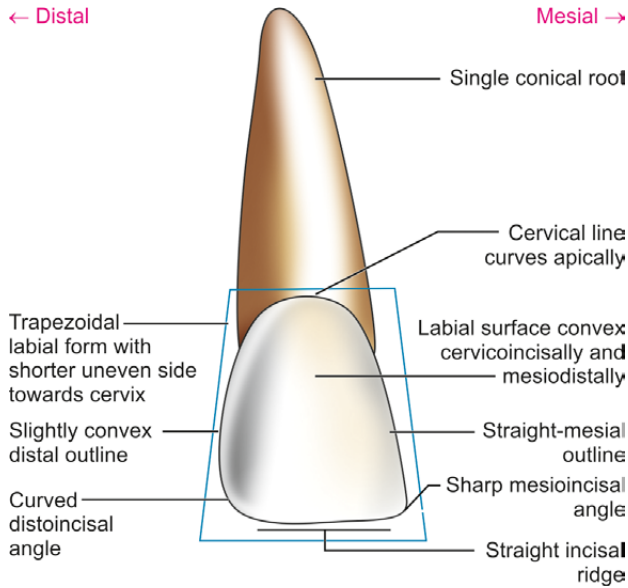


Figure 7.7 Maxillary central incisor—labial aspect

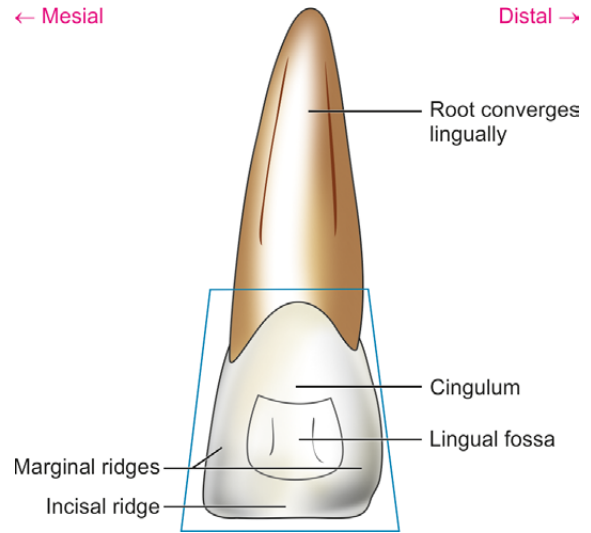


Figure 7.9 Maxillary central incisor—lingual aspect

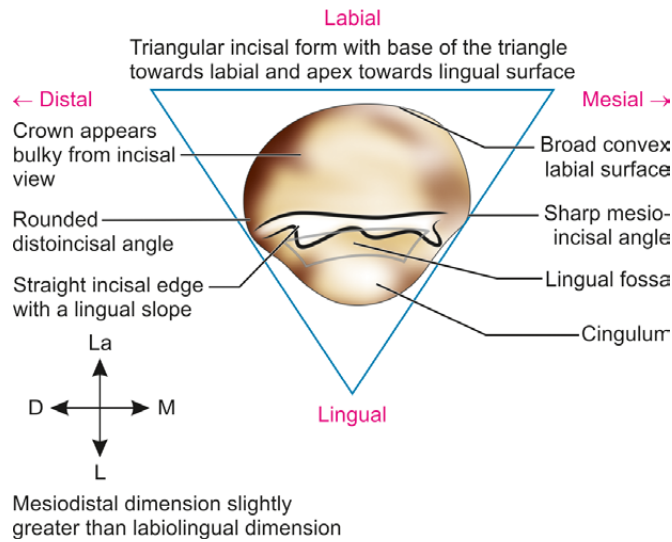


Figure 7.12 Maxillary central incisor—incisal aspect

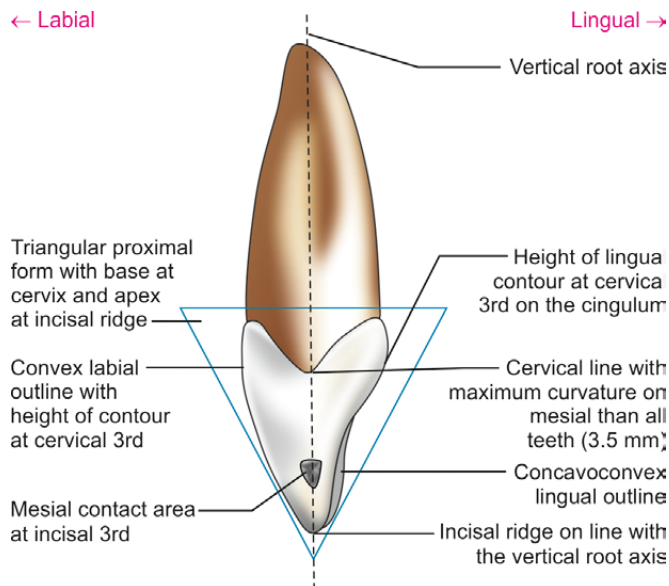


Figure 7.10 Maxillary central incisor—mesial aspect

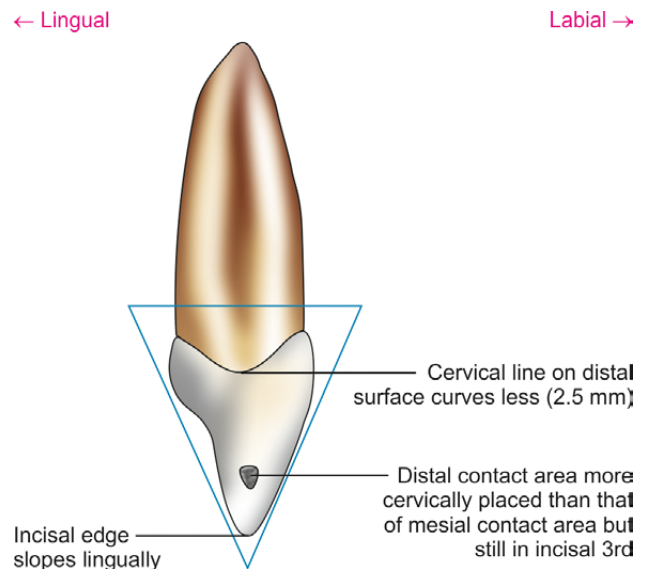
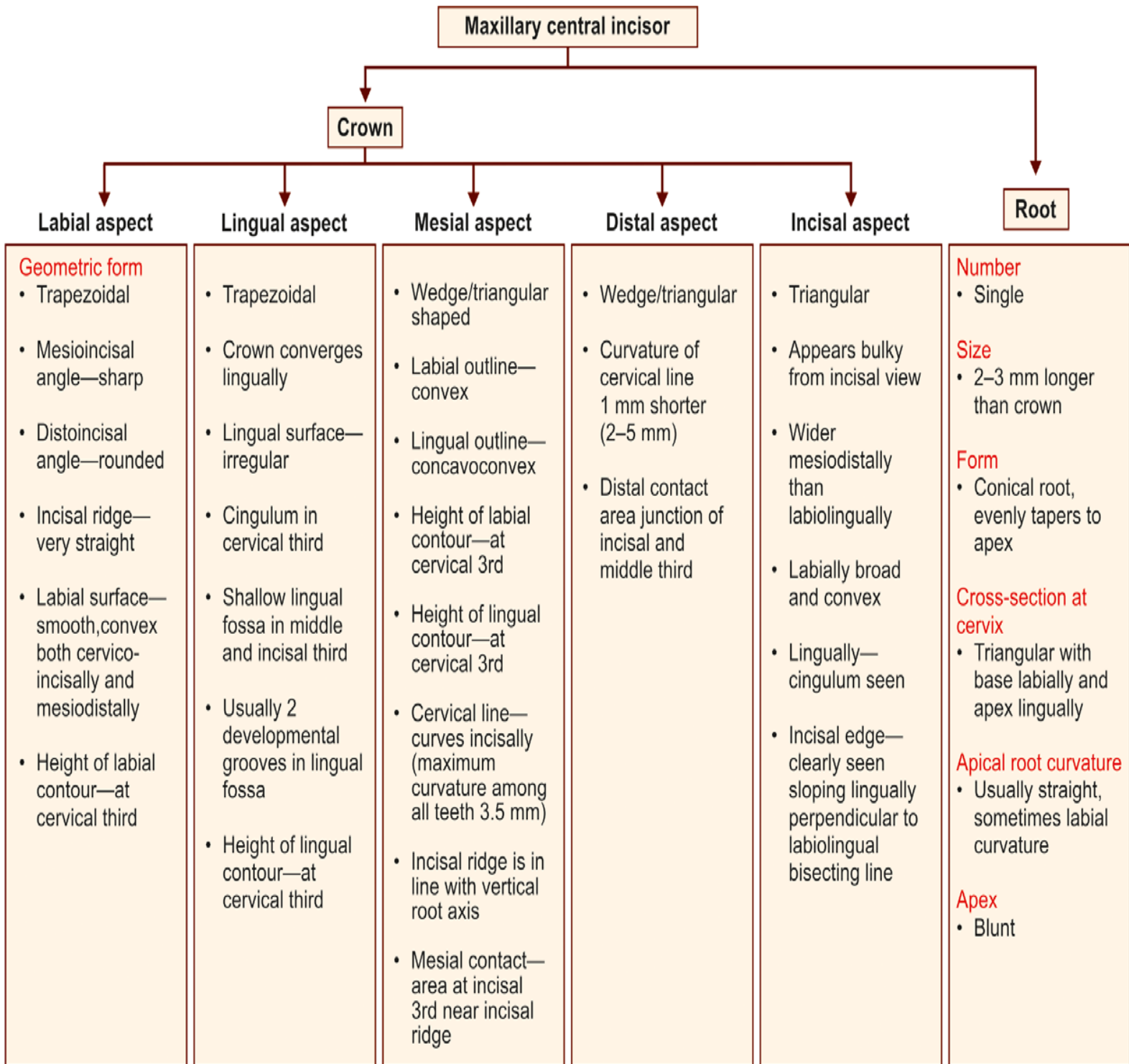
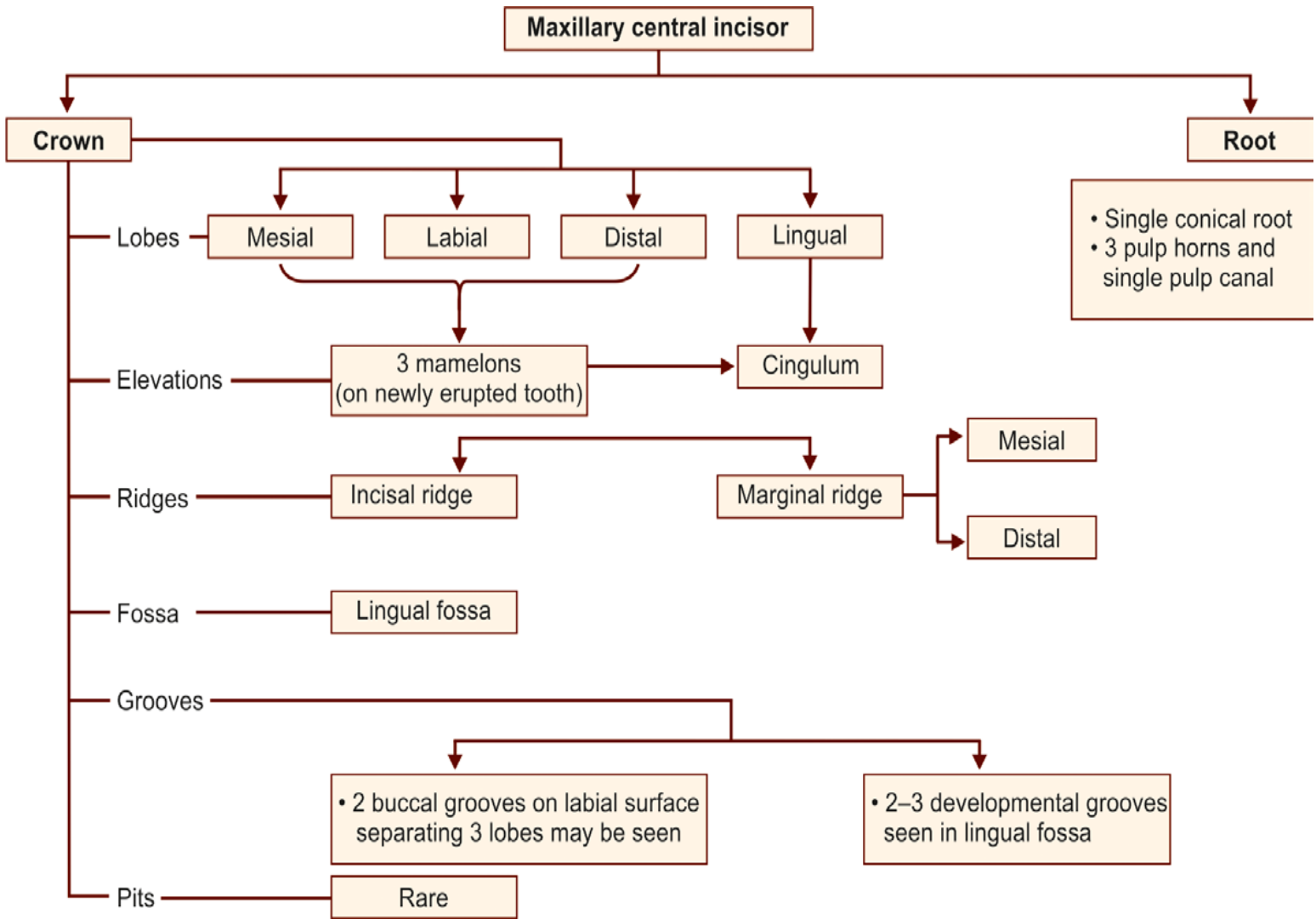


Figure 7.11 Maxillary central incisor—distal aspect

Maxillary central incisor—summary



Flow chart 7.1 Maxillary central incisor—major anatomic landmarks



Box 7.1 Maxillary central incisor—identification features

Identification features of maxillary central incisor

- Tooth with longest crown and single conical, straight root
- Crown more symmetrical and wider mesiodistally
- Greatest cervical line curvature among all teeth
- Lingual fossa and cingulum on lingual aspect
- Straight incisal ridge

Side identification

- Sharp mesioincisal angle and rounded distoincisal angle

Maxillary Lateral Incisors

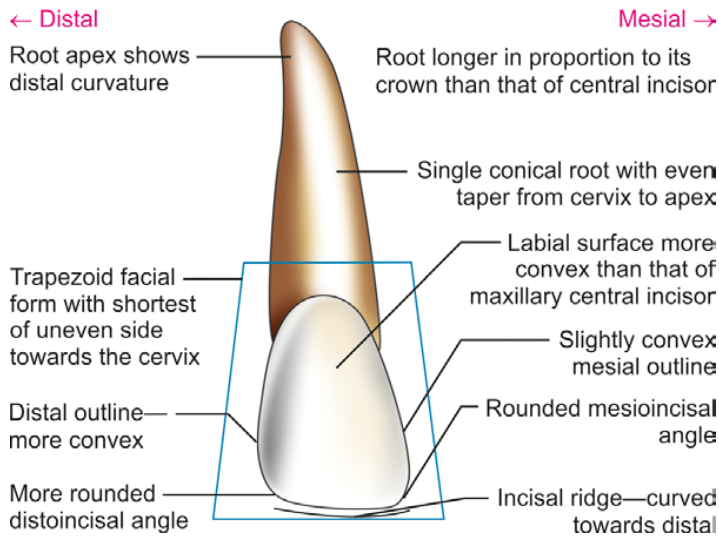


Figure 7.18 Maxillary lateral incisor—labial aspect

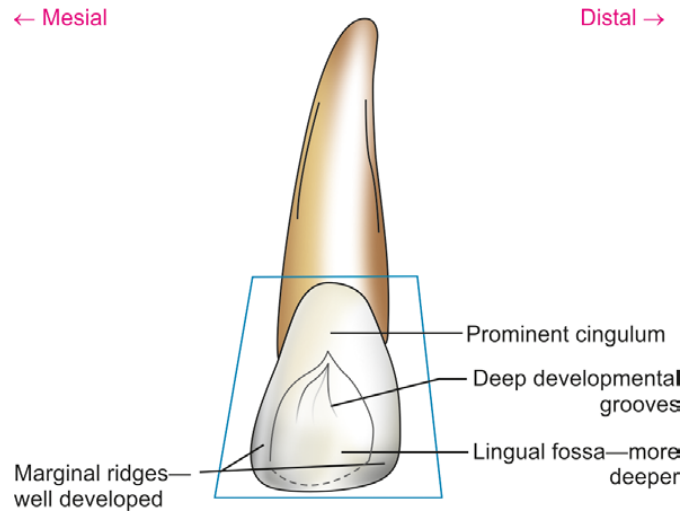


Figure 7.19 Maxillary lateral incisor—lingual aspect

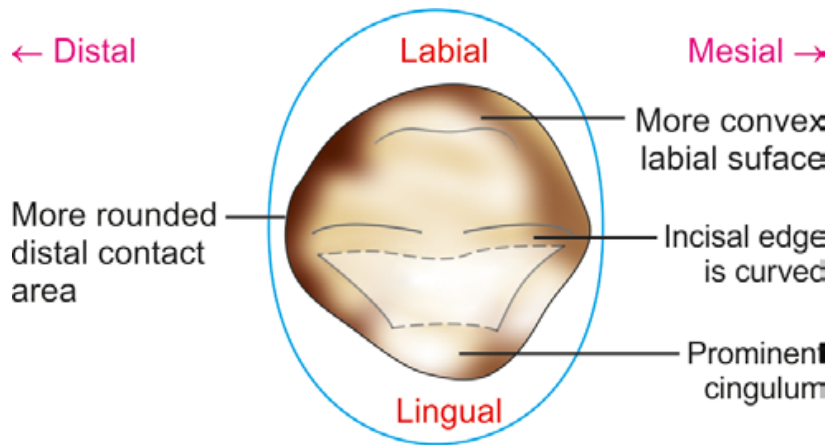


Figure 7.22 Maxillary lateral incisor—incisal aspect

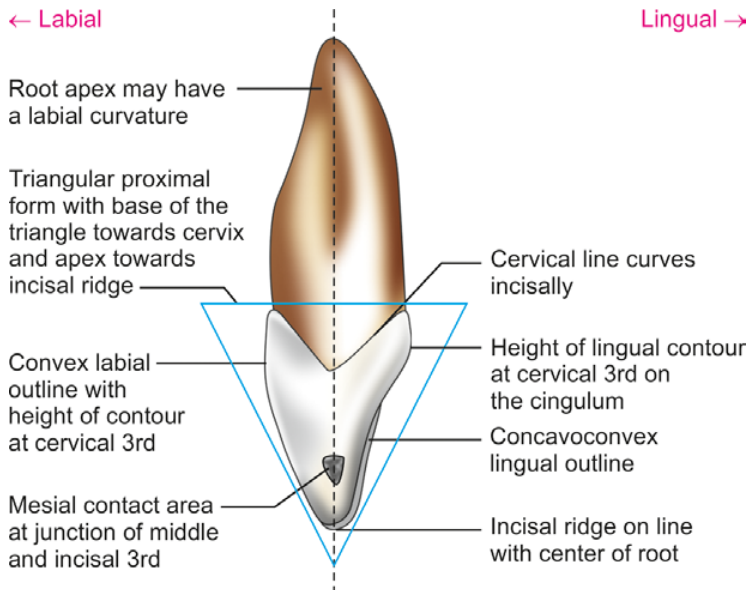


Figure 7.20 Maxillary lateral incisor—mesial aspect

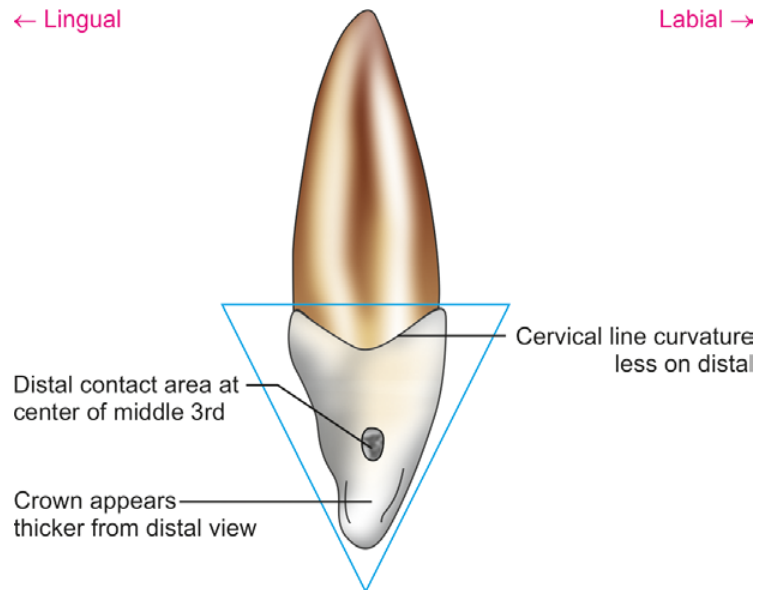
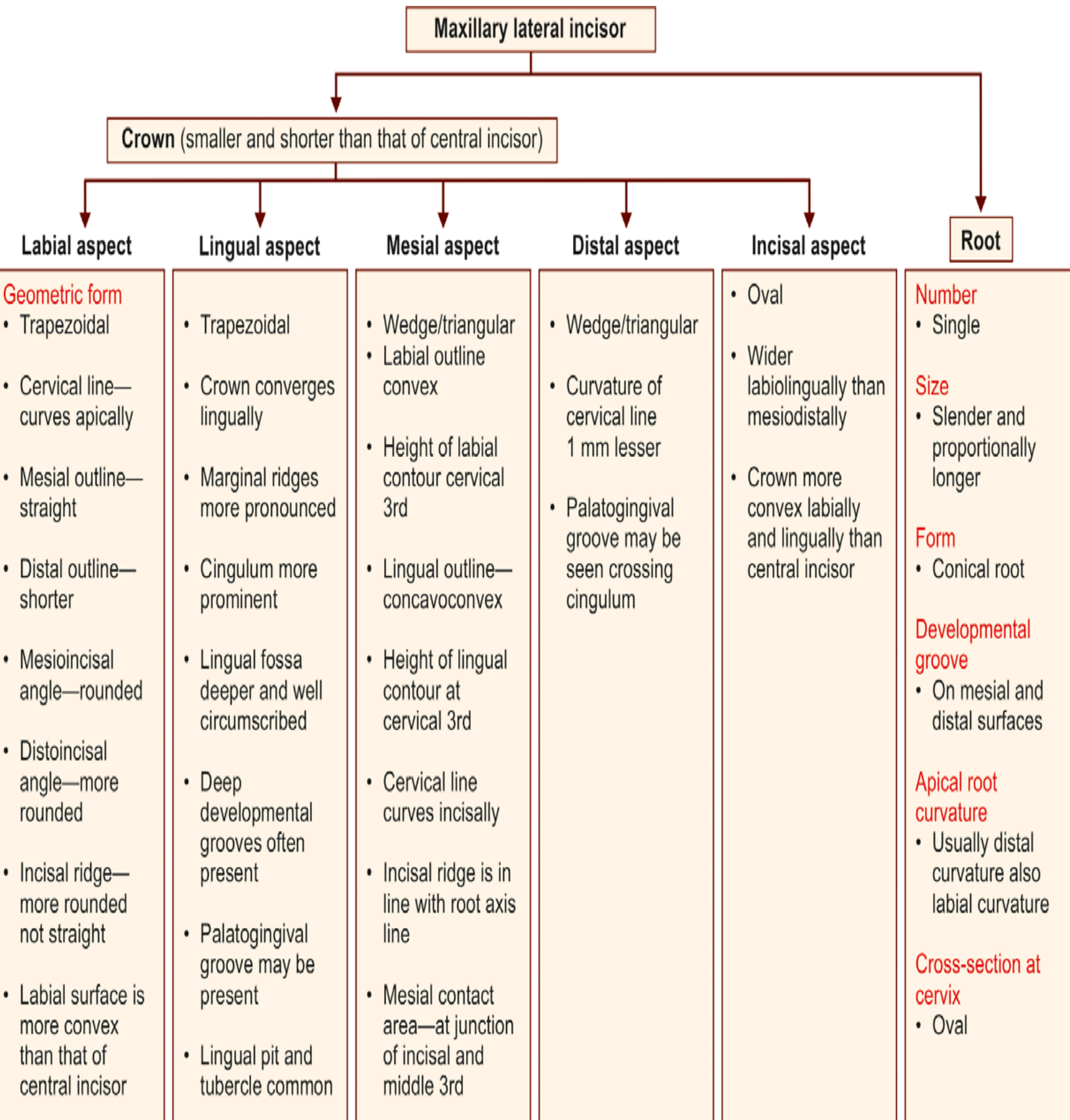
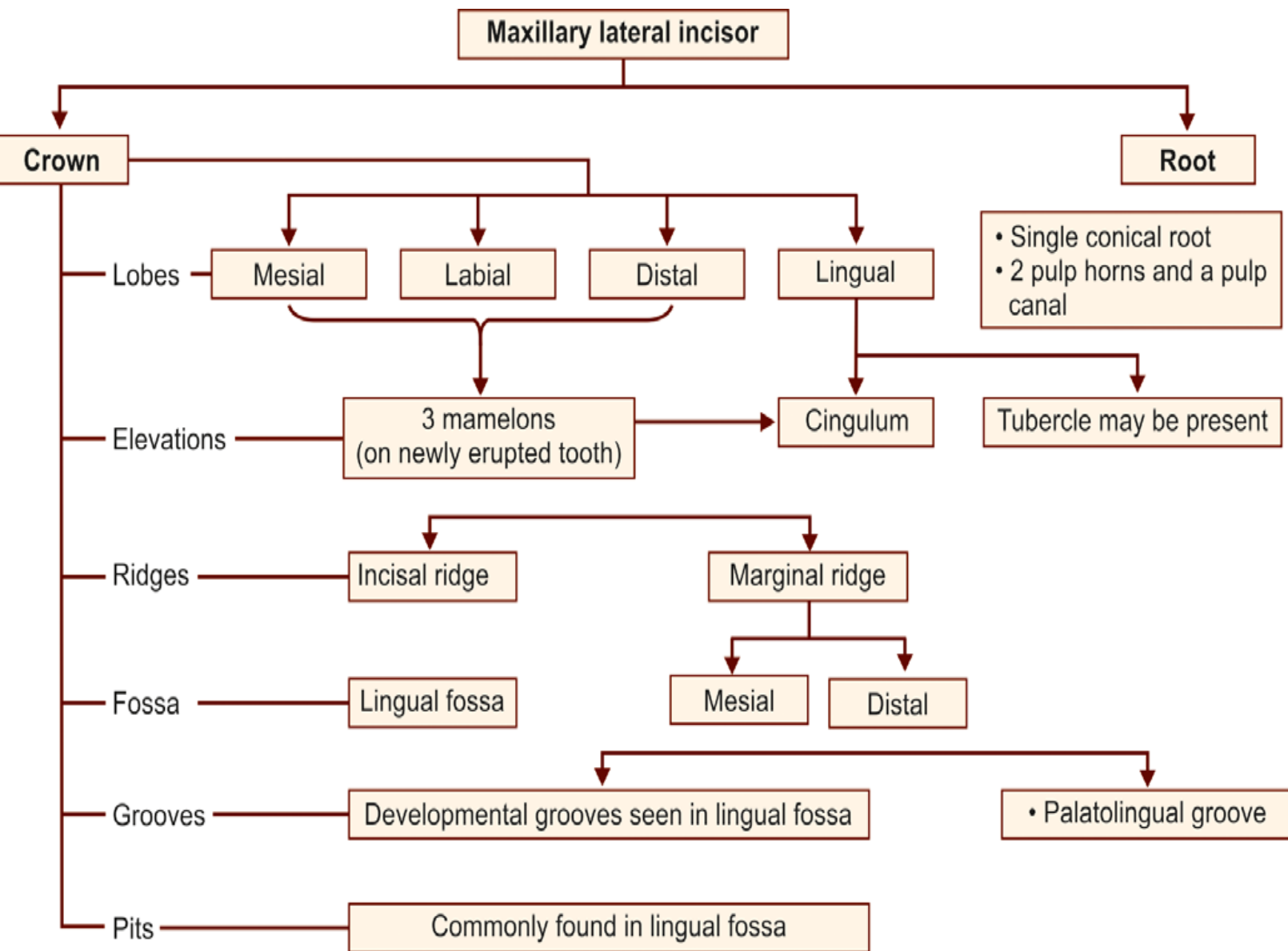


Figure 7.21 Maxillary lateral incisor—distal aspect

Flow chart 7.4 Maxillary lateral incisor—summary





Box 7.2 Maxillary lateral incisor—identification features

Identification features of maxillary lateral incisor

- Tooth with small asymmetrical crown
- Slender and proportionately long root
- Round mesioincisal and more rounded distoincisal angle
- Rounded incisal ridge
- Deep lingual fossa with grooves and pits

Side identification

- More rounded distoincisal angle
- Incisal ridge starts distally
- Root shows distal curvature at apical 3rd

Mandibular Central Incisors

← Distal

Medial →

← Mesial

Distal →

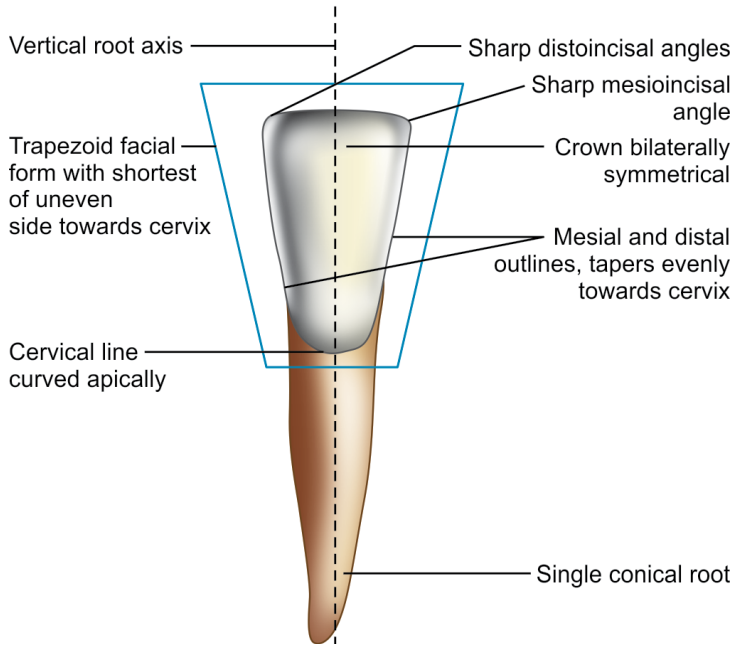


Figure 8.4 Mandibular central incisor—labial aspect

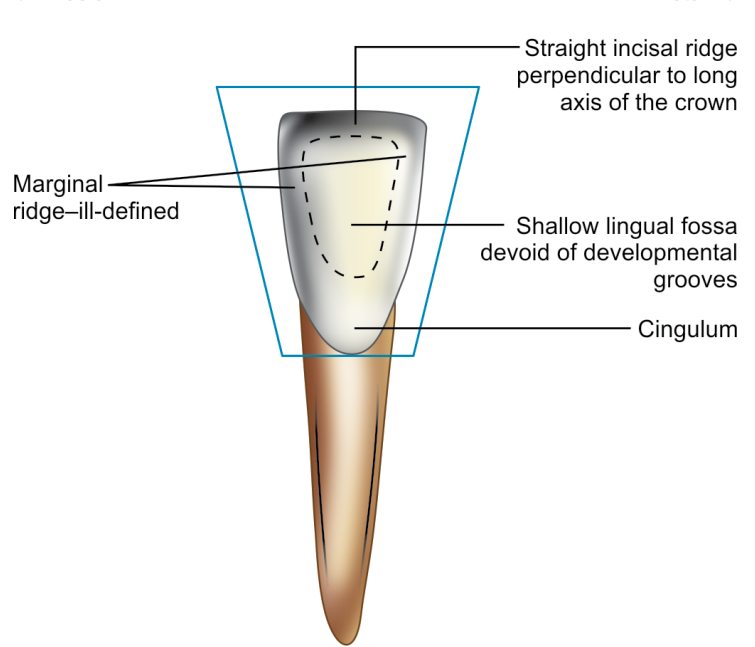


Figure 8.6 Mandibular central incisor—lingual aspect

← Mesial

Distal →

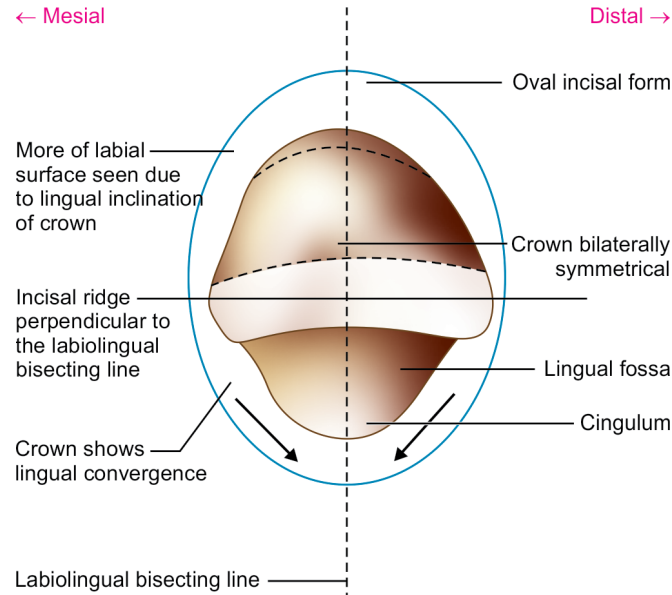


Figure 8.10 Mandibular central incisor—incisal aspect

← Labial

Lingual →

← Lingual

Labial →

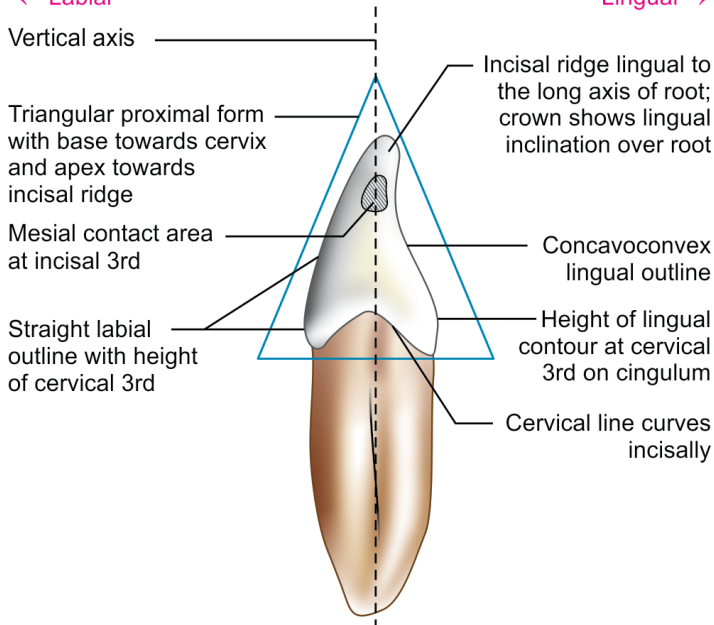


Figure 8.7 Mandibular central incisor—mesial aspect

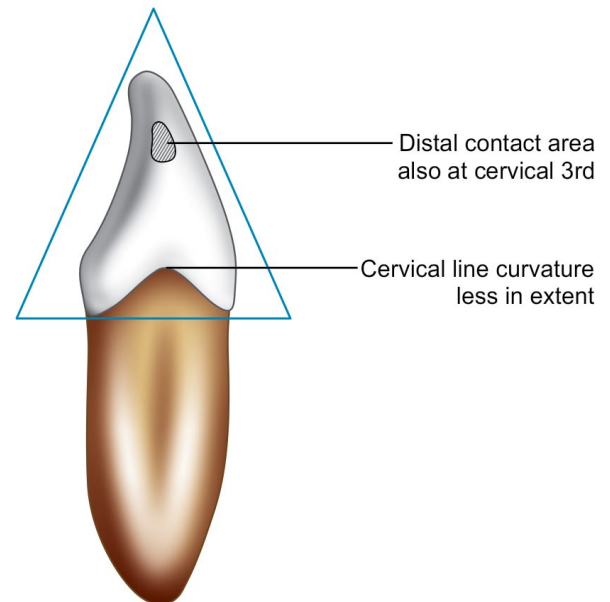
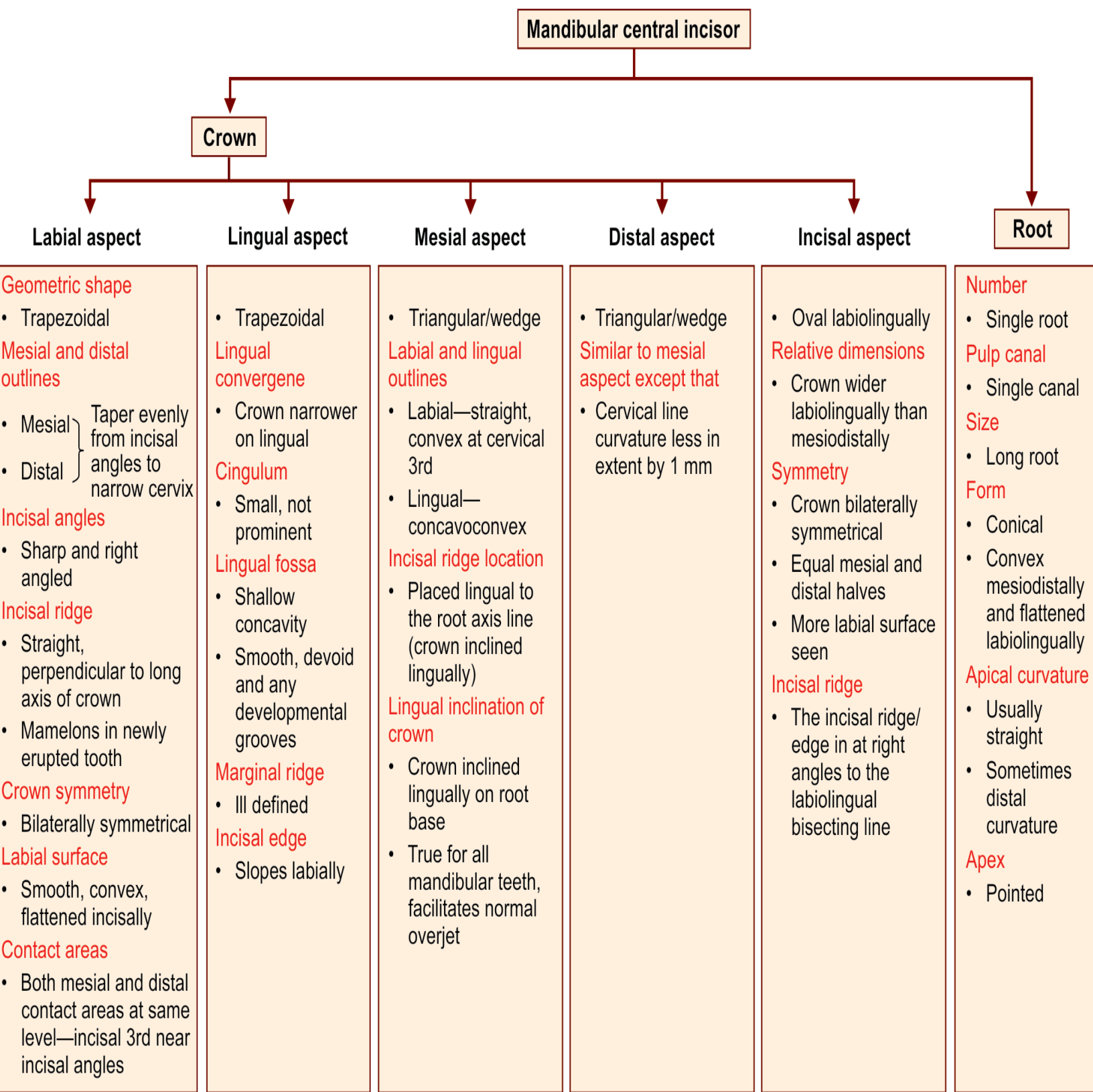
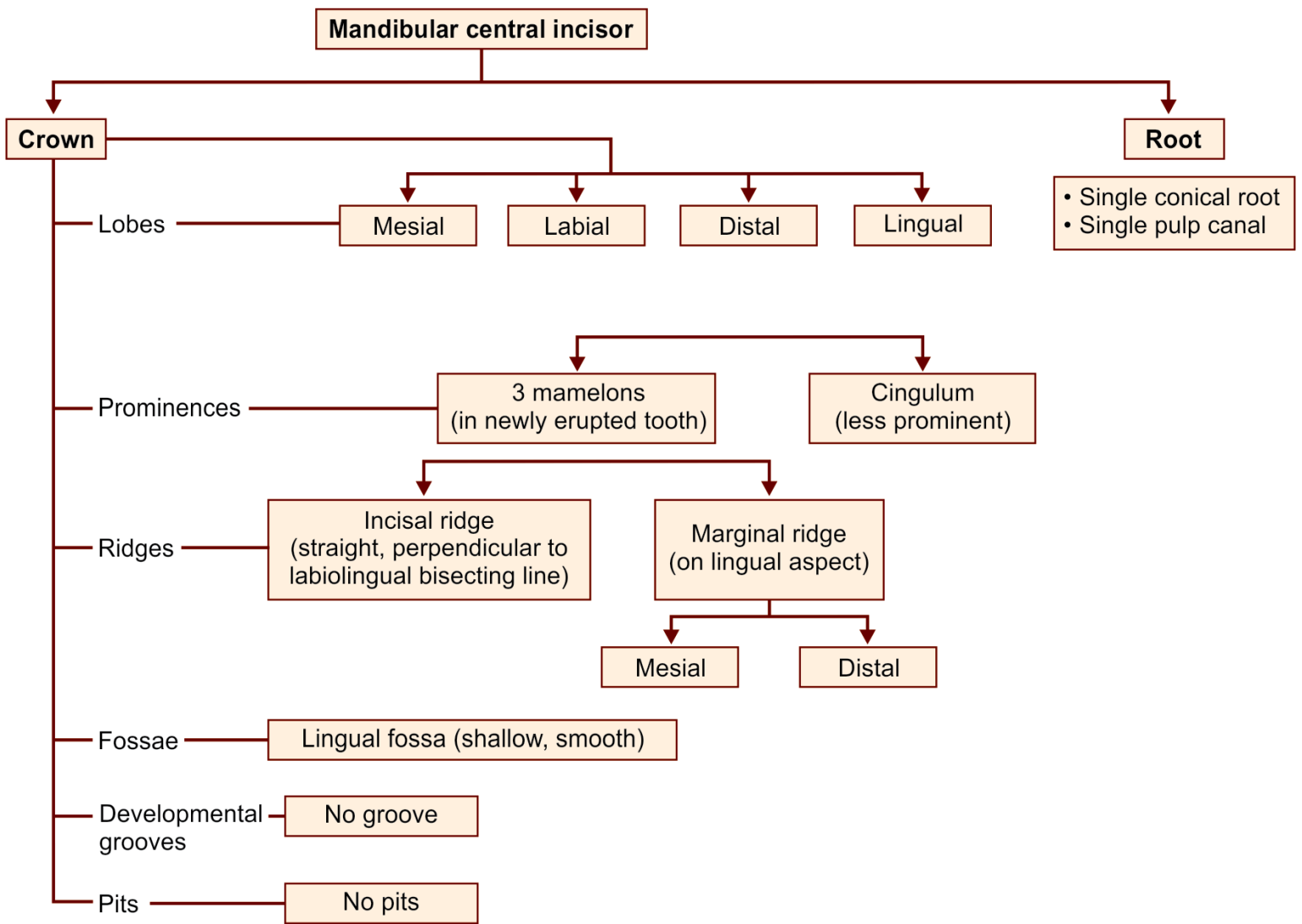


Figure 8.7 Mandibular central incisor—Distal aspect

Flow chart 8.2 Mandibular central incisor—summary



Flow chart 8.1 Mandibular central incisor—major anatomic landmarks



Box 8.1 Mandibular central incisor—identification features

Identification features of mandibular central incisor

- Smallest tooth in permanent dentition
- The crown and root narrow mesiodistally and wider labiolingually
- The crown is bilaterally symmetrical
- Mesial and distal incisal angles are sharp
- Mesial and distal contact areas are at same level near mesial and distal incisal angles
- Viewed incisally, the incisal ridge is perpendicular to the line bisecting the crown labiolingually.

Side identification

- Difficult to differentiate left and right mandibular central incisors since the tooth is bilaterally symmetrical
- Developmental depression on root is deeper on distal surface
- The root may show a distal curvature at the apex.

Mandibular Lateral Incisor

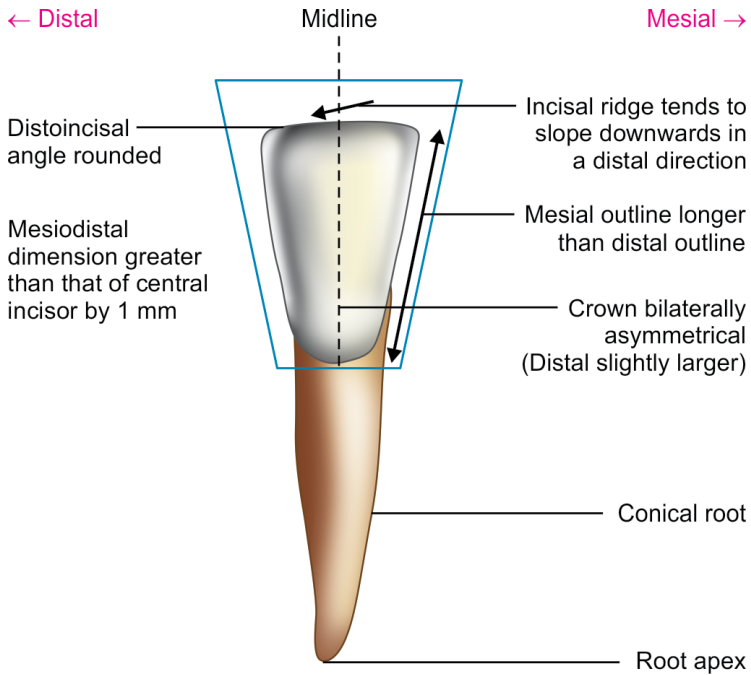


Figure 8.15 Mandibular lateral incisor—labial aspect

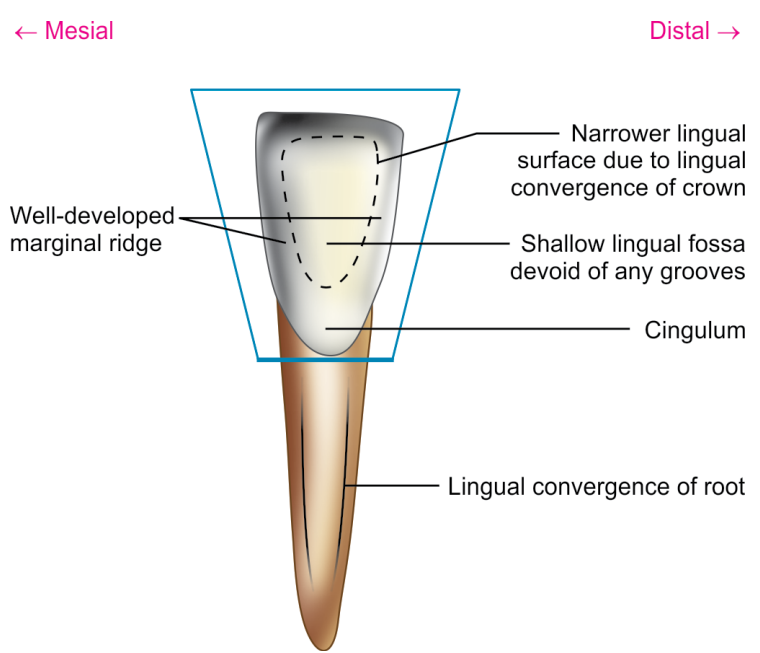


Figure 8.16 Mandibular lateral incisor—lingual aspect

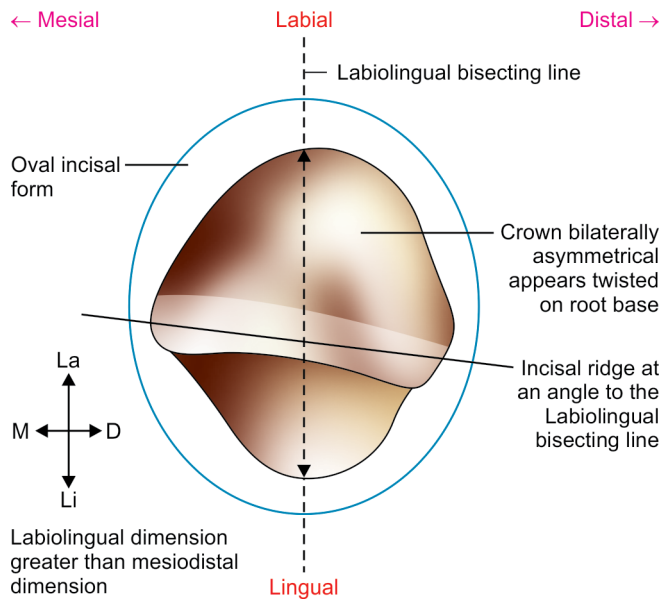


Figure 8.19 Mandibular lateral incisor—incisal aspect

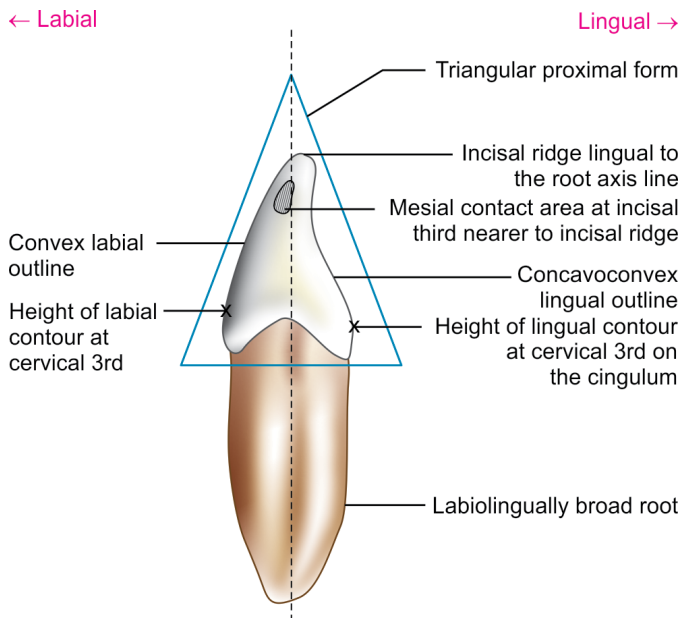


Figure 8.17 Mandibular lateral incisor—mesial aspect

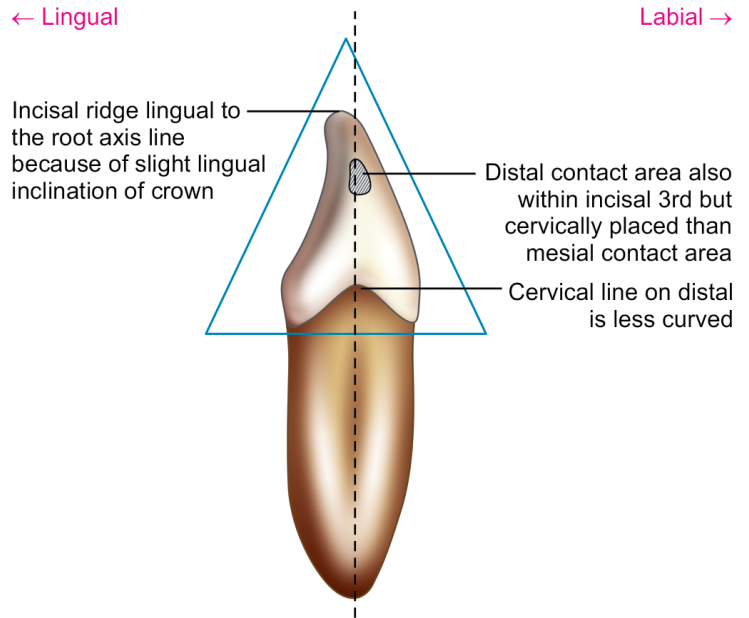
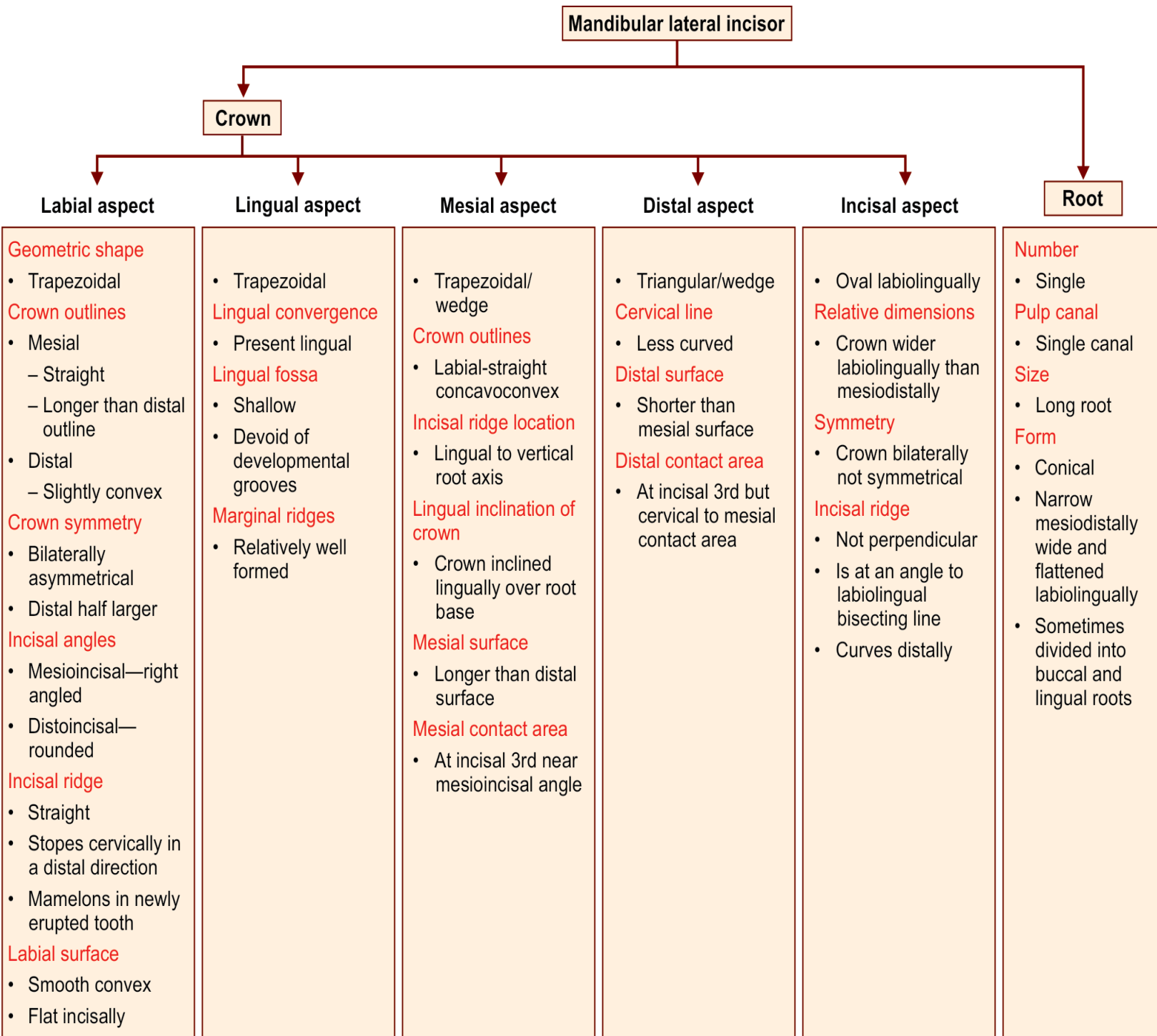
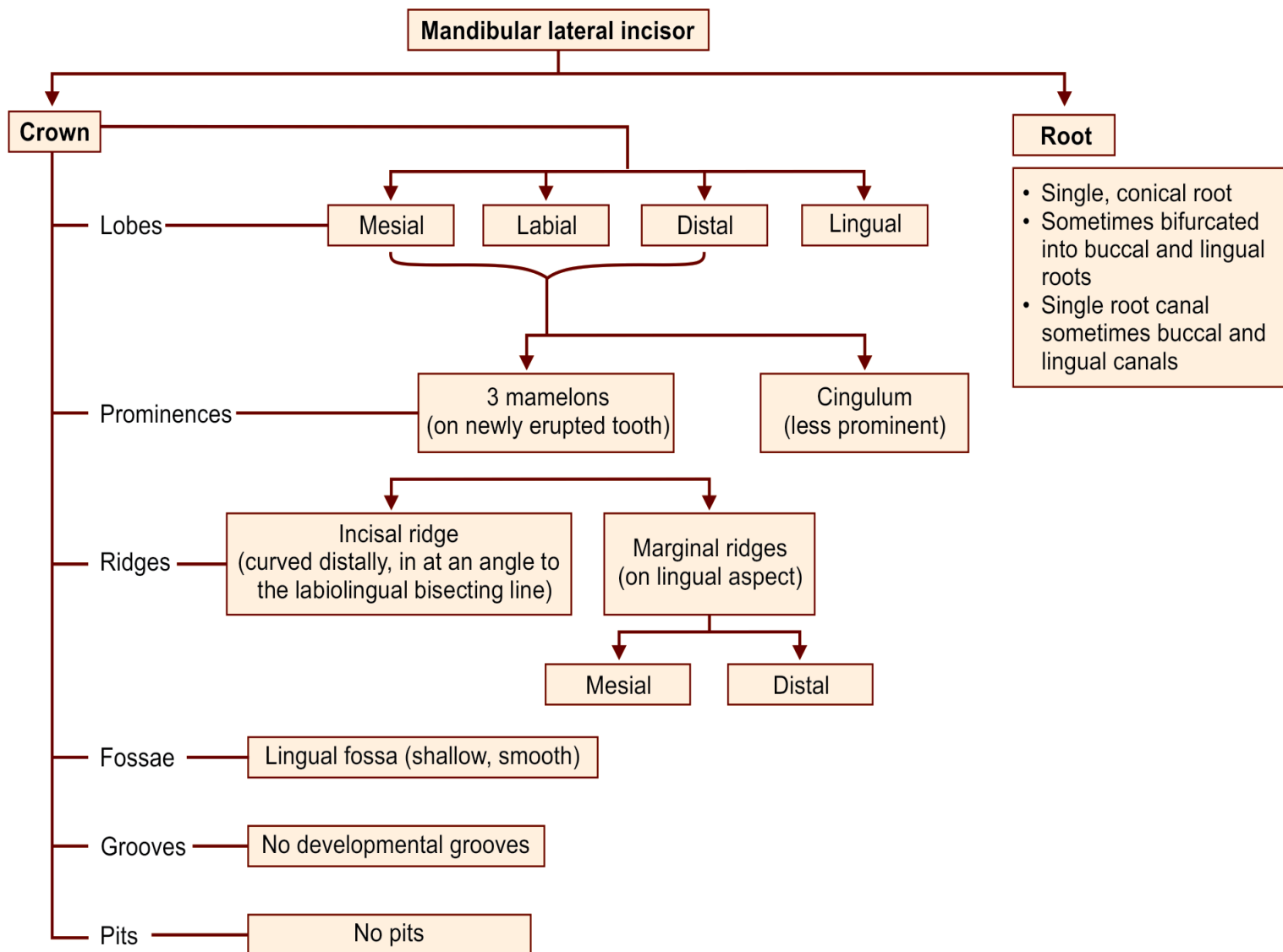


Figure 8.18 Mandibular lateral incisor—distal aspect

Flow chart 8.4 Mandibular lateral incisor—summary



Flow chart 8.3 Mandibular lateral incisor—major anatomic landmarks



Box 8.2 Mandibular lateral incisor—identification features

Identification features of mandibular lateral incisor

- The mandibular lateral incisor is slightly larger than the mandibular central incisor.
- The crown is bilaterally asymmetrical.
- Mesioincisal angle is sharp, distoincisal angle is slightly rounded.
- Viewed incisally, the incisal ridge is placed at an angle to the line bisecting the tooth labiolingually.

Side identification

- Mesioincisal angle is sharp
- Distoincisal angle is rounded.

Maxillary Canines

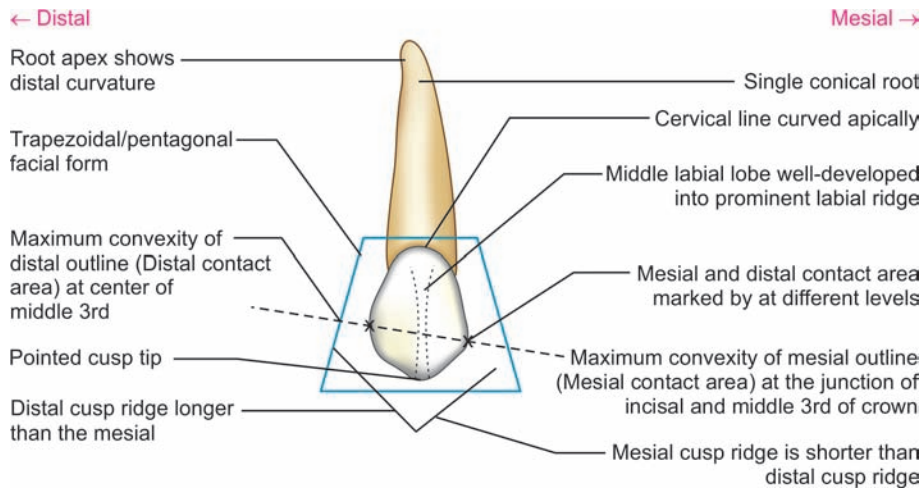


Figure 9.5 Maxillary canine—labial aspect

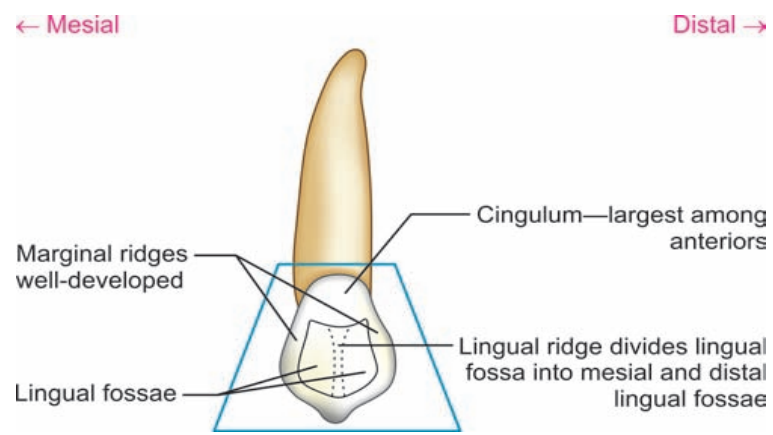


Figure 9.6 Maxillary canine—lingual aspect

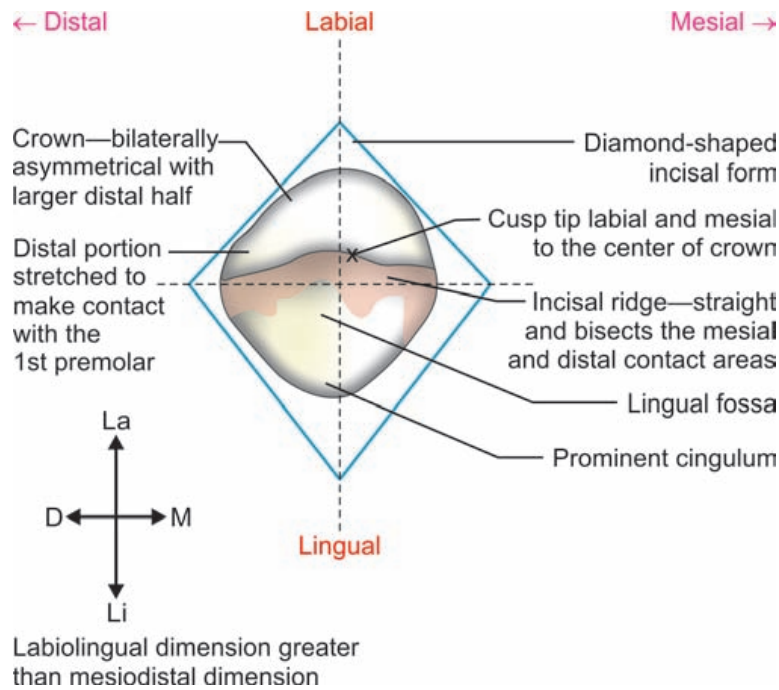


Figure 9.9 Maxillary canine—incisal aspect

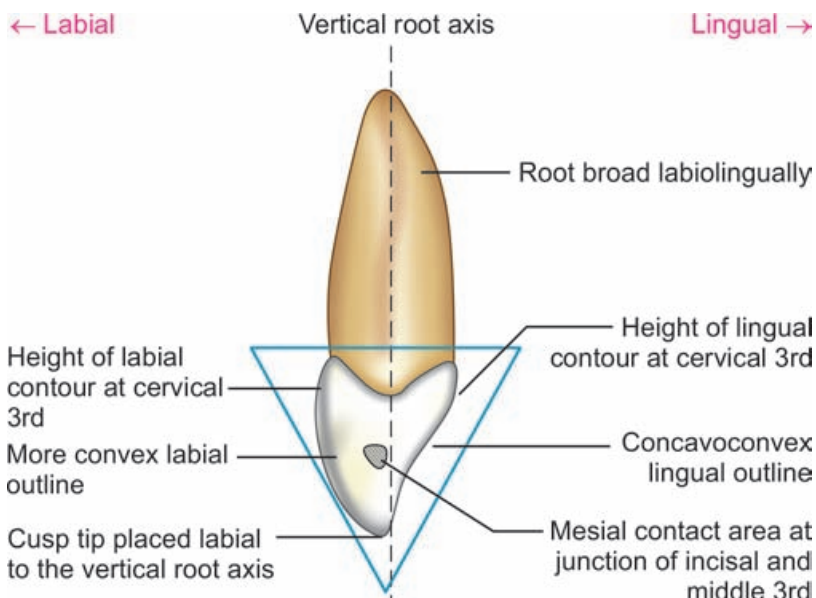


Figure 9.7 Maxillary canine—mesial aspect

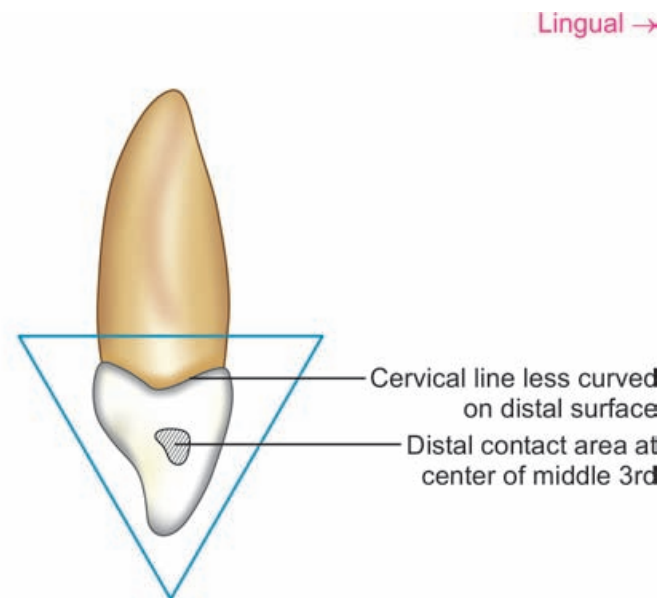


Figure 9.8 Maxillary canine—distal aspect

Flow chart 9.2 Maxillary canine—summary

Maxillary canine

Crown

Labial aspect

- Geometric form**
 - Trapezoidal/pentagonal
- Crown outlines**
 - Mesial—convex
 - Distal—more convex
- Height of mesial and distal contours/contact areas**
 - Markedly at different levels
 - Mesial—junction of middle and incisal 3rd
 - Distal—at center of middle 3rd
- Cusp ridges/slopes**
 - Mesial—short, concave
 - Distal—longer
- Cusp**
 - Single well—developed cusp with pointed tip
- Labial ridge**
 - Middle labial lobe well-developed to form labial ridge running from cervix to cusp tip
- Labial surface**
 - Convex
 - Shallow depressions on either side of labial ridge

Lingual aspect

- Trapezoidal/pentagonal
- Lingual convergence**
 - Marked
- Cingulum**
 - Largest among the anteriors
 - Well-developed sometimes like a small cusp
- Marginal ridges**
 - Strongly developed
- Lingual fossa**
 - May be divided into mesial and distal lingual fossae by the lingual ridge
 - Usually no developmental grooves

Mesial aspect

- Triangular/wedge
- Dimensions**
 - Crown bulkier labiolingually
 - Labiolingual dimension greatest of all anteriors
 - Thicker at incisal portion than incisors
- Outlines**
 - Labial—more convex
 - Lingual—concavoconvex
- Height of labial contour**
 - At cervical 3rd
- Cusp tip location**
 - Placed labial to the vertical root axis
- Mesial surface**
 - Convex except a small concavity in cervical portion
- Mesial contact area**
 - At the junction of incisal middle 3rd cervicoincisally
 - Centered labiolingually

Distal aspect

- Triangular/wedge
- Similar to mesial surface except**
 - Cervical line—less curved
 - Preconcavity apical to contact area
- Distal contact area**
 - At middle 3rd of crown

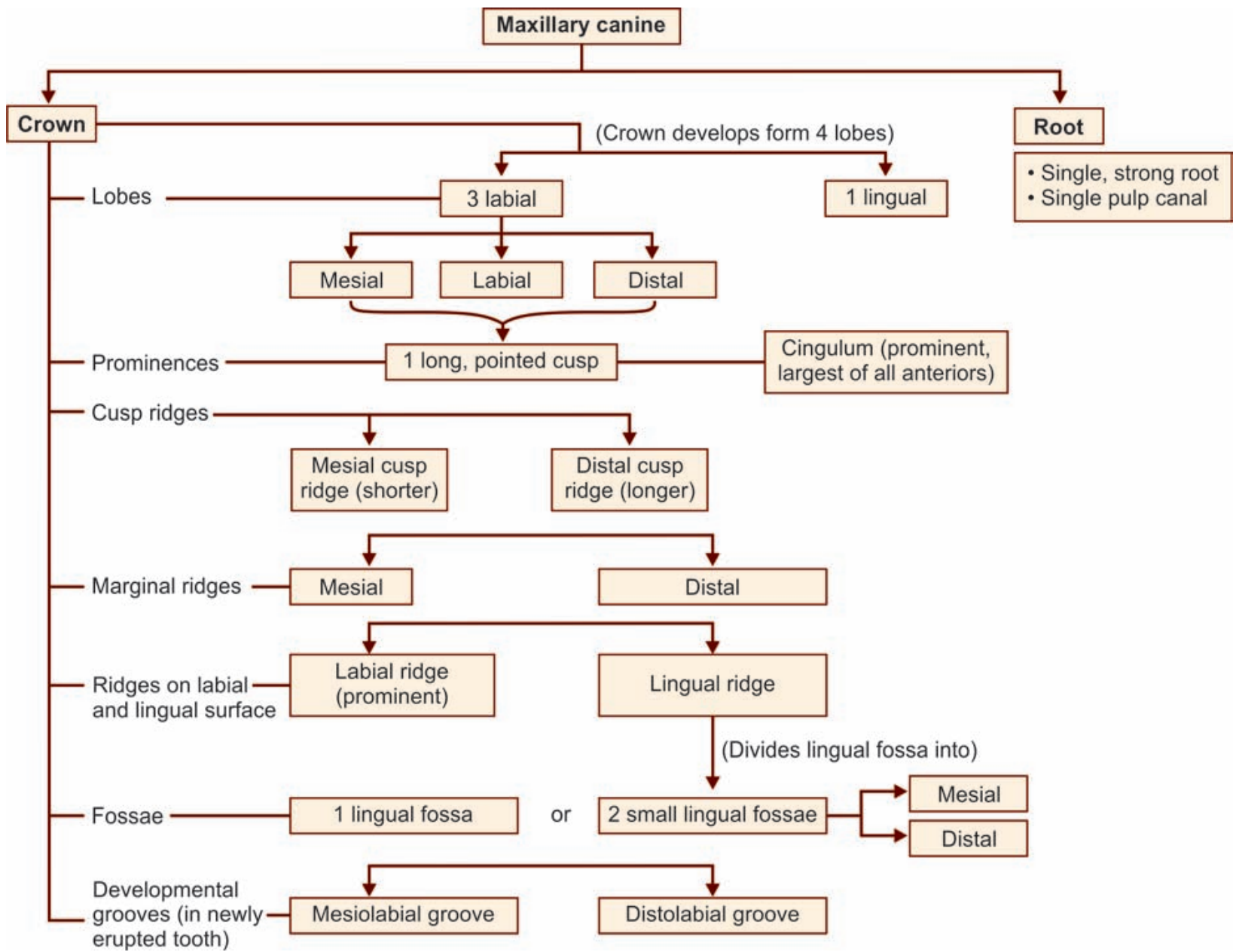
Incisal aspect

- Diamond-shaped
- Relative dimensions**
 - Labiolingual dimension greater than the mesio-distal
- Symmetry**
 - Crown is asymmetric with mesial half larger than distal half
 - Distal portion is stretched to make contact with 8th premolar
- Positions of cusp tip**
 - Cusp tip located labial to crown center labiolingually and mesial to the center mesio-distally
- Cusp ridges**
 - Form straight line mesiodistally and bisect the contact areas

Root

- Number**
 - Single root canal
- Pulp canals**
 - Single canal
- Size**
 - Longest root of all teeth
 - Thicker labiolingually
- Form**
 - Conical-shaped root
 - Narrow mesiodistally, wider labiolingually
- Cross-section at cervix**
 - Oval
- Developmental depressions**
 - On both mesial and distal surfaces root
 - Deeper on distal surface
- Apical curvature**
 - Distal curvature at apical 3rd
- Apex**
 - Blunt

Flow chart 9.1 Maxillary canine—major anatomic landmarks



Box 9.1 Maxillary canine—identification features

Identification features of maxillary canine

- It has long crown with a single cusp
- It has a large cingulum giving the tooth more bulk at the cervical portion when viewed proximally
- The crown is pentagonal, narrower at cervix and wider at contact areas
- The root is longest of all teeth, and is also wider labiolingually

Side identification

- Distal cusp slope is longer than the mesial
- Root apex often show a distal curvature
- Developmental depression of the root is deeper on the distal surface

Mandibular Canines

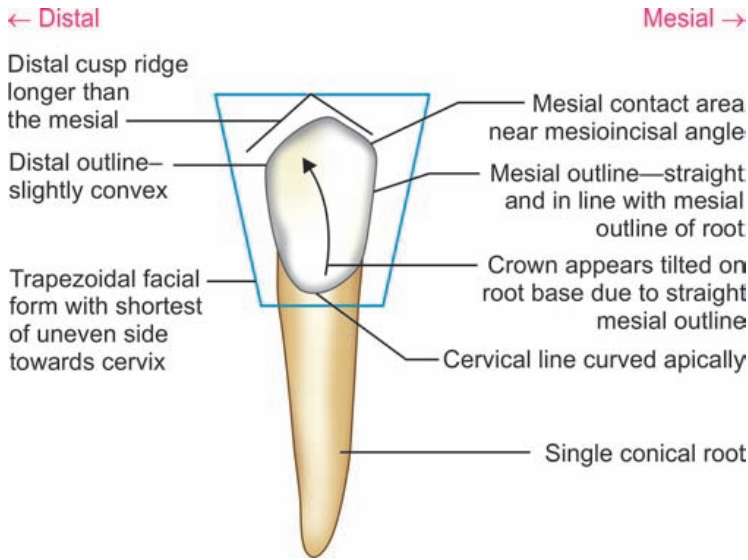


Figure 9.16 Mandibular canine—labial aspect

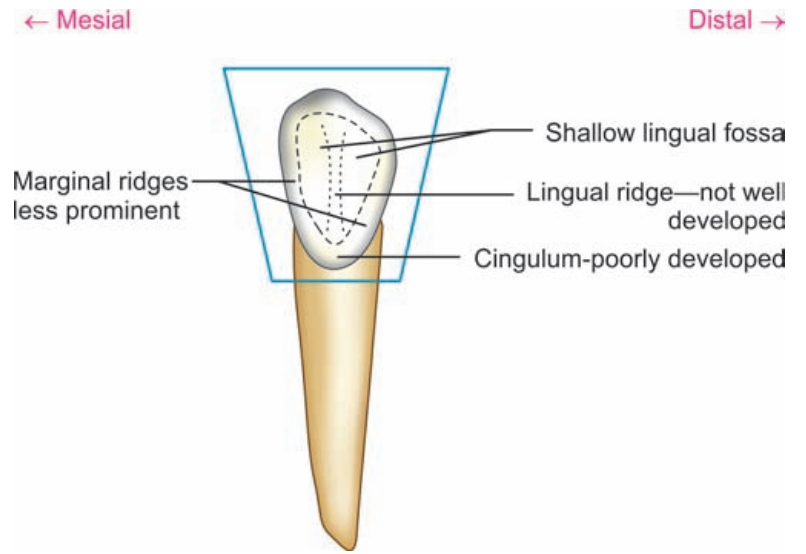


Figure 9.17 Mandibular canine—lingual aspect

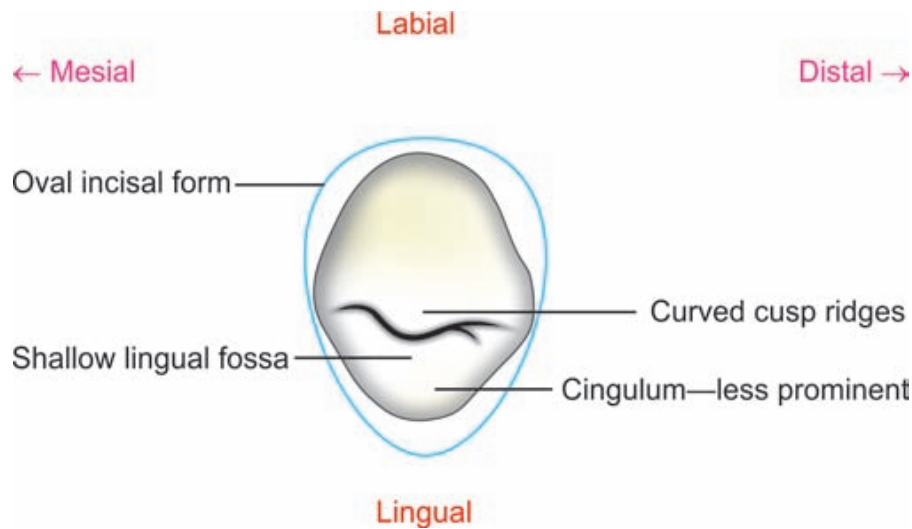


Figure 9.20 Mandibular canine—incisal aspect

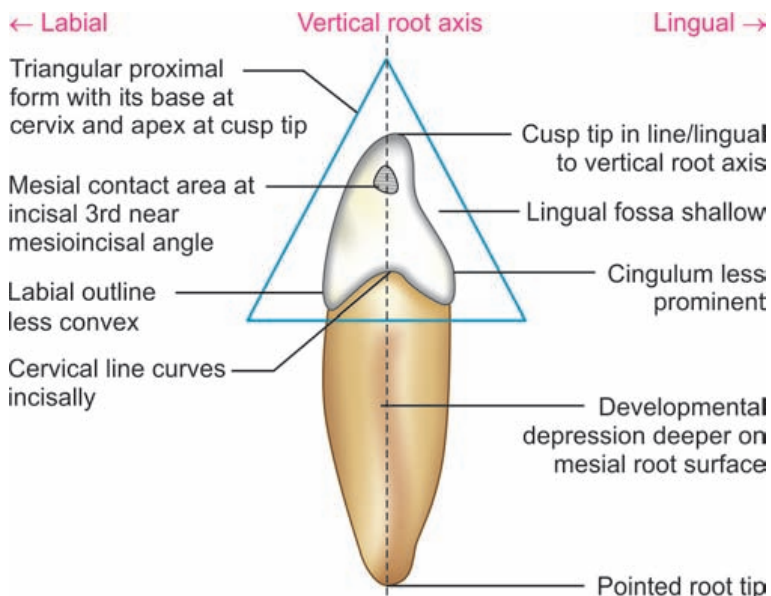


Figure 9.18 Mandibular canine—mesial aspect

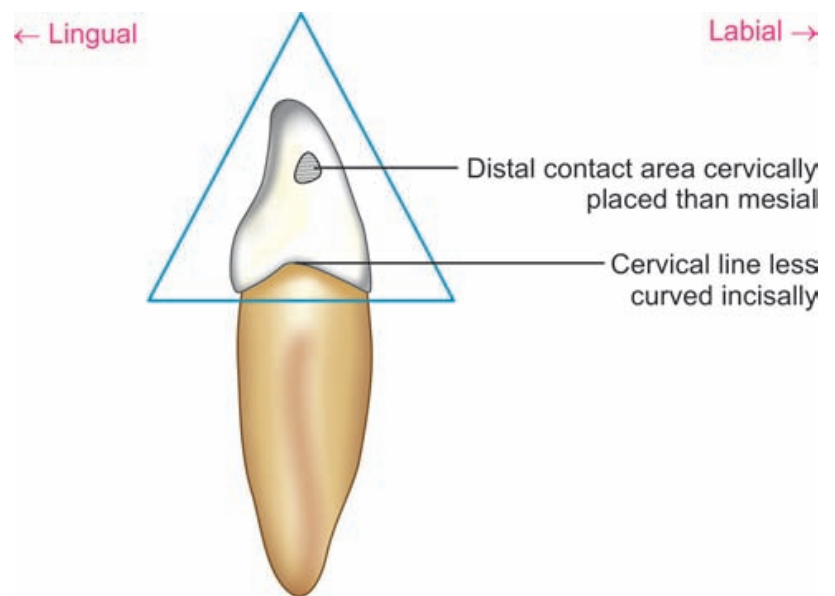
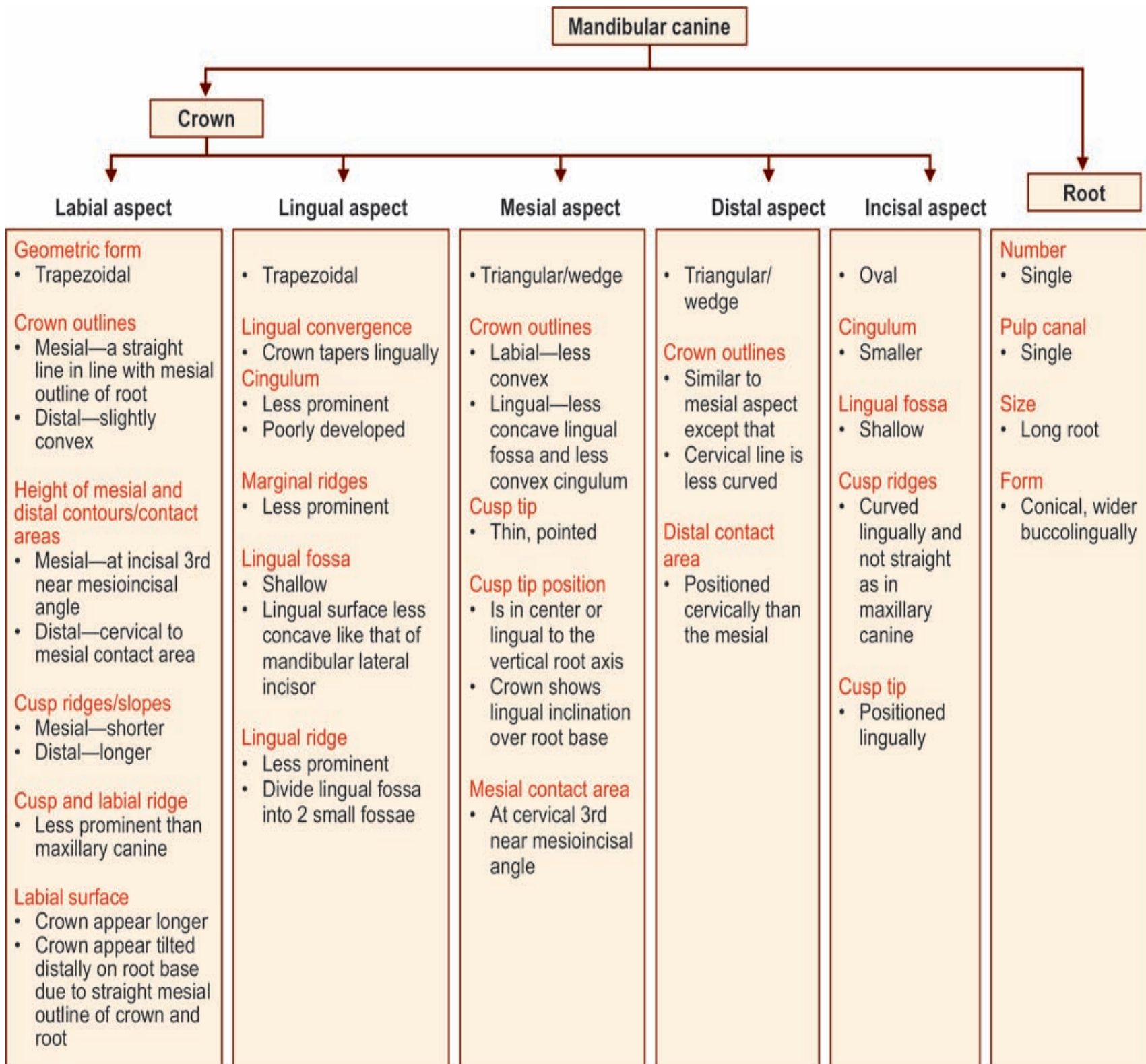
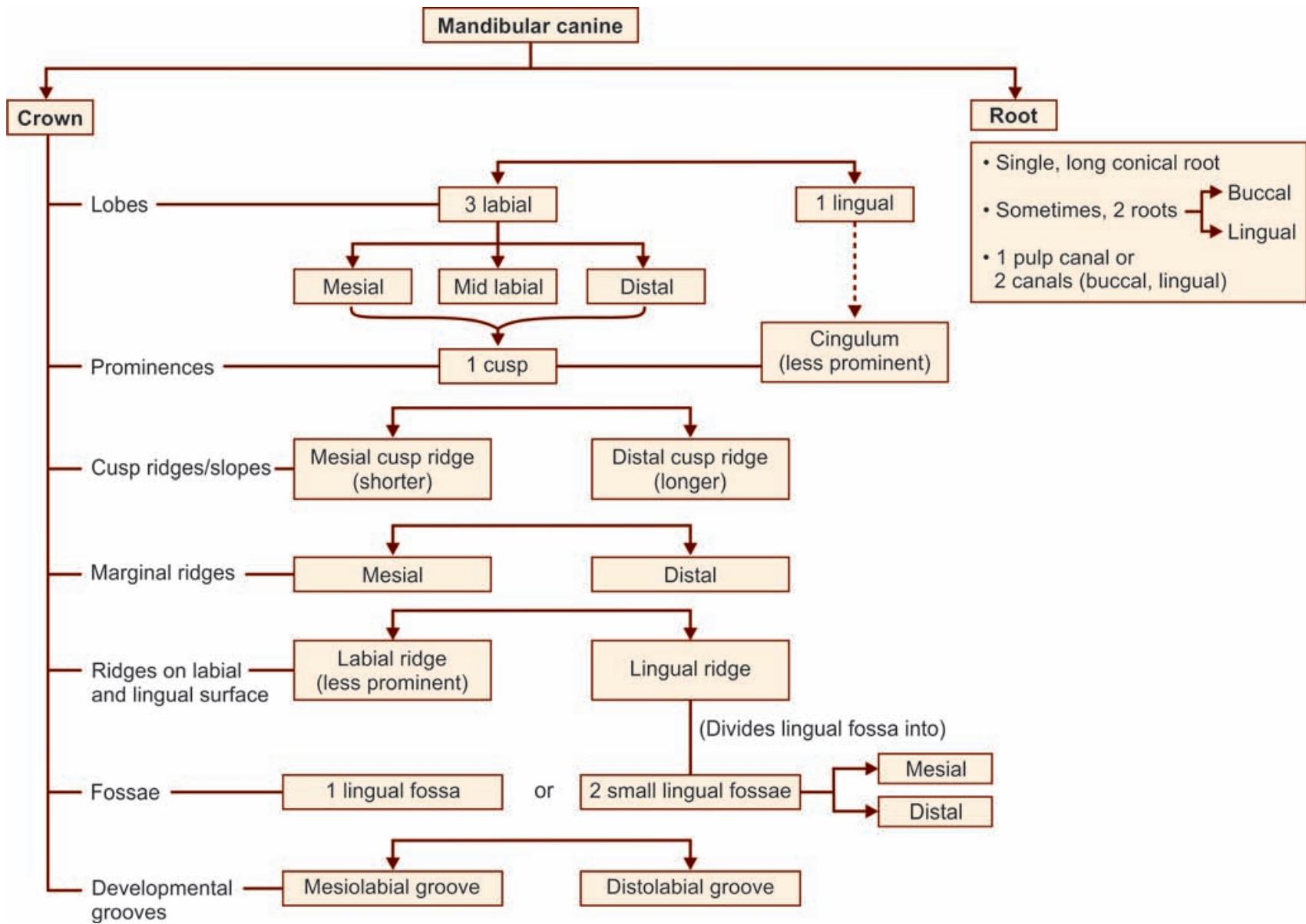


Figure 9.19 Mandibular canine—distal aspect

Flow chart 9.4 Mandibular canine—summary



Flow chart 9.3 Mandibular canine—major anatomic landmarks

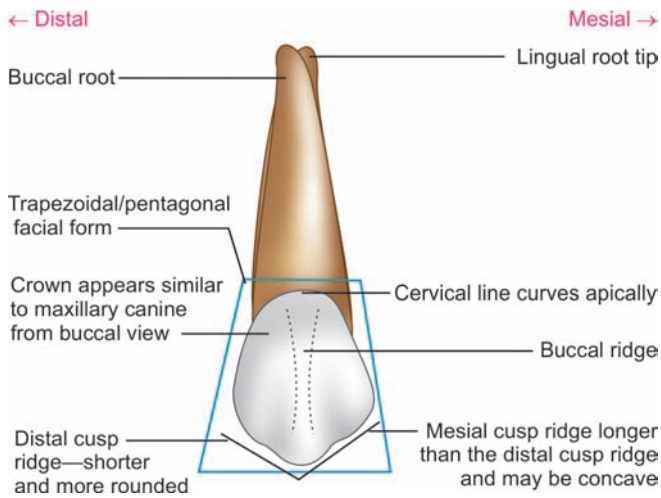


Box 9.2 Mandibular canine—identification features

Identification features of mandibular canine

- The mandibular permanent canine has a long and narrow crown with a sharp cusp
 - The labial ridge and cingulum are less prominent
 - The distal cusp slope is longer than the mesial
 - The crown appears to be tilted distally on the root base
 - The root is long and narrow
 - When viewed proximally, the cusp tip is lingual to the root axis line
- Side identification*
- The distal cusp slope is longer
 - Developmental depression on the mesial surface of the root is deeper
 - Viewed, labially the mesial outline is straight and distal outline is rounded

Maxillary First Premolar



Maxillary 1st Premolar Buccal Aspect

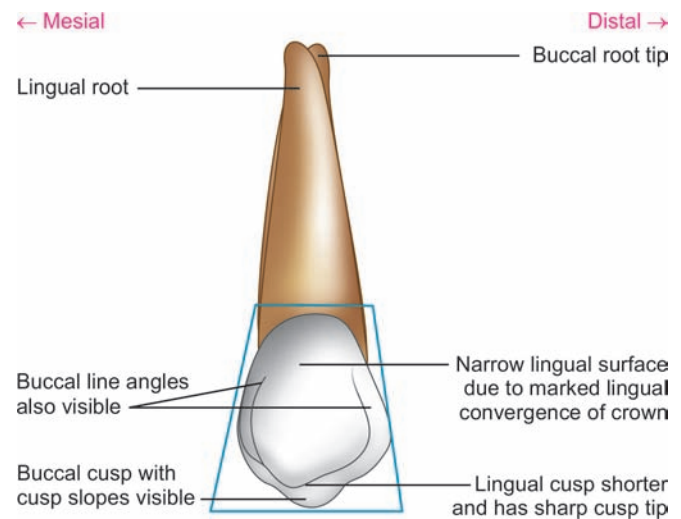
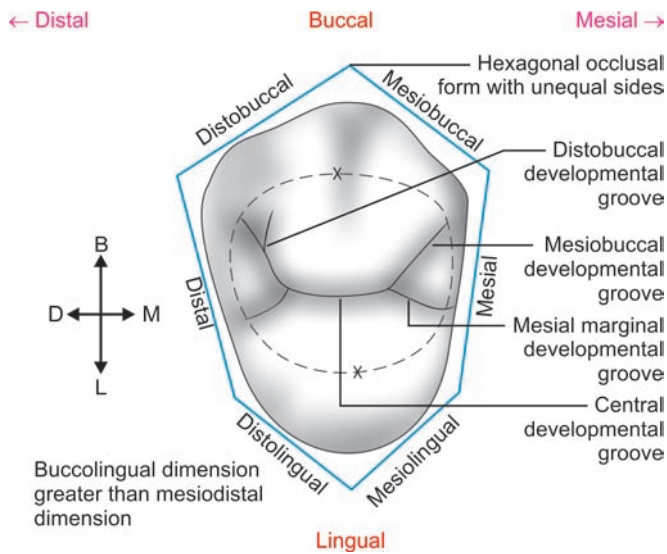
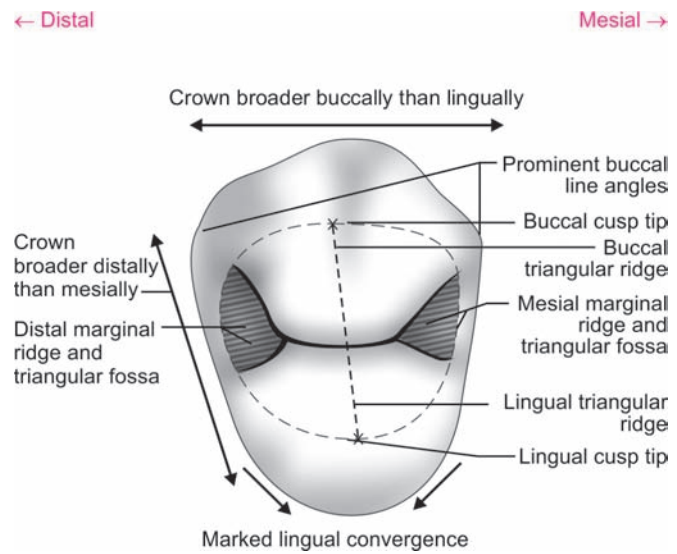


Figure 10.6 Maxillary 1st premolar—lingual aspect



A



B

B Maxillary 1st premolar—occlusal aspect

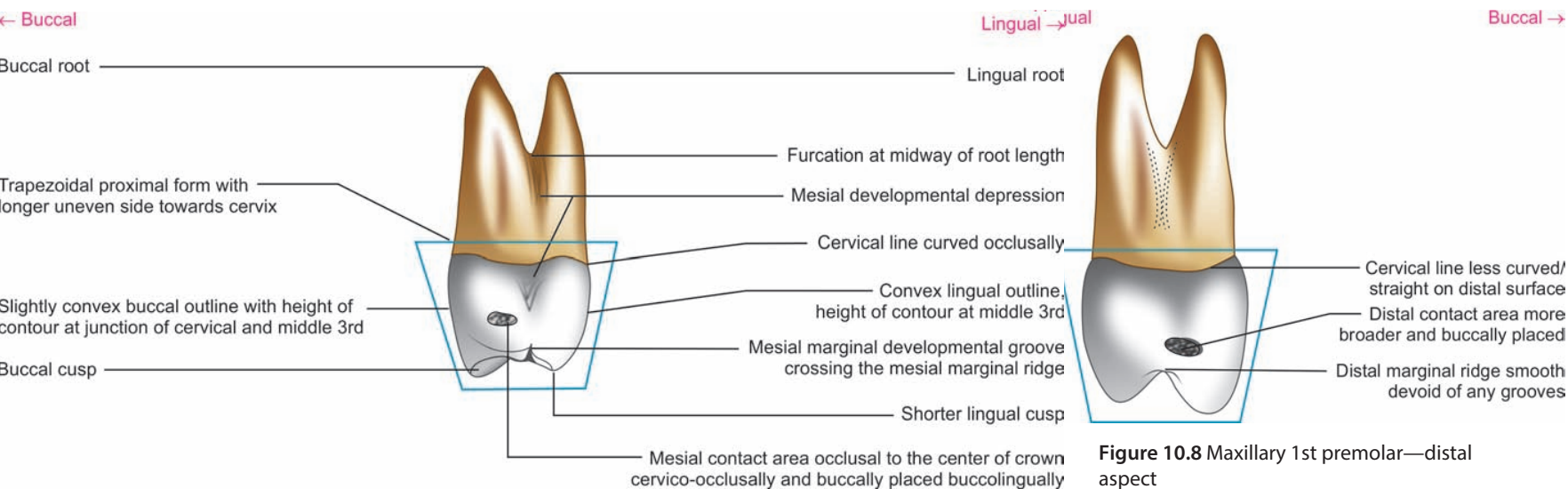
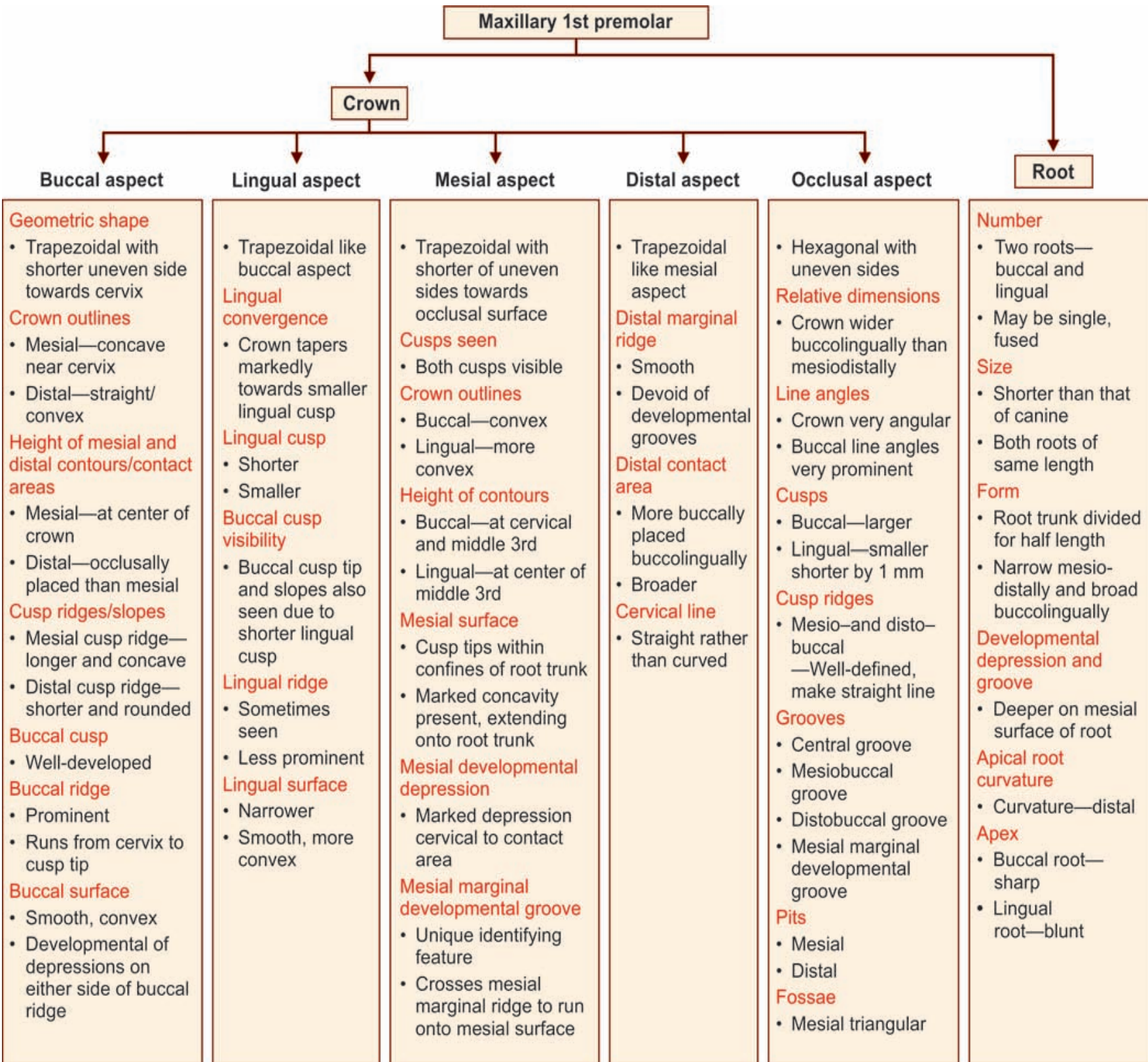


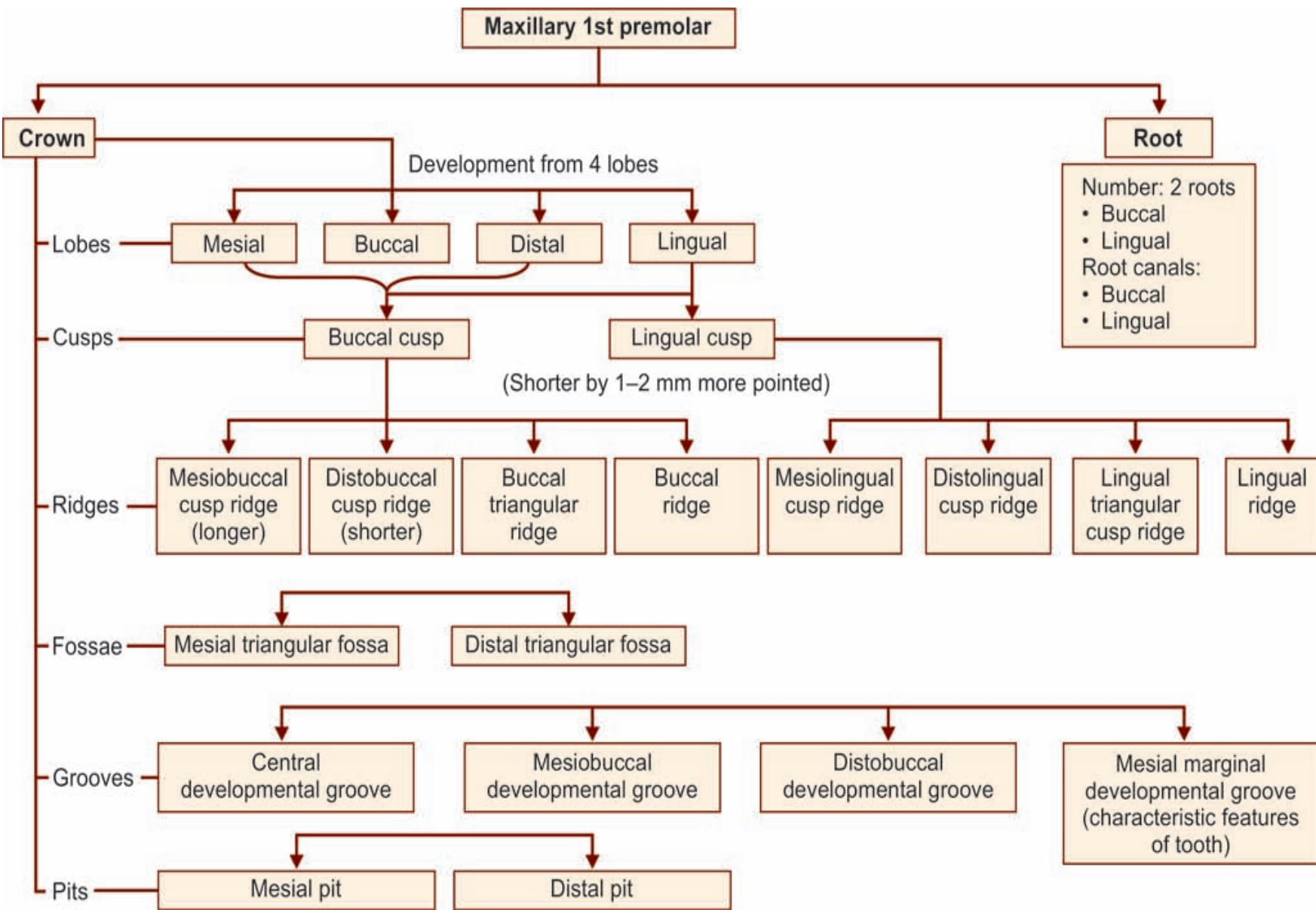
Figure 10.7 Maxillary 1st premolar—mesial aspect

Figure 10.8 Maxillary 1st premolar—distal aspect

Flow chart 10.2 Maxillary 1st premolar—summary



Flow chart 10.1 Maxillary 1st premolar—major anatomic landmarks



Box 10.1 Maxillary 1st premolar—identification features

Identification features of maxillary 1st premolar

- Tooth has two cusps, lingual cusp is shorter
- It frequently has two roots and sometimes single root with deep developmental grooves
- Mesial developmental depression on mesial surface of crown which may extend onto root surface
- Mesial marginal developmental groove is the distinguishing feature of maxillary first permanent premolar

Side identification

- Presence of mesial marginal developmental groove on the mesial side
- Deep developmental depression on mesial surface of the root

Maxillary 2nd Premolar

← Distal

Mesial → ← Mesial

Distal →

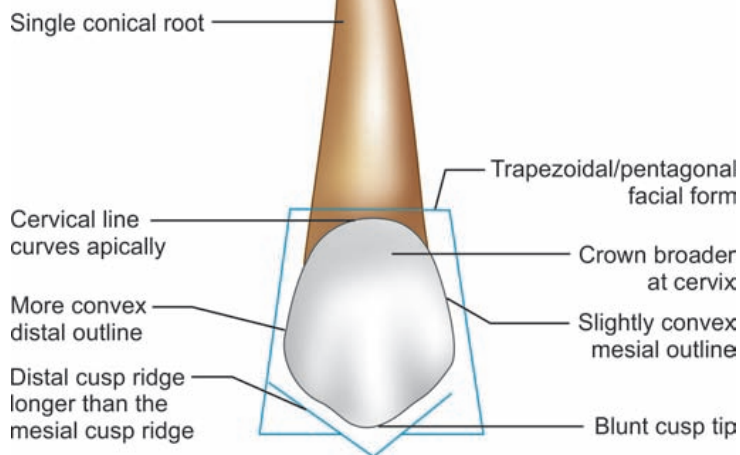


Figure 10.15 Maxillary 2nd premolar—buccal aspect

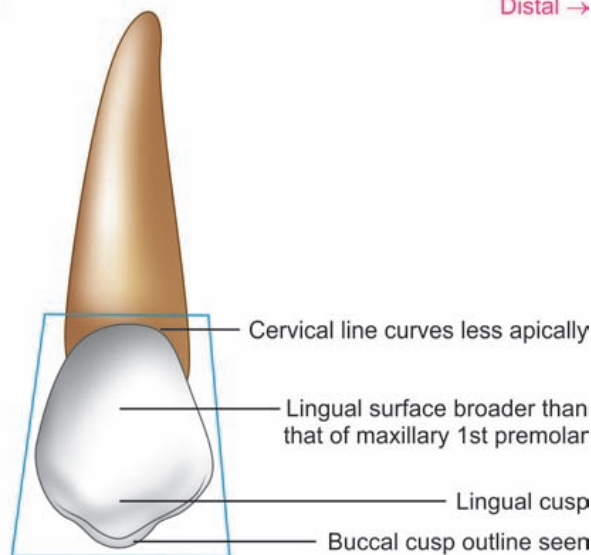


Figure 10.16 Maxillary 2nd premolar—lingual aspect

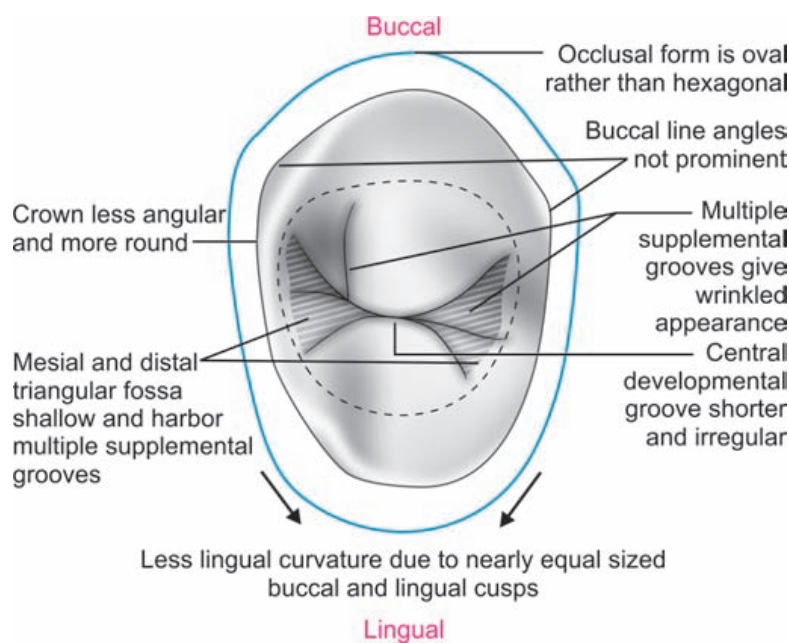


Figure 10.19 Maxillary 2nd premolar—occlusal aspect

← Buccal

Lingual →

← Lingual

Buccal →

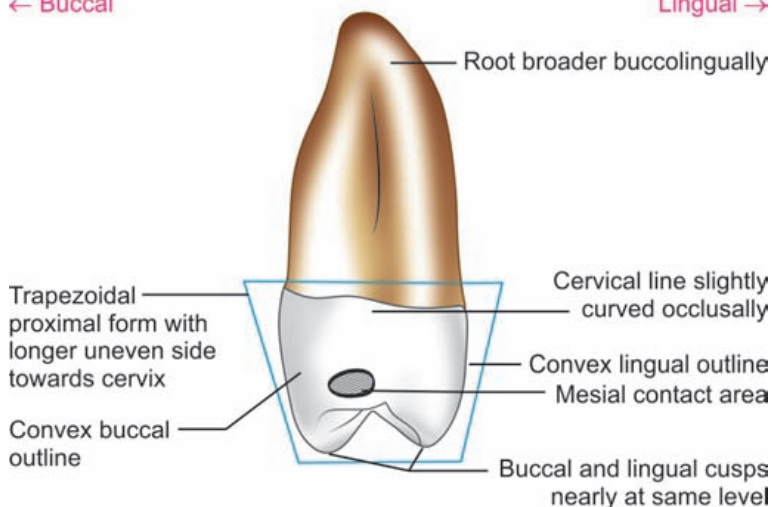


Figure 10.17 Maxillary 2nd premolar—mesial aspect

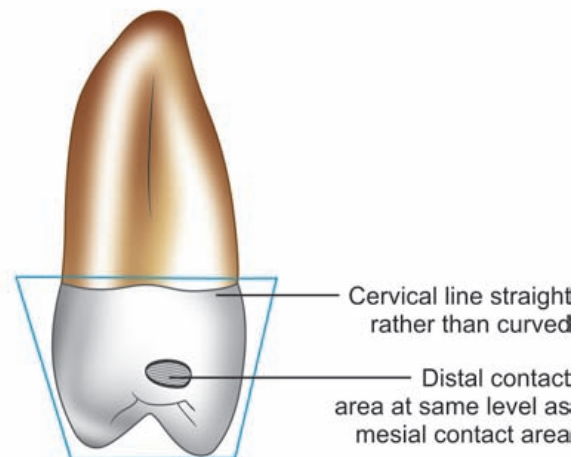


Figure 10.18 Maxillary 2nd premolar—distal aspect

Flow chart 10.4 Maxillary 2nd premolar—summary

Maxillary 2nd premolar

Crown

Root

Buccal aspect

Lingual aspect

Mesial aspect

Distal aspect

Occlusal aspect

Geometric shape

- Trapezoidal with shorter uneven side towards cervix

Crown outlines

- Mesial—slightly convex
- Distal—more convex

Buccal cusp ridges

- Mesial—shorter
- Distal—longer

Buccal cusp tip

- Less pointed than maxillary 1st premolar

Buccal ridge

- Less prominent

Buccal surface

- Crown thicker at cervical portion
- Buccal surface convex

- Trapezoidal like buccal aspect

Lingual convergence

- Not marked as lingual cusp is nearly equal in size to buccal cusp

Cusps seen

- Lingual cusp and only a part of buccal profile seen

Lingual surface

- Broader and longer than that of maxillary 1st premolar
- Smooth

- Trapezoidal with shorter uneven side towards occlusal surface

Cusps seen

- Both cusps seen
- Both cusps nearly of same size

Crown outlines

- Buccal—convex
- Lingual—convex

Height of contours

- Buccal—cervical 3rd
- Lingual—middle 3rd

Cervical line

- Curved occlusally

Mesial surface

- Smoothly convex
- No developmental groove crossing marginal ridge

Mesial contact area

- Occlusal to center of crown
- Broader than maxillary 1st premolar

- Trapezoidal like mesial aspect

Similar to mesial aspect except that

- Cervical line—straight rather than curved

- Oval rather than hexagonal
- Less angular form

Relative dimensions

- Crown wider buccolingually than mesiodistally

Line angles

- Crown less angular, more rounded
- Buccal line angles—less prominent

Cusps

- Both cusps well formed
- Tips blunt

Developmental grooves

- Central groove—shorter and irregular
- Multiple supplemental grooves radiate from central groove—give wrinkled appearance

Fossae

- Mesial and distal triangular fossae

Pits

- Mesial and distal

Number

- Single

Pulp canals

- Single

Size

- Same length as that of maxillary 1st premolar

Form

- Narrow mesiodistally, broad buccolingually

Developmental depression

- Deeper on distal surface

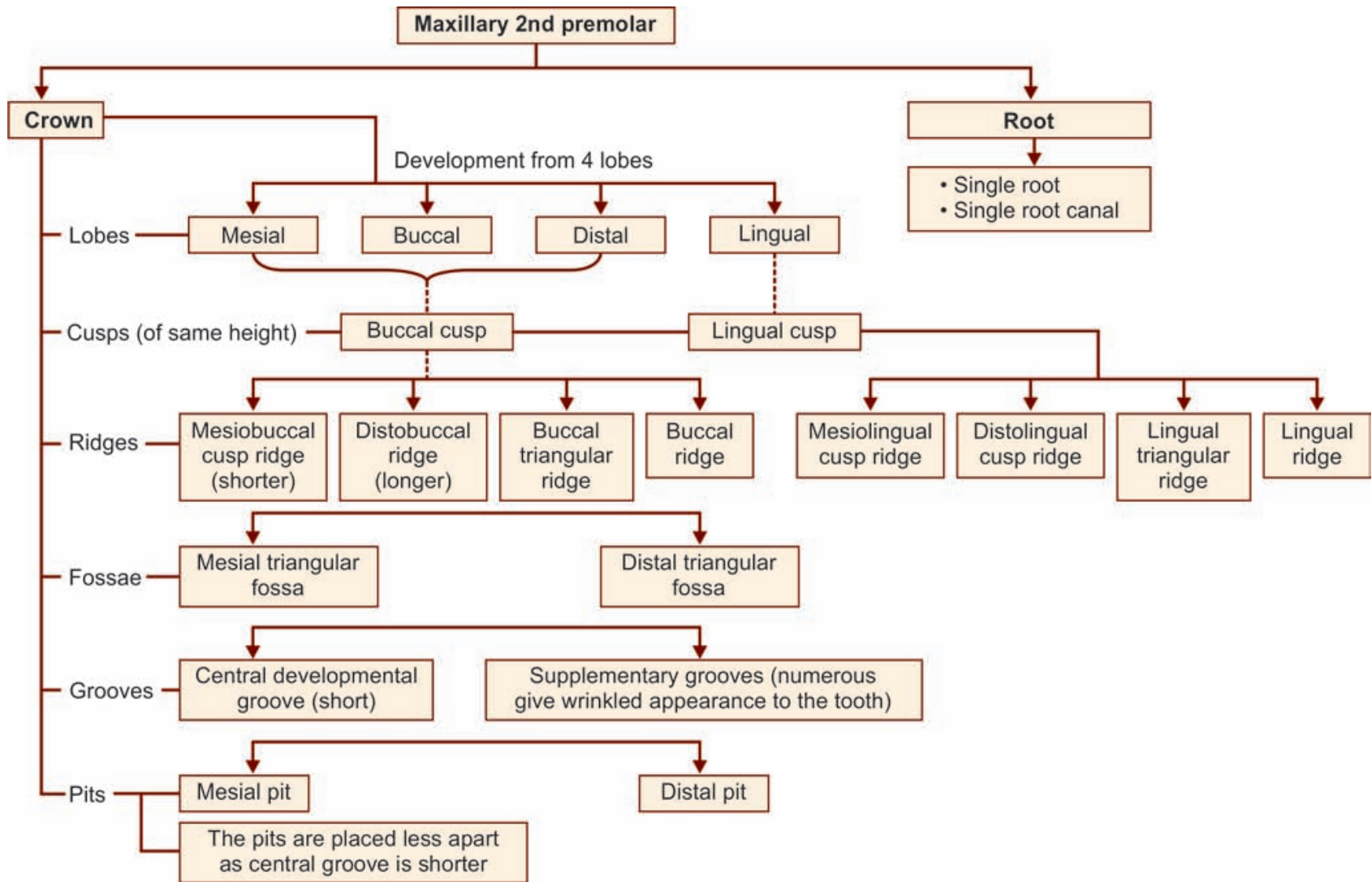
Apical root curvature

- Distal curvature

Apex

- Blunt

Flow chart 10.3 Maxillary 2nd premolar—major anatomic landmarks



Box 10.2 Maxillary 2nd premolar—identification features

Identification features of maxillary 2nd premolar

- Both the cusps are of almost equal size and the crown is not inclined on its root base
- Tooth has a single root
- The crown is less angular and more rounded from occlusal view
- There are no developmental grooves crossing the marginal ridges
- Central developmental groove is shorter and occlusal surface has a wrinkled appearance because of multiple supplementary grooves.

Side identifications

- Distal slope/cusp ridge of buccal cusp is longer than that of mesial
- Root may show distal curvature at its apical third
- Developmental depression deeper on distal surface of root.

Mandibular First Premolar

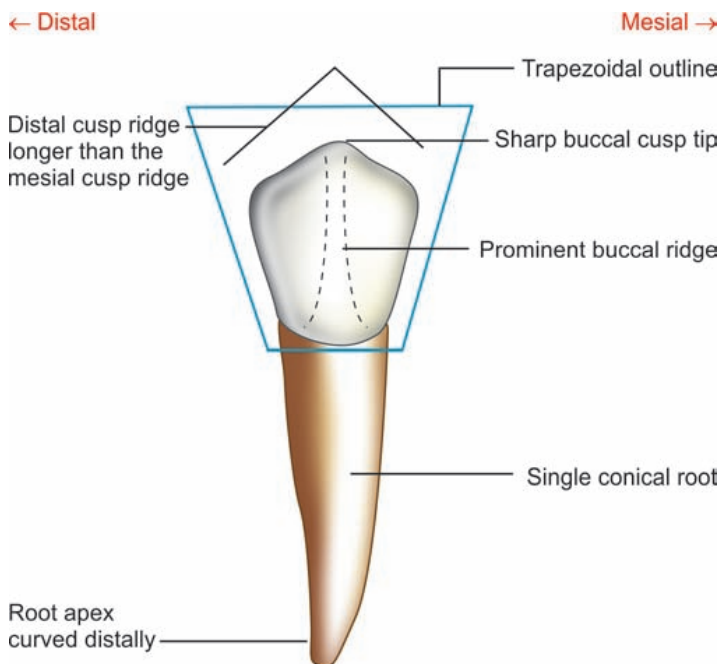


Figure 11.5 Mandibular 1st premolar—buccal aspect

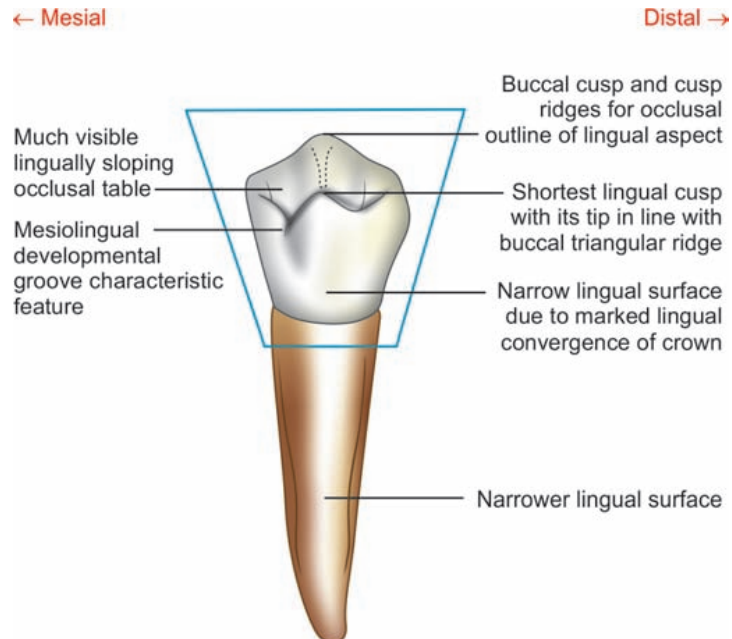


Figure 11.6 Mandibular 1st premolar—lingual aspect

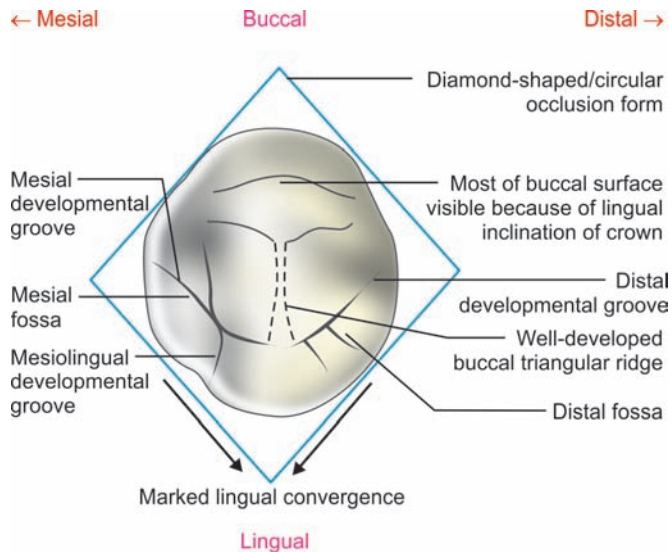


Figure 11.9 Mandibular 1st premolar—occlusal aspect

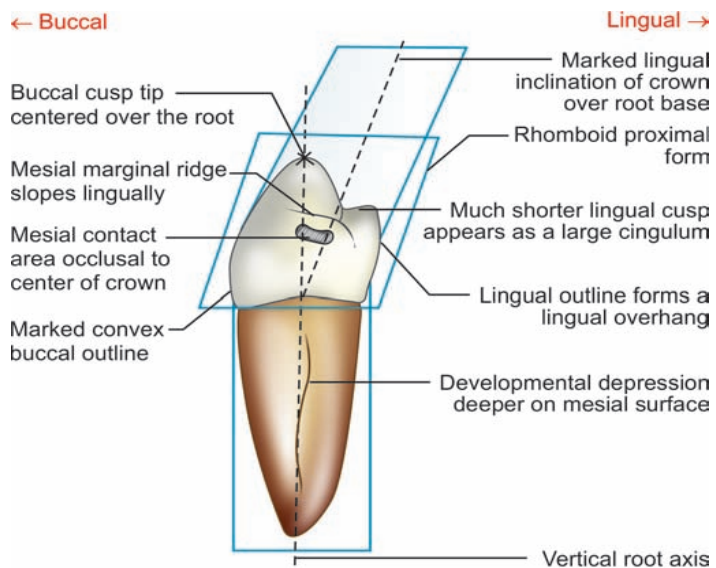


Figure 11.7 Mandibular 1st premolar—mesial aspect

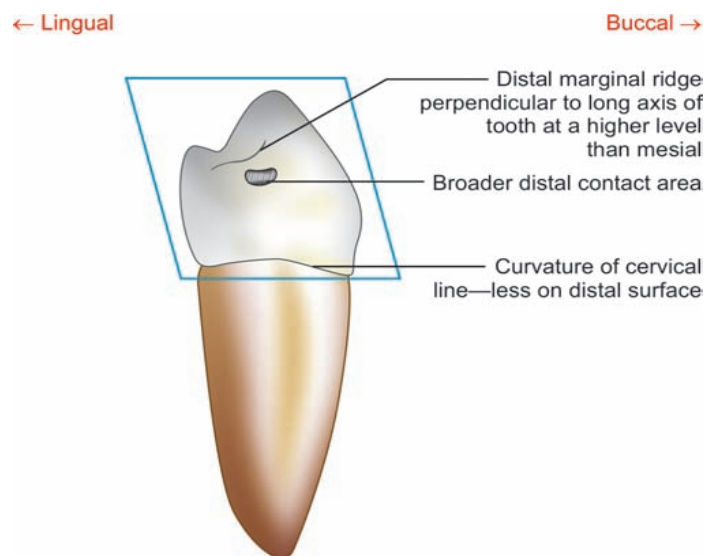


Figure 11.8 Mandibular 1st premolar—distal aspect

Flow chart 11.2 Mandibular 1st premolar—summary

Mandibular 1st premolar

Crown

Buccal aspect

- Geometric shape**
 - Trapezoidal
- Crown outlines**
 - Mesial—slightly convex
 - Distal—slightly convex
- Cusps seen:** Only buccal
- Buccal cusp ridges**
 - Mesial—shorter
 - Distal—longer
- Buccal cusp tip**
 - Sharp, pointed
 - Placed mesial to center of crown
- Buccal ridge**
 - Prominent
- Buccal surface**
 - Smooth and convex
 - Crown appears broader with narrow cervix

Lingual aspect

- Trapezoidal
- Cusps seen**
 - Lingual cusp
 - Most of buccal cusp with tip and ridges seen
- Lingual convergence**
 - Crown tapers markedly towards much smaller lingual cusp
- Occlusal surface visibility**
 - Occlusal table slopes lingually
 - Most of occlusal surface seen
- Lingual cusp tip**
 - Pointed
 - In line with buccal triangular ridge
- Lingual surface**
 - Much narrower
- Mesiolingual developmental groove**
 - Characteristic feature
 - Extends from occlusal surface onto lingual mesially

Mesial aspect

- Rhomboidal
- Cusps seen**
 - Both cusps seen
- Crown outlines**
 - Buccal—markedly convex
 - Lingual—stretches out of confines of root
- Lingual inclination**
 - Crown shows marked lingual inclination over root base
 - Creates lingual overhang
- Cusp tip location**
 - Buccal—centered over root base
 - Lingual—in line with lingual outline of root
- Mesial marginal ridge**
 - Slopes lingually
 - Cervically placed than distal marginal ridge
- Developmental groove**
 - Mesiolingual developmental groove
- Mesial contact area**
 - Occlusal to center of crown
 - In line with buccal cusp tip

Distal aspect

- Rhomboidal
- Distal marginal ridge**
 - Perpendicular to long axis of tooth
 - It is at higher level than mesial marginal ridge
- Distal surface**
 - Smooth
 - No developmental groove
- Cervical line**
 - Straight line
 - Not curved
- Distal contact area**
 - Same level
 - Broader

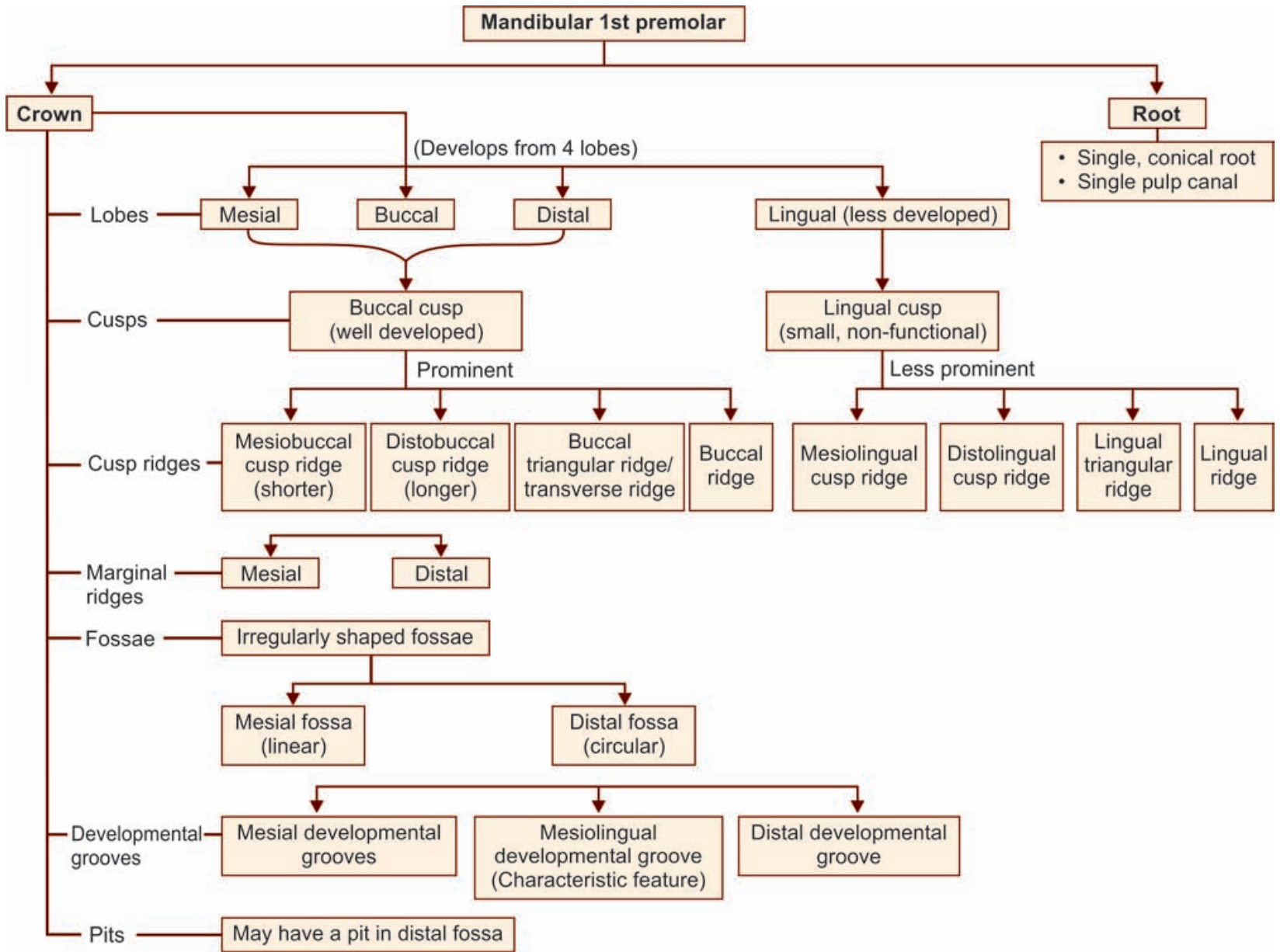
Occlusal aspect

- Diamond-shaped/circular
- Relative dimensions**
 - Buccolingual dimension 0.5 mm greater than mesio-distal dimension
 - Therefore circular appearance
- Lingual inclination**
 - Thus more of buccal surface seen and less of lingual surface seen
- Cusps**
 - Buccal—larger makes bulk of crown
 - Lingual—much smaller
- Cusp ridges**
 - Buccal cusp ridges—well developed
 - Lingual cusp ridges—ill defined
- Grooves**
 - Mesial developmental groove
 - Distal developmental groove
 - Mesiolingual developmental groove
- Fossae**
 - Irregular mesial and distal fossae
- Pits:** Distal pit

Root

- Number**
 - Single
- Pulp canal**
 - Single
- Size**
 - 3–4 mm shorter than mandibular canine
- Form**
 - Conical
 - Wider buccolingually
 - Markedly converges towards lingual
- Developmental depression**
 - Deeper on mesial surface of root
- Apical curvature**
 - Distally curved
- Apex**
 - Pointed

Flow chart 11.1 Mandibular 1st premolar—major anatomic and landmarks



Box 11.1 Mandibular 1st premolar—identification features

Identification features of mandibular 1st premolar

- Large pointed buccal cusp and a very small lingual cusp
- Marked lingual inclination of crown on its root base as observed from proximal view
- The buccal tip is centered over the root trunk as seen from proximal view
- The lingual cusp tip is in line with the lingual outline of the root or may extend lingually out of confines of the root
- *Mesiolingual developmental groove* between mesial marginal ridge and mesiolingual cusp ridge, crossing onto the mesial portion of lingual surface is the characteristic feature of the tooth
- It has a single root.

Side identification

- By locating the mesiolingual developmental groove, it is on the lingual surface towards mesial portion of the crown
- Developmental groove is deeper on the mesial surface of the root which may also have a developmental groove at its center.

Mandibular 2nd Premolar

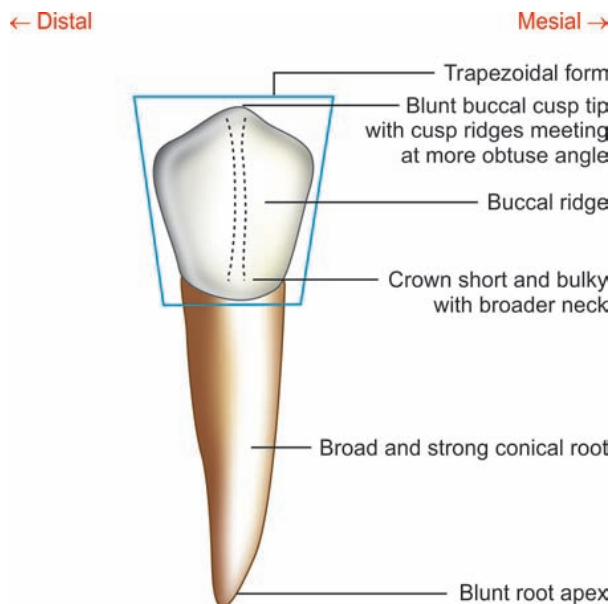


Figure 11.16 Mandibular 2nd premolar—buccal aspect

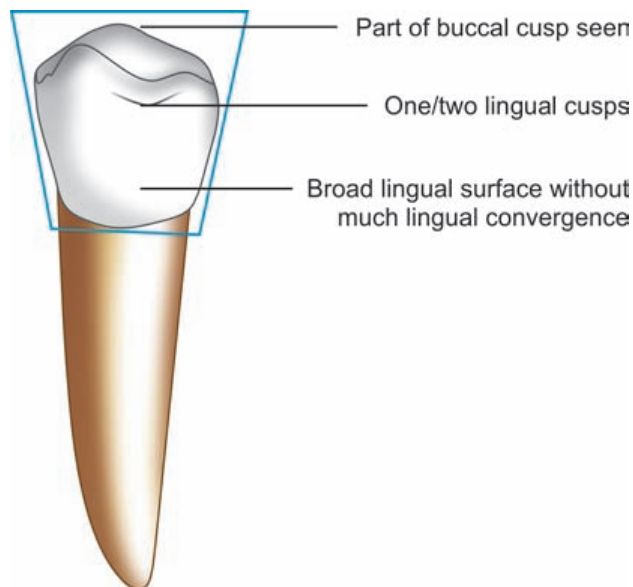


Figure 11.17 Mandibular 2nd premolar—lingual aspect

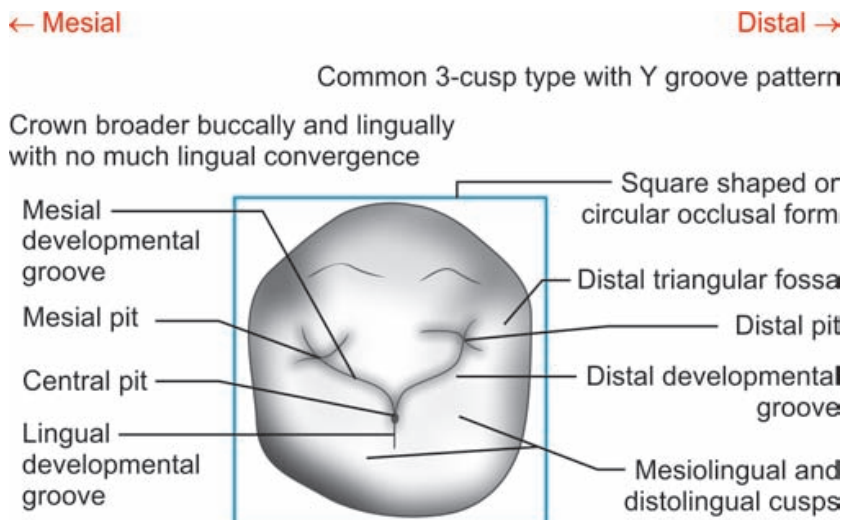


Figure 11.20 Mandibular 2nd premolar—occlusal aspect

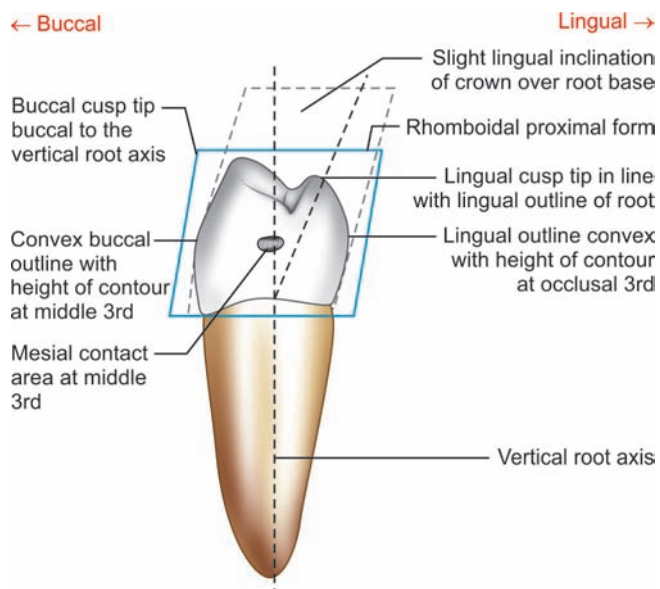


Figure 11.18 Mandibular 2nd premolar—mesial aspect

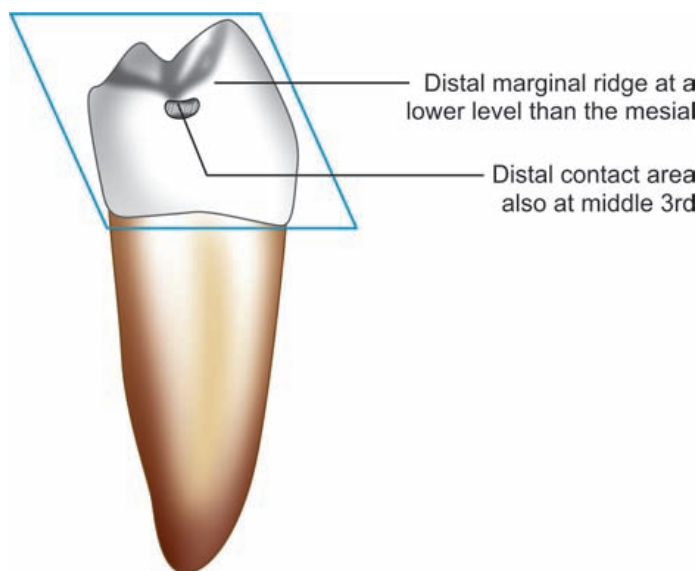
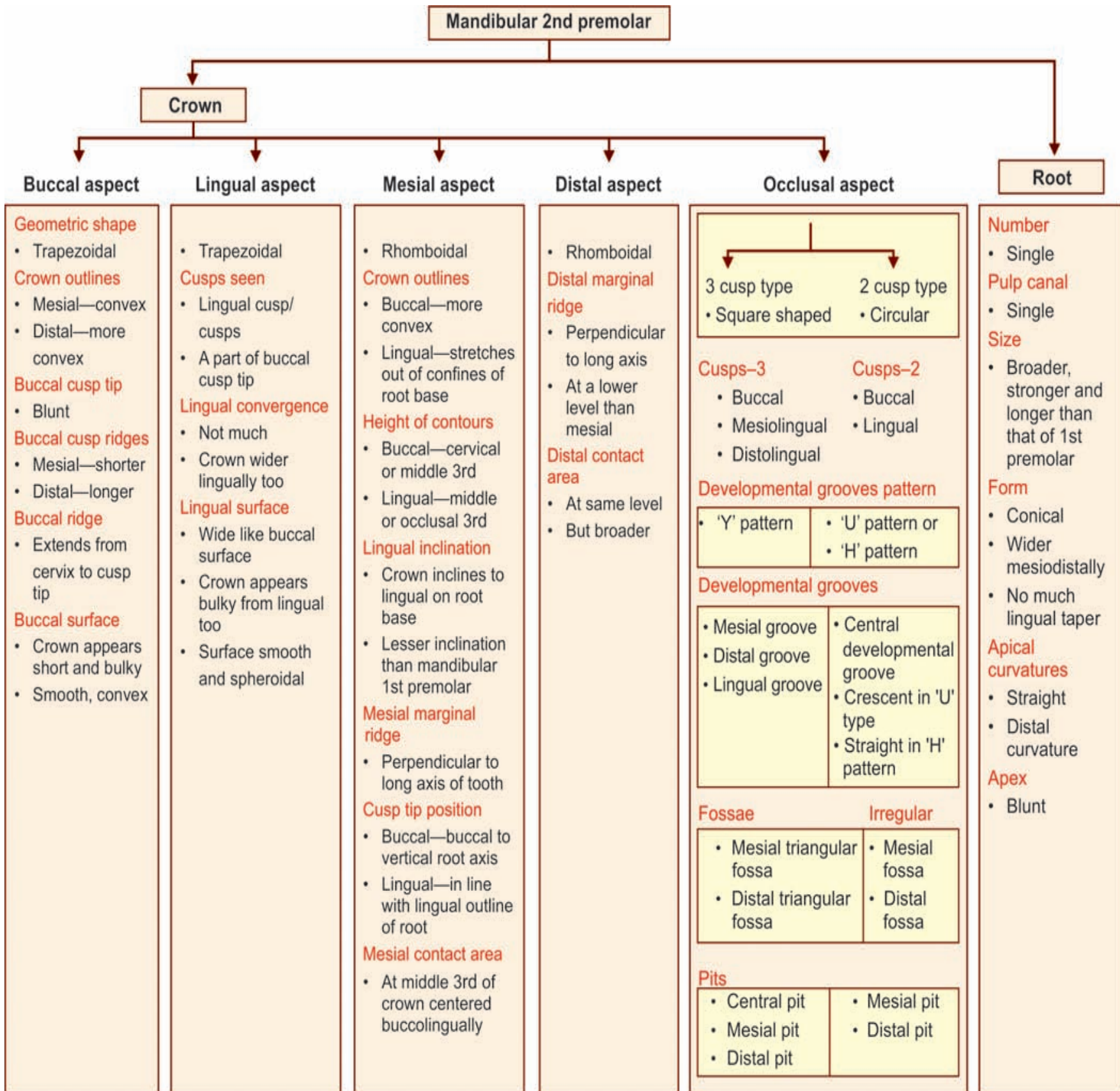
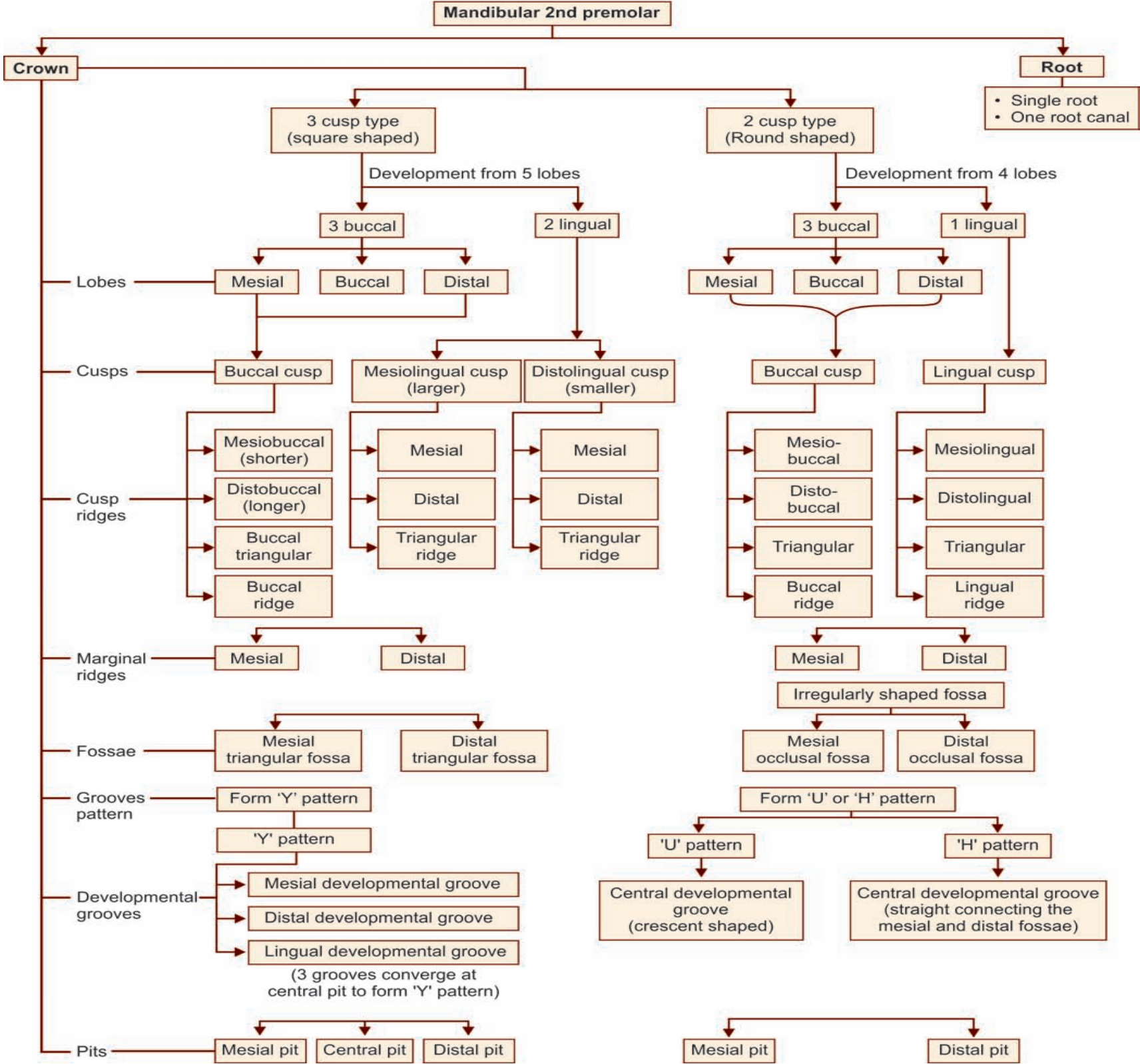


Figure 11.19 Mandibular 2nd premolar—distal aspect

Flow chart 11.4: Mandibular 2nd premolar—summary





Box 11.2 Mandibular permanent 2nd premolar—identification features

Identification features of mandibular 2nd premolar

- Lingual lobes are well developed into one or two lingual cusps
- It is the only premolar with three cusps
- The lingual cusps are almost at the same height as that of buccal cusps
- Lingual inclination of crown on root base
- The three cusps type has 'Y' shaped groove pattern on occlusal surface
- On two cusp type 'U' or 'H' shaped groove pattern seen
- Crown and root have very slight lingual convergence
- Mesiolingual developmental groove not present
- Single root with less tendency for bifurcation.

Side identification

- Apical third of the root may show a distal curvature.
- In 3 cusp type, mesiolingual cusp is larger than the distolingual cusp.

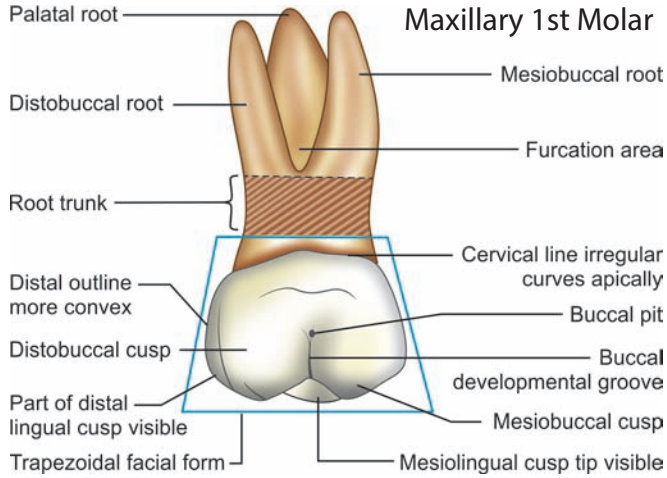


Figure 12.7 Maxillary 1st molar—buccal aspect

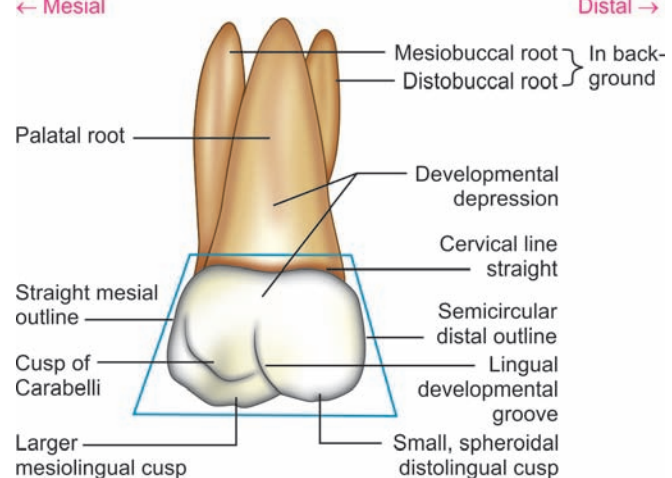
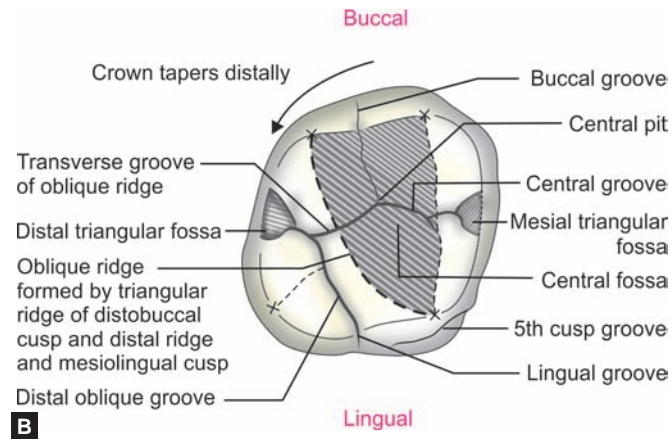
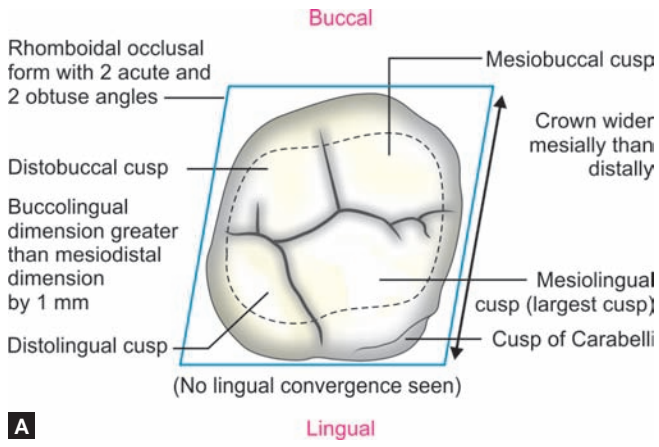


Figure 12.8 Maxillary 1st molar—lingual aspect



Figures 12.11A and B Maxillary 1st molar—occlusal aspect

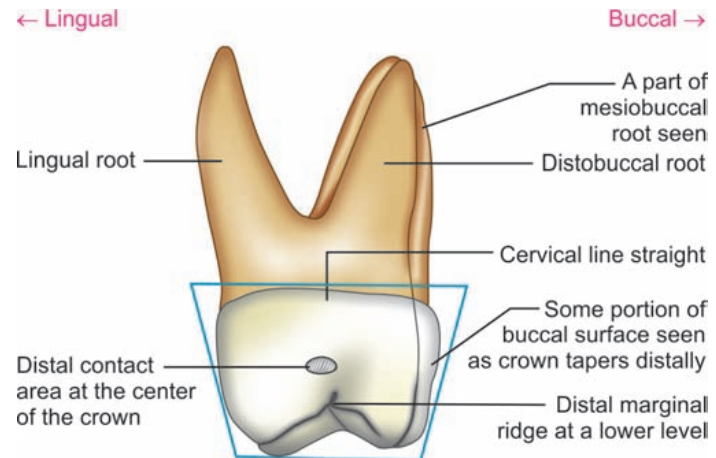


Figure 12.10 Maxillary 1st molar—distal aspect

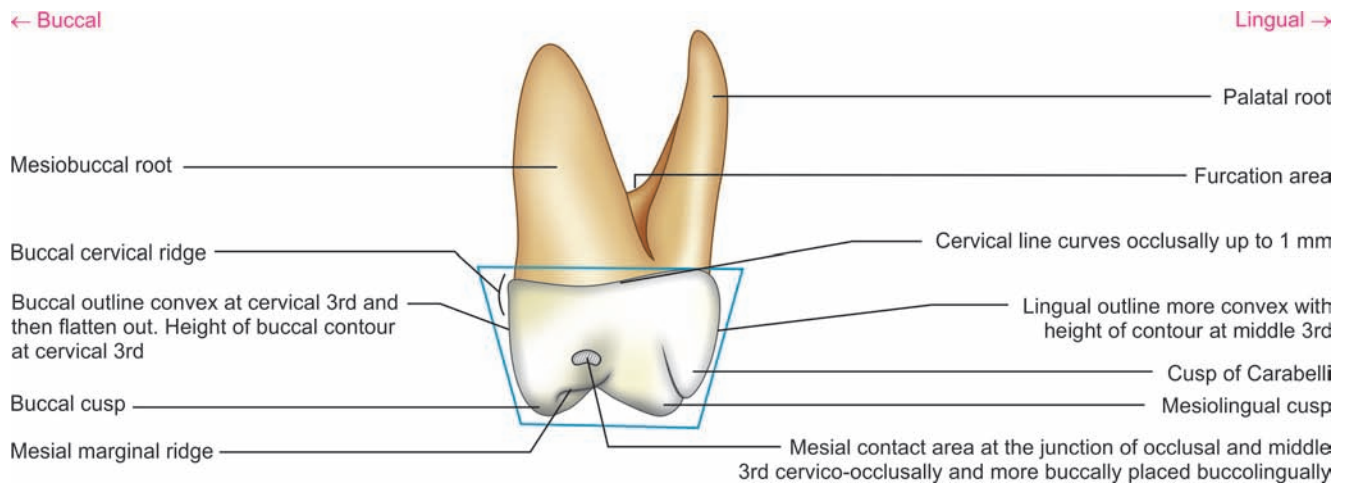


Figure 12.9 Maxillary 1st molar—mesial aspect

Flow chart 12.2 Maxillary 1st molar—summary

Maxillary 1st molar

Crown

Root

Buccal aspect

Lingual aspect

Mesial aspect

Distal aspect

Occlusal aspect

Geometric shape

- Trapezoidal with shorter uneven side towards cervix

Crown outlines

- Mesial—slightly convex
- Distal—more convex

Cusps seen

- Both the buccal cusps
- Part of lingual cusps (all cusps seen)

Buccal cusps

- Mesiobuccal—wider
- Distobuccal—more pointed
- Both cusps are, of same length

Cervical line

- Irregular
- May dip apically towards furcation

Developmental grooves

- Buccal developmental groove

Buccal surface

- Broad
- Convex in cervical 3rd and flattened in middle 3rd

- Trapezoidal like buccal aspect

Lingual convergence

- No lingual convergence
- Crown wider lingually than buccally

Cusps seen

- Only lingual cusps seen

Lingual cusps

- Mesiolingual cusp—larger
- Distolingual cusp—small spheroidal

Accessory cusp/cusp of Carabelli

- Lingual to the mesiolingual cusp

Developmental grooves

- Lingual developmental groove
- Fifth cusp groove

- Trapezoidal with shorter uneven side towards occlusal

Crown outlines

- Buccal—convex—(cervical ridge) cervically and then straight
- Lingual—more convex

Cusps seen

- Mesiobuccal
- Mesiolingual
- Cusp of Carabelli

Height of contours

- Buccal—cervical 3rd on cervical ridge
- Lingual—at middle 3rd

Mesial surface

Concavity present cervical to contact area

Mesial contact area

- At junction of middle and occlusal 3rd
- Buccally placed buccolingually

- Trapezoidal like mesial aspect

Cusp seen

- Only distobuccal and distolingual cusps seen

Distal marginal ridge

- Shorter
- At lower level than mesial marginal ridge

Cervical line

- Straight line without curvature

Distal contact area

- At center of crown both cervico-occlusally and buccolingually

- Rhomboidal with 2 acute and 2 obtuse angles
- 2 acute angles—mesiobuccal and distolingual
- 2 obtuse angles—distobuccal and mesiolingual angles

Relative dimensions

- Buccolingual dimension greater than mesiodistal dimension by 1 mm

Crown taper

- Towards distal
- Crown wider buccolingually at mesial than distal characteristic feature of maxillary 1st molar

Oblique ridge

- Characteristics feature

Developmental grooves

- Buccal groove
- Lingual groove
- Central groove
- Transverse groove of oblique ridge
- Distal oblique groove
- Fifth cusp groove

Fossae

- 2 major**
 - Central fossa
 - Distal fossa
- 2 minor**
 - Mesial and distal triangular fossae

Pits

- Central
- Mesial
- Distal

Number

- 3 roots
- Mesiobuccal
- Distobuccal
- Palatal

Pulp canals

- 3 or 4 canals

Size

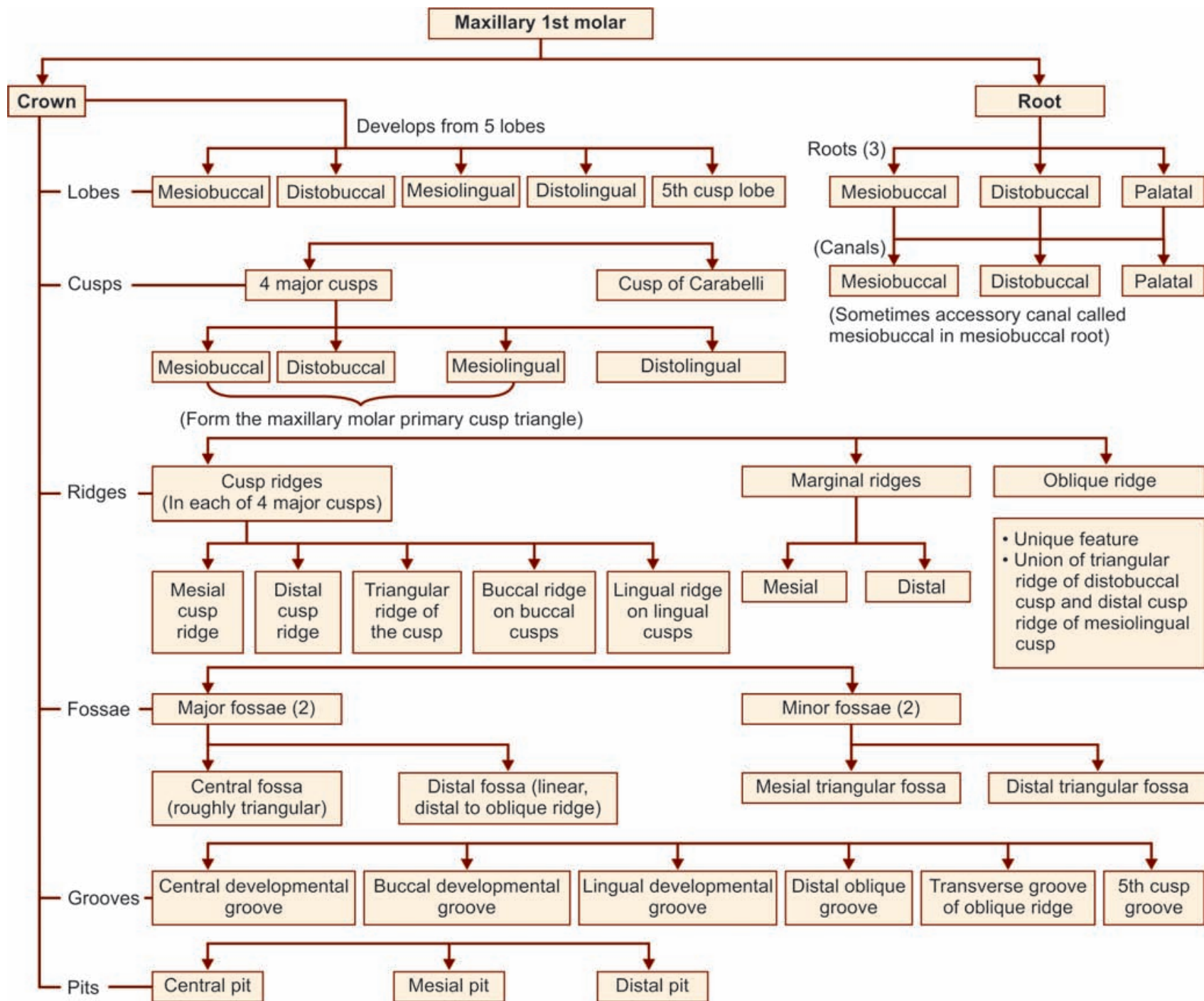
- Twice the length or crown
- All 3 roots of same length
- Palatal larger

Root curvature

- Buccal roots tilt distally
- Palatal root—straight

Apices

Blunt



Box 12.1 Maxillary 1st molar—identification features

Identification features of maxillary 1st molar

- The tooth has a large crown and three roots
- The crown is wider buccolingually than mesiodistally
- Its occlusal aspect is rhomboidal
- The cusp of Carabelli is a unique feature of maxillary molar, present lingual to the mesiolingual cusp
- Another characteristic feature of maxillary molar is the oblique ridge running obliquely from the mesiolingual cusp to the distolingual cusp.

Side identification

- When viewed occlusally, the crown is wider mesially than distally
- By locating the cusp of Carabelli that is located lingual to the mesiolingual cusp
- The buccal roots tend to have a distal inclination.

Maxillary 2nd Molar

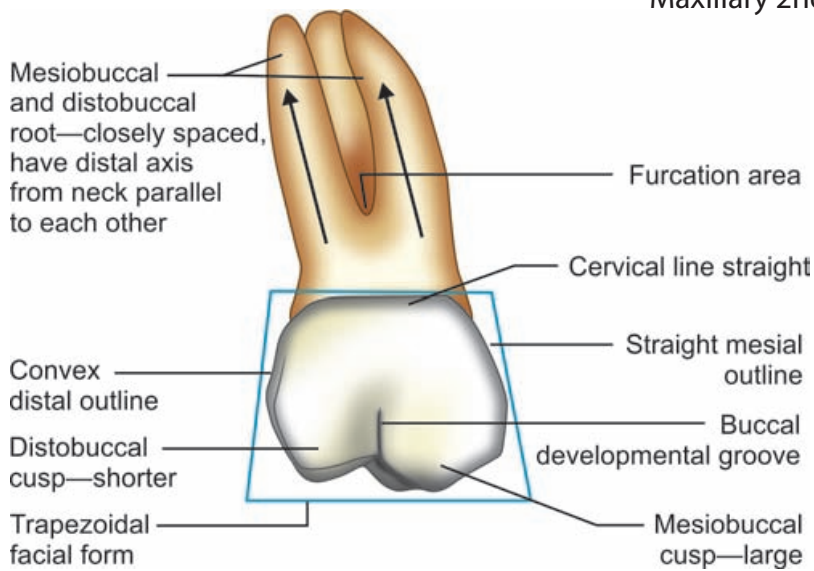


Figure 12.20 Maxillary 2nd molar—buccal aspect

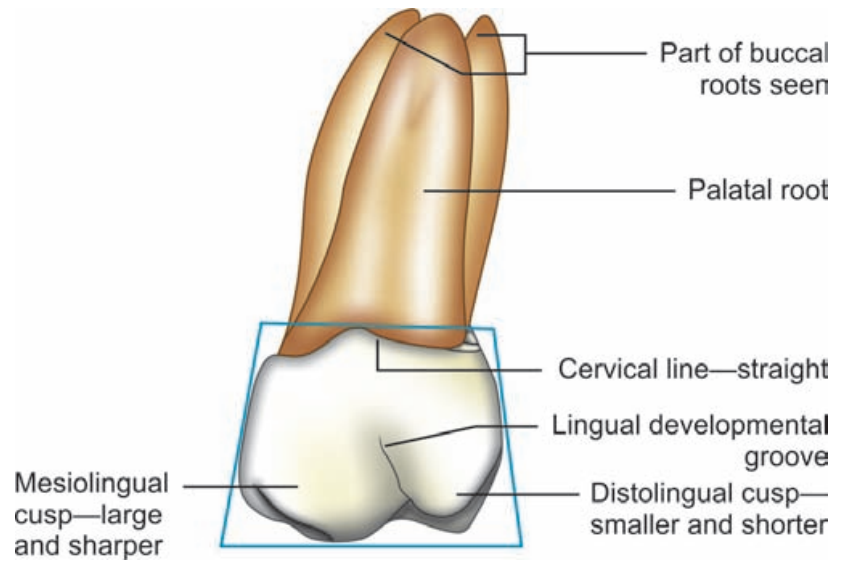


Figure 12.21 Maxillary 2nd molar—lingual aspect

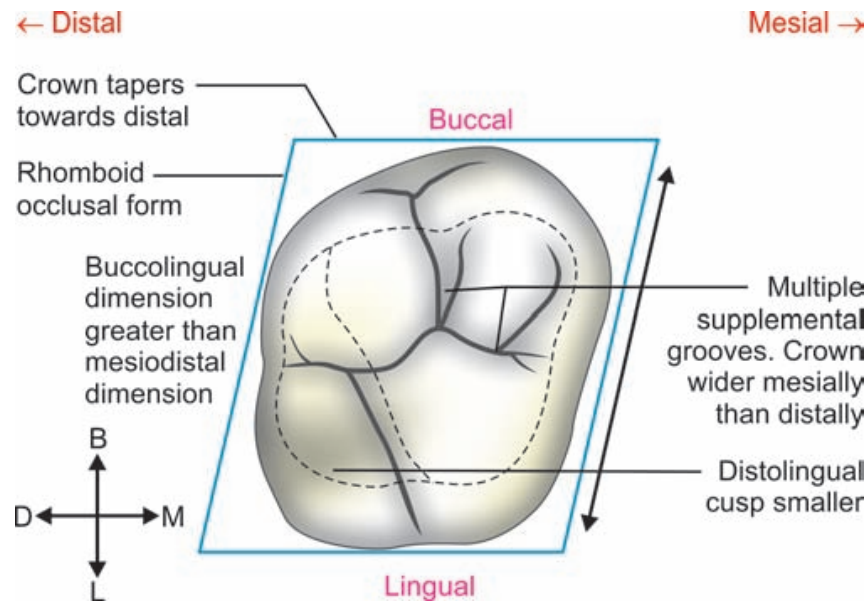


Figure 12.24 Maxillary 2nd molar—occlusal aspect

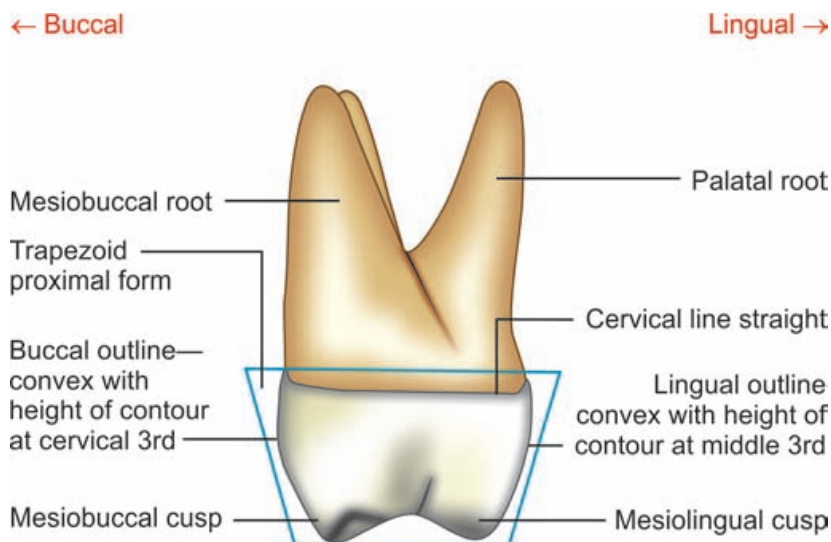


Figure 12.22 Maxillary 2nd molar—mesial aspect

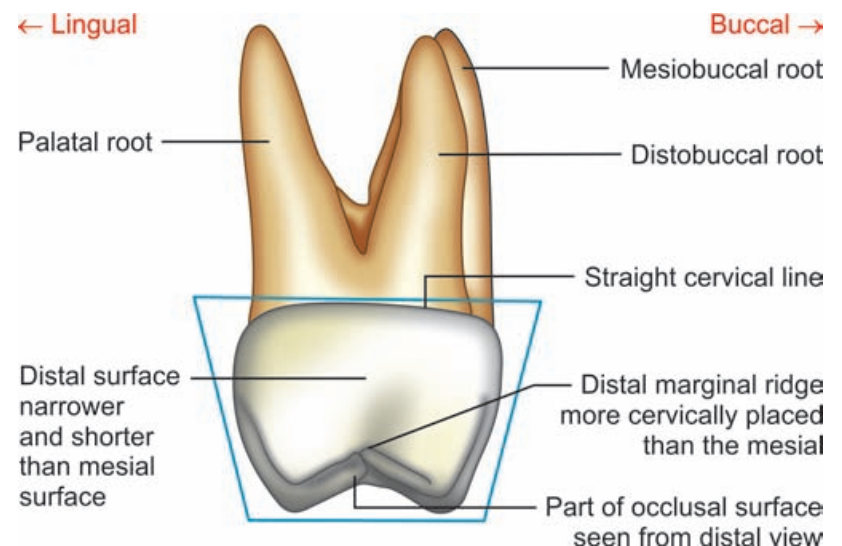
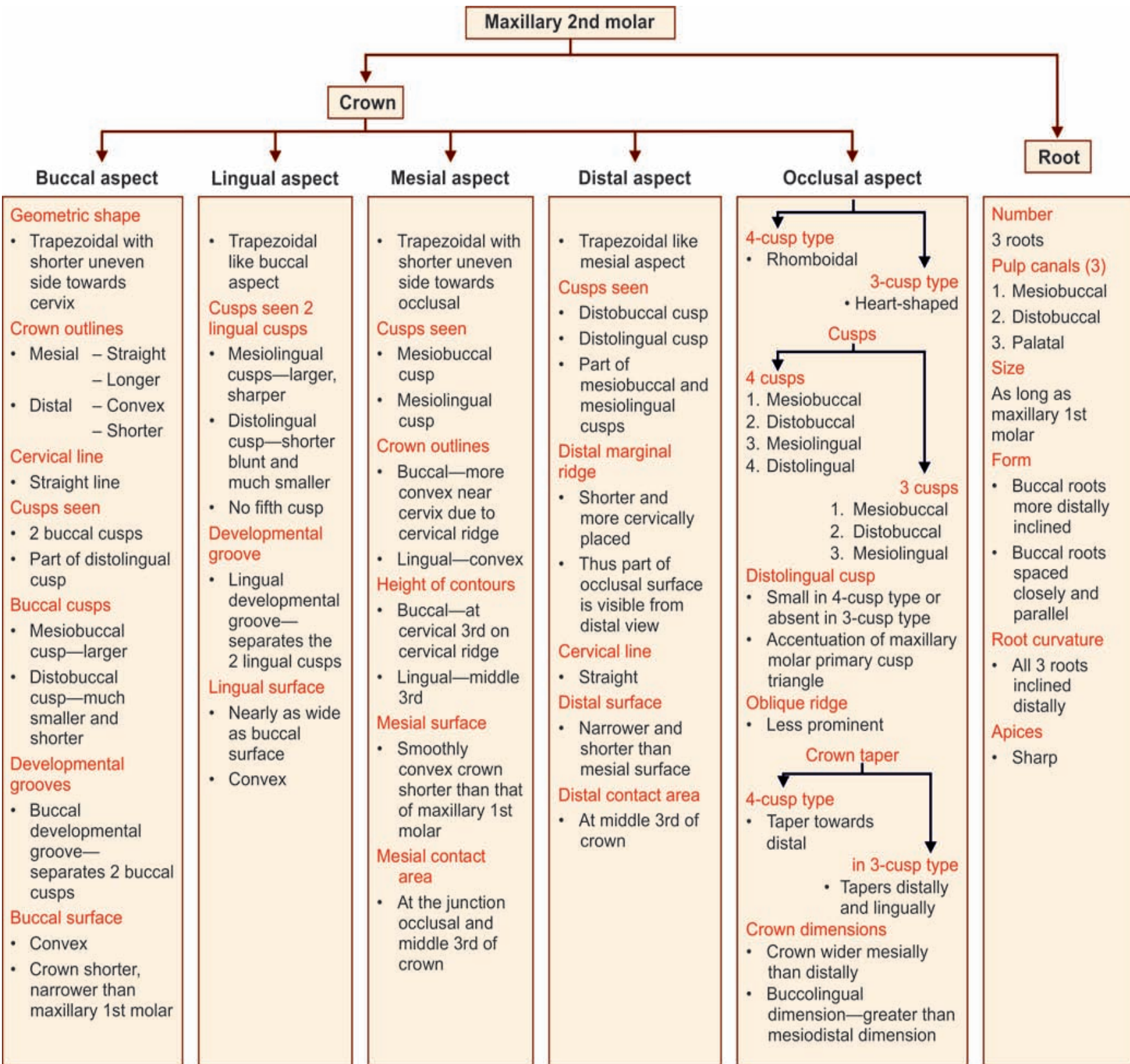
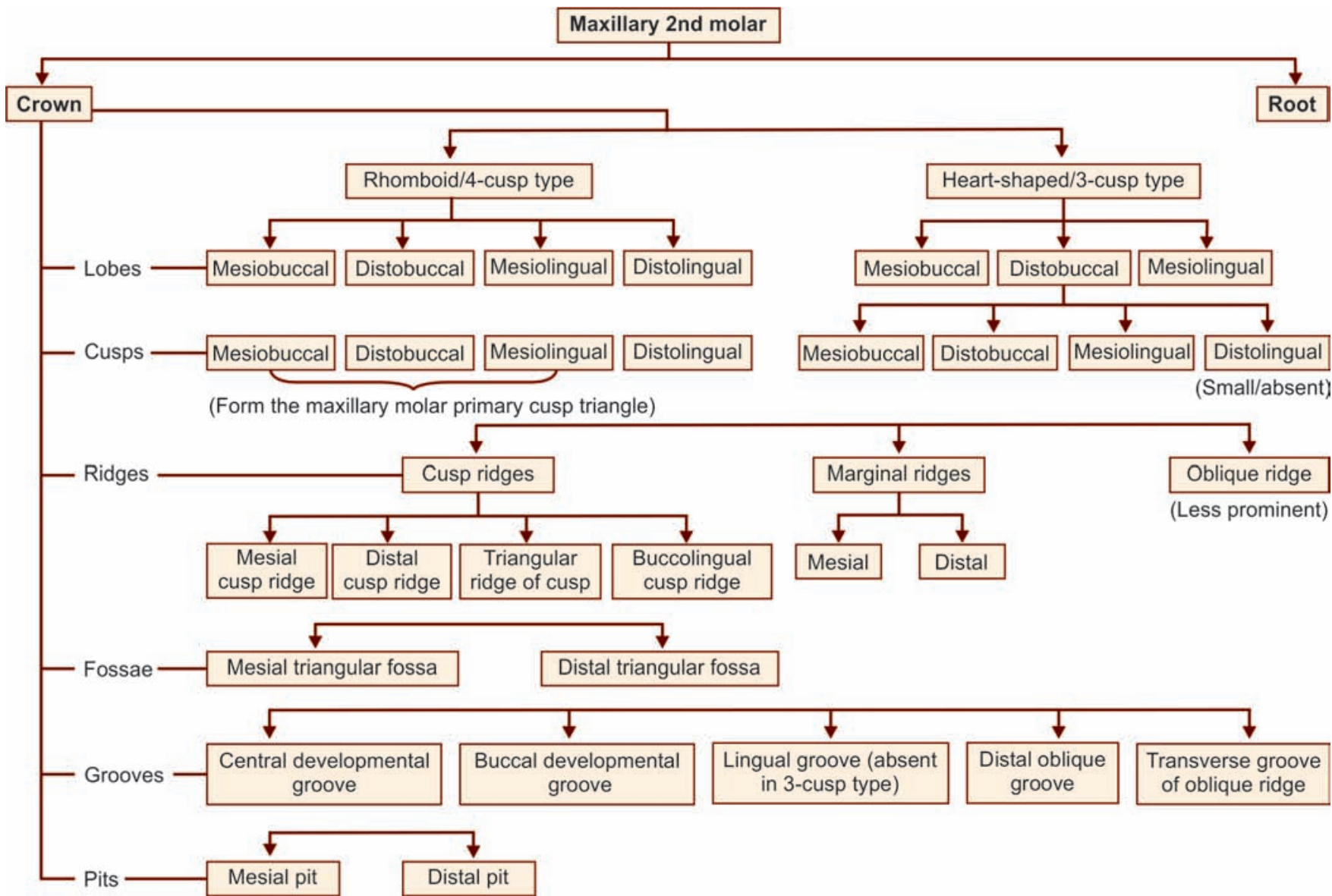


Figure 12.23 Maxillary 2nd molar—distal aspect

Flow chart 12.4 Maxillary 2nd molar—summary



Flow chart 12.3 Maxillary 2nd molar—major anatomic landmarks



Box 12.2 Maxillary 2nd molar—identification features

Identification features of maxillary 2nd molar

- Crown is shorter with comparatively long roots. The root is trifurcated
- There is no evidence of the 5th cusp development
- Mesiolingual cusp is the largest
- Distolingual cusp is small or absent
- The oblique ridge is less prominent
- The roots do not spread out much, tend to fuse and have a distal inclination.

Side identification

- The crown is wider mesially than distally
- The distolingual cusp is small or absent
- The roots are not wide apart and are inclined distally.

Maxillary 3rd Molar

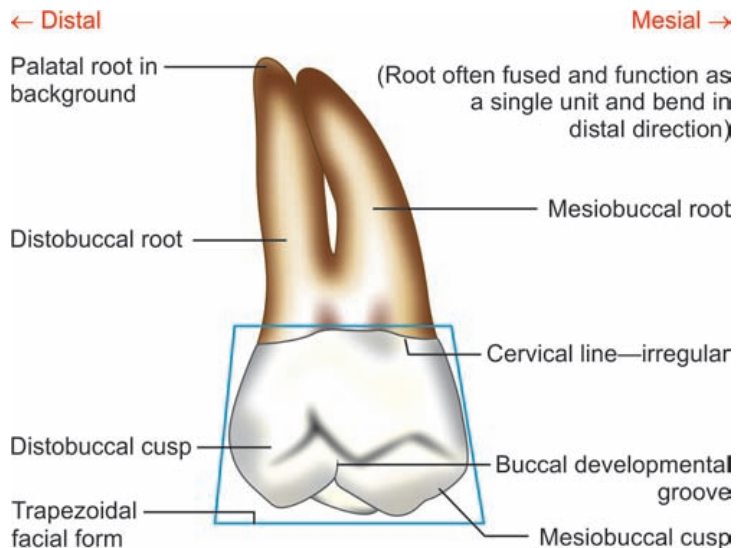


Figure 12.30 Maxillary 3rd molar—buccal aspect

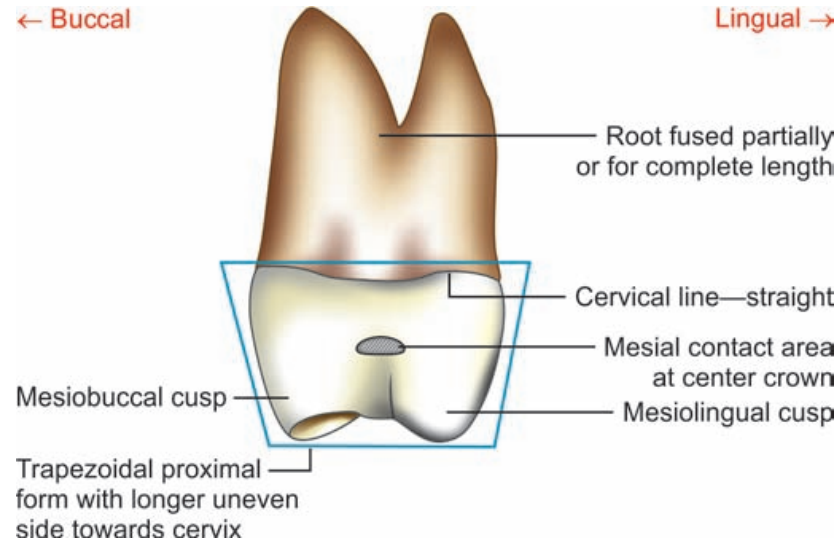


Figure 12.31 Maxillary 3rd molar—lingual aspect

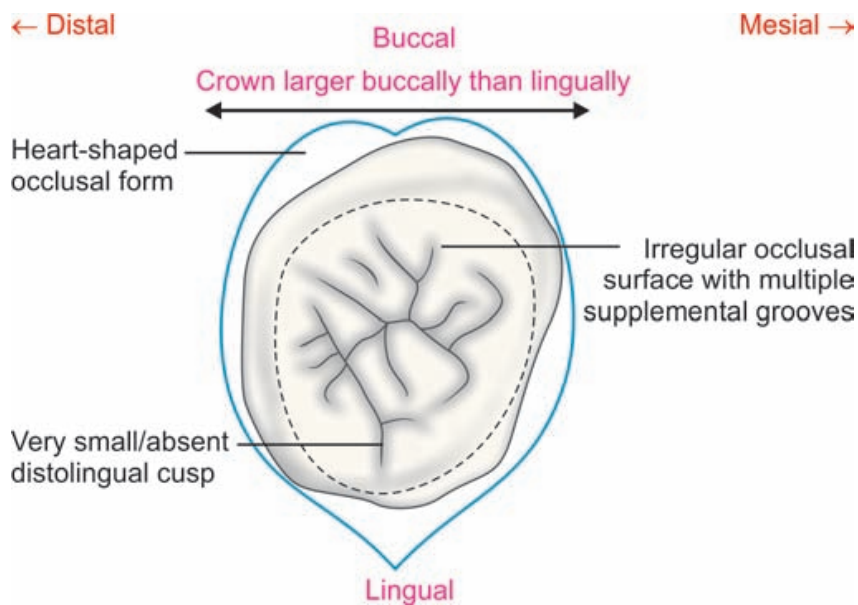


Figure 12.34 Maxillary 3rd molar—occlusal aspect

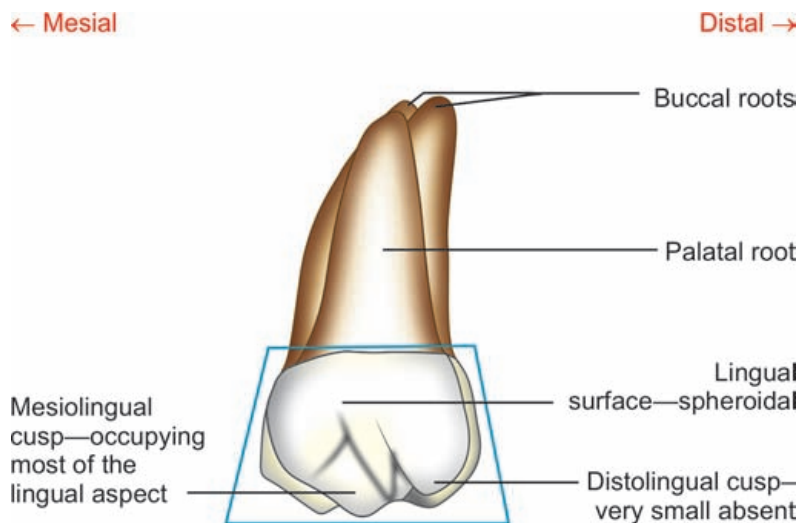


Figure 12.32 Maxillary 3rd molar—mesial aspect

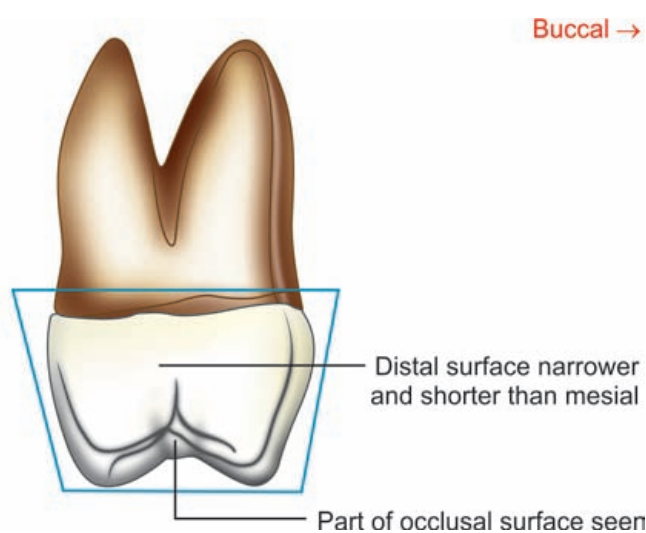


Figure 12.33 Maxillary 3rd molar—distal aspect

Maxillary 3rd molar

Crown

Buccal aspect

Geometric shape

- Trapezoidal with shorter uneven side towards cervix

Cusps seen

- Mesiobuccal cusp
- Distobuccal cusp
- Part of mesiolingual cusp

Cervical line

- Irregular

Developmental grooves

- Buccal developmental groove—separates 2 buccal cusps

Buccal surface

- Crown—shorter and narrower

Lingual aspect

- Trapezoidal like buccal aspect

Cusps seen

- Mesiolingual
- Very small/absent distolingual cusp

Developmental groove

- Lingual developmental groove is not present

Lingual surface

- Spheroidal
- Smooth

Mesial aspect

- Trapezoidal with shorter uneven side towards occlusal

Cervical line

- Straight

Cusps seen

- Mesiobuccal cusp
- Mesiolingual cusp

Mesial surface

- Smooth

Mesial contact area

- At center of groove mesiodistally and cervicoincisally

Distal aspect

- Trapezoidal like mesial aspect

Cusps seen

- All cusps seen

Distal marginal ridge

- Is cervically placed than mesial marginal ridge
- Thus part of occlusal table visible

Distal surface

- Shorter and narrower than mesial surface

Occlusal aspect

- Usually heart-shaped

Relative dimension

- Buccolingual dimension—greater than mesiolingual dimension
- Crown wider buccally than lingually

Occlusal anatomy

- Multiple supplementary grooves
- Crown form may not resemble any tooth and can appear as an anomaly

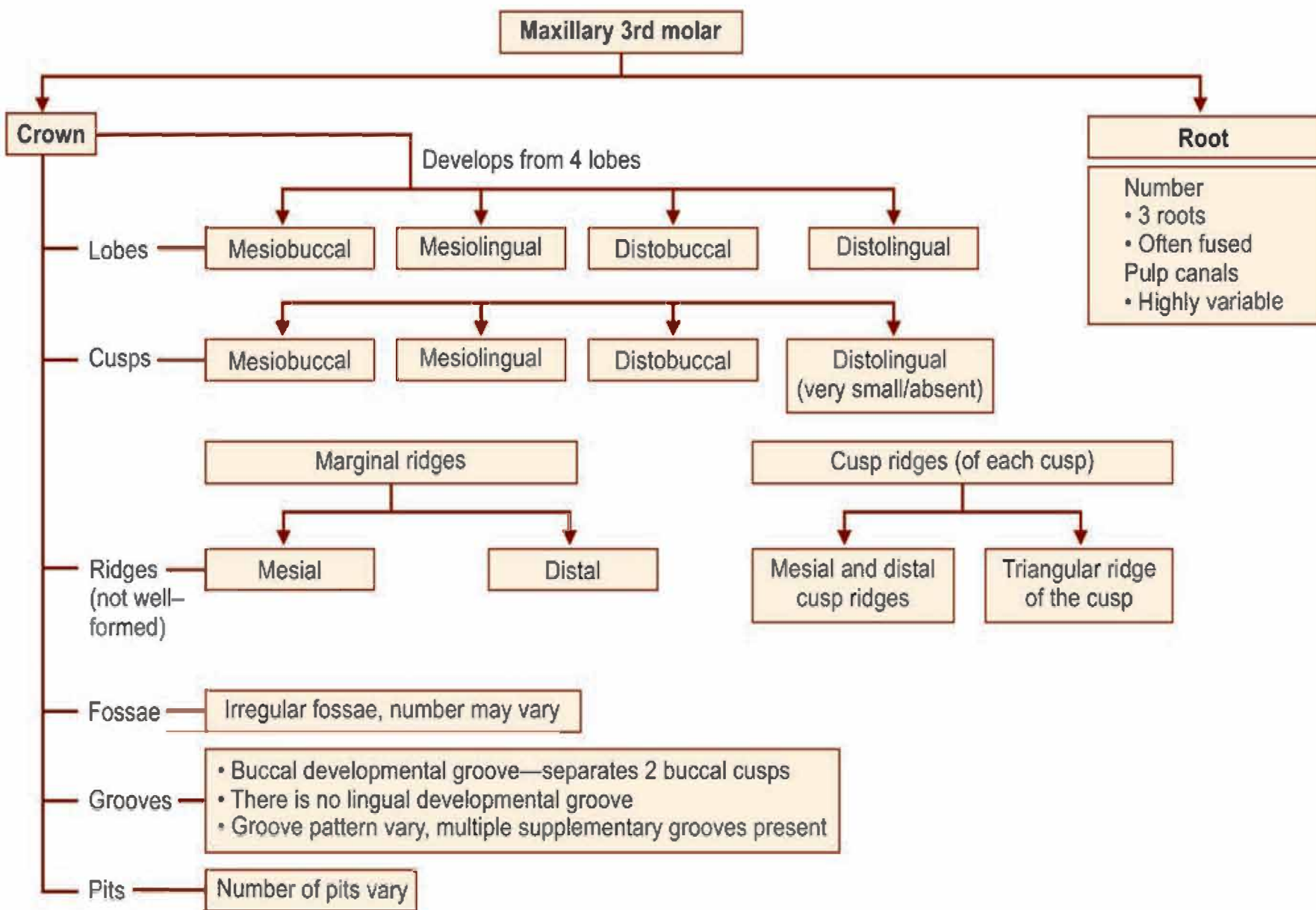
Root

Number

- 3 roots but mostly fused
- Shorter than that of other molars

Pulp canal morphology

- Varies



Box 12.3 Maxillary 3rd molar—identification features

Identification features of maxillary 3rd molar

- Smaller tooth with fused roots
- The crown has heart shaped occlusal outline with a well-developed mesiolingual cusp forming most of the lingual portion
- Very small or no distolingual cusp
- Multiple supplemental grooves and several small tubercles giving an irregular occlusal form to the tooth.

Mandibular 1st Molar

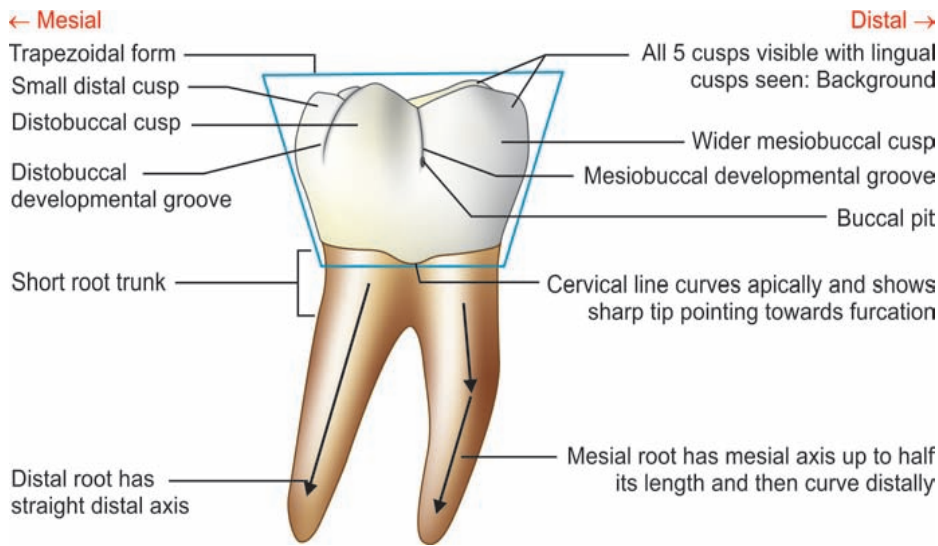


Figure 13.5 Mandibular 1st molar—buccal aspect

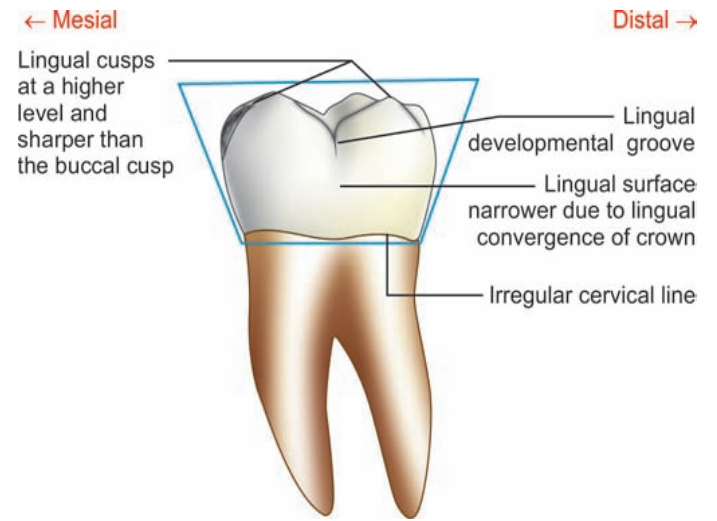
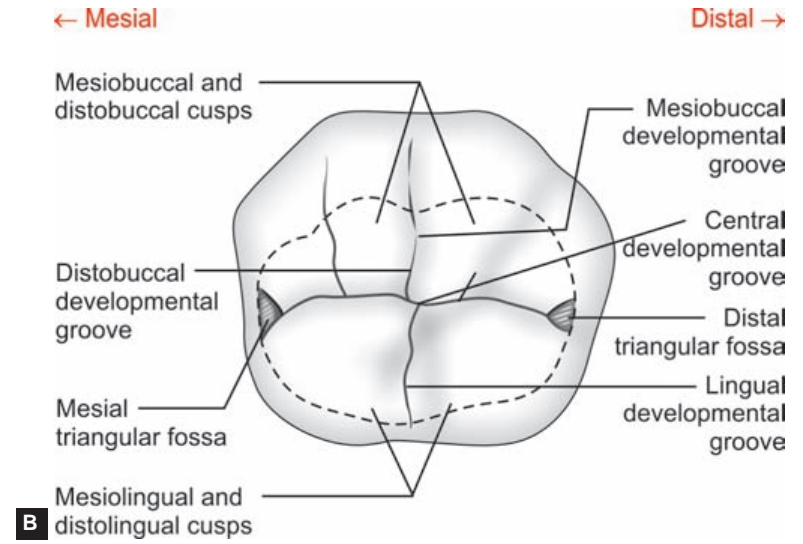
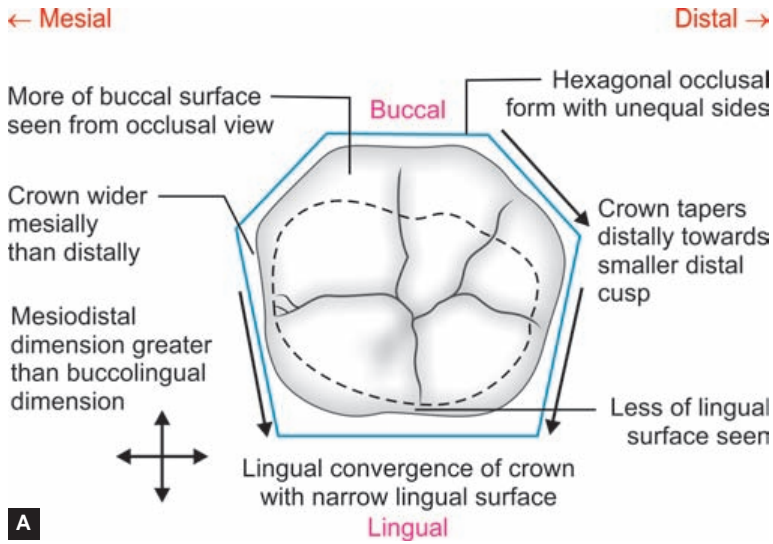


Figure 13.6 Mandibular 1st molar—lingual aspect



Figures 13.9A and B Mandibular 1st molar—occlusal aspect

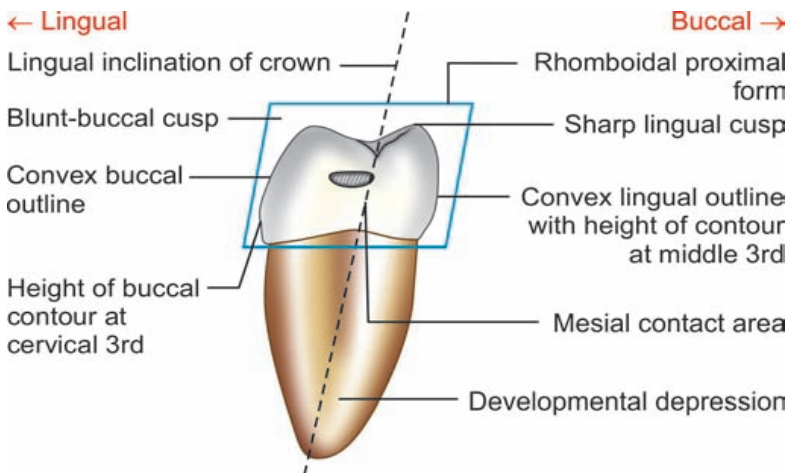


Figure 13.7 Mandibular 1st molar—mesial aspect

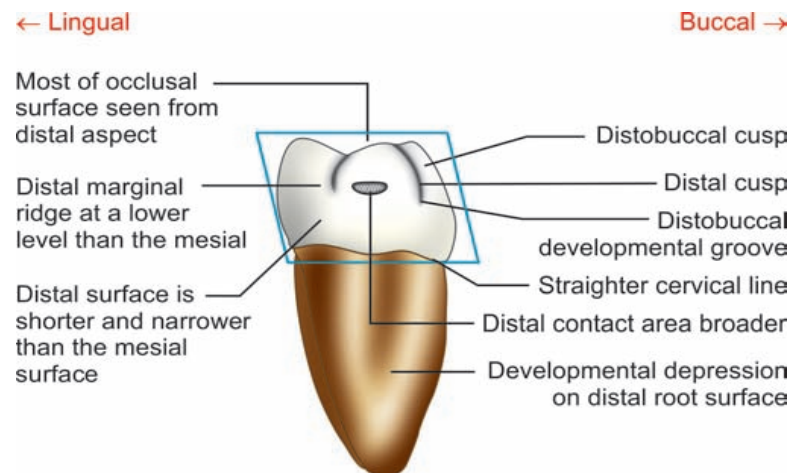


Figure 13.8 Mandibular 1st molar—distal aspect

Flow chart 13.2 Mandibular 1st molar—summary

Mandibular 1st molar

Crown

Buccal aspect

Lingual aspect

Mesial aspect

Distal aspect

Occlusal aspect

Root

Geometric shape

Crown outlines

- Trapezoidal
- Mesial—convex, concave near cervix
- Distal—slightly convex

Cusps seen

- All cusps seen
- 2 buccal cusps, a distal cusp in foreground
- Tips of lingual cusps seen as they are at higher level
- Mesiobuccal cusp wider than distobuccal
- Buccal cusps are blunt

Cervical line

- Curved apically
- Sharp tip pointing towards bifurcation

Developmental grooves

- Mesiobuccal developmental groove
- Distobuccal developmental groove

Buccal surface

- Convex in cervical ridge
- Linear concavity at middle 3rd

Pits

- Buccal pit

- Trapezoidal

Lingual convergence

- Crown tapers lingually

Cusps seen

- Only 2 lingual cusps and portion of distal cusp
- Lingual cusps are sharper
- Both lingual cusps of same width

Cervical line

- Irregular and dips apically towards bifurcation

Developmental grooves

- Lingual developmental groove between lingual cusps

Lingual surface

- Convex, flat cervically

Pits

- Lingual pit

- Rhomboidal

Crown outlines

- Buccal—convex at cervical 3rd on buccal cervical ridge
- Lingual—evenly convex

Height of contours

- Buccal—at cervical 3rd
- Lingual—at middle 3rd

Cusps seen

- Mesiobuccal flattened
- Mesiolingual—sharp tip

Lingual inclination of crown

- Crown inclined lingually on root base
- Cusp tips within confines of root

Mesial surface

- Smoothly convex
- Shallow concavity below contact area that joins developmental depression on mesial root

Mesial contact area

- At junction of occlusal and middle 3rd cervico-occlusally

Pits

- Buccal pit

- Rhomboidal

Cusps seen

- Distolingual and distal cusps in direct view
- Most of distobuccal cusp also seen

Distal marginal ridge

- Shorter and at a lower level than mesial marginal ridge. Placed lingually due to presence of distal cusp

Distal surface

- Narrower and shorter
- Part of occlusal surface seen
- Part of buccal surface seen

Distal contact area

- On distal contour of distal cusp and at center of crown buccolingually

- Hexagonal

Relative dimension

- Mesiodistal dimension greater than buccolingual dimension
- Crown bulkier mesially than distally towards distal cusp

Crown taper

- Tapers lingually
- Tapers distally

Lingual inclination

- More of buccal surface seen and very little lingual surface seen from occlusal view

Cusps: 5 cusps

- Mesiobuccal, mesiolingual and distal (smallest)
- Mesiolingual and distolingual

Fossae

- Major—central fossa
- Minor—mesial and distal triangular fossae

Grooves

- Central developmental groove
- Mesiobuccal, distobuccal, lingual grooves

Pits

- Central, mesial and distal

Number

- 2 roots

Pulp canals

- 3 canals

Size

- As long as crown
- Both roots of same length

Form

- Short root trunk
- Bifurcation near to cervical line

Developmental depressions

- On buccal and lingual surfaces of root trunk
- On mesial and distal surfaces of both roots for entire length

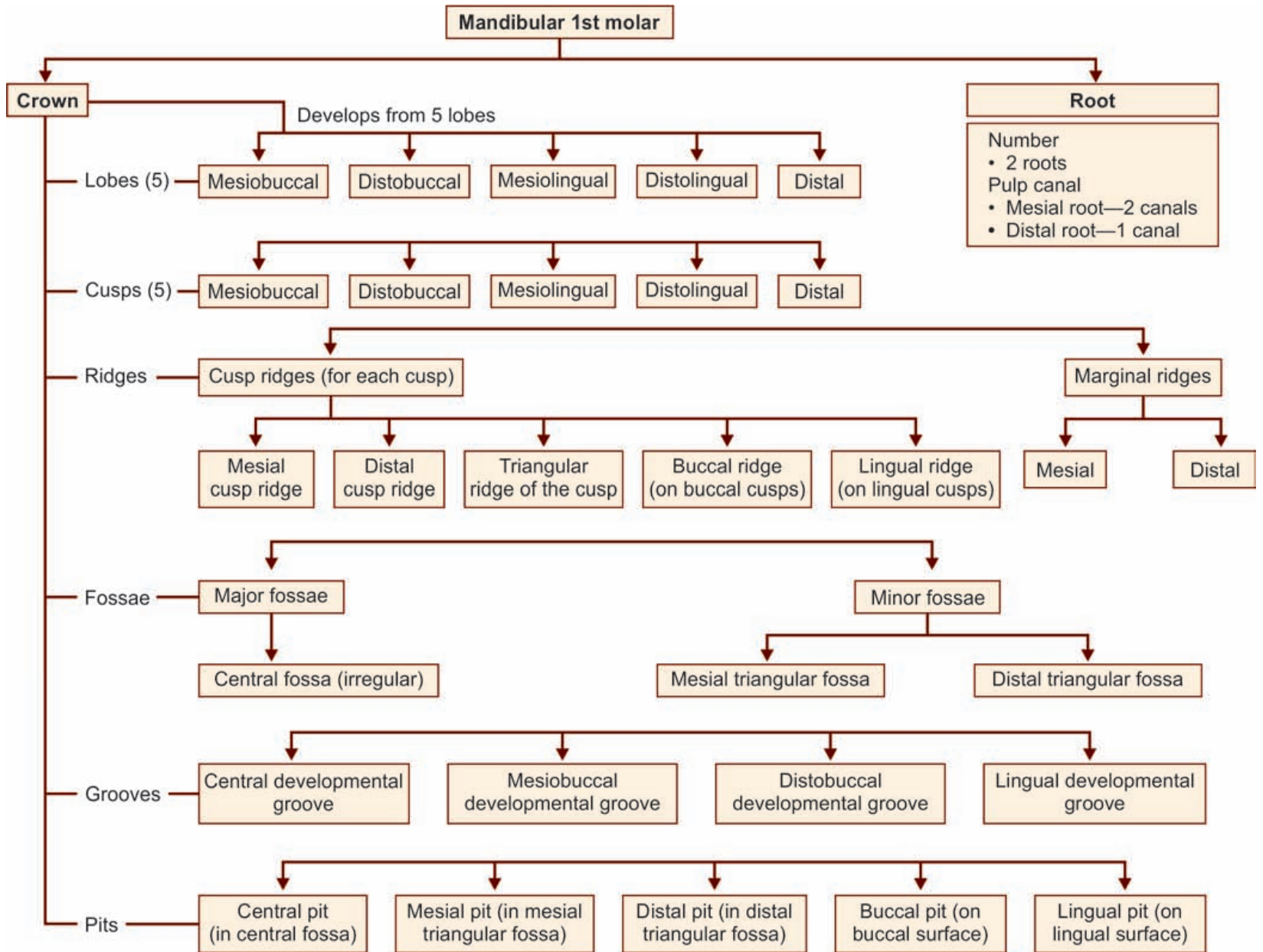
Root curvature

- Mesial root—apical half-curved distally
- Distal root has distal axis from furcation

Apices

- Mesial—blunt
- Distal—sharp

Flow chart 13.1 Mandibular 1st molar—major anatomic landmarks



Box 13.1 Mandibular 1st molar—identification features

Identification features of mandibular 1st molar

- The mandibular 1st molars have five cusps and two well formed roots
- The distal cusp is the smallest cusp and helps to identify the tooth and its side.

Side identification

- Smallest cusp, i.e. the distal cusp helps in identifying the side
- Roots often show distal curvature.

Mandibular 2nd Molar

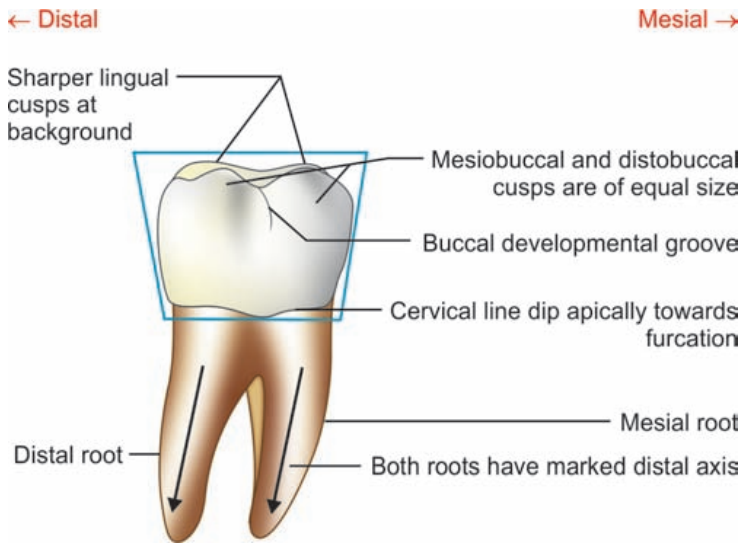


Figure 13.14 Mandibular 2nd molar—buccal aspect

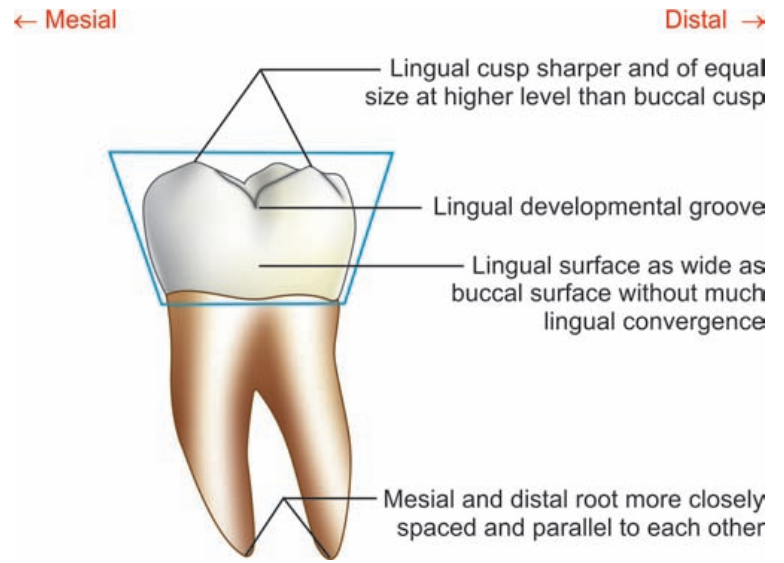
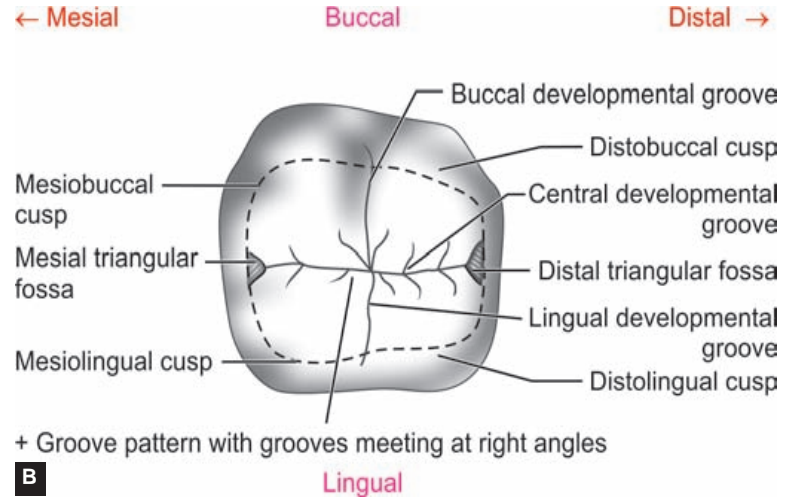
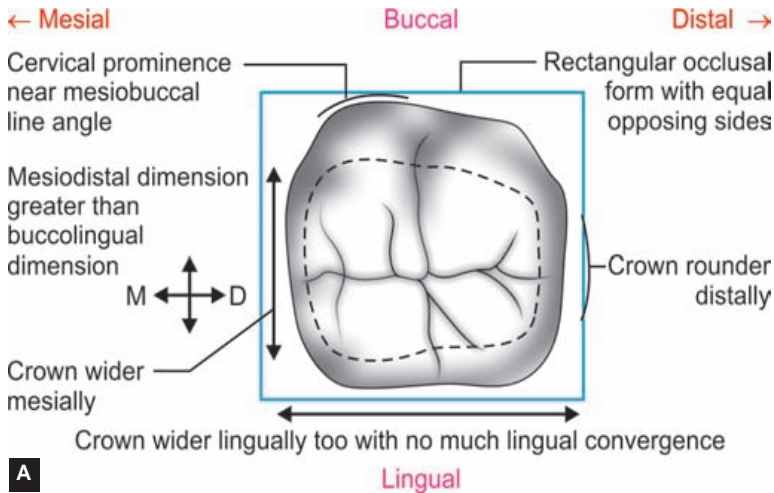


Figure 13.14 Mandibular 2nd molar—lingual aspect



Figures 13.18A and B Mandibular 2nd molar—occlusal aspect

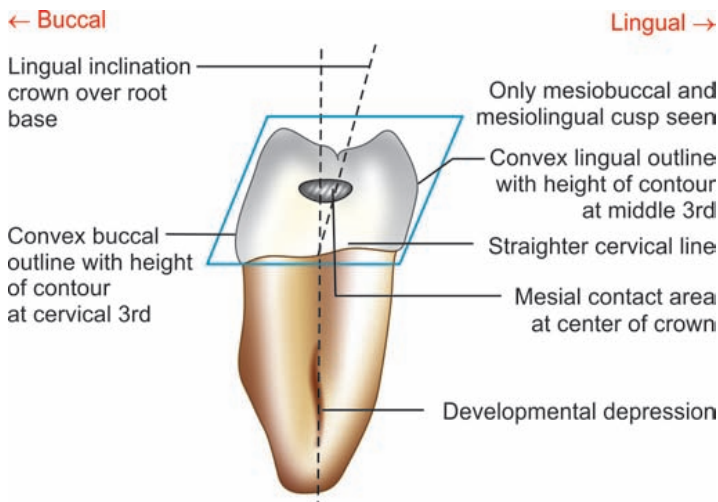


Figure 13.14 Mandibular 2nd molar—mesial aspect

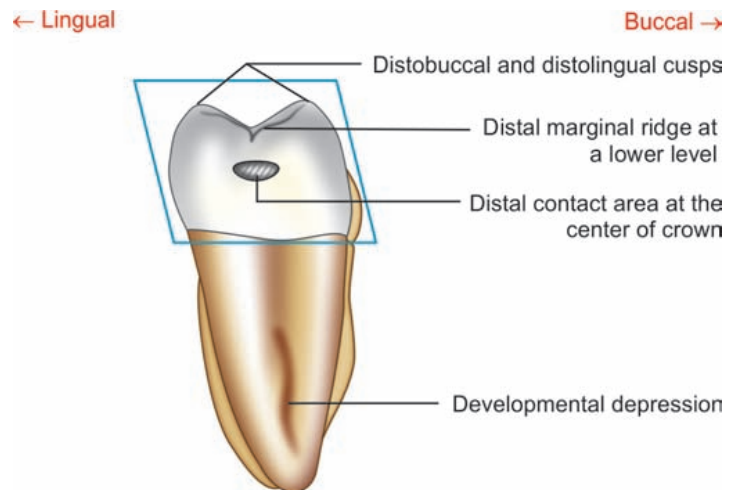


Figure 13.17 Mandibular 2nd molar—distal aspect

Flow chart 13.4 Mandibular 2nd molar—summary

Mandibular 2nd molar

Crown

Buccal aspect

Lingual aspect

Mesial aspect

Distal aspect

Occlusal aspect

Root

Geometric shape

- Trapezoidal

Crown outlines

- Mesial—convex
- Distal—convex

Cervical line

- Straight or dip apically near bifurcation

Cusps seen

- Mesio Buccal and distobuccal cusps
- Equal in width
- Blunt tips
- Lingual cusps may be seen

Developmental grooves

- Buccal developmental groove separating the buccal cusps

Buccal surface

- Crown narrower and shorter than mandibular 1st molar
- Buccal cervical ridge not prominent

- Trapezoidal

Lingual convergence

- Crown do not taper much lingually (not marked)

Cusps seen

- Mesiolingual and distolingual cusps
- Equal in width
- Sharper tips

Developmental grooves

- Lingual developmental groove separating the lingual cusps

Lingual surface

- As wide as buccal surface
- Convex surface

- Rhomboidal

Crown outlines

- Buccal—convex near cervix, flatter later
- Lingual—convex

Height of contour

- Buccal—at cervical 3rd
- Lingual—middle 3rd

Cusps seen

- Mesio Buccal and mesiolingual cusps

Lingual inclination of crown

- Crown inclined lingually on root base

Mesial surface

- Convex
- Flattened near cervical line

Mesial contact area

- At center of crown both cervico-occlusally and buccolingually

- Rhomboidal

Cusps seen

- Distolingual and distobuccal cusps

Distal marginal ridge

- At lower level than mesial marginal ridge

Distal surface

- Convex
- Same portion of occlusal surface seen

Distal contact area

- At center of crown both cervico-occlusally and buccolingually

- Rectangular with equal opposite sides

Relative dimensions

- Mesiodistal dimension greater than buccolingual dimension
- Crown equally wider buccally and lingually
- Broader mesially than distally

Mesio Buccal line angle

- Presence of prominence cervically near mesio Buccal line angle

Cusps

- 4 cusps: 2 buccal, 2 lingual

Fossae

- Mesial and distal triangular

Developmental grooves

- Make '+' or 'Y' pattern
- Central development groove
- Buccal groove
- Lingual groove

Pits

- Central, mesial, distal

Number

- 2 roots

Pulp canals

- 2 or 3 canals

Size

- Both of equal length

Form

- Roots closely spaced and parallel
- Can be fused
- Broad buccolingually

Developmental depressions

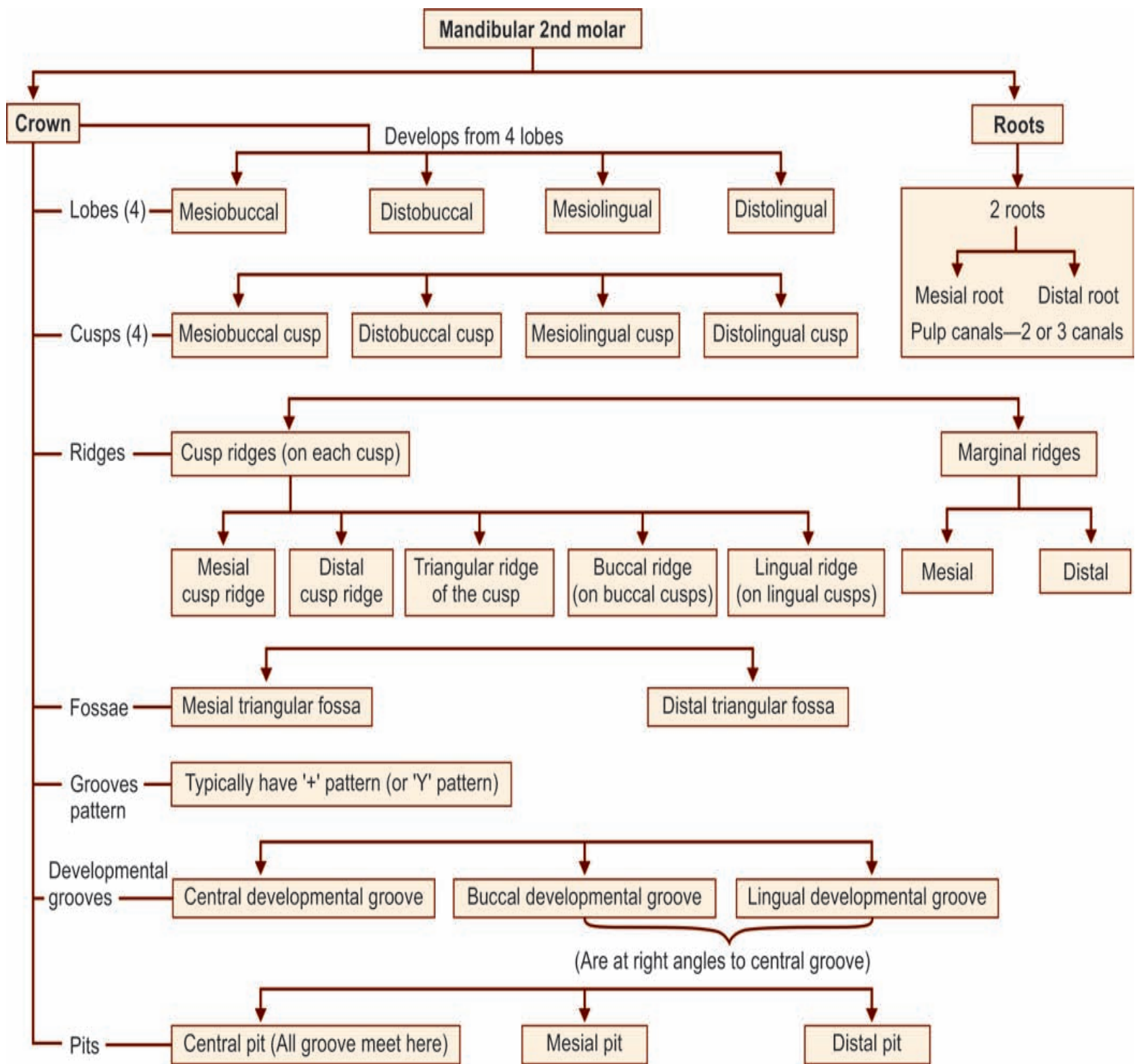
- On mesial and distal surfaces of both roots for apical half

Root curvature

- Distal apical curvature

Apices

- Both roots pointed



Identification features of mandibular 2nd molar

- The mandibular 2nd molar has four cusps and two roots
- The occlusal aspect has a plus '+' or cross-shaped groove pattern, dividing the occlusal surface into four nearly equal parts
- Both the roots are distally inclined and extend parallelly and are close to each other
- Viewed occlusally, there is cervical prominence seen at mesiobuccal line angle of the crown.

Side identification

- Viewed from occlusal aspect, the crown is wider mesially than distally
- Often, there is a prominence cervically near mesiobuccal line angle when viewed from occlusal aspect
- The roots are inclined distally.

Mandibular 3rd Molar

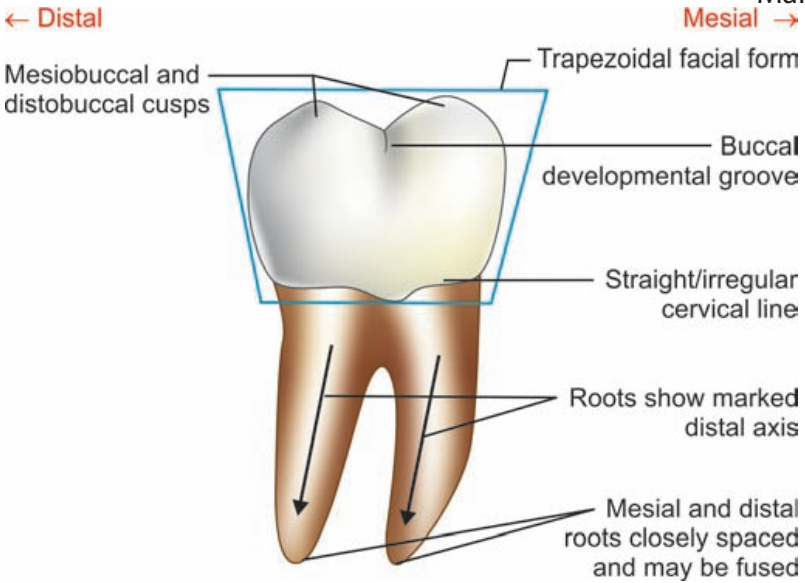


Figure 13.23 Mandibular 3rd molar—features on buccal aspect

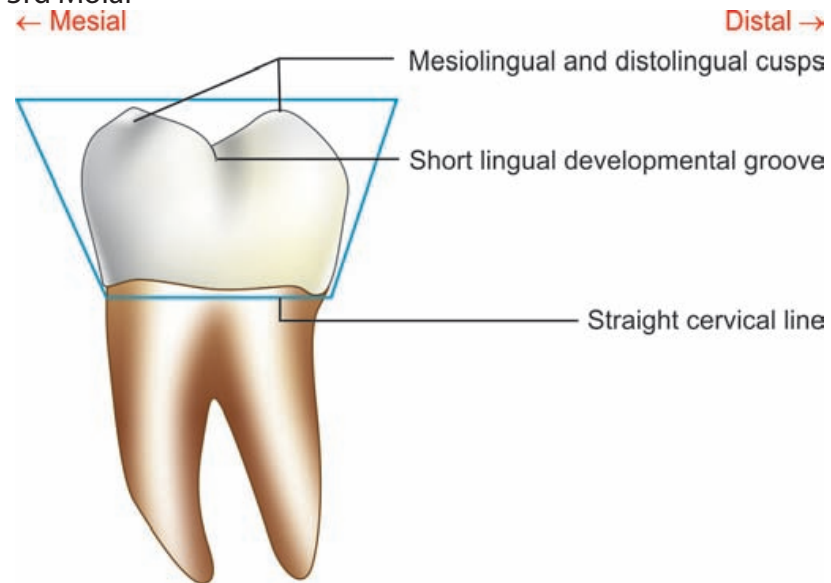


Figure 13.24 Mandibular 3rd molar—features on lingual aspect

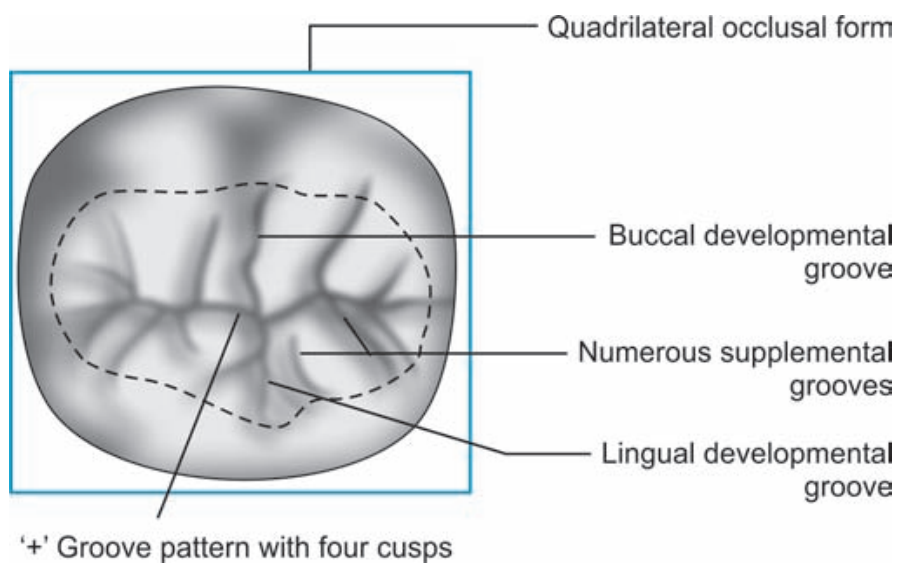


Figure 13.27 Mandibular 3rd molar—features on occlusal aspect

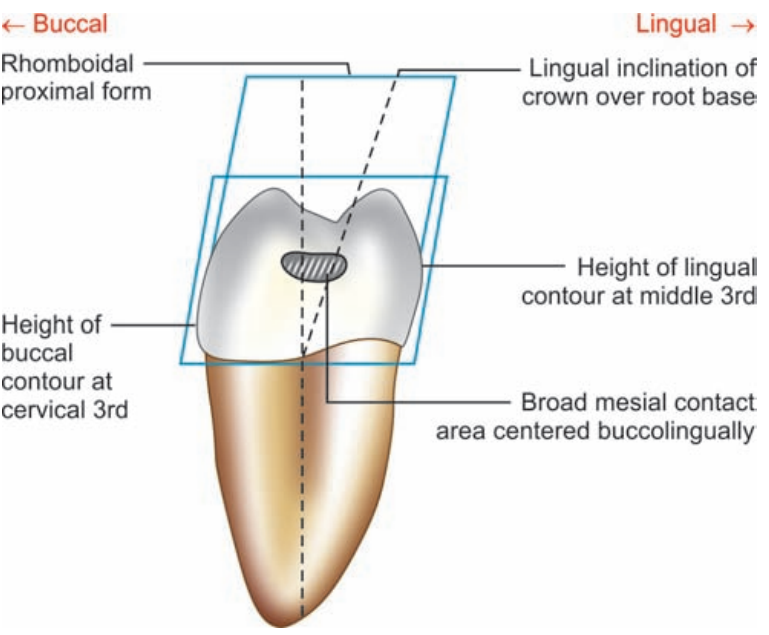


Figure 13.25 Mandibular 3rd molar—features on mesial aspect

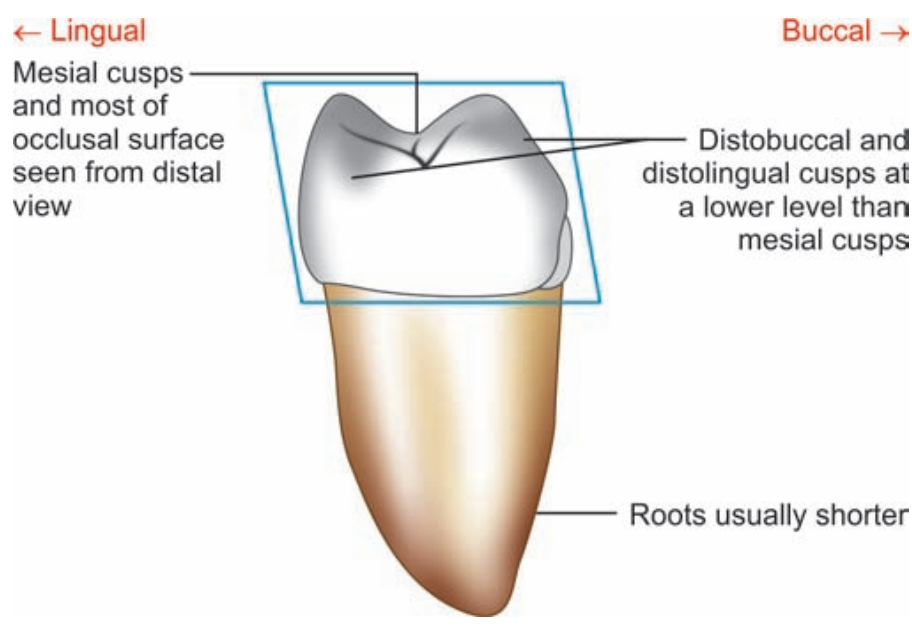


Figure 13.26 Mandibular 3rd molar—features on distal aspect

Flow chart 13.6 Mandibular 3rd molar—summary

Mandibular 3rd molar

Crown

Buccal aspect

Lingual aspect

Mesial aspect

Distal aspect

Occlusal aspect

Root

Geometric shape

- Trapezoidal

Cusps seen

- Mesio Buccal and distobuccal cusps

Developmental grooves

- Buccal developmental groove separates two buccal cusps

Cervical line

- Irregular

Buccal surface

- Convex
- Tooth smaller

- Trapezoidal

Lingual convergence

- Not marked

Cusps seen

- Mesiolingual and distolingual cusps

Developmental grooves

- Lingual groove separating two lingual cusps

- Rhomboid

Cusps seen

- Mesio Buccal and mesiolingual cusps

Height of contour

- Buccal at cervical 3rd
- Lingual of middle 3rd

Mesial contact area

- Centered buccolingually
- Occlusal to center of crown cervico-occlusally
- Broader

- Rhomboid

Cusps seen

- Distobuccal and distolingual cusps
- Part of mesial cusps and occlusal surface seen

Distal marginal ridge

- At a lower level than mesial marginal ridge

No distal contact

- Rectangular

Cusps

- 4 cusps like 2nd molar or
- 5 cusps type like 1st molar

Relative dimension

- Wider mesiodistally than buccolingually
- Wider mesially than distally

Developmental grooves

- Central, buccal, and lingual grooves
- Multiple supplemental grooves

Number

- 2 roots often fused

Pulp canals

- Single fused often

Size

- Shorter root

Form

- Fused partly or for entire length
- Inclined distally

Developmental depression

- Deeper on distal surface

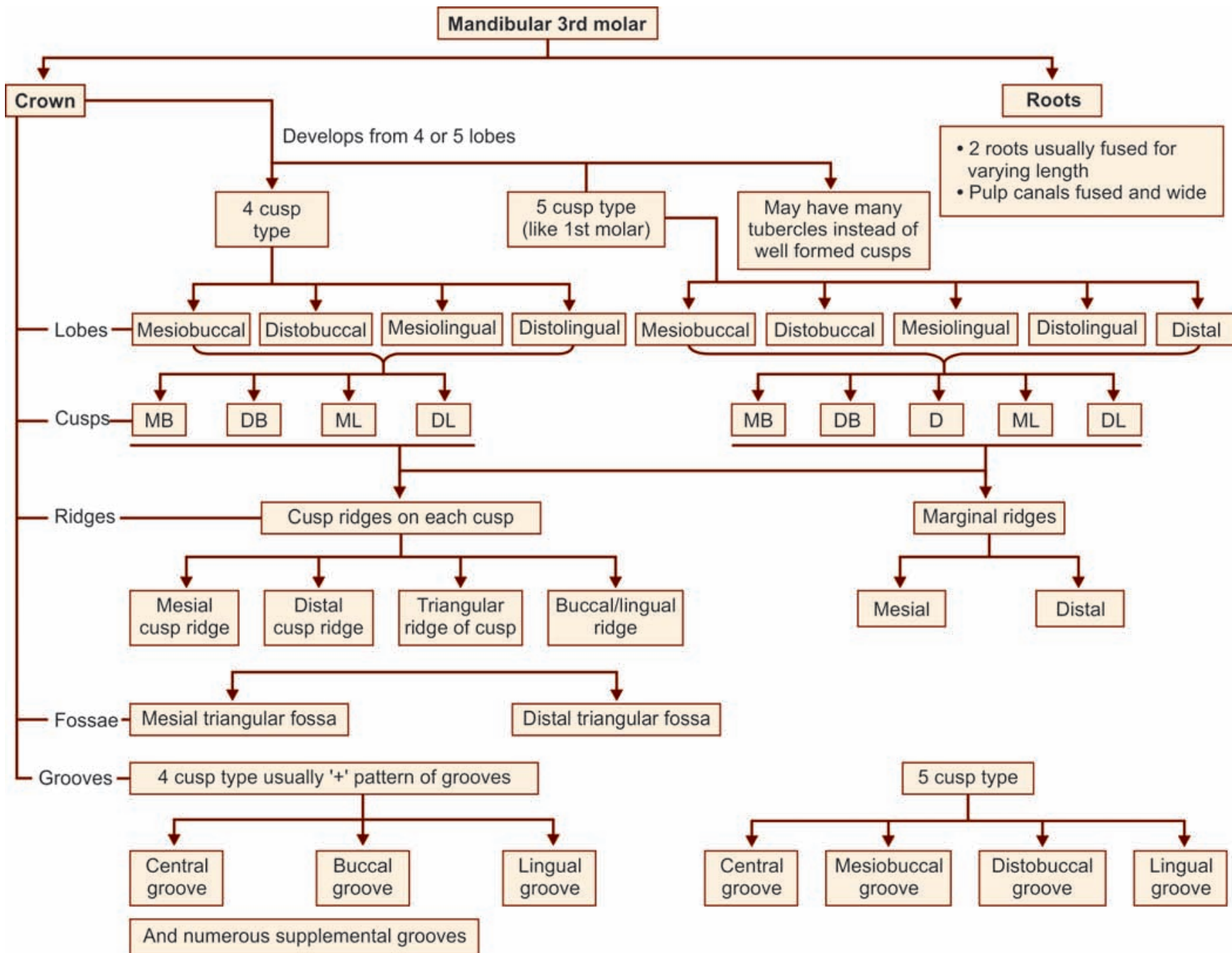
Apical curvature

- Distal curvature

Apices

- More pointed

Flow chart 13.5 Mandibular 3rd molar—major anatomic landmarks



Box 13.3 Mandibular 3rd molar—identification features

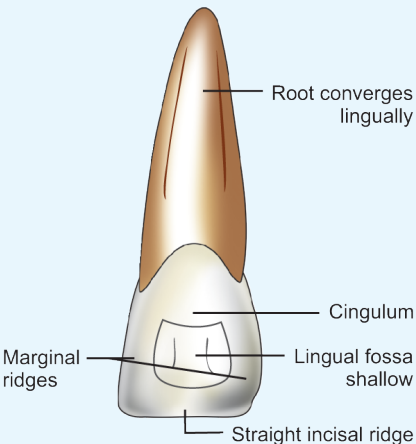
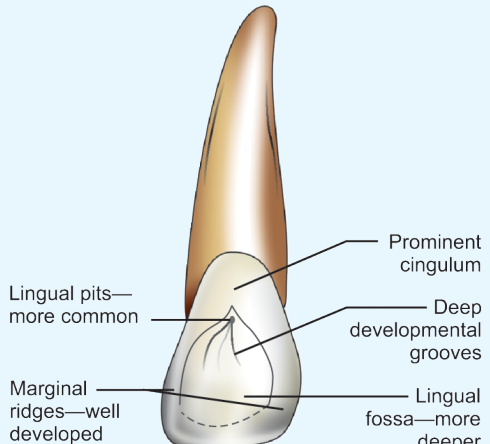
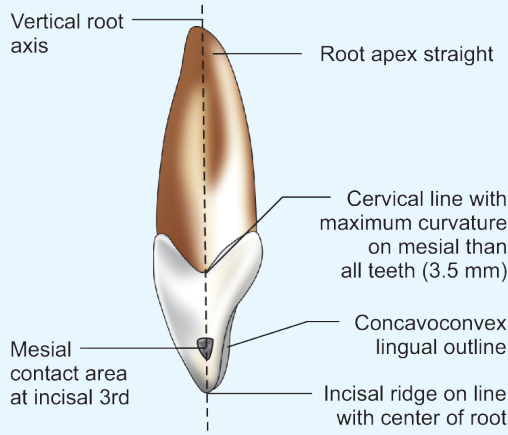
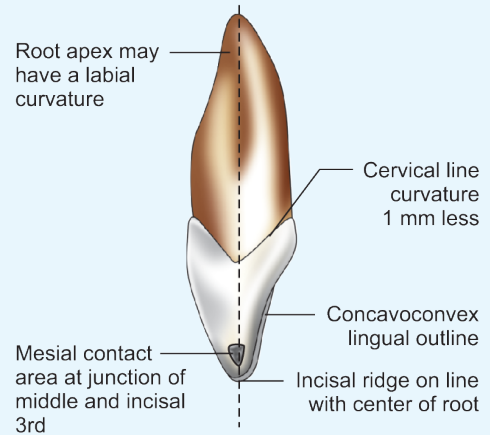
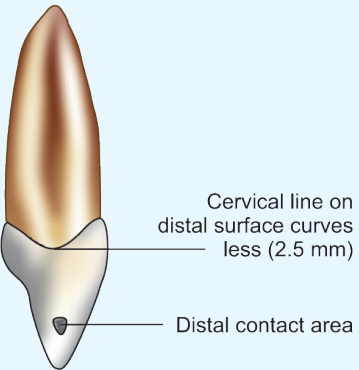
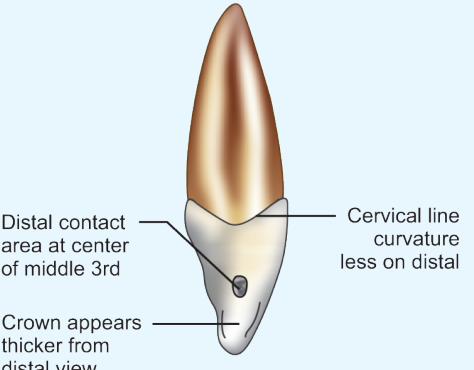
Identification features of mandibular 3rd molar

- Usually, the mandibular 3rd molars are similar to mandibular 2nd molars but a little smaller in size
- The occlusal surface shows more number of supplemental grooves
- The roots are shorter and more pointed and have an extreme distal tilt
- They often have fused roots.

<i>CHARACTERISTICS</i>	<i>MAXILLARY PERMANENT INCISORS</i>	<i>MANDIBULAR PERMANENT INCISORS</i>
Tooth nomenclature		
Universal system	7, 8, 9, 10	26, 25, 24 and 23
Zsigmondy/Palmer system	└┐, └┑, └┑, └┑	└┐, └┑, └┑, └┑
FDI system	11, 12, 21 and 22	31, 32, 41 and 42
Chronology		
Eruption	7–9 years They erupt after the eruption of permanent mandibular incisors	6–8 years They are first permanent teeth to erupt along with 1st molars (6–7 years)
Root completion	10–11 years	9–10 years
General features		
Lobes	4 lobes	4 lobes
Mamelons	Present in newly erupted	Present in newly erupted
General size	<ul style="list-style-type: none"> • Widest of incisor class • Maxillary permanent central incisor is larger than the lateral incisor 	<ul style="list-style-type: none"> • Narrowest of incisors class • Mandibular permanent lateral incisor is larger than the central incisor
Function	Upper incisors form fixed cutting edge	Form movable cutting edge during mastication
Variations	Variations are numerous especially the lateral incisor	Variations are not common
CROWN		
Mesiodistal width	Wider than mandibular permanent incisors	Mesiodistally narrower than all other permanent teeth
Crown symmetry	Wider, less symmetrical crown	More symmetrical crown (especially in mandibular permanent central incisor)
Incisal edge	More rounded distoincisoral angles	Both mesial and distal incisal angles are relatively sharp
Contact areas	Mesial and distal contact areas are at different levels	Mesial and distal contact areas are at the same level
Labial surface	More convex	Less convex
Lingual aspect		
Marginal ridges	More well defined	Ill defined
Cingulum	Larger	Smaller
Lingual fossa	Deeper, well circumscribed often with grooves	Shallower fossa without grooves
Developmental grooves	Often present in lingual fossa	Usually not seen
Lingual pit	Often present	No lingual pit
Proximal aspect (Mesial and distal views)		
Incisal ridge/location	Placed labial to/on line with vertical root axis	Lingual to vertical root axis
Incisal edge slope	On wearing of tooth, incisal edge slopes lingually	Incisal edge slopes labially
Convexity of cingulum	More pronounced	Less pronounced
Height of contour		
Labially	At the cervical third	At the cervical third
Lingually	At the cervical third	At the cervical third
Incisal aspect/view		
Crown dimension	Crown wider mesiodistally than labiolingually	Crown wider labiolingually than mesiodistally
Incisal edge	Centered over the crown labiolingually	Placed lingual to the bisecting line
ROOT		
Number	Single	Single
Form	Thick, conical shaped	Conical shaped
Size	Root relatively wider mesiodistally	Thin mesiodistally markedly, wider labiolingually
Cross-section	Triangular or rounded in cross-section	Oval shaped labiolingually
Developmental depressions	Smooth proximal root surface	Developmental depressions on both mesial and distal surfaces

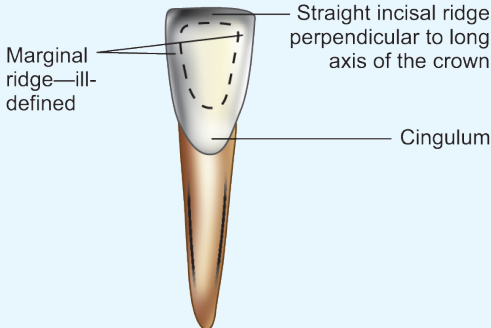
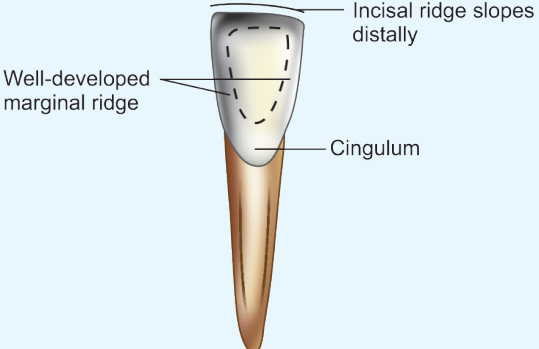
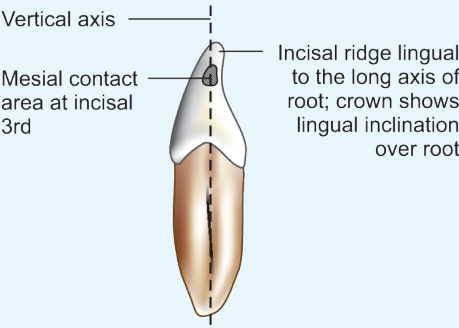
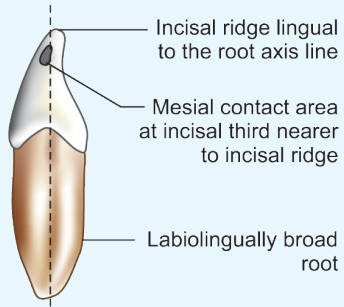
<i>CHARACTERISTICS</i>	<i>MAXILLARY PERMANENT CENTRAL INCISOR</i>	<i>MAXILLARY PERMANENT LATERAL INCISOR</i>
Tooth nomenclature		
Universal system	Right 8; Left 9	Right 7; left 10
Zsigmondy/Palmer system	└┑ Right; Left └┑	└┑ Right; Left └┑
FDI system	Right 11; Left 21	Right 12; Left 22

CHARACTERISTICS	MAXILLARY PERMANENT CENTRAL INCISOR	MAXILLARY PERMANENT LATERAL INCISOR
Chronology		
Calcification begins	months 4–3	months 12–10
Eruption	years 8–7	years 9–8
Root completion	years 10	years 11
General features		
Lobes	lobes 4	lobes 4
Dimension	Crown is larger, root is thicker	Smaller than central incisor in all dimension except root length. Crown smaller, root slender and comparatively longer
Variations	Develops regularly with few variations	Most common tooth to exhibit variation in form and development next to 3rd molars, e.g. peg shaped lateral and agenesis
CROWN		
Labial aspect	<p>Single conical root</p> <p>Cervical line curves apically</p> <p>Labial surface convex</p> <p>Slightly convex distal outline</p> <p>Curved distoincisal angle</p> <p>Straight incisal ridge</p> <p>Straight-mesial outline</p> <p>Sharp mesioincisal angle</p>	<p>Root apex shows distal curvature</p> <p>Root longer in proportion to its crown than that of central incisor</p> <p>Labial surface more convex than that of maxillary central incisor</p> <p>More rounded distoincisal angle</p> <p>Incisal ridge—curved towards distal</p> <p>Slightly convex mesial outline</p> <p>Rounded mesioincisal angle</p>
Mesiodistal width	Comparatively wider	Comparatively narrow
Cervicoincisal length	Longest crown among incisors	Short crown
Mesial profile	Straight	Convex
Distal profile	Slightly convex	More convex
Incisal ridge	Makes straight line	Rounded incisal ridge, slopes cervically towards distal
Incisal angle		
Mesioincisal angle –	Sharp, right angle	Both the angles are rounded
Distoincisal angle –	Rounded	
Proximal contact areas		
Mesial contact area –	At the incisal third	Junction of incisal and middle third
Distal contact area –	Junction of incisal and middle third	At the middle third
Labial surface	Slightly convex	More convex

CHARACTERISTICS	MAXILLARY PERMANENT CENTRAL INCISOR	MAXILLARY PERMANENT LATERAL INCISOR
Lingual aspect	 <p>Root converges lingually</p> <p>Cingulum</p> <p>Marginal ridges</p> <p>Lingual fossa shallow</p> <p>Straight incisal ridge</p>	 <p>Prominent cingulum</p> <p>Lingual pits—more common</p> <p>Deep developmental grooves</p> <p>Marginal ridges—well developed</p> <p>Lingual fossa—more deeper</p>
Cingulum	Moderately pronounced	Comparatively more prominent
Marginal ridge	Moderately developed	More prominent
Lingual fossa	Moderately deep	Deeper and well circumscribed
Grooves	Few grooves in lingual fossa	Deep palatogingival groove may be present
Lingual pits	Less common	More common
Mesial aspect	 <p>Vertical root axis</p> <p>Root apex straight</p> <p>Cervical line with maximum curvature on mesial than all teeth (3.5 mm)</p> <p>Mesial contact area at incisal 3rd</p> <p>Concavoconvex lingual outline</p> <p>Incisal ridge on line with center of root</p>	 <p>Root apex may have a labial curvature</p> <p>Cervical line curvature 1 mm less</p> <p>Mesial contact area at junction of middle and incisal 3rd</p> <p>Concavoconvex lingual outline</p> <p>Incisal ridge on line with center of root</p>
Labial and lingual contours	More curved	Less curved
Height of contour	Both at cervical third	Both at cervical third
Incisal ridge	On line with vertical root axis	On line with vertical root axis
Curvature of cervical line	Shows the maximum curvature on mesially 3.5 mm, distally 2.5 mm	mm less than that of central incisor 1
Distal aspect	 <p>Cervical line on distal surface curves less (2.5 mm)</p> <p>Distal contact area</p>	 <p>Distal contact area at center of middle 3rd</p> <p>Crown appears thicker from distal view</p> <p>Cervical line curvature less on distal</p>

CHARACTERISTICS	MAXILLARY PERMANENT CENTRAL INCISOR	MAXILLARY PERMANENT LATERAL INCISOR
Cervical line	Less curved than mesial —2.5 mm	Less curved
Distal contact area	At incisal 3rd	At middle 3rd
Incisal aspect		
Geometric form	Triangular	Ovoid/round
Relative dimension	Crown markedly wider mesiodistally	Mesiodistal and labiolingual dimensions of crown nearly same
ROOT		
Number	Single	Single
Size	Thick conical root	Delicate and slender root, comparatively longer root
Developmental groove	Usually not present	May present on mesial and distal surfaces
Curvature	Usually straight	Distal and labial curvature of apical third is common
Cross-section of root at cervix	Triangular	Oval
Pulp horns	pulp horns from labial view 3	Usually 2 from labial view
Pulp canals	One canal	One canal, apical accessory canals are more frequent

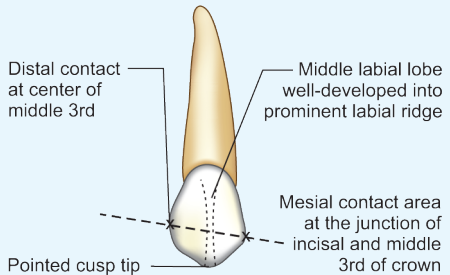
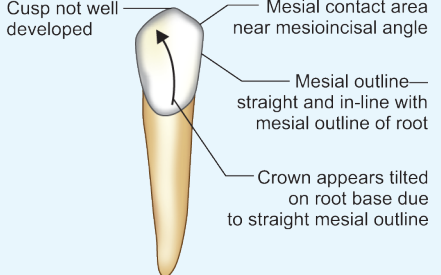
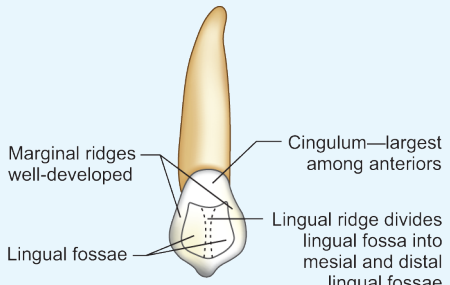
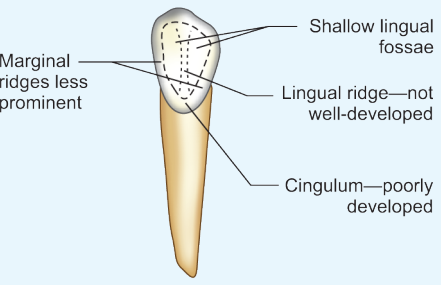
CHARACTERISTICS	MANDIBULAR PERMANENT CENTRAL INCISOR	MANDIBULAR PERMANENT LATERAL INCISOR
Tooth nomenclature		
Universal system	Right 25; Left 24	Right 26; Left 23
Zsigmondy/Palmer system	Right 1 $\overline{}$; Left 1 $\overline{}$	Right 2 $\overline{}$; Left 2 $\overline{}$
FDI system	Right 41; Left 31	Right 42; Left 32
Chronology		
Eruption	years, First tooth to erupt along with 1st molar 7–6	years 8–7
Root completion	years 9	years 10
Dimensions	Smallest tooth in permanent dentition	Slightly larger than the mandibular central incisor in all dimensions
CROWN		
Labial aspect		

CHARACTERISTICS	MANDIBULAR PERMANENT CENTRAL INCISOR	MANDIBULAR PERMANENT LATERAL INCISOR
Symmetry	Crown bilaterally symmetrical	Asymmetrical bilaterally
Mesial profile	Both mesial and distal outlines are straight	Straight
Distal profile		Slightly curved
Proximal contacts	Both contact areas are at same level, very near to incisal ridge	Not exactly same level. Though still in incisal third are cervically located than those of central incisors
Mesial •	Incisal third	Incisal third
Distal •		
Incisal angle	Sharp and right angled	Sharp and right angled
Mesioincisal angle •		
Distoincisal angle •	Sharp and right angled	Slightly rounded
Incisal ridge	Straight	Slopes downwards distally
Lingual aspect		
	 <p>Marginal ridge—ill-defined</p> <p>Straight incisal ridge perpendicular to long axis of the crown</p> <p>Cingulum</p>	 <p>Incisal ridge slopes distally</p> <p>Well-developed marginal ridge</p> <p>Cingulum</p>
	No major differences seen except that the lateral incisor is wider	
Marginal ridge	Ill-defined	Well defined
Incisal ridge/edge	Located lingual to the vertical root axis	Lingual to vertical root axis
Proximal surface (Mesial and distal views)	 <p>Vertical axis</p> <p>Mesial contact area at incisal 3rd</p> <p>Incisal ridge lingual to the long axis of root; crown shows lingual inclination over root</p>	 <p>Incisal ridge lingual to the root axis line</p> <p>Mesial contact area at incisal third nearer to incisal ridge</p> <p>Labiolingually broad root</p>

CHARACTERISTICS	MANDIBULAR PERMANENT CENTRAL INCISOR	MANDIBULAR PERMANENT LATERAL INCISOR
Incisal aspect	<p>More of labial surface seen due to lingual inclination of crown</p> <p>Incisal ridge perpendicular to the labiolingual bisecting line</p> <p>Labiolingual bisecting line</p>	<p>Labial</p> <p>Crown bilaterally asymmetrical appears twisted on root base</p> <p>Incisal ridge at an angle to the labiolingual bisecting line</p> <p>Labiolingual bisecting line</p> <p>Lingual</p>

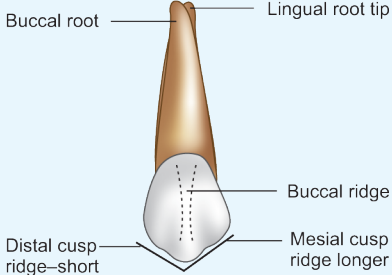
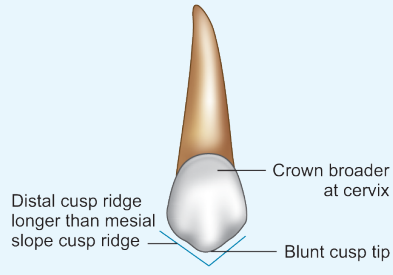
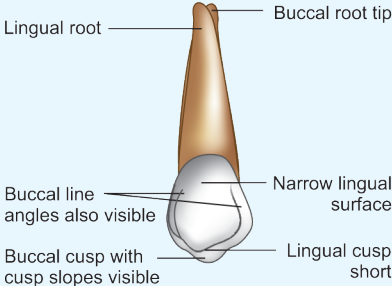
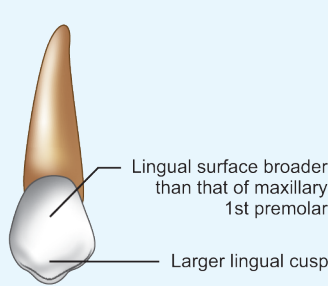
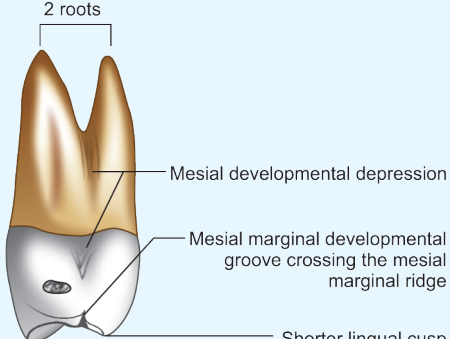
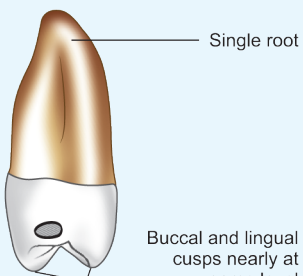
It is mainly from incisal view that the mandibular central and lateral incisors can be differentiated from one another

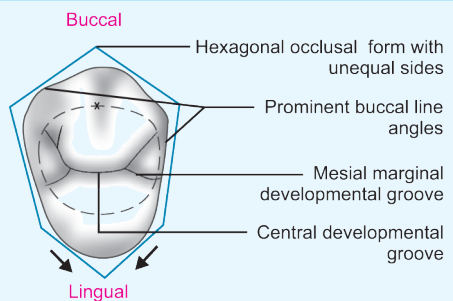
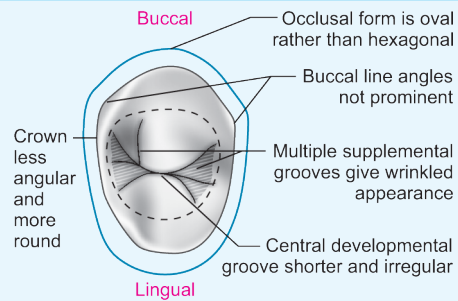
Incisal ridge/edge	Is at right angles to the labiolingual bisecting line	Is at an angle to the labiolingual bisecting line. It is twisted distolingually on the root base to conform to the mandibular arch curvature
Cingulum	Cingulum is centered mesiodistally	(Positioned distally (Cingulum is off center to distal
ROOT		
Number	Single	Single
Size	Shorter and smaller	Longer and larger
Developmental grooves	On both mesial and distal surfaces Deeper on distal surface	On both mesial and distal surfaces
Pulp canals	Usually 1, 2 possible	1

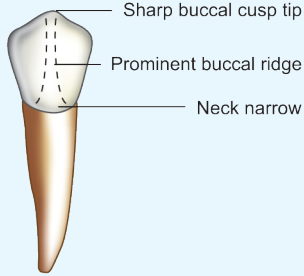
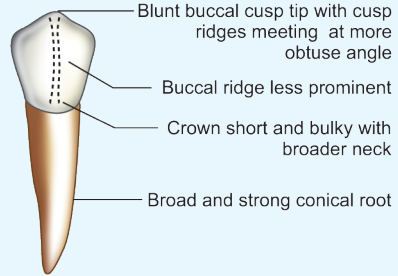
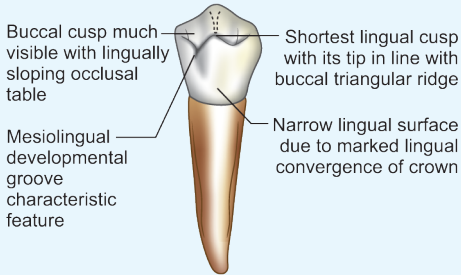
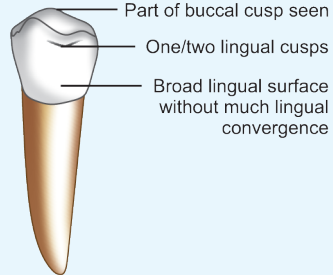
CHARACTERISTICS	MAXILLARY PERMANENT CANINE	MANDIBULAR PERMANENT CANINE
Tooth nomenclature		
Universal system	Right 6; Left 11	Right 27; Left 22
Zsigmondy/Palmer system	Right 3̄; Left 1̄3̄	Right 3̄; Left 1̄3̄
FDI system	Right 13; Left 23	Right 43; Left 33
Chronology		
Eruption	11–12 years Usually erupt after maxillary premolars	9–10 years Erupts before mandibular premolars and well before maxillary canine
Root completion	13–15 years	12–14 years
General features		
Lobes	Develops from 4 lobes middle labial lobe is very well-developed into labial ridge	From 4 lobes Middle labial lobe is not so well-developed
General size	<ul style="list-style-type: none"> • Longest tooth of all • Bulkier crown • Longest root of all 	<ul style="list-style-type: none"> • 2nd longest tooth • Crown longer by 1 mm and slender • Root shorter by 1 mm
CROWN		
Labial aspect	 <p>Distal contact at center of middle 3rd</p> <p>Middle labial lobe well-developed into prominent labial ridge</p> <p>Mesial contact area at the junction of incisal and middle 3rd of crown</p> <p>Pointed cusp tip</p>	 <p>Cusp not well developed</p> <p>Mesial contact area near mesioincisal angle</p> <p>Mesial outline—straight and in-line with mesial outline of root</p> <p>Crown appears tilted on root base due to straight mesial outline</p>
Mesiodistal width	Crown is broader and shorter	Crown is longer and narrower mesiodistally
Labial surface	The labial surface more convex	Labial surface convex
The cusp	The cusp is sharp and very well-developed Incisal portion of cusp and cusp ridges occupy 1/3rd of crown length	The cusp is not so well-developed Incisal portion occupies 1/5th of crown length
Cusp ridges	Mesial cusp ridge is usually concave	Cusp ridges are straight
Labial ridge	Labial ridge is very prominent	Labial ridge is less prominent
Crown outline	Mesial outline is generally convex	Mesial outline is straight following mesial outline of root. So crown looks bent distally on root base
Mesioincisal angle	Mesioincisal angle is less pronounced	Mesioincisal angle is more pronounced
Crown tilt	Crown is upright on root base	From this aspect crown appears to be tilted distally on root base
<i>Contact area</i>		
<ul style="list-style-type: none"> • Mesial • Distal 	Mesial is at the junction of incisal and middle 3rd Distal is at center of middle 3rd	Mesial is near mesioincisal angle Distal is at the junction of incisal and middle 3rd
Lingual aspect	 <p>Marginal ridges well-developed</p> <p>Cingulum—largest among anteriors</p> <p>Lingual ridge divides lingual fossa into mesial and distal lingual fossae</p> <p>Lingual fossae</p>	 <p>Shallow lingual fossae</p> <p>Marginal ridges less prominent</p> <p>Lingual ridge—not well-developed</p> <p>Cingulum—poorly developed</p>
Lingual surface	Lingual surface is more irregular	Smooth and is similar to that of mandibular lateral incisors
Cingulum	The cingulum is large, very well developed; sometimes may even be pointed like a small cusp	The cingulum is smooth and poorly developed
Marginal ridges	Marginal ridges are strongly developed	Marginal ridges are thin and less distinct
Lingual fossa	Lingual fossa is more concave	Lingual fossa is shallow and smooth
Lingual ridge	Lingual ridge is more prominent	Lingual fossa is less prominent

CHARACTERISTICS	MAXILLARY PERMANENT CANINE	MANDIBULAR PERMANENT CANINE
Mesial aspect	<p>Vertical root axis</p> <p>More convex labial outline</p> <p>Cusp tip placed labial to the vertical root axis</p> <p>Mesial contact area at junction of incisal and middle 3rd</p>	<p>Mesial contact area at incisal 3rd near mesioincisal angle</p> <p>Labial outline less convex</p> <p>Cusp tip in line/lingual to vertical root axis</p> <p>Cingulum less prominent</p>
Crown bulk	Crown is more bulky labiolingually	Crown appears less bulkier
Labial outline	More convex due to prominent labial ridge	Labial outline is less convex
Lingual outline	Lingual outline is more convex near cingulum and more concave near lingual fossa	Lingual outline shows curvatures of lesser degree
Position of cusp tip	Cusp tip is labial to the vertical root axis	Cusp tip is lingually placed to the vertical root axis
Incisal edge	Incisal edge is lingually sloping	Incisal edge is labially sloping
Distal aspect		
Cervical line	Less curved	Less curved
Incisal aspect	<p>Labial</p> <p>Crown—bilaterally asymmetrical with larger distal half</p> <p>Distal portion stretched to make contact with the 1st premolar</p> <p>Diamond-shaped incisal form</p> <p>Cusp tip labial and mesial to the center of crown</p> <p>Incisal ridge—straight</p> <p>Lingual fossa</p> <p>Prominent cingulum</p> <p>Lingual</p>	<p>Labial</p> <p>Oval incisal form</p> <p>Shallow lingual fossa</p> <p>Curved cusp ridges</p> <p>Cingulum—less prominent</p> <p>Lingual</p>
Dimension	Labiolingual dimension is greater among all the anteriors	Crown is less bulkier labiolingually
Crown symmetry	Crown appears asymmetrical with the mesial half of the crown bigger than the distal half	Crown is symmetrical
Cusp tip	Cusp tip is labial to the center of crown labiolingually and mesial to the center mesiodistally	Cusp tip is in the center or lingually placed
Cusp ridges	Cusp ridges with contact area extensions form a straight line mesiodistally Large cingulum forms a more pronounced convexity of lingual surface Labial ridge prominently seen on labial surface Lingual ridge is more prominent	Cusp ridges (especially distal) are inclined lingually Less convex lingual surface Labial ridge less prominent Lingual ridge less prominent
ROOT		
Number	Single conical root and is never bifurcated	Usually single root may be bifurcated
Size	Longest root with extra anchorage Lingual surface is narrower than labial	Root is 1–2 mm shorter Lingual surface is much more narrower about ½ of the width of labial surface
Apex curvature	Apex is blunt Apical 3rd of the root shows distal curvature	Apex is slightly sharp Root is usually straight sometimes has mesial curvature
Developmental grooves	Developmental groove on distal surface of root is more deeper	Developmental groove on mesial surface is more pronounced
Pulp canals	Single canal	Single canal

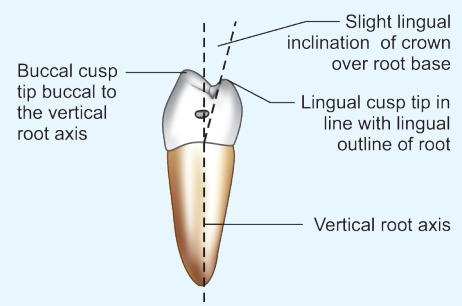
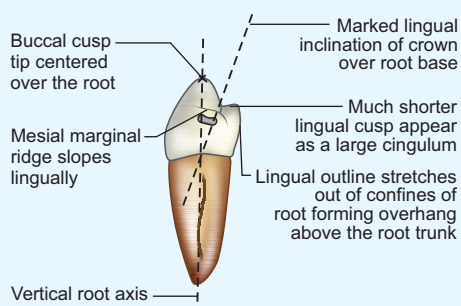
CHARACTERISTICS	MAXILLARY PERMANENT PREMOLARS	MANDIBULAR PERMANENT PREMOLARS
Tooth nomenclature		
Universal system	Right 4, 5; Left 12, 13	Right 28, 29; Left 20, 21
Zsigmondy/Palmer system	Right 4̄, 5̄; Left 14̄, 15̄	Right 4̅, 5̅; Left 14̅, 15̅
FDI system	Right 14, 15; Left 24, 25	Right 44, 45; Left 34, 35
General features		
Eruption sequence	Usually erupt before maxillary permanent canine	Erupt after mandibular permanent canine
Lobes	Develop from 4 lobes	4 lobes—for 1st permanent premolar and 5 lobes—for 2nd permanent premolars
Number of cusps	Two	Two—1st premolar 3 common for 2nd premolar, or two cusps
Number of roots	Two—1st premolar One—2nd premolar	Usually one
Sizes of cusps	Buccal and lingual cusps are almost equal in size and height Buccal and lingual cusps nearly equally well developed and of equal prominence	Lingual cusps much shorter, especially in mandibular 1st premolar which is nonfunctional Buccal and lingual cusps of uneven development and prominence
Crown form	1st and 2nd premolars are similar in form	1st and 2nd premolars are widely different in form
Buccal aspect		
Buccal cusp tip	Mesial and distal cusp ridges at the cusp tip meet at sharp angle	Cusp ridges meet at more obtuse angle
Buccal ridge	More prominent on maxillary premolars (especially on 1st premolar)	Less prominent on mandibular premolars
Buccal cusp slope/ridge	1st premolar—mesial cusp slope is longer 2nd premolar—distal cusp slope is longer	Distal cusp slope is longer in both premolars
Lingual aspect		
Lingual convergence	Maxillary premolars show marked lingual convergence, especially the 1st premolars	Lingual convergence not present, especially in 2nd premolar
Mesial and distal aspects		
Geometric form	Trapezoidal	Rhomboidal
Crown inclination	Crown nearly upright on root base	Crown show marked lingual inclination on root base
Cusp height	Buccal and lingual cusps nearly of equal height	Lingual cusp much shorter and small in 1st premolar. It is non-functional cusp
Cusp tips spacing	Buccal and lingual cusp tips wide apart	Buccal and lingual cusps are more nearer
Buccal cusp tip location	Buccal cusp located buccal to the vertical root axis	Buccal cusp is centered over root base, because lingual tilt of crowns, the buccal cusp tip is in line with the vertical root axis
Lingual cusp tip	Located lingual to the root axis line	On or lingual to the lingual confines of root
Crown outlines	Buccal and lingual crown outlines well within confines of root base	Lingual crown outline out of confines of root base
Occlusal aspect		
Crown dimension	Much wider buccolingually than mesiodistally	Buccolingual and mesiodistal dimensions nearly same
Geometric form	Ovoid/oblong	Round/squarish
Tapers to lingual	Marked in 1st premolars	Marked in 1st premolars
Cusps	Relatively wider buccolingually	Wider mesiodistally

CHARACTERISTICS	MAXILLARY 1ST PERMANENT PREMOLAR	MAXILLARY 2ND PERMANENT PREMOLAR
Tooth nomenclature		
Universal system	Right 5, Left 12	Right 4; Left 13
Zsigmondy/Palmer system	Right 4 ¹ , Left 1 ⁴	Right 5 ¹ , Left 1 ⁵
FDI system	Right 14; Left 24	Right 15; Left 25
Chronology		
Eruption	10–11 years	10–12 years
Lobes	From 4 lobes	Also from 4 lobes
General tooth size and form	No much variation in tooth size More angular and lingual cusp is shorter	Crown may be smaller or bigger than the 1st premolar. Root may be slightly longer Crown is less angular. Both the cusps are of almost same size
CROWN		
Buccal aspect		
Crown width	Crown is narrow at cervix	Crown appears thicker at cervical portion
Crown height	Larger and longer	Smaller and shorter crown
Cusp tip	More pointed with sharp angle between cusp slopes (105 degree)	Less pointed, blunt. Cusp angle (125 degree)
Slopes/ridges of buccal cusp	Mesial slope is longer than the distal	Distal slope is longer
Buccal line angles	Crown is more angular Buccal line angles are sharp	Crown is more rounded and less angular
Buccal surface	More convex	Less convex
Lingual aspect		
Lingual cusp	It is shorter and narrower than the buccal cusp	Lingual cusp is of the same length and width as buccal cusp
Crown length	The crown appears shorter from lingual aspect	Crown appears comparatively longer from lingual aspect
Lingual surface	Less convex	More convex
Lingual convergence	Marked lingual convergence present Crown tapers more towards lingual aspect because of smaller lingual cusp	Crown does not tapers much lingually
Mesial aspect		

CHARACTERISTICS	MAXILLARY 1ST PERMANENT PREMOLAR	MAXILLARY 2ND PERMANENT PREMOLAR
Cusps height	Lingual cusp is shorter by 1–2 mm	The two cusps are same height
Intercuspal width	Distances between buccal and lingual cusp tip is less	Distances between the two cusp tips is more
Cusp tips	More sharp	More blunt
<i>Height of contour</i>		
• Buccal	At cervical third	At cervical third
• Lingual	At middle third	At middle third
Developmental depression	Marked concavity present in the center of mesial surface called " <i>mesial developmental depression</i> ". This mesial concavity extends onto root trunk	No developmental depression, mesial surface is smoothly convex
Developmental grooves	<i>Mesial marginal developmental grooves</i> extending from central groove of occlusal surface crosses the mesial marginal ridge to reach the mesial surface of crown	No developmental groove crossing the mesial marginal ridge
Contact areas	Contact area is narrower on mesial surface rather than on the distal surface as the tooth contacts with maxillary canine mesially	Both the contact area are broader. As it is in contact with posterior teeth on both sides
Distal aspect		
Cervical line	Less curved	Less curved
Distal contact area	Broader than mesial	Both contacts are broader
Occlusal aspect	 <p>Buccal</p> <p>Hexagonal occlusal form with unequal sides</p> <p>Prominent buccal line angles</p> <p>Mesial marginal developmental groove</p> <p>Central developmental groove</p> <p>Lingual</p>	 <p>Buccal</p> <p>Occlusal form is oval rather than hexagonal</p> <p>Buccal line angles not prominent</p> <p>Crown less angular and more round</p> <p>Multiple supplemental grooves give wrinkled appearance</p> <p>Central developmental groove shorter and irregular</p> <p>Lingual</p>
General shape	Hexagonal outline	Oval outline
Line angles	Crown is angular with well defined buccal line angles	Crown appears more rounded with less pronounced buccal line angles
Occlusal table	The occlusal table is smaller buccolingually because of a lesser distance between the cusp tips	Wider occlusal table because a greater distance between the cusp tips
Location of cusp tips	Lingual cusp tip positioned off center to the mesial	Both cusp tips centered mesiodistally
Crown width (mesiodistal)	Crown is wider buccally than lingually because of a smaller lingual cusp	Crown is equally wide both buccally and lingually
Crown width buccolingual	Wider distally than mesially. Crown appears to curve mesially due to mesial marginal developmental groove	Equally wide mesially and distally
Marginal ridges	Mesial marginal ridge is shorter	Both marginal ridges equal length
Central developmental groove	Longer	Shorter
Supplementary grooves	Very few supplementary grooves. Occlusal surface is more regular	Multiple supplementary grooves radiate from central distal groove giving the occlusal surface a " <i>wrinkled appearance</i> "
ROOT		
Number	2 roots: buccal and lingual Sometimes single	1 root
Size	Comparatively shorter. Both buccal and lingual roots are of same length	Root is often slightly longer than the maxillary 1st premolar
Root form	Long root trunk with bifurcation at middle 3rd of the root. The two roots diverge from bifurcation point and later face each other at apical ends	Conical root tapers evenly from cervix to apex
Developmental grooves and depressions	More deeper on mesial surface	More deeper on distal side
Variations	Root form is variable The root is frequently bifurcated but can be single or laminated (fused bifurcated roots)	Root formed is less variable
Root canals	2 canals	1 canal

CHARACTERISTICS	MANDIBULAR 1ST PERMANENT PREMOLAR	MANDIBULAR 2ND PERMANENT PREMOLAR
Tooth nomenclature		
Universal system	Right 28, left 21	Right 29; left 20
Zsigmondy/Palmer system	Right $\bar{4}$; Left $\bar{4}$	Right $\bar{5}$; Left $\bar{5}$
FDI system	Right 44; Left 34	Right 45; Left 35
Chronology		
Developmental lobes	4 lobes, 3 labial and 1 lingual lobe Lingual lobe not well developed	5 lobes—frequently (3 labial and 2 lingual lobes) or 4 lobes Lingual lobe well developed
Eruption	10–12 years	11–12 years
Root completion	12–13 years	13–14 years
Variation in form	No much variation in form	3 cusp type or two cusp type
CROWN		
Buccal aspect	 <p>Sharp buccal cusp tip Prominent buccal ridge Neck narrow</p>	 <p>Blunt buccal cusp tip with cusp ridges meeting at more obtuse angle Buccal ridge less prominent Crown short and bulky with broader neck Broad and strong conical root</p>
Crown height	Longer crown	Shorter crown
Crown width	Narrow	Wider and bulky crown
Neck of the tooth	Narrow at cervix	Crown wider at cervix
Buccal ridge	More prominent	Less prominent
Contact area	Mesial contact area cervically located than distal	Distal contact area cervically located than the mesial
Lingual aspect	 <p>Buccal cusp much more visible with lingually sloping occlusal table Mesiolingual developmental groove characteristic feature Shortest lingual cusp with its tip in line with buccal triangular ridge Narrow lingual surface due to marked lingual convergence of crown</p>	 <p>Part of buccal cusp seen One/two lingual cusps Broad lingual surface without much lingual convergence</p>
Number of lingual cusps	1 lingual cusp	1 or 2 lingual cusps (Mesiolingual cusp wider than distolingual cusp)
Lingual cusp(s)	Very small, non-functional lingual cusp	Functional lingual cusp or cusps
Lingual cusp height	Very short	Nearly of same height as buccal cusp
Lingual convergence	Marked lingual convergence of crown due to small lingual cusp	Crown on lingual is as wide as buccal (Very little lingual convergence)
Visibility of buccal profile and proximal surfaces	All of buccal profile Proximal walls of crown are visible from lingual view	Only buccal cusp tip and part of proximal walls seen
Occlusal surface visibility	Most of occlusal surface visible along with buccal triangular ridge and marginal ridges	No much occlusal surface visible
Developmental grooves	<i>Mesiolingual developmental groove</i> extends from occlusal surface onto lingual surface mesially	No mesiolingual groove A short lingual developmental groove separating 2 lingual cusps may be seen (In 3 cusp type).
Lingual surface	Narrow, notched by mesiolingual groove mesially	Broad and smooth spheroidal

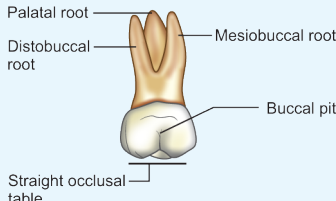
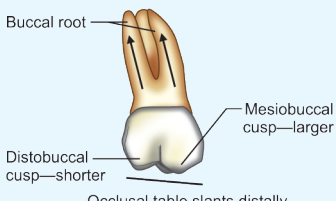
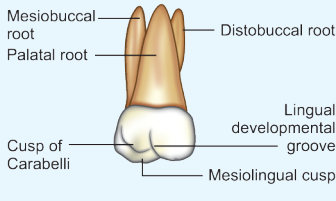
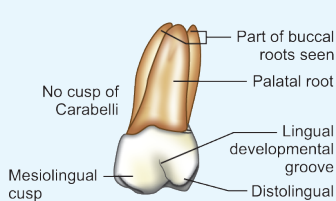
Mesial aspect

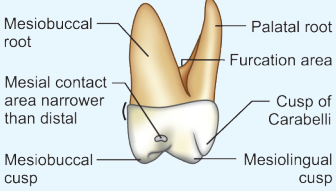
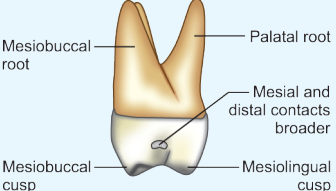
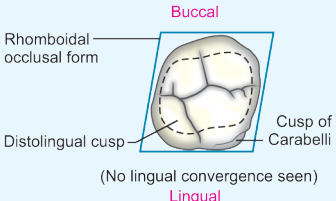
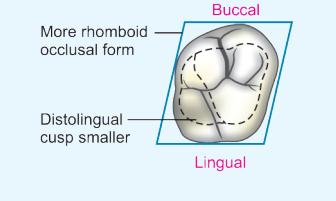


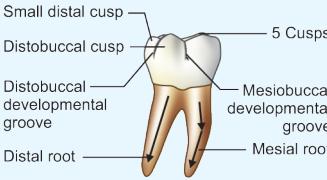
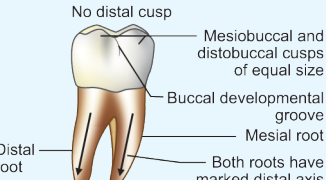
Similarity to canine	Appears similar to canine from proximal view	No similarity to canine
Lingual inclination of crown	Crown more lingually inclined on root base	Lingual tilt not so pronounced
Lingual cusp	Much shorter than buccal cusp	Lingual cusps are slightly shorter than buccal cusp
Occlusal plane	Tilted lingually due to very small lingual cusp	Horizontal, no lingual tilt
Lingual overhang on root	Lingual outline stretches out of confines of root. Creates overhang over root trunk	Lingual overhang of crown not so pronounced
Marginal ridges		
Length	Mesial marginal ridge is shorter than distal	Both marginal ridges of same size
Tilt	Marginal ridges lingually tilted	Marginal ridges are horizontal
Location	Mesial marginal ridge more cervically placed than distal (In general, distal marginal ridge is more cervically located)	Distal marginal ridge is more cervically placed than the mesial
Visibility of occlusal surface	More of occlusal surface is visible from mesial aspect	More of occlusal surface visible from distal aspect
Cusp tip		
• Buccal cusp tip	In line with vertical root axis (centered over root base)	Buccal to the vertical root axis
• Lingual cusp tip	In line with lingual outline of root	In line with or lingual to the lingual outline of root
Proximal surfaces	Mesial surface has mesiolingual groove	Smooth
Distal aspect		
Distal marginal ridge	At higher level than mesial ridge	At lower level than mesial ridge
Cervical line	Less curved	Less curved
Occlusal aspect		
Geometric form	Diamond shaped	Square shaped (3 cusp) circular (2 cusp type)
Occlusal table	Small, non-functional occlusal surface	Large functional occlusal surface
Mesiodistal crown dimension	Greater buccally than lingually	Nearly equal buccally and lingually Can be wider on lingually than buccally (3 cusp type)
Visibility of buccal and lingual surfaces	Because of lingual crown tilt, most of buccal surface and very little lingual surface visible from occlusal view	Less of buccal and lingual surfaces are visible
Occlusal anatomy	Do not vary much	Varies according to 3 cusp type or 2 cusp type
Cusps	Large buccal and small non-functional lingual cusp	Buccal and 1 lingual or 2 lingual cusps (Mesiolingual and distolingual)
Transverse ridge	Present	Not present
Occlusal groove pattern	No variability	Varies "Y" pattern—3 cusp type "U" or "H" pattern—2 cusp type
Developmental grooves	Mesial developmental groove Distal developmental groove Mesiolingual developmental groove	In 3 cusp type • Mesial developmental groove • Distal developmental groove • Lingual developmental groove In 2 cusp type • Mesial developmental groove • Distal developmental groove • Central developmental groove
Fossae	Circular fossae near marginal ridges called mesial and distal fossae	In 3 cusp type, Mesial and distal triangular fossae, In 2 cusp type, Mesial and distal irregular fossae
Marginal ridges	Mesial marginal ridge is shorter and constricted because of mesiolingual developmental groove	Both mesial and distal marginal ridge equally well developed

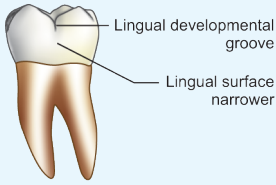
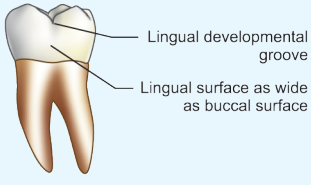
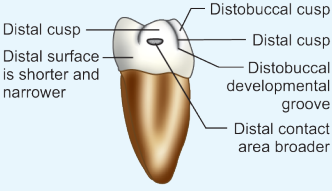
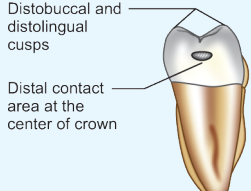
CHARACTERISTICS	MAXILLARY MOLARS	MANDIBULAR MOLARS
Tooth nomenclature		
Universal system	Right 1, 2, 3; Left 14, 15, 16	Right 30, 31, 32; Left 17, 18, 19
Zsigmondy/Palmer system	Right 6, 7, 8; Left 16, 17, 18	Right 6̄, 7̄, 8̄; Left 16̄, 17̄, 18̄
FDI system	Right 16, 17, 18; Left 26, 27, 28	Right 46, 47, 48; Left 36, 37, 38
General features		
Development	4 to 5 lobes One lobe for each cusp	4 to 5 lobes One lobe for each cusp
Number of cusps	In general, 3 large cusps and 1 small cusp—the distolingual cusp 3 large cusps make the <i>Maxillary molar primary cusp triangle</i> (They are mesiobuccal, mesiolingual and distobuccal cusps) An accessory cusp is present only in 1st molar—cusp of Carabelli	In general, 4 large cusps—2 buccal, 2 lingual 1st molar has 5 cusps; the additional small cusp is the distal cusp No cusp of Carabelli
Size of the cusps	2 buccal cusps are unequal—mesiobuccal cusp is larger than distobuccal cusp 2 lingual cusp are unequal, distolingual is smallest of all cusps	2 main buccal cusps—mesiobuccal and distobuccal are equal in size 2 lingual cusps are of equal size
Number of roots	3 roots; 2 buccal and 1 palatal Tripod arrangement—gives good anchorage in alveolar bone	2 roots—1 mesial and 1 distal
Crown dimensions	Buccolingual diameter is greater than the mesiodistal diameter	Mesiodistal diameter is larger than buccolingual
Oblique ridge	Oblique ridge on occlusal surface is a characteristic feature of maxillary molars	No oblique ridge
CROWN		
Buccal aspect		
Geometric form	Trapezoid	Trapezoid
Crown width	Mesiodistal width is greater than cervicoincisal crown height	Mesiodistal width is much greater than crown height
Buccal cusps	Sharper	Blunt and often attrited
Lingual cusp visibility	Only a part of lingual cusps is visible from buccal view	All the cusps are visible from buccal view due to blunt buccal cusps
Visibility of distal surface	Distal surface is visible because of crown form	Not visible from this view
Developmental grooves on buccal surface	One buccal groove separating the buccal cusps	Two buccal grooves—on 1st molar (and 3rd molar) One buccal groove—2nd and 3rd molars
<i>Contact areas</i>		
• Mesial • Distal	At or near the junction of occlusal and middle 3rd At middle 3rd	At or near the junction of occlusal and middle 3rd At middle 3rd
Buccal surface	Relatively vertical	Buccal surface bends lingually from middle 3rd
Lingual aspect		
Geometric form	Trapezoid	Trapezoid
Lingual convergence	1st molar—no lingual taper Less lingual convergence in 2nd and 3rd molars	Marked lingual tapering of crown, especially in 1st molar
Visibility of proximal surfaces from lingual view	Portion of mesial surface visible from this view	Portion of both mesial and distal surfaces visible from this view
Proximal aspect		
Geometric form	Trapezoid	Rhomboid
Lingual crown tilt	Crown upright over root base	Crown tilted lingually over the root base (a feature common to all the mandibular teeth)
Buccal cervical ridge	Less prominent	More prominent, especially on 1st molar
Proximal surfaces	Distal surface narrower than mesial	Distal surface narrower than mesial
Occlusal aspect		
Geometric form	Rhomboid—with 2 acute and 2 obtuse angles	Quadrilateral
Crown dimension	Buccolingual diameter greater than mesiodistal	Mesiodistal diameter greater than buccolingual
Lingual convergence	No marked lingual convergence Crown converges towards buccal in 1st molar	Marked lingual convergence in all molars
Mesiodistal width	Mesiodistal width at lingual is greater than that at buccal in 1st molar	Mesiodistal dimension greater buccally than lingually
Crown taper	Crown tapers from mesial towards distal aspect	Crown tapers from mesial towards distal aspect
Buccolingual width	Greater mesially than distally	Greater mesially than distally
Number of cusps	1st molar—5 cusp 2nd and 3rd molars—4 cusps	1st molar—5 cusps 2nd molar—4 cusps 3rd molar—4 or 5 cusps

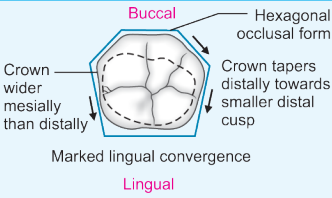
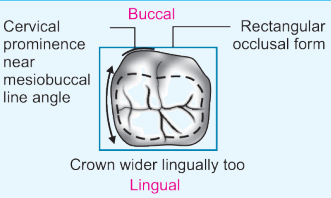
<i>CHARACTERISTICS</i>	<i>MAXILLARY MOLARS</i>	<i>MANDIBULAR MOLARS</i>
Accessory cusp	Cusp of Carabelli on 1st molar	No accessory cusp
Largest cusp	Mesiopalatal cusp	Mesiobuccal cusp
Size of lingual cusps	Unequal in size	Equal in size
Buccal cusps	Sharp	Blunt and often attrited
Centric holding cusps	Lingual cusps	Buccal cusps
Primary cusp triangle	Developmentally only 3 major cusps (2 buccal and mesiolingual cusps) are considered as primary They make a triangular arrangement	No primary cusp triangle present
3rd molars	When not of normal size, tends to be smaller	When not of normal size, tends to be larger
3rd molars resemblance	3rd molars resemble 2nd molar	3rd molars resemble 1st or 2nd molar
Distolingual cusp size	Decreases from 1st molar to 3rd molar in which it may be absent completely	No significant decrease in size
Oblique ridge	Ridge running obliqually on occlusal surface Formed by union of distal ridge of mesiopalatal cusp and triangular ridge of distobuccal cusp Most prominent on 1st molar and barely visible on 3rd molar	No oblique ridge
Fossae	4 fossae— 2 major fossae—central and distal 2 minor fossae—mesial and distal triangular fossae	3 fossae— 1 major central fossa 2 minor—mesial and distal triangular fossae
Groove pattern	No 'Y' or '+' pattern	'Y' or '+' pattern
ROOT		
Number	3 roots—2 buccal and 1 palatal	2 roots—1 mesial and 1 distal
Size	Palatal root—strongest and longest	Two roots are equal in size and length
Root trunk	Long	Short, nearer to cervical line especially in 2nd molar

CHARACTERISTICS	MAXILLARY 1ST MOLAR	MAXILLARY 2ND MOLAR	MAXILLARY 3RD MOLAR
Synonym	6-year molar	12-year molar	Wisdom tooth
Tooth nomenclature	Right Left	Right Left	Right Left
Universal system	3 14	2 15	1 16
Zsigmondy/Palmer system	6̅ 16̅	7̅ 17̅	8̅ 18̅
FDI system	16 26	17 27	18 28
Chronology			
1st evidence of calcification	At birth	2.5–3 years	7–9 years
Eruption	6 years	12–13 years	17–21 years
Root completion	9–10 years	14–16 years	
General features			
Tooth size	Largest tooth in the arch	Smaller than 1st molar	Smallest molar
Variation in form, eruption pattern, timing	Least variable	2 crown forms: (Rhomboidal(4 cusp type i. Heart shaped like 3rd molar ii. (3 cusp type	Most variable tooth in the arch May be congenitally missing (agenesis), impacted, Crown form may be irregular, looking like anomaly
Developmental lobes	5 lobes	4 lobes	3 or 4 lobes
Number of cusps	5	4	4 or 3 cusps
CROWN			
Buccal aspect			
Crown width	Widest of three	Moderate width	Smallest of the three
Height of buccal cusps	Mesio Buccal and distobuccal cusps of same height	Distobuccal cusp slightly shorter than mesio Buccal cusp	Distobuccal cusp much shorter than mesio Buccal cusp
Crown height	Crown height on distal slightly lesser than on mesial	Distal crown height much shorter than mesial	Distal crown height much more shorter than mesial
Distal crown tilt	Crown nearly upright on the root base	Crown shows slight distal tilt on root base due to shorter distobuccal cusp	More distal tilt on root base
Mesial and distal profiles	Mesial and distal crown outlines nearly equal sized	Distal crown outline shorter than mesial crown outline	Distal outline much shorter than mesial outline form
Occlusal surface slant	Nearly horizontal	Slants cervically from mesial to distal	Slants more cervically towards distal
Buccal dental groove (separating 2 buccal cusps)	Relatively longer	Relatively shorter	Shortest
Buccal pit	More pronounced, buccal groove often ends here in buccal pit (often site of caries)	Less marked	May be absent
<i>Proximal contacts</i>			
• Mesial • Distal	At junction of occlusal and middle third Middle third	Middle third Middle third	Middle third No distal contact
Visibility of distal surface from buccal view	Portion of distal surface visible, as the distal surface tapers buccally	Distal surface of crown not visible	Distal surface of crown not visible
Cervical ridge on buccal surface	Prominent cervical ridge	Less prominent cervical ridge	Least prominent cervical ridge
Lingual aspect			
Crown width	Lingually crown is as wide or wider than buccal surface	Lingual width narrower than on buccal	Narrower on lingual than buccal
Lingual convergence	Least or no lingual convergence present	Slight lingual convergence	More lingual convergence
Number of cusps on lingual aspect	2 lingual cusps + 1 accessory cusp (cusp of Carabelli)	2 (in 4 cusp type/rhomboid shaped); 1 (in 3 cusp type/heart shaped 2nd molar)	Usually 1 (distolingual cusp absent)

CHARACTERISTICS	MAXILLARY 1ST MOLAR	MAXILLARY 2ND MOLAR	MAXILLARY 3RD MOLAR
Distolingual cusp	Never missing	Distolingual cusp is absent in 3 cusp type	Usually absent
Size of distolingual cusps	Distolingual cusp smaller than mesiolingual cusp	Distolingual cusp much smaller than mesiolingual cusp	Least in size or entirely absent
Accessory cusp (Cusp of Carabelli)	Cusp of Carabelli is additional cusp lingual to mesiolingual cusp Carabelli's trait may be expressed as a well formed cusp, a tubercle, groove or a pit Carabelli's trait is the characteristic feature of maxillary 1st molar	Rarely present	Not present
Lingual developmental groove	Present between two lingual cusp, relatively long	Present in 4 cusp type/ rhomboid form of 2nd molar	Absent
Mesial aspect	 <p>Mesiobuccal root, Palatal root, Furcation area, Mesial contact area narrower than distal, Cusp of Carabelli, Mesiobuccal cusp, Mesiolingual cusp</p>	 <p>Mesiobuccal root, Palatal root, Mesial and distal contacts broader, Mesiobuccal cusp, Mesiolingual cusp</p>	
Number of cusps visible from mesial aspect	Mesiobuccal, mesiolingual and cusp of Carabelli	Mesiobuccal, mesiolingual	Mesiobuccal, mesiolingual
Buccolingual width	Crown is narrower buccolingually on distal than mesial side	Crown is more narrower buccolingually on distal side	Crown is much narrower buccolingually on distal side
Contact areas	Mesial contact area narrower than distal	Mesial and distal contact areas are equally broader	Broad mesial contact No distal contact
Height of contour			
Buccal	At cervical 3rd (prominent cervical ridge)	Cervical 3rd	Cervical 3rd
Lingual	Middle 3rd (when cusp is large, lingual crest of contour more occlusally)	Middle 3rd	Middle 3rd
Distal aspect			
Distal surface area	Shorter	Shorter and narrower	Shorter and narrower
Occlusal aspect	 <p>Buccal, Rhomboidal occlusal form, Distolingual cusp, Cusp of Carabelli, (No lingual convergence seen), Lingual</p>	 <p>Buccal, More rhomboid occlusal form, Distolingual cusp smaller, Lingual</p>	
• Geometric shape	Rhomboidal	Rhomboidal/Heart shaped	Heart shaped
• Cusp of Carabelli	Present	Absent	Absent
• Oblique ridge	Prominent	Less prominent	Varied
• Distolingual cusp size	Relatively large	Smaller	Smallest/absent

CHARACTERISTICS	MANDIBULAR 1ST MOLAR		MANDIBULAR 2ND MOLAR		MANDIBULAR 3RD MOLAR	
Synonym	6-year molar		12-year molar		Wisdom tooth	
Tooth nomenclature	Right	Left	Right	Left	Right	Left
Universal system	30	19	31	18	32	17
Zsigmondy/Palmer system	6̄	6̅	7̄	7̅	8̄	8̅
FDI system	46	36	47	37	48	38
Chronology						
1st evidence of calcification	At birth		2.5–3 years		8–10 years	
Eruption	6–7 years		11–13 years		17–21 years	
Root completion	9–10 years		14–15 years		18–25 years	
Development	5 lobes		4 lobes		4 and 5 lobes	
Tooth size	Largest tooth in mandibular arch		Smaller than 1st molar		Smallest of mandibular molars	
Number of cusps	Five		Four		Four	
	2-buccal; 2-lingual; 1-distal		2-buccal; 2-lingual		2-buccal; 2-lingual	
Variations	Least variable		Less variable		Highly variable Can be 4 or 5 cusps (like 1st molar) Small or large May be congenitally missing Impaction common	
Buccal aspect	 <p>Small distal cusp Distobuccal cusp Distobuccal developmental groove Distal root 5 Cusps Mesiobuccal developmental groove Mesial root</p>		 <p>No distal cusp Mesiobuccal and distobuccal cusps of equal size Buccal developmental groove Mesial root Distal root Both roots have marked distal axis</p>			
Number of cusps on buccal aspect	Three: Mesiobuccal Distobuccal Distal cusp		Two: Mesiobuccal Distobuccal		Two: Mesiobuccal Distobuccal	
Size of buccal cusps	Mesiobuccal cusp is largest		Both the buccal cusps nearly same size		Both the buccal cusps nearly same size	
Mesiodistal crown width	Greatest mesiodistal width among all permanent teeth		Mesiodistal width less than 1st molar		Mesiodistal width less	
Mesiodistal width at cervix	Crown narrower at cervix		Crown appear broader at cervix due to absence of distal cusp		Broader at cervix	
Relative crown dimensions	Mesiodistal crown width is much greater than cervico-occlusal height		Mesiodistal crown width is slightly greater than cervico-occlusal height		Mesiodistal crown width may be equal to or greater than cervico-occlusal height	
Crown height	Crown appears shorter due to its greater mesiodistal width Crown is shorter at distal than mesial side		Crown appears longer. Its length nearly same; both mesially and distally		Crown height varies	
Developmental groove on buccal surface	Two developmental grooves—mesiobuccal and distobuccal, long groove		One buccal development groove-relatively shorter Also distobuccal developmental groove		Varies 1 buccal developmental groove (in 4 cusp type) 2 buccal developmental groove (in 5 cusp type)	

CHARACTERISTICS	MANDIBULAR 1ST MOLAR	MANDIBULAR 2ND MOLAR	MANDIBULAR 3RD MOLAR
Buccal pit	Commonly present, caries can occur Mesiobuccal developmental groove terminates in this pit	Less common	Varies
Visibility of lingual cusps	Since buccal cusps are blunt, the lingual cusps are visible from buccal view	The lingual cusps are visible	The lingual cusps are visible
<i>Proximal contact areas</i>			
• Mesial • Distal	At junction occlusal and middle 3rd At middle 3rd	Middle 3rd At middle 3rd	Middle 3rd No distal contact
Crown taper to cervical	Mesial and distal outlines taper noticeably from contact areas to cervical line	Less tapering mesial and distal crown outlines	May or may not taper to cervical
Distal crown tilt	Crown appears to be tilted to distal on root base due to shorter crown height distally	Not much distal tilt	May or may not show distal crown tilt
Occlusal surface tilt	Occlusal surface slopes cervically from mesial to distal direction	Occlusal surface is horizontal	May be horizontal or slanting
Lingual aspect			
Lingual convergence	Marked lingual convergence	No much tapering towards lingual	Can vary
Lingual surface	Narrower than the buccal surface since crown tapers towards lingual	Nearly of same width as buccal surface	Narrower or of same width
Visibility of buccal profile	Buccal profile and portion of proximal surfaces visible from lingual aspect	Not visible	May or may not be visible
Lingual cusps	Longer and more pointed than the buccal cusps		
Cusp visibility	Lingual cusp and a part of distal cusp visible	Only lingual cusps visible	Only lingual cusps (like 3rd molar—4 cusp type)
Developmental groove on lingual surface	Lingual groove separates mesiolingual and distolingual cusps	Lingual groove shorter	Shorter or not present
Lingual pit	Often present lingual groove terminates here	May be present	Usually absent
Proximal aspect (Mesial and Distal aspects)			
Crown height	Shorter on distal aspect than mesial	Crown height nearly same on mesial and distal aspect	

CHARACTERISTICS	MANDIBULAR 1ST MOLAR	MANDIBULAR 2ND MOLAR	MANDIBULAR 3RD MOLAR
Lingual crown inclination over root base	Crown more tilted lingually	Moderately tilted lingually	Less tilt lingually
Contact areas	Mesial contact area is smaller than distal, as tooth contacts with a premolar on mesial side	Both contact areas are broader as the tooth contacts with molar on both sides	Broad mesial contact No distal contact
<i>Height of contours</i>			
• Buccal contour • Lingual contour	At cervical 3rd At middle 3rd	At cervical 3rd At middle 3rd	At cervical 3rd At middle 3rd
Buccal cervical ridge	More prominent	Less prominent	Least prominent
Occlusal surface visibility	Greater occlusal surface visible from distal view	Some portion of occlusal surface visible from distal view	Can vary
Cusps seen from distal aspect	Distal, distobuccal, distolingual cusp	Distobuccal, distolingual cusp	Distobuccal, distolingual cusp
Occlusal aspect			
Occlusal form	Hexagonal with unequal size	Rectangular with opposing sides equal	Varies
Relative crown dimensions	Mesiodistal dimension much greater than buccolingual dimension	Mesiodistal dimension slightly greater than buccolingual dimension	Varies
Lingual convergence	More pronounced taper	Less taper	Less taper
Mesiodistal crown width	Greater on buccal side than on lingual	Nearly equal on buccal and lingual	Nearly equal on buccal and lingual or greater on buccal
Crown taper to distal	Marked tapering towards distal	Less taper	Varies
Buccolingual width	Greater mesially than distally	Nearly equal both on mesial and distal	Varies
Cervical bulge	Not present	Prominent cervical bulge at mesiobuccal line angle	Not present
Occlusal table	Broadest of all teeth in the arch	Smaller than 1st molar	Smaller/bigger
<i>Marginal ridges</i>			
• Mesial • Distal	Straight and converge lingually Distal shorter, not well developed	Curved and do not converge to lingual Mesial and distal marginal ridge of same length	More curved Equal or vary
Distal cusp	Present	Not present	Absent (in 4 cusp type) Present (in 5 cusp type)
Groove pattern	Main developmental grooves form 'Y' pattern	Main developmental grooves form '+' pattern	'+' pattern or 'Y' pattern
ROOT			
Number	Two: Mesial and distal	Two: Mesial and distal	Two or fused to one root
Size	Broader buccolingually	Narrower than 1st molar	Much narrower
Length	Mesial and distal roots of same length	Shorter than that of 1st molar	Much shorter
Spacing between roots	Spread wide apart	Closely spaced/sometimes partly fused	Very close/fused
Vertical axis of roots	Mesial root straight for half length, then curved distally; Distal root slants distally for whole length	Both nearly parallel Both roots have more distal inclination	Straight or curved distally
Developmental depression on root	Extend longitudinally on both roots for entire length	Extend for only apical half of root length	Less marked depression/absent
Variations	Less likely	Less likely	More commonly vary—supernumerary root, crooked root

Introduction to Dental Anatomy

1. The permanent teeth that are not succedaneous teeth in the strict sense are:

- a. Permanent incisors
- b. Permanent premolars
- c. Permanent canines
- d. Permanent molars

2. Dental formula for human deciduous dentition is:

- a. I2/2 C1/1 P2/2 M 3/3
- b. I2/2 C 1/1 M3/3
- c. I2/2 C1/1 M2/2
- d. I2/2 C1/1 P1/1 M2/2

3. The only teeth that have their mesial surfaces facing each other are:

- a. Maxillary and mandibular 3rd molars
- b. Maxillary and mandibular central incisors
- c. Maxillary and mandibular canines
- d. None of the above

4. The minimum number of lobes in the development of permanent tooth is:

- a. 5
- b. 3
- c. 4
- d. 2

5. The buccal cervical ridge is most prominent on:

- a. Permanent 1st molars
- b. Deciduous 1st molars
- c. Permanent 2nd molars
- d. Deciduous 2nd molars

6. The number of line angles and point angles on posterior teeth:

- a. 4 line angles and 4 point angles
- b. 6 line angles and 6 point angles
- c. 4 line angles and 6 point angles
- d. 6 line angles and 4 point angles

7. Which of the maxillary posterior teeth, which has both the cusps are symmetrical and are having same height and width:

- a. Maxillary permanent 1st molar
- b. Maxillary permanent 1st premolar
- c. Maxillary permanent 2nd premolar
- d. Mandibular permanent 3rd molars

8. In maxillary permanent 1st molar, the cusp of Carabelli is located on:

- a. Mesio Buccal cusp
- b. Mesiolingual cusp
- c. Distobuccal cusp
- d. Distolingual cusp

9. Cusp of Carabelli is a:

- a. Functional cusp
- b. Non-functional cusp
- c. Fifth cusp
- d. Both b and c

Introduction and Nomenclature

1. According to Universal tooth numbering system, the alphabets used to designate teeth in deciduous dentition are:

- a. 1–32
- b. A–T
- c. I–XX
- d. All of the above

2. According to Universal tooth numbering system the tooth 1 denotes:

- a. Maxillary permanent right central incisor
- b. Mandibular permanent right central incisor
- c. Maxillary permanent right third molar
- d. Mandibular permanent right third molar

3. According to Universal tooth numbering system the tooth 27 denotes:

- a. Maxillary permanent left second molar
- b. Mandibular permanent right canine
- c. Maxillary permanent left canine
- d. Mandibular permanent left second molar

4. According to Universal tooth numbering system, F denotes:

- a. Maxillary deciduous left central incisor
- b. Maxillary deciduous second molar
- c. Maxillary deciduous right first molar
- d. Maxillary deciduous right central incisor

5. Numerical used for permanent dentition in Zigmondy-Palmer notation are:

- a. 1–8
- b. 9–16
- c. 17–24
- d. 25–32

6. According to Zsigmondy-Palmer notation teeth in deciduous dentition is represented by:

- a. 1–8
- b. A-E**
- c. Both of the above
- d. None of the above

7. In FDI system, first and second digit denotes:

- a. Quadrant and tooth**
- b. Tooth and quadrant
- c. Both of the above
- d. None of the above

Chronology of Tooth Development and Form and Function

1. Development of teeth in human begin:

- a. At birth
- b. Prenatally**
- c. At 6 months
- d. At 1 years

2. Primary teeth begin to calcify at:

- a. Birth
- b. 6 months
- c. 6 weeks *in utero*
- d. 14 weeks *in utero***

3. First primary tooth to show its evidence of calcification (begin its development):

- a. Primary maxillary 1st molar
- b. Primary mandibular 1st molar
- c. Primary mandibular central incisor**
- d. Primary mandibular lateral incisor

4. All primary teeth would have begun to calcify by:

- a. 14 weeks of intrauterine life
- b. 18–20 weeks of intrauterine life**
- c. 6 months of gestation
- d. 6 months of age

5. The duration of time each primary tooth takes for its formation, from first evidence of calcification to root completion is:

- a. 3–4 months
- b. 2–3 years**
- c. 5–6 years
- d. 1–2 years

6. The duration of time each permanent tooth takes for its complete formation is:

- a. 3–4 months
- b. 2–3 years
- c. 5–6 years
- d. 8–12 years

7. Mineralization of permanent teeth is:

- a. Entirely prenatal
- b. Entirely postnatal
- c. Occurs both prenatally and postnatally
- d. None of the above

8. Eruption of all the primary teeth would be completed by:

- a. 6 months
- b. 12 months
- c. 12 years
- d. 2½ years

9. Development of primary dentition is considered to be completed:

- a. At 6 months
- b. 30 months
- c. When second primary molars in occlusion
- d. Both b and c

10. Transitional (mixed) dentition period begins at:

- a. 6 months
- b. 6–7 years
- c. When first permanent teeth erupts
- d. Both b and c

Chronology of Tooth Development and Form and Function

1. Each tooth in permanent dentition is in contact with two adjacent teeth except:

- a. Maxillary central incisors
- b. Maxillary lateral incisors
- c. Maxillary and mandibular 1st molars
- d. Maxillary and mandibular 3rd molars

2. Which of the following statement is false regarding the location of contact areas?

- a. Contact more cervically placed on posterior than in anteriors
- b. Mesial and distal contact areas are nearly at same level in posterior than in anteriors
- c. The contact areas are broader in posteriors than that of anteriors
- d. Mesial contact area is already cervically located than the distal contact area

3. The distal contact area is more cervically placed than the mesial contact area in all teeth except in:

- a. Maxillary canine
- b. Mandibular 1st premolar
- c. Mandibular 1st molar
- d. Mandibular canine

4. Among anteriors both mesial and distal contact areas at the same level in:

- a. Maxillary central incisors
- b. Mandibular central incisors
- c. Mandibular lateral incisors
- d. Mandibular canine

5. Which of the following statements is false about the embrasures?

- a. Lingual embrasures are wider than facial embrasures
- b. They are 'V' shaped spaces between adjacent teeth
- c. Embrasures are more uniform in anteriors than posteriors
- d. Embrasures should be ideally symmetrical

6. In posterior teeth, the crest of curvature buccally is at:

- a. Occlusal 3rd
- b. Middle 3rd
- c. Cervical 3rd
- d. None of above

7. In posterior teeth, the crest and curvature is at:

- a. Occlusal 3rd
- b. Middle 3rd
- c. Cervical 3rd
- d. None of above

8. The curvature of cervical line is maximum on:

- a. Mesial surface of maxillary central incisor
- b. Mesial surfaces of maxillary 2nd molar
- c. Distal surface of mandibular 3rd molar
- d. Distal surface of maxillary 3rd molar

9. The geometric form of proximal aspect of anterior is:

- a. Triangular
- b. Rhomboid
- c. Trapezoid
- d. Quadrilateral

10. The geometric form of maxillary molar is:

a. Trapezoid

b. Rhomboid

c. Quadrilateral

d. Circular

Deciduous Dentition

1. Primary/deciduous dentition consists of:

- a. 30 teeth, 15 in each jaw
- b. 32 teeth, 16 in each jaw
- c. 20 teeth, 10 in each jaw**
- d. 12 teeth, 6 in each jaw

2. Each quadrant in deciduous dentition consists of:

- a. 4 teeth
- b. 5 teeth**
- c. 6 teeth
- d. 8 teeth

3. The term 'deciduous' comes from latin meaning:

- a. The first set
- b. The important
- c. The small
- d. To fall off**

4. The following terms are also used to describe primary teeth except:

- a. Milk teeth
- b. Lacteal teeth
- c. Succedaneous teeth**
- d. Baby teeth

5. The following classes of teeth are present in primary dentition:

- a. Incisors, canines, premolars, molars
- b. Incisors, canines, molars**
- c. Incisors, premolars, molars
- d. Canines, premolars and molars

6. Teeth that are not present in primary dentition:

- a. Premolars
- b. Canines, premolars
- c. Premolars, molars
- d. Premolars, 3rd molar

7. Each quadrant in primary dentition contains the following teeth:

- a. Central incisor, lateral incisor, canine, 1st premolar, 1st molar
- b. Central incisor, lateral incisor, canine, 1st molar, 2nd molar
- c. Central incisor, lateral incisor, 1st molar, 2nd molar
- d. Central incisor, lateral incisor, canine, 1st premolar, 2nd premolar, 1st molar, 2nd molar and 3rd molar

8. In mixed dentition period, the primary molars are replaced by:

- a. Permanent molars
- b. Permanent canines
- c. Permanent premolars
- d. None of the above

9. There are how many molars in primary dentition:

- a. 3—1st, 2nd and 3rd molars
- b. 2—1st and 2nd molars
- c. 4—1st, 2nd, 3rd and 4th molars
- d. 1—1st molar

10. There are how many premolars in primary dentition:

- a. 2
- b. 1
- c. 3
- d. There are no premolars in primary dentition

Deciduous Dentition

1. Total number of deciduous teeth in each quadrant are:

- a. 20
- b. 10**
- c. 5
- d. 8

2. The differences between deciduous and permanent teeth with regards to classes of teeth are:

- a. 3 classes of teeth seen in deciduous dentition**
- b. 4 classes of teeth seen in deciduous dentition
- c. Both of the above
- d. None of the above

3. The dental formula for the permanent dentition is:

- a. I 2/2 C 1/1 M 2/2
- b. I 2/2 C 1/1 PM 2/2 M 3/3**
- c. I 1/1 C 1/1 M 1/1
- d. I 2/2 C 2/2 M 2/2

4. By what age the child would have his/her complete set of deciduous dentition:

- a. 2½–3 years of age**
- b. 1–2 years
- c. 0–1½ years
- d. 3½–6 years

5. The sequence of eruption of maxillary permanent teeth is:

- a. 6 1 2 4 5 3 7 8**
- b. 6 1 2 3 4 5 7 8
- c. 1 2 3 4 5 6 7 8
- d. 6 1 2 4 3 5 7 8

Maxillary Incisors

- 1. Which of the following teeth shows great variation in development and form:**
 - a. Permanent maxillary lateral incisor
 - b. Permanent third molars
 - c. Both a and b
 - d. Permanent maxillary molars

- 2. The permanent maxillary lateral incisor is smaller than the maxillary permanent central incisor in all dimensions except:**
 - a. Crown length
 - b. Root length
 - c. Both a and b
 - d. None of the above

- 3. Distal outline of maxillary permanent lateral incisor is:**
 - a. Shorter than mesial outline
 - b. Larger than mesial outline
 - c. Similar to that of mesial
 - d. None of the above

- 4. In comparison to maxillary permanent central incisor, the labial surface of maxillary permanent lateral incisor is:**
 - a. More convex
 - b. Less convex
 - c. More concave
 - d. Less concave

- 5. When present, the developmental groove crossing the distal side of the cingulum extending on the root of maxillary permanent lateral incisor is called as:**
 - a. Palatogingival groove
 - b. Palatoradicular groove
 - c. Palatocervical groove
 - d. Both a and b

6. The geometric shape of maxillary permanent lateral incisor from the mesial aspect is:

- a. **Triangular**
- b. Trapezoidal
- c. Cuboidal
- d. Rectangular

7. Mesial contact area of permanent maxillary lateral incisor is located at:

- a. Junction of middle and cervical third
- b. Center of middle third
- c. **Junction of incisal and middle third**
- d. Center of incisal third

8. Distal contact area of permanent maxillary lateral incisor is located at:

- a. **At the middle third**
- b. At the cervical third
- c. At the incisal third
- d. None of the above

9. Which of the following statements is false regarding the root of the permanent maxillary lateral incisor?

- a. Has single root
- b. Root is about one and a half times the length of the crown
- c. Root length is greater in proportion to the crown length when compared to central incisor
- d. **Apical third of root usually shows no curvature**

10. Cross-section of the maxillary permanent lateral incisor root at cervix is:

- a. Triangular
- b. **Oval**
- c. Circular
- d. Diamond shaped

Mandibular Incisors

1. The smallest tooth in permanent dentition is:

- a. Maxillary permanent lateral incisor
- b. Mandibular permanent lateral incisor
- c. Mandibular permanent central incisor
- d. Maxillary permanent central incisor

2. Which of the following statements is true:

- a. In maxillary arch, the central incisor is larger than the lateral
- b. In mandibular arch, also the central incisor is larger than the lateral
- c. In mandibular arch, the lateral incisor is larger than the central
- d. Both a and c

3. The crown of mandibular permanent central incisor is:

- a. Bilaterally asymmetrical from labial and lingual aspects
- b. Bilaterally symmetrical from labial, lingual and incisal aspects
- c. Bilaterally symmetrical from all aspects
- d. Bilaterally asymmetrical from all aspects

4. The geometrical shape of mandibular permanent central incisor from the labial aspect is:

- a. Triangular
- b. Hexagonal
- c. Octagonal
- d. Trapezoid

5. Mesioincisal angle of mandibular permanent central incisor is:

- a. Acute angled
- b. Obtuse angled
- c. Right angled
- d. None of the above

6. Distoincisal angle of mandibular permanent central incisor is:

- a. Acute angled
- b. Right angled**
- c. Obtuse angled
- d. None of the above

7. In mandibular permanent central incisor, the mesial and distal contact areas are:

- a. At the same level**
- b. At different levels
- c. Absent one side
- d. Absent on both the sides

8. Mesial and distal contact area of mandibular permanent central incisor is located at:

- a. Middle third
- b. Cervical third
- c. Incisal third**
- d. None of the above

9. The differences between mesial and distal surface of mandibular permanent central incisor is:

- a. Extent of curvature of cervical line on distal aspect is 1 mm less than on the mesial**
- b. Extent of curvature of cervical line on mesial aspect is 1 mm less than on the distal
- c. Extent of curvature of cervical line on distal aspect is 4 mm more than on the mesial
- d. None of the above

10. In mandibular permanent central incisor, the labiolingual dimension is:

- a. Always smaller than mesiodistal dimension
- b. Always greater than mesiodistal dimension**
- c. Both are exactly same
- d. None of the above

Permanent Canines

1. Synonyms of maxillary permanent canine are followings, except:

- a. Beauty tooth
- b. Corner stone of dental arch
- c. Cuspids
- d. Canivos teeth

2. The maxillary permanent canines are named because they:

- a. Closely resemble the tearing teeth of carnivores, especially those of dogs
- b. Are corner stones of arches
- c. Are four in number
- d. Are having longest roots

3. The maxillary permanent canine develops from:

- a. 2 lobes
- b. 3 lobes
- c. 4 lobes
- d. 5 lobes

4. Which of the following statement is false?

- a. The maxillary permanent canine has longest and strongest roots of all teeth
- b. The maxillary permanent canines are six in number
- c. The maxillary permanent canines are also called as cuspids
- d. Roots of maxillary permanent canines have excellent anchorage in the alveolar bone with an extra length and wider labiolingual width

5. The term *canine eminence* refers to:

- a. Alveolar bone over the roots of maxillary permanent canines, labially, is prominent and or is prominent labial alveolar bone over the roots of maxillary permanent canines
- b. Prominent lingual alveolar bone over the roots of maxillary permanent canines
- c. Least prominent labial alveolar ridge/bone over the roots of maxillary permanent canines
- d. Least prominent labial alveolar ridge/bone over the roots of maxillary permanent canines

6. Following are the functions of maxillary permanent canines, except:

- a. They assist permanent incisors and premolars in mastication
- b. They are mainly used for tearing food
- c. They help in seizing, slicing and chewing food
- d. They are esthetically not important

7. The characteristics of maxillary permanent canines are:

- a. Maxillary permanent canines exhibit some of the characteristics of maxillary permanent incisors
- b. Maxillary permanent canines exhibit some of the characteristics of permanent premolars
- c. Maxillary permanent canines exhibit longest root of all
- d. All of the above

8. The shape of the crown of maxillary permanent canine from the labial aspect is:

- a. Trapezoidal
- b. Pentagonal
- c. Hexagonal
- d. Both a and b

9. The mesial outline of the crown of maxillary permanent canine from the labial aspect is:

- a. Convex arc from cervix to the area where it joins the mesial cusp slope
- b. Concave arc from cervix to the area where it joins the mesial cusp slope
- c. Straight from cervix to the area where it joins the mesial cusp slope
- d. None of the above

10. The minimum convexity of the mesial outline of maxillary permanent canine from the labial aspect lies at:

- a. The junction of cervical and middle third of the crown
- b. The junction of incisal and middle third of the crown
- c. At the cervical third
- d. Near the gingival margin.

Permanent Maxillary Premolars

1. Which of the following statement is false regarding the maxillary premolars:

- a. There are eight premolars, four in each and two in each quadrant
- b. There are no premolars in deciduous dentition and they succeed deciduous molars
- c. Premolars along with molars occupy posterior segment of dental arches and are collectively referred to as posterior teeth
- d. Premolars are often also called as tricuspid

2. Which of the following premolar has only one functional cusp?

- a. Mandibular 1st premolar
- b. Mandibular 2nd premolar
- c. Maxillary 1st premolar
- d. Maxillary 2nd premolar

3. Which of the following premolar can have three cusps?

- a. Mandibular 1st premolar
- b. Mandibular 2nd premolar
- c. Maxillary 1st premolar
- d. Maxillary 2nd premolar

4. Generally premolars develop from four lobes, except:

- a. Mandibular 1st premolar
- b. Mandibular 2nd premolar
- c. Maxillary 1st premolar
- d. Maxillary 2nd premolar

5. Which of the following premolar develops from five lobes?

- a. Mandibular 1st premolar
- b. Mandibular 2nd premolar
- c. Maxillary 1st premolar
- d. Maxillary 2nd premolar

6. Which of the following premolar generally has two roots?

- a. Mandibular 1st premolar
- b. Mandibular 2nd premolar
- c. Maxillary 1st premolar
- d. Maxillary 2nd premolar

7. Which of the following premolar has a single root?

- a. Mandibular 1st premolar
- b. Mandibular 2nd premolar
- c. Maxillary 2nd premolar
- d. All of the above

8. The following are the functions of premolar except:

- a. They grind the food along with molar
- b. They provide support to check near corner of mouth
- c. They reinforce esthetics during smiling
- d. None of the above

9. Which of the following statements is false regarding maxillary 1st premolar?

- a. The maxillary 1st premolar has two cusps and frequently has one root with one pulp canal
- b. The maxillary 1st premolar has two cusps and two roots; buccal and lingual
- c. Sometimes they can have a single root with two pulp chamber
- d. The buccal cusp is longer than the lingual cusp by 1 mm
- e. The crown is angular with prominent buccal line angle

10. In maxillary permanent 1st premolar?

- a. The buccal cusp is longer than the lingual cusp by 1–2 mm
- b. The lingual cusp is longer than the buccal cusp
- c. Both the cusps are equal sized
- d. Either a or b

Mandibular Premolars

1. Mandibular permanent premolars differs from each other in their:

- a. Development
- b. Form
- c. Both a and b**
- d. Neither a nor b

2. Mandibular permanent 1st premolar develops from:

- a. 4 lobes**
- b. 5 lobes
- c. 3 lobes
- d. 2 lobes

3. Mandibular permanent 2nd premolar develops from:

- a. 4 lobes
- b. 5 lobes**
- c. 3 lobes
- d. 2 lobes

4. Compared to mandibular 2nd premolar the mandibular 1st premolar is:

- a. Smaller**
- b. Larger
- c. Same size
- d. None

5. Compared to mandibular 1st premolar the mandibular 2nd premolar is:

- a. Smaller
- b. Larger**
- c. Same size
- d. None

6. Mandibular permanent 1st premolar has:

- a. Two cusps
- b. Three cusps
- c. Four cusps
- d. One cusp

7. Functional cusp of mandibular permanent 1st premolar is:

- a. Buccal cusp
- b. Lingual cusps
- c. Both a and b
- d. Neither a nor b

8. Non-functional cusp of mandibular 1st premolar is:

- a. Buccal cusp
- b. Lingual cusp
- c. Both a and b
- d. Neither a nor b

9. The largest cusp of mandibular permanent 1st premolar is:

- a. Lingual cusp
- b. Buccal cusp
- c. Accessory cusp
- d. None

10. The feature of mandibular permanent 1st premolar is that are true:

- a. Mesial and distal contact areas at same level
- b. Buccolingual measurement is similar to that of mandibular canine
- c. Occlusal surface slopes drastically lingually in a cervical direction
- d. All of the above

Maxillary Molars

1. Non-functional cusp of maxillary permanent 1st molar is:

- a. Mesiobuccal cusp
- b. Distobuccal cusp
- c. Mesiolingual cusp
- d. Cusp of Carabelli

2. How many cusps are seen in maxillary permanent 1st molar?

- a. Four
- b. Five
- c. Two
- d. Three

3. Tripod design of maxillary permanent 1st molar is best suited to resist:

- a. Oblique occlusal forces
- b. Horizontal force
- c. Vertical force
- d. Transverse force

4. The geometrical shape of buccal aspect of maxillary permanent 1st molar is:

- a. Trapezoidal
- b. Triangular
- c. Octagonal
- d. Hexagonal

5. Mesial contact area of maxillary permanent 1st molar is located at:

- a. Occlusal third of the crown
- b. Incisal third of the crown
- c. Cervical third of the crown
- d. None of the above

6. The cervical line on buccal surface of the crown of the maxillary permanent 1st molar is:

- a. Regular
- b. In occlusal direction
- c. In apical direction and irregular**
- d. None of the above

7. Which cusp of maxillary permanent 1st molar is widest?

- a. Mesiobuccal cusp**
- b. Distobuccal cusp
- c. Mesiolingual cusp
- d. Distolingual cusp

8. Which cusp is sharper in maxillary permanent 1st molar?

- a. Mesiobuccal cusp
- b. Distobuccal cusp**
- c. Mesiolingual cusp
- d. Distolingual cusp

9. Groove separating mesiobuccal cusp from distobuccal cusp of maxillary permanent 1st molar is:

- a. Mesiobuccal developmental groove
- b. Distobuccal developmental groove
- c. Buccal developmental groove**
- d. Transverse developmental groove

10. Groove separating mesiolingual cusp from distolingual cusp of maxillary permanent 1st molar is:

- a. Mesiobuccal developmental groove
- b. Distobuccal developmental groove
- c. Lingual developmental groove**
- d. Transverse developmental groove

11. Which cusp of maxillary permanent 1st molar is largest?

- a. Mesiobuccal cusp
- b. Distobuccal cusp
- c. Mesiolingual cusp**
- d. Distolingual cusp

Mandibular Molars

1. In mandibular arch, the size of the molar teeth:

- a. Increases from 1st molar to 3rd molar
- b. Decreases from 1st molar to 3rd molar**
- c. Remains same for all three molars
- d. None of the above

2. Mandibular molar crowns are:

- a. Wider mesiodistally than buccolingually**
- b. Wider buccolingually than mesiodistally
- c. Equal in mesiodistal and buccolingual dimensions
- d. None of the above

3. The largest tooth of mandibular arch in permanent dentition is:

- a. Mandibular 2nd premolar
- b. Mandibular 1st molar**
- c. Mandibular 2nd molar
- d. Mandibular 3rd molar

4. Mandibular 1st molar has:

- a. 3 cusps
- b. 4 cusps
- c. 5 cusps**
- d. 6 cusps

5. Mandibular 1st molar has:

- a. 2 roots; buccal and lingual
- b. 2 roots; mesial and distal**
- c. 3 roots; 2 buccal and lingual
- d. 3 roots; 2 mesial and distal

6. Buccal and lingual aspects of mandibular 1st molar are:

- a. Triangular
- b. Rhomboidal
- c. Trapezoidal with shorter uneven side towards the cervix
- d. Trapezoidal with shorter uneven side towards the occlusal portion

7. Buccal surface of the mandibular 1st molar has:

- a. No developmental groove
- b. One developmental groove
- c. Two developmental grooves
- d. Three developmental grooves

8. In permanent mandibular 1st molars, the cusps visible from buccal view are:

- a. Two buccal cusps only
- b. Two buccal cusps and the distal cusp
- c. Two buccal cusps and two lingual cusps
- d. All five cusps can be seen

9. The cusps present in permanent mandibular 1st molar:

- a. Mesio Buccal, distobuccal, mesiolingual, distolingual and distal
- b. Mesio Buccal, middle distal, mesiolingual, and distolingual
- c. Mesio Buccal, distobuccal, mesiolingual, distolingual and cusp of Carabelli
- d. None of the above

10. The 2 buccal cusps of mandibular 1st molar are separated by:

- a. The central developmental groove
- b. The oblique developmental groove
- c. The mesio Buccal developmental groove
- d. The distobuccal developmental groove

Incisor Teeth

1. The following are the first permanent teeth to erupt along with the first permanent molars:

- a. Maxillary central incisors
- b. Mandibular central incisors**
- c. Maxillary lateral incisors
- d. Mandibular lateral incisors

2. Smallest tooth in permanent dentition is:

- a. Maxillary central incisor
- b. Maxillary lateral incisor
- c. Mandibular central incisor**
- d. Mandibular lateral incisor

3. Among incisor teeth, the crowns are more symmetrical in:

- a. Maxillary incisors
- b. Mandibular incisors**
- c. Both of the above
- d. None of the above

4. The mesial and distal contact areas are nearly at the same level in:

- a. Maxillary incisors
- b. Mandibular incisors**
- c. Both of the above
- d. None of the above

5. Which of the following statement is true?

- a. In the maxillary arch, central incisor is larger than the lateral
- b. In the mandibular arch, lateral incisor is larger than the central
- c. Both of the above**
- d. None of the above

6. In the incisor group, which tooth exhibits greatest variation in its morphology?

- a. Maxillary central incisor
- b. Maxillary lateral incisor**
- c. Mandibular central incisor
- d. Mandibular lateral incisor

7. Both the contact areas are very much nearer to incisal edge in:

- a. Maxillary incisors
- b. Mandibular incisors**
- c. Both of the above
- d. None of the above

8. When compared to maxillary incisors, the lingual fossa of mandibular incisors is:

- a. Deeper
- b. Exhibit more developmental grooves
- c. Shallower without developmental grooves**
- d. Both a and b

9. Lingual pits are often present in:

- a. Maxillary incisors**
- b. Mandibular incisors
- c. Both of the above
- d. None of the above

10. When viewed from proximal aspect, the incisal ridge/edge of maxillary incisors is placed:

- a. In line with the vertical root axis**
- b. Labial to the line with the vertical root axis
- c. Lingual to the line with the vertical root axis
- d. None of the above

Canine Teeth

1. The permanent maxillary canine erupts:

- a. After the eruption of mandibular canine
- b. Before eruption of both the maxillary premolars
- c. After the eruption of one or both maxillary premolars
- d. Both a and c

2. The labial ridge is prominent in:

- a. Maxillary canine
- b. Mandibular canine
- c. Both
- d. None

3. Among the permanent canines:

- a. The maxillary canine crown is bulkier and broader
- b. Mandibular canine crown is longer and narrower
- c. Crowns of both the canines are of same size
- d. Both a and b

4. Which of the following statements is true about permanent canines?

- a. The cusp is sharp and well developed in maxillary canine
- b. Angle formed by the mesial and distal cusp ridges is wider in mandibular canine
- c. The occlusal portion occupies 1/3rd of the crown length in maxillary canine; while it occupies 1/5th of the crown length in mandibular canine
- d. All of the above

5. Which of the following statements is true regarding contact areas of permanent canines?

- a. Mesial and distal contact areas are markedly at dissimilar levels in maxillary canine
- b. Contact areas are placed more incisally in mandibular canine
- c. Contact areas are placed at same level in maxillary and mandibular canines
- d. Both a and b

6. When permanent mandibular canine is viewed from labial aspect, the crown is:

- a. Upright on the root base
- b. Tilted mesially on the root base
- c. Tilted distally on the root base
- d. None of the above

7. The cingulum is:

- a. More prominent in maxillary canine
- b. More prominent in mandibular canine
- c. Small in both the canines
- d. Prominent in both the canines

8. Lingual ridge is often seen dividing the lingual fossa into two small fossae in:

- a. Maxillary canine
- b. Mandibular canine
- c. Maxillary central incisor
- d. Maxillary lateral incisor

9. When maxillary canine is viewed proximally, the cusp tip is:

- a. On line with the vertical root axis
- b. Labial to the vertical root axis
- c. Lingual to the vertical root axis
- d. Distal to the vertical root axis

10. When mandibular canine is viewed proximally, the cusp tip is:

- a. On line with the vertical root axis
- b. Labial to the vertical root axis
- c. Lingual to the vertical root axis**
- d. Distal to the vertical root axis

Premolar Teeth

1. Which of the following statements is true regarding the premolar teeth?

- a. Maxillary 1st and 2nd premolars are similar in form
- b. Mandibular 1st and 2nd premolars are similar in form
- c. Mandibular 1st and 2nd premolars are widely different in form
- d. Both a and c

2. The distal cusp ridge is longer than the mesial cusp ridge in all the premolars except:

- a. Maxillary 1st premolar
- b. Maxillary 2nd premolar
- c. Mandibular 1st premolar
- d. Mandibular 2nd premolar

3. From proximal aspect, the maxillary premolar crowns appear:

- a. Triangular
- b. Trapezoidal
- c. Rhomboidal
- d. Ovoid

4. From proximal aspect, the mandibular premolar crowns appear:

- a. Triangular
- b. Trapezoidal
- c. Rhomboidal
- d. Ovoid

5. When viewed proximally, the maxillary premolar crowns are:

- a. Upright on the root base
- b. Tilted buccally on the root base
- c. Tilted lingually on the root base
- d. Tilted mesially on the root base

6. When viewed proximally, mandibular premolar crowns are:

- a. Upright on the root base
- b. Tilted buccally on the root base
- c. Tilted lingually on the root base
- d. Tilted distally on the root base

7. Compared to maxillary premolars, the buccal and lingual cusp tips of mandibular premolars are:

- a. Wide apart
- b. More nearer
- c. Blunt/flattened
- d. None of above

8. When viewed proximally, buccal cusp tip of maxillary premolars is located:

- a. Buccal to the vertical root axis
- b. Lingual to the vertical root axis
- c. On line with vertical root axis
- d. Both b and c

9. When viewed proximally, the buccal cusp tip of mandibular premolars is:

- a. Buccal to the vertical root axis
- b. Lingual to the vertical root axis
- c. On line with the vertical root axis
- d. Distally to the vertical root axis

10. When viewed proximally, compared to maxillary premolars the mandibular premolars have:

- a. Buccal and lingual crown outlines well within the confines of root base
- b. Buccal crown outlines out of the confines of root base
- c. Lingual crown outline out of the confines of root base**
- d. Buccal and lingual crown outlines out of the confines of root base

Molar Teeth

1. The cusp of Carabelli is a feature of: ~~مطلوب لان ماعدنه~~

~~البراييري بس مابيه حيل امسح الكتابه~~

- a. Permanent maxillary 1st molar
- b. Primary maxillary 1st molar
- c. Primary maxillary 2nd molar
- d. Both a and c

2. Which of the following statements is true regarding the molars?

- a. Maxillary molars have 2 roots; mandibular molars have 3 roots
- b. Maxillary molars have 3 roots; mandibular molars have 2 roots
- c. Both maxillary and mandibular molars have 3 roots
- d. Both maxillary and mandibular molars have 2 roots

3. Maxillary molars have 3 roots. They are:

- a. Buccal, lingual and distal
- b. 1 buccal, 2 lingual
- c. Mesio Buccal, distobuccal and palatal
- d. 2 mesial and 1 distal

4. The mandibular molars have 2 roots. They are:

- a. Mesial and distal
- b. Buccal and lingual
- c. Buccal and palatal
- d. Both b and c

5. Oblique ridge is a feature of:

- a. Maxillary premolars
- b. Maxillary molars
- c. Mandibular premolars
- d. Mandibular molars

6. The following are the features of maxillary molars except:

- a. Cusp of Carabelli on 1st molar
- b. Oblique ridge on occlusal surface
- c. Trifurcated roots
- d. Rectangular occlusal crown outline

7. Maxillary molar crowns have:

- a. Mesiodistal dimension greater than the buccolingual dimension
- b. Buccolingual dimension greater than the mesiodistal dimension
- c. Mesiodistal and buccolingual dimensions nearly equal
- d. None of the above

8. Mandibular molar crowns have:

- a. Mesiodistal dimension greater than the buccolingual dimension
- b. Buccolingual dimension greater than the mesiodistal dimension
- c. Mesiodistal and buccolingual dimensions nearly equal
- d. None of the above

9. Compared to maxillary molars, the buccal surface of mandibular molar crowns:

- a. Is more vertical
- b. Bends buccally from middle third
- c. Bends lingually from cervical third
- d. Bends mesially

10. Compare to mandibular molars, the maxillary molar crowns exhibit:

- a. Less lingual convergence
- b. Greater lingual convergence
- c. No lingual convergence in 1st molar, which may show a buccal taper
- d. Both a and c

Review Questions

Select the one best answer.

1. How many teeth are present in one quadrant of a complete adult (permanent) dentition?
 - a. 5
 - b. 8
 - c. 10
 - d. 20
 - e. 32

2. What class of teeth is present in the permanent dentition that is NOT present in the primary dentition?
 - a. Incisors
 - b. Canines
 - c. Premolars
 - d. Molars

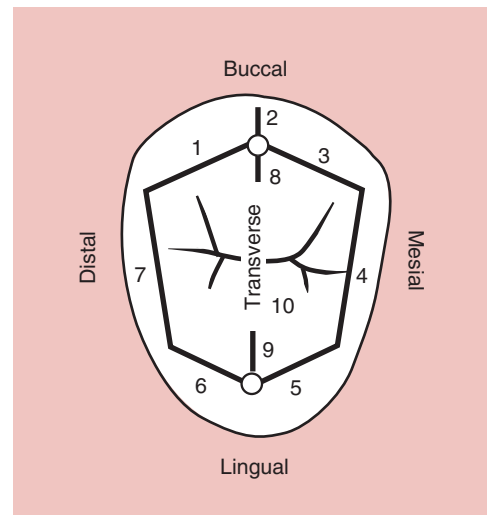
3. In a permanent dentition, the fifth tooth from the midline is a
 - a. Canine
 - b. Premolar
 - c. Molar
 - d. Incisor

4. Posterior teeth in the permanent dentition include which of the following?
 - a. Premolars only
 - b. Molars only
 - c. Premolars and molars only
 - d. Canines, premolars, and molars

5. Which permanent tooth erupts into the space previously held by the primary second molar?
 - a. First molar
 - b. Second molar
 - c. First premolar
 - d. Second premolar

ANSWERS: 1—b, 2—c, 3—b, 4—c, 5—d

1. _____
2. _____
3. _____
4. _____
5. _____
6. _____
7. _____
8. _____
9. _____
10. Transverse



ANSWERS: 1—distal cusp ridge of buccal cusp; 2—buccal (cusp) ridge; 3—mesial cusp ridge of buccal cusp; 4—mesial marginal ridge; 5—mesial cusp ridge of lingual cusp; 6—distal cusp ridge of lingual cusp; 7—distal marginal ridge; 8—triangular ridge of buccal cusp; 9—triangular ridge of lingual cusp—7

FIGURE 1-22. Identify the ridges numbered on this maxillary premolar.

Review Questions

- If you read an article in a British dental journal that refers to tooth No. 48, you would suspect that the authors were using the International Numbering System. What universal number (or letter) would they be talking about?
 - a.
 - b.
 - c.
 - d.
 - e.
- Using the Universal Numbering System, what numbers are used to identify maxillary canines?
 - a.
 - b.
 - c.
 - d.
 - e.
- Which tooth junctions are NOT normally visible on a handheld intact tooth?
 - a. Cementoenamel junction
 - b. Dentinoenamel junction
 - c. Dentinocementum junction
 - d. Dentinopulpal junction
- Which statement(s) is (are) likely to be true on a person with a barely erupted tooth No. 9?
 - a. The clinical crown is larger than the anatomic crown
 - b. The clinical crown is smaller than the anatomic crown
 - c. The clinical root is larger than the anatomic root
 - d. The clinical root is smaller than the anatomic root
- Which tooth surface(s) face(s) the lips or cheeks?
 - a. Facial
 - b. Distal
 - c. Buccal
 - d. Occlusal
 - e. Labial
- Which pairs of teeth have a mesial surface touching a mesial surface?
 - a. 25 and 26
 - b. 16 and 17
 - c. 7 and 8
 - d. 1 and 32
 - e. 8 and 9
- When viewing tooth No. 8 from the distal view, it can be divided into thirds from the incisal to the cervical and from the facial to the lingual. Which third is NOT possible to see from the distal view?
 - a. Facial
 - b. Cervical
 - c. Middle
 - d. Mesial
 - e. Incisal
- If you were observing the faciolingual dimension of a tooth, what surface(s) could you be viewing?
 - a. Mesial
 - b. Occlusal
 - c. Proximal
 - d. Labial
 - e. Distal
- If the root-to-crown ratio of a maxillary molar (No. 14) is 1.72 and that of another molar, No. 16, is 1.49, which tooth has the longest root relative to its shorter crown?
 - a. No. 14
 - b. No. 16
 - c. More information is required in order to answer this question
- Which of the following bumps or ridges is NOT likely to be found on a maxillary premolar?
 - a. Oblique ridge
 - b. Cingulum
 - c. Mesial marginal ridge
 - d. Transverse ridge
 - e. Triangular ridge
- Which ridges surround the perimeter of the occlusal surface (occlusal table) of a two-cusped premolar?
 - a. Mesial marginal ridge
 - b. Distal marginal ridge
 - c. Mesial cusp ridge of the buccal cusp
 - d. Distal cusp ridge of the lingual cusp
 - e. Transverse ridge
- What is the correct order of anatomic landmarks of a tooth with two roots from the cementoenamel junction to the root tip?
 - a. Cervix, trunk, furcation, apex
 - b. Trunk, cervix, furcation, apex
 - c. Trunk, furcation, cervix, apex
 - d. Cervix, trunk, apex, furcation
 - e. Furcation, trunk, cervix, apex

13. When viewed from the proximal views, what is the location of the greatest bulge (crest of curvature or height of contour) on the facial surface of all teeth?
- Occlusal third
 - Lingual third
 - Buccal third
 - Middle third
 - Cervical third
14. Which space(s) contain(s) the part of the gingiva known as the interdental papilla?
- The buccal embrasure
 - Occlusal embrasure
 - Lingual embrasure
 - Cervical embrasure
 - Interproximal space
15. Ideal class I occlusion involves an important first permanent molar relationship where the mesiobuccal cusp of the maxillary first molar is located within the
- Mesiobuccal groove of the mandibular first molar
 - Distobuccal groove of the mandibular first molar
 - Buccal groove of the mandibular second molar
 - Mesiobuccal groove of the mandibular second molar
 - Distobuccal groove of the mandibular second molar
16. Where do lingual cusps of maxillary teeth occlude in ideal class I occlusion?
- In the buccal embrasure space between mandibular teeth
 - In the lingual embrasure space between mandibular teeth
 - In occlusal fossae of mandibular teeth
17. How many developmental lobes form a premolar with two cusps (one buccal cusp and one lingual cusp)?
- 1
 - 2
 - 3
 - 4
 - 5

ANSWERS: 1—e; 2—a, d; 3—b, c, d; 4—b, c; 5—a, c, e; 6—e; 7—d; 8—a, b, c, e; 9—a; 10—a, b; 11—a, b, c, d; 12—a; 13—e; 14—d, e; 15—a; 16—c; 17—d

Review Questions

For each of the traits listed below, select the letter(s) of the permanent incisor(s) that normally exhibit(s) that trait. More than one answer may apply.

- Maxillary central incisor
 - Maxillary lateral incisor
 - Mandibular central incisor
 - Mandibular lateral incisor
- Mesiodistal dimension of the crown is larger than the labiolingual dimension. a b c d
 - The incisal ridge exhibits a distolingual twist. a b c d
 - The root is very narrow mesiodistally with mesial and distal root depressions a b c d
 - The incisal edge is positioned more to the lingual of the root axis line. a b c d
 - The distal proximal height of contour is more cervical than the mesial height of contour. a b c d
 - This tooth has the widest (mesiodistally) incisor crown. a b c d
 - This tooth has the shortest root relative to its crown. a b c d
 - This tooth is the most symmetrical incisor. a b c d
 - This tooth has the largest curvature of the mesial cervical line. a b c d
 - This tooth has the narrowest incisor crown (mesiodistally). a b c d

ANSWERS: 1—a, b; 2—a, d; 3—c, d; 4—c, d; 5—a, b, d; 6—a; 7—a; 8—c; 9—a; 10—c

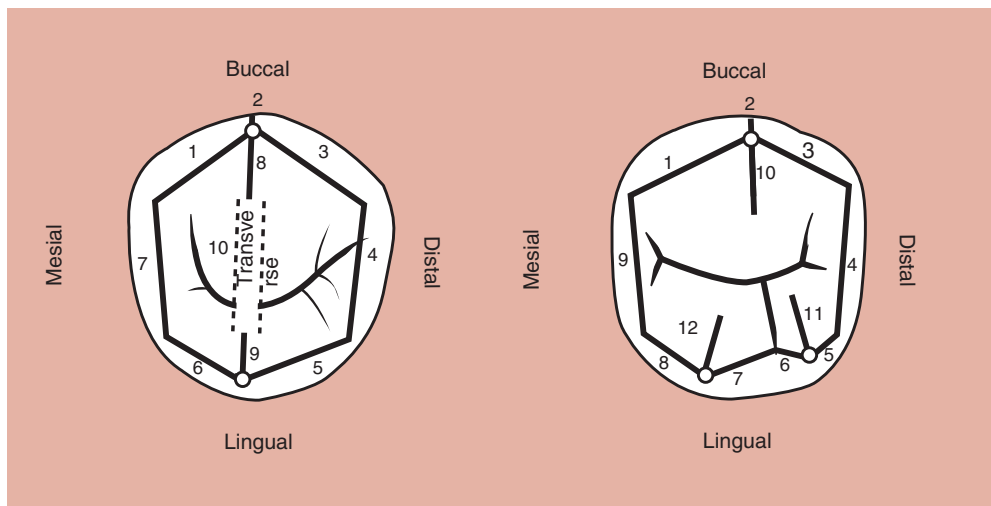
Review Questions

For each trait described below, indicate the letter of the best response from the five selections provided. Each trait has only one best answer.

- a. Maxillary central incisor
- b. Maxillary canine
- c. Mandibular canine
- d. All of the above
- e. None of the above

1. This tooth exhibits less cervical line curvature on the distal aspect than on the mesial aspect. a b c d e
2. The cingulum is centered mesiodistally. a b c d e
3. There is an almost continuous crown-root outline on the mesial surface of this tooth. a b c d e
4. The mesial contact area is located more incisally than the distal contact area on the same tooth. a b c d e
5. The cusp tip is positioned lingual to the mid-root axis line from the proximal view. a b c d e
6. Mamelons could be observed on this tooth. a b c d e
7. On which tooth is the cusp angle most acute? a b c d e
8. The mesiodistal width of this tooth is greater than its labiolingual width. a b c d e
9. The mesial and distal marginal ridges are aligned more vertically than horizontally on the lingual surface. a b c d e
10. The teeth (tooth) develop(s) from four lobes. a b c d e
11. The teeth (tooth) develop(s) from three lobes. a b c d e

ANSWERS: 1—d; 2—b; 3—c; 4—d; 5—c; 6—a; 7—b; 8—a; 9—d; 10—d; 11—e



A. Name the ridges

B. Name the ridges

Ridges	Name
1.	_____
2.	_____
3.	_____
4.	_____
5.	_____
6.	_____
7.	_____
8.	_____
9.	_____
10.	_____

Ridges	Name
1.	_____
2.	_____
3.	_____
4.	_____
5.	_____
6.	_____
7.	_____
8.	_____
9.	_____
10.	_____
11.	_____
12.	_____

ANSWERS: A. Ridges for two-cusp type: 1—mesial cusp ridge of buccal cusp; 2—buccal ridge; 3—distal cusp ridge of buccal cusp; 4—distal marginal ridge; 5—distal cusp ridge of lingual cusp; 6—mesial cusp ridge of lingual cusp; 7—mesial marginal ridge; 8—triangular ridge of buccal cusp; 9—triangular ridge of lingual cusp; 10—transverse ridge.

B. Ridges for three-cusp type: 1—mesial cusp ridge of buccal cusp; 2—buccal ridge; 3—distal cusp ridge of buccal cusp; 4—distal marginal ridge; 5—distal cusp ridge of distolingual cusp; 6—mesial cusp ridge of distolingual cusp; 7—distal cusp ridge of mesiolingual cusp; 8—mesial cusp ridge of mesiolingual cusp; 9—mesial marginal ridge; 10—triangular ridge of buccal cusp; 11—triangular ridge of distolingual cusp; 12—triangular ridge of mesiolingual cusp.



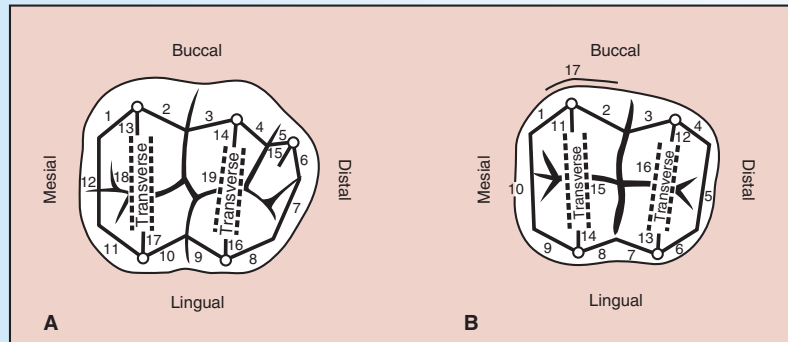
Review Questions

For each of the following traits or statements, circle the letter (or letters) of the premolars (if any) that apply. More than one answer may be correct.

- a. Maxillary first premolar
 - b. Maxillary second premolar
 - c. Mandibular first premolar
 - d. Mandibular second premolar (two-cusp type)
 - e. Mandibular second premolar (three-cusp type)
1. Mesial cusp ridge of the buccal cusp is longer than the distal cusp ridge. a b c d e
 2. Has a nonfunctioning lingual cusp. a b c d e
 3. Two premolars that most frequently have a groove crossing the mesial marginal ridge or one groove just lingual to it. a b c d e
 4. Has a depression in the cervical one third of the mesial side of the crown and root. a b c d e
 5. Maxillary premolar that has the longer sharper buccal cusp. a b c d e
 6. Largest maxillary premolar. a b c d e
 7. Mandibular premolar with the longest and sharpest buccal cusp. a b c d e
 8. Maxillary premolar that is most symmetrical (occlusal view). a b c d e
 9. Two premolars without a central groove. a b c d e
 10. Crowns tipped lingually with respect to the root axis line (proximal view). a b c d e
 11. From buccal view, crown is tipped distally from the root axis. a b c d e
 12. Mesial marginal ridge is more cervically located than its distal marginal ridge. a b c d e
 13. Has no transverse ridge. a b c d e
 14. Has the longer central groove. a b c d e
 15. Has two major cusps almost the same size and length. a b c d e
 16. Has a central fossa. a b c d e
 17. Premolars with only two fossae: both are triangular fossae. a b c d e
 18. Has a central fossa and two triangular fossae. a b c d e
 19. Has a lingual groove. a b c d e

ANSWERS: 1—a; 2—c; 3—a, c; 4—a; 5—a; 6—a; 7—c; 8—b; 9—c, e; 10—c, d, e; 11—c, d, e; 12—c; 13—e; 14—a; 15—b; 16—e; 17—a, b; 18—e; 19—e

LEARNING EXERCISE



A. Name the ridges

Ridges	Name
1.	_____
2.	_____
3.	_____
4.	_____
5.	_____
6.	_____
7.	_____
8.	_____
9.	_____
10.	_____
11.	_____
12.	_____
13.	_____
14.	_____
15.	_____
16.	_____
17.	_____
18.	_____
19.	_____

B. Name the ridges

Ridges	Name
1.	_____
2.	_____
3.	_____
4.	_____
5.	_____
6.	_____
7.	_____
8.	_____
9.	_____
10.	_____
11.	_____
12.	_____
13.	_____
14.	_____
15.	_____
16.	_____
17.	_____

FIGURE 5-14.

A. List all 19 ridges that circumscribe or make up the boundary of the occlusal surface of a mandibular first molar as represented in Figure 5-14A. **B.** List all 17 ridges that circumscribe or make up the boundary of the occlusal surface of a mandibular second molar as represented in Figure 5-14B. In case you wondered, ridge 17 on the second molar is the buccal cervical ridge (sometimes evident, sometimes not).

ANSWERS: A. Mandibular first molar ridges: 1—mesial cusp ridge of mesiobuccal cusp; 2—distal cusp ridge of mesiobuccal cusp; 3—mesial cusp ridge of distobuccal cusp; 4—distal cusp ridge of distobuccal cusp; 5—mesial cusp ridge of distal cusp; 6—distal cusp ridge of distal cusp; 7—distal marginal ridge; 8—distal cusp ridge of distolingual cusp; 9—mesial cusp ridge of distolingual cusp; 10—distal cusp ridge of mesiolingual cusp; 11—mesial cusp ridge of mesiolingual cusp; 12—mesial marginal ridge; 13—triangular ridge of mesiobuccal cusp; 14—triangular ridge of distobuccal cusp; 15—triangular ridge of distal cusp; 16—triangular ridge of distolingual cusp; 17—triangular ridge of mesiolingual cusp; 18—transverse ridge (mesial); 19—transverse ridge (distal)

B. Mandibular second molar ridges: 1—mesial cusp ridge of mesiobuccal cusp; 2—distal cusp ridge of mesiobuccal cusp; 3—mesial cusp ridge of distobuccal cusp; 4—distal cusp ridge of distobuccal cusp; 5—distal marginal ridge; 6—distal cusp ridge of distolingual cusp; 7—mesial cusp ridge of distolingual cusp; 8—distal cusp ridge of mesiolingual cusp; 9—mesial cusp ridge of mesiolingual cusp; 10—mesial marginal ridge; 11—triangular ridge of mesiobuccal cusp; 12—triangular ridge of distobuccal cusp; 13—triangular ridge of distolingual cusp; 14—triangular ridge of mesiolingual cusp; 15—transverse ridge (mesial); 16—transverse ridge (distal); 17—mesial (mesiobuccal) cervical ridge

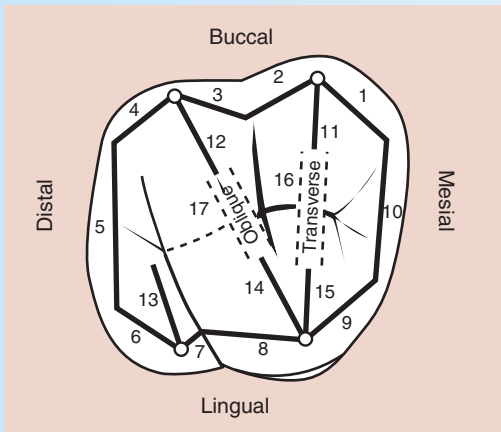
Answer the following questions about mandibular molars by circling the best answer(s). More than one answer may be correct.

- Which of the following grooves radiate out from the central fossa in a mandibular second molar?
 - Centr
 - Mesiobucc
 - Distobucc
 - Lingu
 - Bucc
- Which cusp is the largest and longest on a mandibular second molar?
 - Mesiobucc
 - Distobucc
 - Mesiolingu
 - Distolingu
 - Dist
- Which cusp may be absent on a mandibular first or third molar?
 - Mesiobucc
 - Distobucc
 - Mesiolingu
 - Distolingu
 - Dist
- When this cusp is absent in question No. 3 above, which groove(s) would not be present?
 - Bucc
 - Lingu
 - Mesiobucc
 - Distobucc
 - Lingu
- Which fossae are found on a mandibular first molar?
 - Mesia triangular
 - Dista triangular
 - Bucc
 - Lingu
 - Centr
- Which developmental groove connects with the lingual groove running in the same direction on a mandibular second molar?
 - Mesiobucc
 - Distobucc
 - Bucc
 - Mesiolingu
 - Distolingu
- From which view is only one root visible on a mandibular first molar?
 - Mesi
 - Dist
 - Bucc
 - Lingu
 - Apic
- Which root may occasionally be divided or bifurcated on a mandibular first molar?
 - Bucc
 - Lingu
 - Mesi
 - Dist
 - Mesiobucc
- Which cusp triangular ridge does not meet to form a transverse ridge on a five-cusp first molar?
 - Mesiobucc
 - Distobucc
 - Mesiolingu
 - Distolingu
 - Dist
- Which ridges form the boundaries of the mesial triangular fossa of a mandibular molar?
 - Triangular ridge of mesiobuccal cusp
 - Triangular ridge of mesiolingual cusp
 - Mesial marginal ridge
 - Buccal cusp ridge of mesiobuccal cusp
 - Lingual cusp ridge of mesiolingual cusp
- Which two pairs of cusp triangular ridges make up or join to form the two transverse ridges on a mandibular second molar?
- List in sequential order the longest to shortest cusps on the mandibular first molar.

ANSWERS: 1—a, d, e; 2—c; 3—e; 4—c, d; 5—a, b, e; 6—c; 7—a; 8—c; 9—e; 10—a, b, c; 11—mesiobuccal and mesiolingual PLUS distobuccal and distolingu, 12—mesiolingual, distolingu, mesiobuccal, distobuccal, then distal

LEARNING EXERCISE

Name each of the 17 ridges in *Figure 5-29*.



Name the ridges

Ridges	Ridges
1. _____	10. _____
2. _____	11. _____
3. _____	12. _____
4. _____	13. _____
5. _____	14. _____
6. _____	15. _____
7. _____	16. _____
8. _____	17. _____
9. _____	

FIGURE 5-29.

Maxillary molar (circles denote cusp tips and lines denote ridges). Write the names of each of the 17 ridges next to the number corresponding to its location. Answers follow.

ANSWERS: Maxillary molar ridges: 1—mesial cusp ridge of mesiobuccal cusp; 2—distal cusp ridge of mesiobuccal cusp; 3—mesial cusp ridge of distobuccal cusp; 4—distal cusp ridge of distobuccal cusp; 5—distal marginal ridge; 6—distal cusp ridge of distolingual cusp; 7—mesial cusp ridge of distolingual cusp; 8—distal cusp ridge of mesiolingual cusp; 9—mesial cusp ridge of mesiolingual cusp; 10—mesial marginal ridge; 11—triangular ridge of mesiobuccal cusp; 12—triangular ridge of distobuccal cusp; 13—triangular ridge of distolingual cusp; 14—distal cusp ridge (or triangular ridge) of mesiolingual cusp; 15—(mesial) triangular ridge of mesiolingual cusp; 16—transverse ridge; 17—oblique ridge.

LEARNING EXERCISE

Match the tooth with the correct geometric shape for its occlusal outline.

- Trapezoid (tapered rectangle)
 - Parallelogram (rhomboid)
 - Heart shaped or triangular
 - Pentagon
- Maxillary first molar
 - Maxillary second molar (four-cusp type)
 - Maxillary second molar (three-cusp type)
 - Mandibular first molar
 - Mandibular second molar

ANSWERS: 1—b, 2—b, 3—c, 4—d, 5—a

Review Questions

Maxillary molars

Circle the correct answer(s) that apply. More than one answer may be correct.

- Which three grooves radiate out from the central fossa in a maxillary first molar?
 - Central
 - Distolingual
 - Transverse groove of oblique ridge (when present)
 - Buccal
 - Lingual
- Which cusp on a maxillary first molar has two ridges: one that forms part of a transverse ridge and the other that forms part of an oblique ridge?
 - Mesiobuccal
 - Mesiolingual
 - Distobuccal
 - Distolingual
 - Cusp of Carabelli
- Which cusp is the largest and longest on a maxillary second molar?
 - Mesiobuccal
 - Mesiolingual
 - Distobuccal
 - Distolingual
 - Cusp of Carabelli
- Which cusp is most likely to be absent on a maxillary second molar?
 - Mesiobuccal
 - Mesiolingual
 - Distobuccal
 - Distolingual
 - Distal
- When the cusp is absent in question 4 above, which groove(s) would not be present?
 - Central
 - Buccal
 - Distal oblique
 - Lingual
- Of the four fossae on a maxillary first molar, which is the largest?
 - Mesial triangular
 - Distal triangular
 - Central
 - Distal
- From which view are only two roots visible on a maxillary first molar?
 - Mesial
 - Distal
 - Buccal
 - Lingual
- Which grooves are likely to radiate out of the mesial triangular fossa on the maxillary first molar?
 - Mesiobuccal fossa groove
 - Mesiolingual fossa groove
 - Mesial marginal ridge groove (when present)
 - Central
 - Buccal
- Which two cusps have the ridges that make up or join to form the oblique ridge on a maxillary molar?
 - Mesiobuccal
 - Distobuccal
 - Mesiolingual
 - Distolingual
 - Cusp of Carabelli
- Which two cusps have a triangular ridge that make up or join to form a transverse (not oblique) ridge on most maxillary molars?
 - Mesiobuccal
 - Distobuccal
 - Mesiolingual
 - Distolingual
 - Cusp of Carabelli
- List in sequential order the largest to smallest cusp area on the maxillary first molar (occlusal view).

ANSWERS: 1—a, c, d; 2—b; 3—b; 4—d; 5—c, d; 6—c; 7—a; 8—a, b, c, d; 9—b, c; 10—a, c; 11—mesiolingual, (mesiobuccal, distobuccal, distolingual, cusp of Carabelli (if even present

Review Questions

Circle the correct answer(s). More than one answer may be correct. Unless otherwise stated, teeth are identified using the Universal Identification System.

- Which primary teeth have crowns that are wider mesiodistally than they are long incisio- or occluso-cervically?
 - Maxillary central incisor
 - Maxillary first molar
 - Mandibular lateral incisor
 - Mandibular first molar
 - Mandibular canine
- Which one tooth is adjacent and distal to the primary maxillary second molar in a 7-year-old?
 - Maxillary first premolar
 - Maxillary second premolar
 - Secondary maxillary first molar
 - Secondary maxillary second molar
 - Primary maxillary first molar
- How many teeth should be visible in the mouth of a 3-year-old?
 - None
 - 10
 - 20
 - 24
 - 28
- How many teeth should be present in the mouth of a 13-year-old?
 - 10
 - 20
 - 24
 - 28
 - 32
- Which primary molar most resembles a secondary maxillary right first molar?
 - Tooth A
 - Tooth E
 - Tooth F
 - Tooth T
 - Tooth B
- What would you estimate to be the dental age of a child with the following teeth: all primary maxillary incisors, canines, and molars; secondary mandibular incisors and first molars.
 - 2 to 4 years
 - 5 to 7 years
 - 8 to 9 years
 - 10 to 11 years
 - Over 12 years
- Which teeth (primary or secondary) have the mesial proximal contact positioned more cervically than the distal proximal contact?
 - Mandibular first premolar
 - Maxillary first premolar
 - Primary maxillary canine
 - Primary mandibular canine
 - Mandibular second premolar
- Which teeth (secondary or primary) have the mesial cusp ridge of the facial cusp longer than the distal cusp ridge of the facial cusp?
 - Mandibular first premolar
 - Maxillary first premolar
 - Primary maxillary canine
 - Primary mandibular canine
 - Mandibular second premolar
- Which succedaneous tooth erupts beneath tooth J?
 - No. 1
 - No. 5
 - No. 10
 - No. 13
 - No. 16
- Which of the following traits can be used to differentiate primary teeth from secondary teeth?
 - Primary teeth have greater facial cervical bulges.
 - Primary teeth have relatively thinner and longer roots.
 - Primary teeth are whiter.
 - Primary anterior teeth are larger than their successors.
 - Primary teeth have relatively larger pulps.
- Which of the following secondary teeth would you expect to be erupted in the average 9- to 10-year-old?
 - Maxillary lateral incisor
 - Maxillary central incisor
 - Mandibular canine
 - Maxillary canine
 - Mandibular second molar
- Which traits apply to a primary mandibular first molar?
 - Its roots are resorbed by the eruption of the 6-year mandibular first molar.
 - It resembles a mandibular 6-year first molar.
 - It has a prominent buccal cervical bulge.
 - It has a prominent mesial marginal ridge.
 - It has a prominent transverse ridge.
 - It has an occlusal table larger in the mesial half than in the distal half.

ANSWERS: 1—a, b, d; 2—c; 3—c; 4—d; 5—a; 6—b; 7—a, c; 8—b, c; 9—d; 10—a, b, c, e; 11—a, b, c; 12—c, d, e