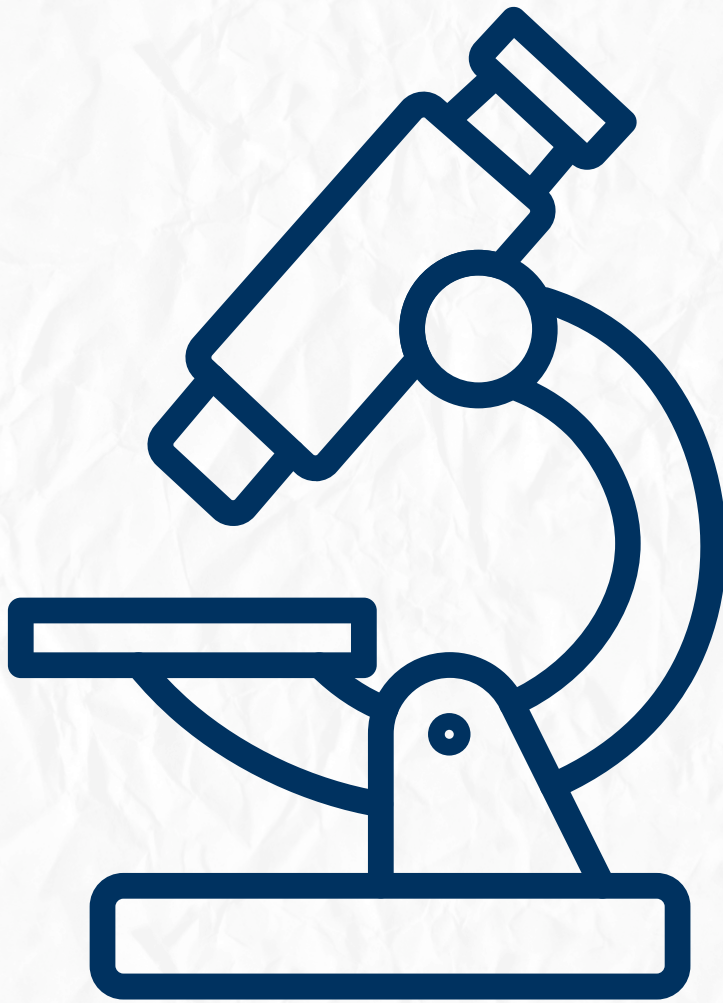


Oral Histology

Quiz time



Physiological tooth movement

Done by : Lujain Hamdan

Q1: While examining a histological section of the alveolar bone proper, you notice it appears radiographically as a dense white line. However, the histologist refers to it as "Cribriform Plate." What is the anatomical reason for this name?

- A) Because it consists mainly of cancellous bone.
- B) Due to the presence of numerous "Volkmann's canals" for the passage of blood vessels and nerves.
- C) Because it contains a high concentration of Sharpey's fibers.
- D) Due to the absence of osteocytes within its matrix.

Answer:- B

Q2: A patient undergoes orthodontic treatment to move a malaligned tooth. On the "Pressure Side" of the movement, which cell type will be predominantly active in the Periodontal Ligament (PDL) space?

- A) Osteoblasts
- B) Cementoblasts
- C) Osteoclasts
- D) Fibrocytes

Answer:- C

Q3: Which type of cementum is the first to be formed, covers the cervical two-thirds of the root, and contains no trapped cells within its matrix?

- A) Cellular, Mixed Stratified Cementum
- B) Acellular, Primary Cementum
- C) Cellular, Secondary Cementum
- D) A fibrillar Cementum

Answer:- B

Q4: In the "Bundle Bone," what is the specific nature of the fibers that are embedded into the bone matrix to provide tooth anchorage?

- A) Elastic fibers from the gingiva.
- B) Non-collagenous proteins from the pulp.
- C) Sharpey's fibers from the Periodontal Ligament.
- D) Reticular fibers from the bone marrow.

Answer:- C

Q5: A histological slide shows multinucleated giant cells in contact with the cementum surface. These cells are resorbing the root structure. What are they called?

- A) Osteoclasts
- B) Odontoclasts
- C) Cementocytes
- D) Macrophages

Answer:- B

Q6: What is the most common relationship at the Cementodentinal Junction (CEJ) as mentioned in the "CEJ Relation" table?

- A) Cementum and enamel meet edge-to-edge (30%).
- B) Cementum overlaps enamel (60%).
- C) A gap exists between cementum and enamel (10%).
- D) Enamel overlaps cementum (5%).

Answer:- B

Q7: "Bundle Bone" is specifically that part of the alveolar bone proper that is constantly being remodeled. Why is it called "Bundle" bone histologically?

- A) Because it bundles the nerves of the tooth.
- B) Due to the high density of collagen fiber bundles (Sharpey's fibers) embedded in it.
- C) Because it contains bundles of cancellous trabeculae.
- D) It is a clinical term for the cortical plate.

Answer:- B

Q8: During the "Tension" phase of orthodontic tooth movement, what happens to the alveolar bone?

- A) Resorption occurs by osteoclasts.
- B) Apposition (formation) of new bone occurs by osteoblasts.
- C) The bone becomes more porous (cribriform).
- D) Hyaline degeneration of the bone matrix.

Answer:- B

Q9: Cementocytes are found in "secondary" cementum. Where are these cells specifically located within the cementum structure?

- A) On the surface facing the PDL.
- B) Trapped within lacunae inside the calcified matrix.
- C) Within the Volkmann's canals.
- D) In the Howship's lacunae.

Answer:- B

Q10: Which part of the alveolar process consists of trabecular bone and fills the area between the cortical plates and the alveolar bone proper?

- A) Lamina dura
- B) Spongy (Cancellous) bone
- C) Bundle bone
- D) Cortical plate

Answer:- B