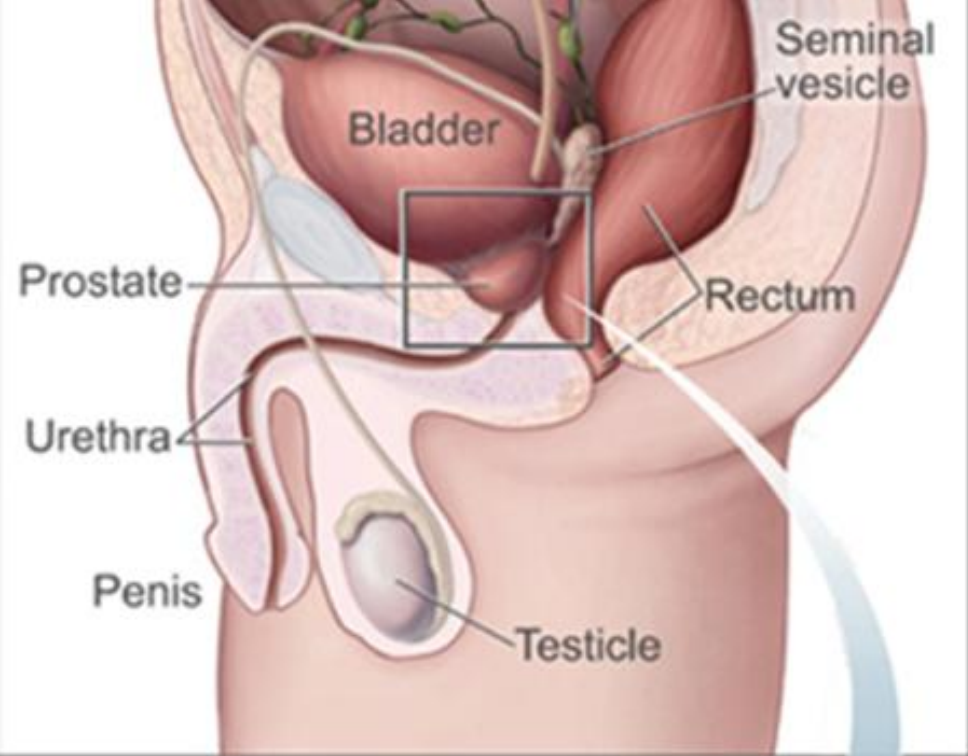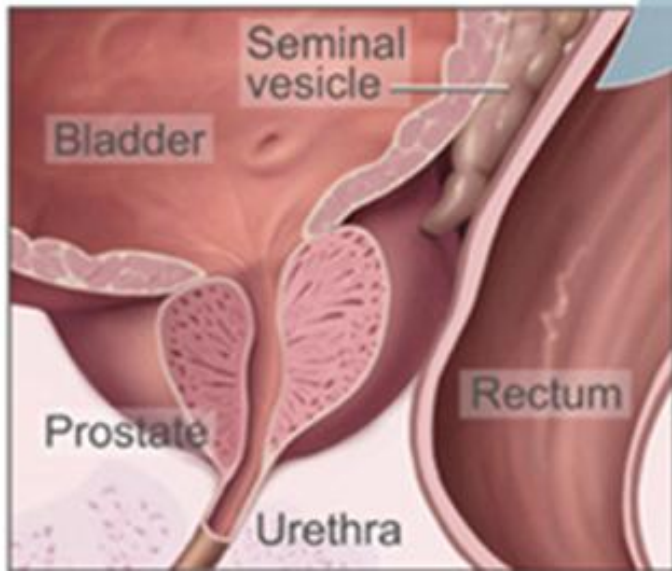


This shows the prostate and nearby organs.



# MALE GENITAL SYSTEM, LECTURE 2 TESTICLE

” قوي التوكل لا يهزم  
وملح الدعاء لا يخذل ”

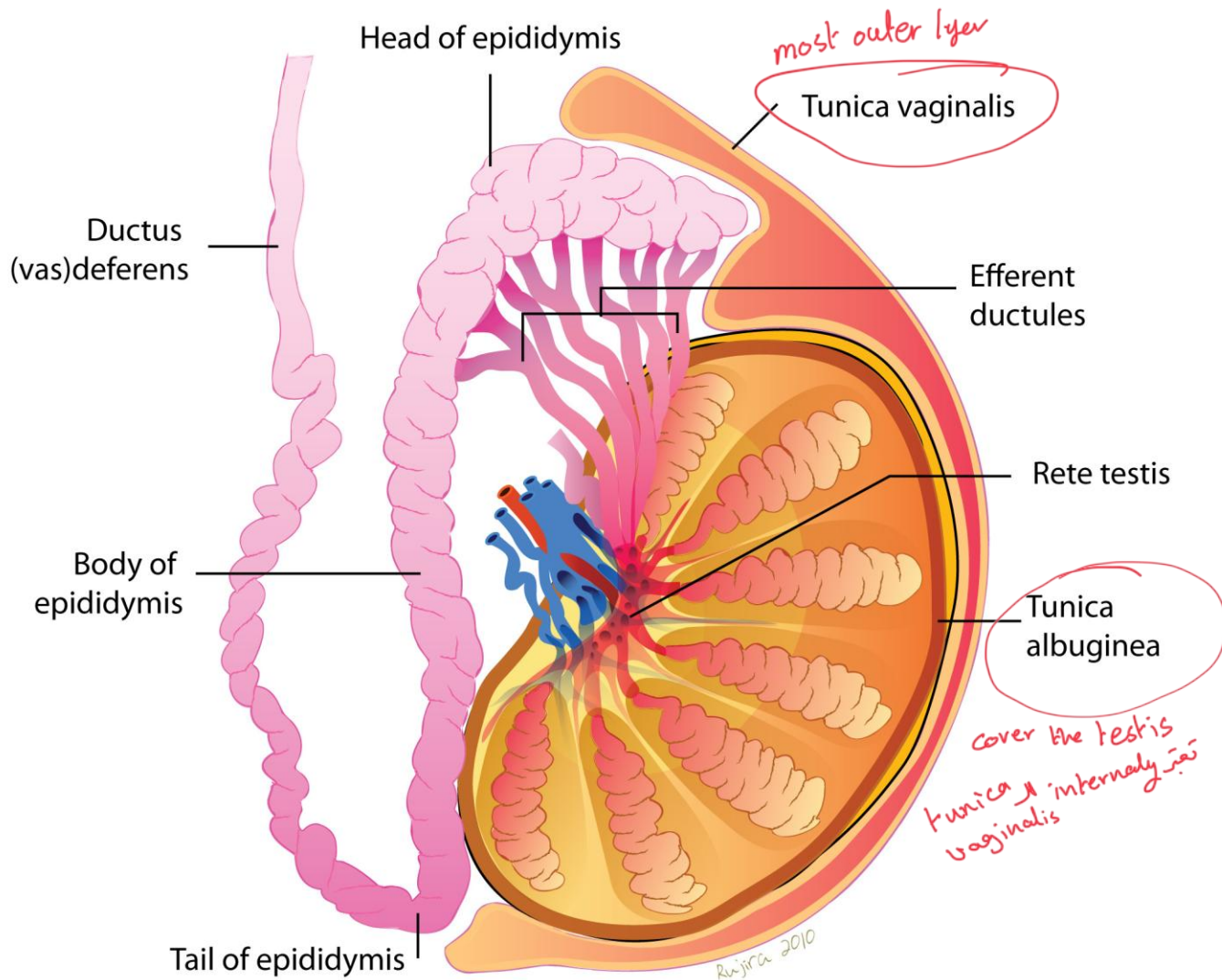
DR. BUSHRA AL-TARAWNEH, MD

ANATOMICAL PATHOLOGIST-GYNECOLOGIC AND BREAST A

DEPARTMENT OF MICROBIOLOGY & PATHOLOGY

MUTAH UNIVERSITY SCHOOL OF MEDICINE

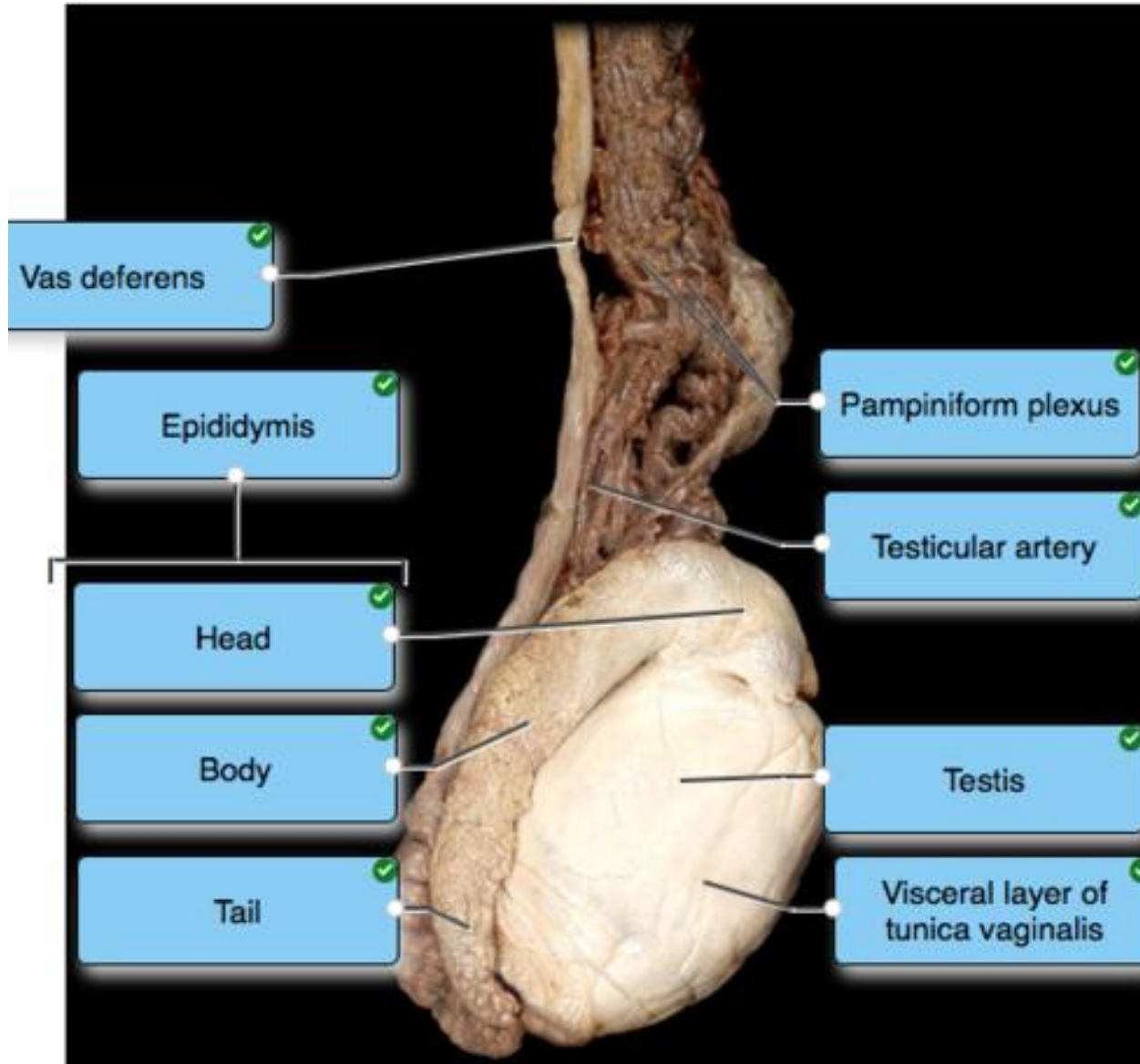
UGS LECTURES 2026



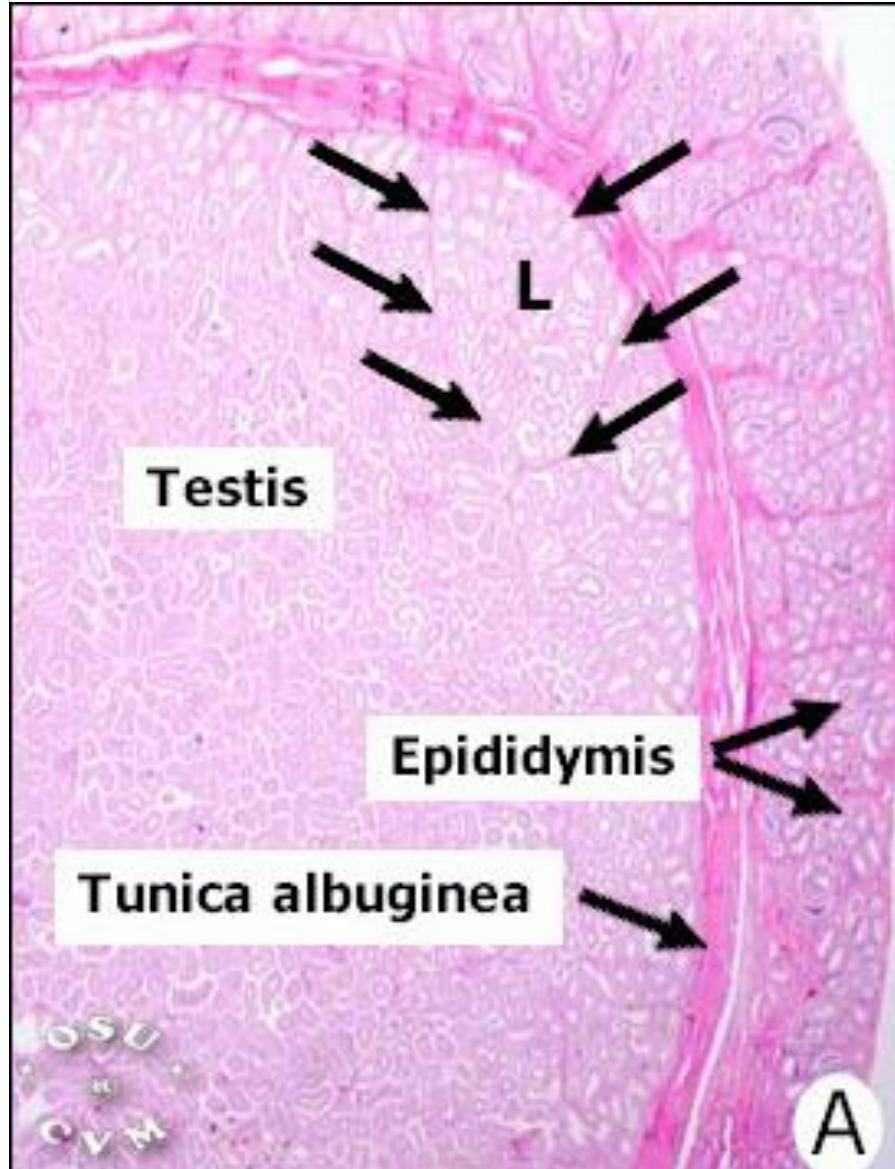
good prognosis ← testis فان اى كى ال  
 tunica منة الى ال

# Testis..anatomy.

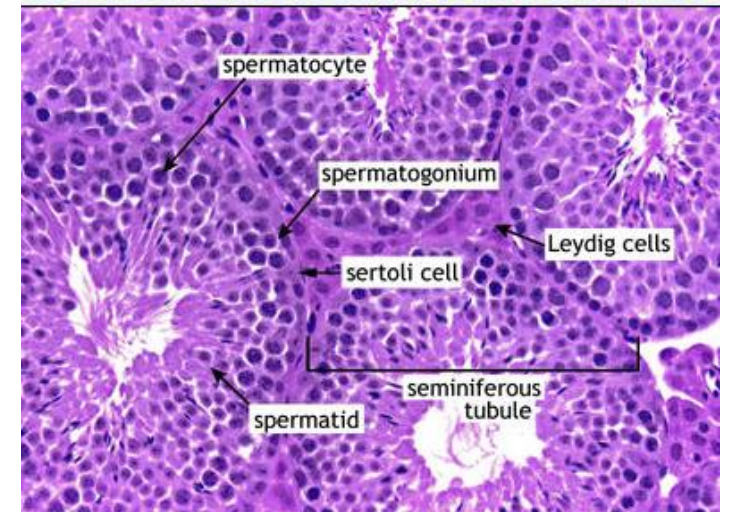
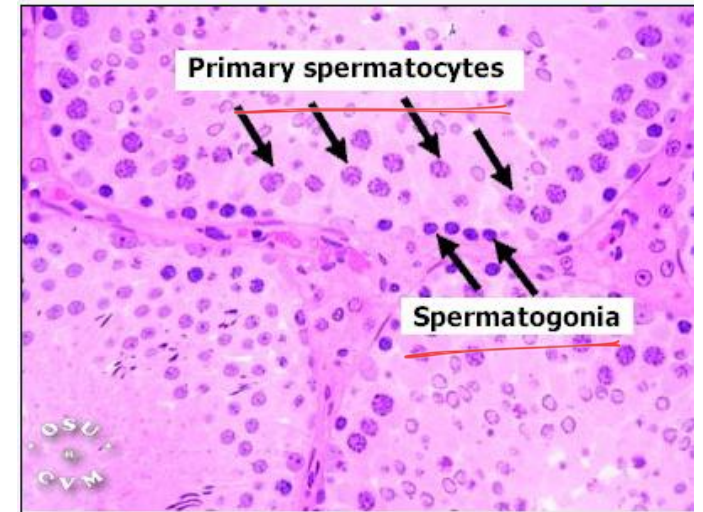
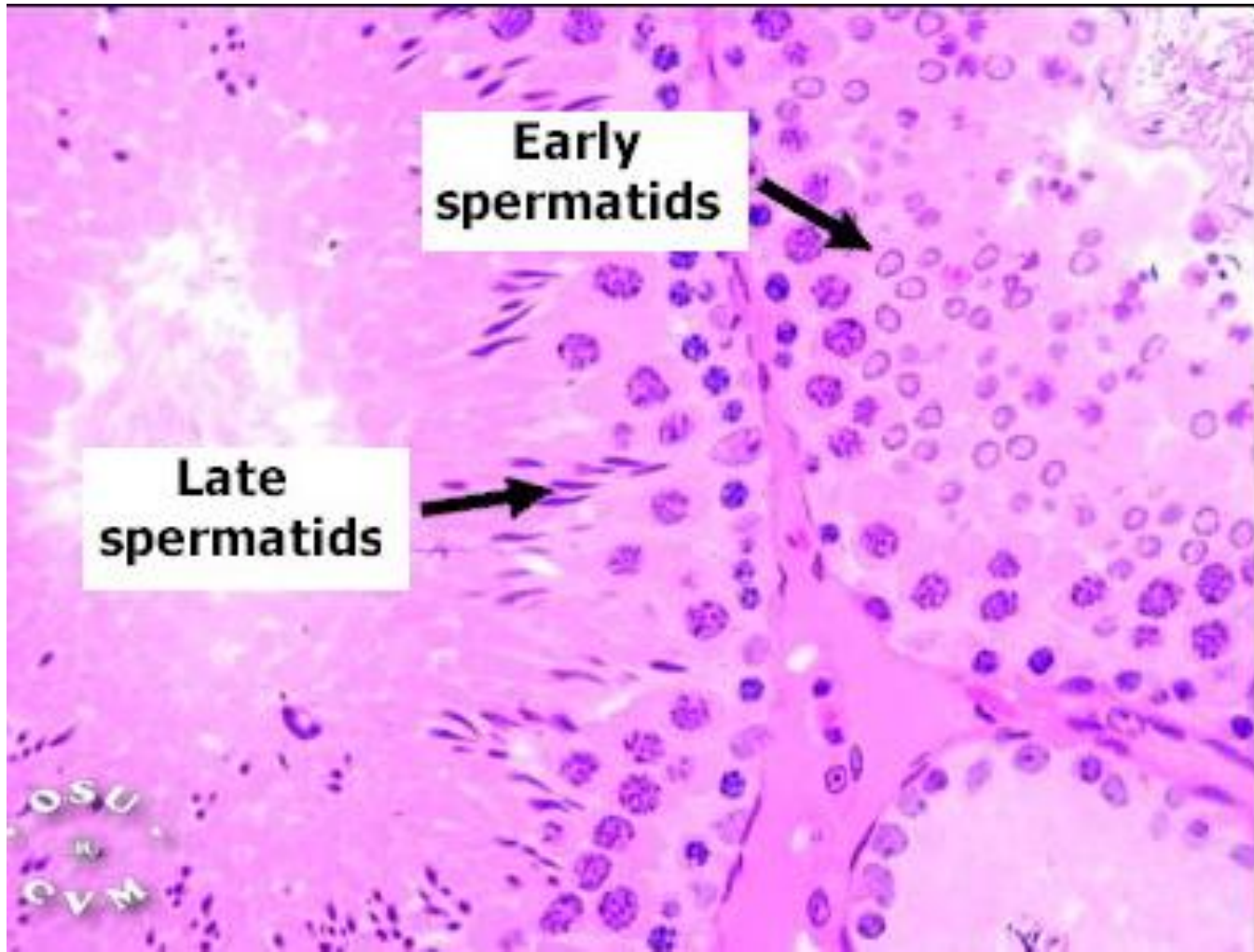
any testicular cancer lead to adherent of tunica vaginalis and tunica albuginea → stages ال upgrading ال of the tumor



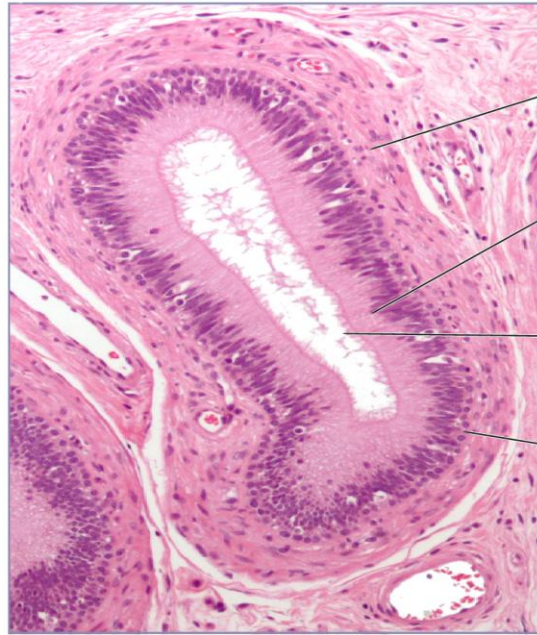Grossly



Testis..histology



## Epididymis



Smooth muscle

Columnar cells

Stereocilia

Basal cells

Fallopian tube  
بيجہ ال

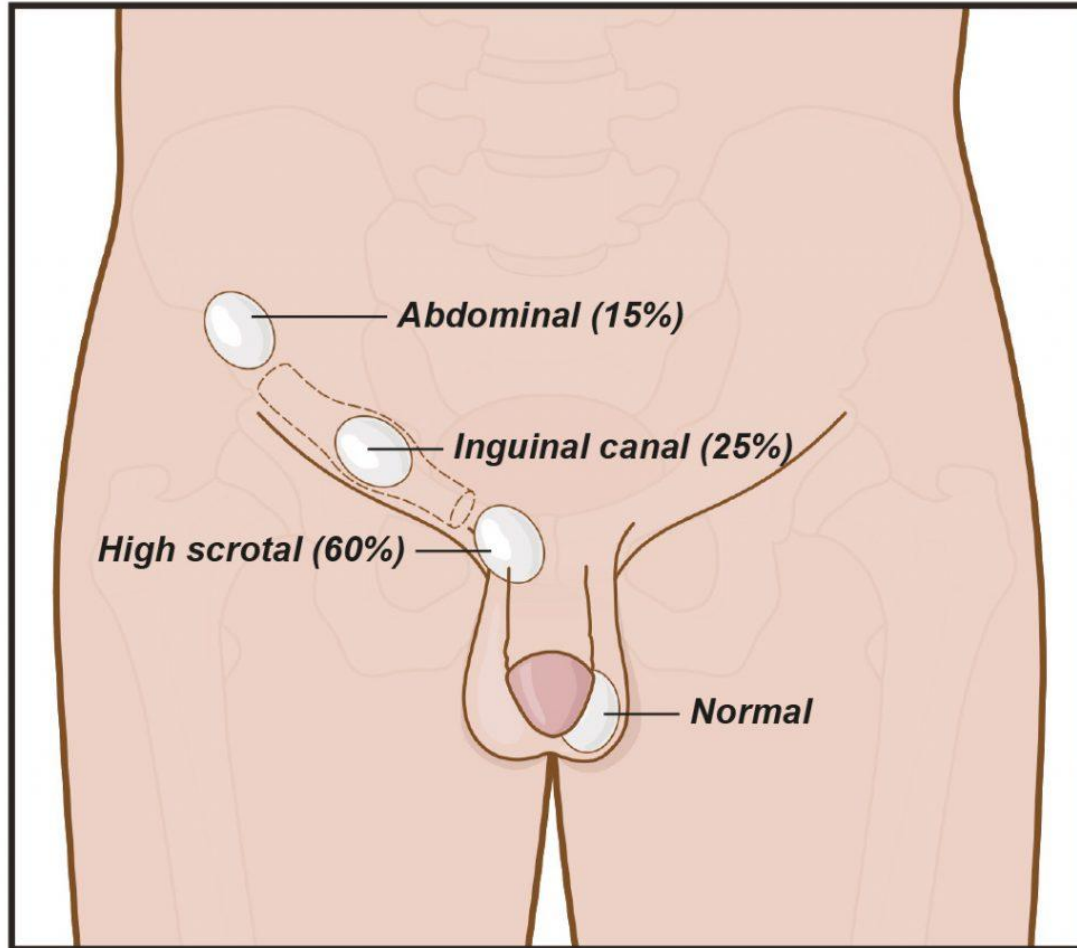
Epididymis  
..histology.

# Testicular disorders

Cryptorchidism.

Vascular Disturbances.

Neoplasms.



©2017 patients.uroweb ALL RIGHTS RESERVED

# 1. Cryptorchidism

It is a failure of testicular descent into the scrotum.

Normally, the testes descend from the abdominal cavity into the pelvis (3rd month of gestation) → then through the inguinal canals into the scrotum (last 2 months of intrauterine life).

# Cryptorchidism

Cryptorchidism affects 1% of the male population.

Mostly the cause is unknown.

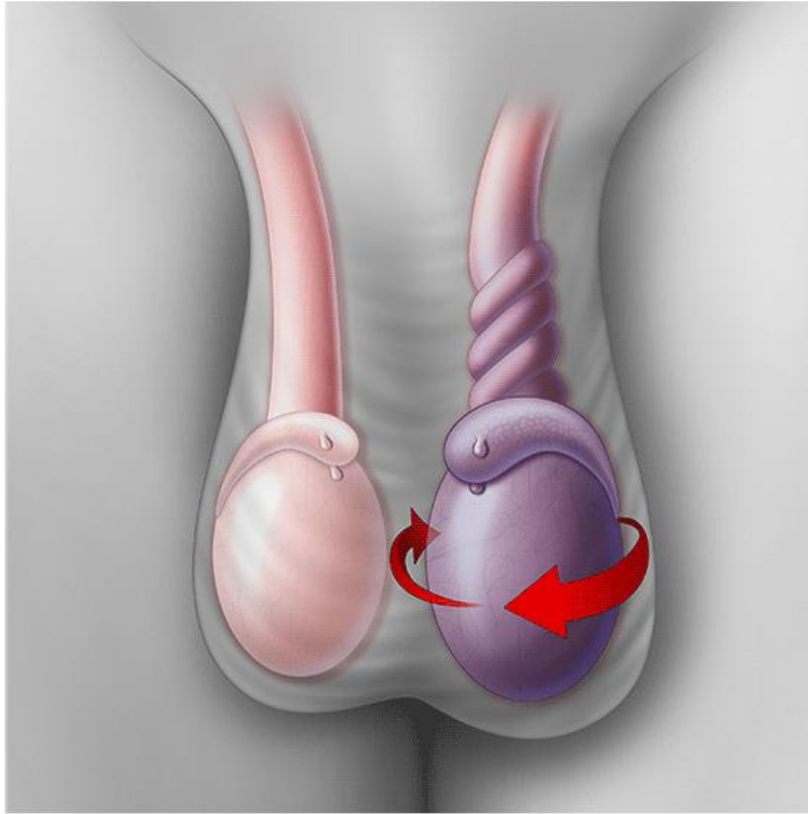
Bilateral in ~ 10% of affected patients

*cause is unknown*

Undescended testes may become atrophic → if bilateral → sterility.

Ass with a 3-5 fold increased risk for testicular cancer → in **both** testes, (including normally descended testis) suggesting that some intrinsic abnormality)

## Torsion



© 2014 The Children's Hospital of Philadelphia

## 2. Vascular Disturbances. Torsion

Torsion or twisting of the spermatic cord <sup>with vascularity</sup> → <sup>and testis</sup> results in obstruction of testicular venous drainage (thick-walled & more resilient arteries are left patent)

Leads to intense vascular engorgement & infarction if not relieved.

sever scrotal pain <sup>ألم شديداً (16-17) في الخصية</sup> ← emergency case  
on one side with  
nausea and vomiting

↓  
preserve testis ← <sup>حضانة 6 ساعات كحد أقصى</sup>  
and available up  
to 6 hours

# Types

Two types:

## Neonatal torsion :

- occurs in utero or shortly after birth. No associated anatomic defect is present.

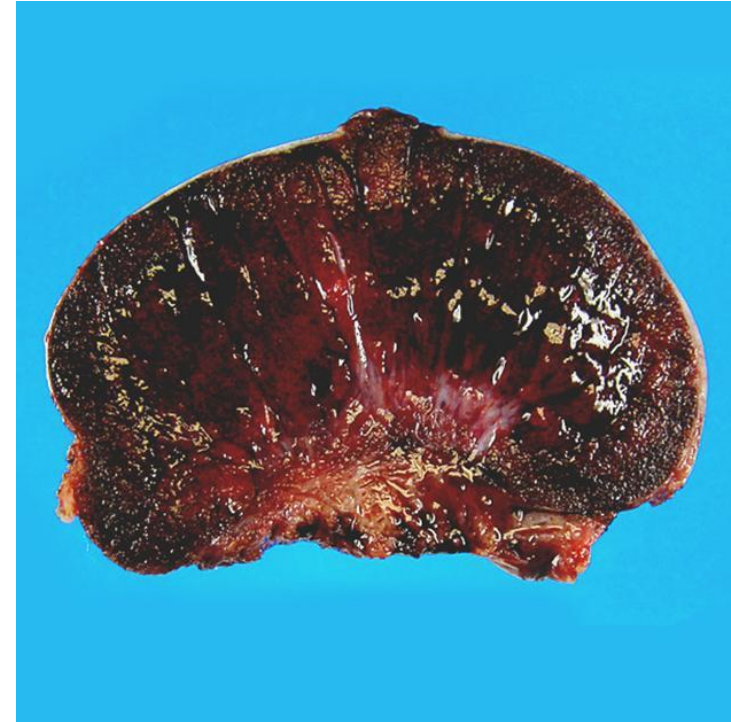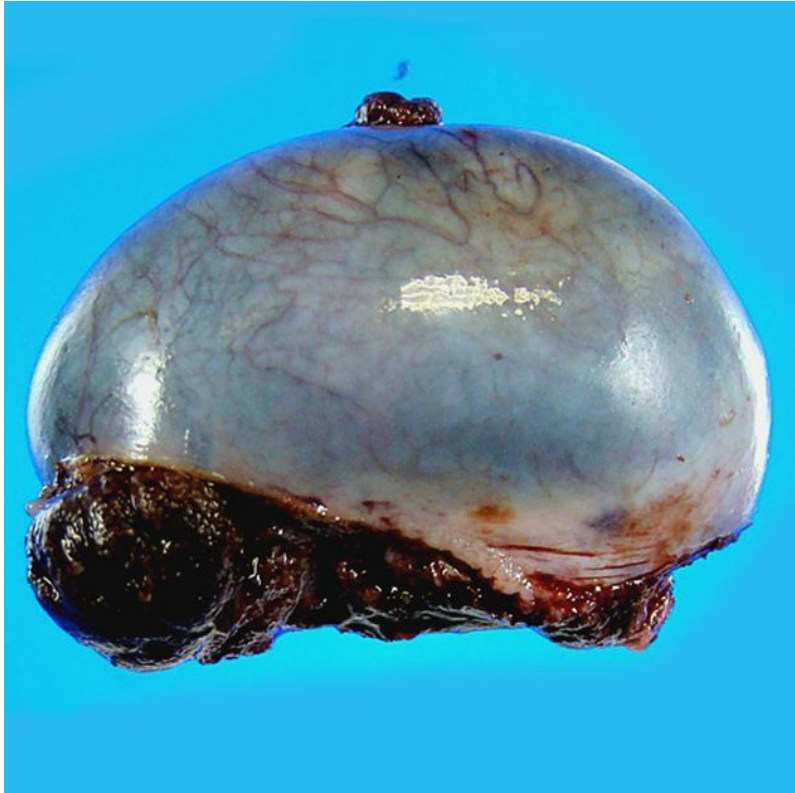## Adult torsion.

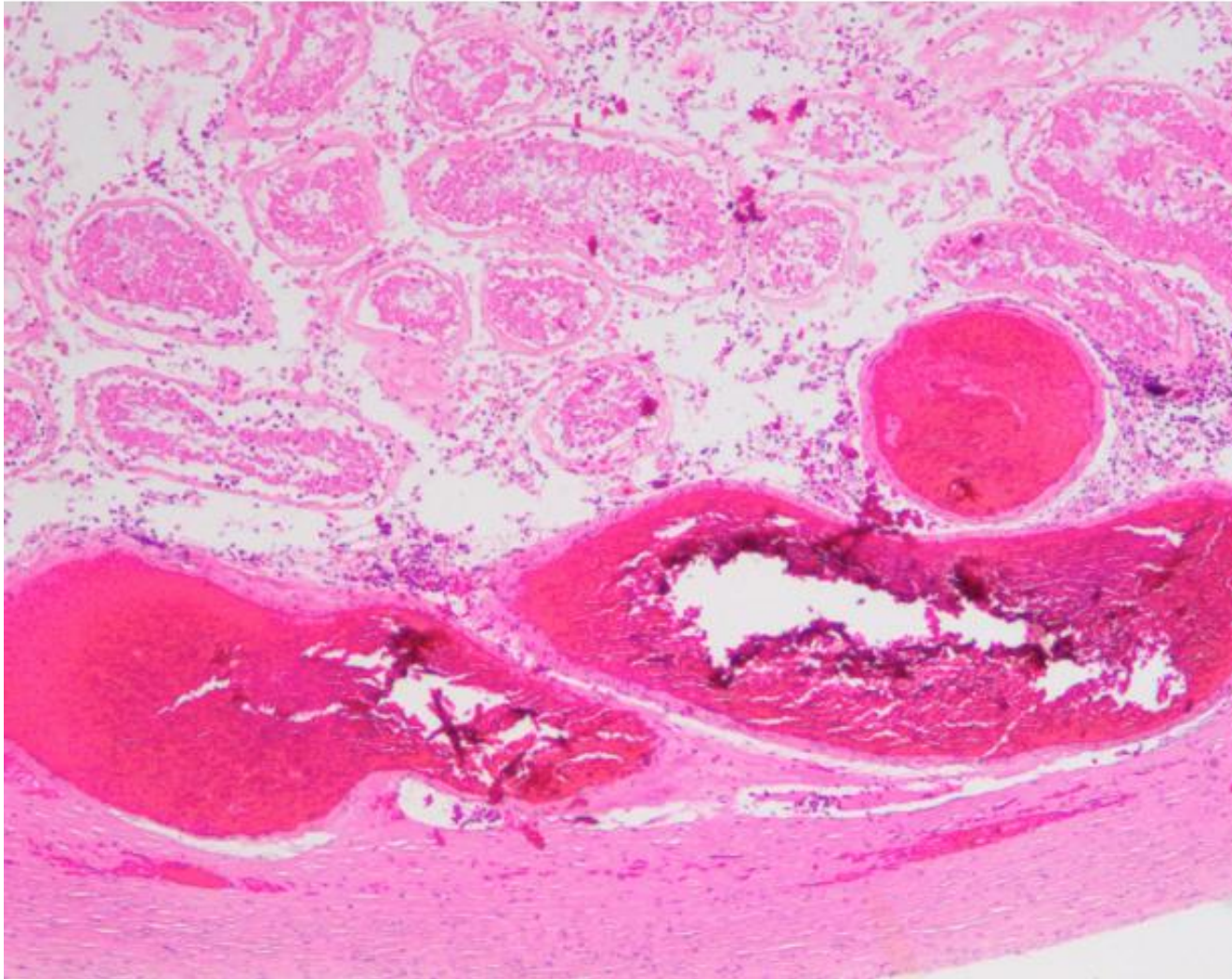
Surgical emergency due to twisting of the testicle around the spermatic cord or vascular pedicle attachments .

Mostly under 18 years old.

Usually patient presented with Unilateral scrotal pain, nausea and vomiting

# Testicular torsion





# Microscopic

DAMAGED BLOOD VESSELS WITH  
COAGULATIVE NECROSIS

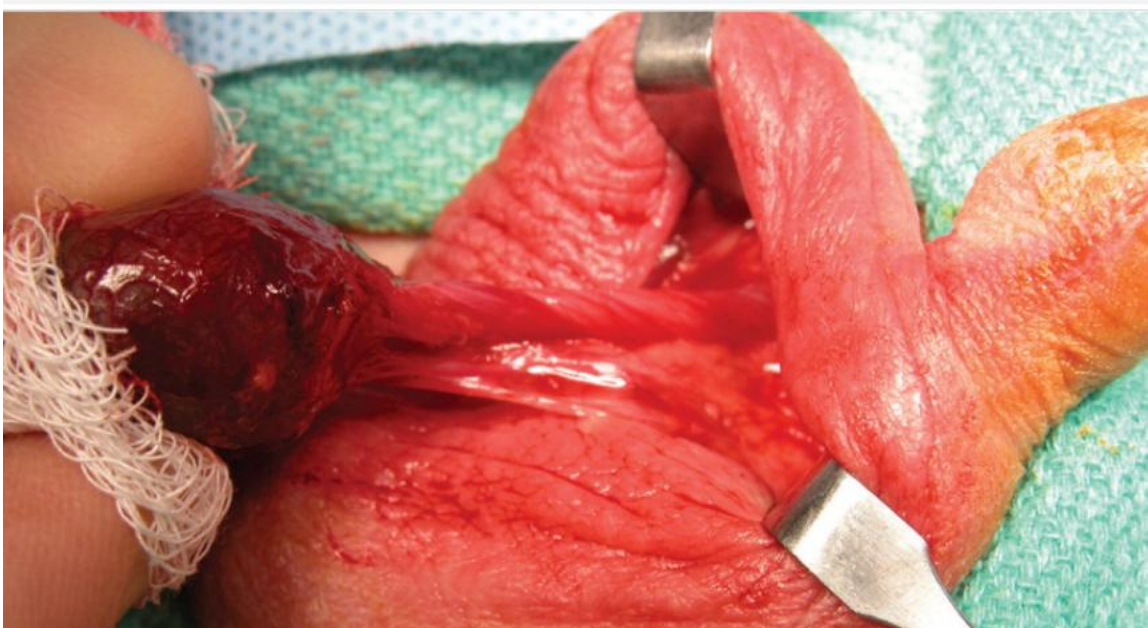
Orchiectomy

## Treatment

---

If explored surgically & the cord is manually untwisted within ~ 6 hours, the testis will likely remain viable.

To prevent the catastrophic occurrence of another torsion in contralateral testis, unaffected testis is surgically fixed within the scrotum (orchiopexy).



### 3. Neoplasms

In the 15-34-year-old age group, they are the most common tumors in men (peak in incidence).

Heterogeneous groups include:

- ✓ Germ cell tumors: 95%, all are malignant.
- ✓ Sex cord–stromal tumors: uncommon, usually benign, & derived from Sertoli or Leydig cells.

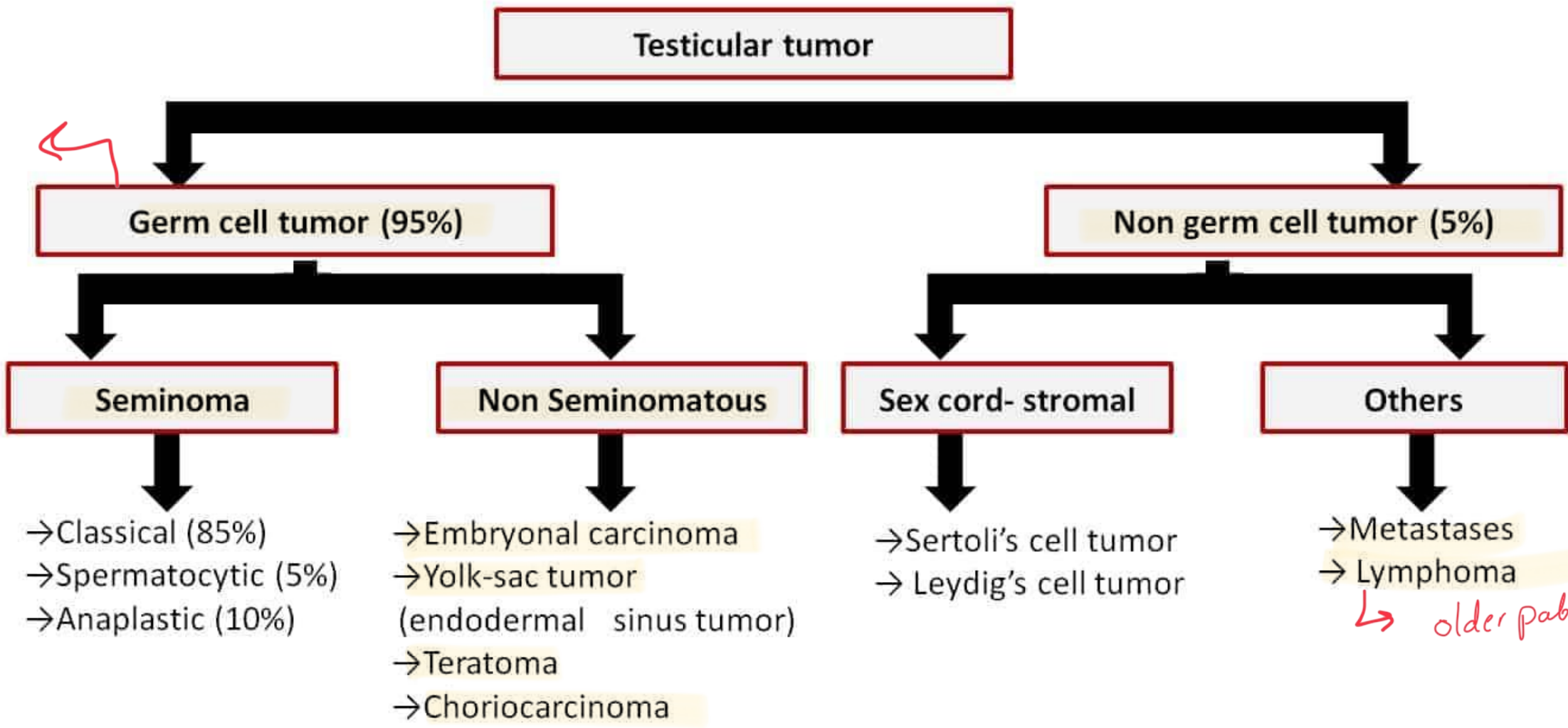
The cause of testicular neoplasms is poorly understood.

# Risk factors

---

- The isochromosome of the short arm of chromosome 12 - (i12p)
- Undescended testicle
- Family history
- Carcinoma in situ
- Cancer in the other testicle
- Age
- Race and ethnicity

*Young patient*



*↳ older patient*

# Clinical features

Presentation: mostly as a painless testicular mass. #

Biopsy of a testicular neoplasm is associated with a risk of tumor spillage (contraindicated).

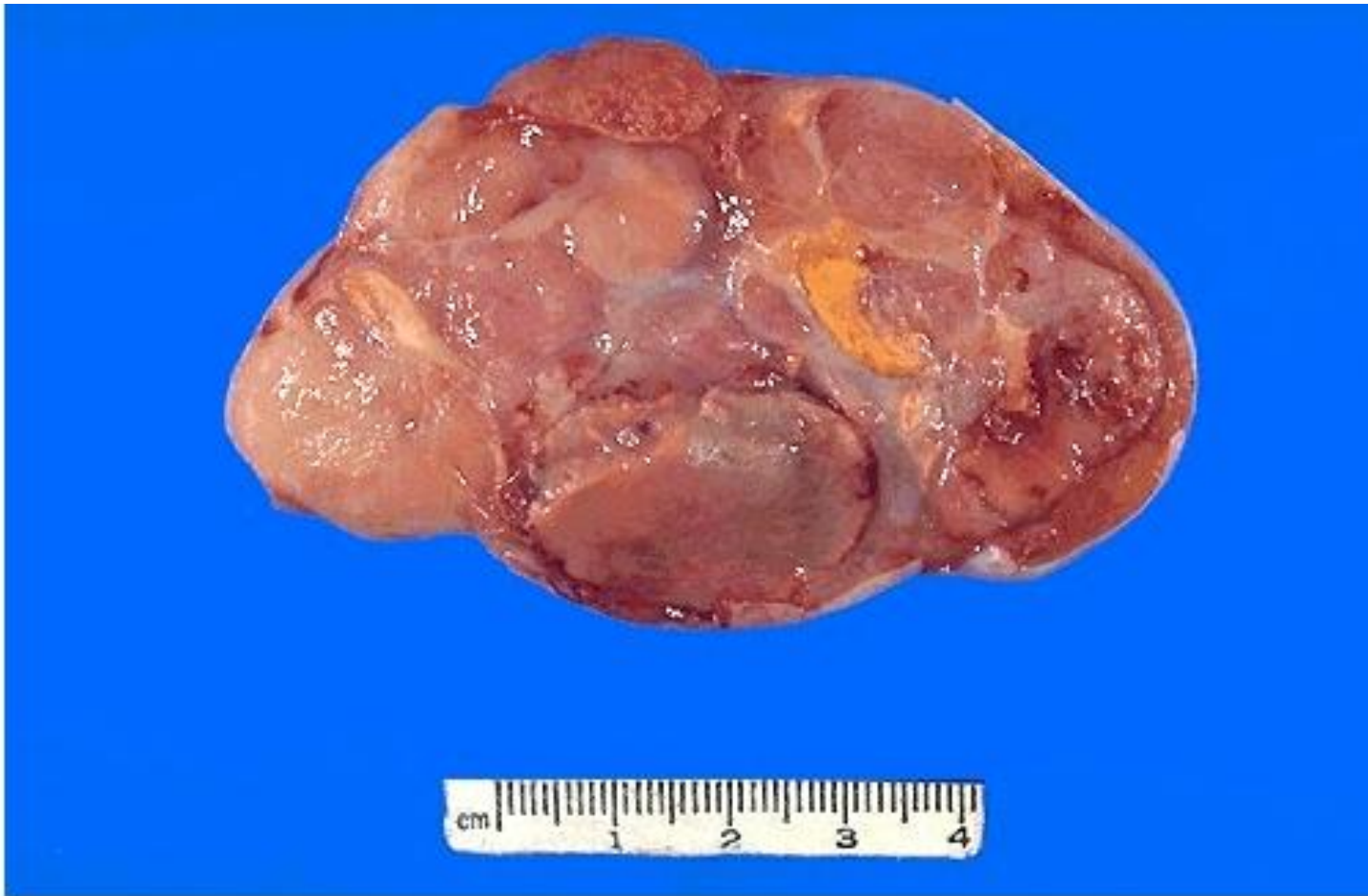Standard management of a solid testicular mass is radical orchiectomy, based on the presumption of malignancy.

# 1. Seminoma

Third decade of life – never in infants.

Histologically identical tumors called dysgerminomas , in the ovary, and germinomas , CNS & other extragonadal sites. #

Presentation: progressive painless enlargement of the testis.

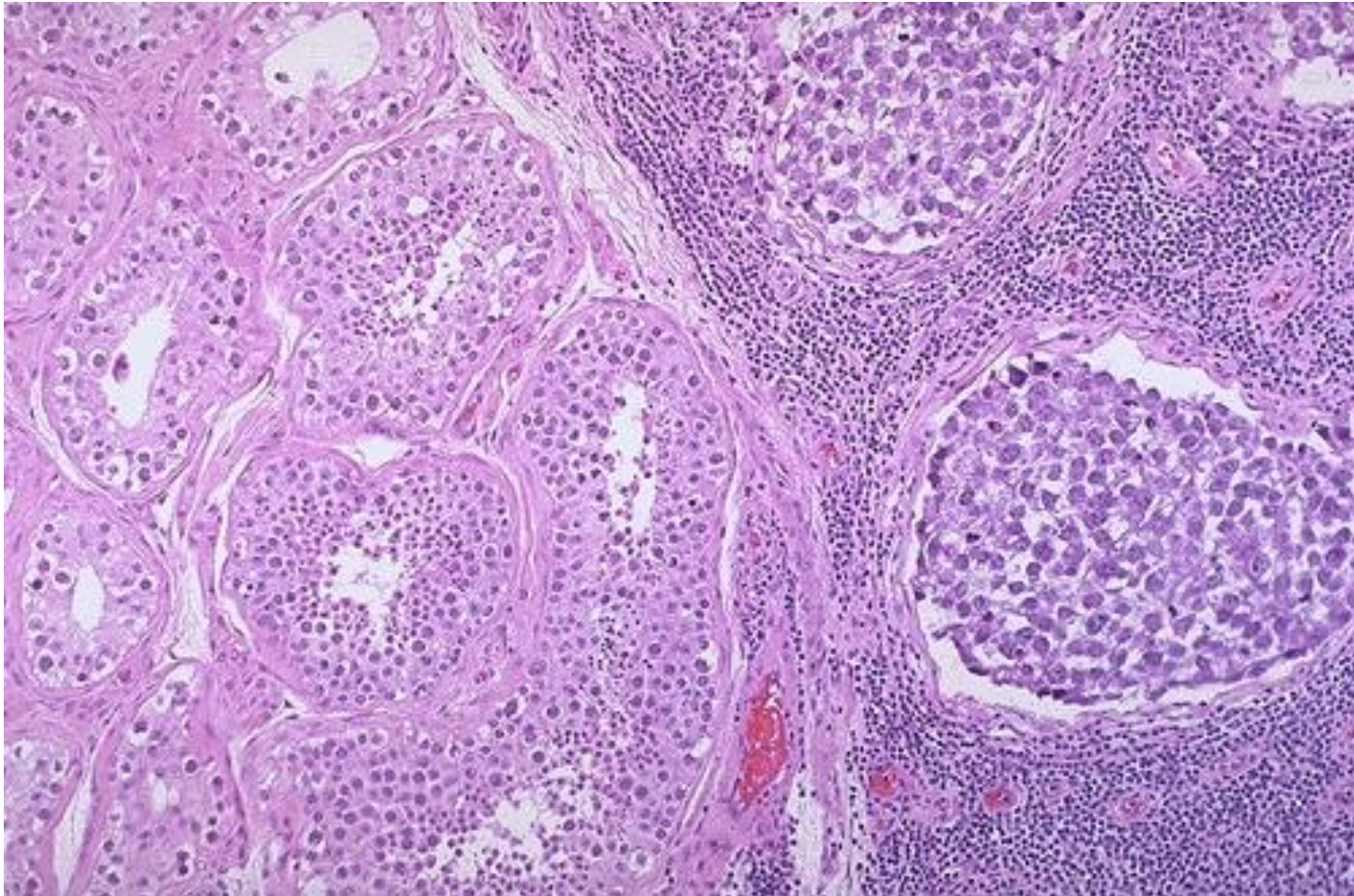


# morphology

---

**Gross:** soft, well-demarcated gray-white, usually w/o hemorrhage

هناك إلى بهم



# Microscopic

- Large, uniform cells with clear, glycogen-rich cytoplasm, round nuclei, and conspicuous nucleoli. *nest cells*
- Intervening fibrous septa with dense lymphocytic infiltrate.
- Granulomatous reaction & syncytiotrophoblasts (15%).

## 2. Embryonal carcinoma

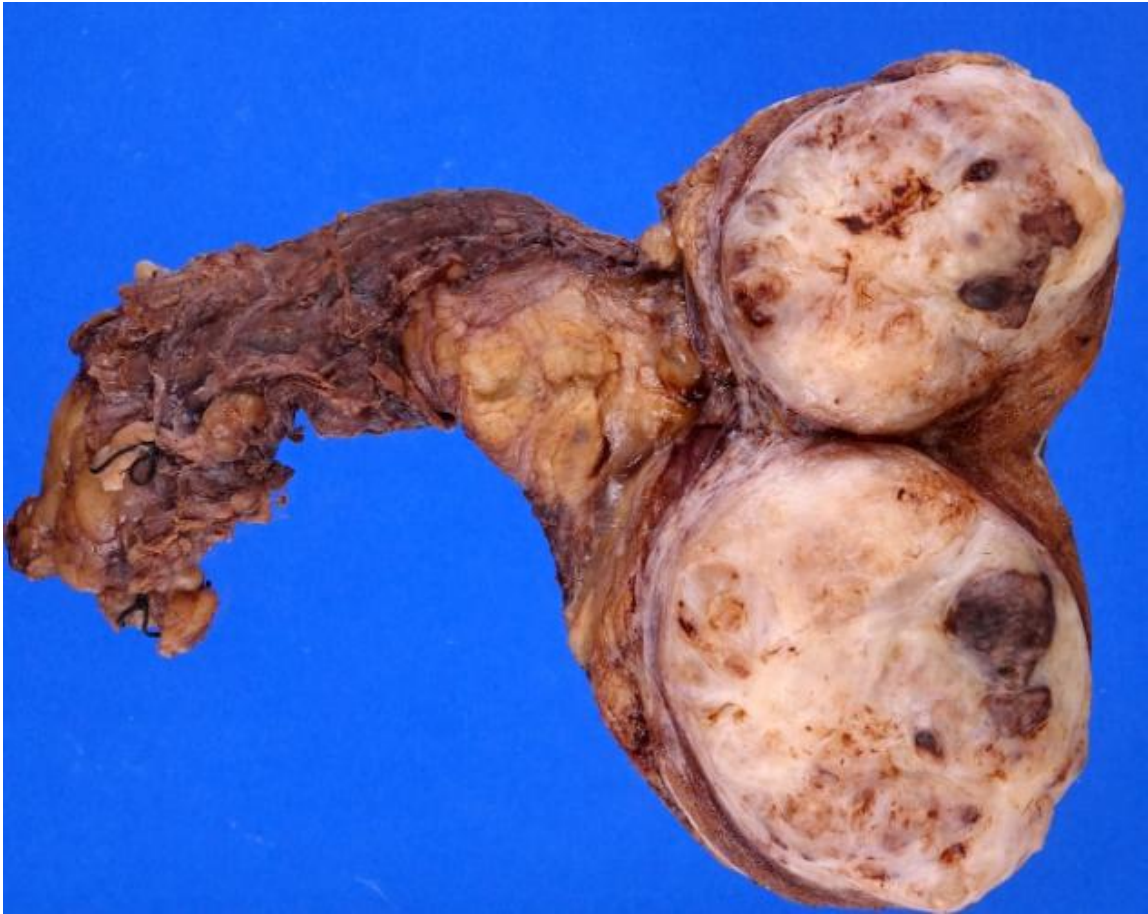---

Malignant germ cell tumor (GCT) resembling undifferentiated stem cells during embryonic development.

Second most common type of testicular pure GCT

Average age of presentation 25 - 35 years old, ~10 years younger than seminoma

Can occur in Anterior mediastinum and retroperitoneum.

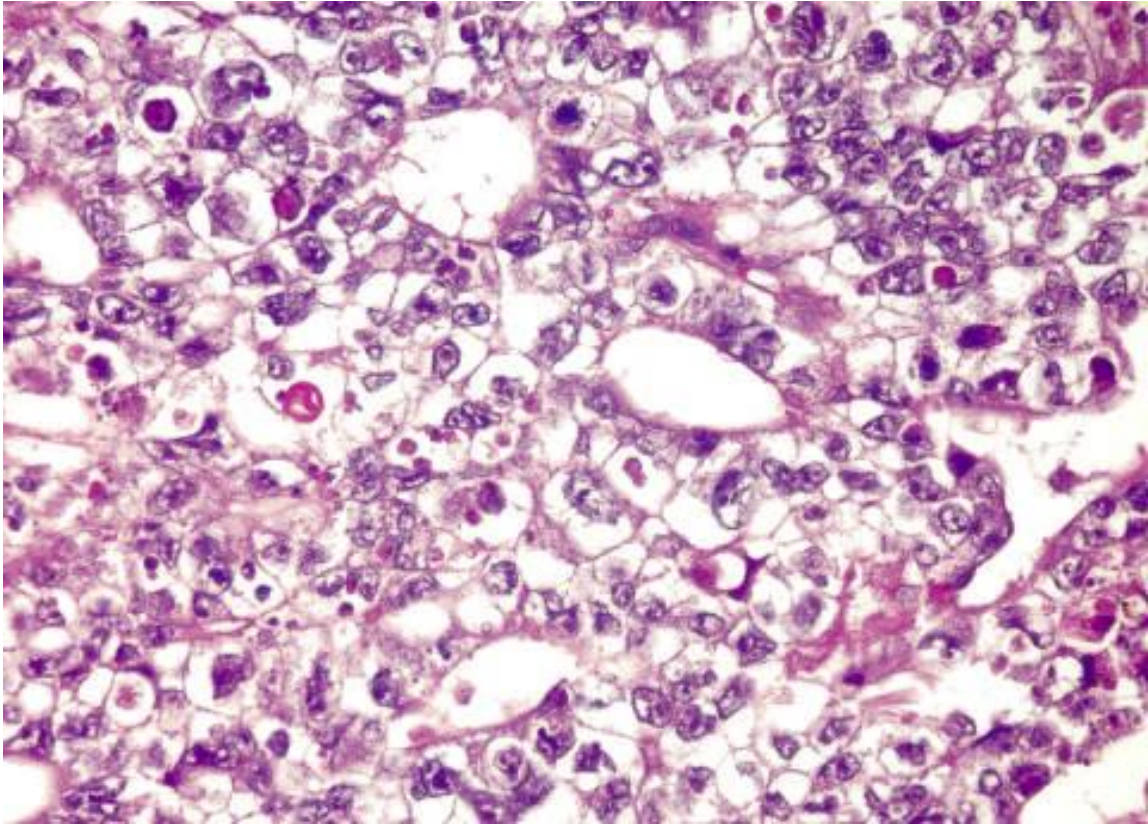


# Morphology

---

**Gross:** ill-defined, invasive masses containing foci of hemorrhage and necrosis.





# Microscopic

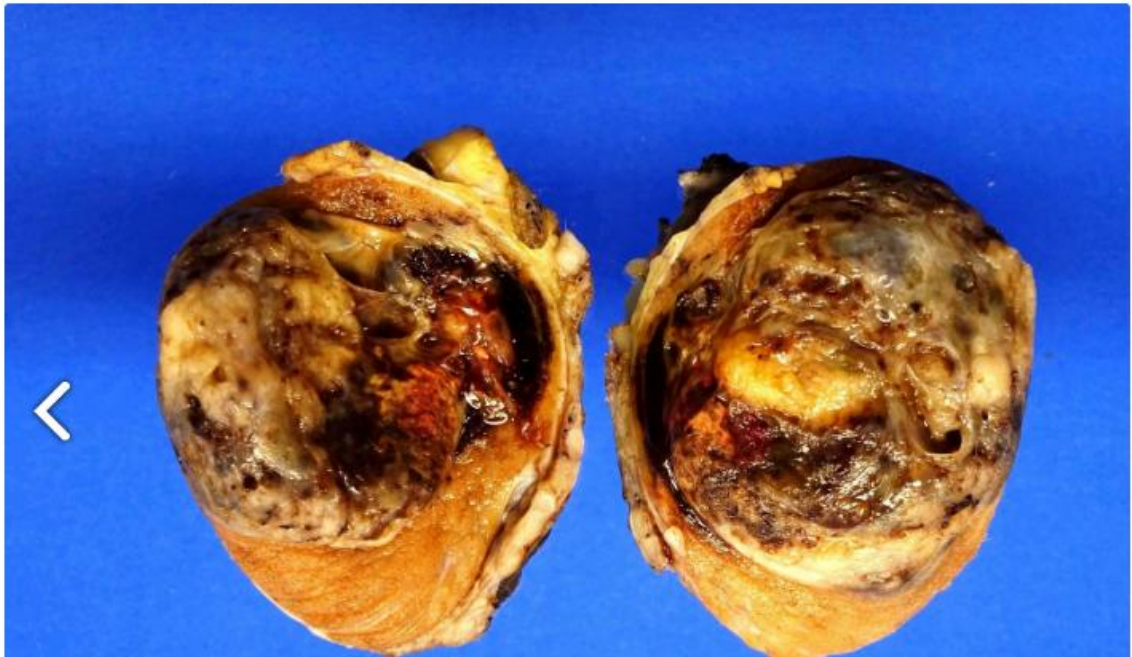---

large cells with basophilic cytoplasm, they are undifferentiated & may form primitive glands.

### 3. Yolk sac tumor

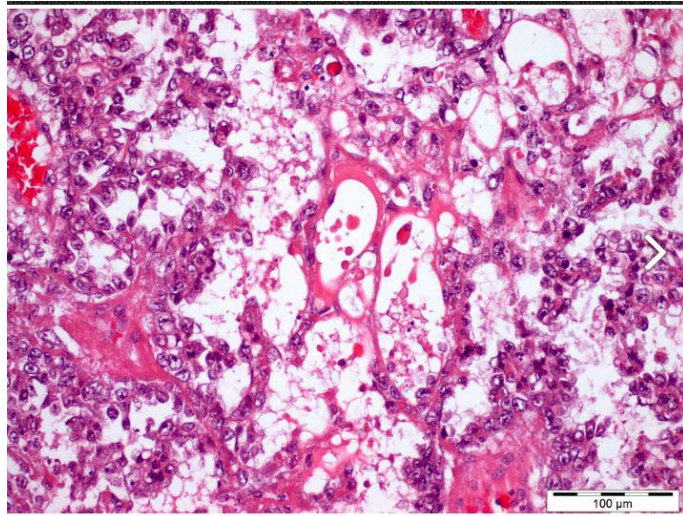
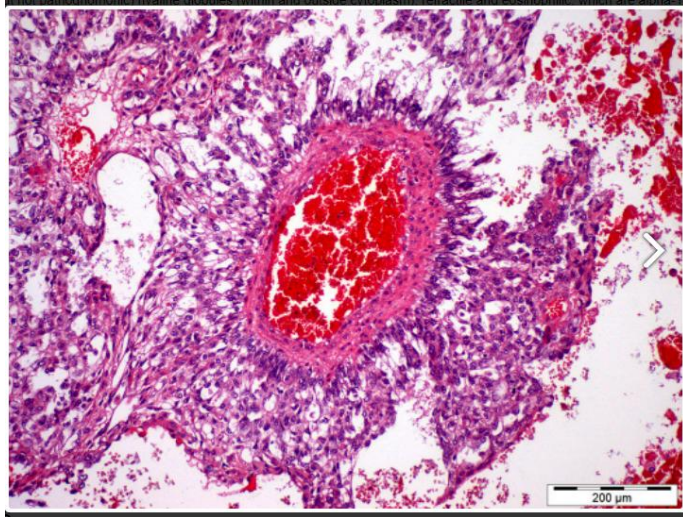
- The most common primary testicular neoplasm in children younger than 3 years old.
- In this age group, it has a very good prognosis.
- In adults, yolk sac tumors most often are seen admixed with embryonal carcinoma (incidence of yolk sac elements is 80% in mixed).

or without adjuvant (cisplatin based) chemotherapy



# Morphology

- Poorly circumscribed, nonencapsulated, predominantly solid. Gray to white to yellow to tan, gelatinous surface



# Microscopic

- ❑ Tumor composed of low cuboidal to columnar epithelial cells that form microcysts, lacelike (reticular) patterns.
- ❑ A distinctive feature is the presence of structures resembling primitive glomeruli, the so-called Schiller-Duval bodies.
- ❑ Tumors have eosinophilic globules containing  $\alpha$ 1-anti-trypsin and alpha fetoprotein (AFP – can be detected in the serum)

extensive background of  
necrosis and hemorrhage  
#

#### 4. Choriocarcinoma

Malignant germ cell tumor composed of syncytiotrophoblast, cytotrophoblast and intermediate trophoblast cells,

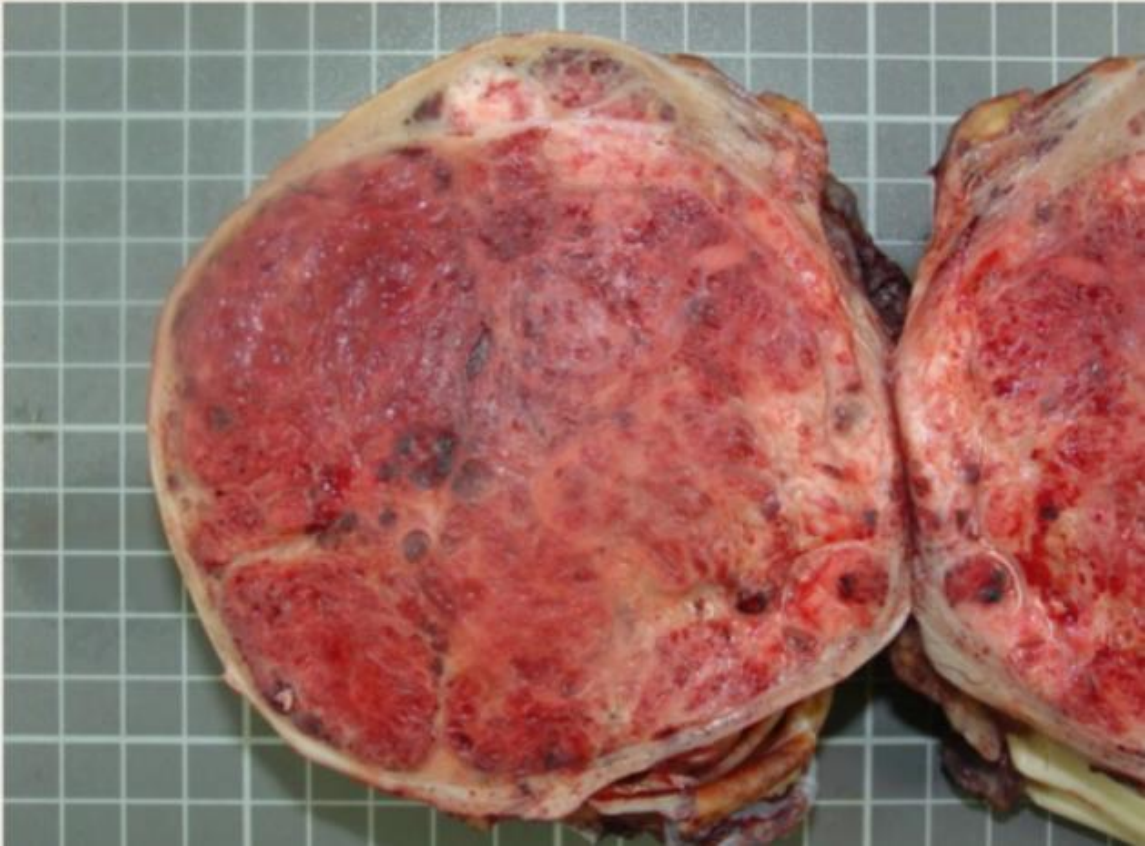May present initially with metastases (liver, lung, mediastinum, retroperitoneum) with normal testis or small tumor but with increased serum hCG.

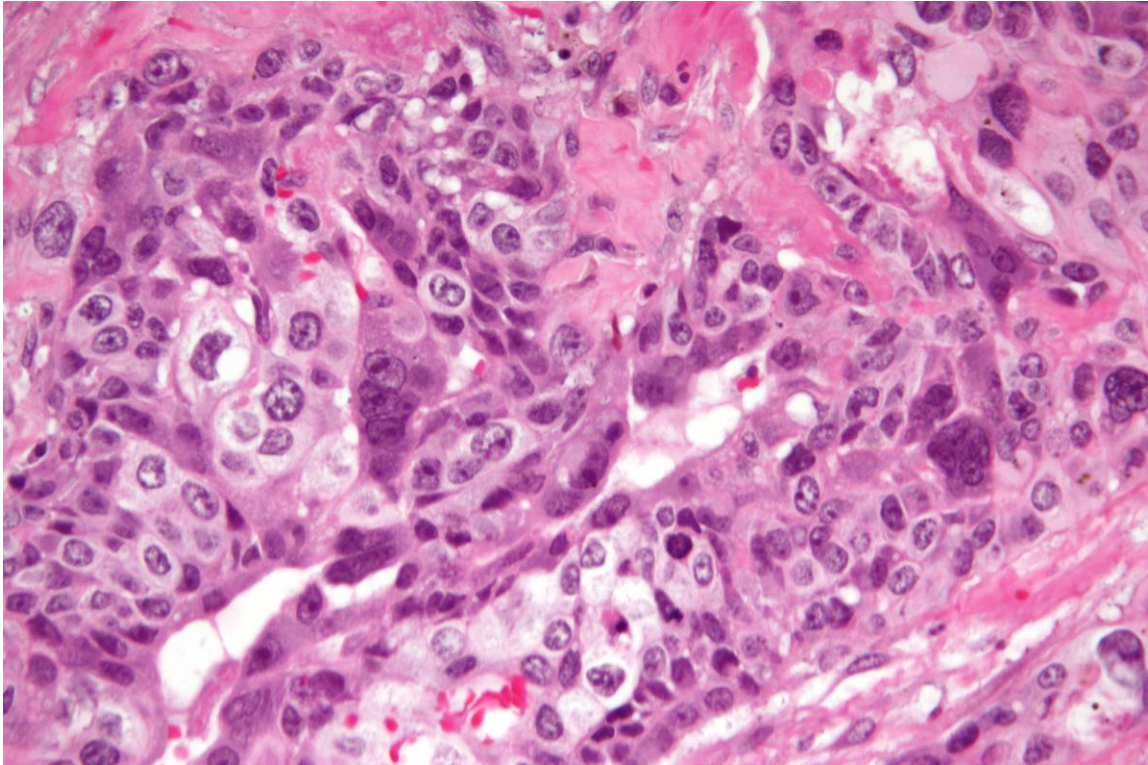
# Morphology

---

❖ Gross:

- may be small lesions, even those with extensive systemic metastases
- May show total necrosis & extensive hemorrhage





# Microscopic

---

- histopathology : *BhCG*
- (1)Cytotrophoblast: Sheets of small cuboidal cells, irregularly intermingled with
  - (2)Syncytiotrophoblast: large, eosinophilic cells with multiple dark, pleomorphic nuclei.

## 5. Teratoma

Neoplastic germ cells differentiate along multiple somatic cell lineages.

Pure forms of teratoma are common in infants and children , 2nd in frequency only to yolk sac tumors.

In adults it is seen in combination with other histologic types (mixed), pure forms are rare.

meso  
ecto  
endo dermal

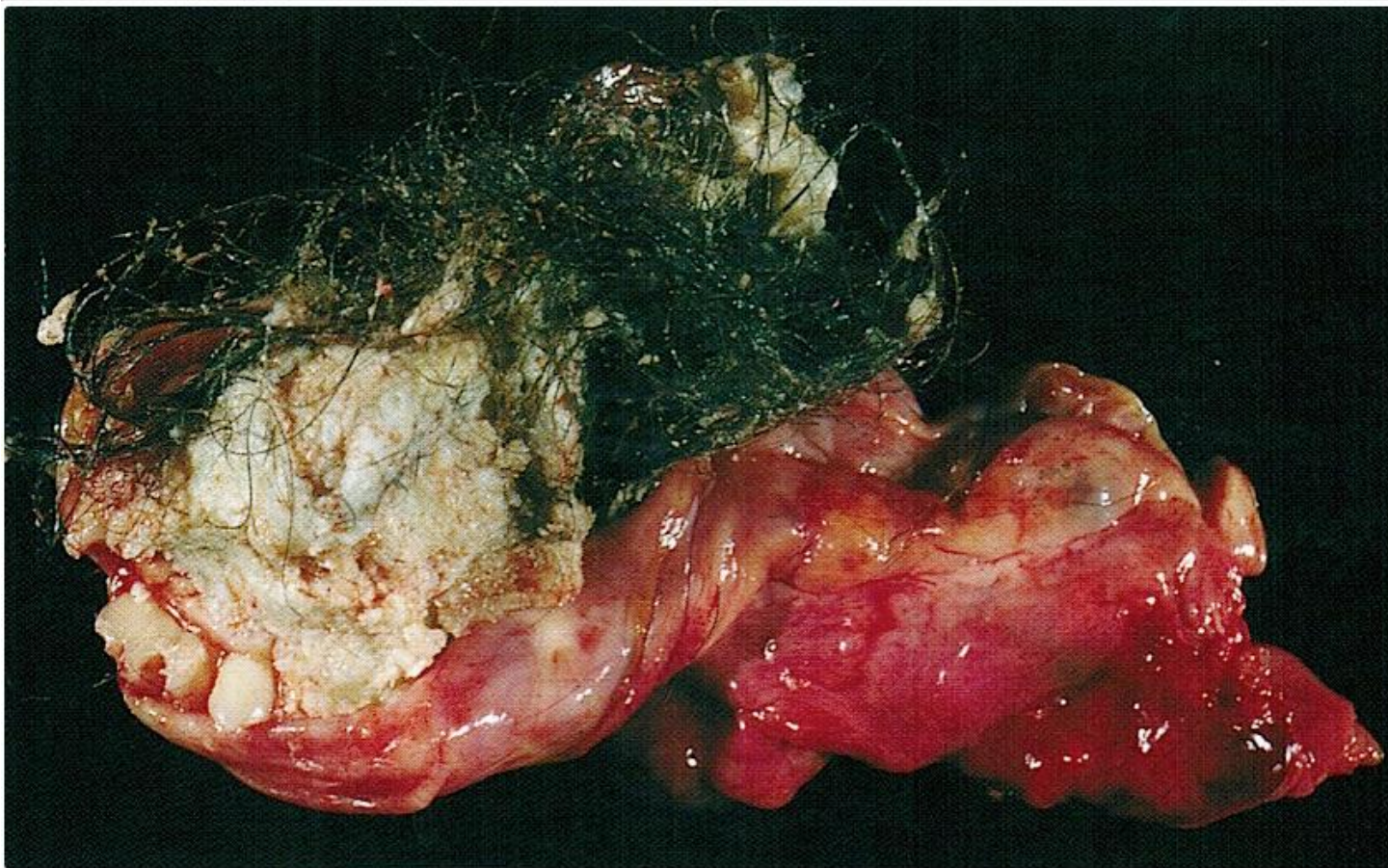
# Morphology

Elements may be:

- ❖ mature (resembling various tissues within the adult)
- ❖ immature (sharing features with fetal or embryonal tissues).

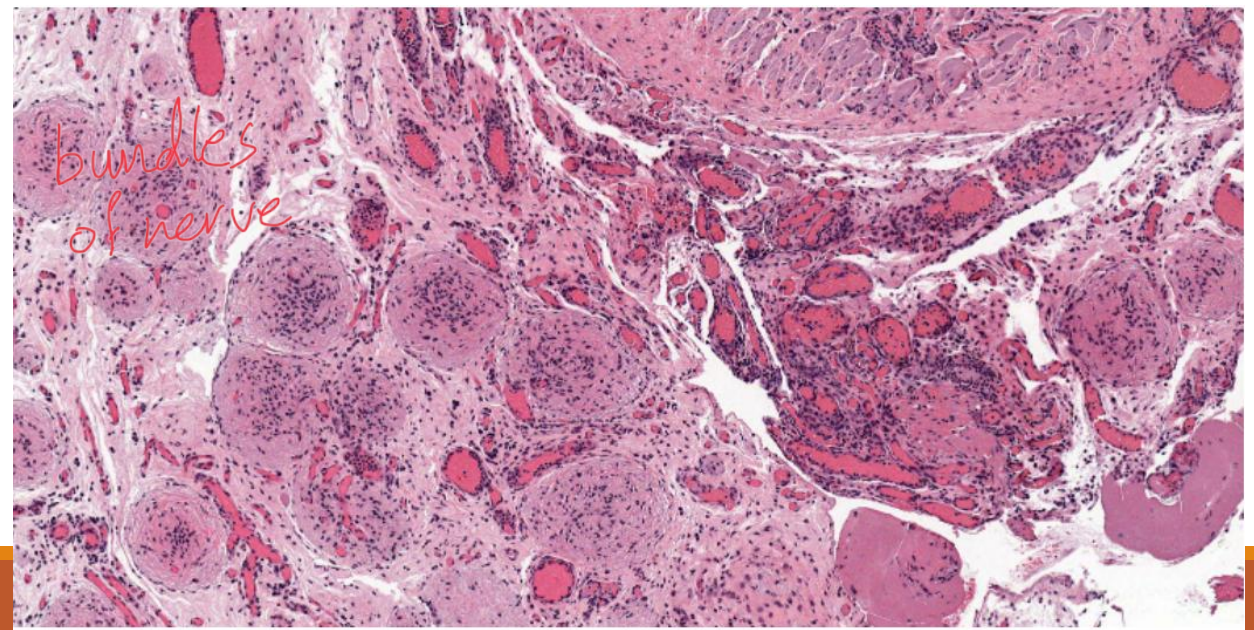
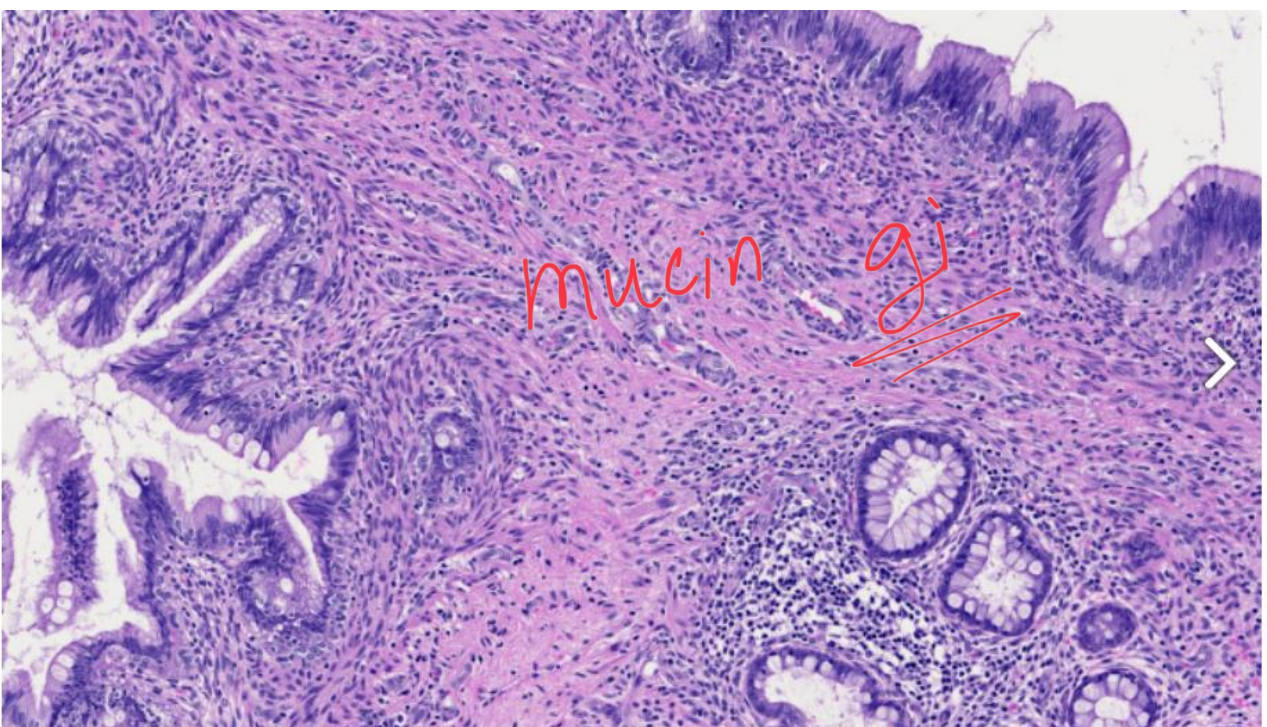
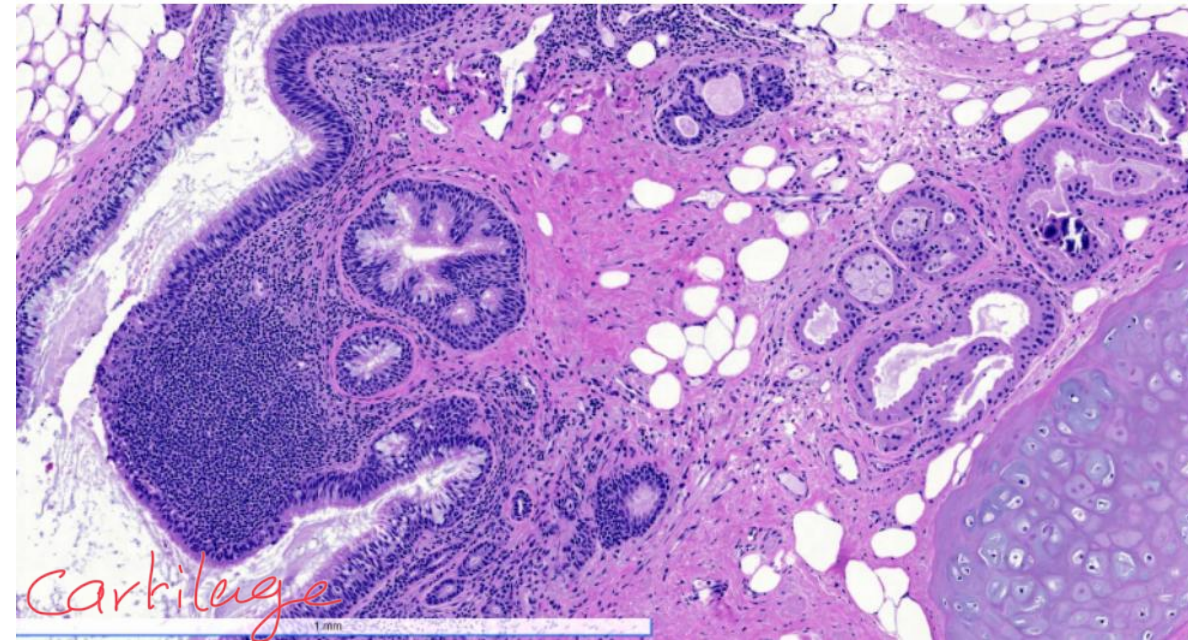
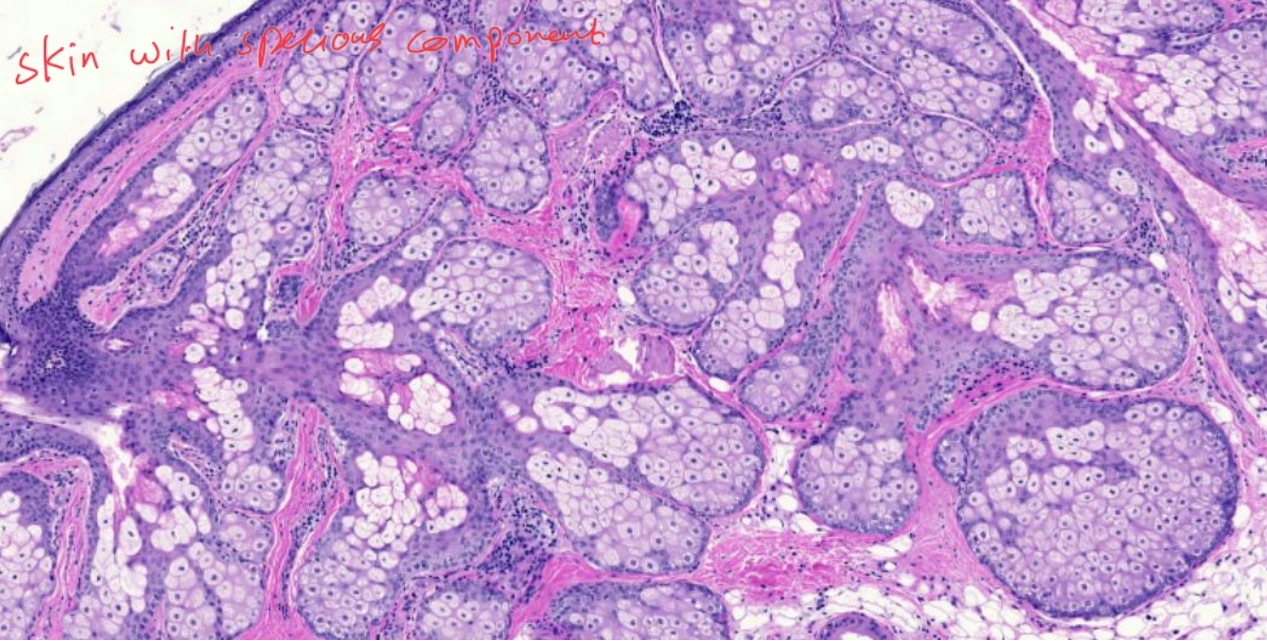
In prepubertal males, teratomas are benign.

The majority of teratomas in postpubertal males are malignant whether they have mature or immature elements.



Gross

hair and special material



# Tumor markers

Serum tumor markers secreted by germ cell tumors is important in two ways; diagnostically & in following the response to therapy after the diagnosis:

- ✓ Human chorionic gonadotropin (hCG): always elevated in choriocarcinoma
- ✓ Alpha fetoprotein (AFP): when elevated in testicular neoplasm, indicates a yolk sac tumor component.
- ✓ Lactate dehydrogenase (LDH): correlate with the tumor burden.

↳ Follicular lymphoma