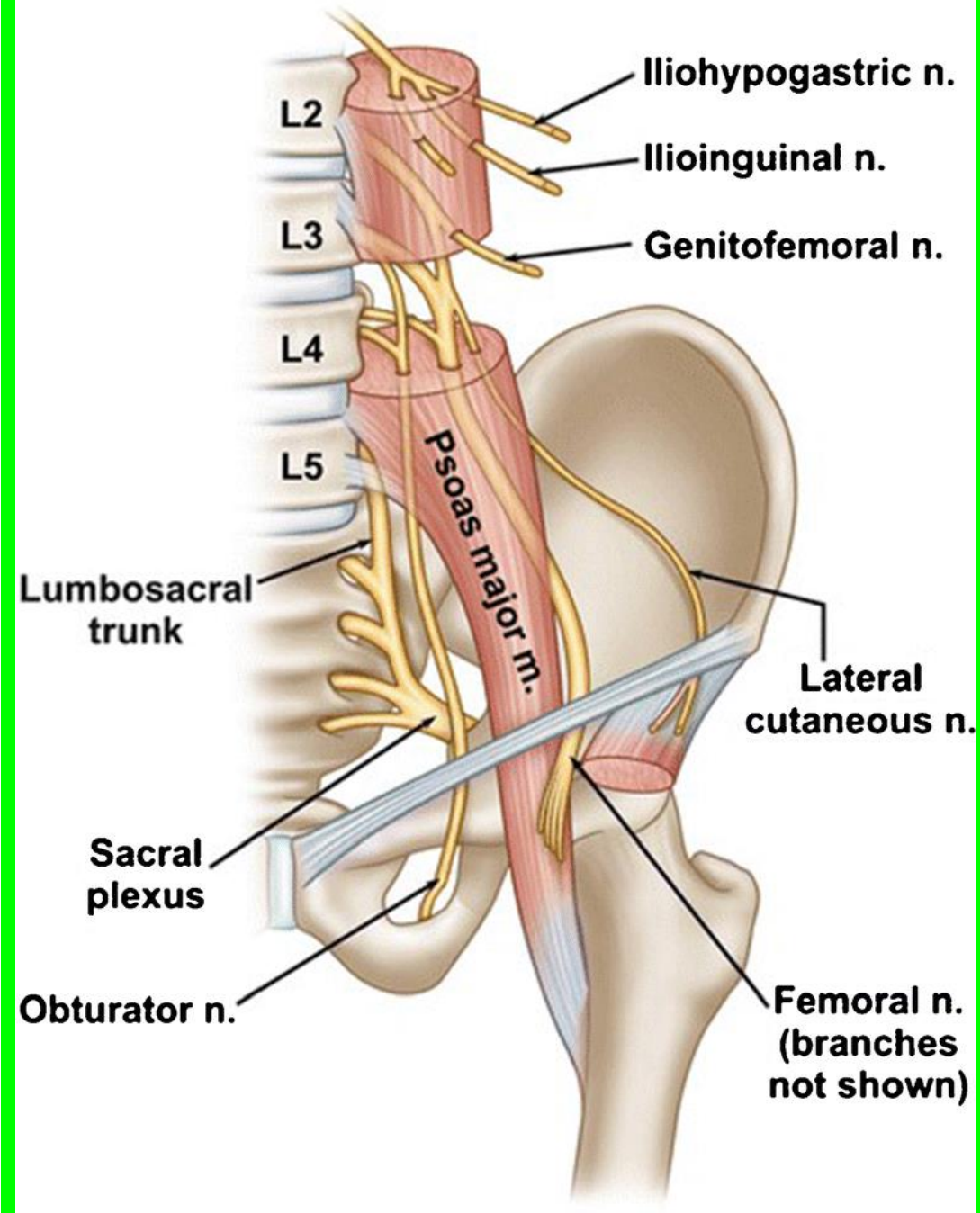
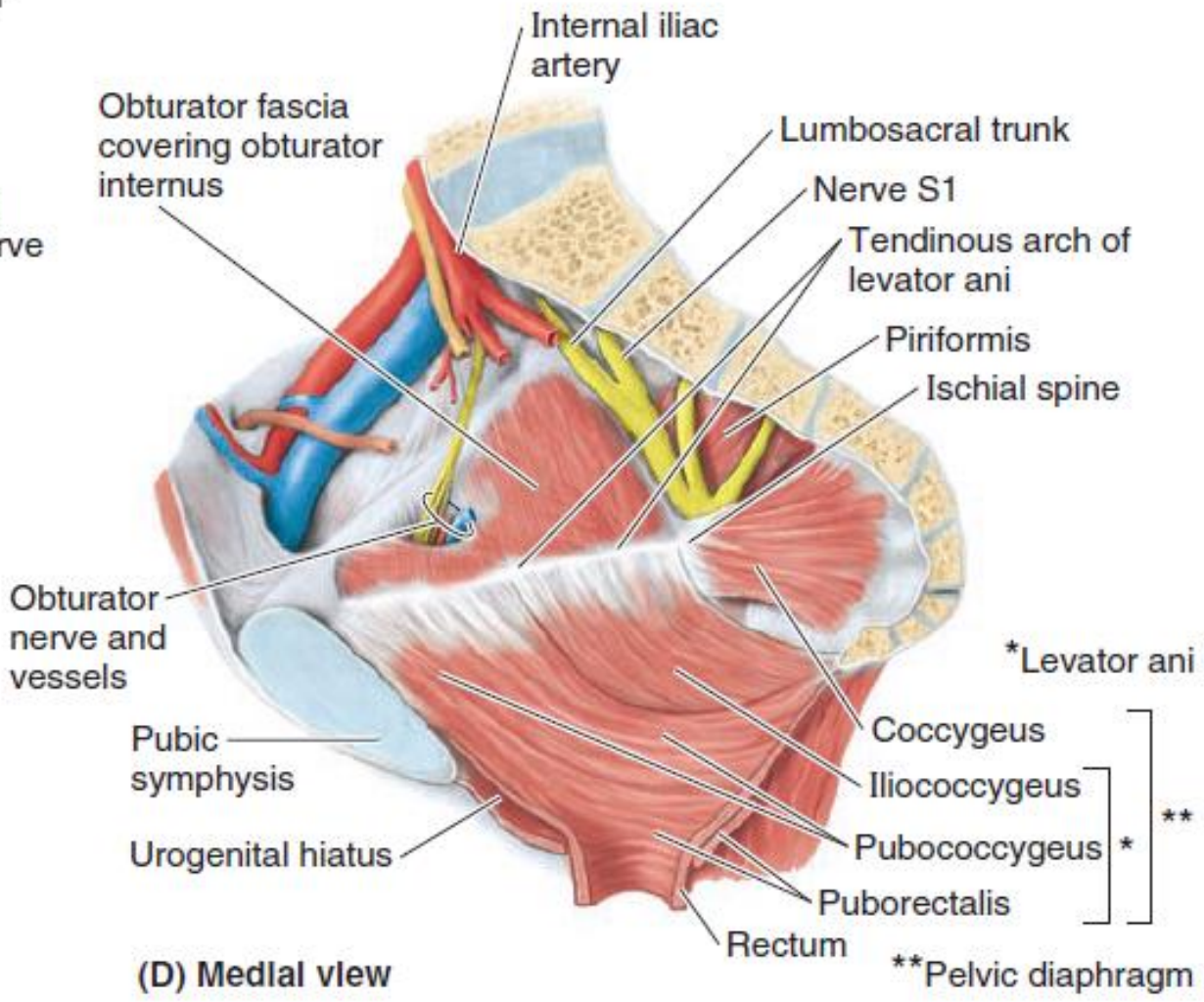
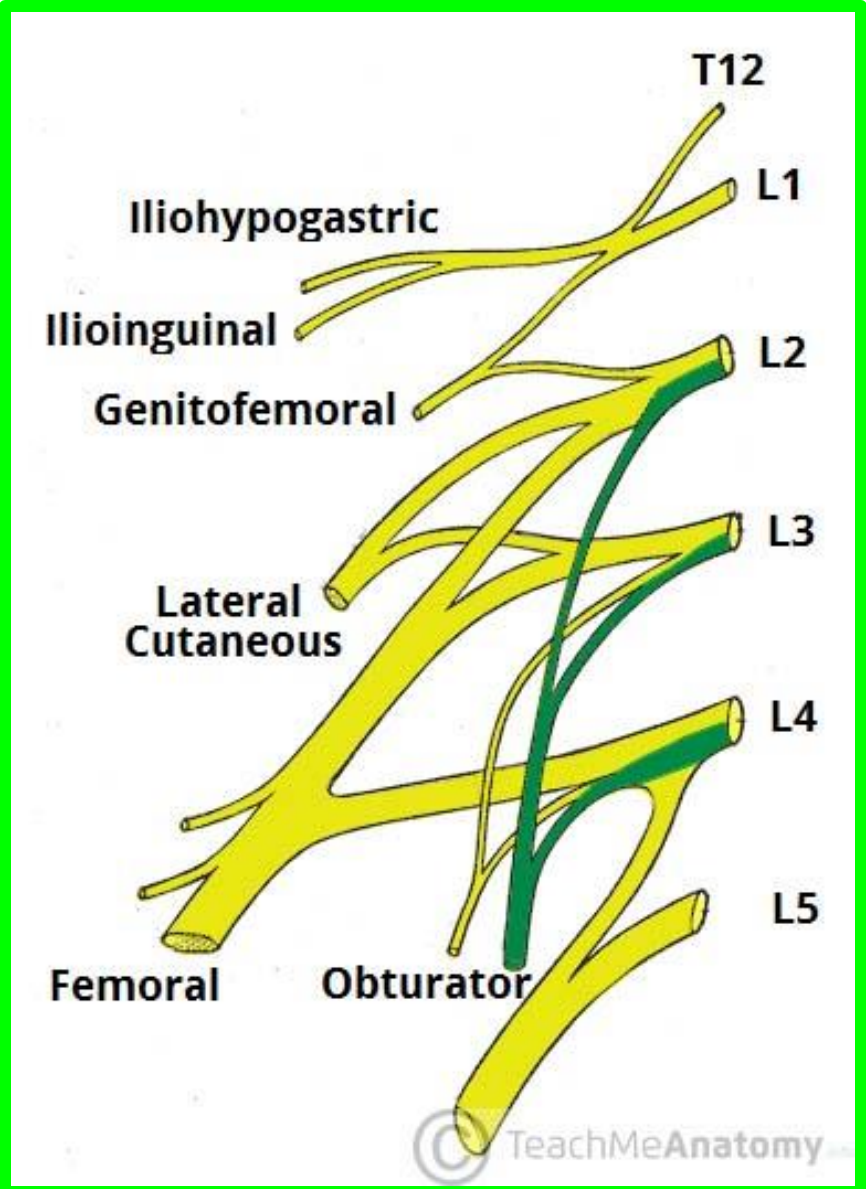
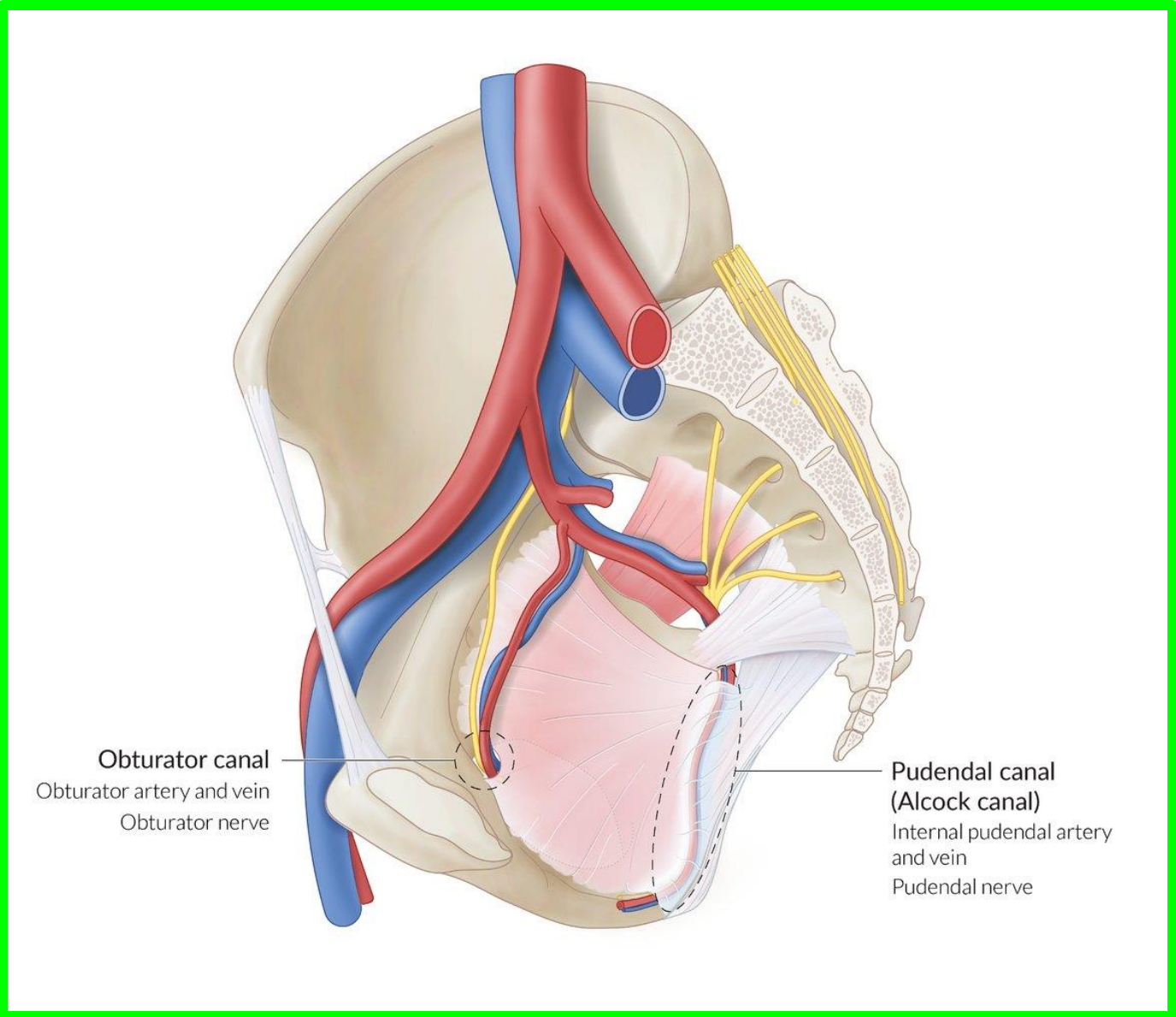


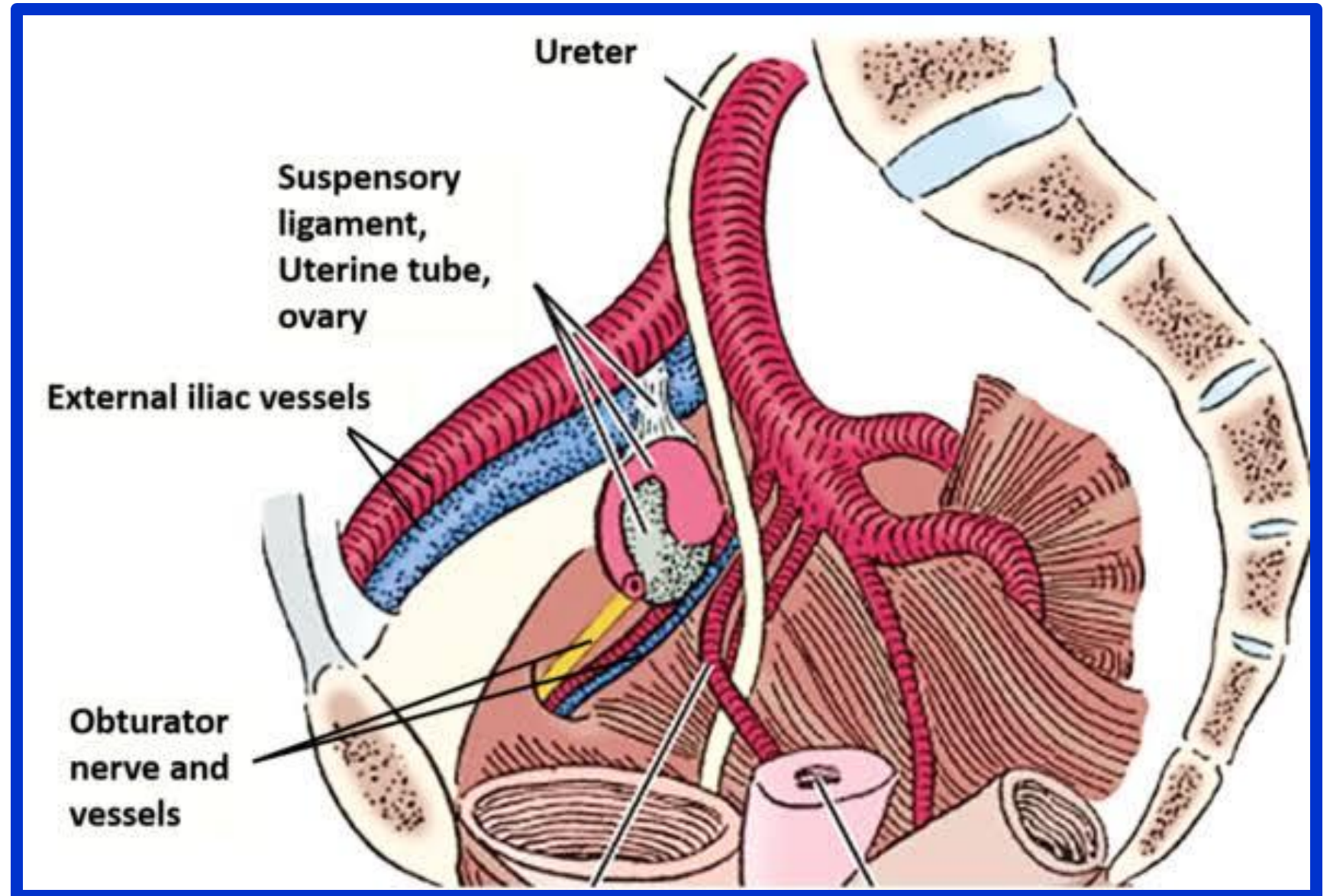
ator  
us  
s  
us  
ctal  
nerve



# The obturator nerve



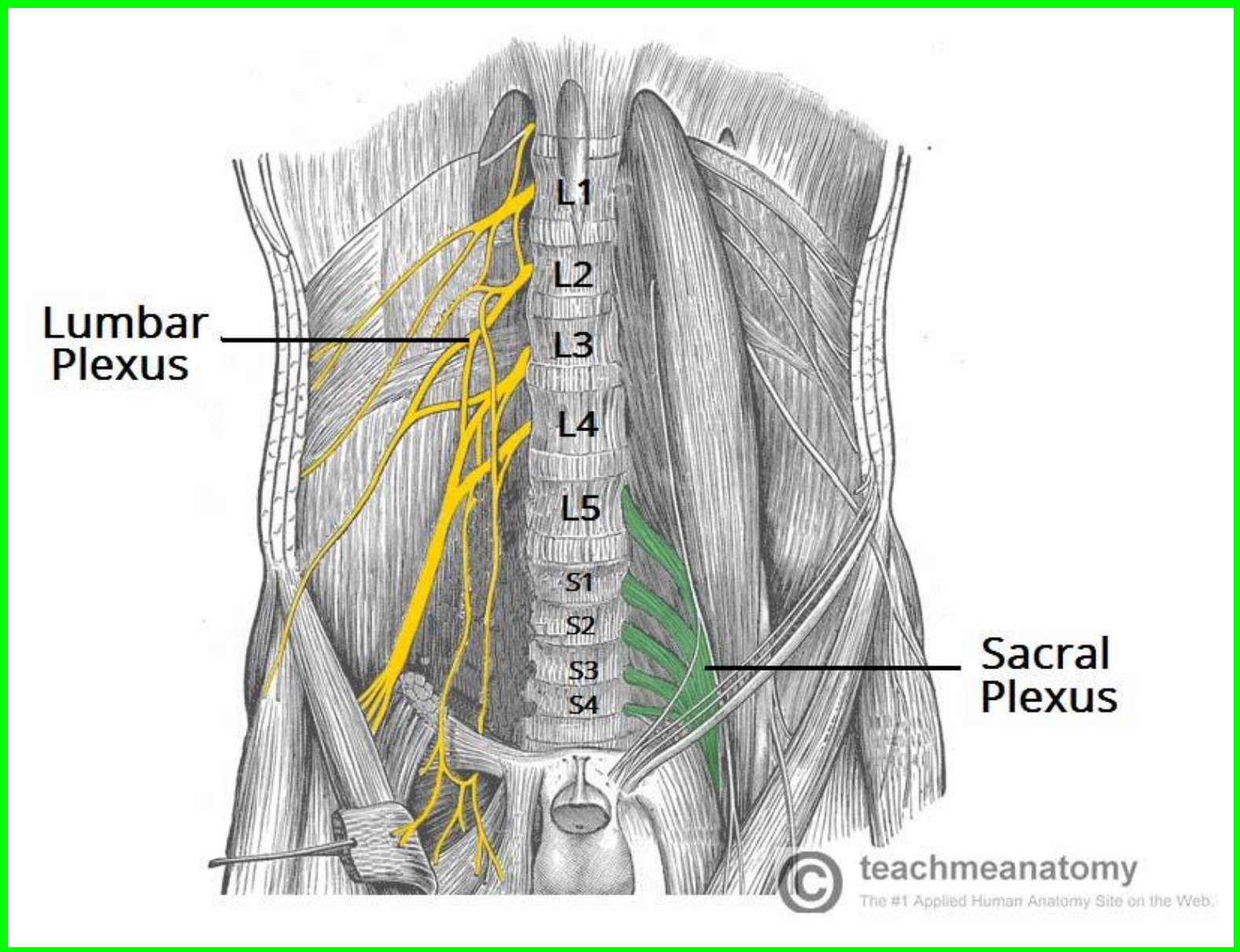
The obturator nerve (L2-L4) passes along the lateral pelvic wall, directly underlying the ovarian fossa (a shallow peritoneal depression on the pelvic side wall).



# The sacral plexus

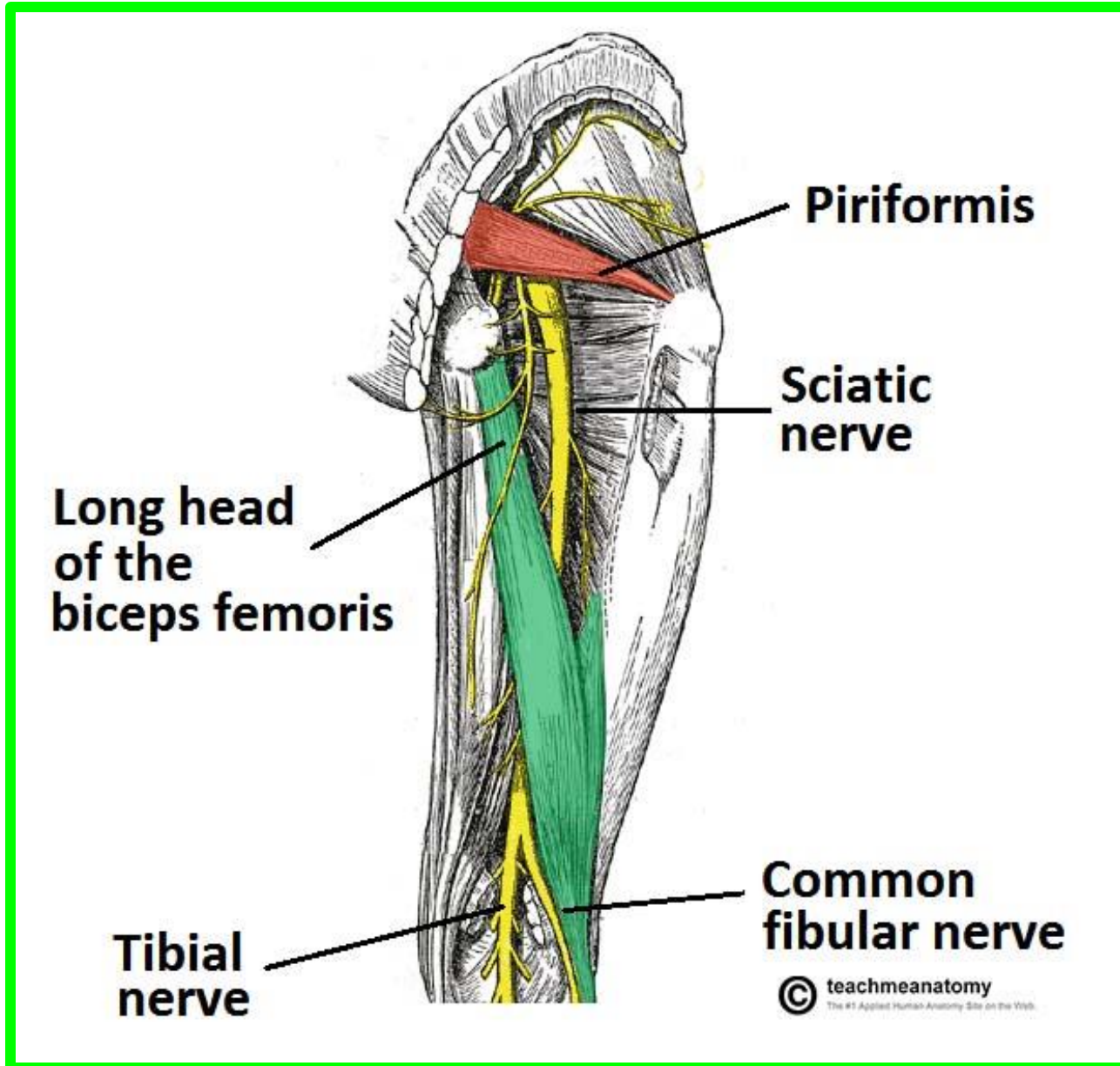
anterior to the piriformis

## Spinal nerves L4-L5 and S1-S4

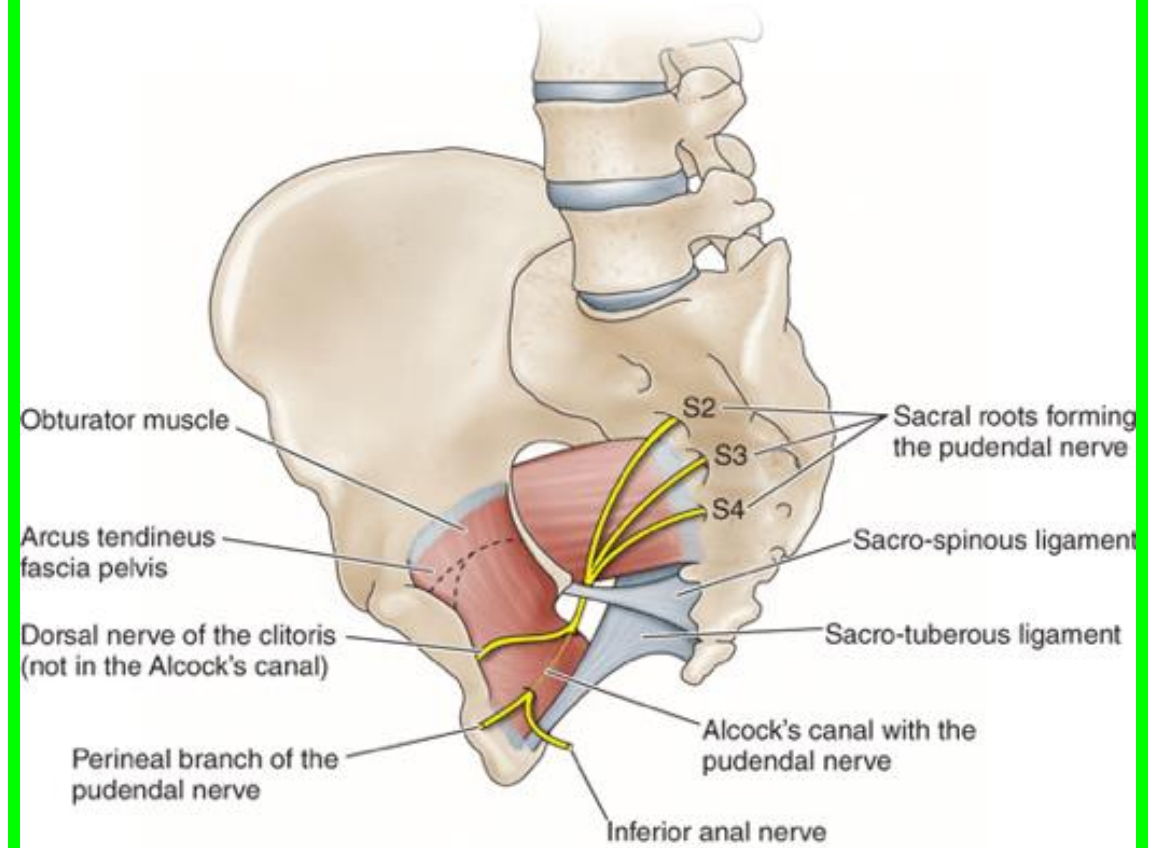
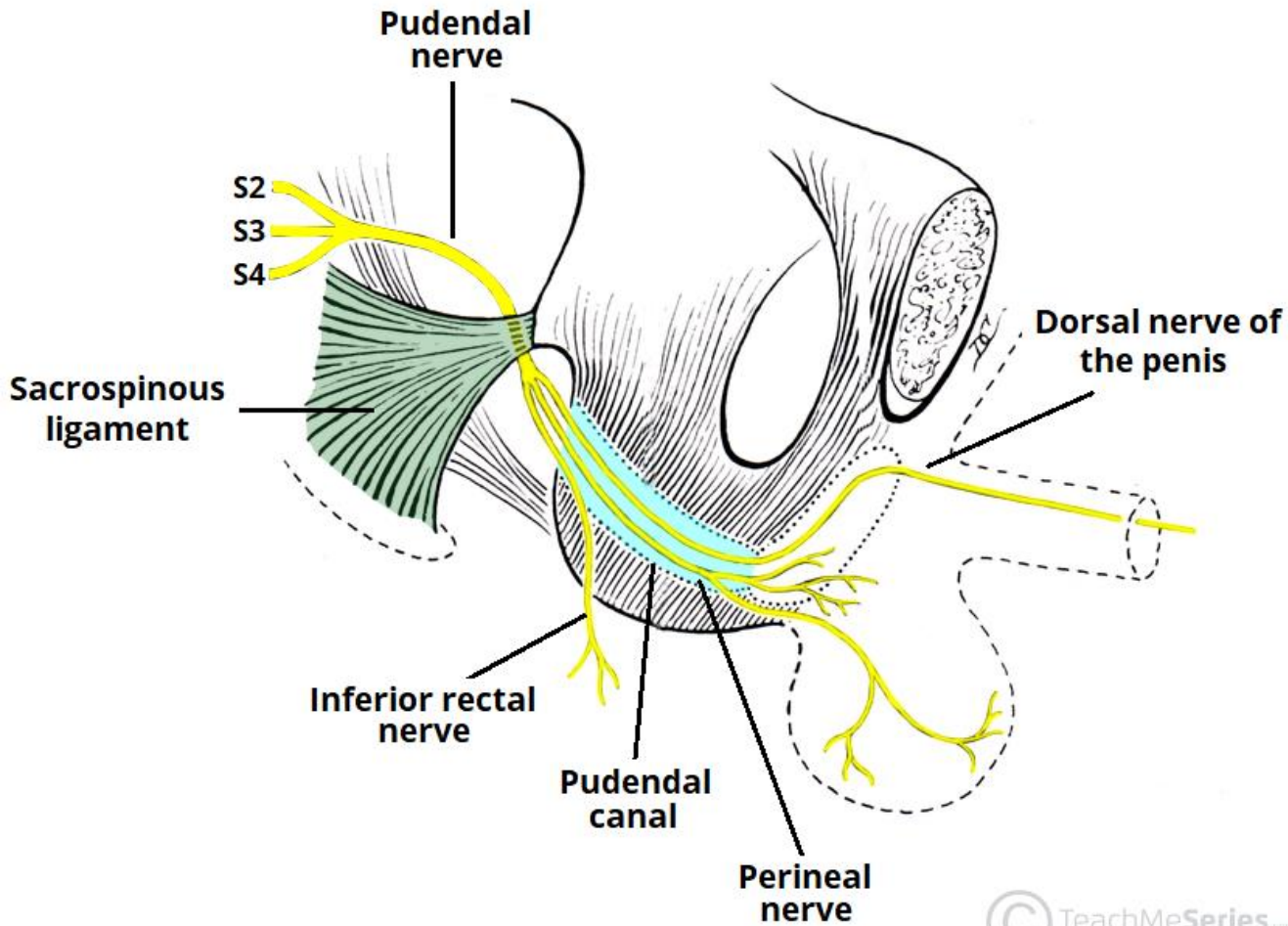


## ❖ The sciatic nerve

✓ anterior rami of spinal nerves L4, L5, S1, S2, S3

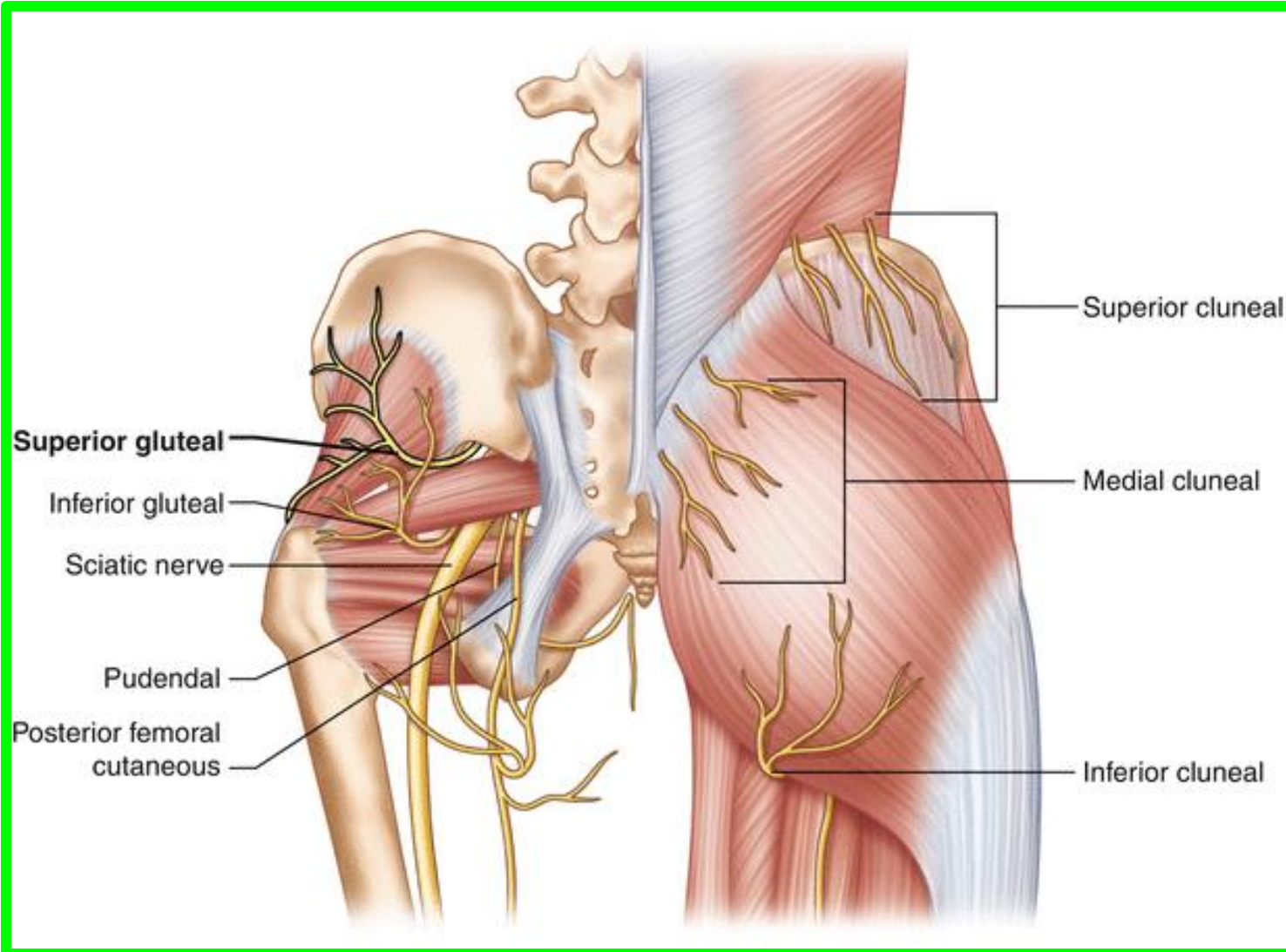


# ❖ The pudendal nerve



❖ **The superior gluteal nerve** L4, L5, S1

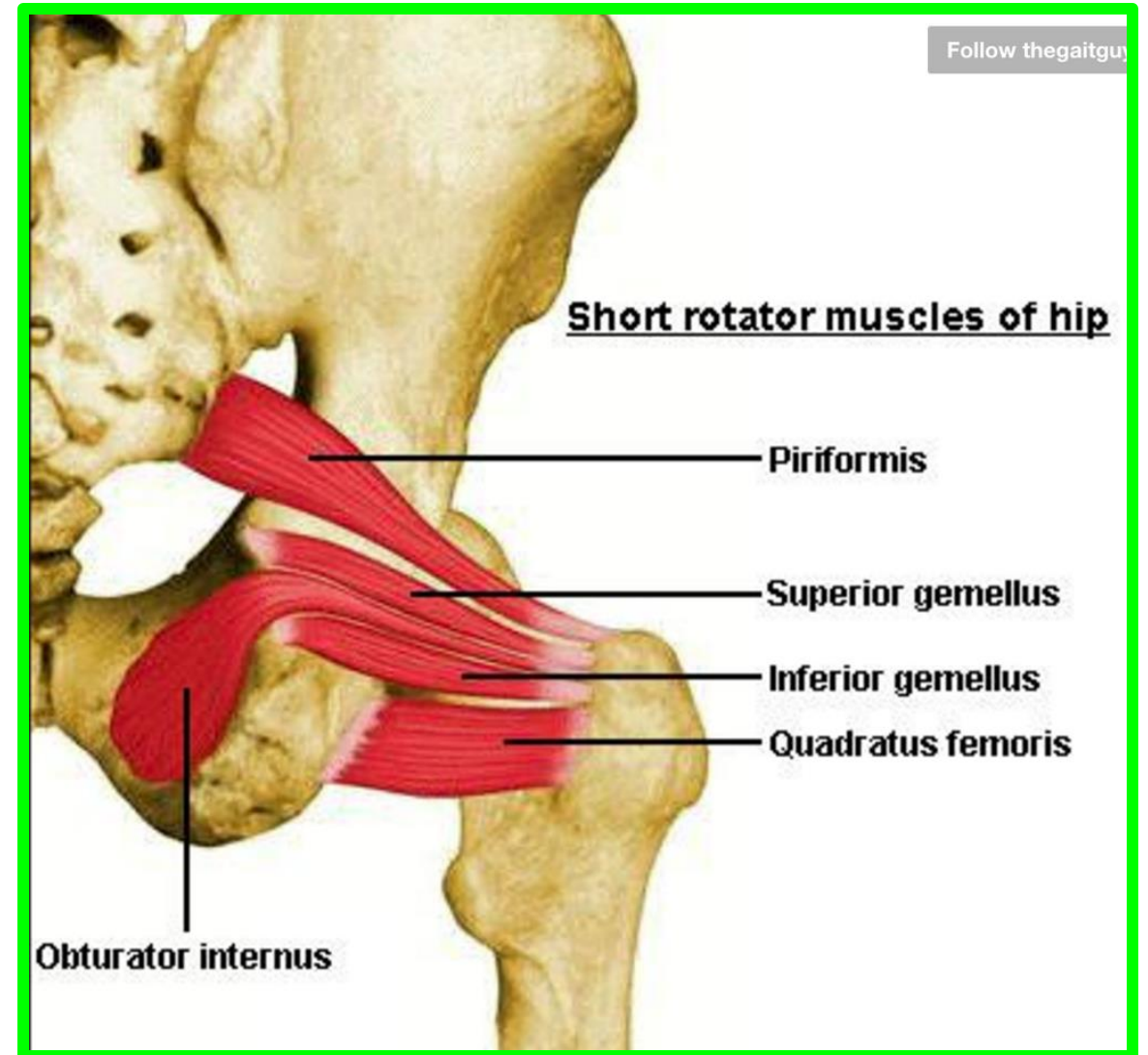
❖ **The inferior gluteal nerve** L5, S1, S2



❖ Nerve to quadratus femoris (& inferior gemellus) L4, L5, S1

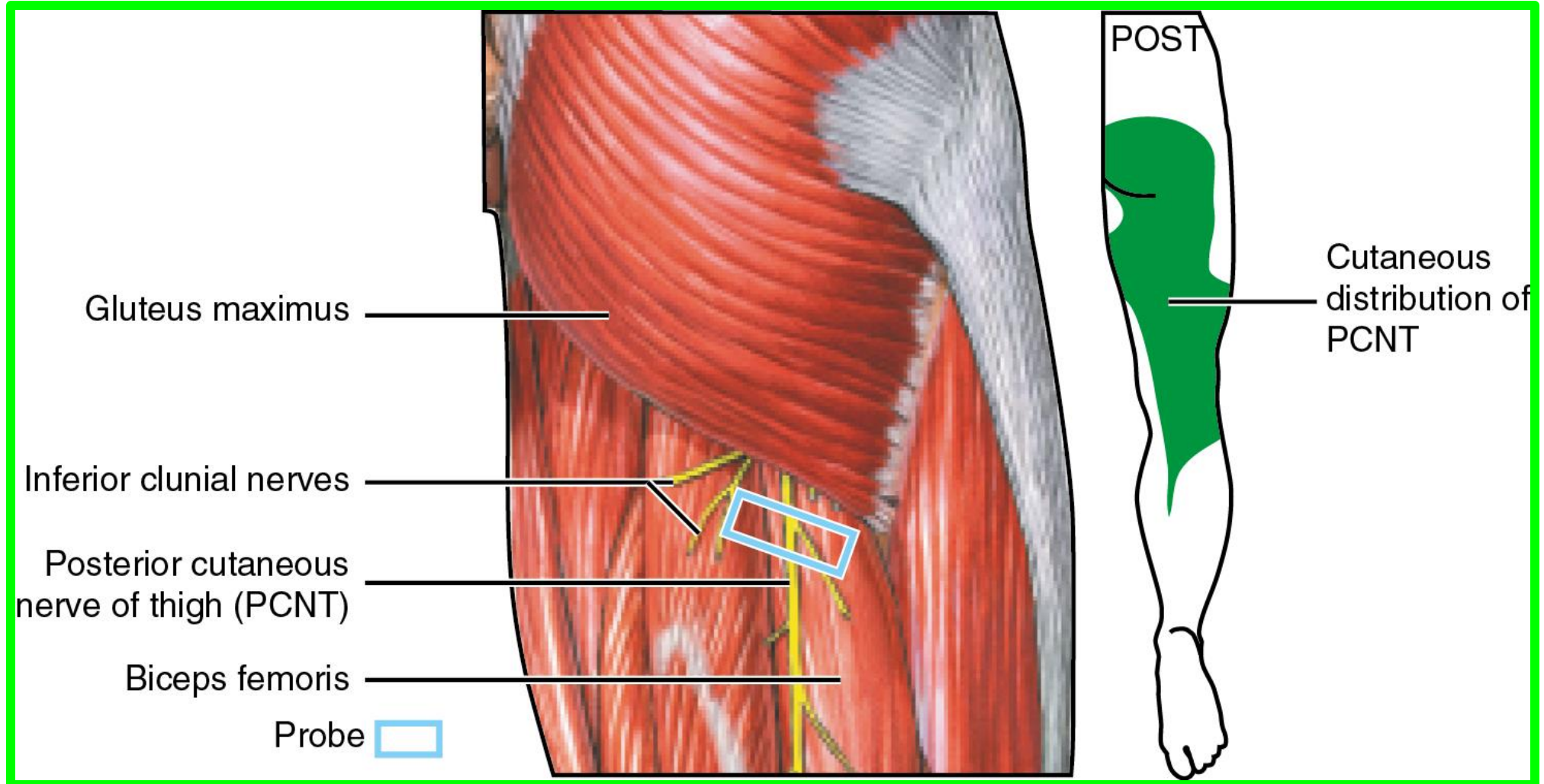
❖ Nerve to obturator internus (& superior gemellus) L5, S1, S2

❖ Nerve to piriformis: S1, S2



# Posterior cutaneous nerve of thigh

S<sub>2</sub>, S<sub>3</sub>

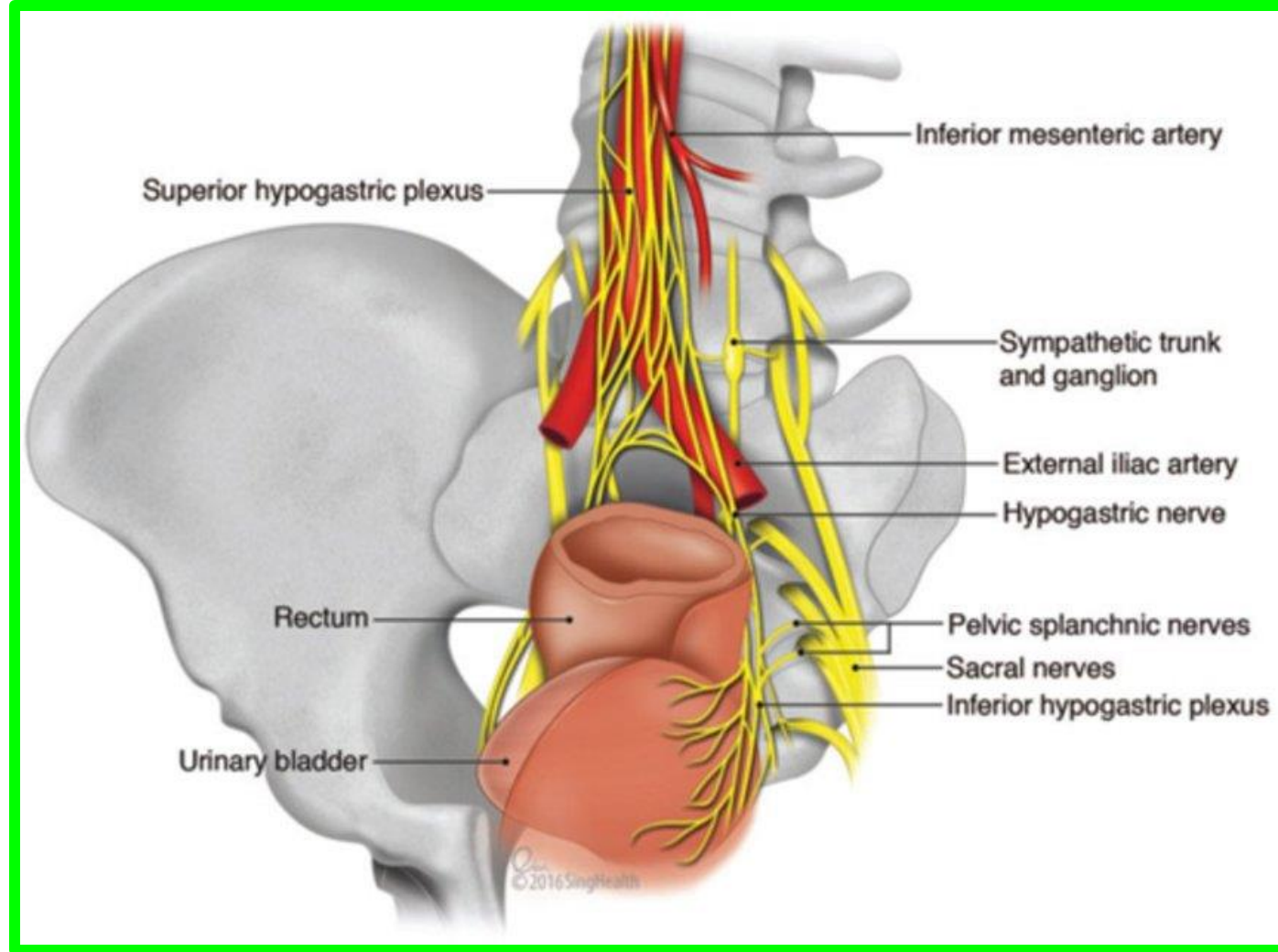
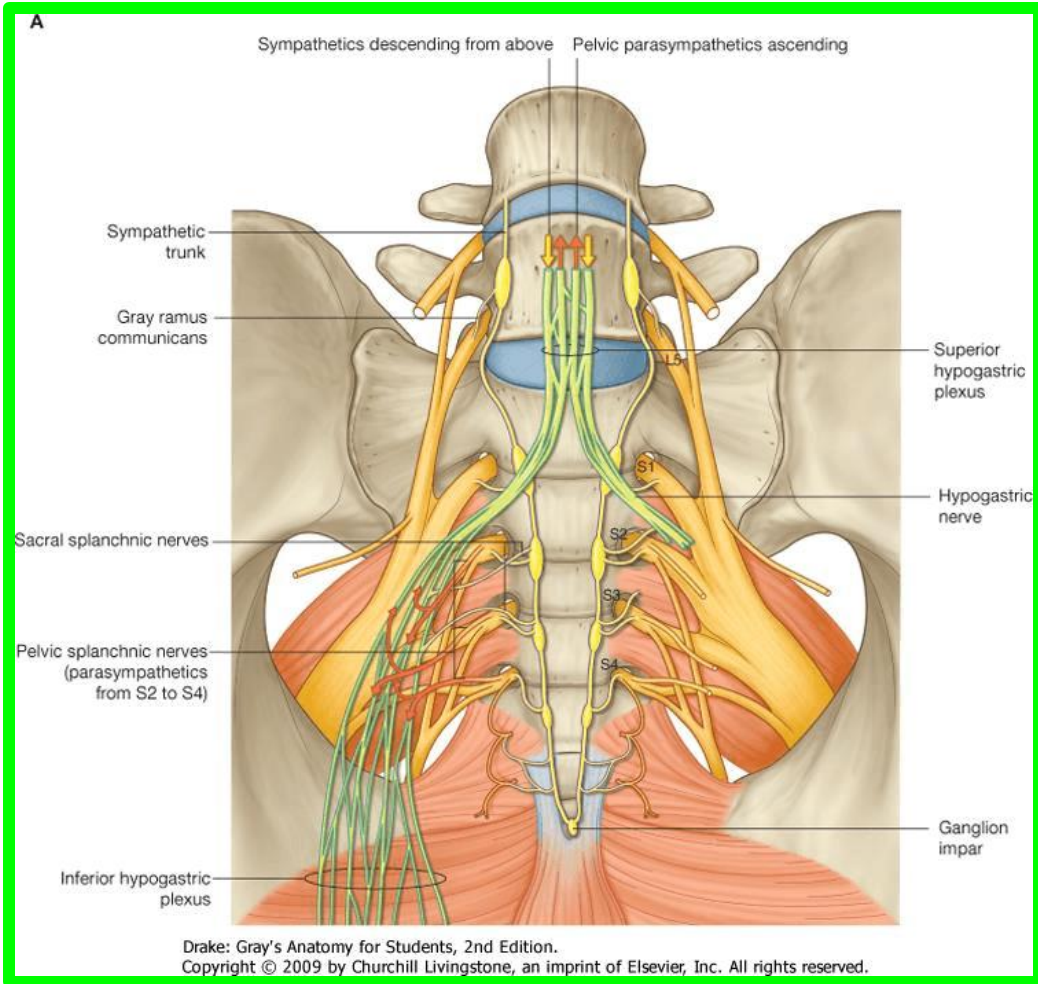


# The superior hypogastric plexus

## Left and right hypogastric nerves

The hypogastric nerves and pelvic splanchnic nerves S2,S3,S4

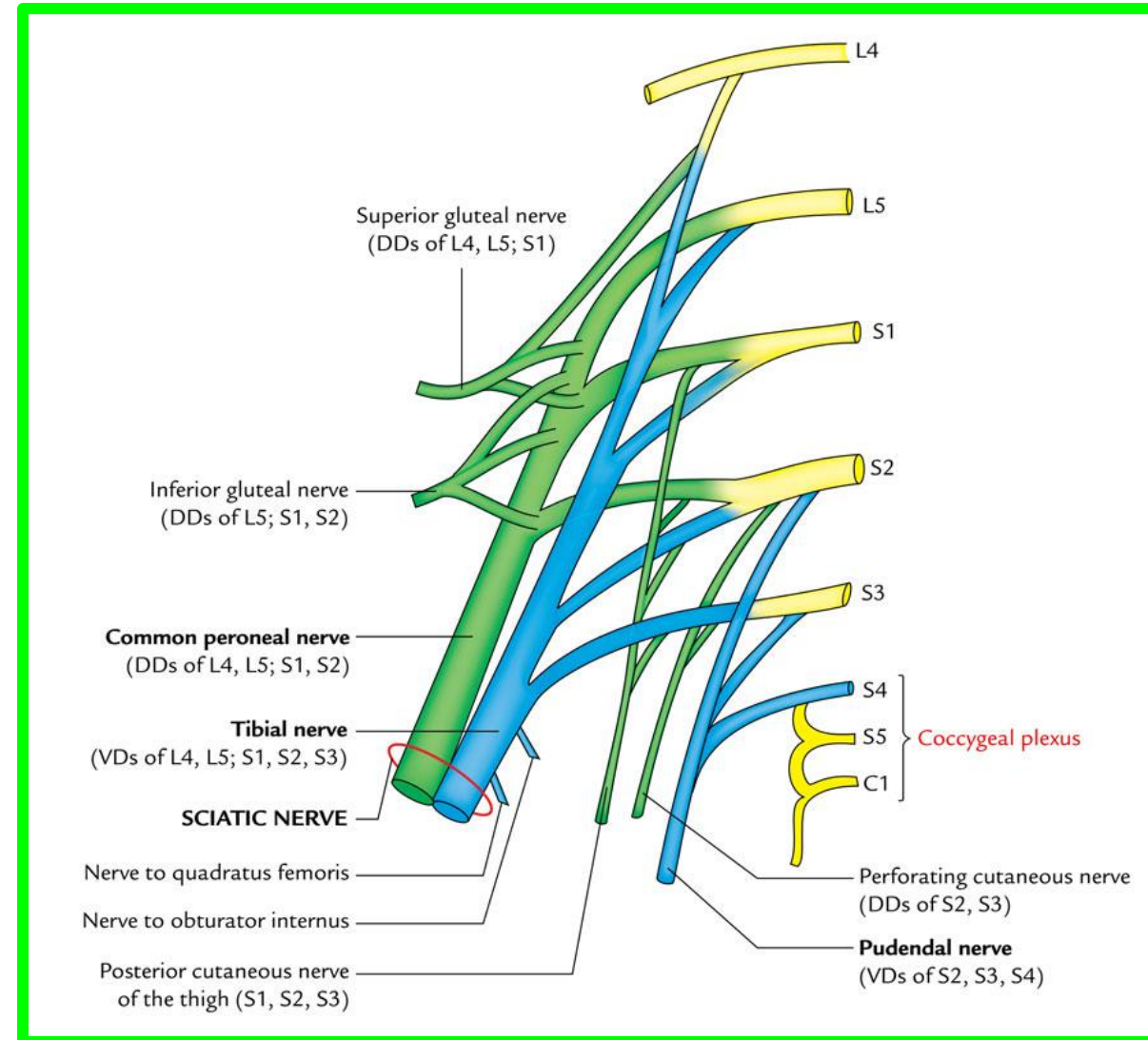
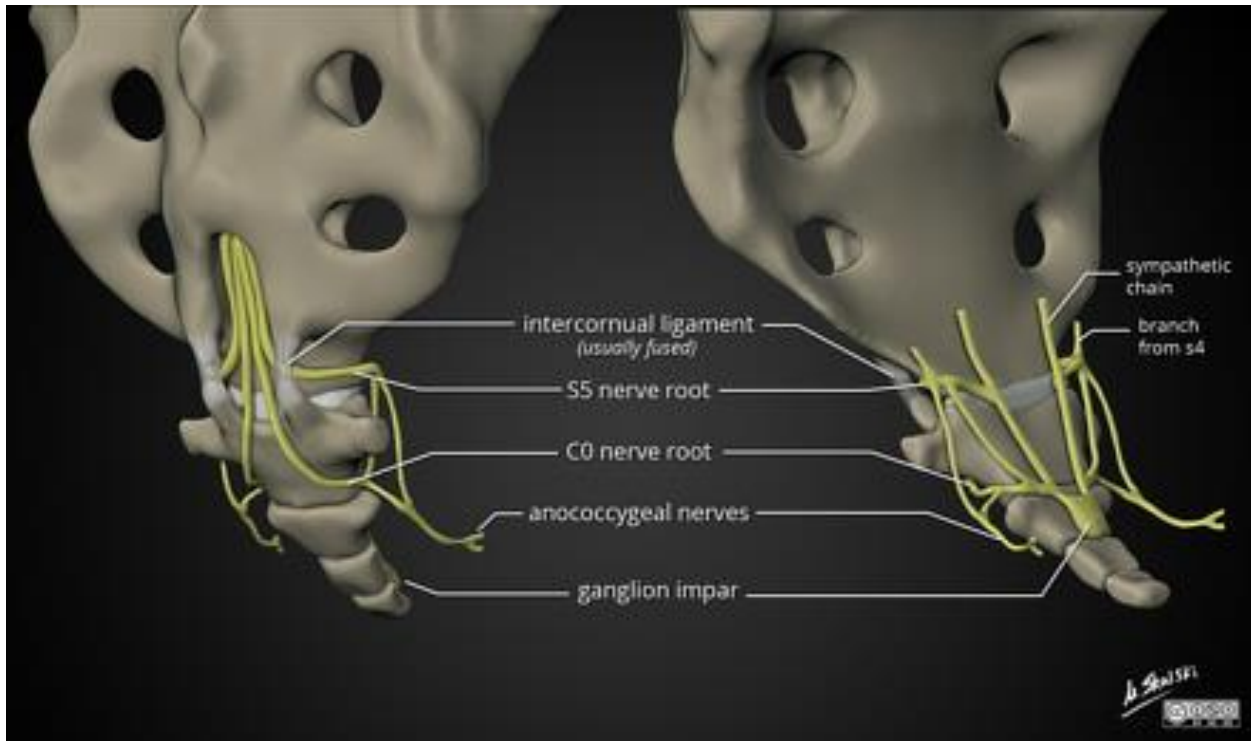
## The inferior hypogastric plexus



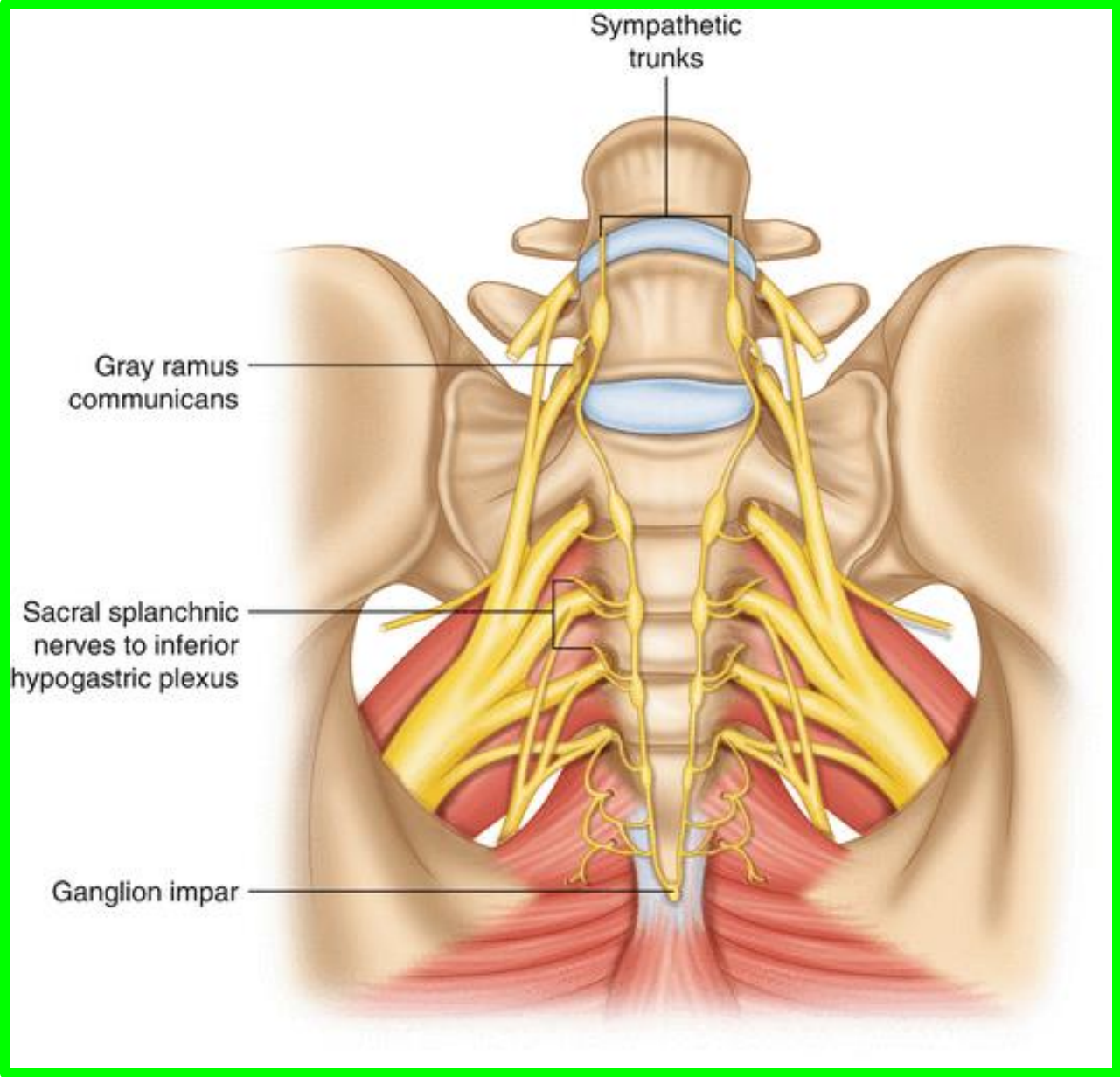
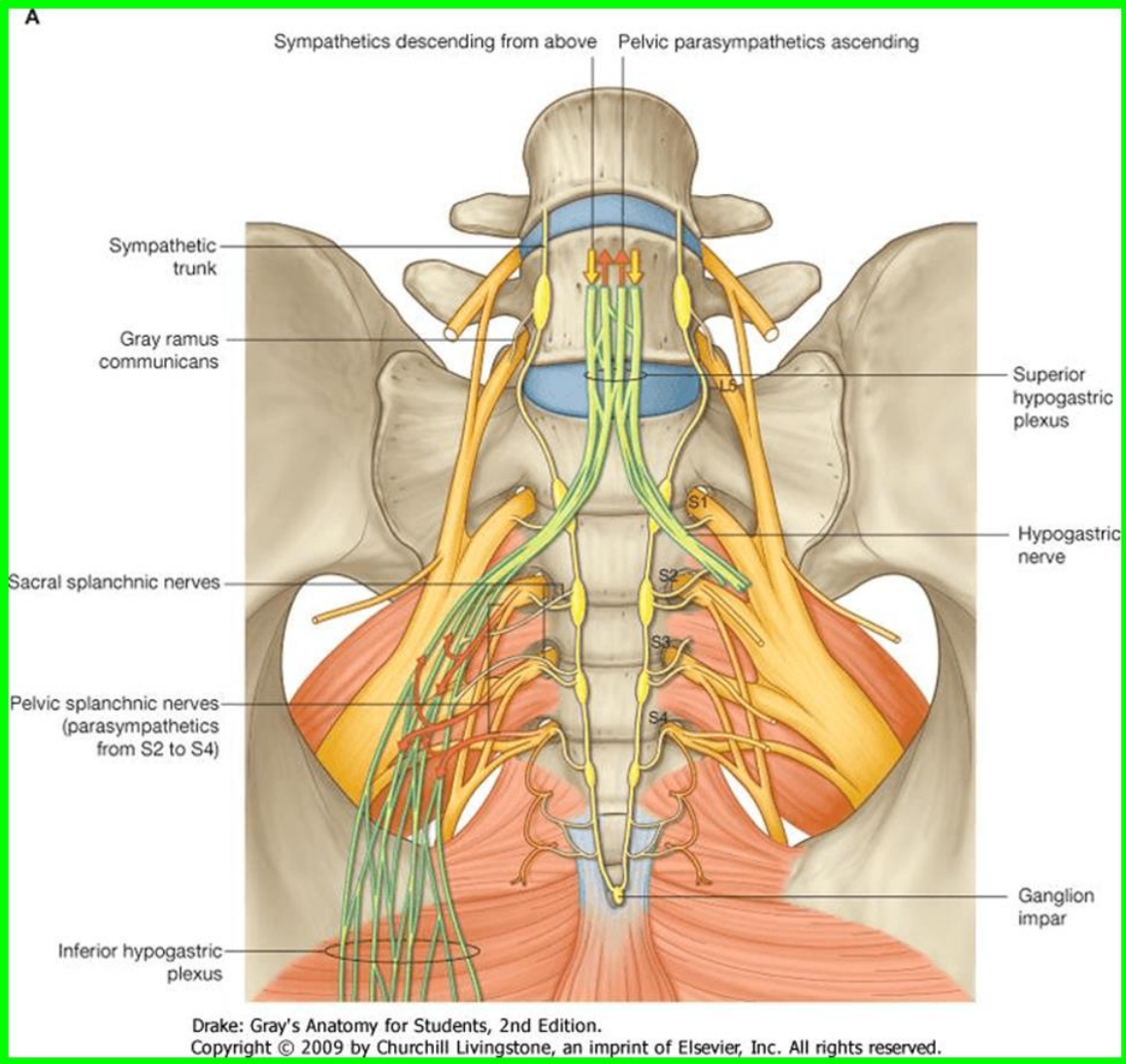
# COCCYGEAL PLEXUS

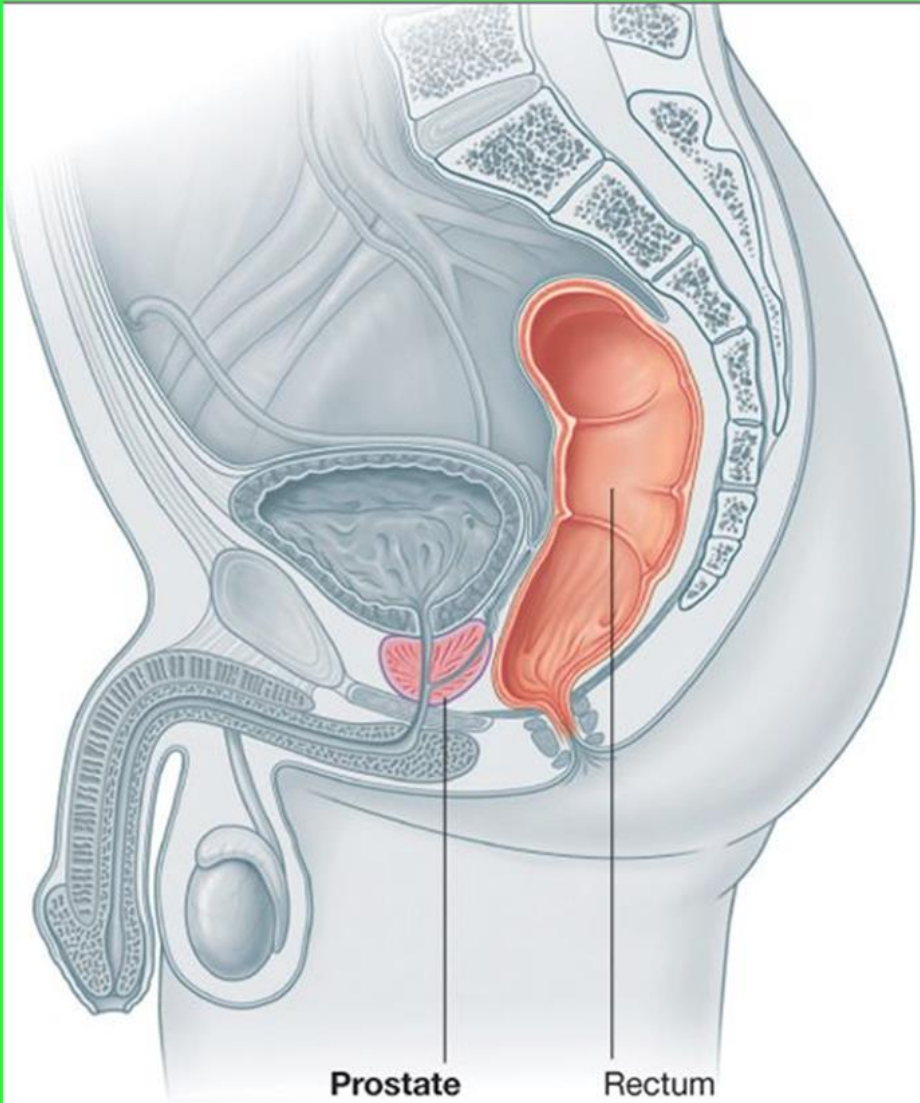
## S4 and S5 and the coccygeal nerve

### The anococcygeal nerves

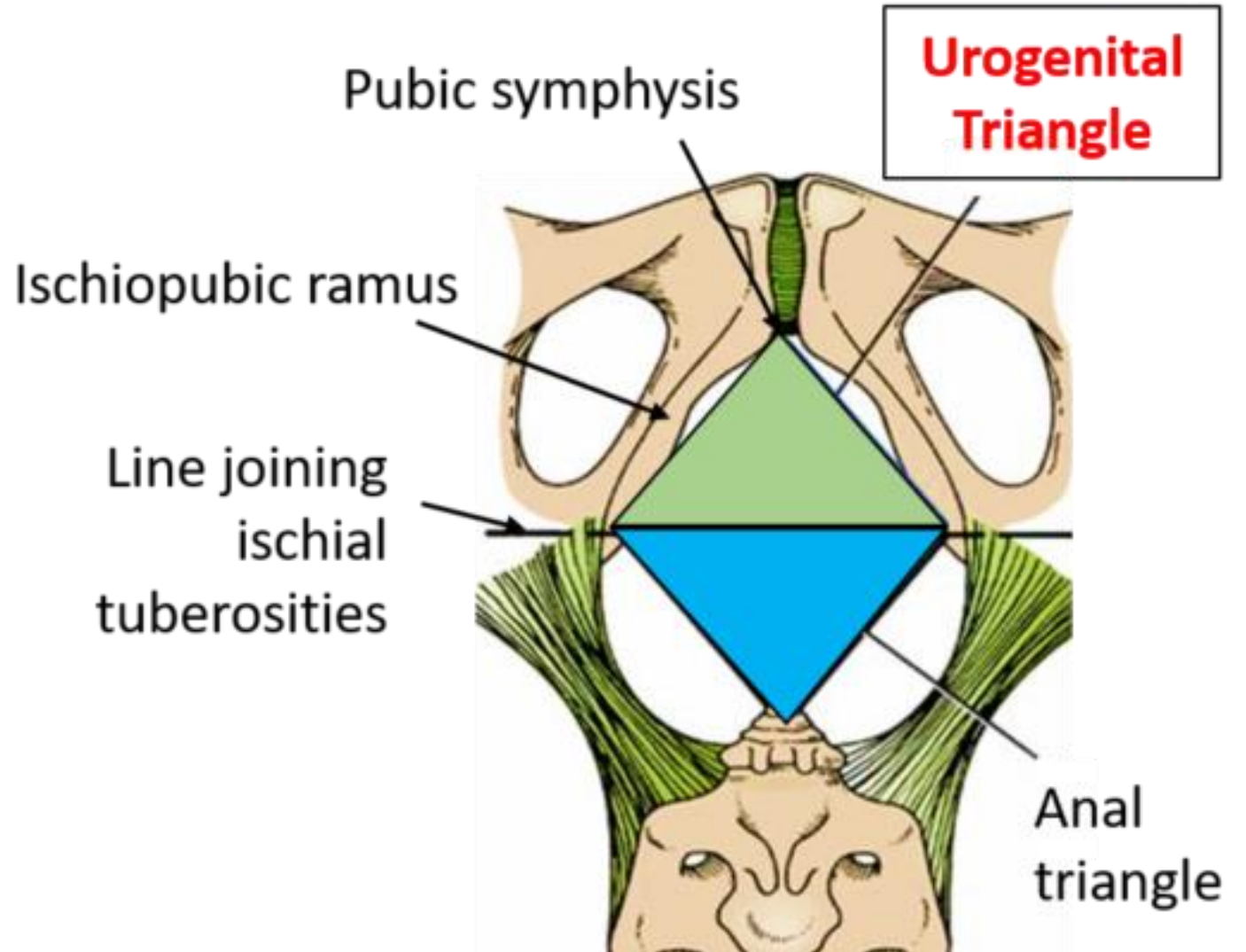


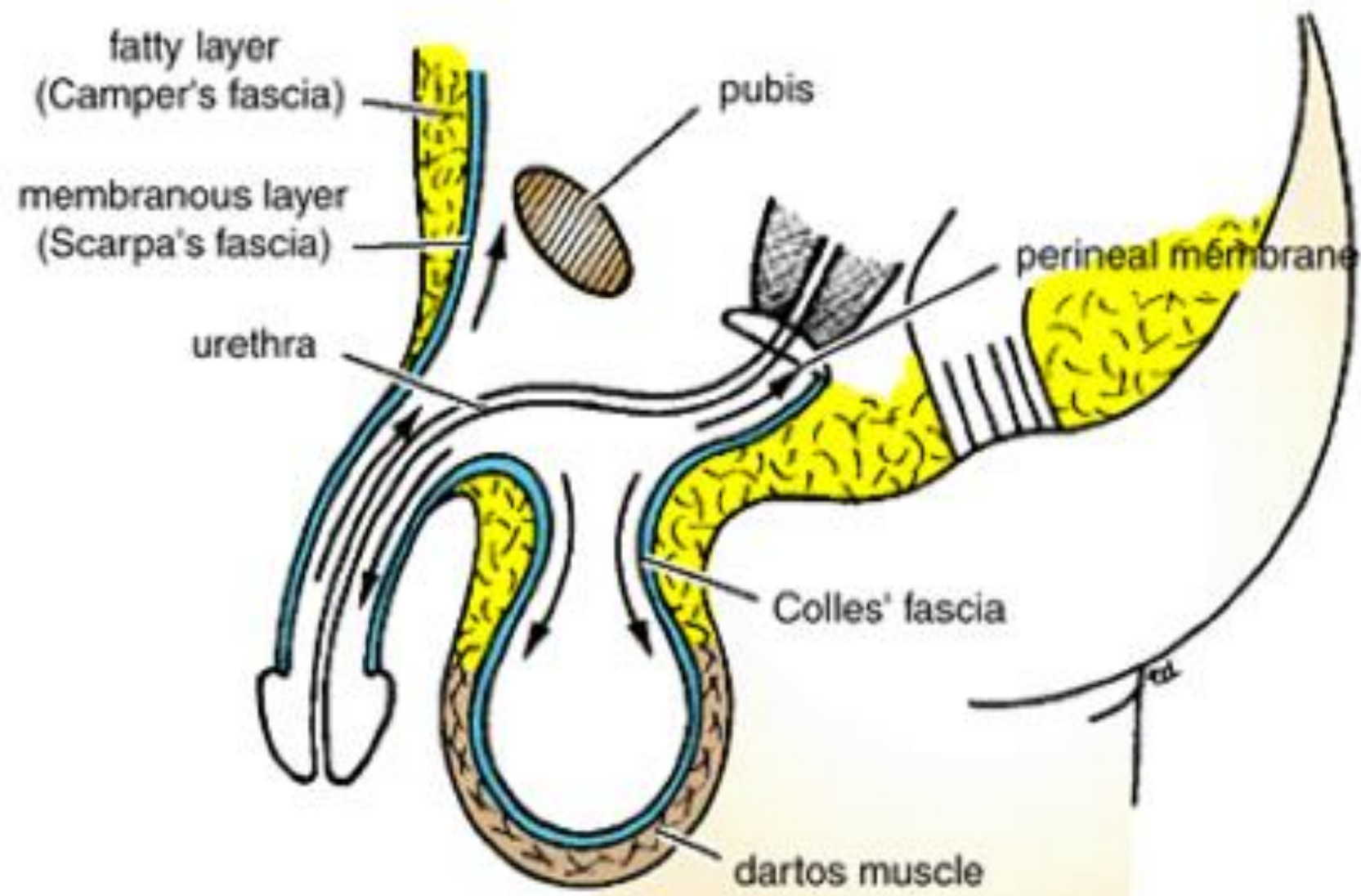
# Pelvic Part of the Sympathetic Trunk



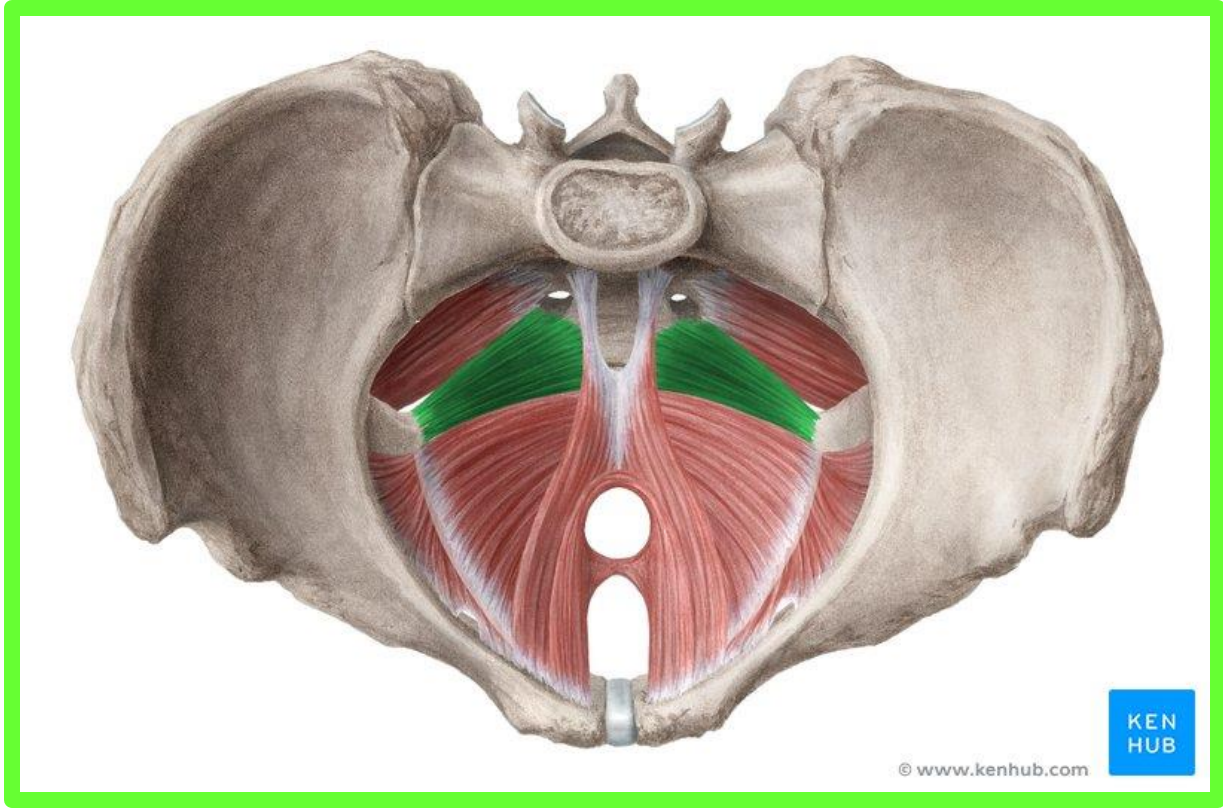
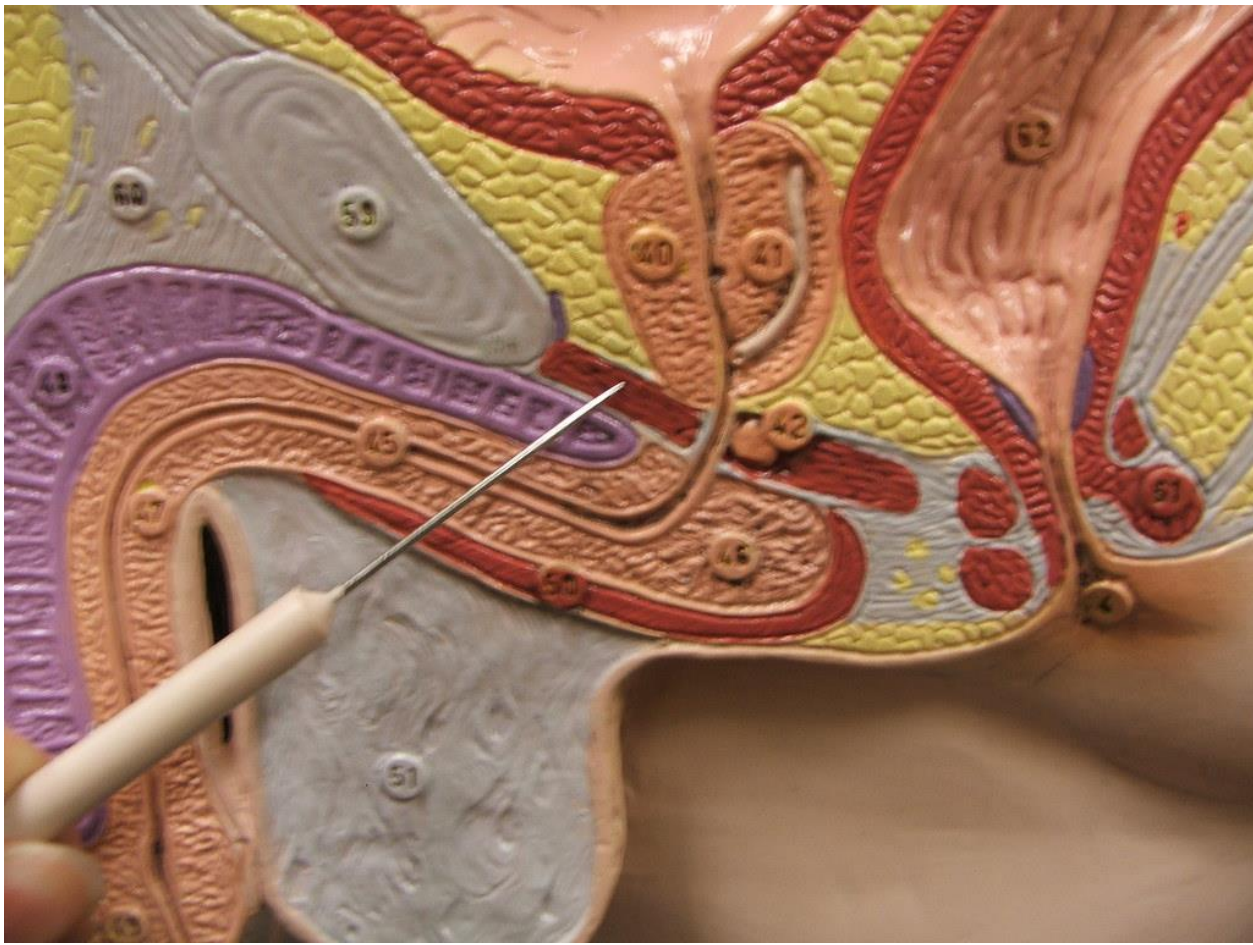


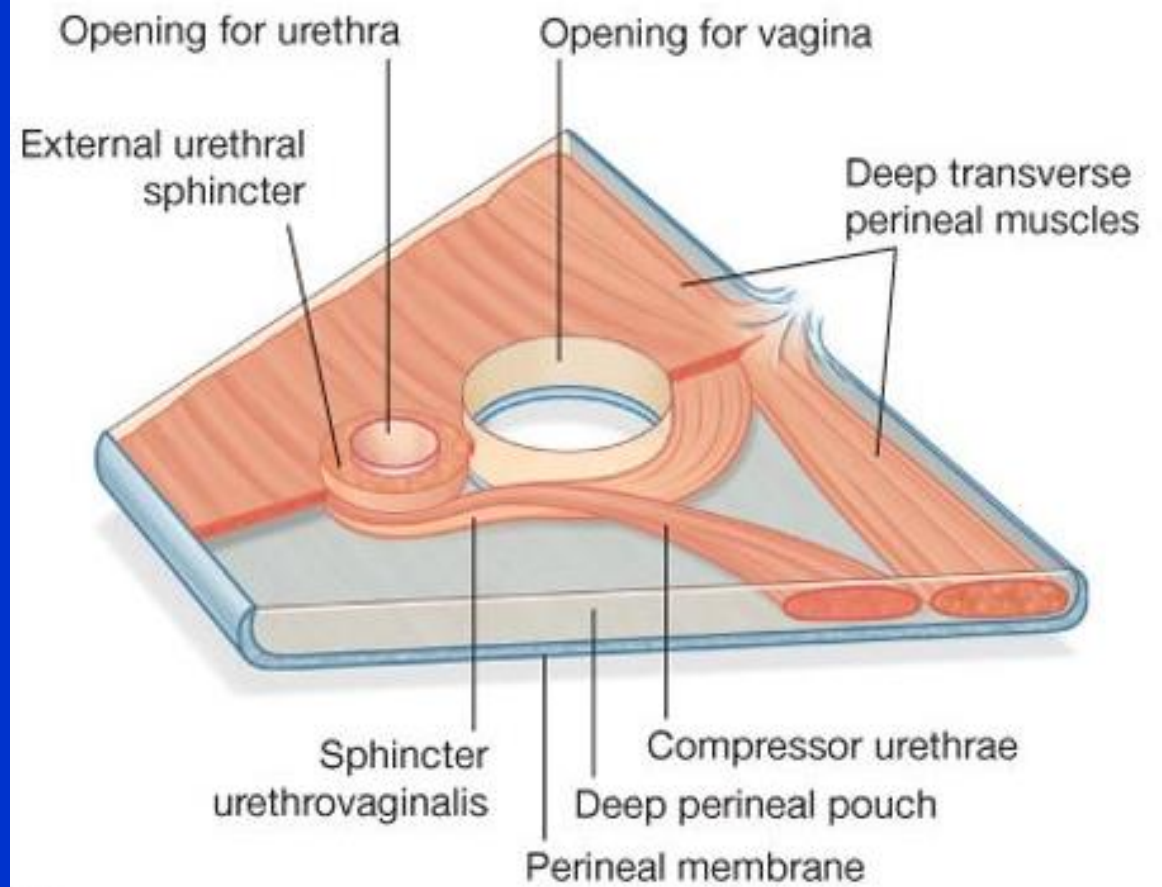
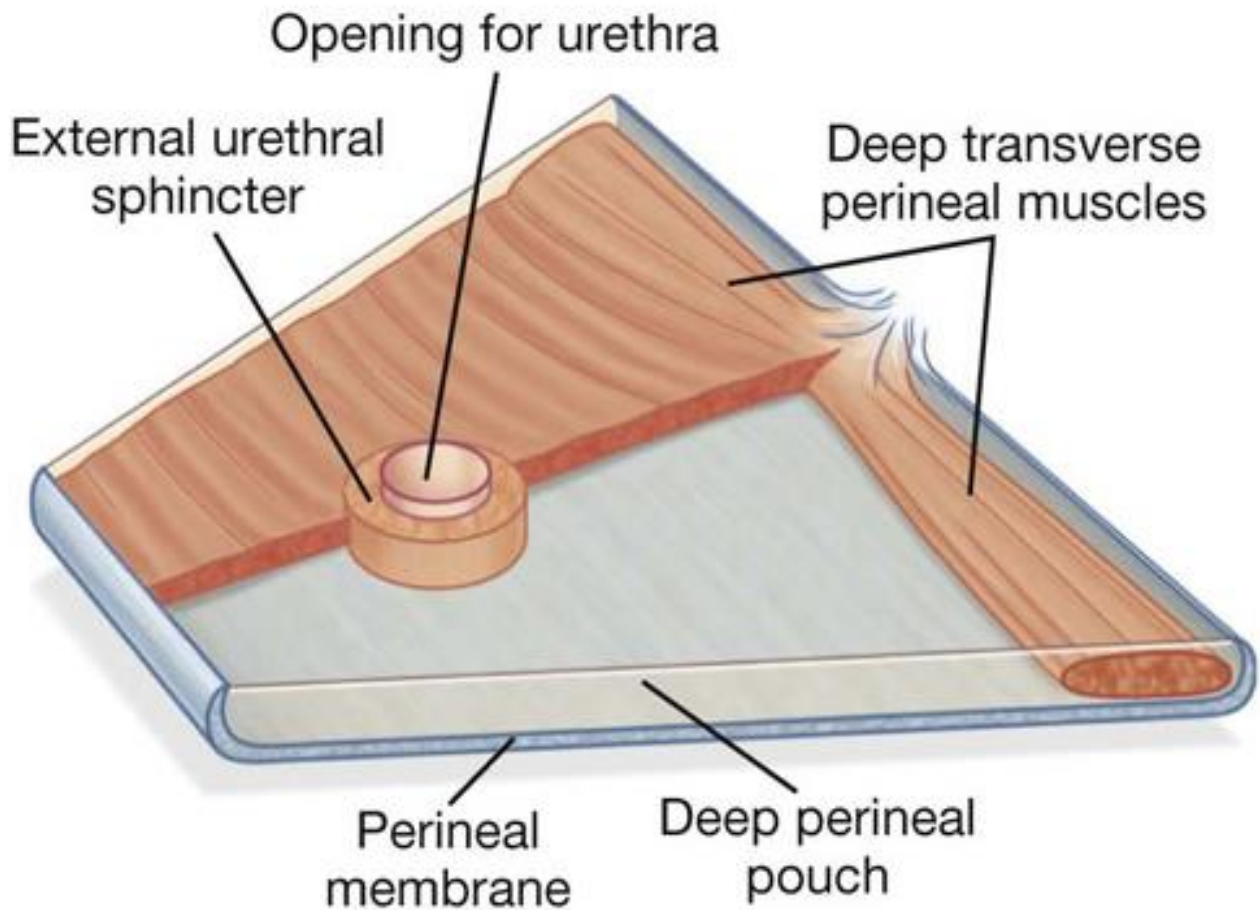
Drake: Gray's Anatomy for Students, 2nd Edition.

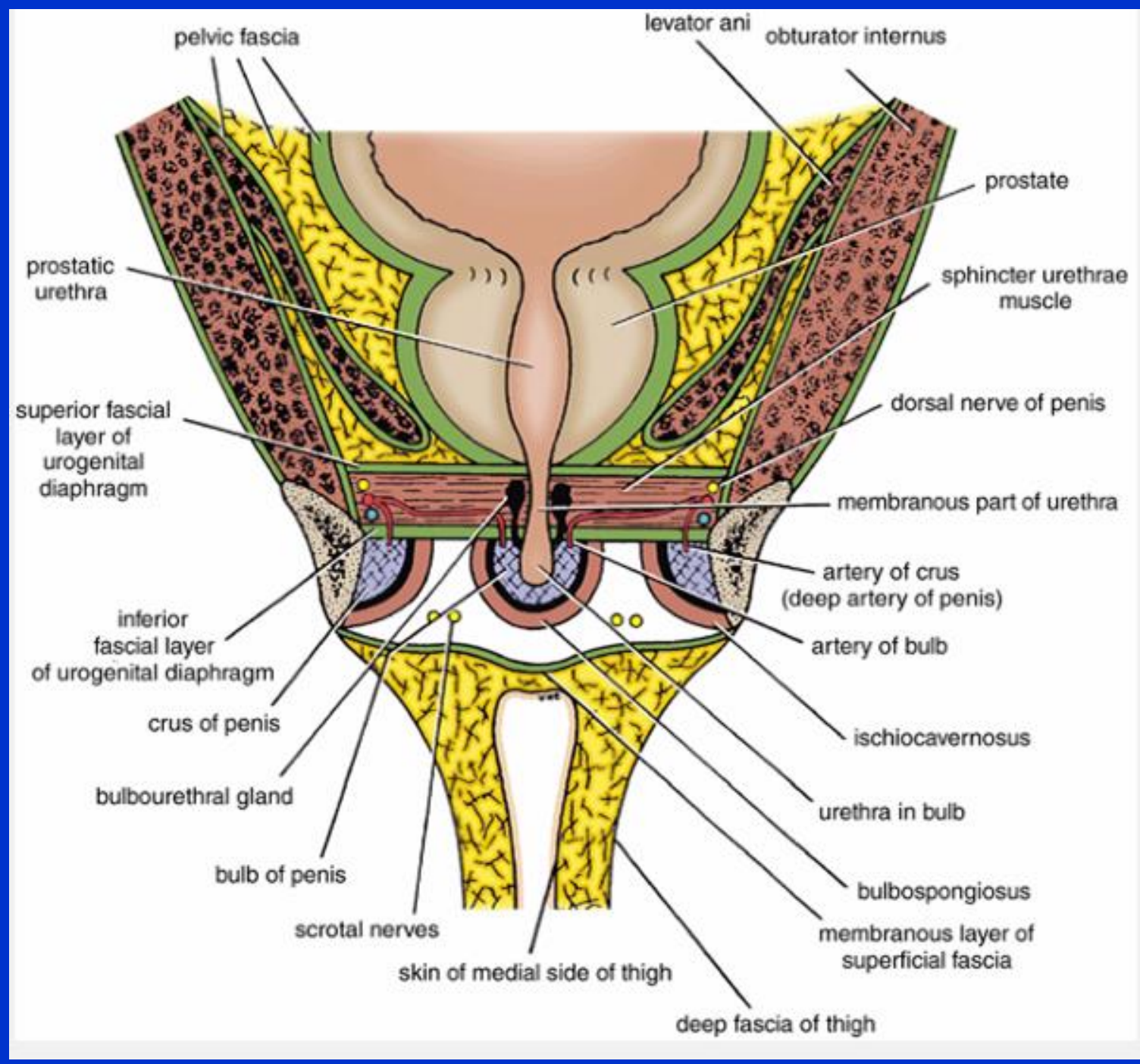


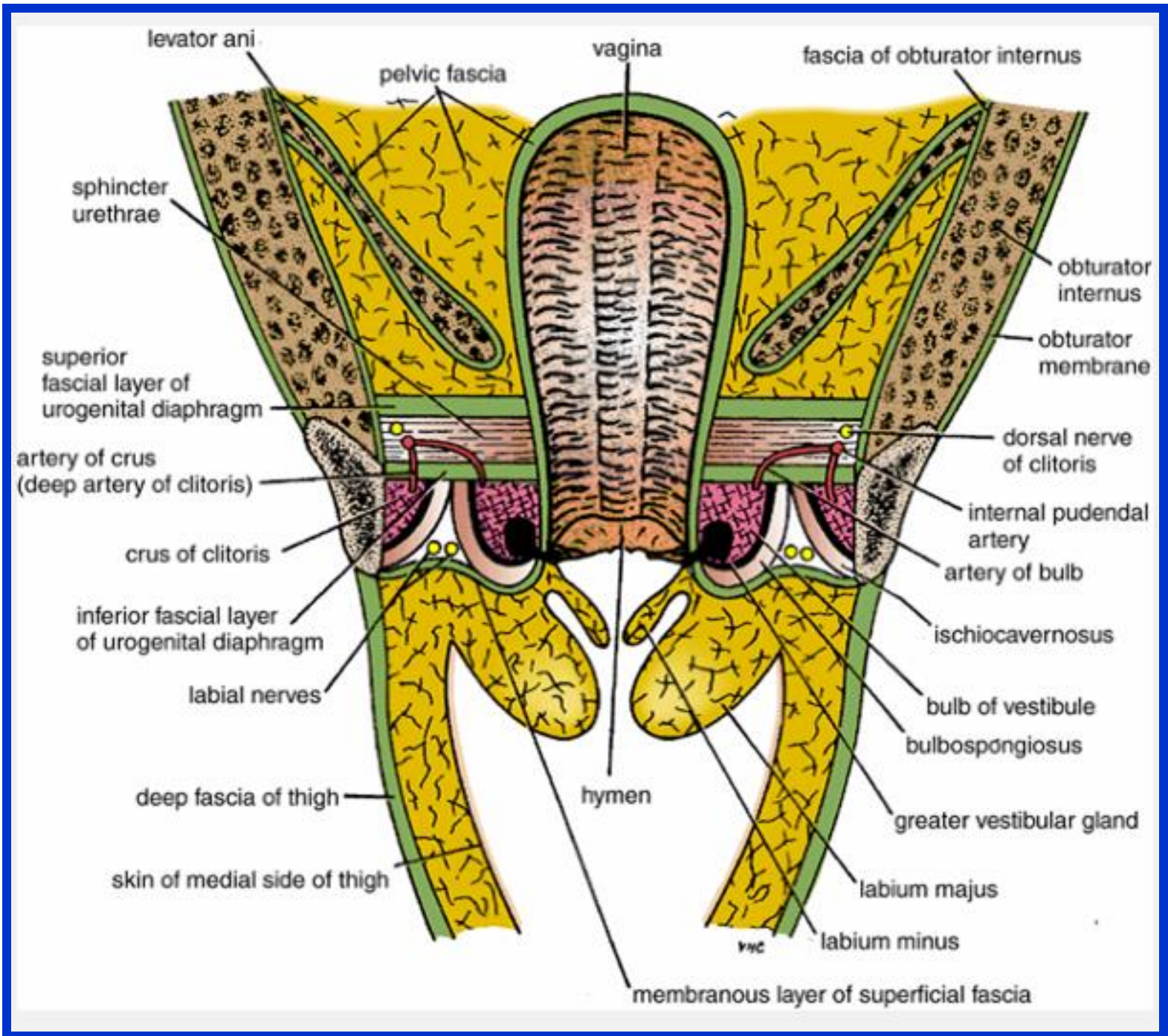


**B**

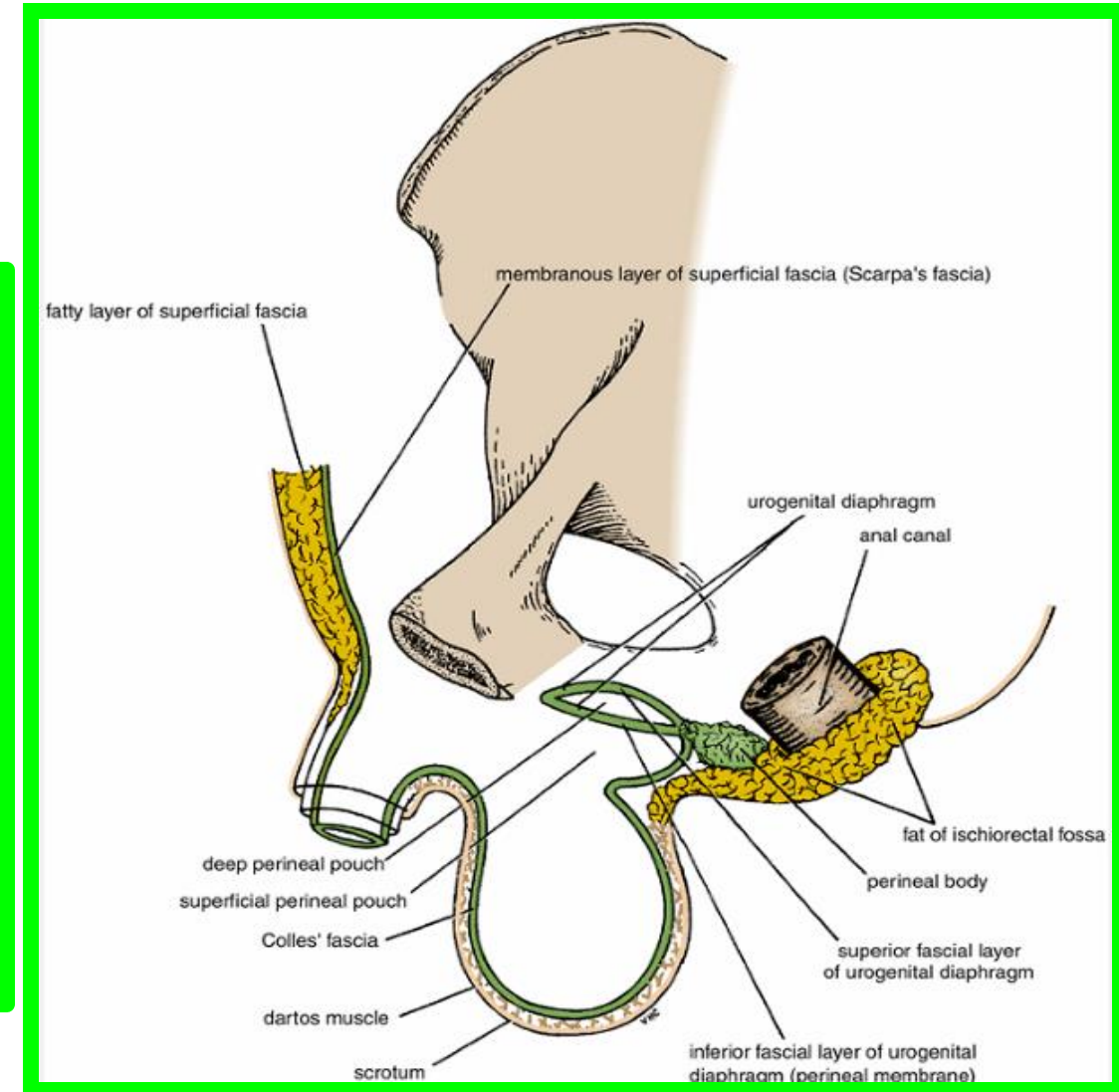
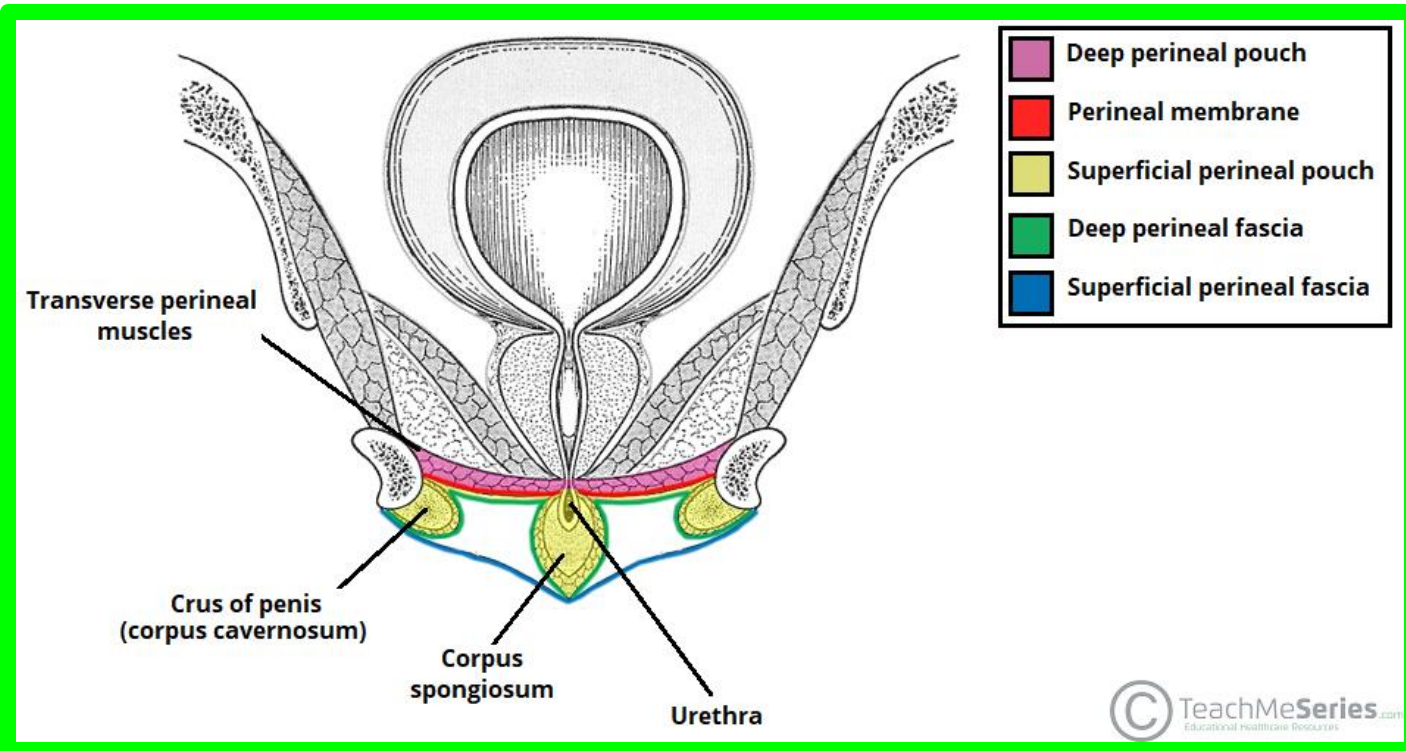




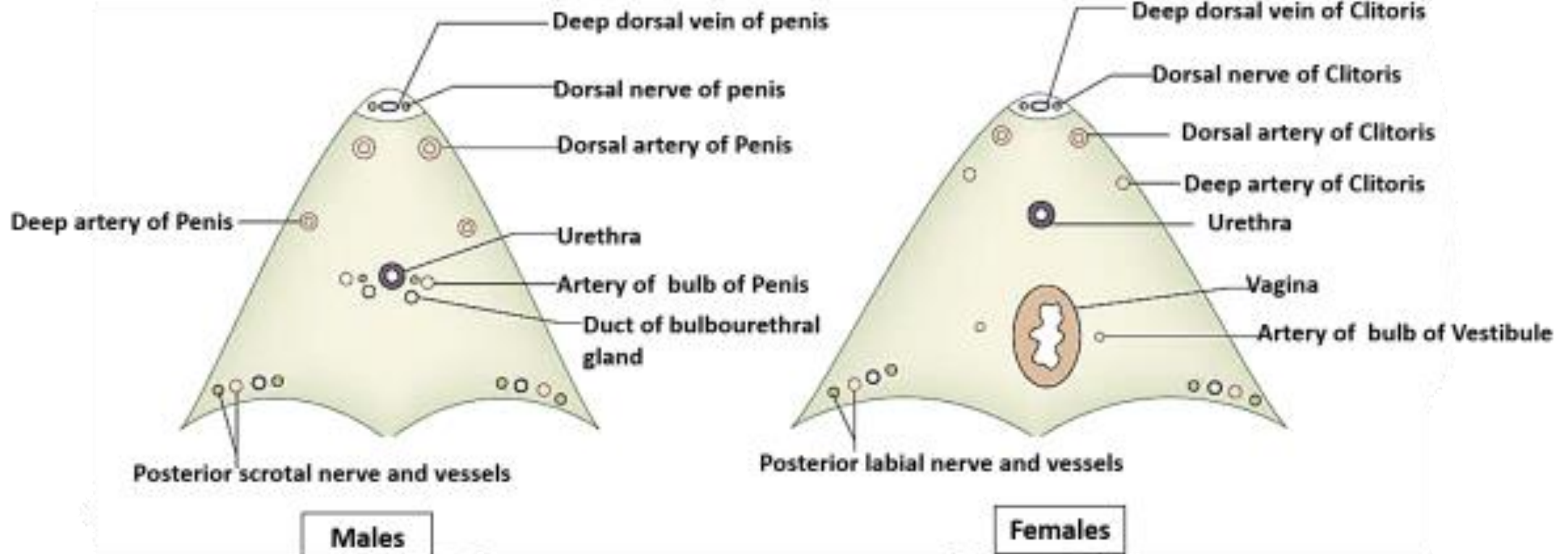


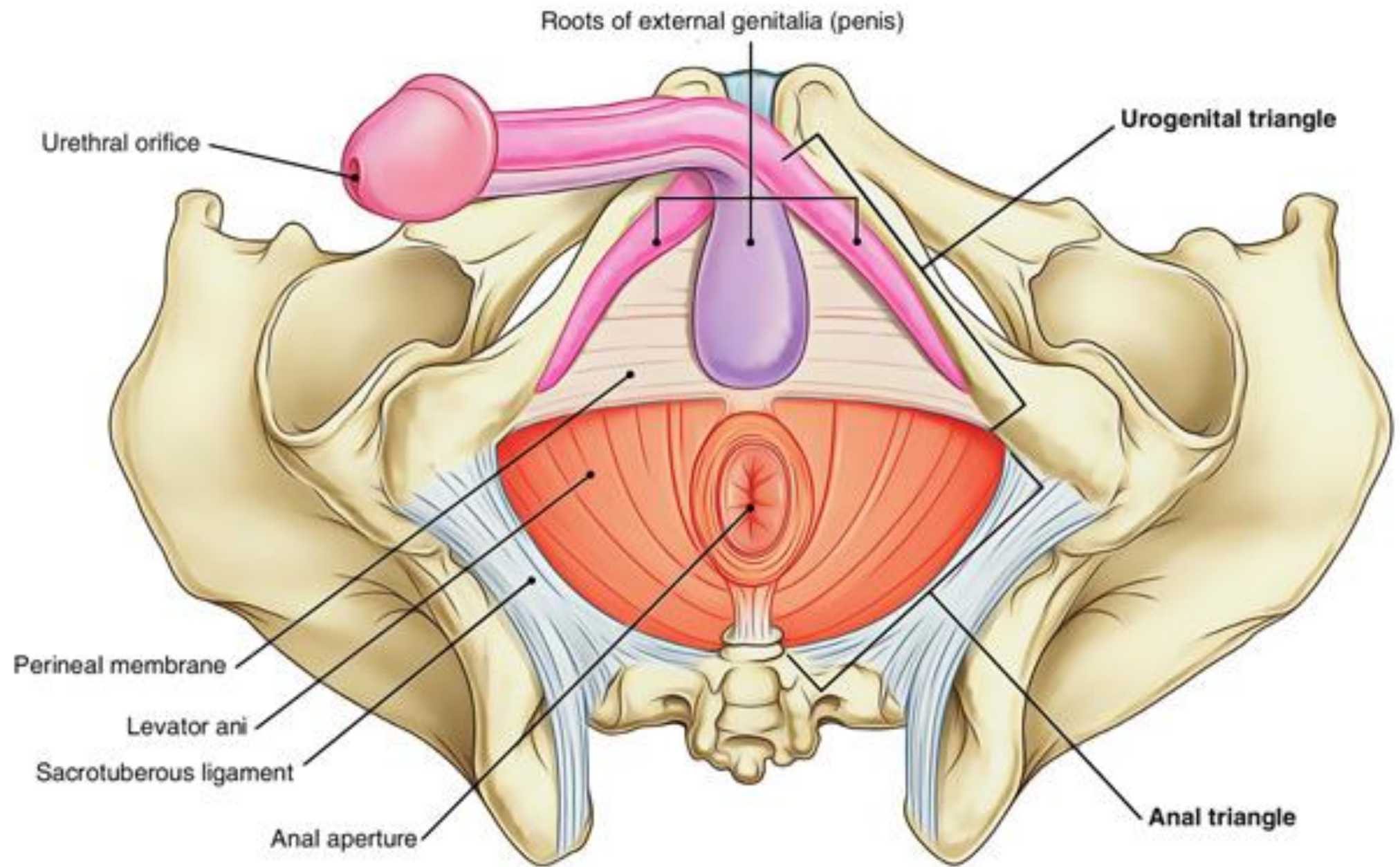


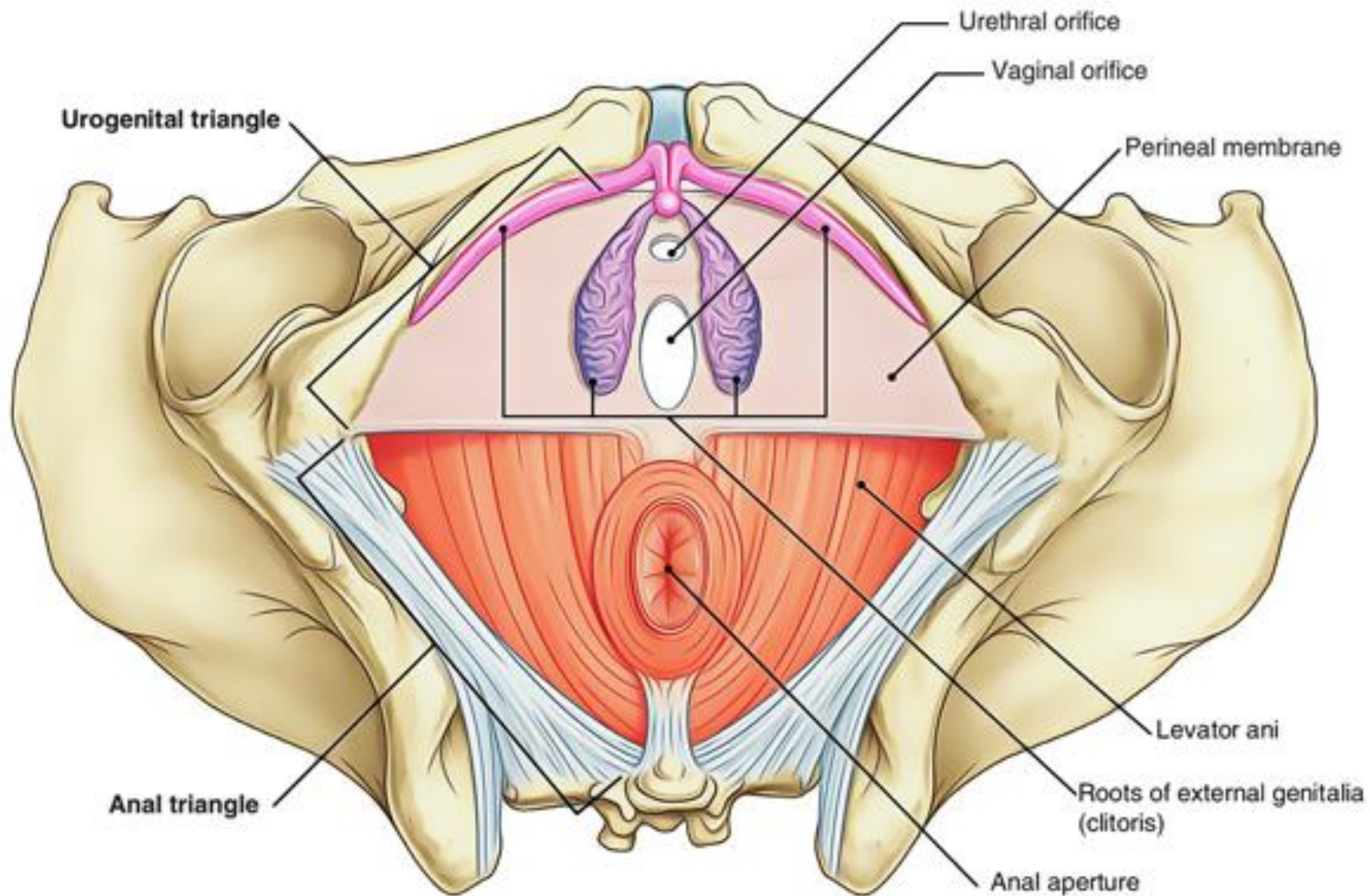
# ❑ Superficial Perineal Pouch



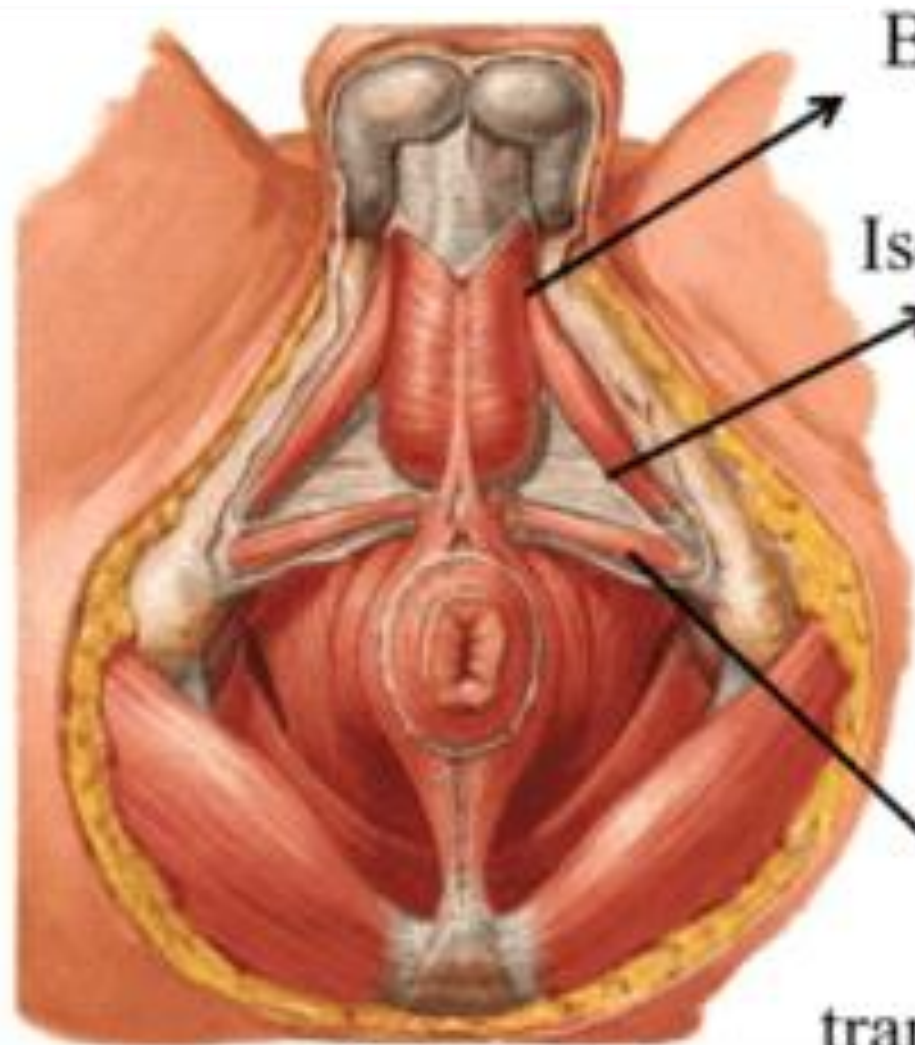
### Structures Piercing Perineal Membrane





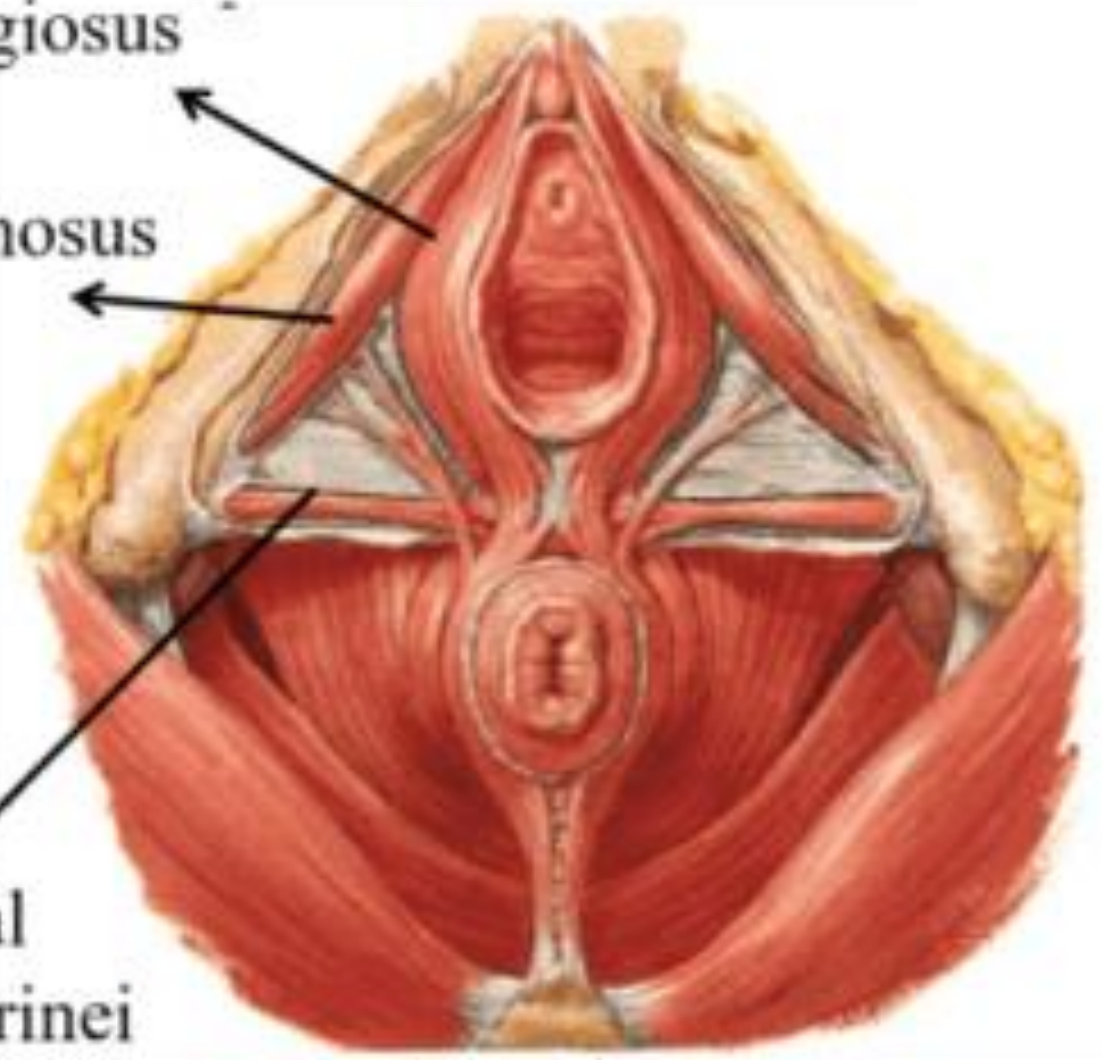


**Muscles in Superficial Perineal Pouch**



**MALES**

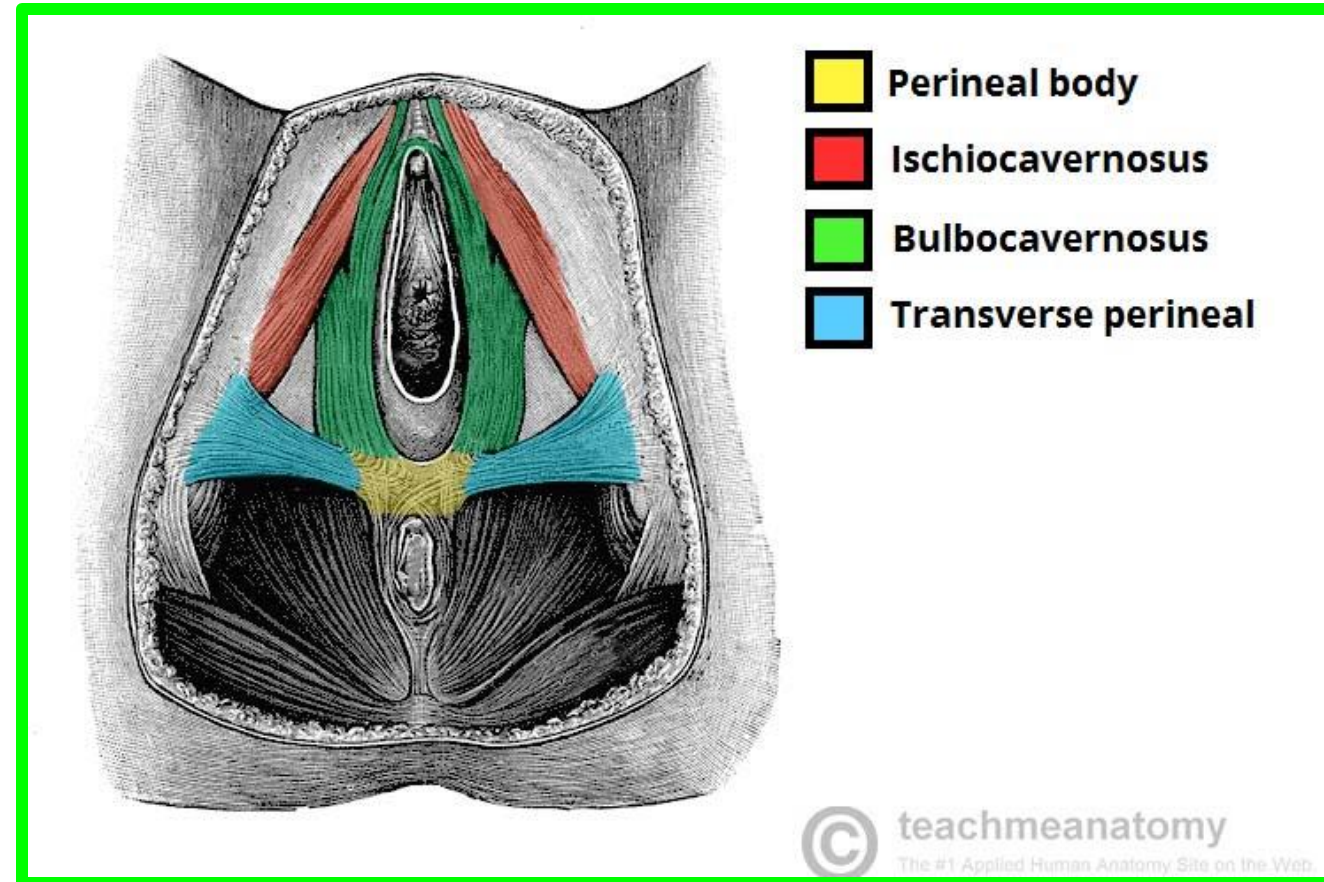
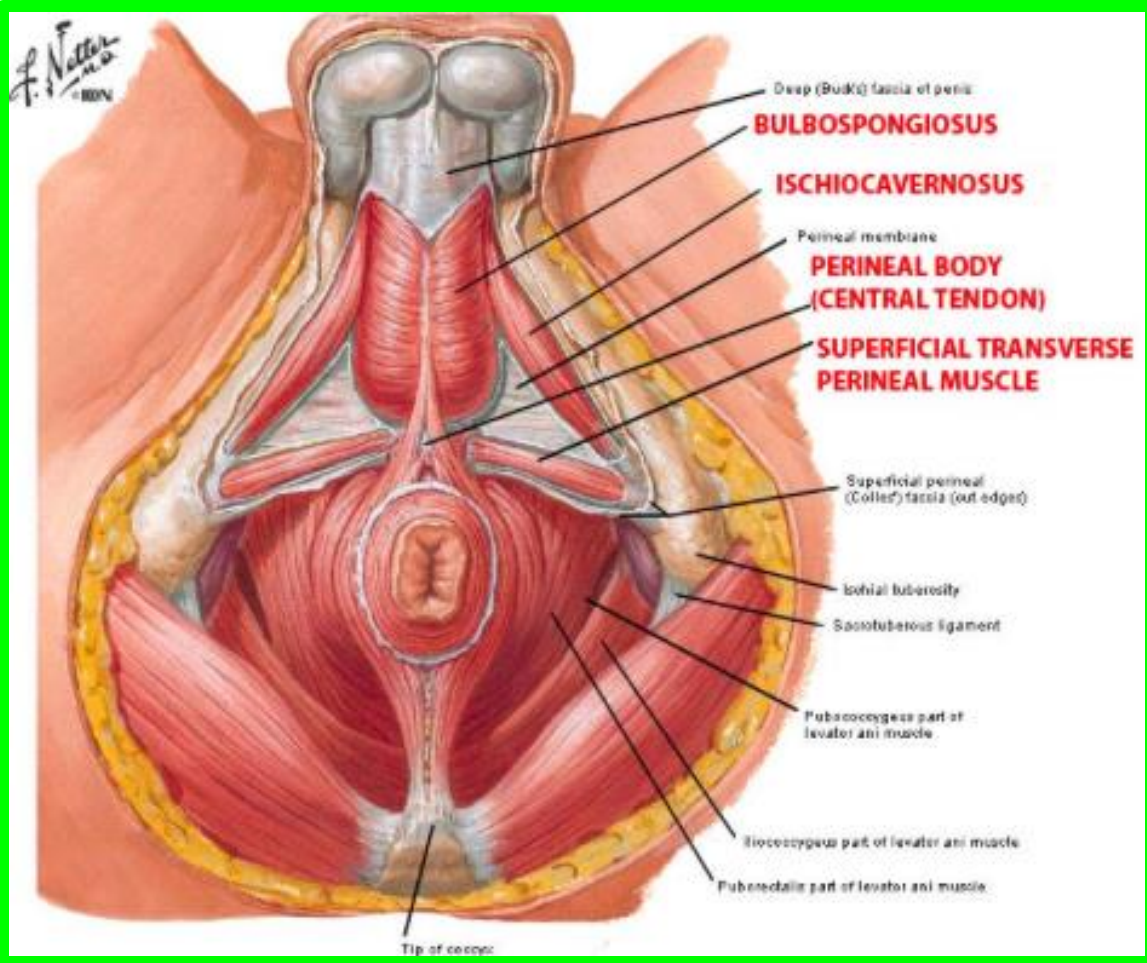
Bulbospongiosus  
Ischiocavernosus  
Superficial transverse perineal

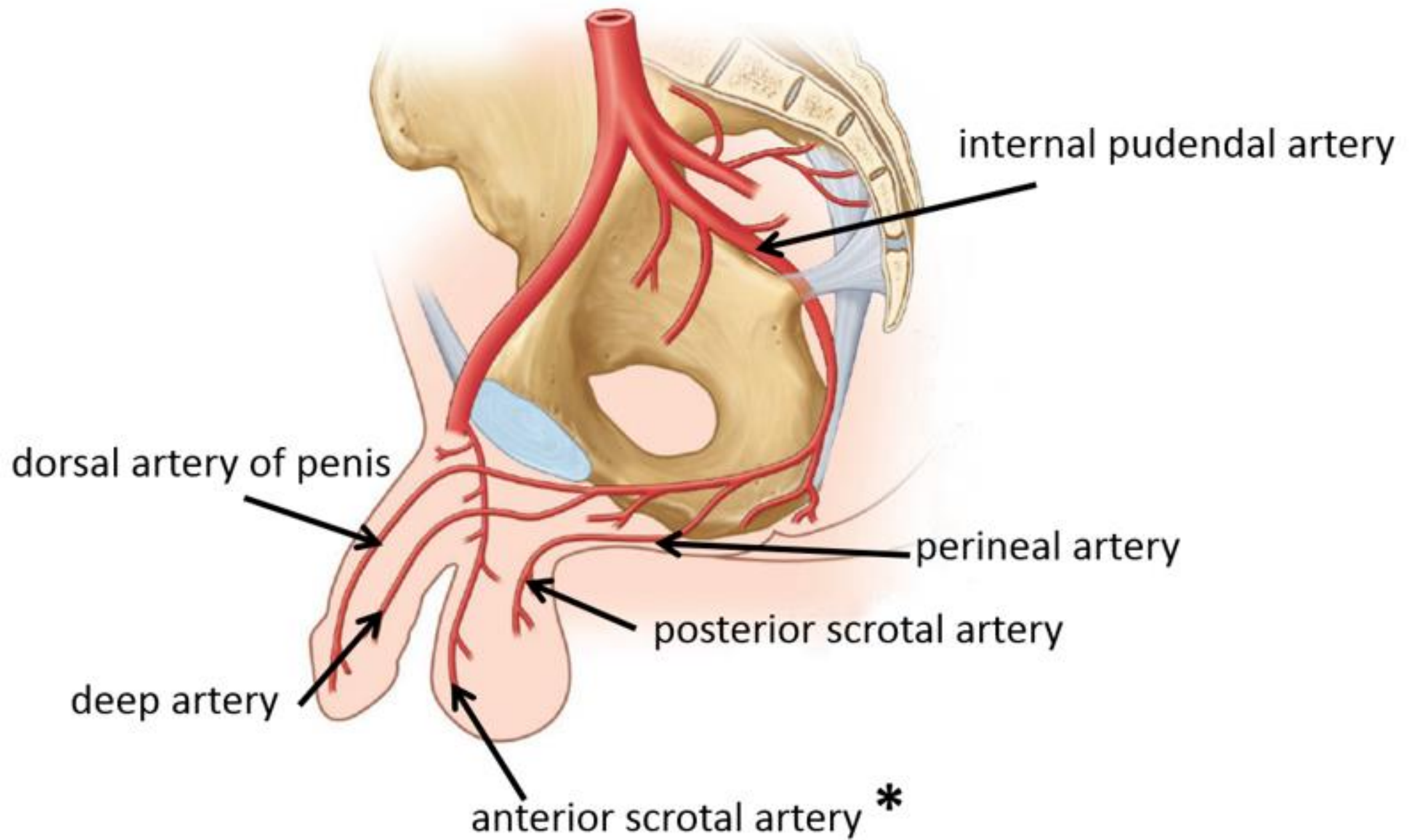


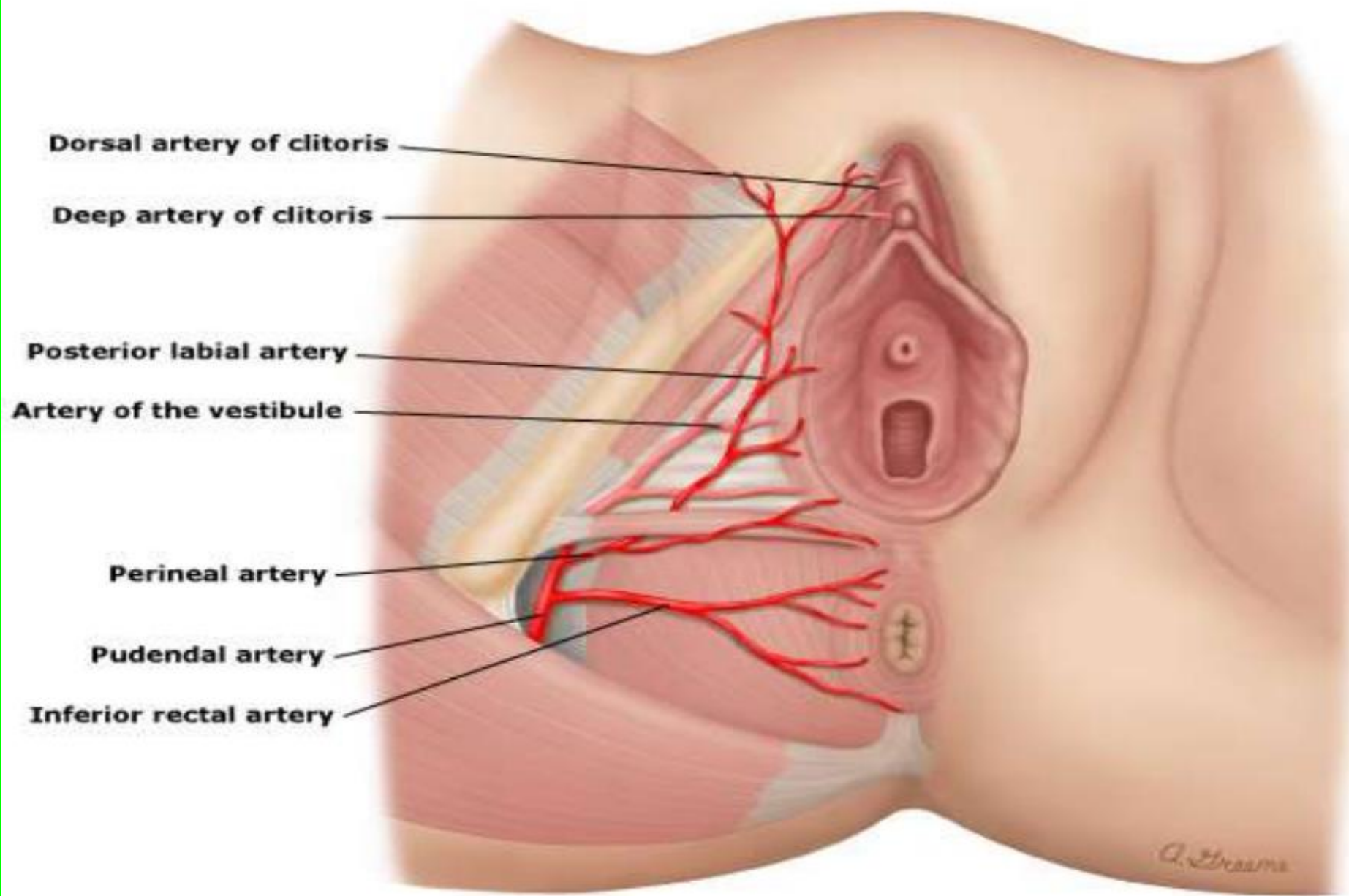
**FEMALES**

# • Perineal Body

is a median fibromuscular pyramidal mass







**Dorsal artery of clitoris**

**Deep artery of clitoris**

**Posterior labial artery**

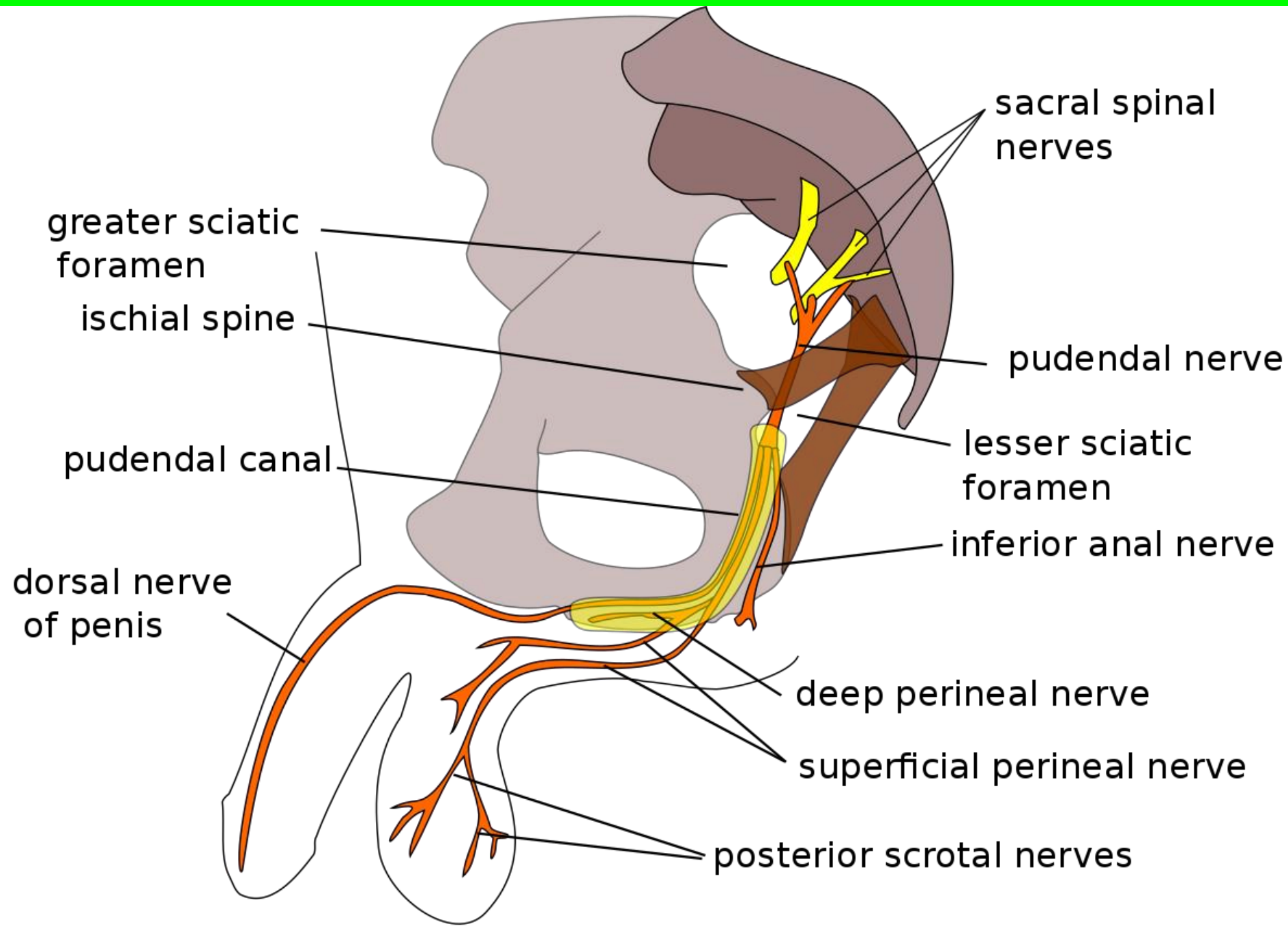
**Artery of the vestibule**

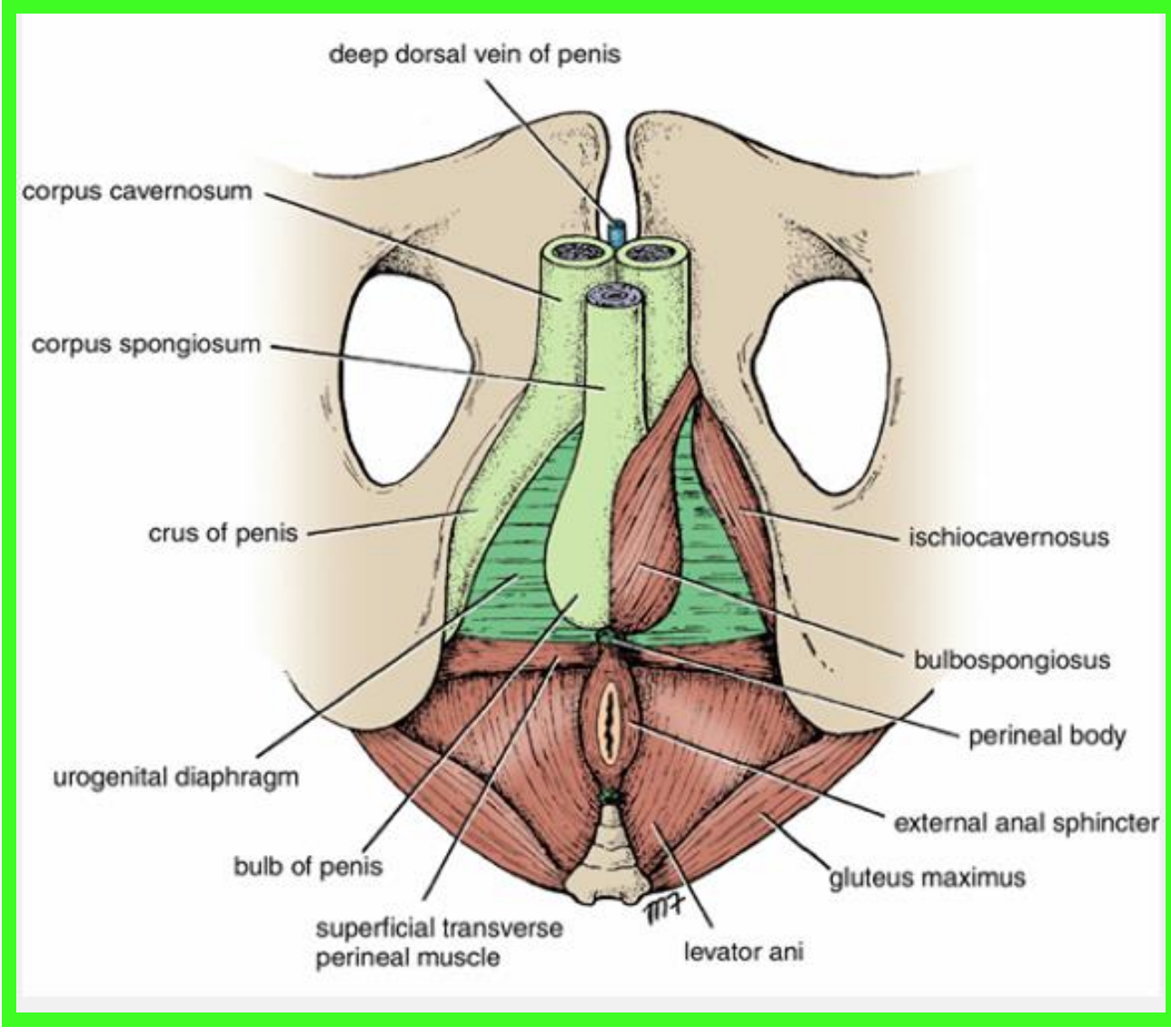
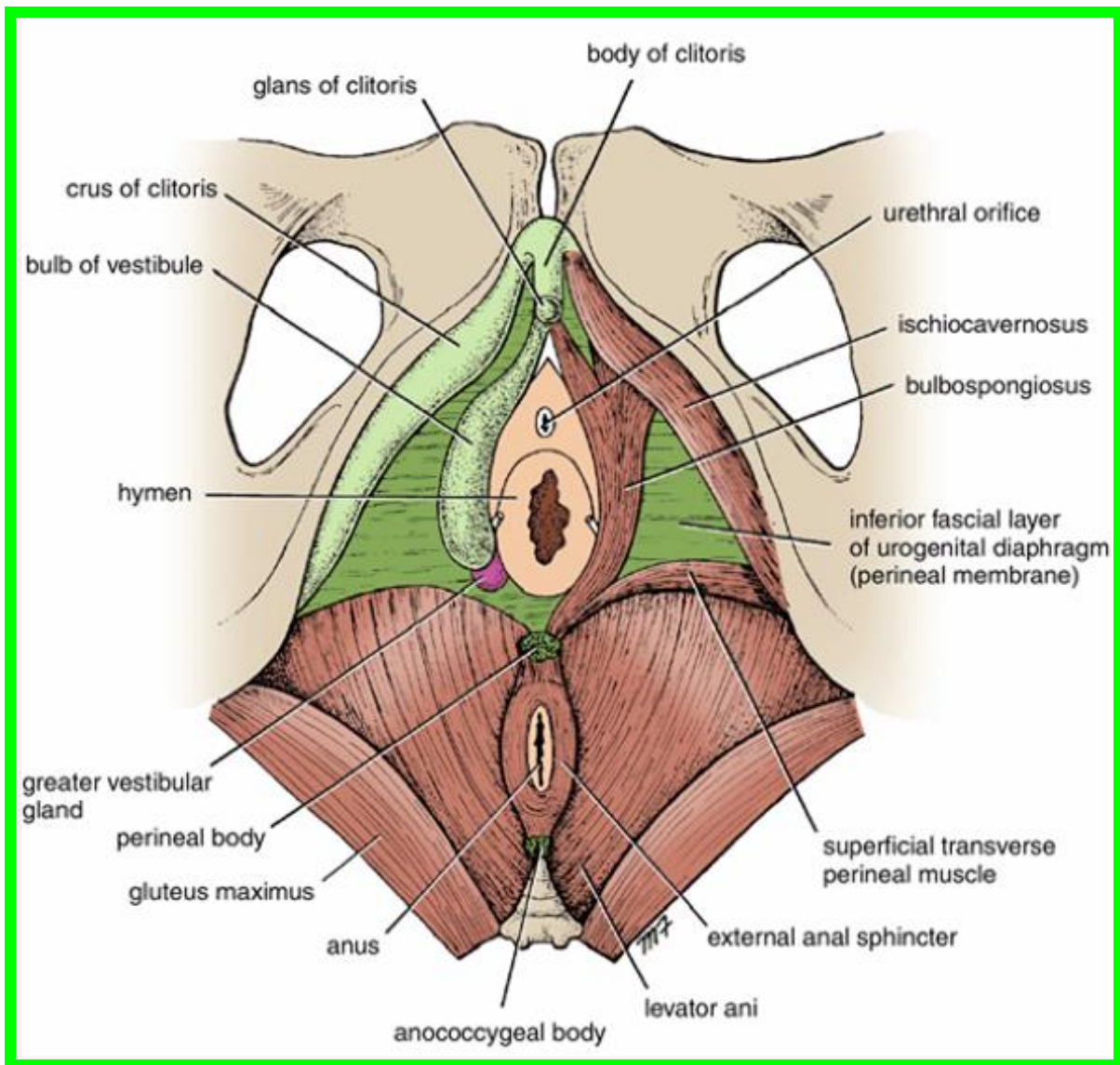
**Perineal artery**

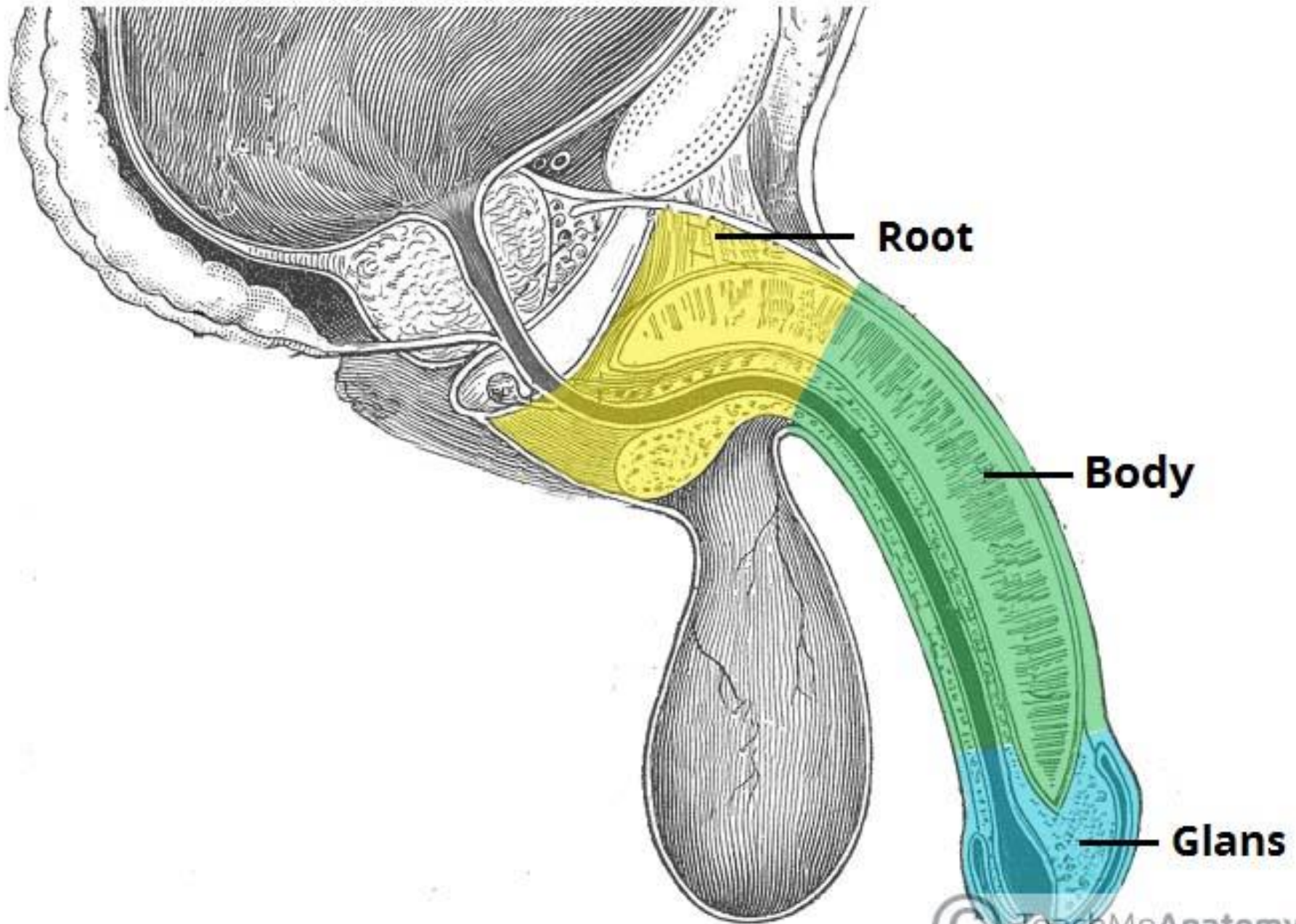
**Pudendal artery**

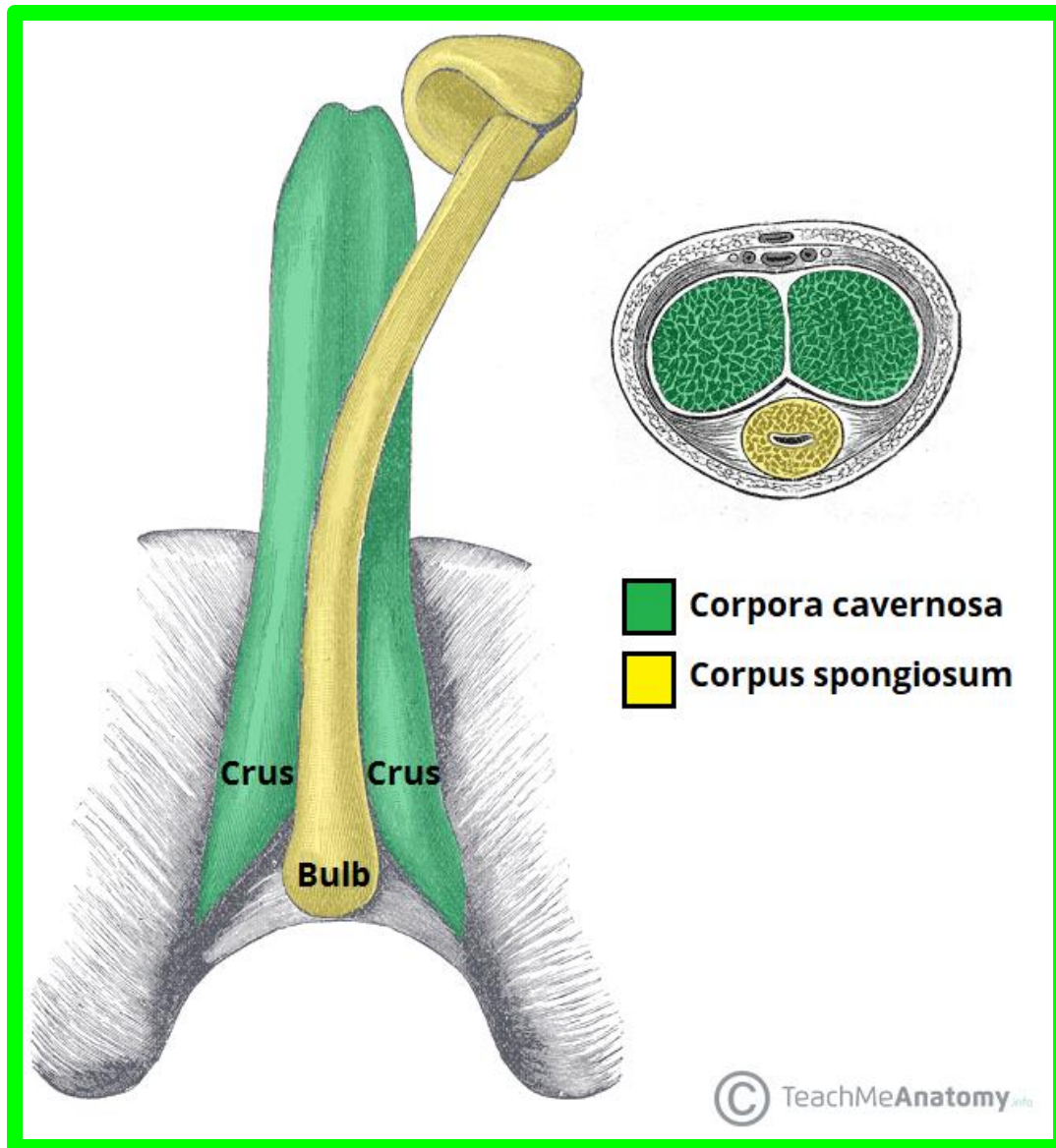
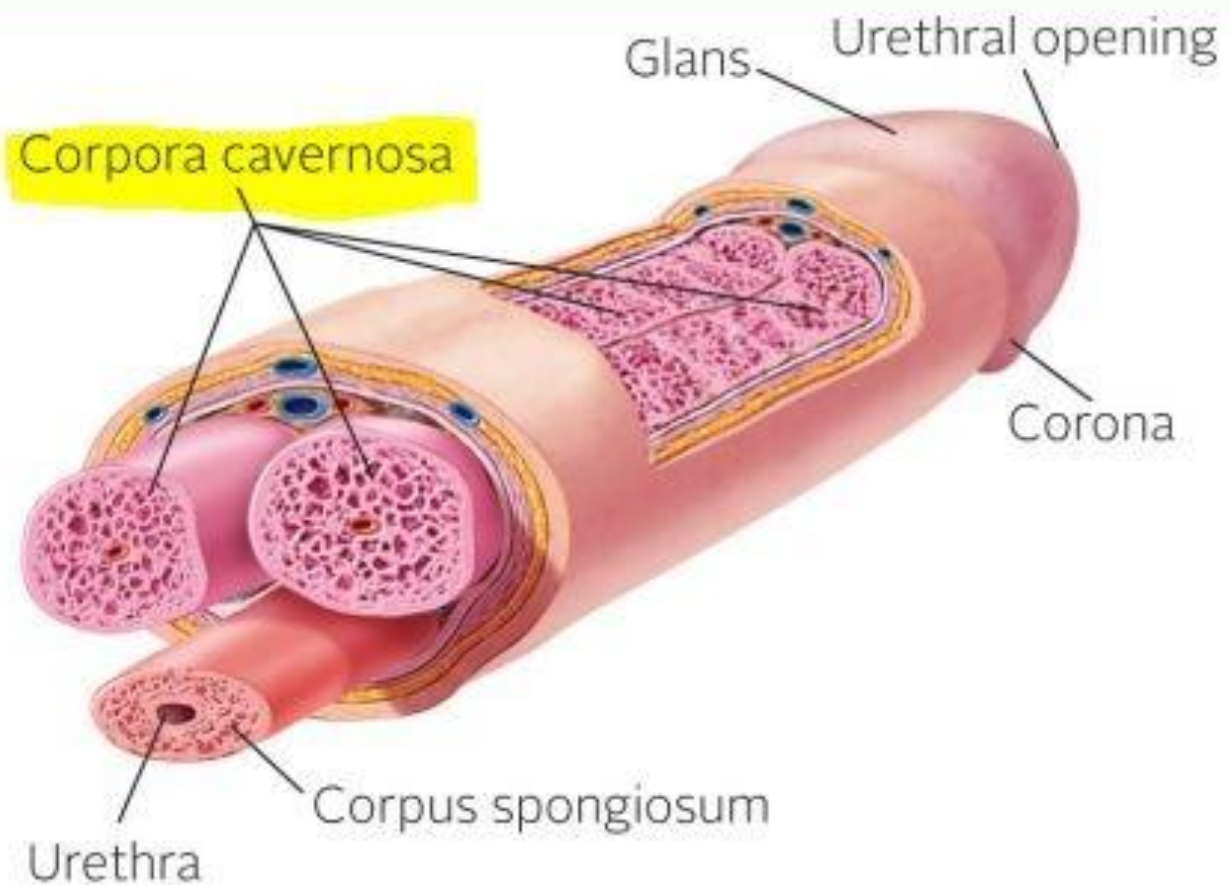
**Inferior rectal artery**

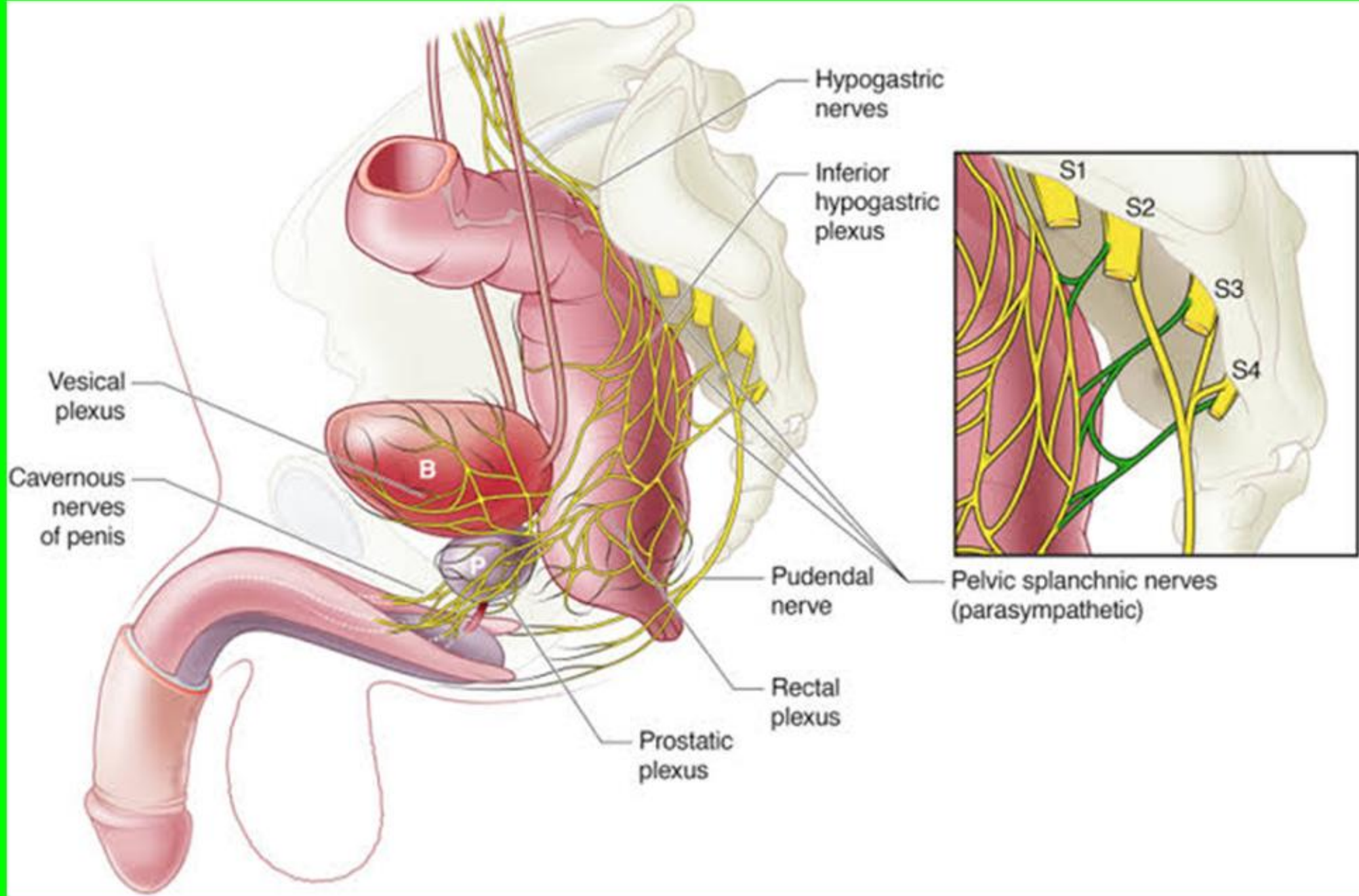
*A. Braune*

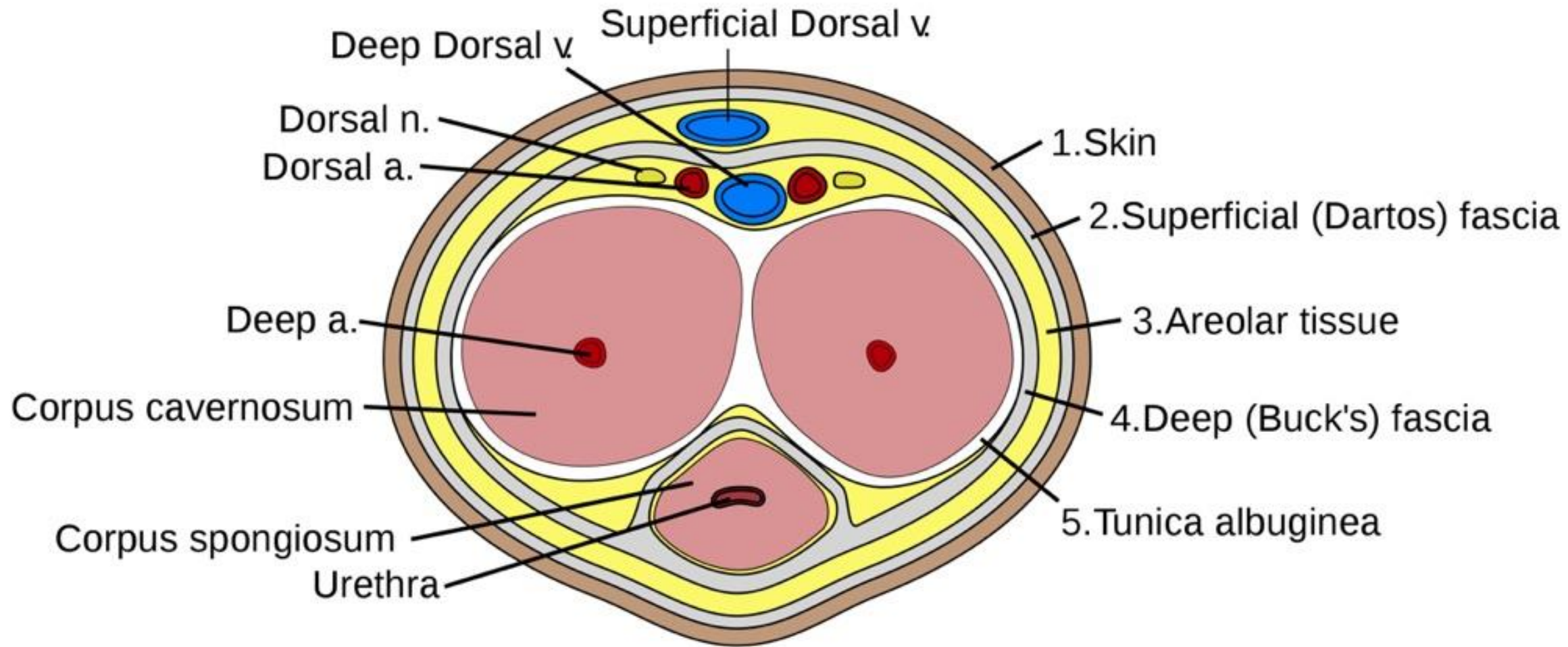












Superficial dorsal vein

Dorsal nerve

Deep dorsal artery

Deep dorsal vein

Deep artery

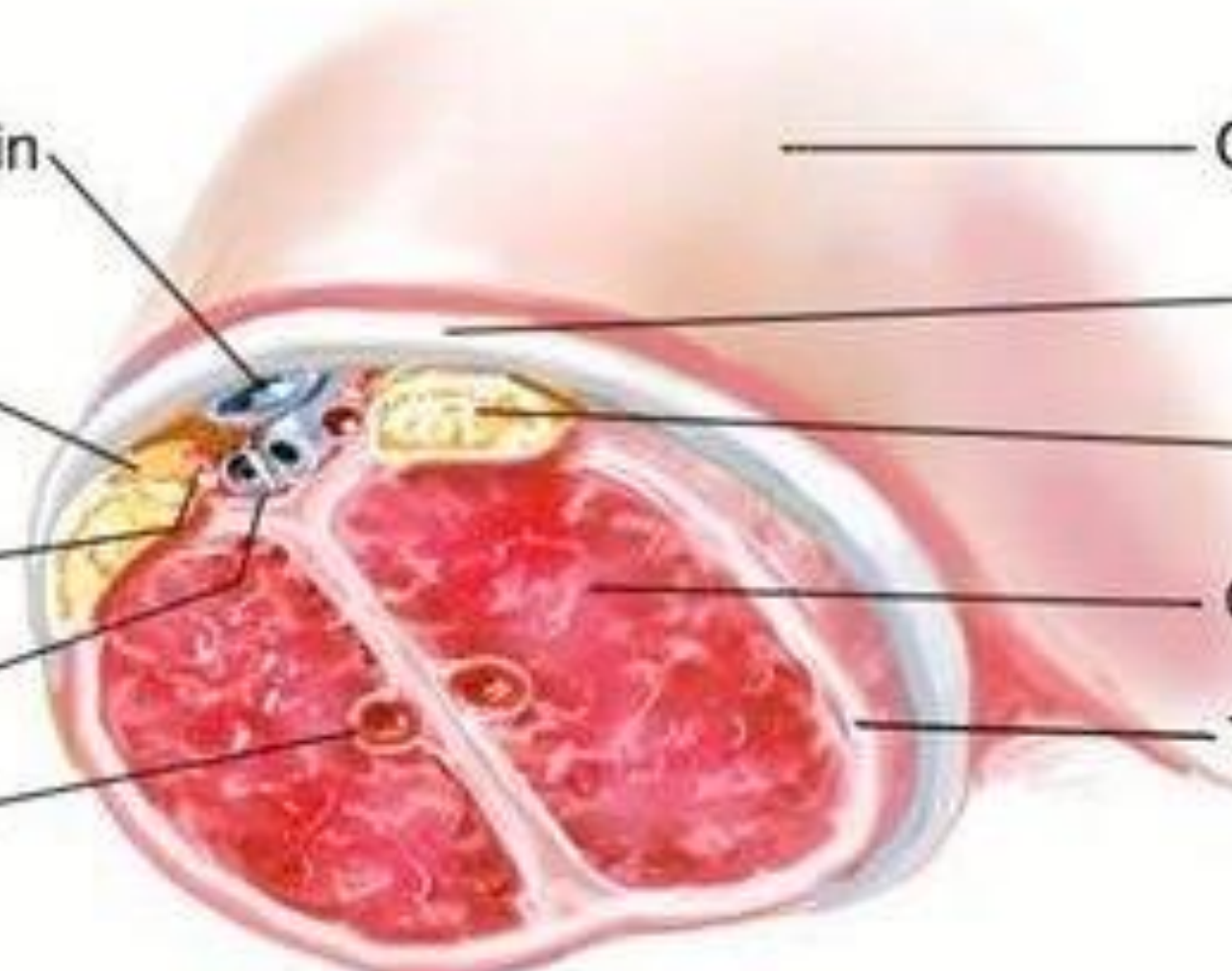
Clitoral hood skin

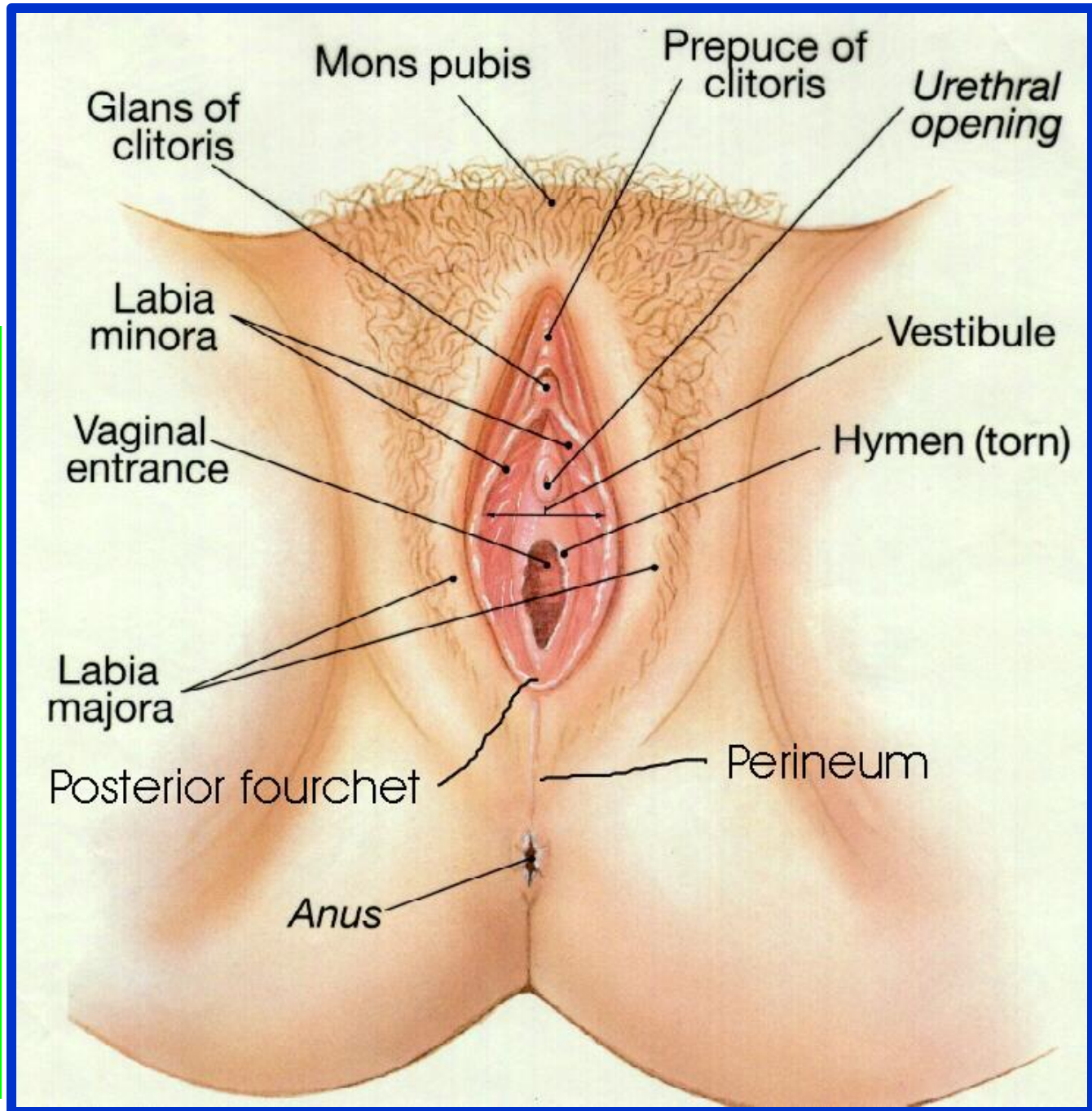
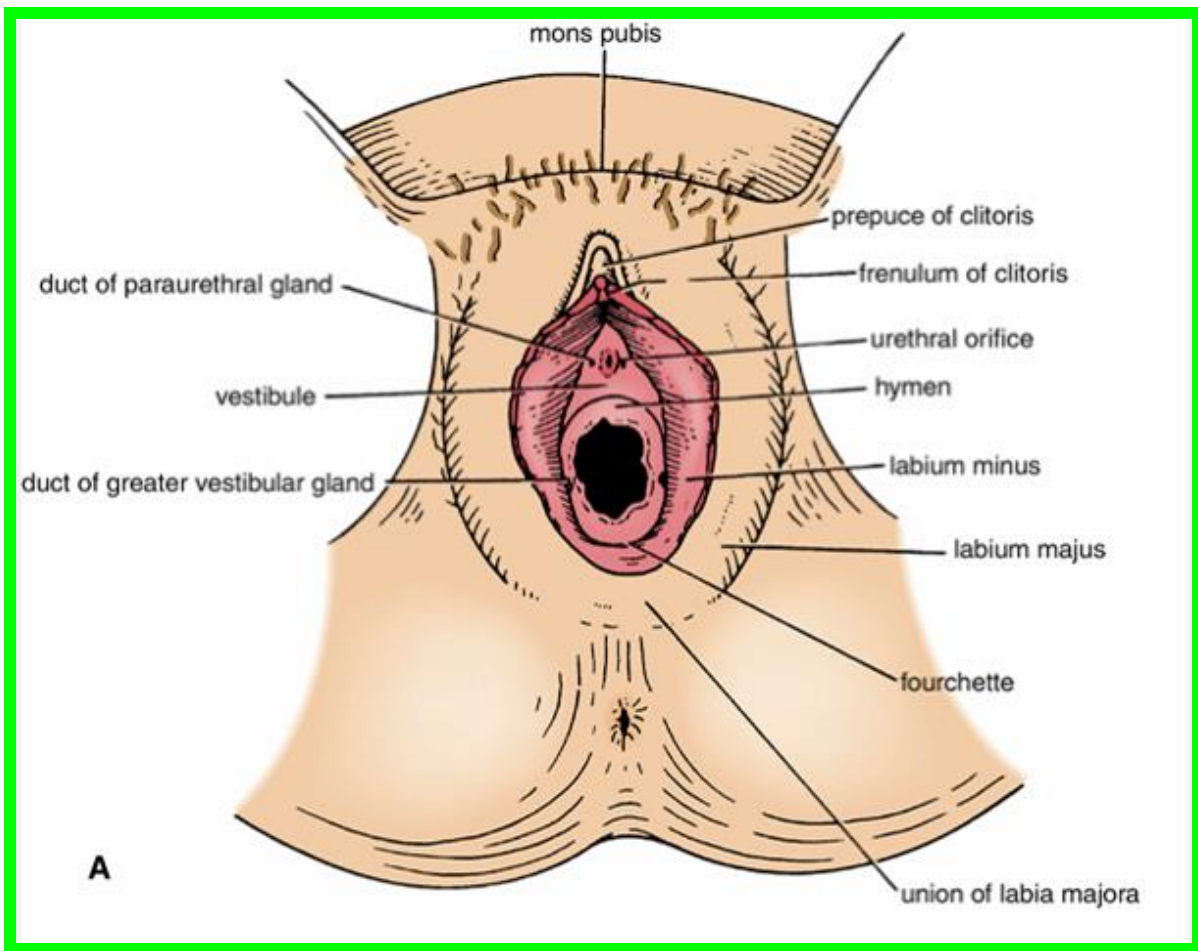
Clitoral fascia

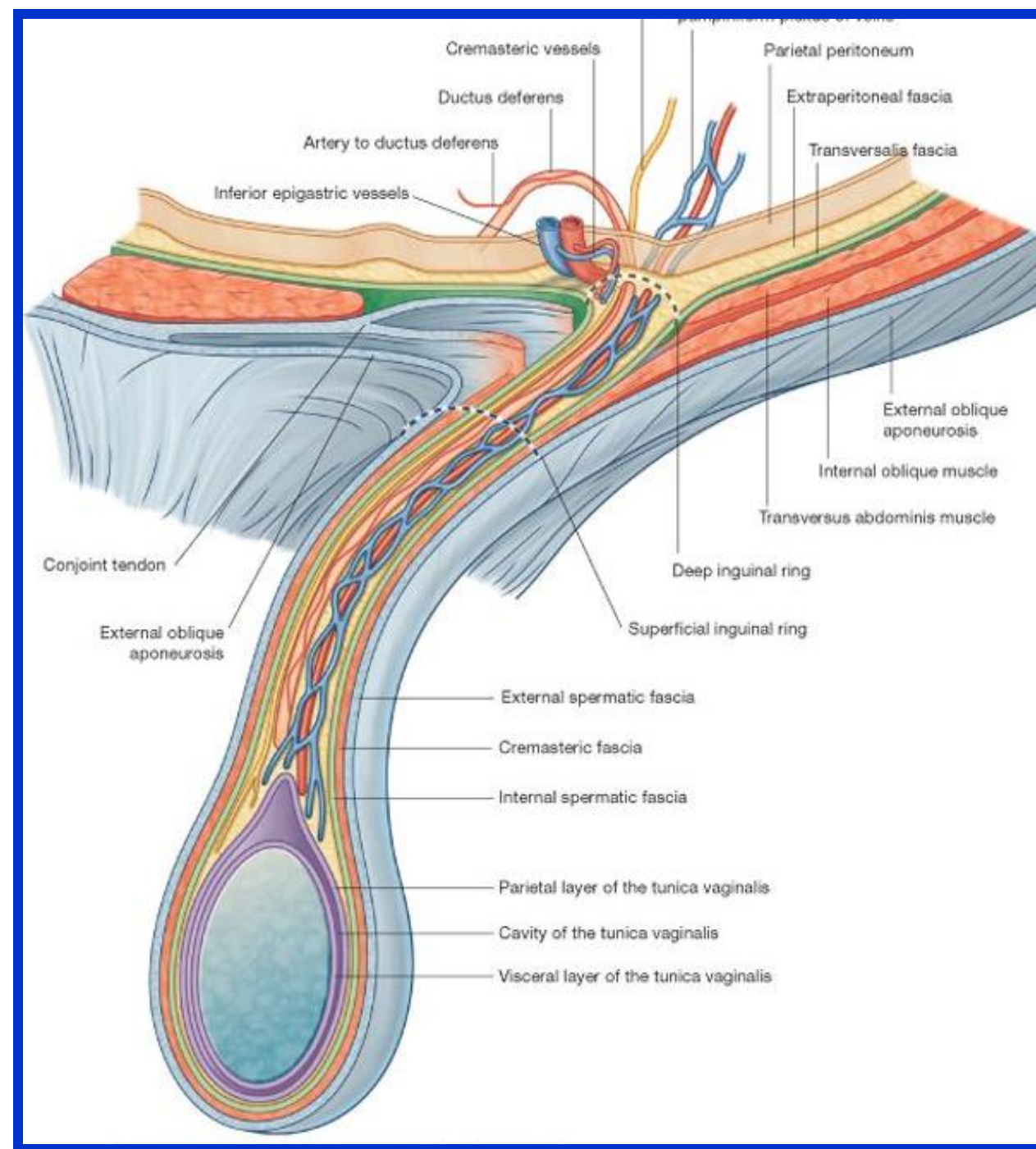
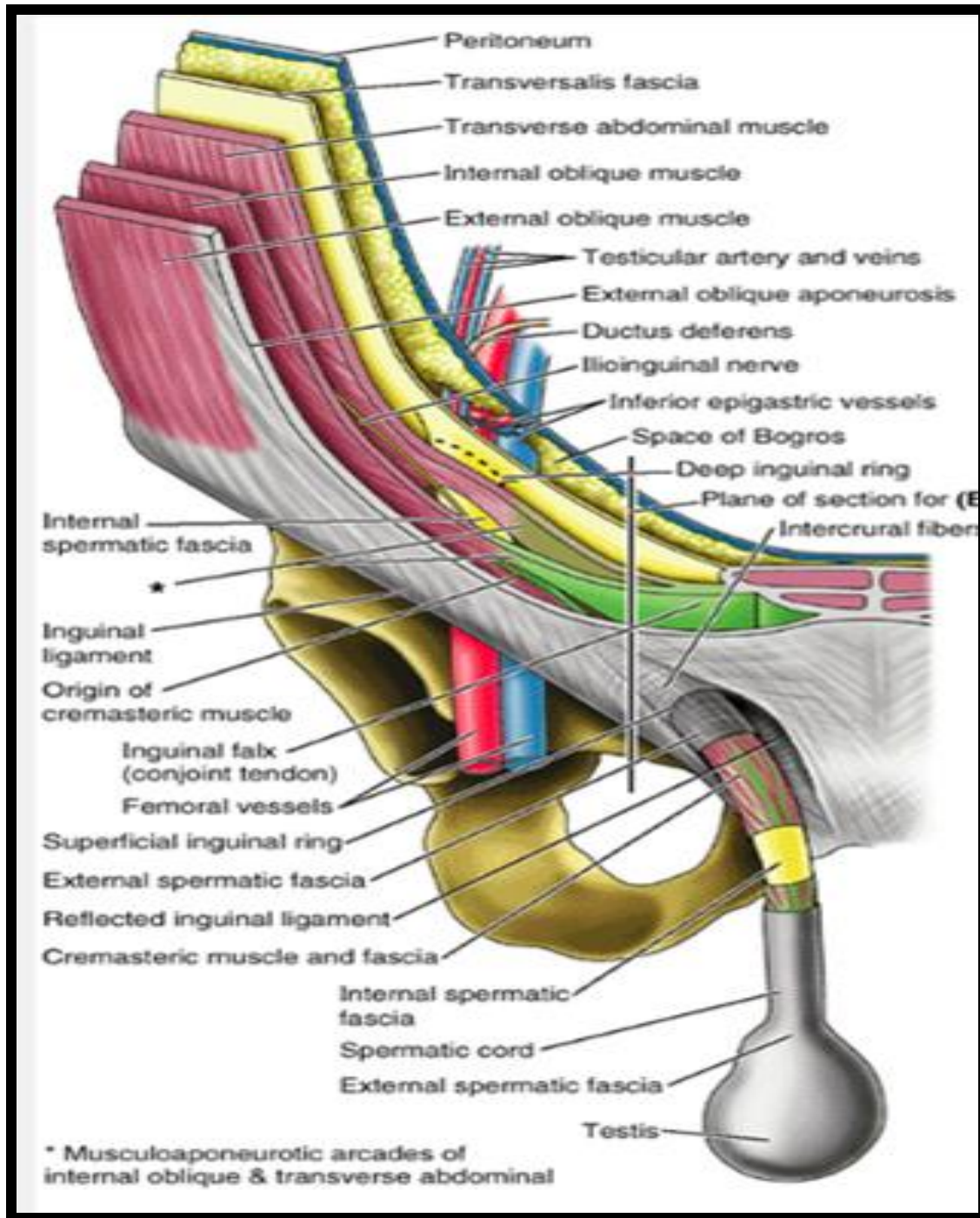
Dorsal nerve

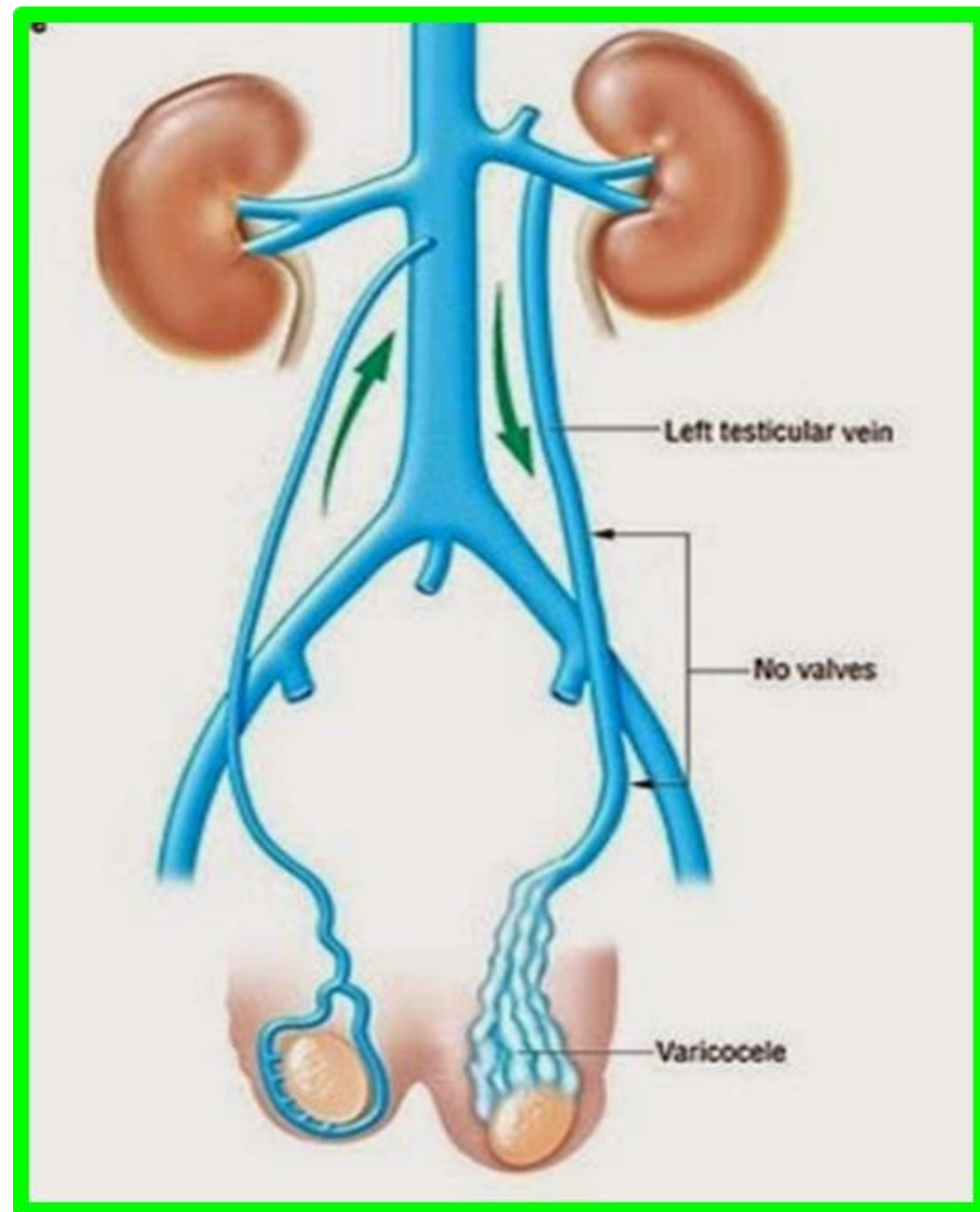
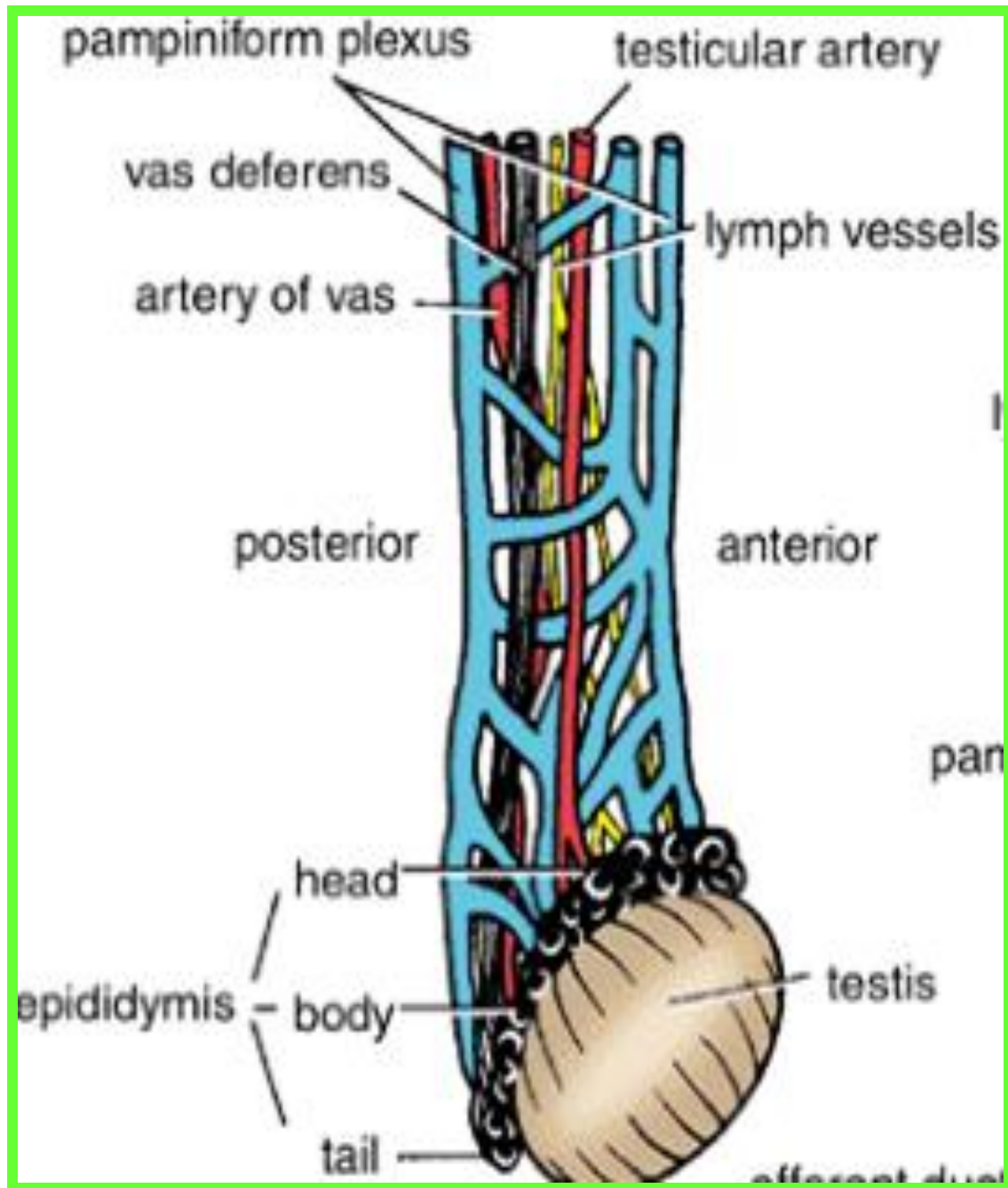
Corpus cavernosum

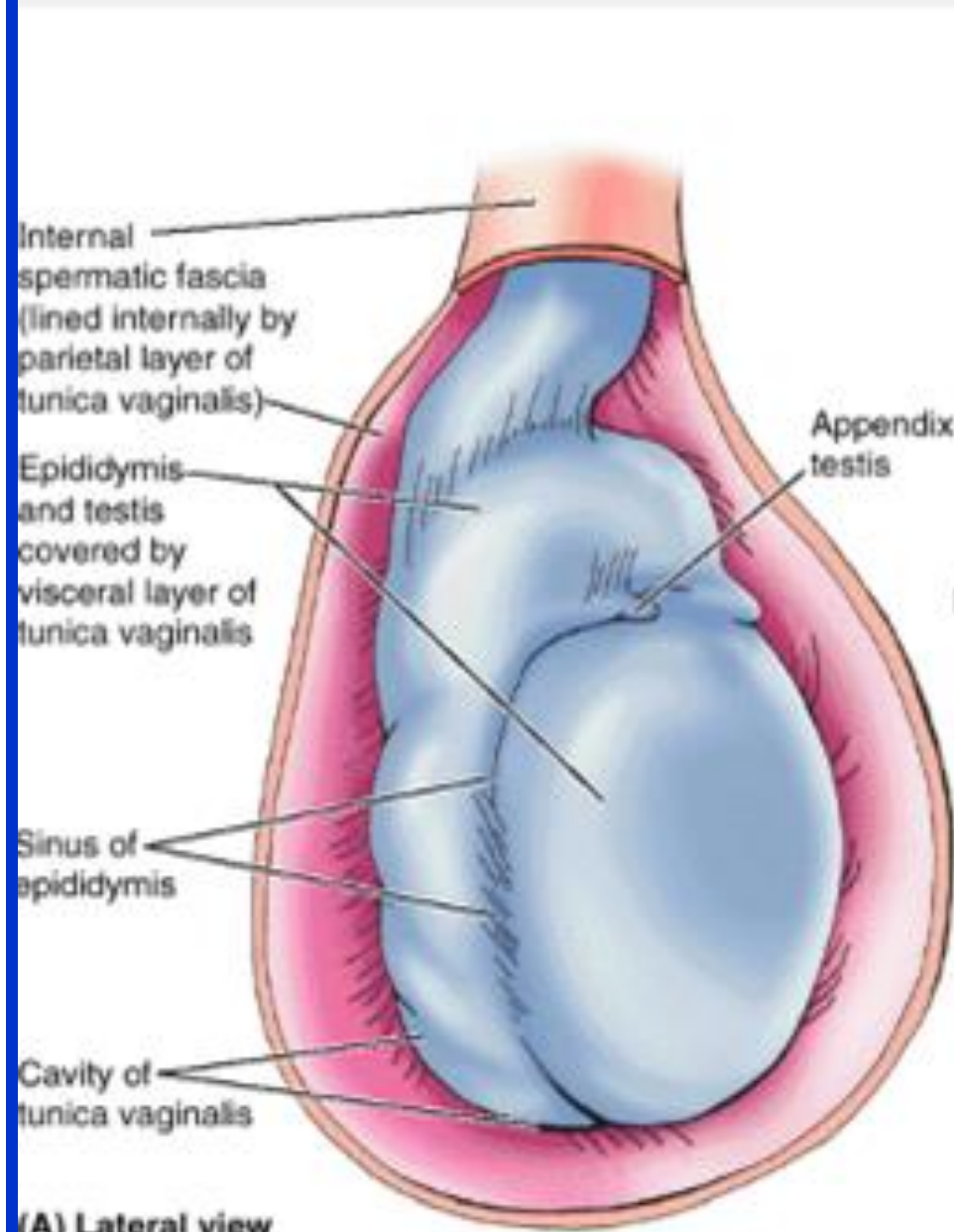
Tunica albuginea



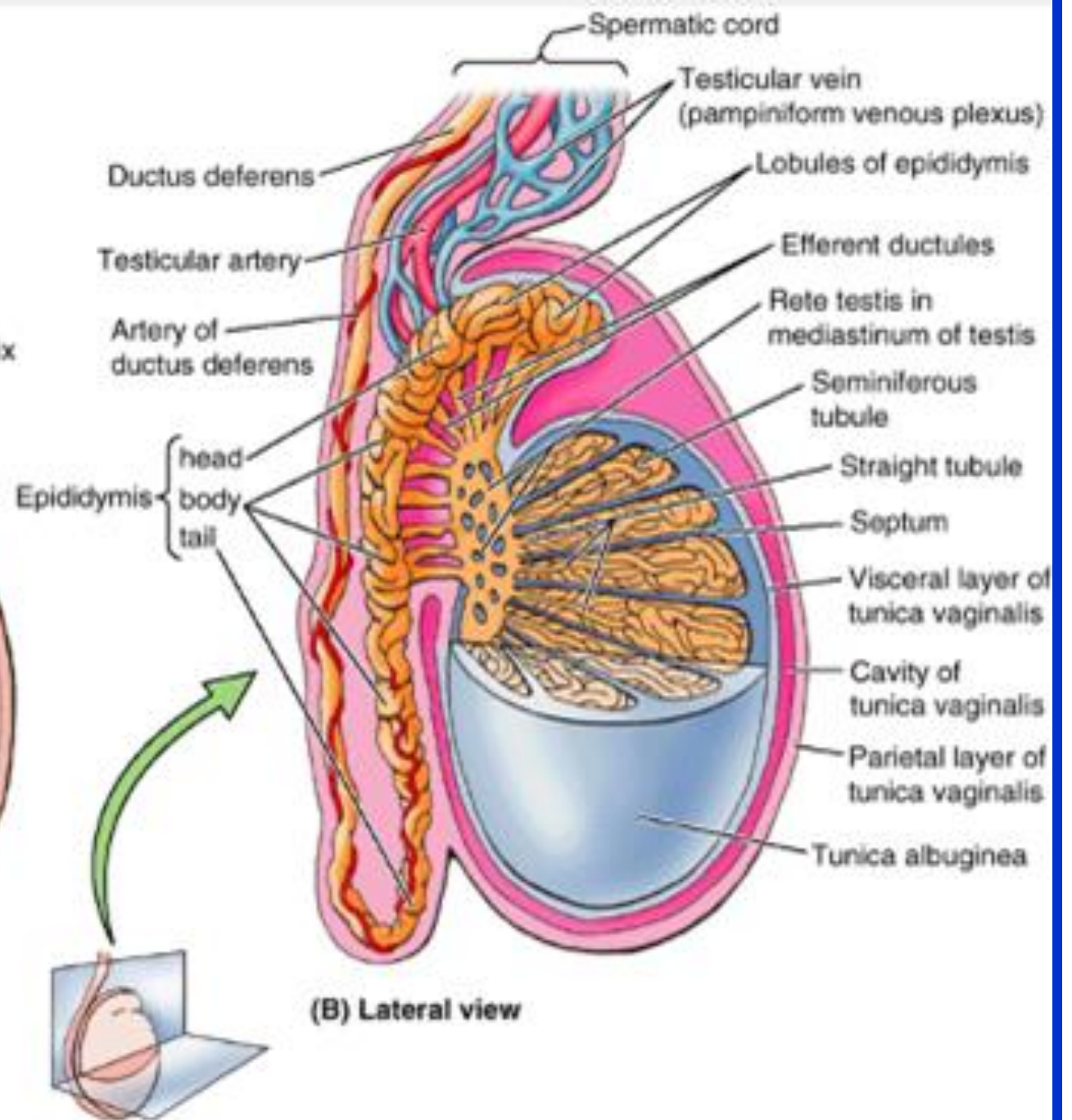




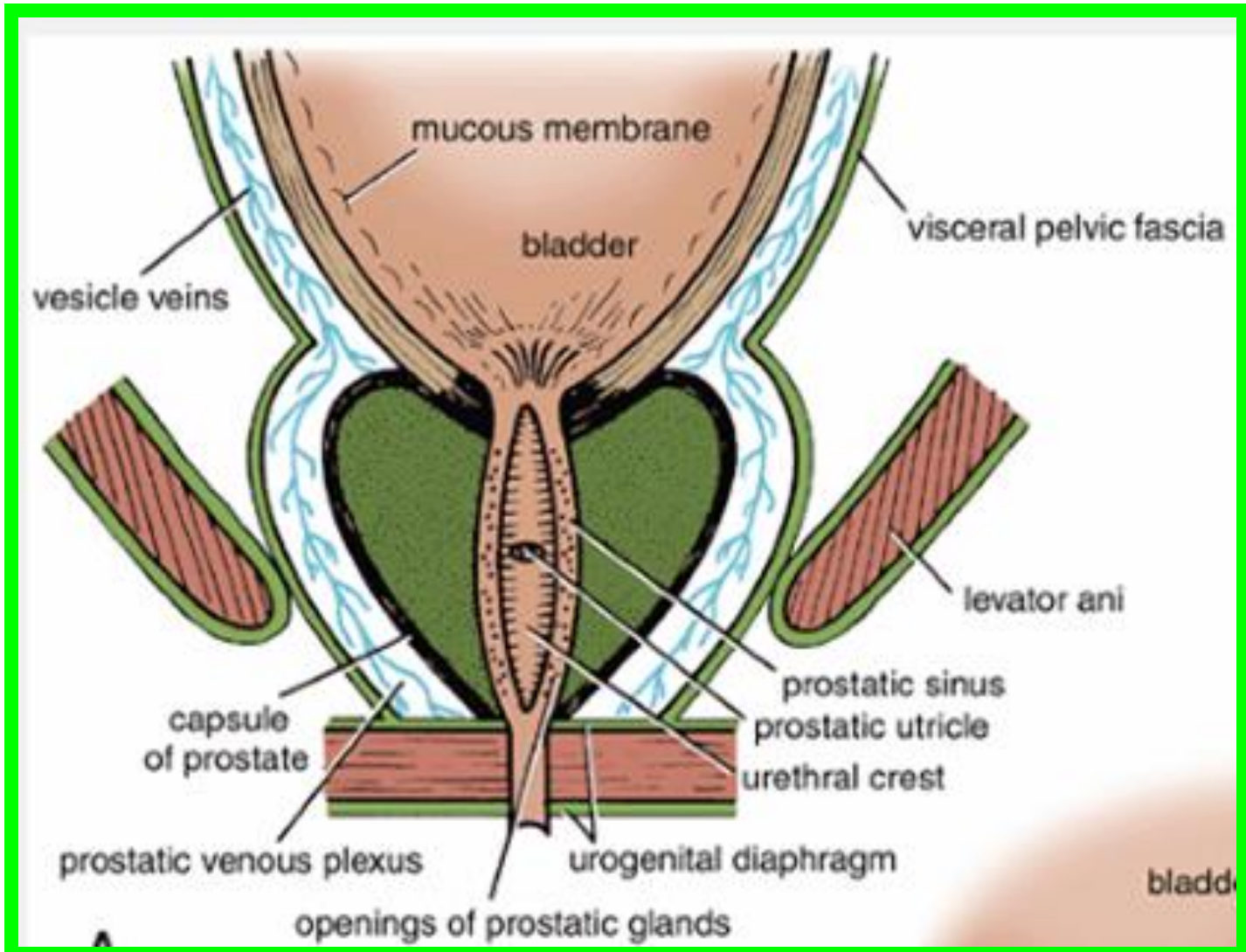
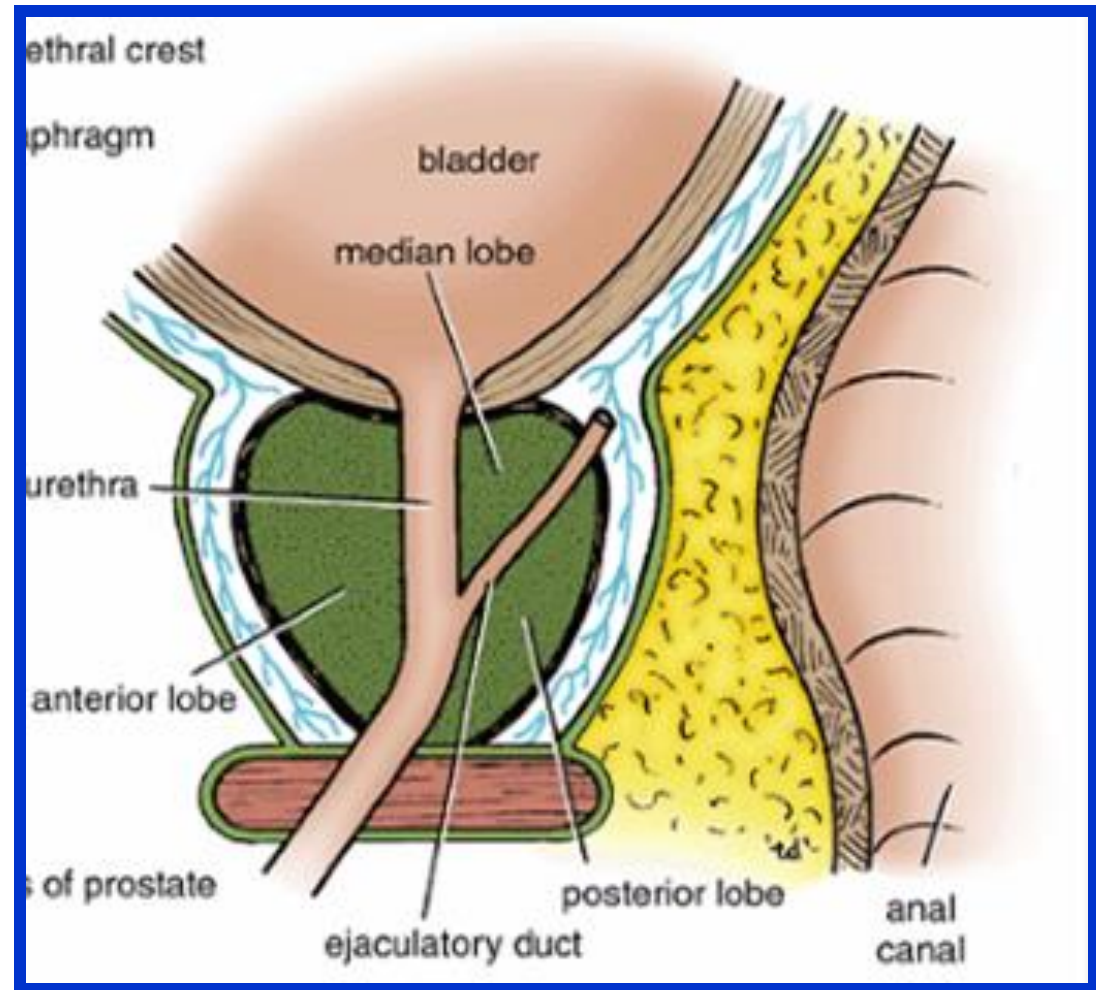


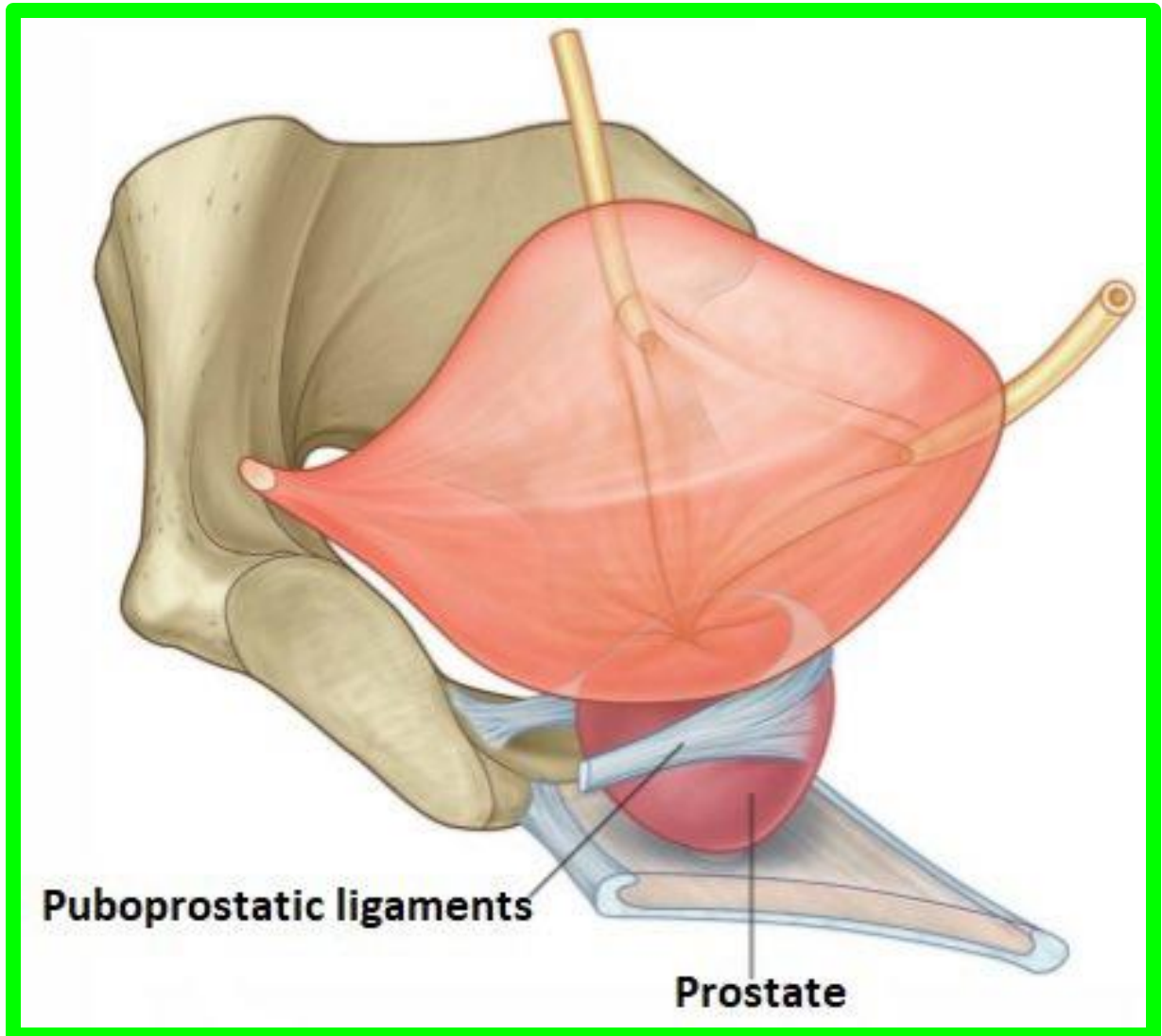
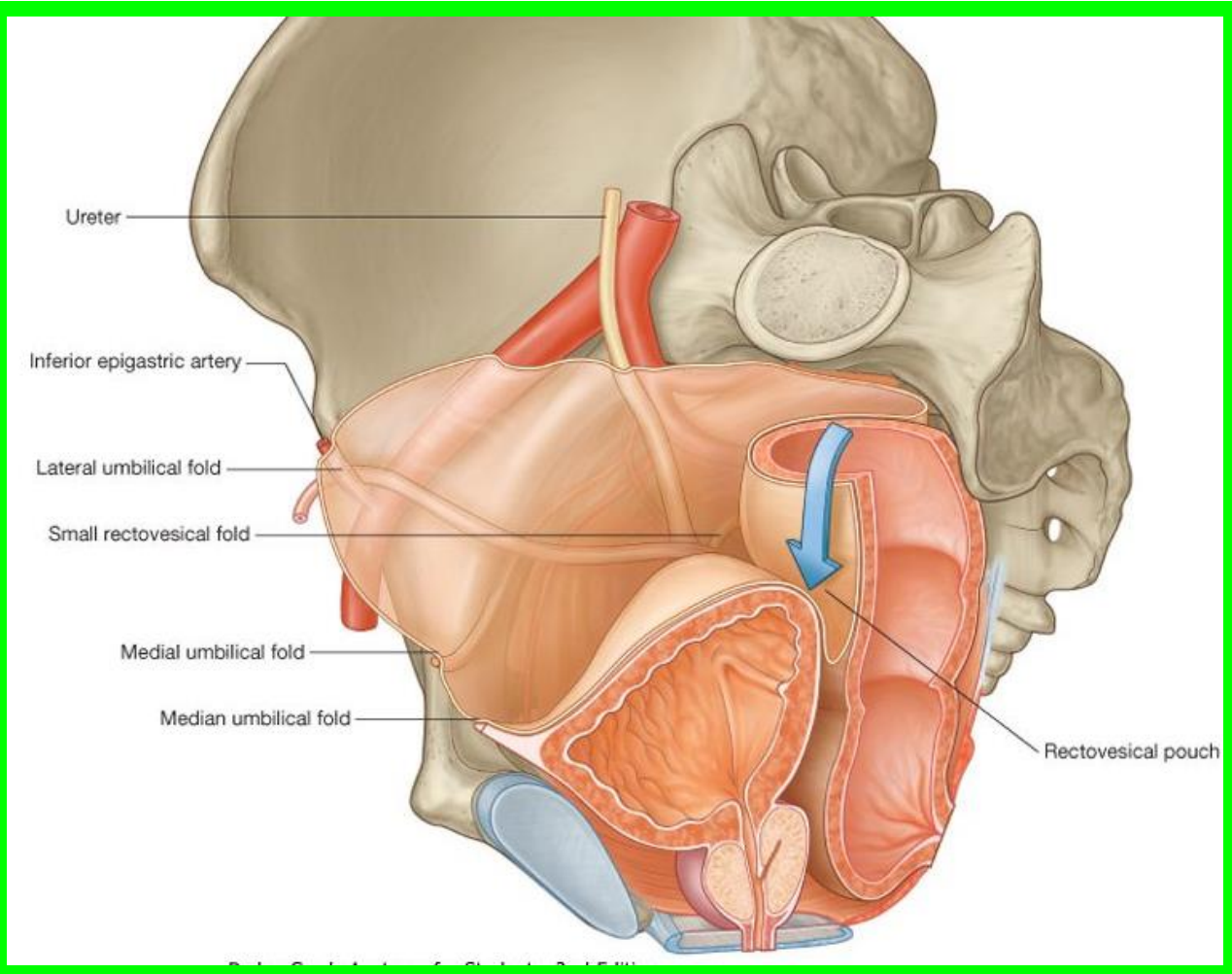


(A) Lateral view

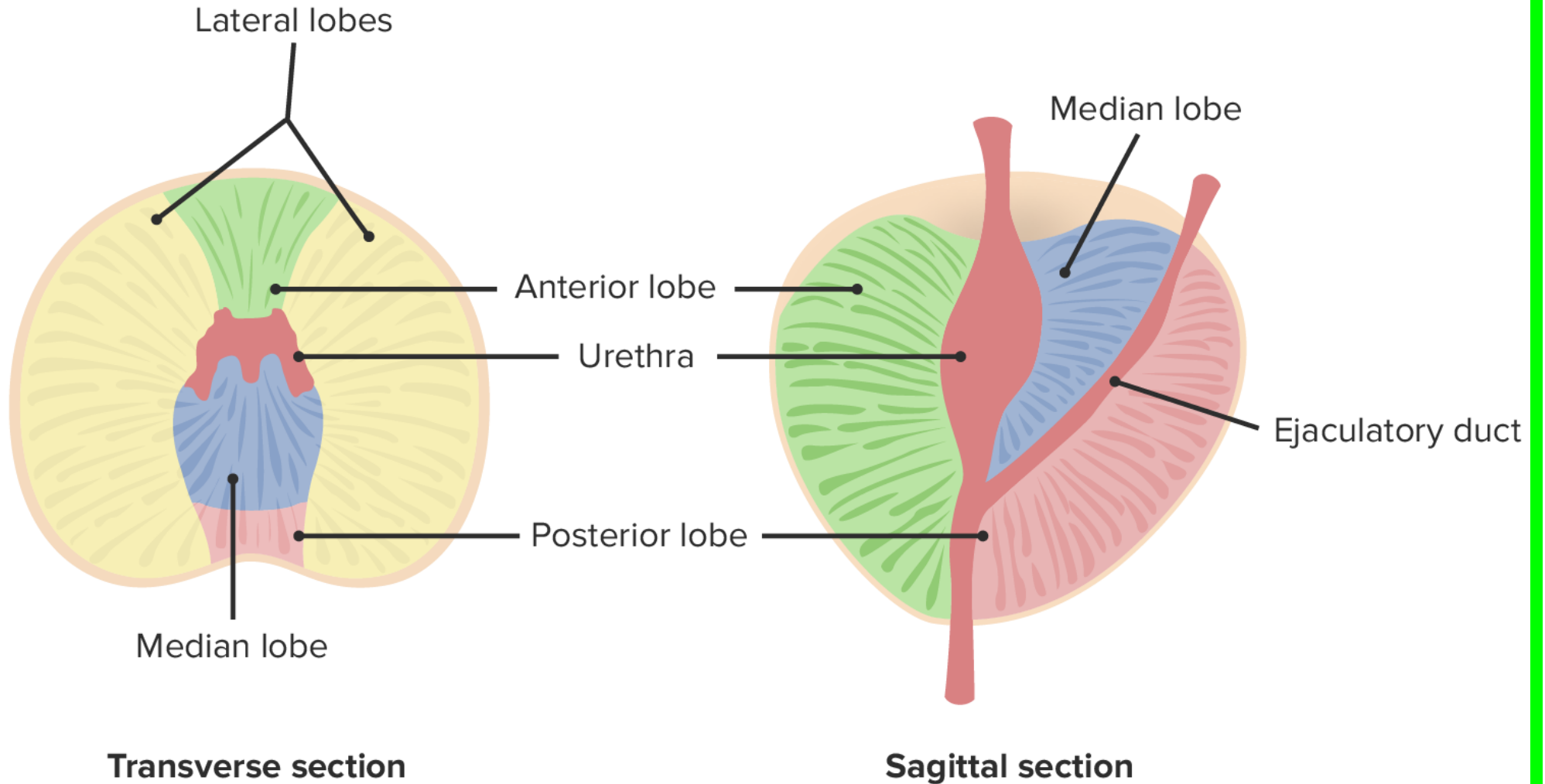


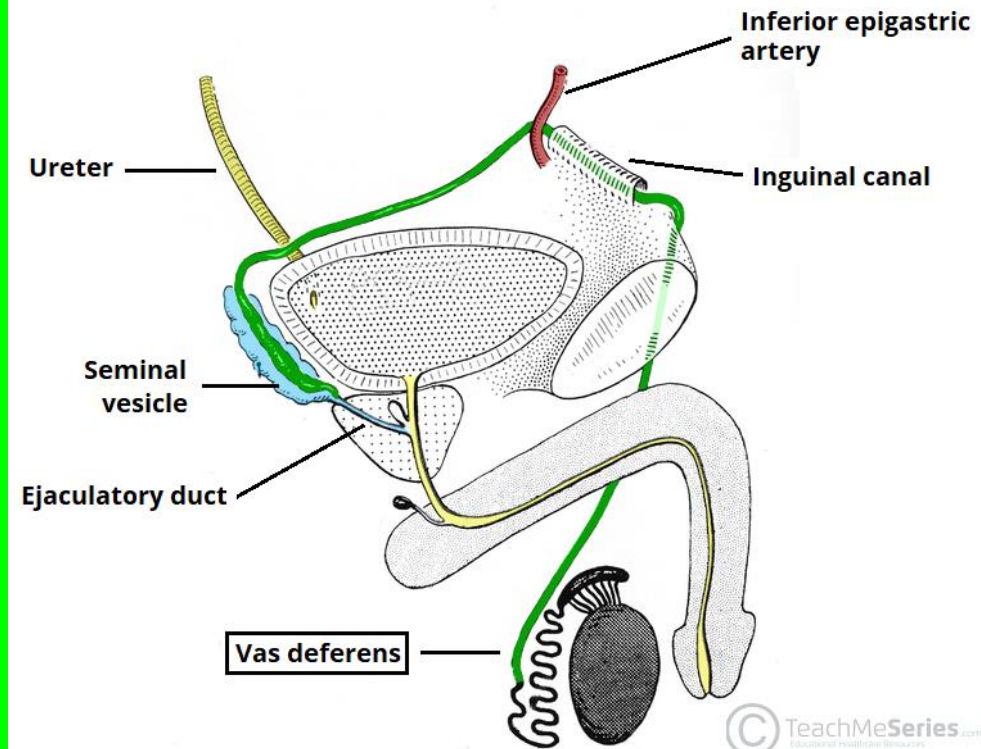
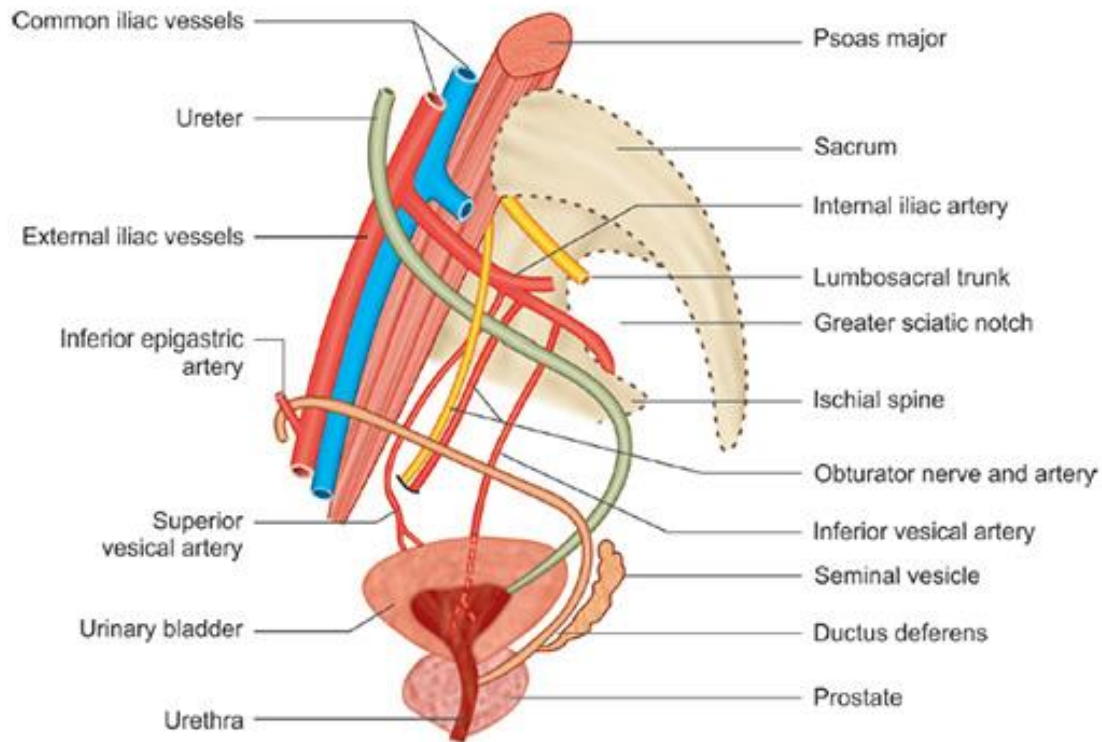
(B) Lateral view



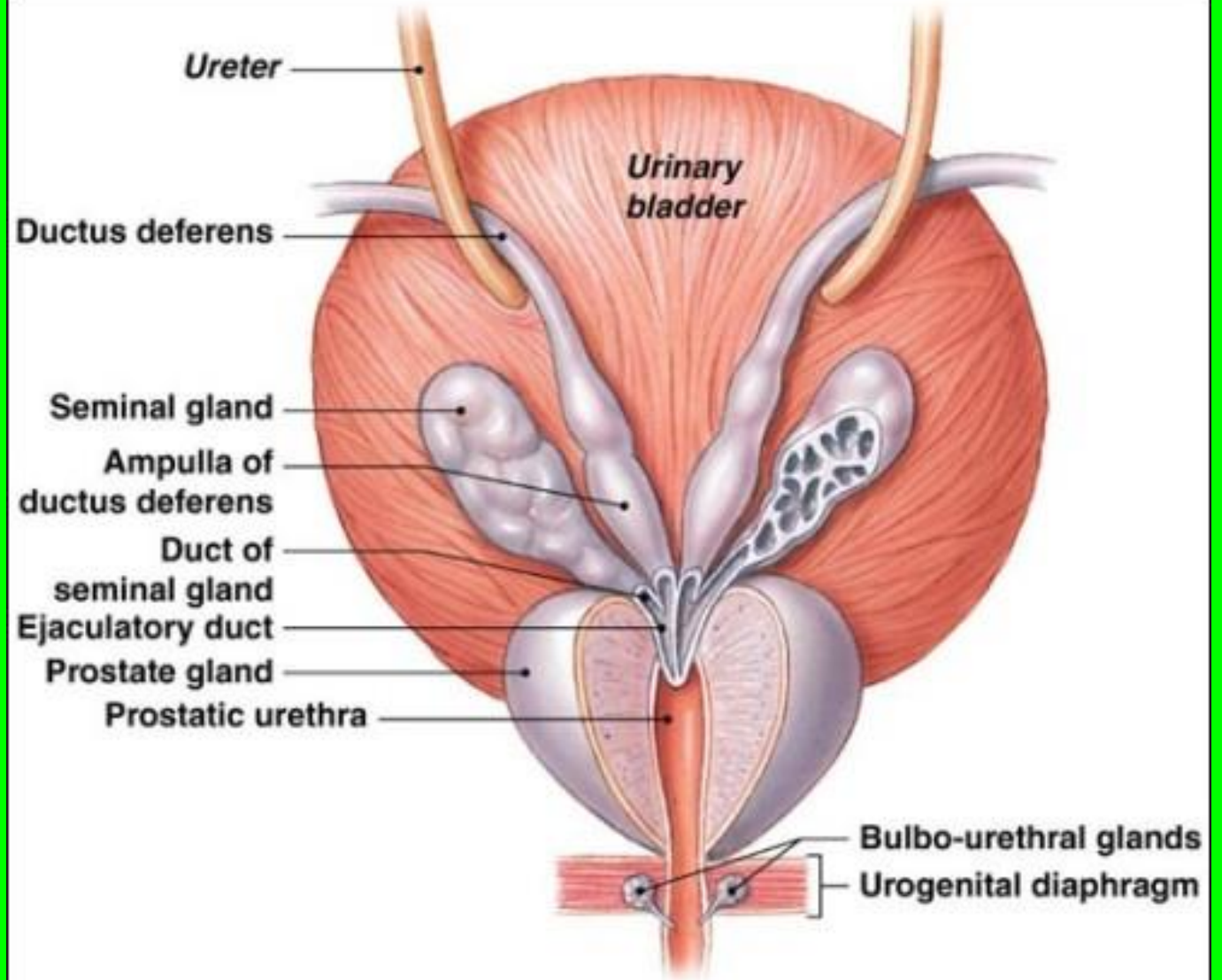
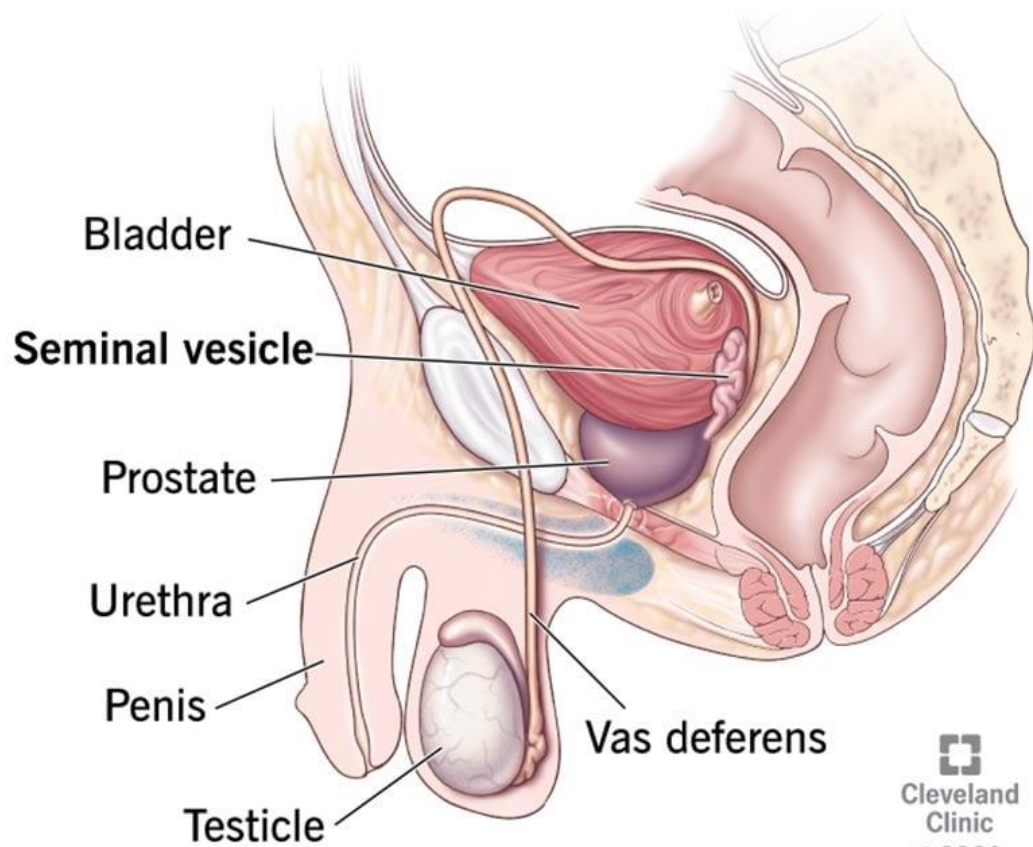


## Lobes of prostate gland





## Seminal vesicle



**a** A posterior view of the urinary bladder and prostate gland, showing subdivisions of the ductus deferens in relation to surrounding structures.

