

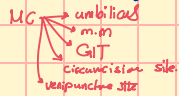neonate

upper

Swallowed mat. blood

healthy baby / 1st day
 Apt. Dasey test.

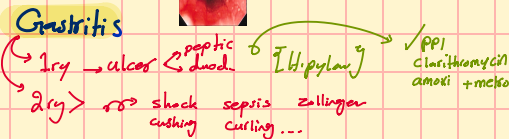
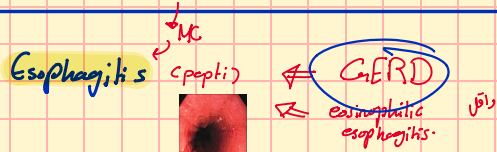
hemorrhagic dis of newborn ✓ vit.k FFP



Stress gastritis

"NICU" premature neonatal distress mech. ventilation
 Upper endoscopy.

1 month - 1 year



Varices

Mallory-weiss tear

Toddler 1-2 g

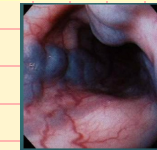
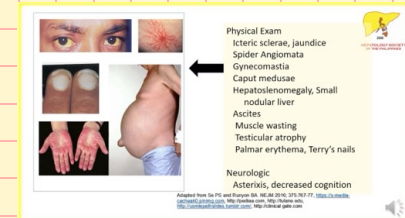PUD

Gastritis

older children

Esophageal varices

Comp of serious liver dis → portal vein throm → Esophageal varices.



PUD

Mallory weiss tear

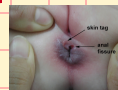lower

Anal Pissure → MCC of GI bleeding in children

bright red streaks on stool. - tear dorsally / midline

Chronic > 6w → skin tags (sentinel pile)
 hypertrophied anal papillae.

✓ stool softener / lubricants oils

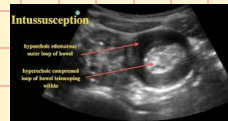

Anal Pissure

Intussusception

ileocecal

dry, older children → Meckle intest. lymphoma, duplication cyst.



US

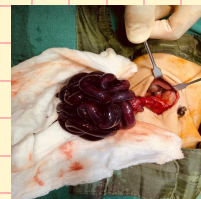
- current jelly stool

- paroxysmal abd. pain

- vomiting (loud → bile stained)

CMPPA

Gangrene



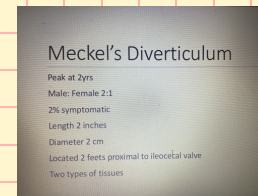
Juvenile polyps

blood on the surface of stool / painless bleeding
 Colonoscopy.

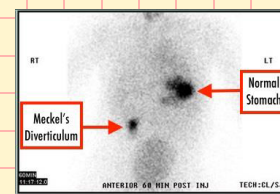
Meckle. diverticulum

Gastric tissue
 pancreatic tissue.

painless
 friable
 bleeding.



✓ surgery



Technetium 99m

polyps

IBD

Infectious diarrhea

vascular lesion

↳ hemangioma

↳ AV malformation

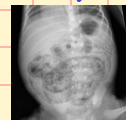
↳ vasculitis.

NEC

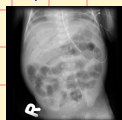premature / LBW

* terminal ileum

distention, poor feeding, V, D, apnea
 syst → hypotension, instability, bloody stool.



pneumatosis intestinalis
 portal vein gas



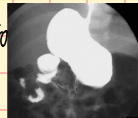
perforation
 ↓
 * pneumoperitoneum

✓ NPO NG tube ab

malrotation with volvulus

distention, pain, rectal bloody
 bile stained vomiting

✓ Laparotomy.



Barium study
 "coiled screw" sign

CMPPA.