

وسهلا



أهلا

يُمنع أخذ السلايدات بدون
إذن المحرر واي اجراء
يخالف ذلك يقع تحت طائلة
المسؤولية القانونية
جميع المعلومات للاستخدام
التعليمي فقط

الأستاذ الدكتور يوسف حسين

كلية الطب - جامعة مؤتة - الأردن

دكتورة من جامعة كولونيا المانيا

Prof. Dr. Youssef Hussein Anatomy - YouTube

الواتس 00201224904207

Development of Urinary bladder

اليوتيوب د. يوسف حسين

<https://www.youtube.com/@ProfDrYoussefHusseinAnatomy/playlists>

❖ Derivatives of cloaca

- The cloaca is the caudal dilated part of the **hindgut**, which is closed by the cloacal membrane and connected to umbilicus by **allantois (urachus)**.

- The cloaca separates around 4-7 weeks of gestation by **Urorectal septum** into:

1. Ventral part: **(Urogenital Sinus)** closed by urogenital membrane
2. Dorsal part called **anorectal sinus**, closed by anal membrane. forms the mucosa of the rectum and upper part of the anal canal.

A



B



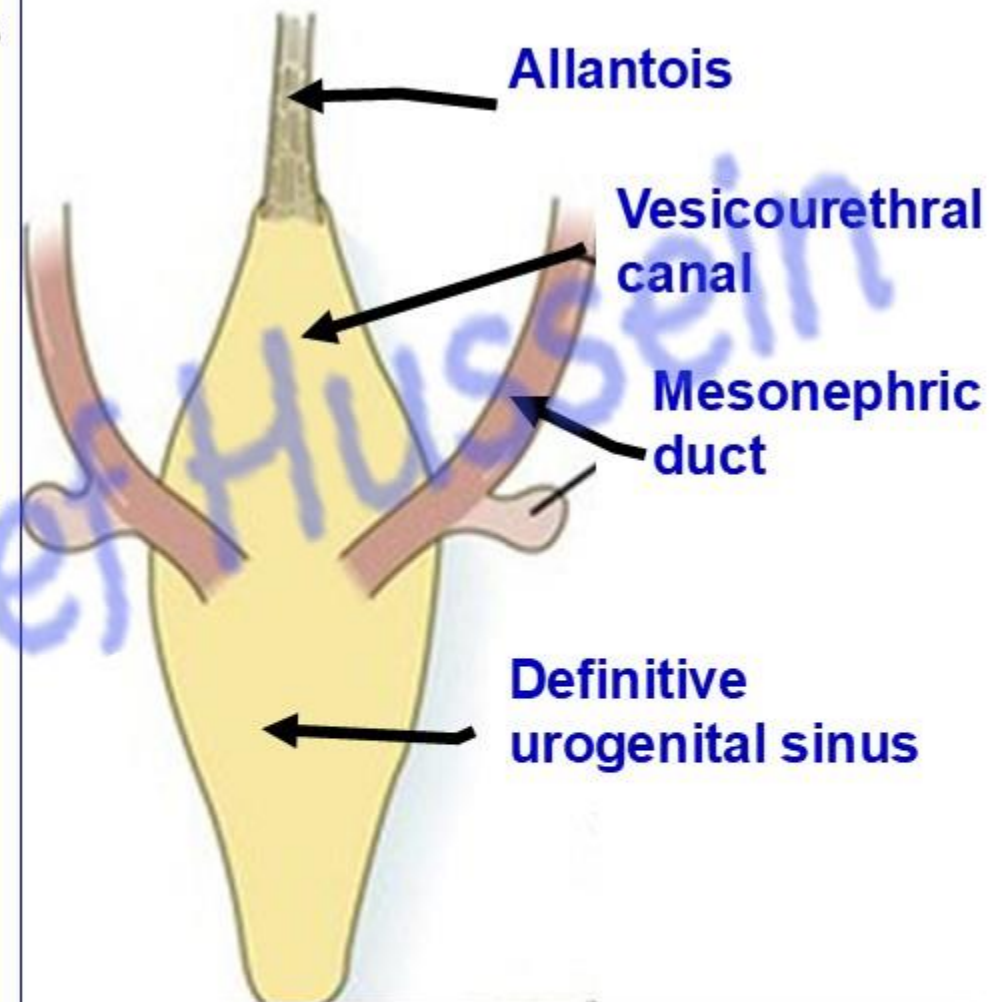
البيوتيوب د. يوسف حسين

- **Urogenital sinus** receives openings of allantois and 2 mesonephric ducts.
- The site of opening of mesonephric ducts into **urogenital sinus** dividing it into:

- 1- **Cranial part** called **vesicourethral canal**
- 2- **Caudal part** called **definitive urogenital sinus**.

**** Derivatives of the urogenital sinus:**

1. **Cranial (Vesical) Part:** Urinary bladder (except the trigone).
2. **Middle (Pelvic) Part:** Prostatic/membranous urethra (males); entire female urethra.
3. **Caudal (Phallic) Part:** Penile urethra (males); vestibule of the vagina (females).



اليوتيوب د. يوسف حسين

- **Development of the Urinary Bladder**

- ** Development of the mucous membrane**

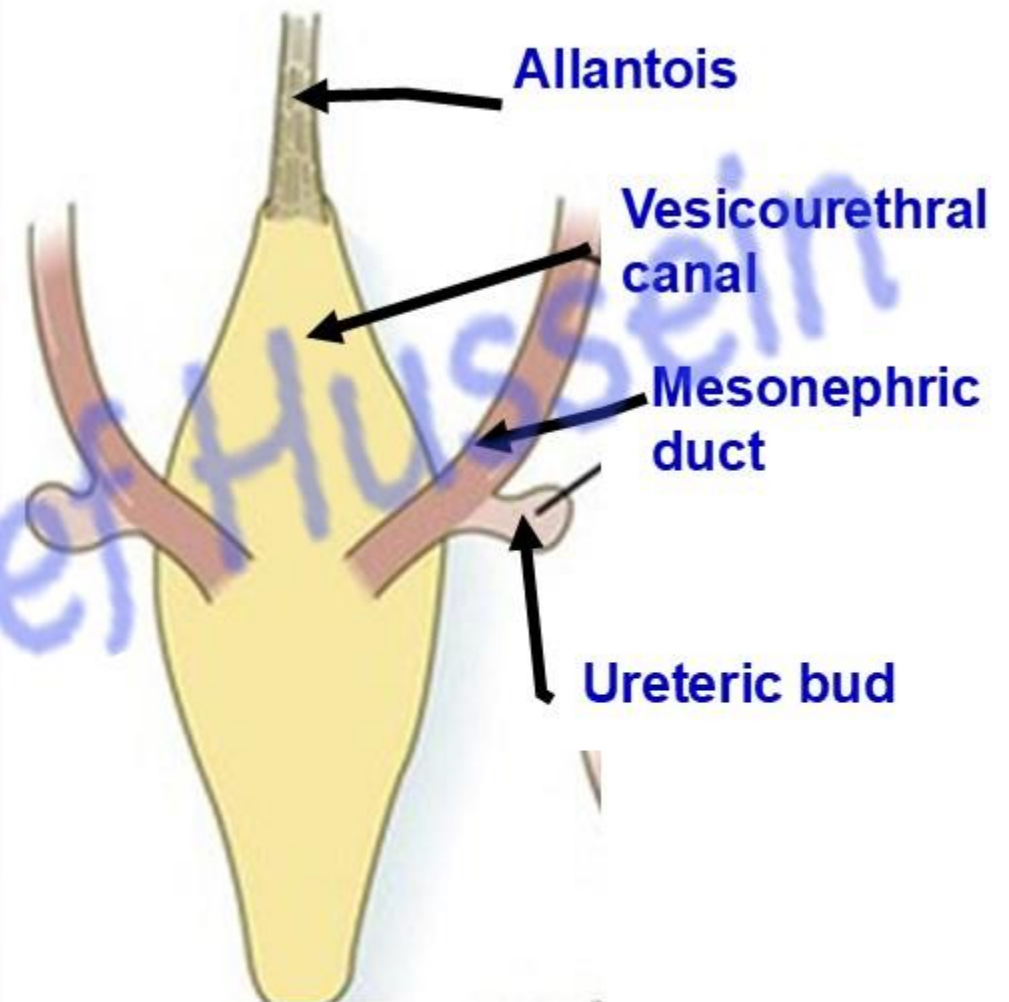
1- Proximal part of allantois (urachus), forms the apex of the urinary bladder (endodermal in origin).

2- Vesicourethral canal, forms most of the urinary bladder (endodermal in origin).

3- Proximal parts of mesonephric ducts till the opening of ureteric buds form **trigone** (mesodermal in origin).

- ** Development of muscles** (from the mesoderm surrounding the vesicourethral canal).

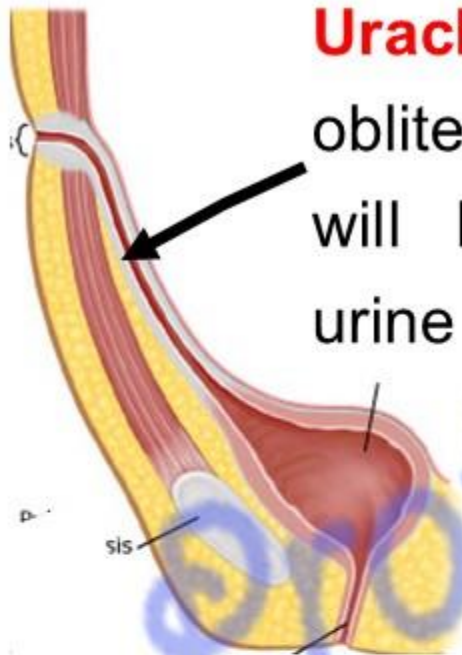- Distal part of allantois (urachus) obliterated, fibrosed and formed **median umbilical ligament.**



اليوتيوب د. يوسف حسين

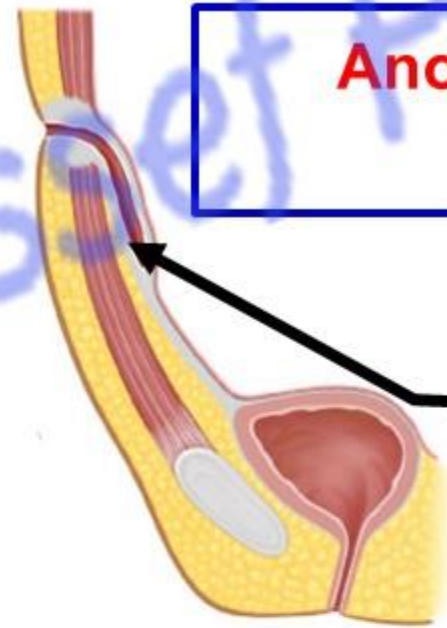
<https://www.youtube.com/@ProfDrYoussefHusseiniAnatomy/playlists>

Urachal fistula: failure of obliteration of **urachus**. This will lead to discharge of urine from umbilicus.

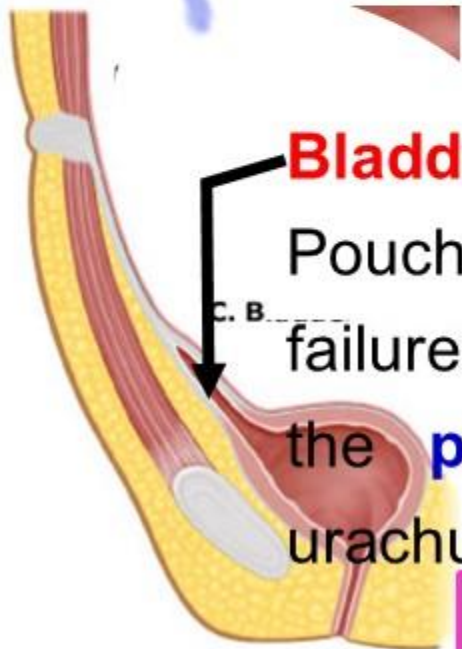


Anomalies of urachus (allantois):

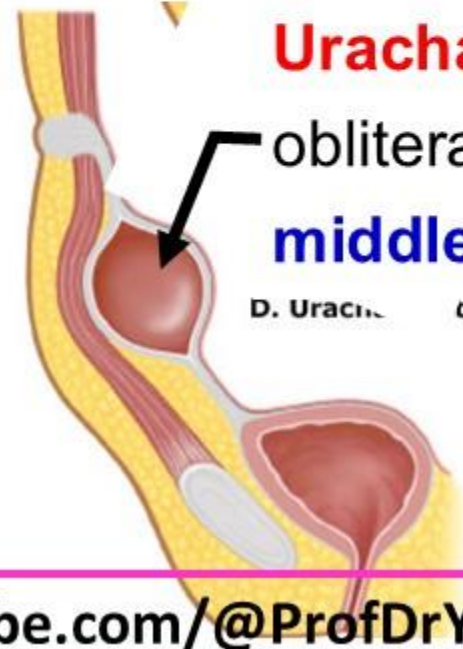Urachal sinus: failure of obliteration of **distal** part of urachus.



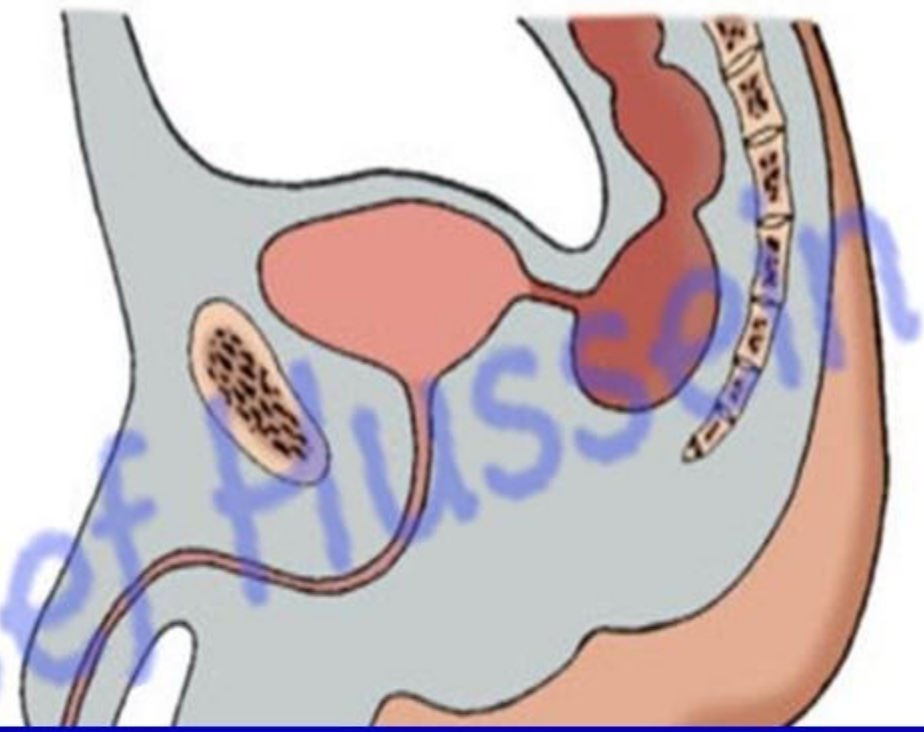
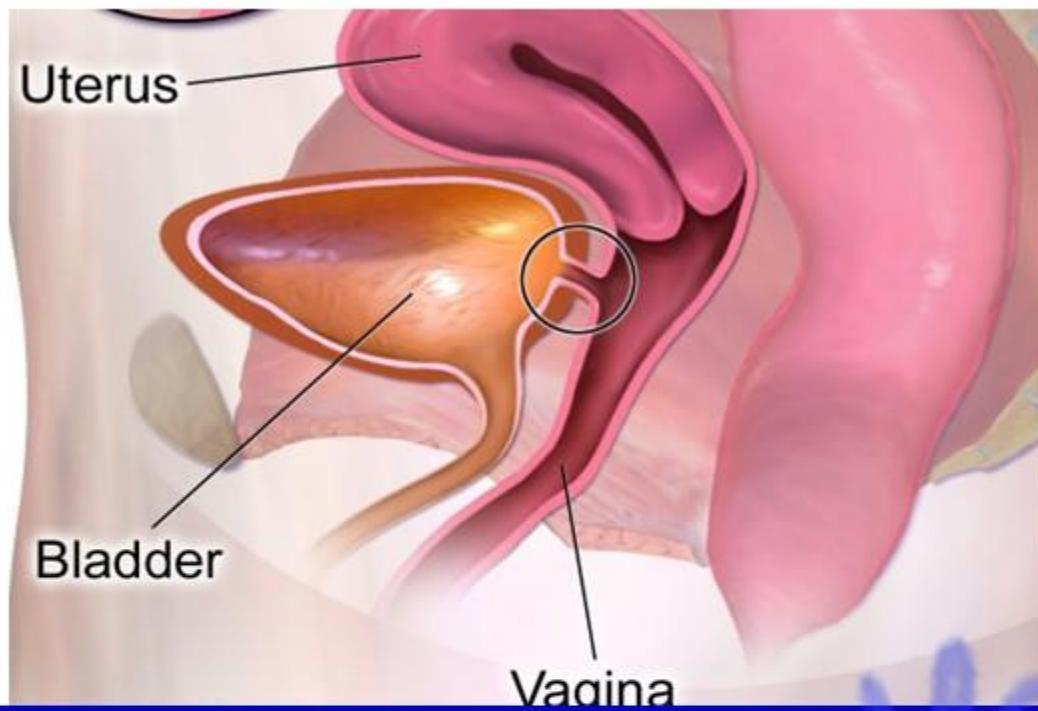
Bladder diverticulum: Pouch in the apex failure of obliteration of the **proximal** part of urachus.



Urachal cyst: failure of obliteration of the **middle** part of urachus.

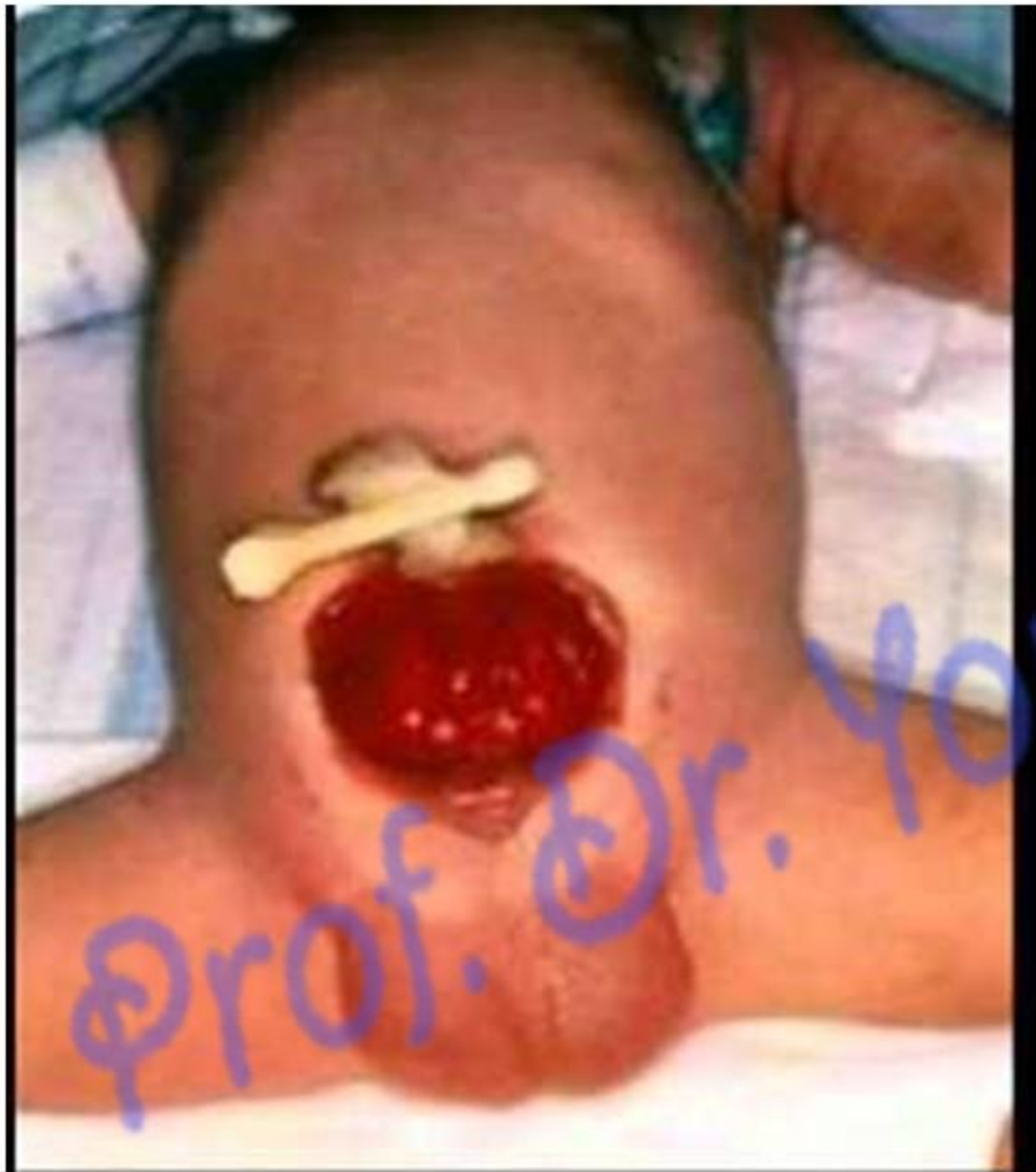

اليوتيوب د. يوسف حسين



Fistulae of the urinary bladder: due to defect in the urorectal septum.

- (a) **Vesicovaginal fistula:** communication between urinary bladder and vagina (female).
- (b) **Rectovesical fistula:** communication between urinary bladder and rectum (male).



- **Ectopia vesica:**

- The inner aspect of the urinary bladder is exposed below the umbilicus.
- This occurs due to failure of the formation of the anterior abdominal wall and anterior wall of the urinary bladder (Failure in the lateral folding, midline closure)

Bladder Diverticulum: A sac or pouch that protrudes through the muscle layer of the bladder, often leading to urine retention and infections

اليوتيوب د. يوسف حسين

<https://www.youtube.com/@ProfDrYoussefHusseinAnatomy/playlists>



Development of urethra

اليوتيوب د. يوسف حسين

<https://www.youtube.com/@ProfDrYoussefHusseinAnatomy/playlists>

**** Development of the female urethra**

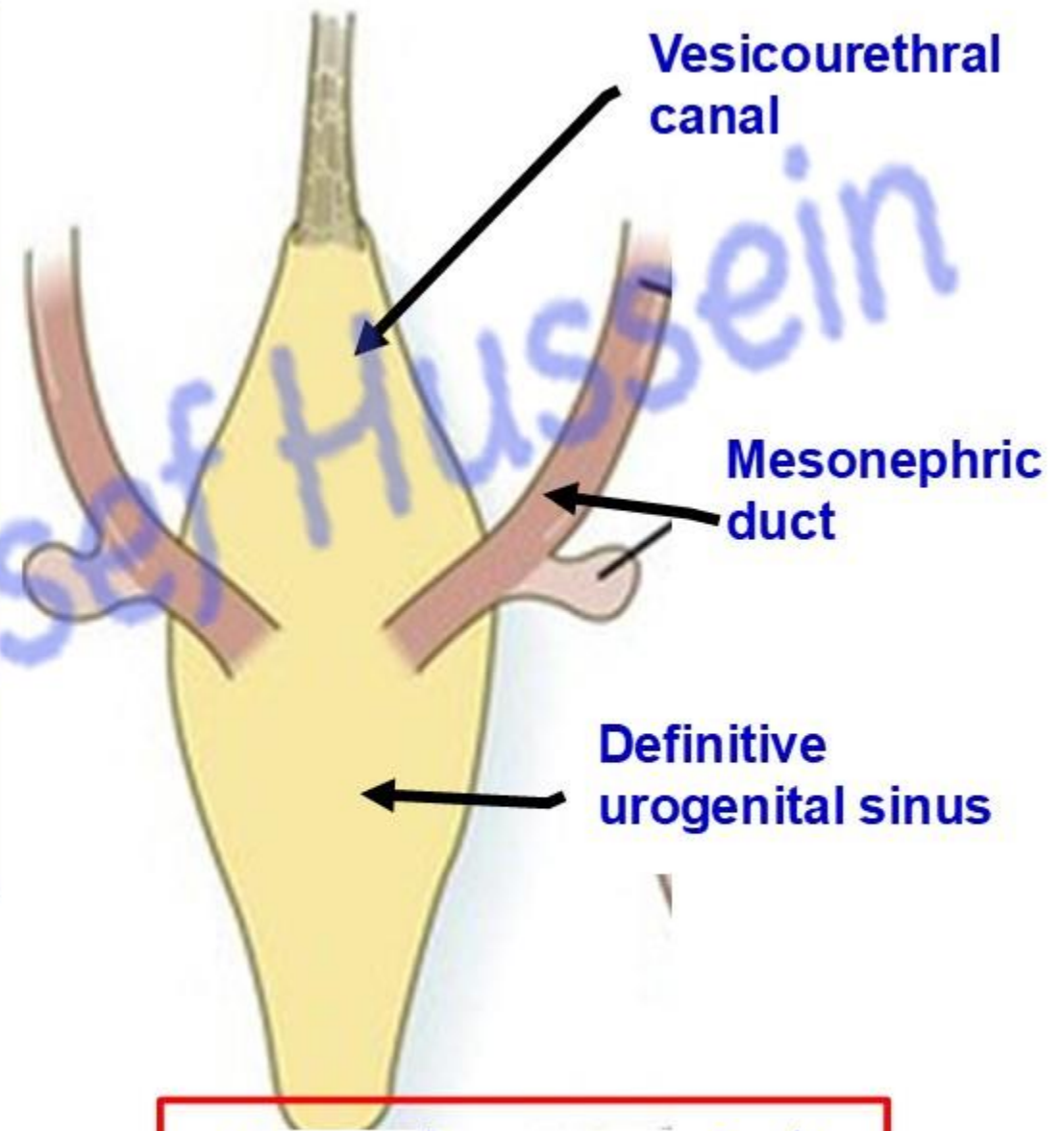
- The site of opening of mesonephric ducts into **urogenital sinus** dividing it into:

1- Cranial part called vesicourethral canal

which forms mucous membrane of Upper 4/5 of the **urethra**.

2- Caudal part called definitive urogenital sinus

- The urethral sphincters are developed from the surrounding mesoderm.



اليوثيوب د. يوسف حسين

** Development of male urethra

A- Vesicourethral canal forms Prostatic part of the urethra above the Seminal colliculus .

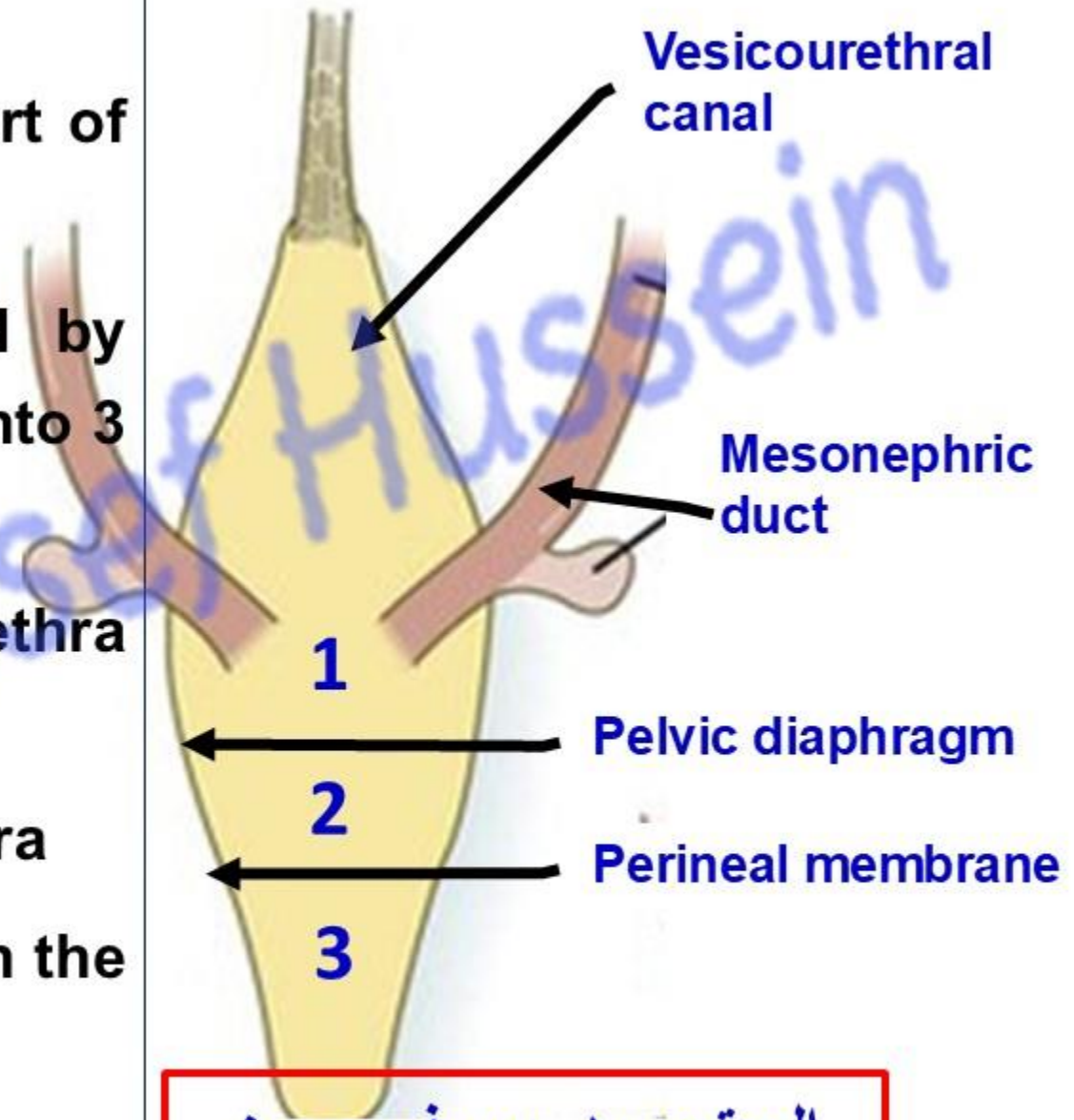
A- Definitive urogenital sinus is divided by **pelvic diaphragm** and **perineal membrane** into 3 parts:

1- Cranial part form **Prostatic** part of the urethra **below** the seminal colliculus

2- Middle part forms the **membranous** urethra

3- Caudal part forms forms **penile urethra** in the root of the penis (in the pelvis)

- The urethral sphincters around membranous are developed from the surrounding mesoderm.



اليوتوب د. يوسف حسين

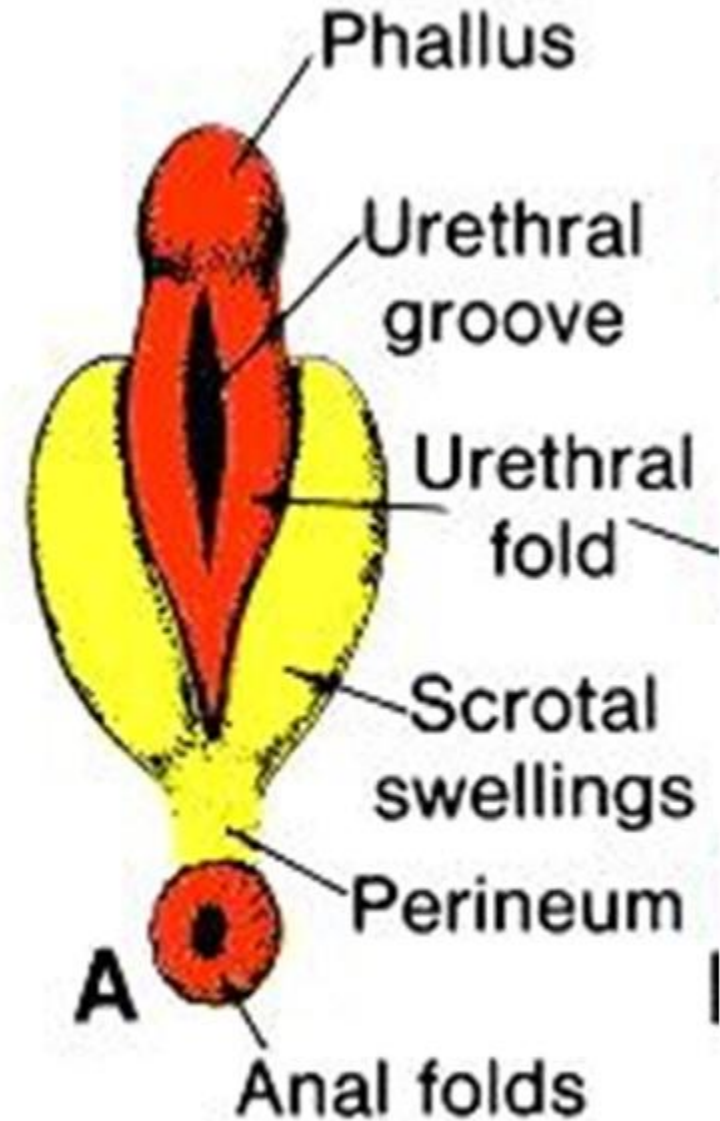
- **Steps of development of penile (spongy) urethra**

- **Penile Urethra in the body of the penis:**

- The urethral **plate**, located in the ventral midline, becomes **grooved**.
- Urethral **folds** fuse from proximal to distal to form a closed tube, or penile urethra.

- **Glanular Urethra in the glans penis (head).**

- A solid epithelial plate grows through the glans, genital tubercle, (phallus), forming a central canal that joins the penile urethra.



اليو تيوب د. يوسف حسين

<https://www.youtube.com/@ProfDrYoussefHusseinAnatomy/playlists>

• Hypospadias

- The external meatus is found on the **Under (Ventral) surface** of the penis anywhere between the glans penis and perineum.
- It is caused by failure in fusion of the **urethral Folds.**

A- Complete: groove extends from the head of the penis till the scrotum (resembles labia majora).

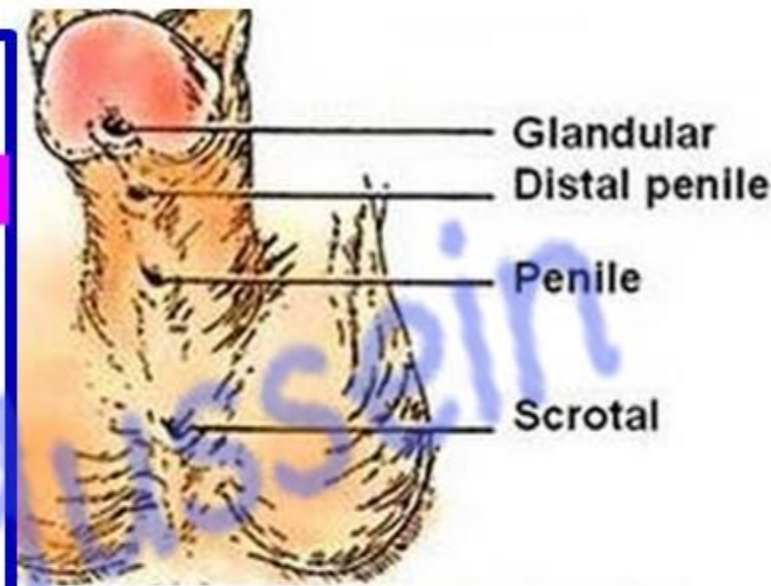
B- Incomplete:

a- Perineal (scrotal): at the root of the penis, The opening is between the scrotum and the anus (perineum)

b- Penile: at any site along the body (shaft) of the penis

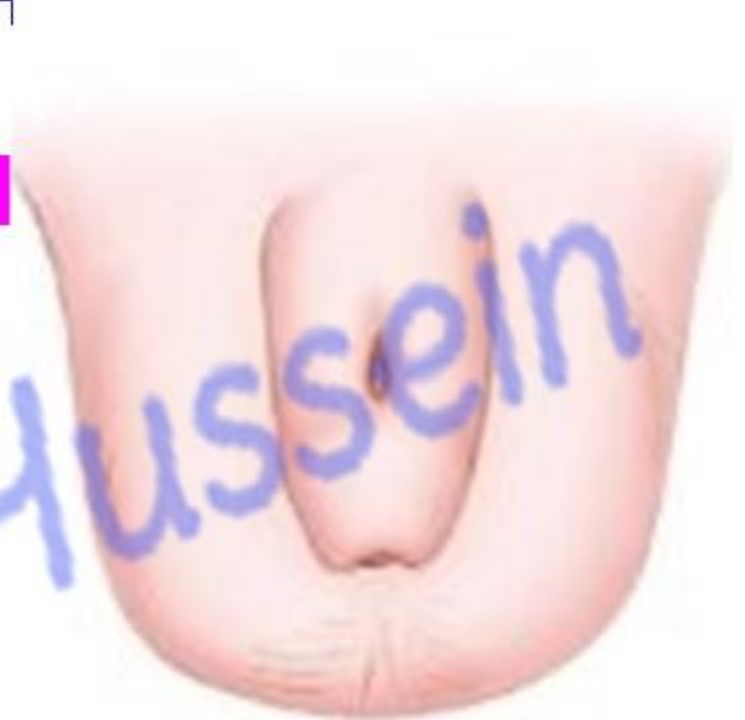c- Distal at the terminal of body of the body of the penis

d- Glanular (Glandular): The opening is on the glans (head) of the penis, but not at the tip (The best one for man, can not be repair).



- **Epispadias**

- The opening of urethra lies on the **upper (dorsal) surface of the penis.**
- It is either occurred alone or with ectopia vesica.
- **Glanular Epispadias:** The urethral opening (meatus) is located on the glans (head) of the penis. This is the mildest form and typically allows for normal bladder control.
- **Penile Epispadias:** The meatus is located along the shaft of the penis.
- **Penopubic Epispadias:** The most severe form, where the meatus is located near the pubic bone. This is often associated with urinary incontinence due to an affected bladder neck



Epispadias


• **Types of Female Epispadias**

- Female epispadias is extremely rare and usually presents with a bifid clitoris and malformed labia.
- 1. **Sub-symphyseal Epispadias:** Involves a defect in the anterior wall of the urethra for about half its length.
- 2. **Retropubic Epispadias:** The most severe form, where the anterior wall defect extends the entire length of the urethra.
- 3. **Vesicular Epispadias:** The urethra is mostly normal, but its position is altered relative to the clitoris
 - **Urethral fistula (defect in urorectal septum)**
 - **Recto-urethral fistula:** communication between rectum and urethra.
 - **Urethrovaginal fistula:** communication between vagina and urethra.
 - **Posterior Urethral Valves (PUV):** The most common cause of congenital urethral obstruction in boys, where abnormal tissue flaps in the posterior urethra block urine flow, potentially damaging the bladder and kidneys.

https://www.youtube.com/channel/UCVSNqbibj9UWYaJdd_cn0PQ

يُمنع أخذ السلايدات بدون
إذن المحرر واي اجراء
يخالف ذلك يقع تحت طائلة
المسؤولية القانونية
جميع المعلومات للاستخدام
التعليمي فقط

اليوتيوب د. يوسف حسين



<https://www.youtube.com/@ProfDrYoussefHusseinAnatomy/playlists>