

URETHRA & SACRAL PLUXSUS

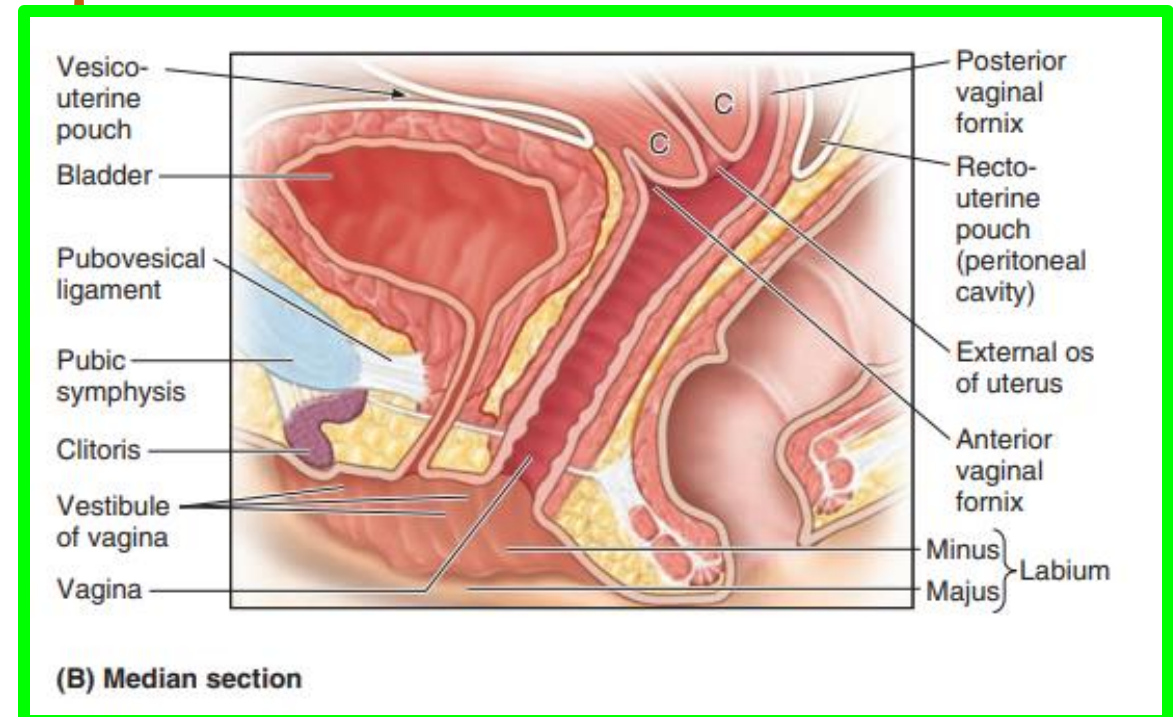
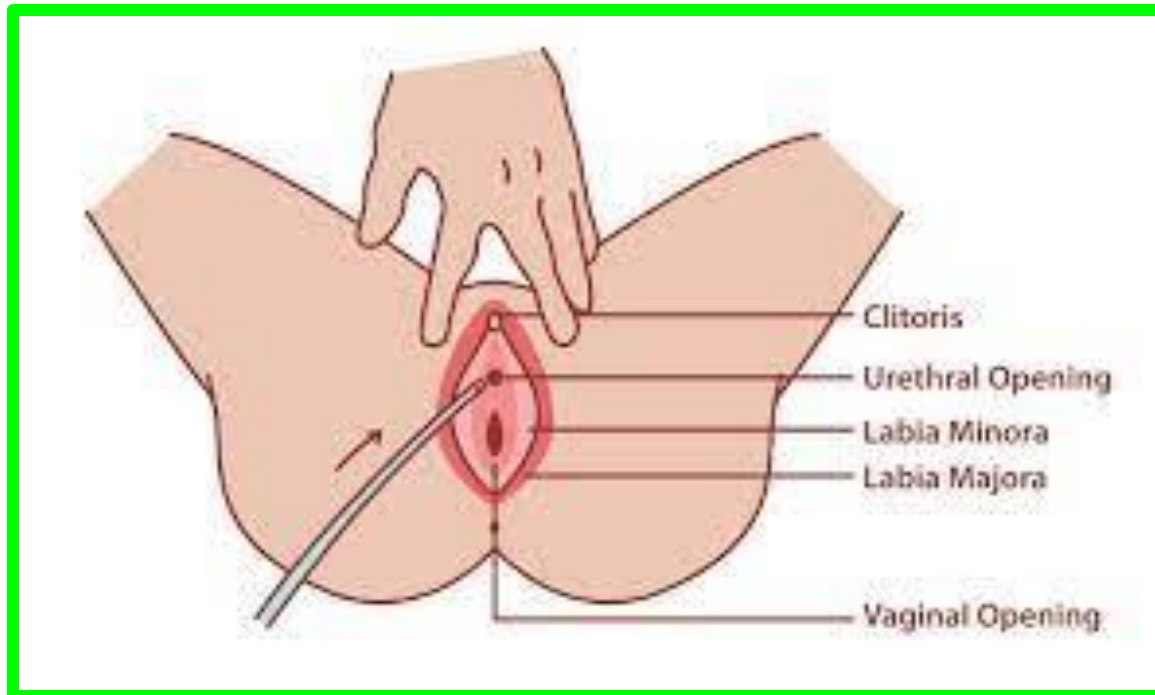
Dr. Aiman Qais Afar
Surgical Anatomist

College of Medicine / University of Mutah
2025-2026

Sunday 3 May 2026

Female Urethra

- ❖ It is very short, approximately **4 cm long** and **6 mm in diameter**
- ❖ It is **wider and more dilatable** than the male urethra.
- ❖ It begins from the bladder neck at the **internal urethral orifice**, and descends downwards and forwards, traversing **the deep perineal pouch**.
- ❖ It opens by the **external urethral orifice** into **the vestibule of the vagina**.
- ❖ It is surrounded by **an internal urethral sphincter**.



Male Urethra

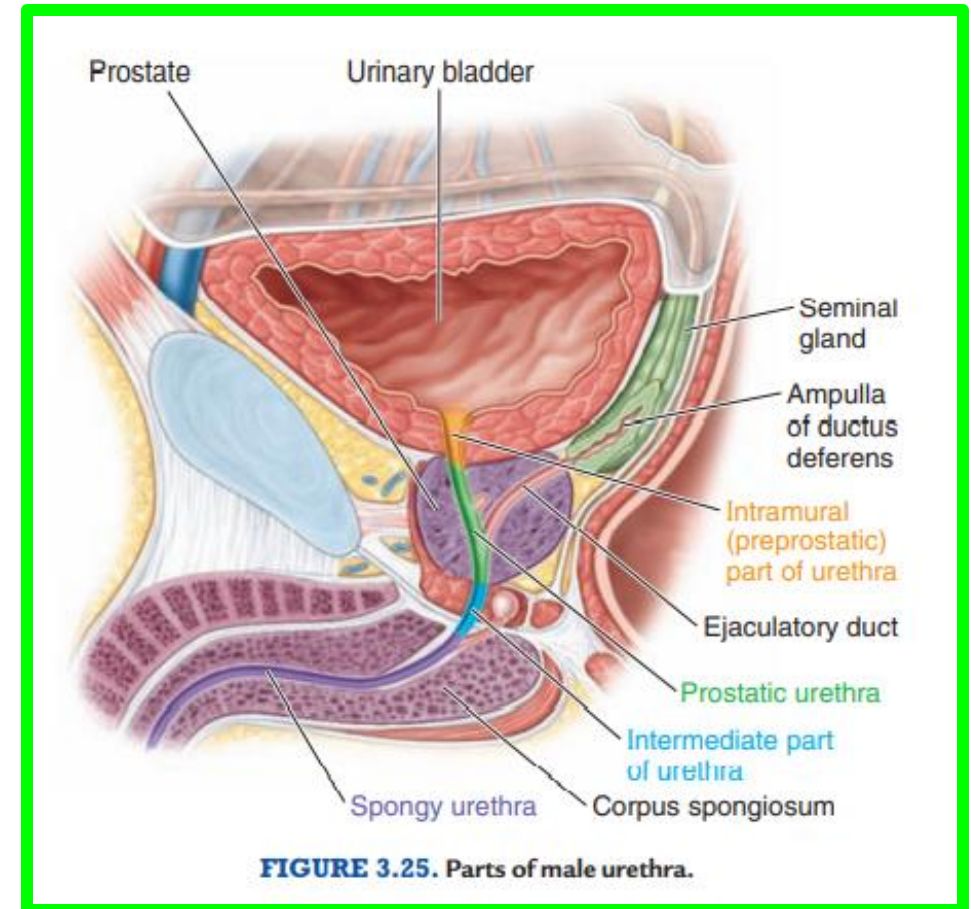
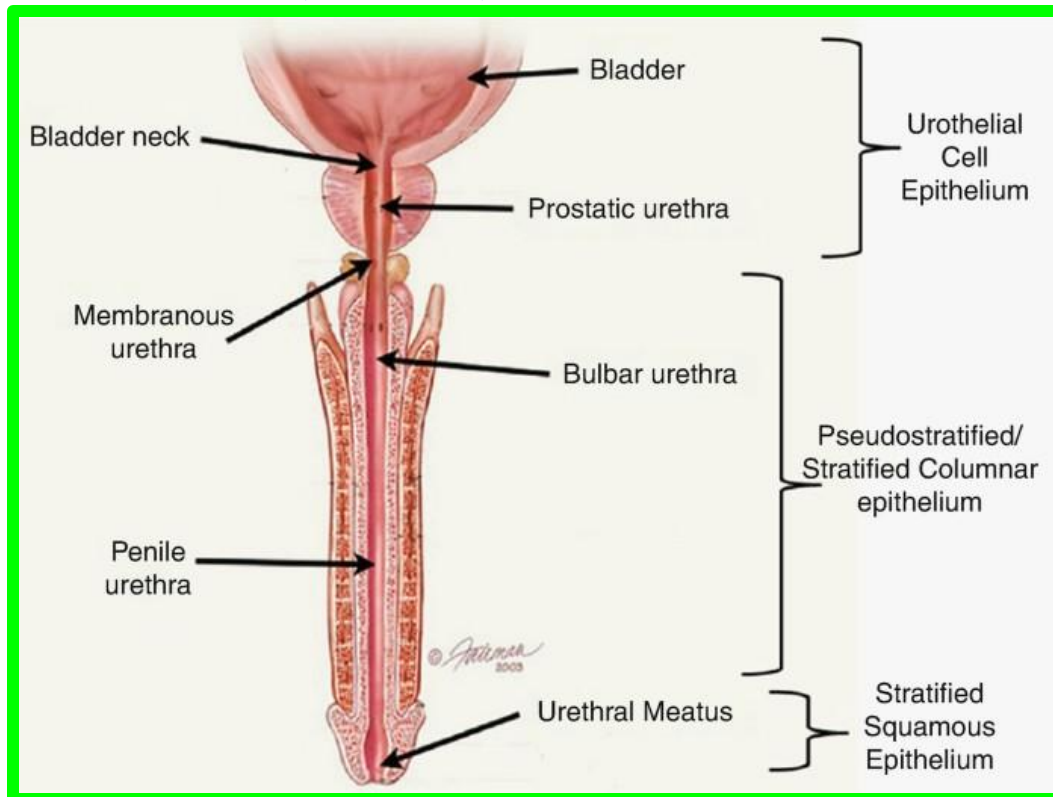
**** Begins:** from **internal urethral orifice** in the urinary bladder.

**** Ends:** **external urethral orifice** at the tip of the glans penis.

The narrowest point in the whole male urethra

**** Length:** It is about **20 cm long**.

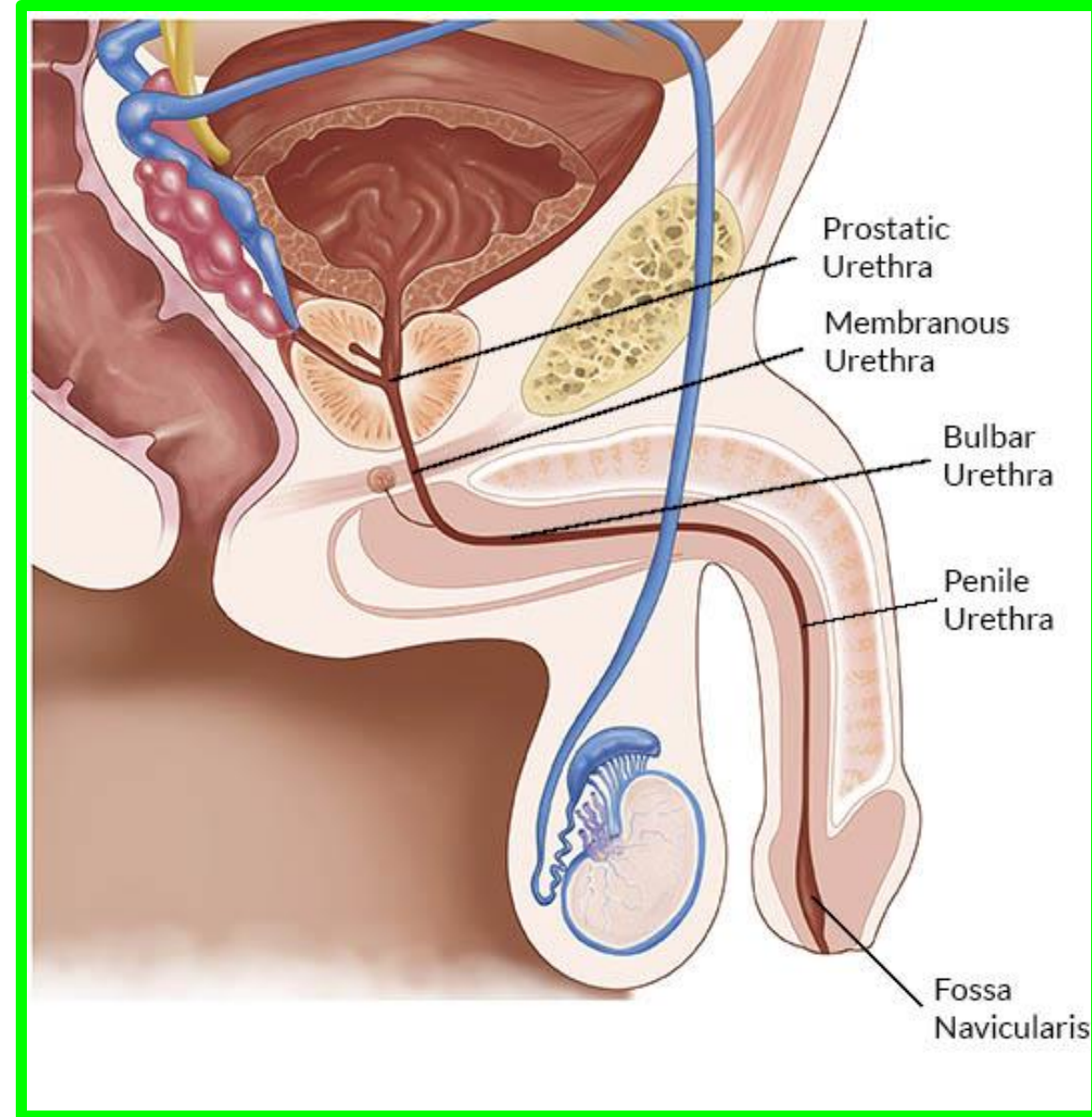
**** Divisions (parts):** It is divided into **3 parts**



Male Urethra

I. Prostatic Urethra: about 3 cm long

- ❖ It pierces the **base of the prostate** and exits from its apex.
- ❖ It is **the widest and most dilatable division** of the male urethra.
- ❖ It lies **nearer the anterior surfaces** of the prostate.



Male Urethra

- The posterior wall presents a number of features.

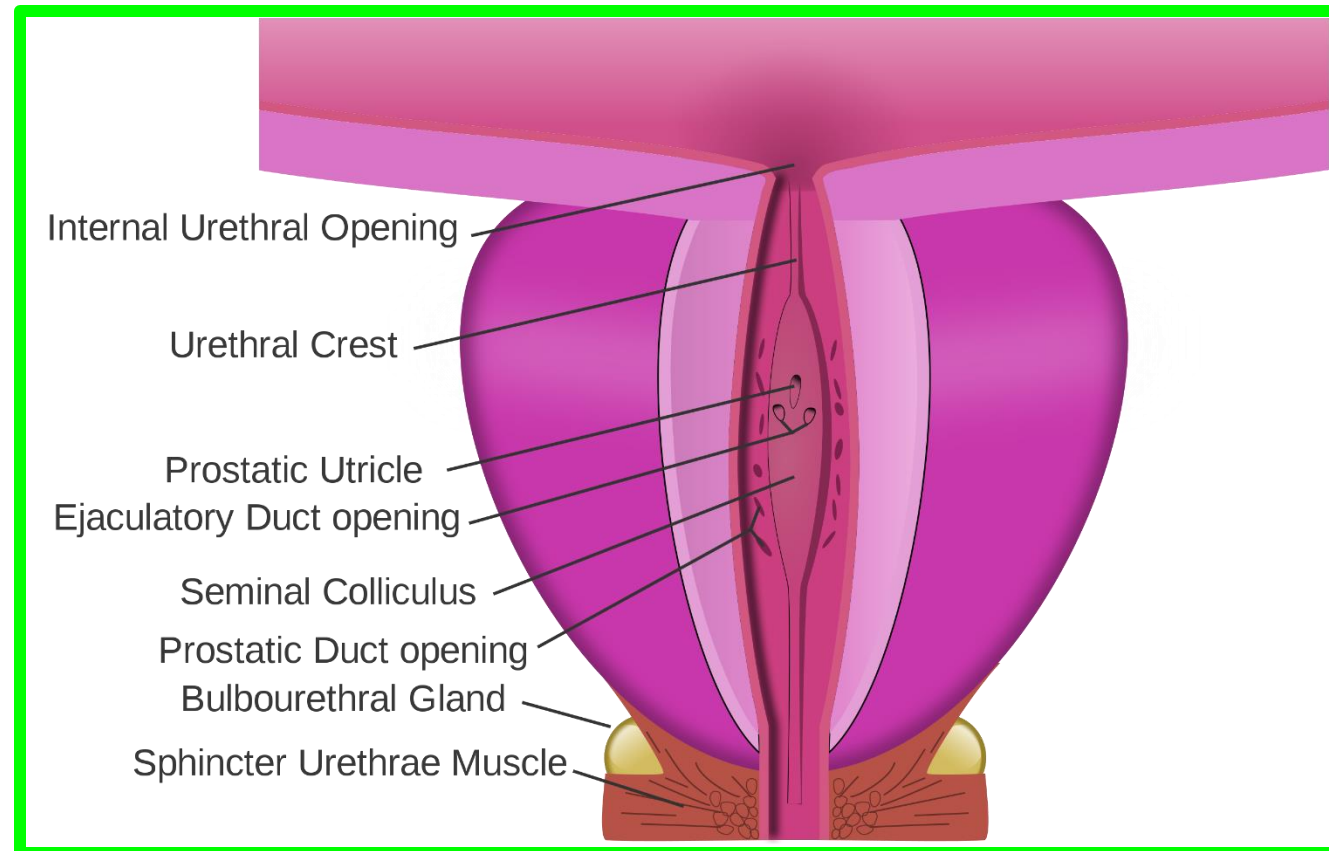
1. **Urethral crest**, a median longitudinal elevation.

2. **Prostatic sinuses**, shallow grooves around the urethral crest receiving the opening of the prostatic glands.

3. **Seminal colliculus** is a swelling in the middle of the urethral crest showing 3 openings;

A. The opening of the prostatic utricle (homologue the uterus in female).

B. 2 lateral openings of the ejaculatory ducts.



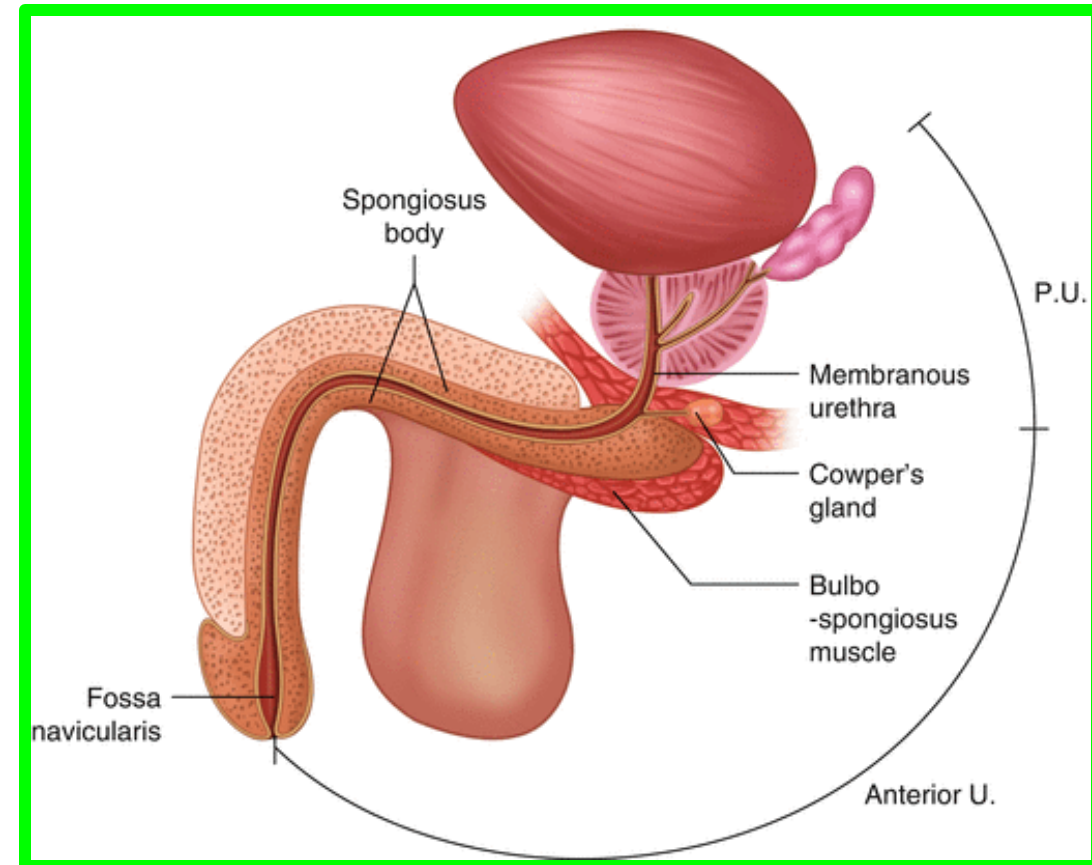
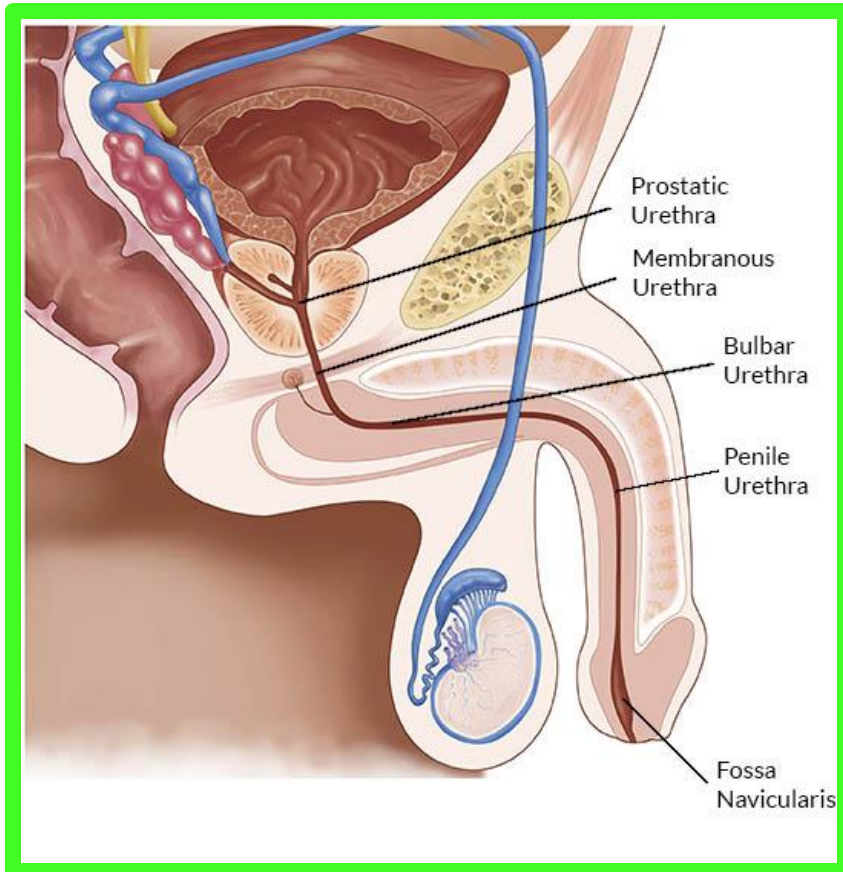
Male Urethra

Dr. Aiman AL Maathidy
Sunday 3 May 2026

6

II. Membranous Urethra: about 2 cm long

- ✓ It is the **narrowest division** of the male urethra.
- ✓ It **traverses deep perineal pouch**.
- ✓ It is surrounded by the **sphincter of the urethra**.



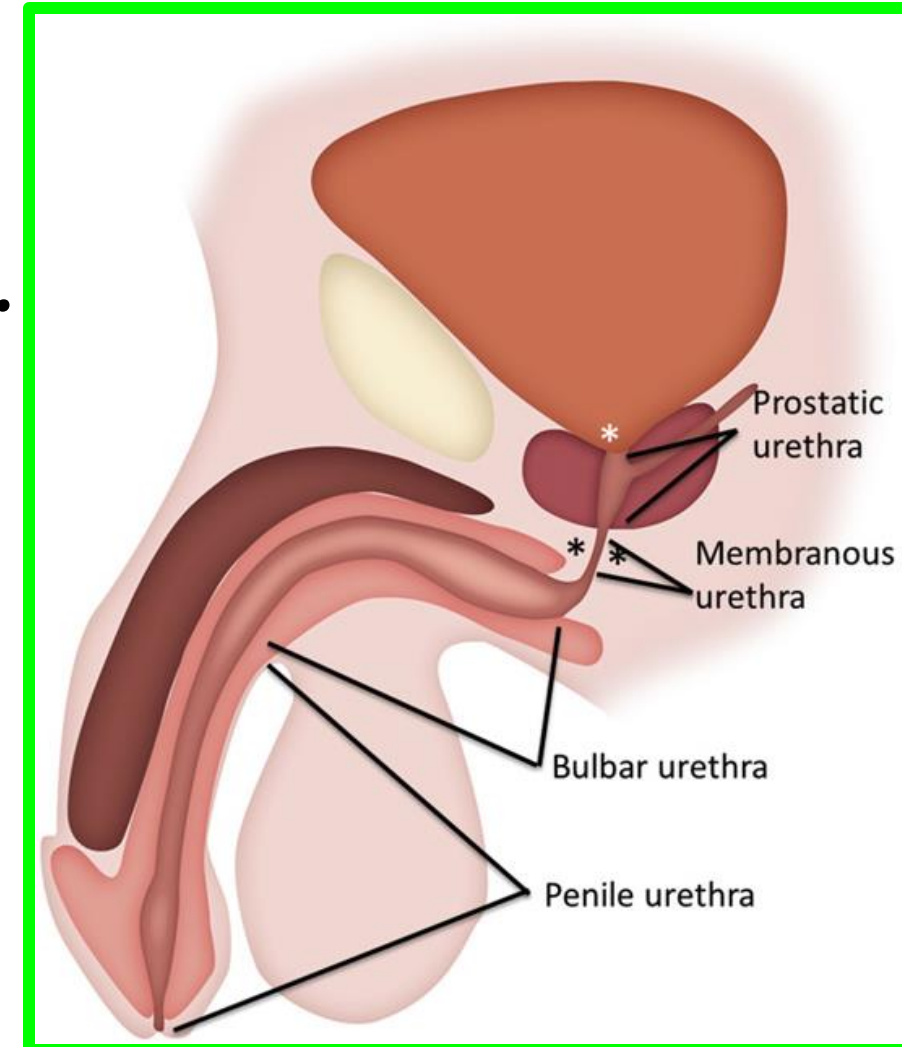
III. Spongy (Penile) Urethra about 15 cm long

✓ It transverses the bulb of the penis and corpus spongiosum.

✓ It presents 2 dilatation

a. **Intrabulbar fossa**, at its beginning in the bulb.

b. **Fossa terminalis (navicularis)** at its termination in the glans.



Male Urethra

** Urethral sphincters:

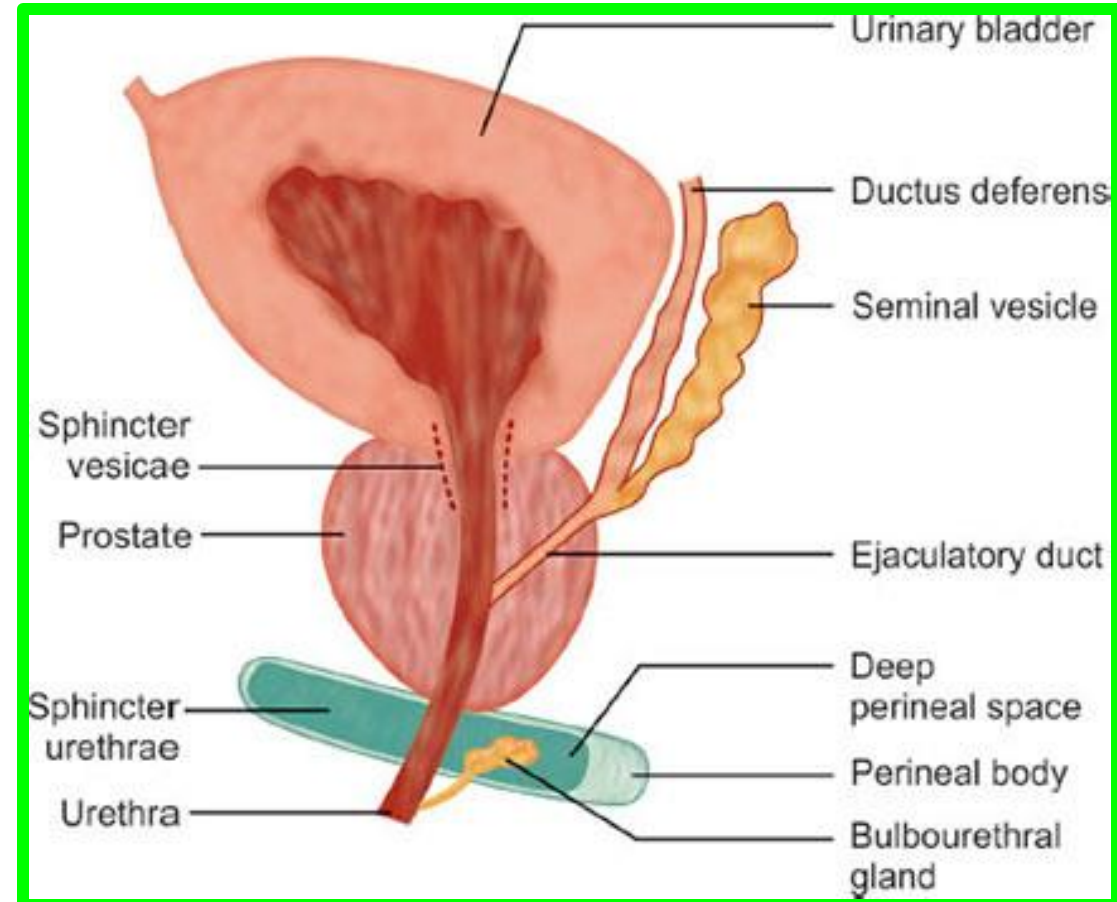
1. Internal urethral sphincter (sphincter vesicae).

❖ It surrounds the neck of the bladder and the prostatic urethra above the opening of the ejaculatory ducts.

✓ It is smooth muscle fibers.

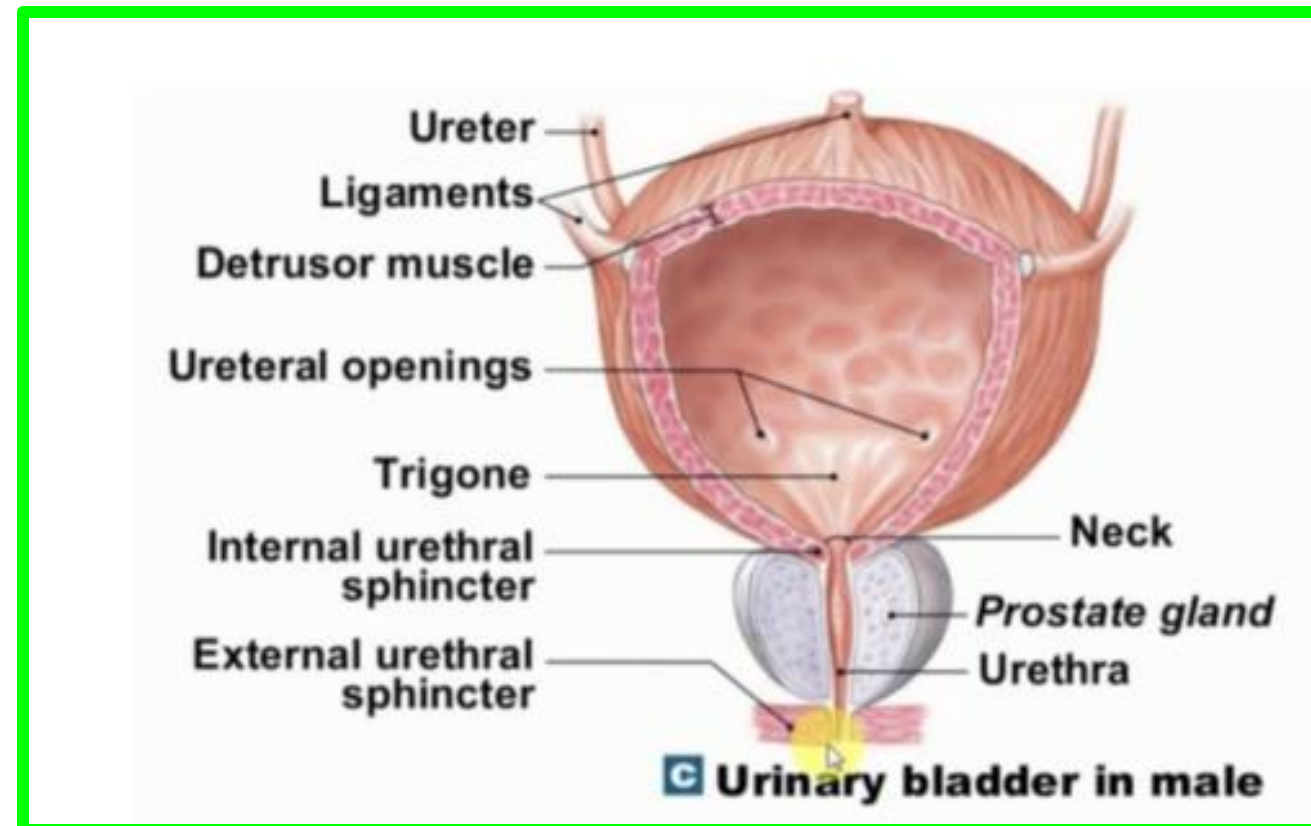
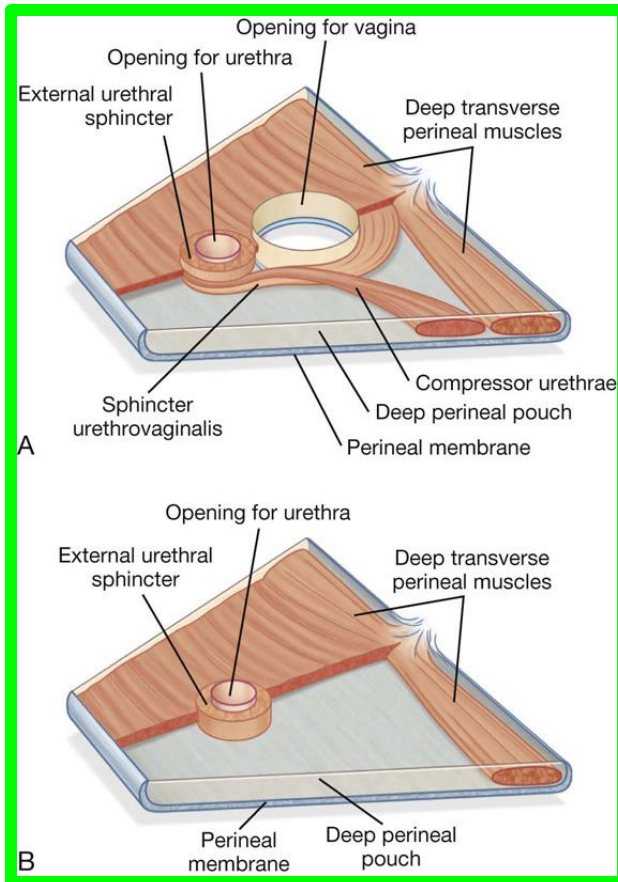
✓ It is **involuntary** and supplied by **autonomic fibers**.

✓ This sphincter contracts during ejaculation to prevent retrograde ejaculation (ejaculatory reflux) of semen into the bladder.



2. External urethral sphincter (sphincter urethrae)

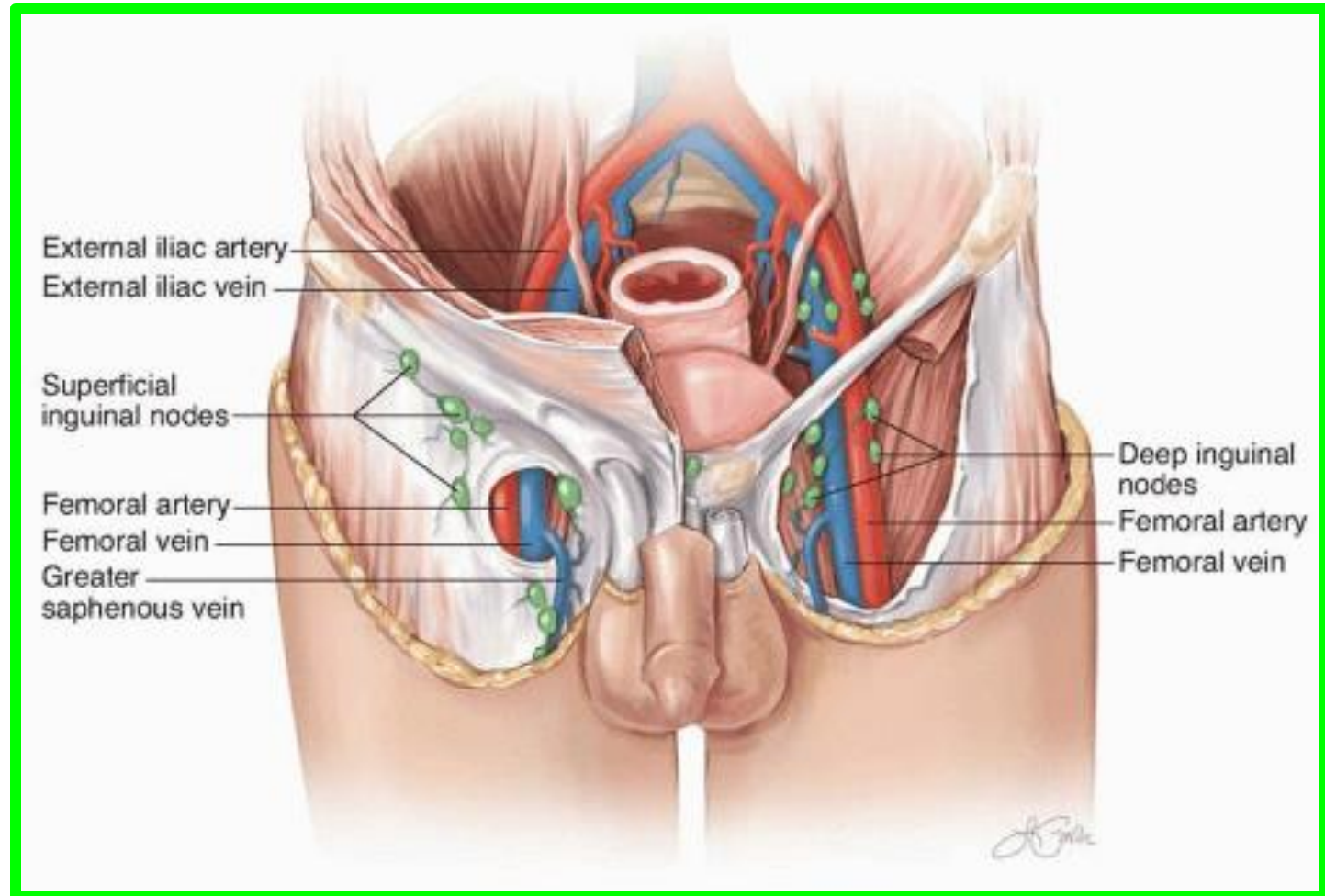
- ✓ It surrounds the membranous urethra in the deep perineal pouch.
- ✓ It is a striated muscle fibers.
- ✓ It is voluntary and supplied by the perineal branch of the pudendal nerve.



Male Urethra

** Lymphatic drainage

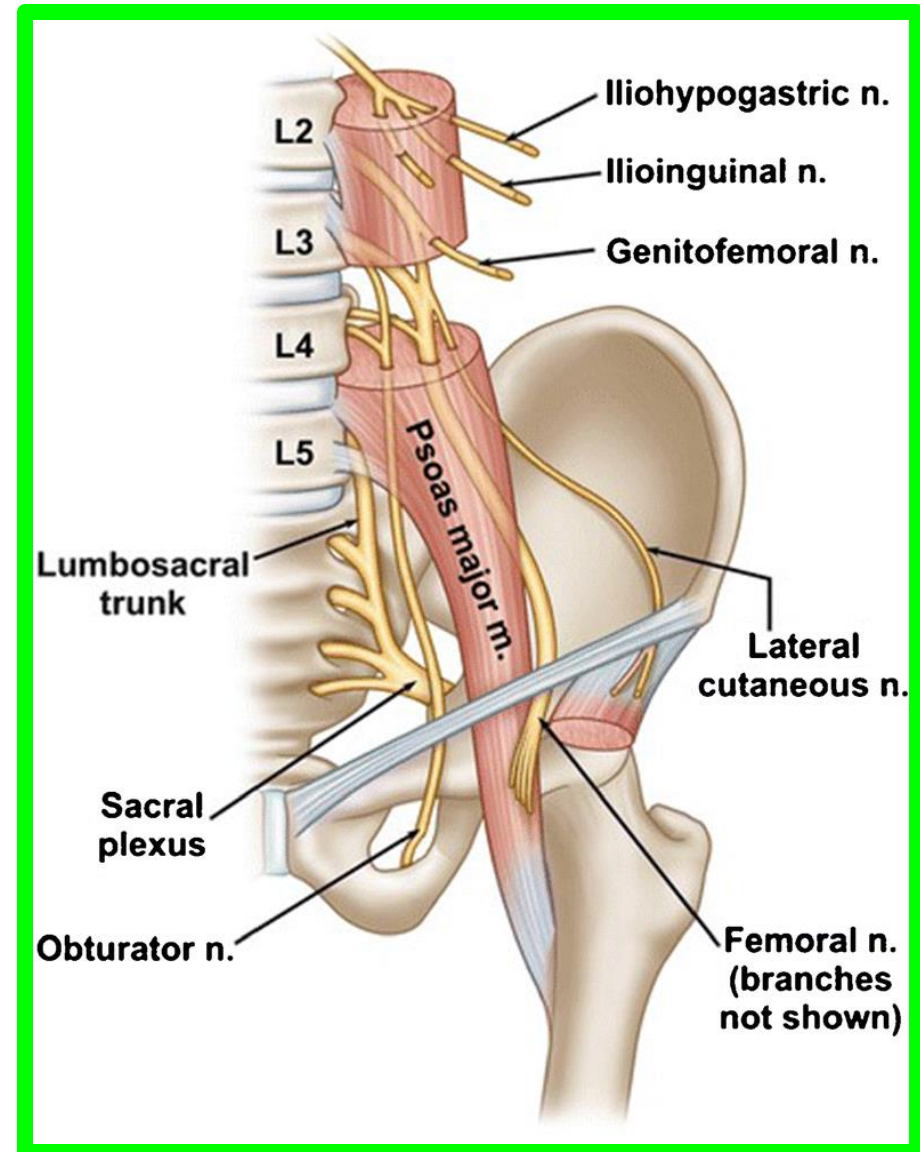
1. The prostatic and membranous parts drain into the internal iliac lymph nodes.
2. The penile (spongy) urethra drains into the deep inguinal lymph nodes.



The lumbar plexus

The supply motor and sensory innervation to the lower limb and pelvic girdle and formed by the ventral rami of **L1-L4**

1. The iliohypogastric nerve (**T12,L1**)
2. The ilioinguinal nerve (**L1**)
3. The genitofemoral nerves (**L1,L2**)
4. The lateral femoral cutaneous nerve (**L2,L3**)
5. The obturator nerve (**L2,L3,L4**)
6. The femoral nerve (**L2,L3,L4**)



PELVIC NERVES

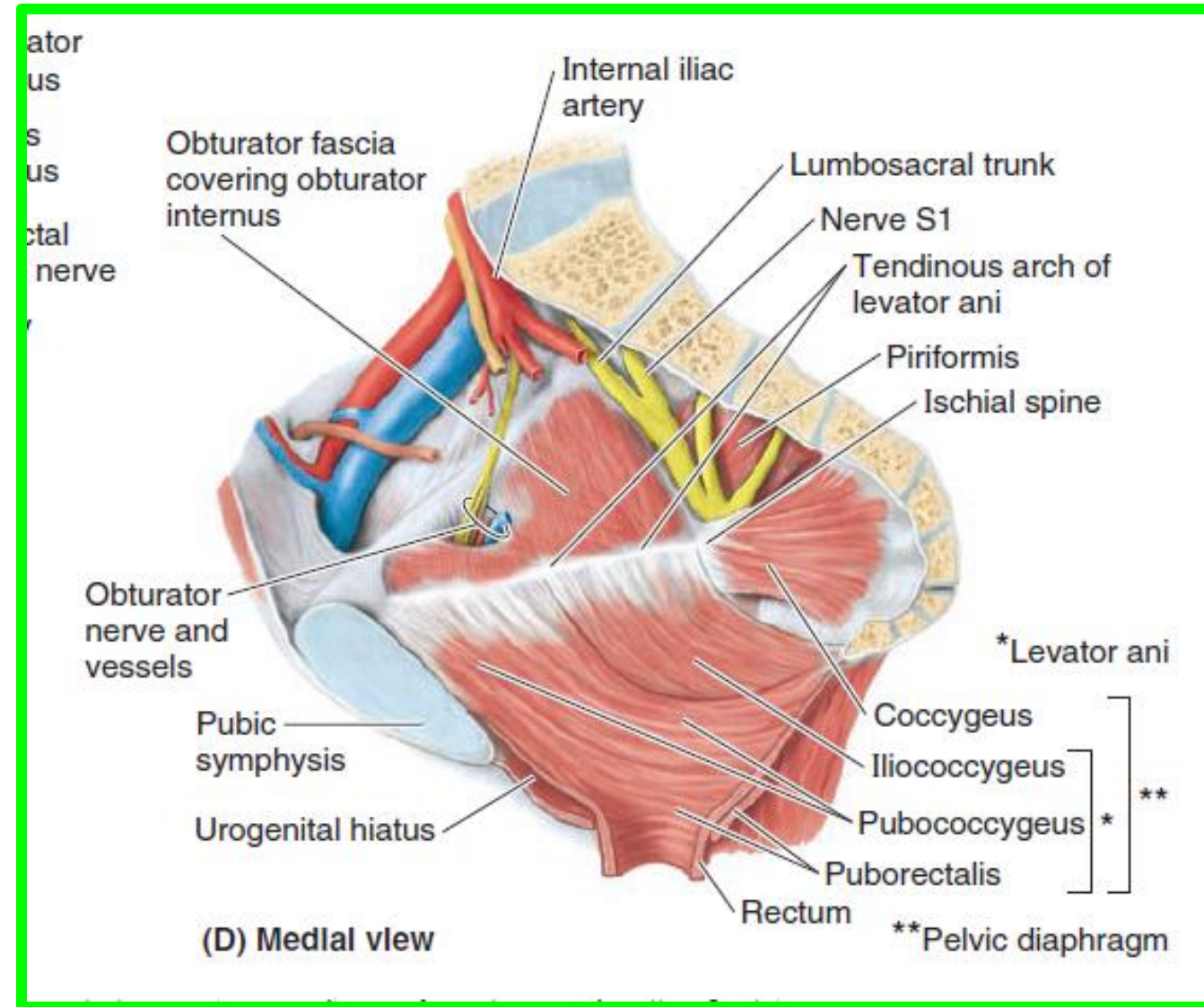
Dr. Aiman AL Maathidy
Sunday 3 May 2026

The pelvis is innervated mainly by:

1. The sacral spinal nerves
2. The coccygeal spinal nerves and
3. The pelvic part of the autonomic nervous system.

The **piriformis** and **coccygeus** muscles form a bed for the **sacral** and **coccygeal nerve plexuses**

The anterior rami of the **S2** and **S3** nerves emerge between the digitations of these muscles.



OBTURATOR NERVE

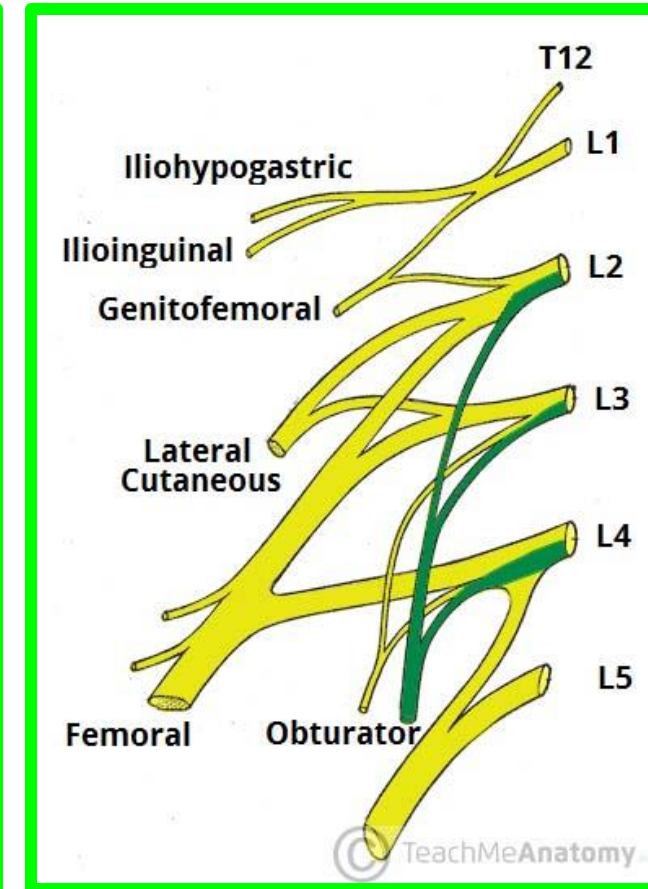
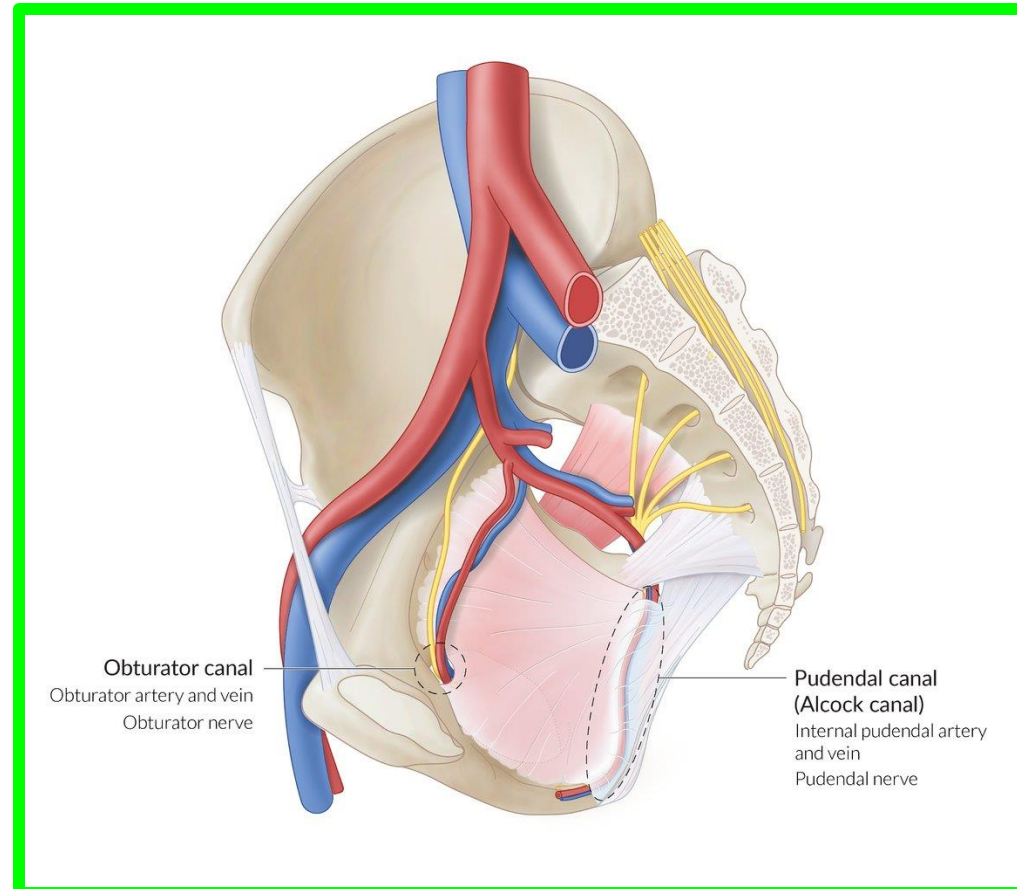
Sunday 3 May 2026

13

Dr. Aiman AL Maathidy

❖ The **obturator nerve** arises from the anterior rami of spinal nerves **L2-L3-L4** of the **lumbar plexus** in the abdomen (greater pelvis) and **enters the lesser pelvis**.

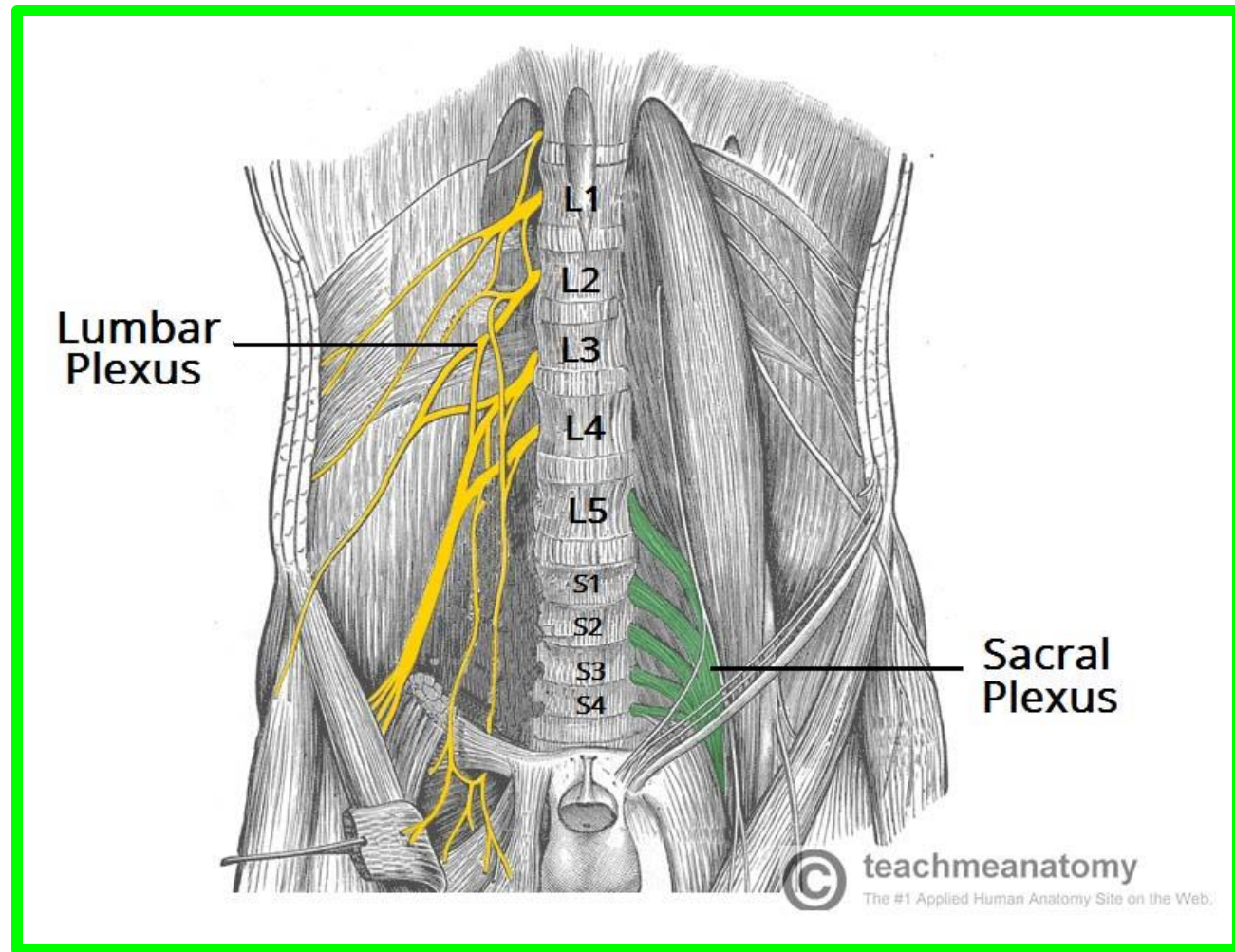
❖ It runs in the extraperitoneal fat along the lateral wall of the pelvis to **the obturator canal**, an opening in the obturator membrane that otherwise fills the obturator foramen.



❖ **No pelvic structures are supplied by the obturator nerve.**

SACRAL PLEXUS

- ❖ The sacral plexus is located on the **posterolateral wall of the lesser pelvis**.
- ❖ The two main nerves arising from the sacral plexus, **the sciatic and pudendal nerves**, lie external to the parietal pelvic fascia.
- ❖ Most branches of the sacral plexus leave the pelvis through **the greater sciatic foramen**.



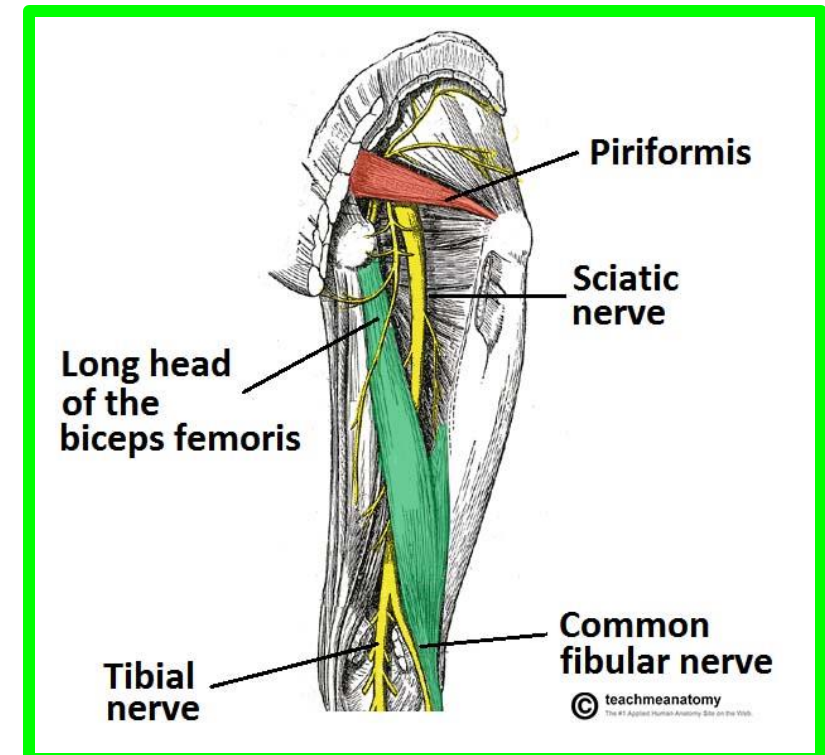
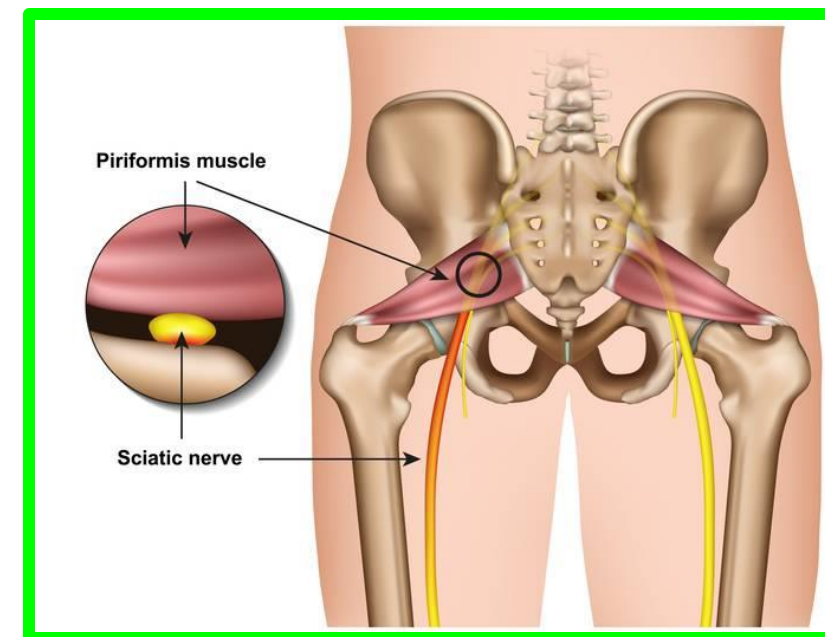
SACRAL PLEXUS

15

Sunday 3 May 2026
Dr. Aiman AL Maathidy

❖ (1) The sciatic nerve

- ✓ Is the largest nerve in the body.
- ✓ It is formed as the large **anterior rami of spinal nerves L4, L5, S1, S2, S3**
- ✓ As it is formed, the sciatic nerve **passes through the greater sciatic foramen, usually inferior to the piriformis, to enter the gluteal region.**
- ✓ Supply Articular branches to hip joint and muscular branches to flexors of knee in thigh and all muscles in leg and foot



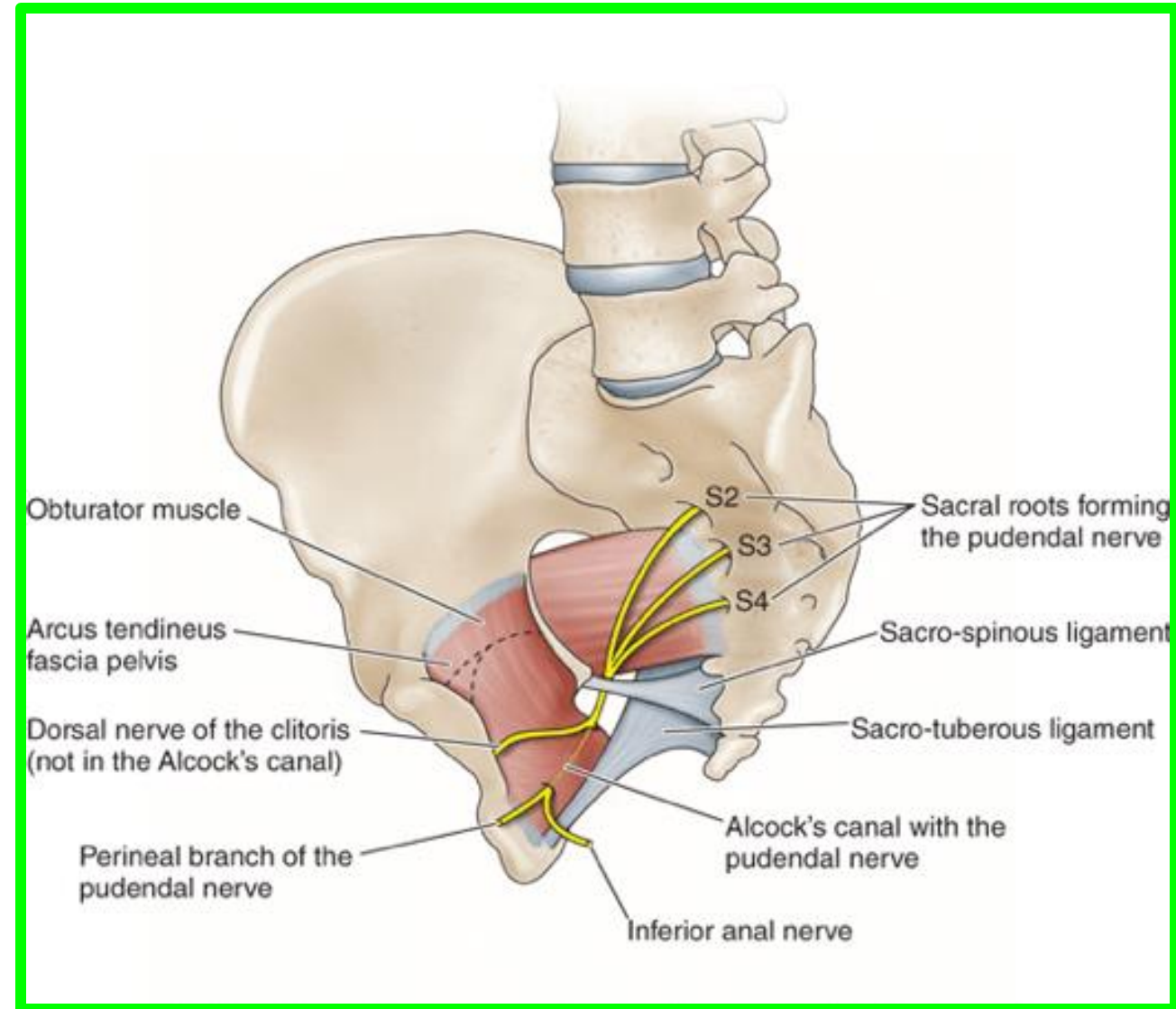
SACRAL PLEXUS

❖(2) The pudendal nerve

✓ is the main nerve of the perineum and the chief sensory nerve of the external genitalia.

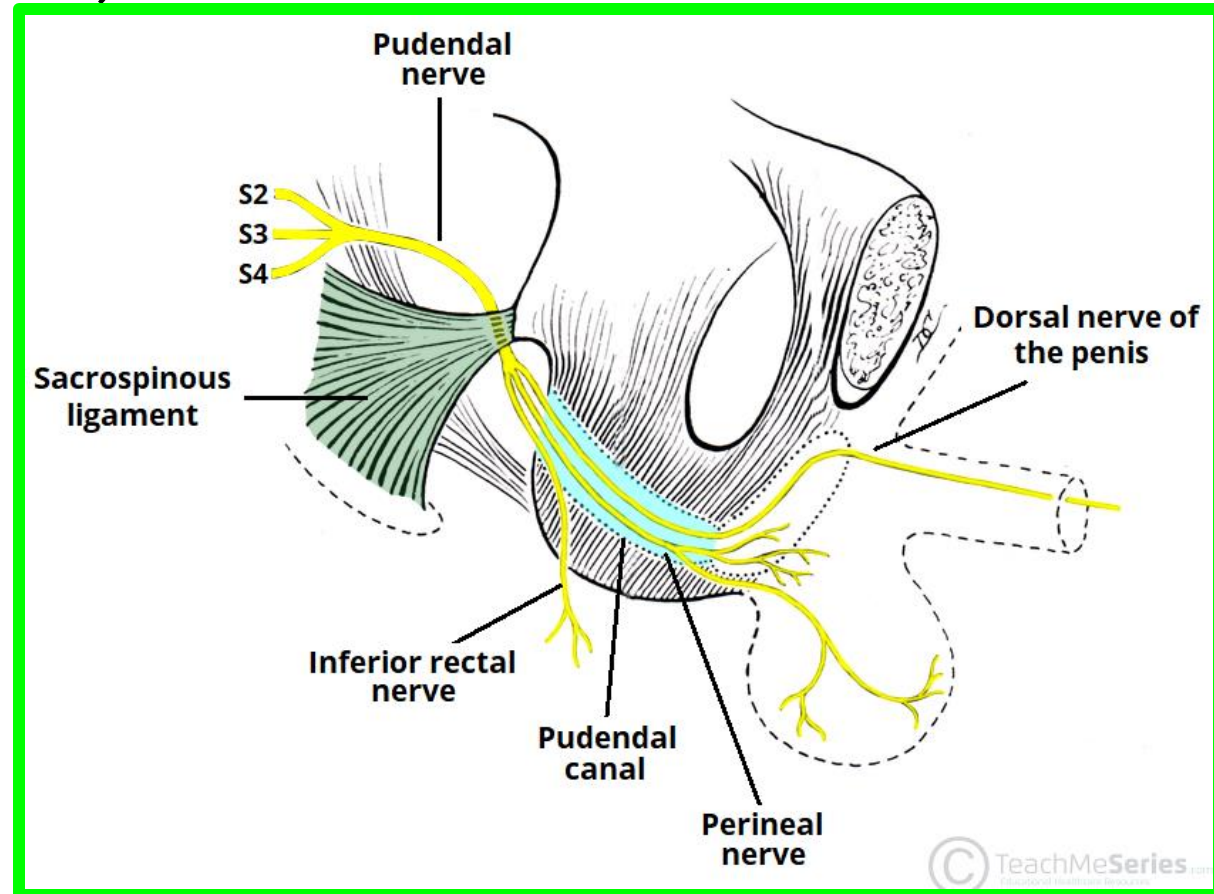
✓ Accompanied by the internal pudendal artery, it leaves the pelvis through the greater sciatic foramen between the piriformis and coccygeus muscles.

✓ It then hooks around the ischial spine and sacrospinous ligament and enters the perineum through the lesser sciatic foramen



❖ (2) The pudendal nerve

- ❖ Origin: **S2, S3, S4**
- ❖ Supply: Structures in perineum:
 1. Sensory to genitalia;
 2. Muscular branches to perineal muscles,
 3. External urethral sphincter, and
 4. External anal sphincter



SACRAL PLEXUS

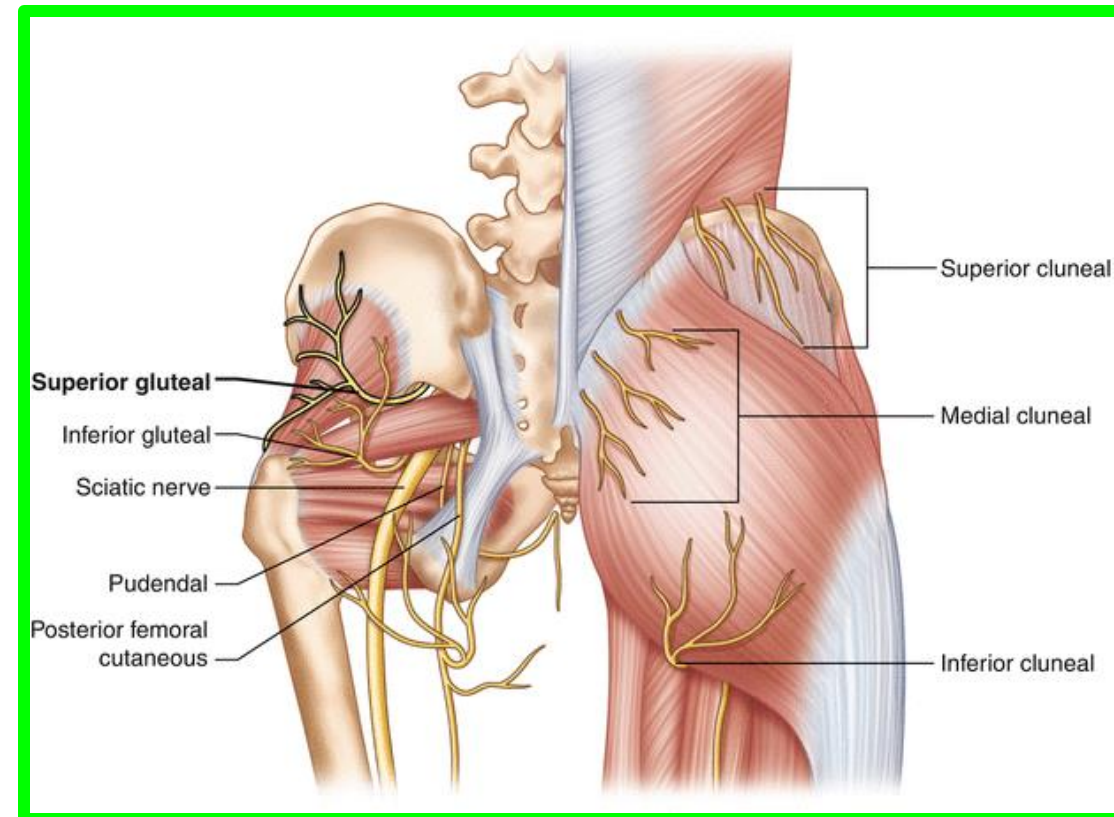
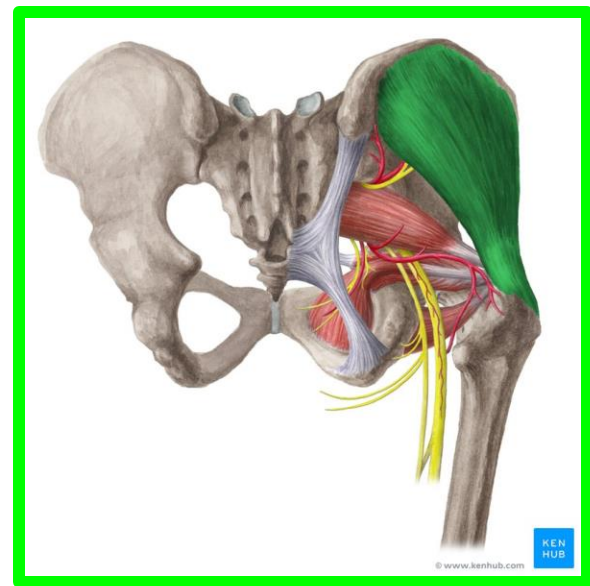
❖ (3) The superior gluteal nerve

The superior gluteal nerve leaves the pelvis through **the greater sciatic foramen**, superior to the piriformis to **supply muscles in the gluteal region**.

Origin: L4, L5, S1

To: Gluteus medius and gluteus minimus muscles

18



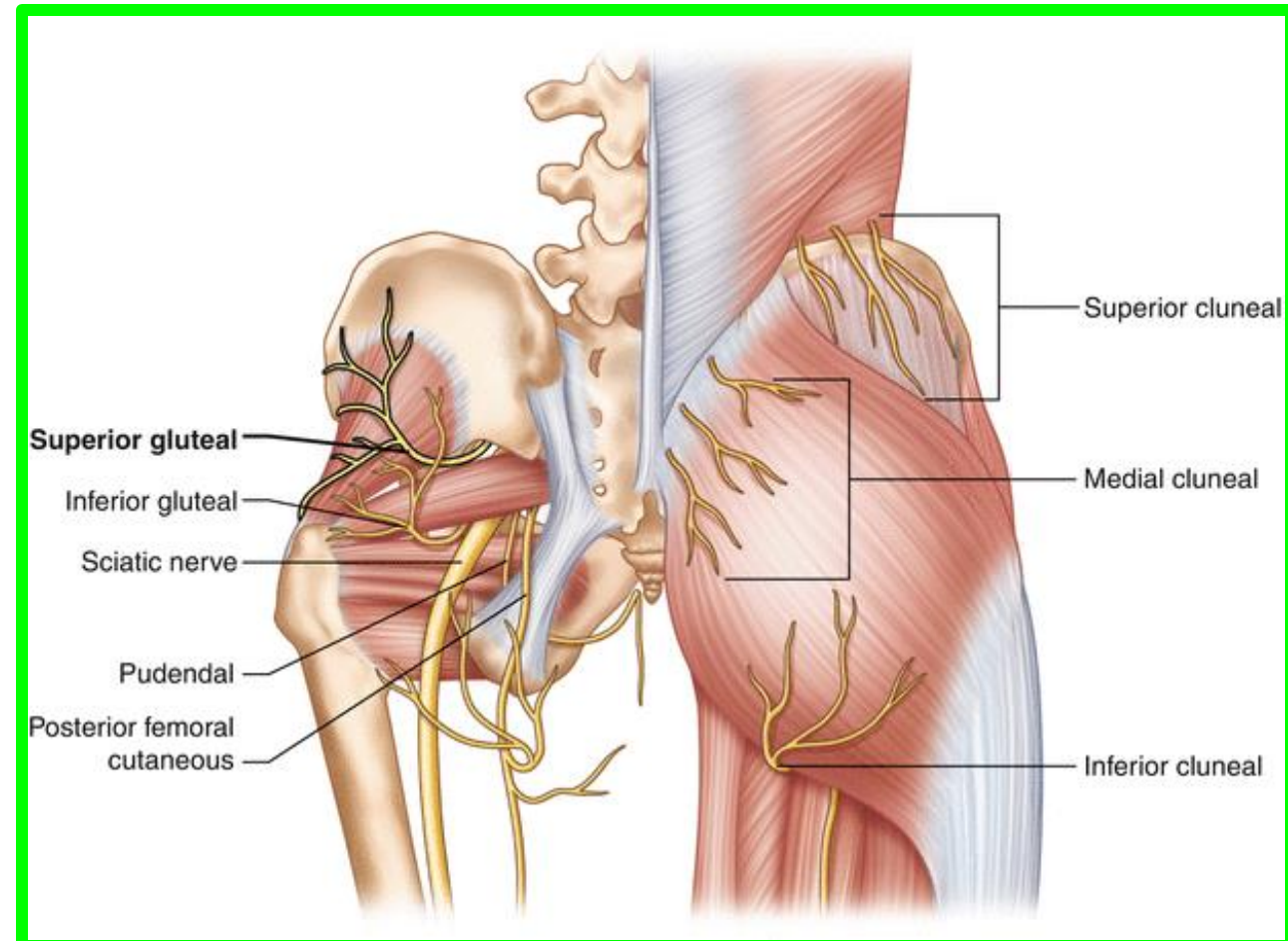
❖ (4) The inferior gluteal nerve

leaves the pelvis through **the greater sciatic foramen** inferior to the piriformis and superficial to **the sciatic nerve**, accompanying **the inferior gluteal artery**.

Both break up into several branches that enter the deep surface of the overlying **gluteus maximus muscle**.

Origin: **L5, S1, S2**

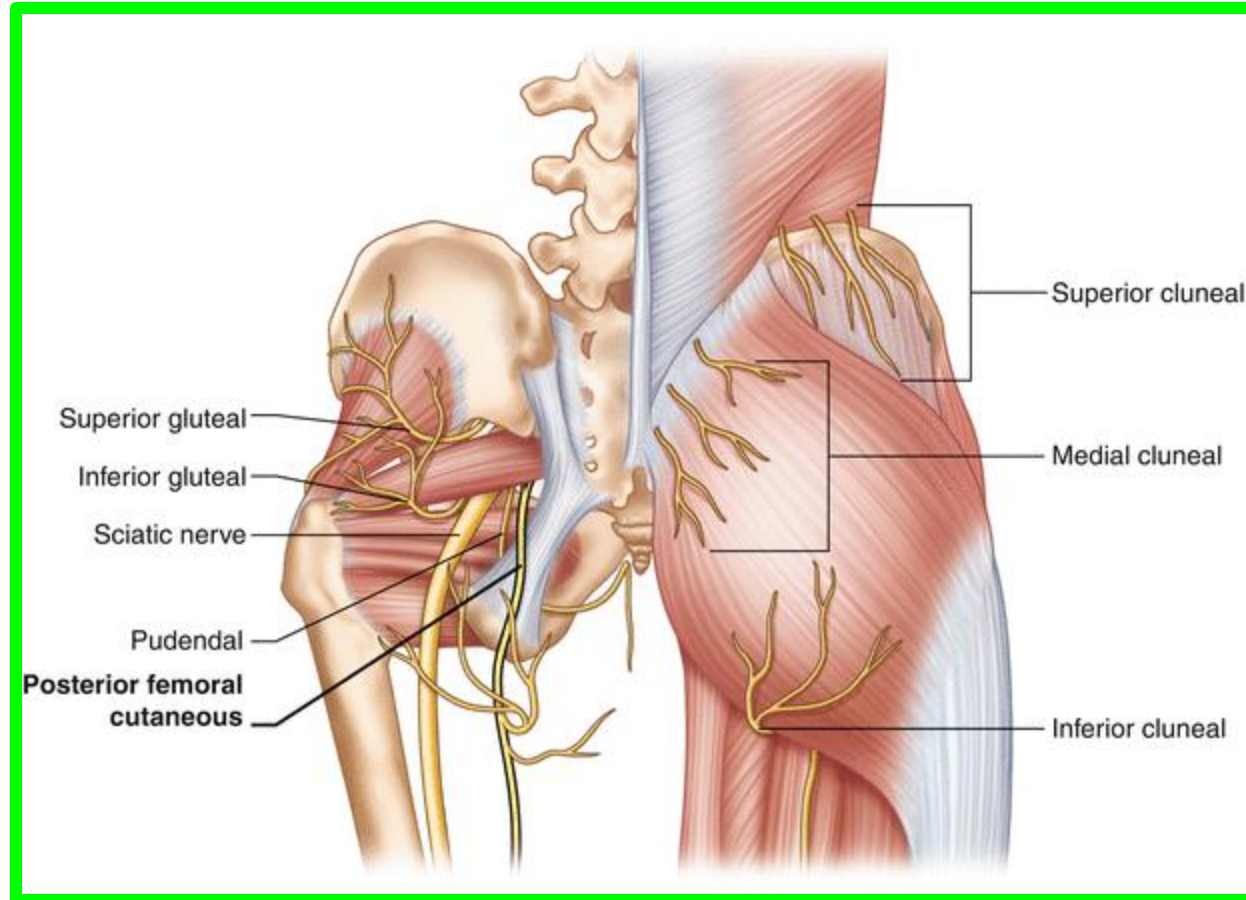
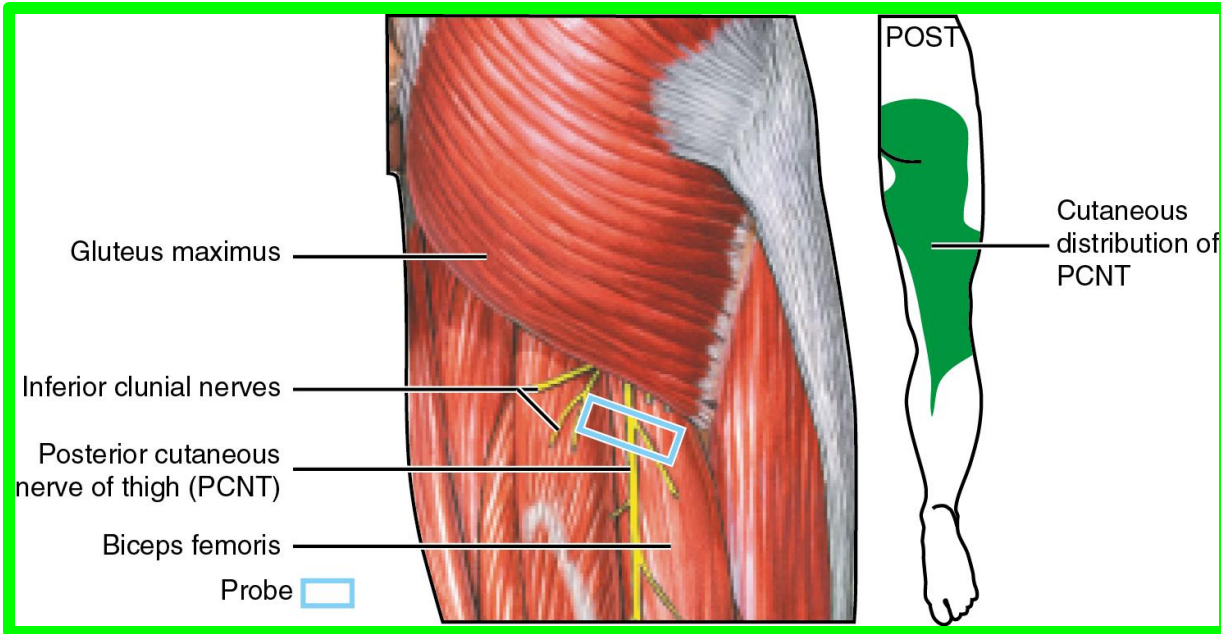
Supply: **Gluteus maximus**



❖ (5) Posterior cutaneous nerve of thigh

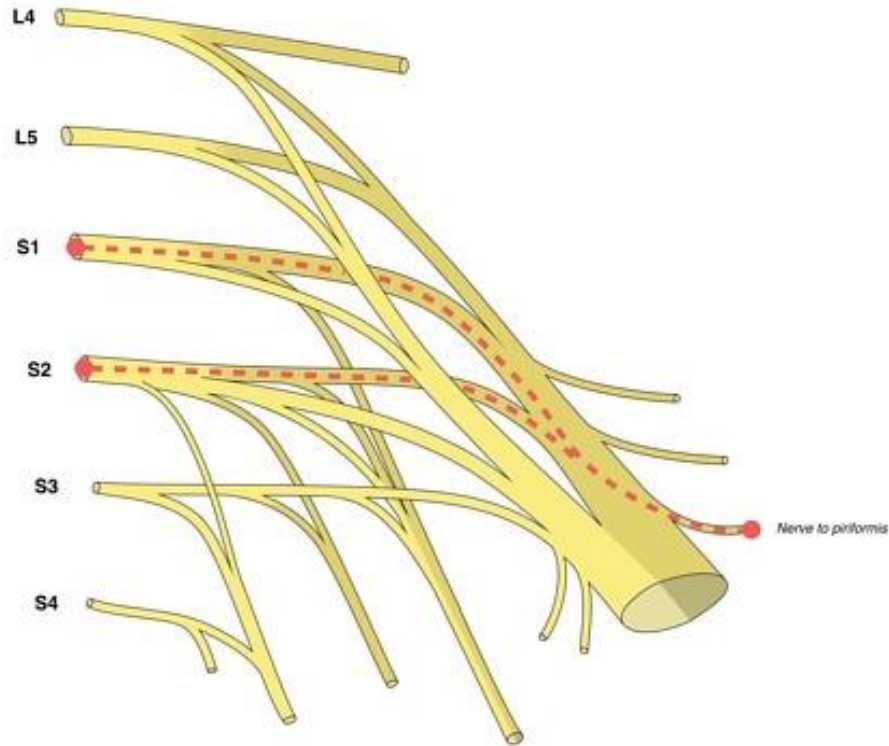
Origin: **S2, S3**

Supply: Cutaneous branches to buttock and uppermost medial and posterior surfaces of thigh

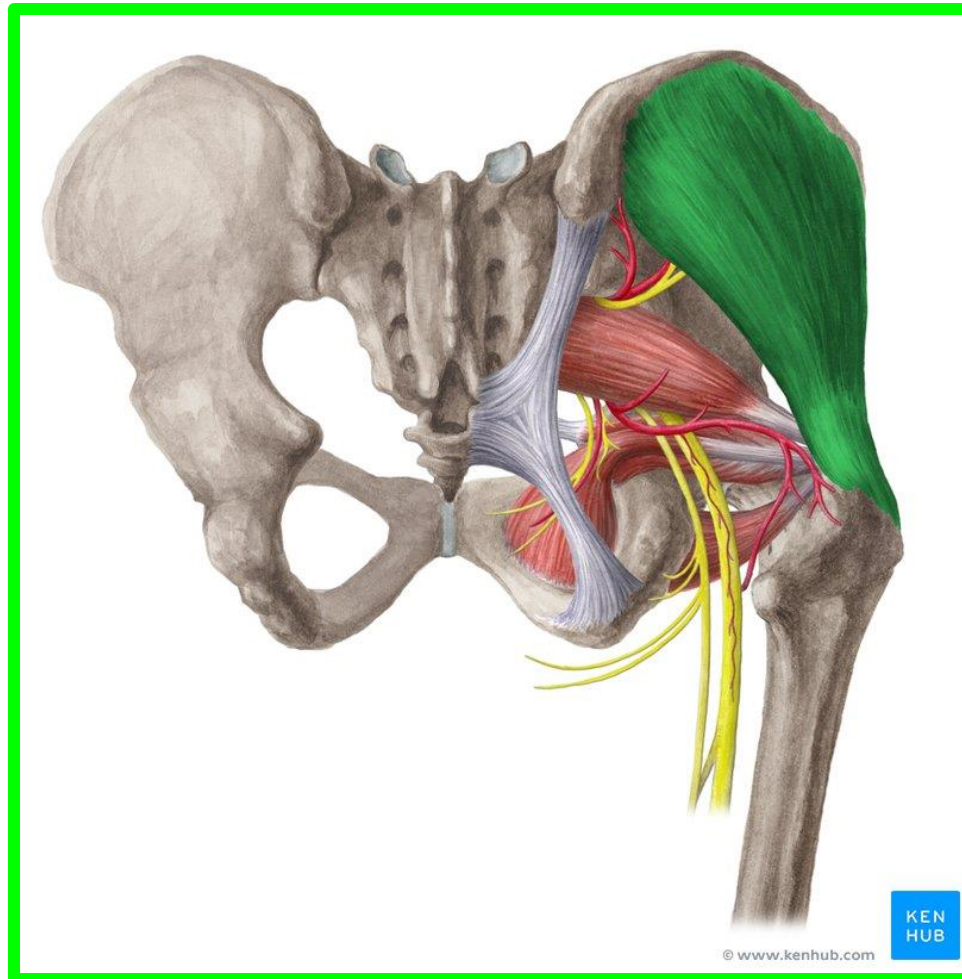


Number of small branches of the sacral plexus tend directly to supply muscles

❖ **Nerve to piriformis: Origin: S1, S2 Supply: Piriformis muscle**



Craig Hacking
2015 CC-BY-SA-NC
Radiopaedia.org



© www.kenhub.com

KEN
HUB

21

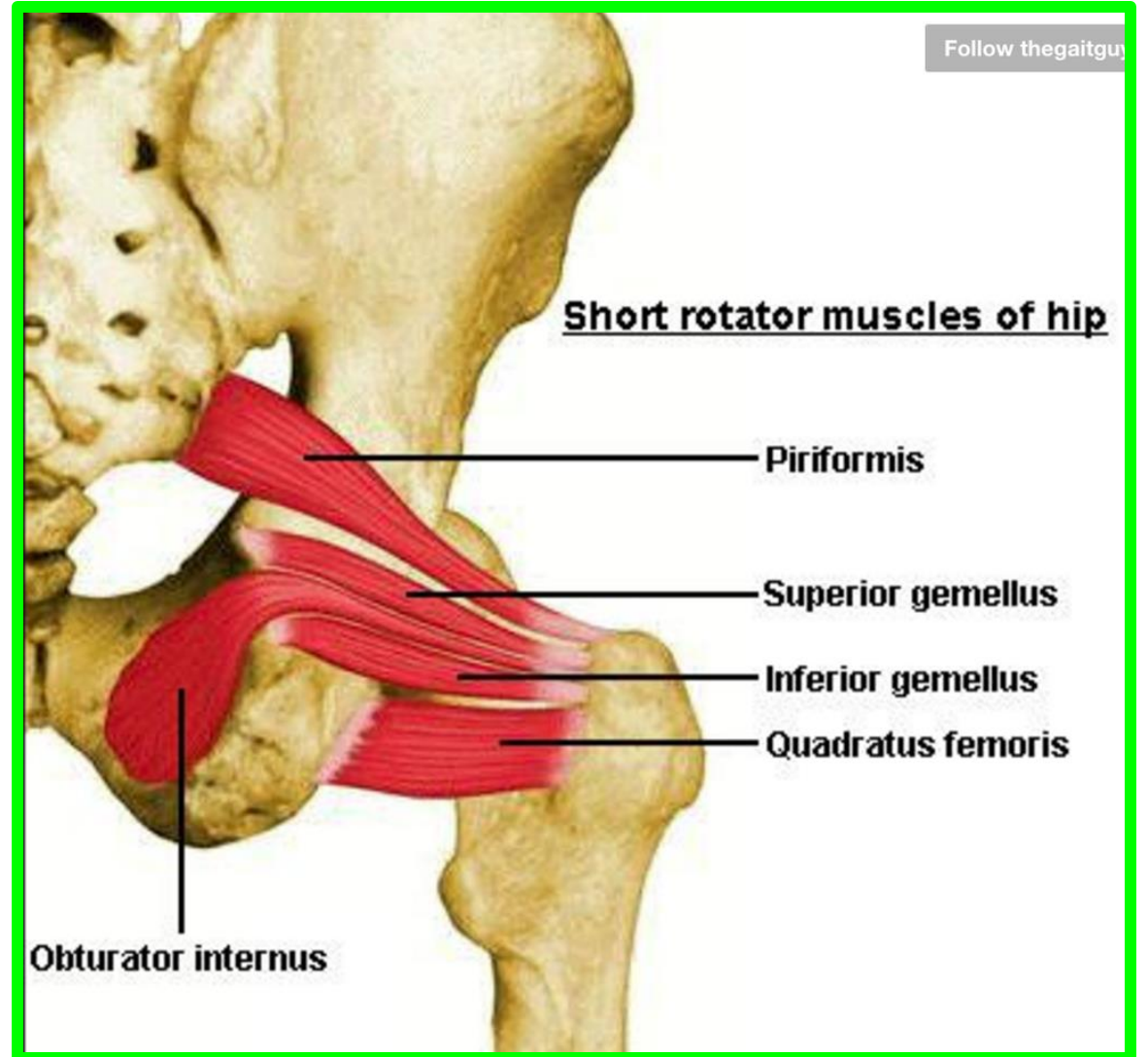
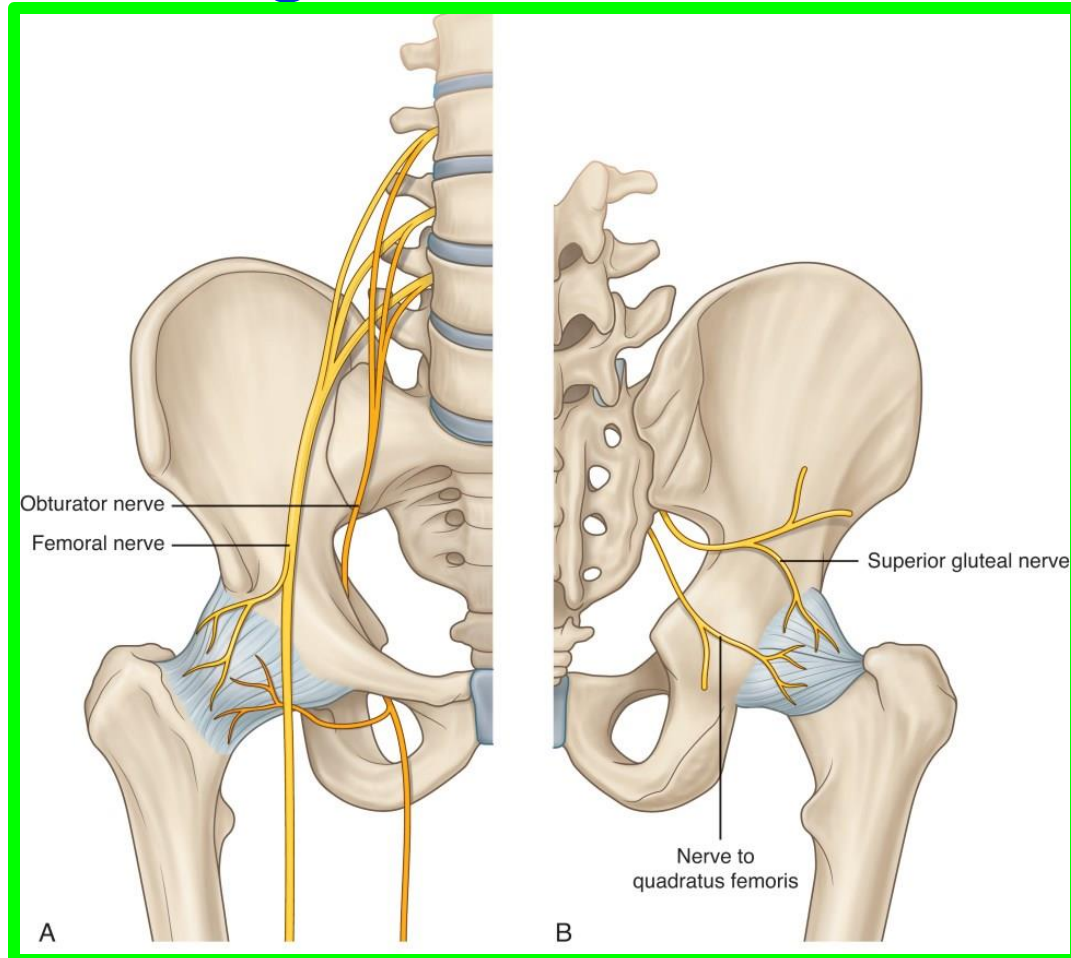
Sunday 3 May 2026

Dr. Aiman AL Maathidy

❖ Nerve to quadratus femoris (and inferior gemellus)

Origin: L4, L5, S1

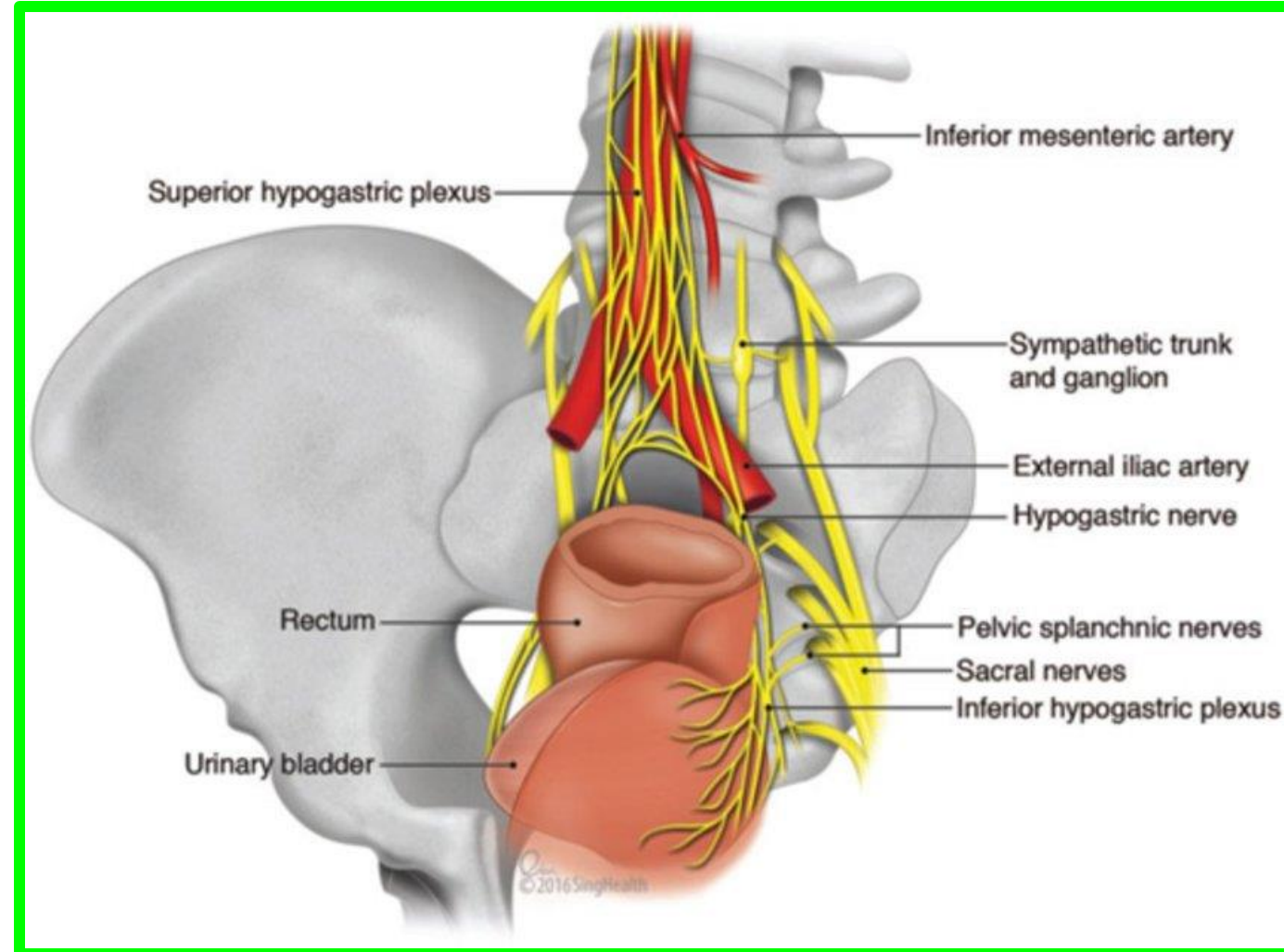
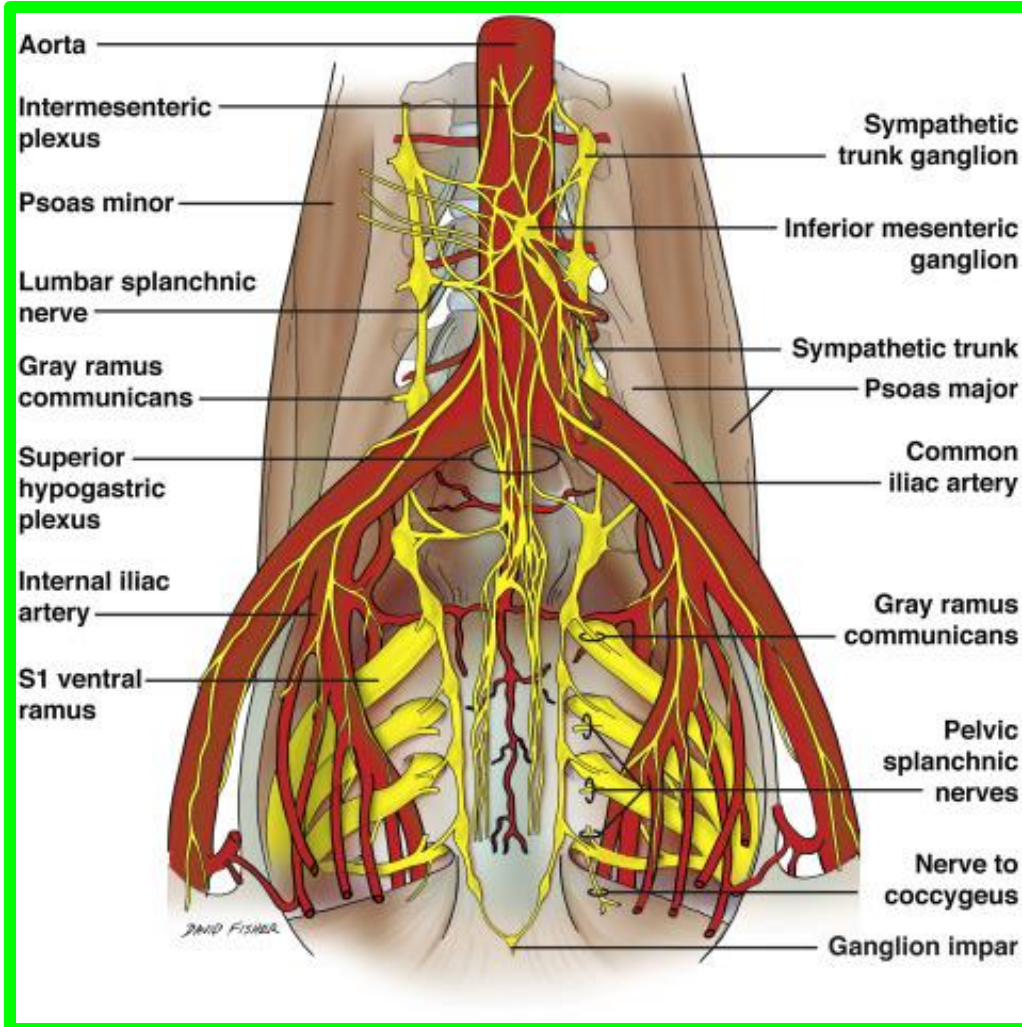
Supply: Quadratus femoris and inferior gemellus muscles



❖ Pelvic splanchnic Nerves

Origin: **S2, S3, S4**

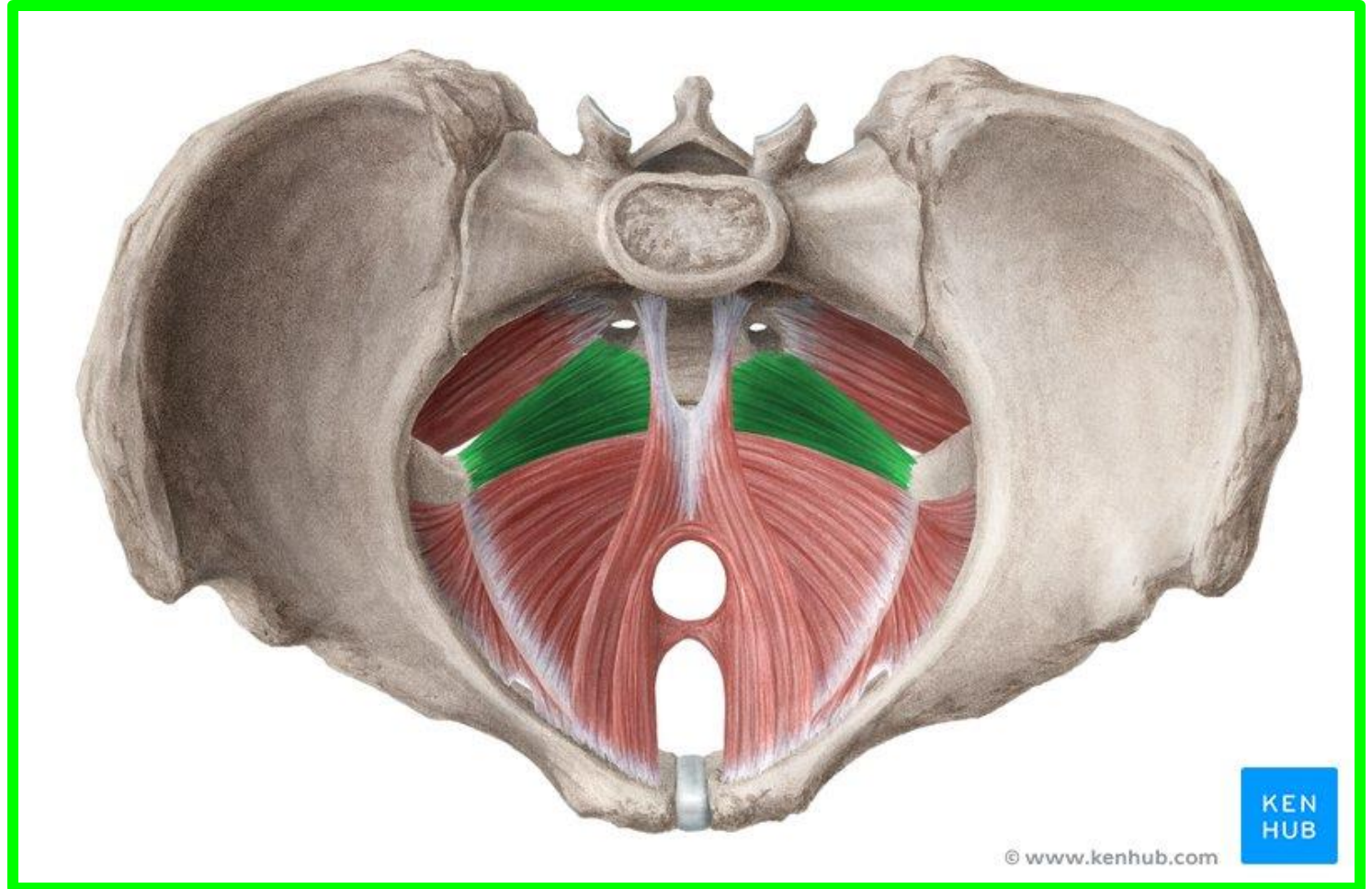
Supply: **Pelvic viscera** via inferior hypogastric and pelvic plexuses



❖ Nerves to levator ani and coccygeus

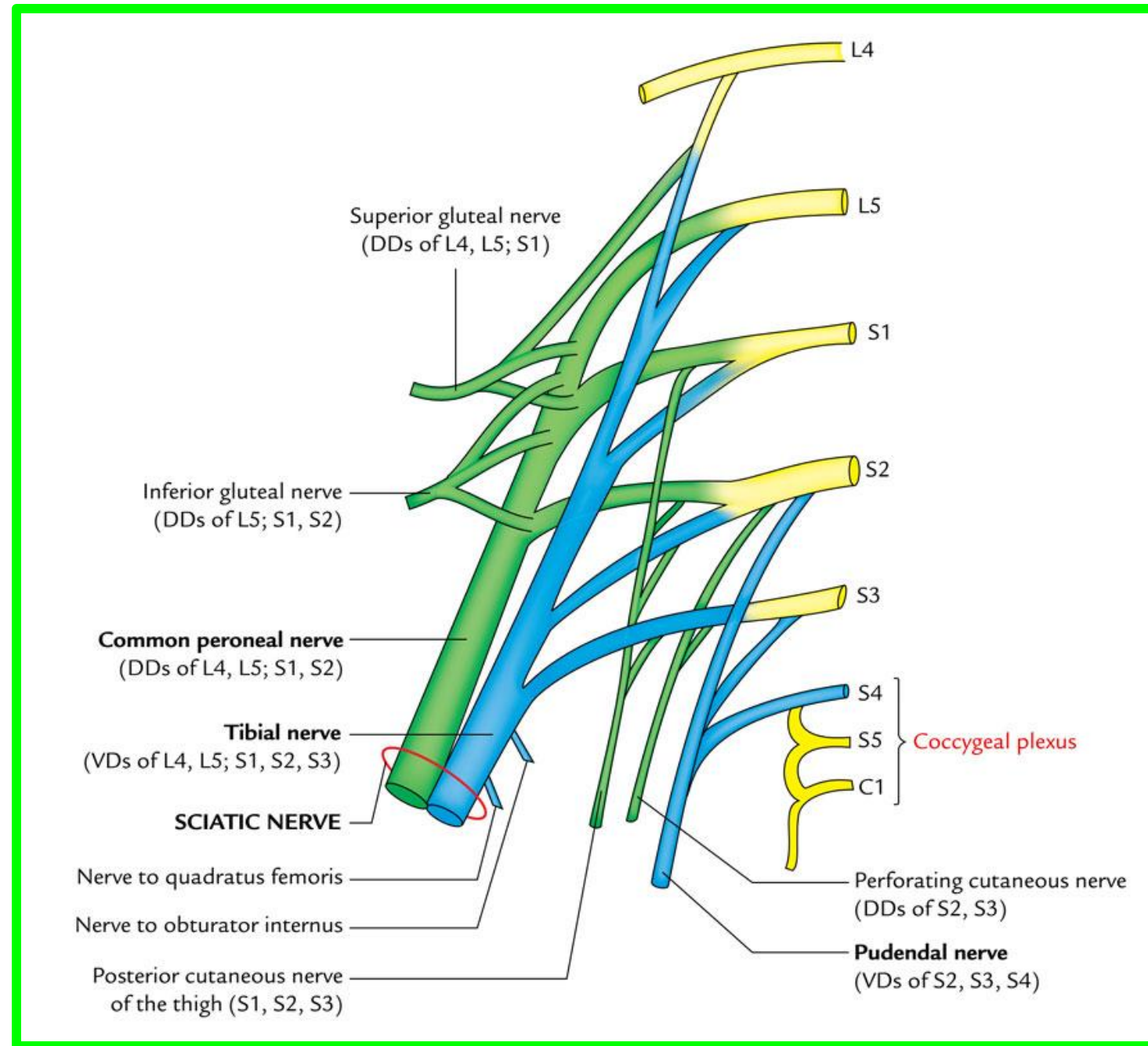
Origin: **S3, S4**

Supply: **Levator ani and coccygeus muscles**



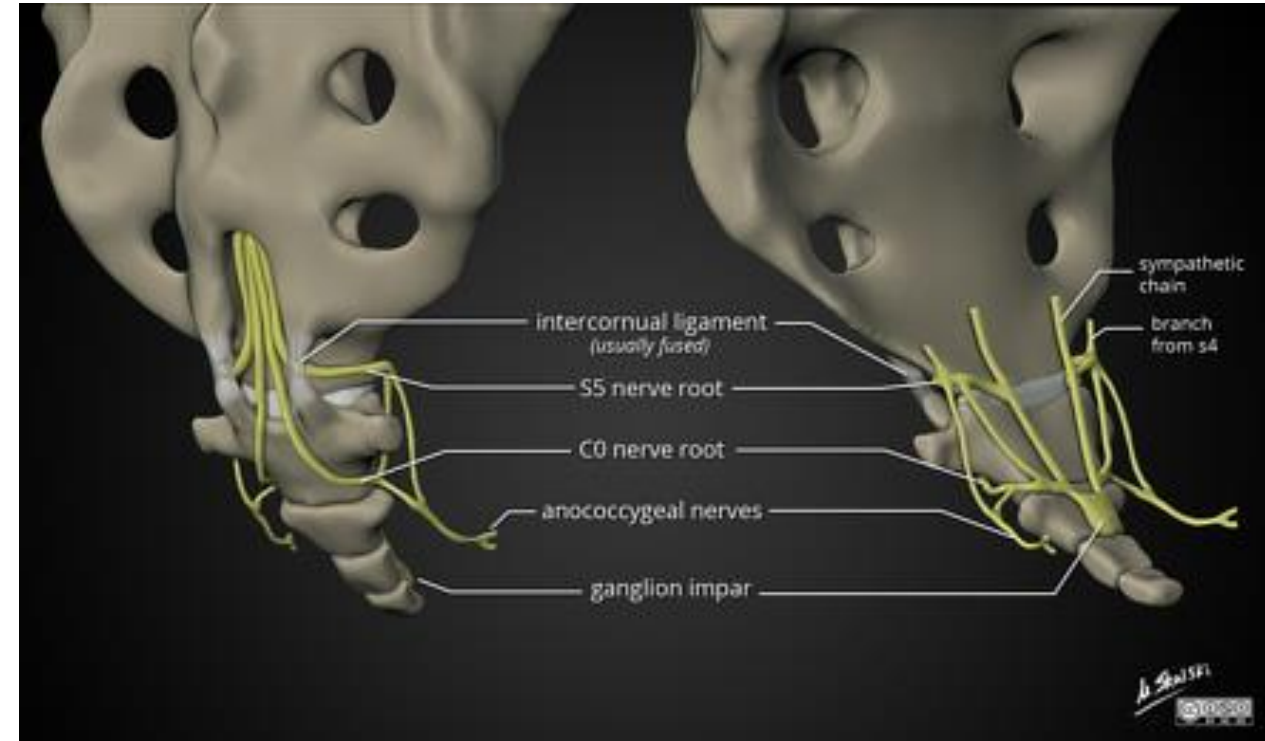
COCCYGEAL PLEXUS

The coccygeal plexus is a small network of nerve fibers formed by the anterior rami of **S4 and S5** and **the coccygeal nerve**



COCCYGEAL PLEXUS

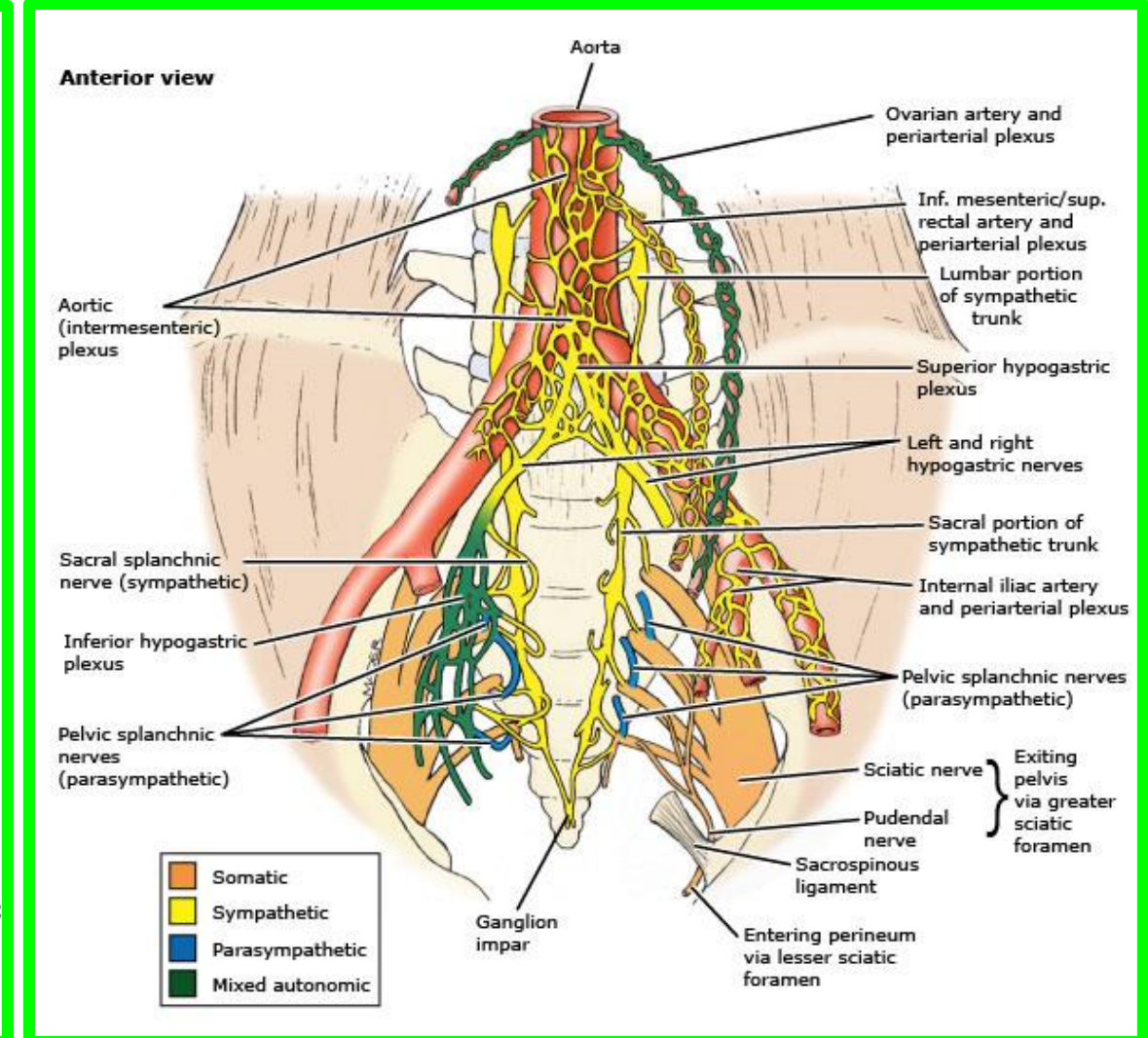
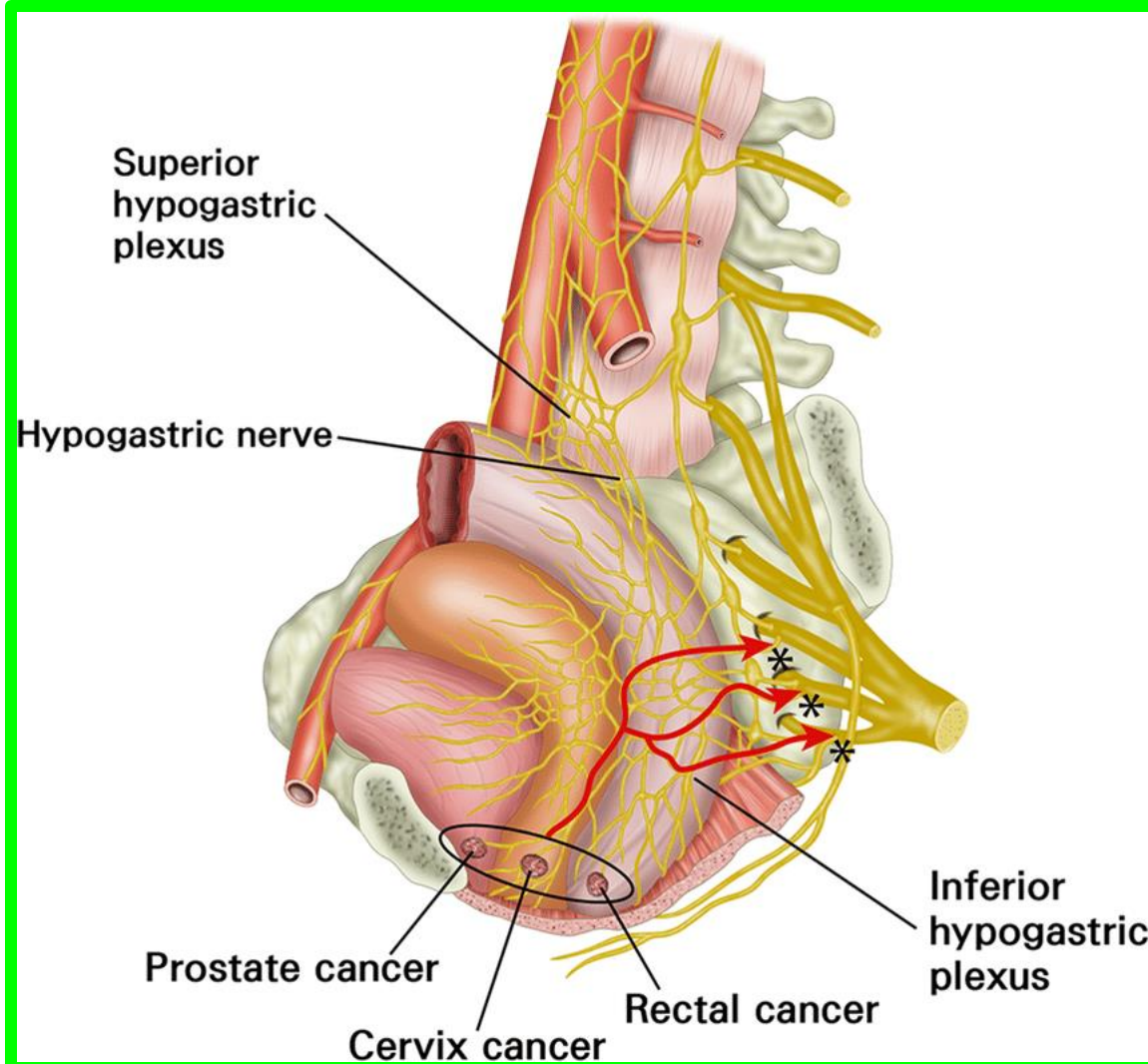
- ✓ It lies on the pelvic surface of the **coccygeus** and supplies this muscle, part of the **levator ani**, and the **sacrococcygeal joint**.
- ✓ **The anococcygeal nerves** arising from this plexus pierce the coccygeus and anococcygeal ligament to supply a **small area of skin between the tip of the coccyx and the anus**.



Autonomic nerves of pelvis

Dr. Aiman AL Maathidy
Sunday 3 May 2026

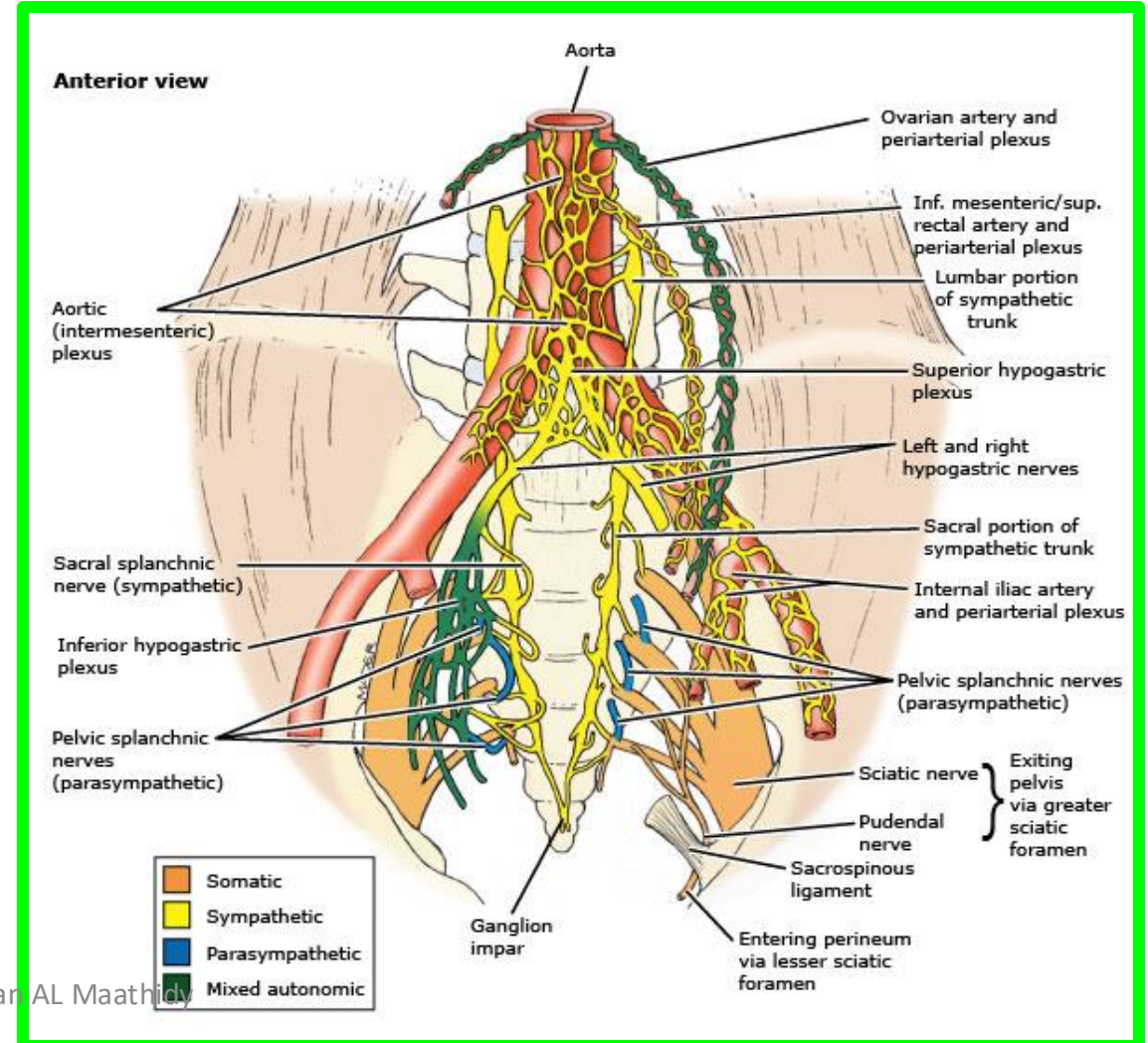
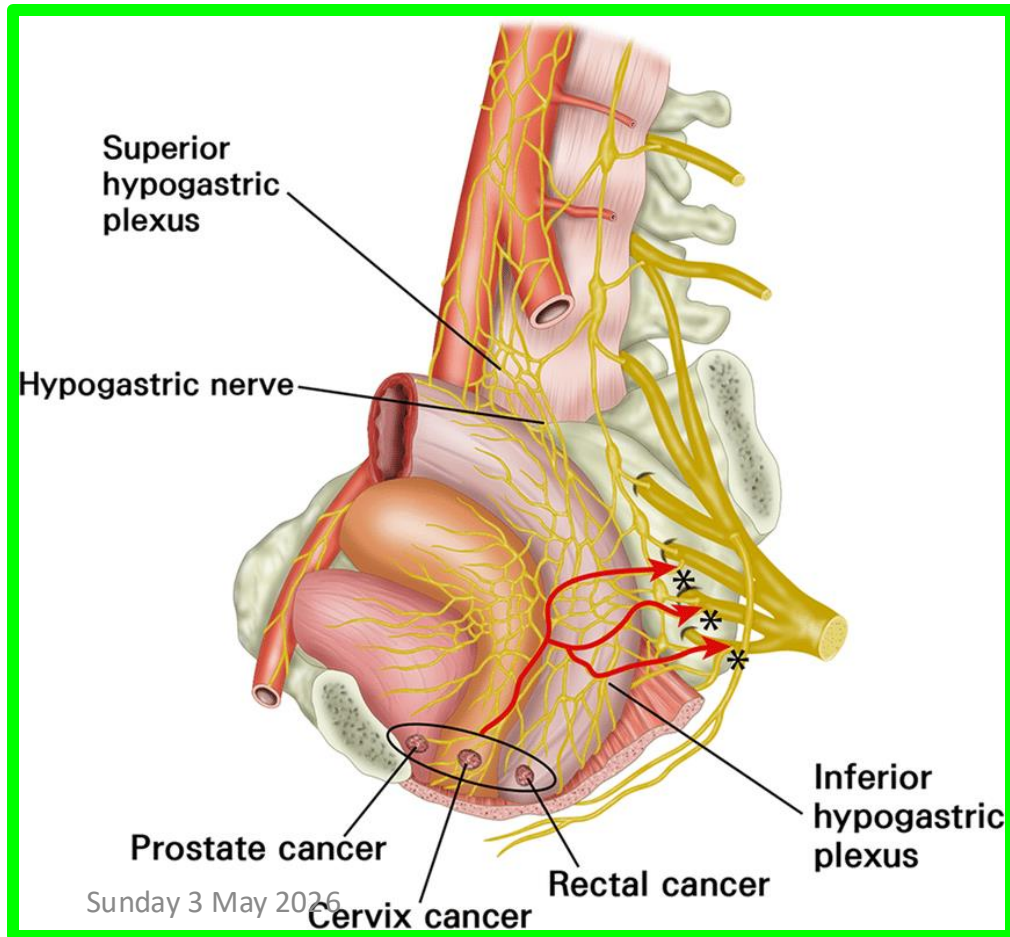
❖ The superior hypogastric plexus is a continuation of the aortic plexus that divides into left and right hypogastric nerves as it enters the pelvis.



Autonomic nerves of pelvis

Dr. Aiman AL Maathidy
Sunday 5 May 2024

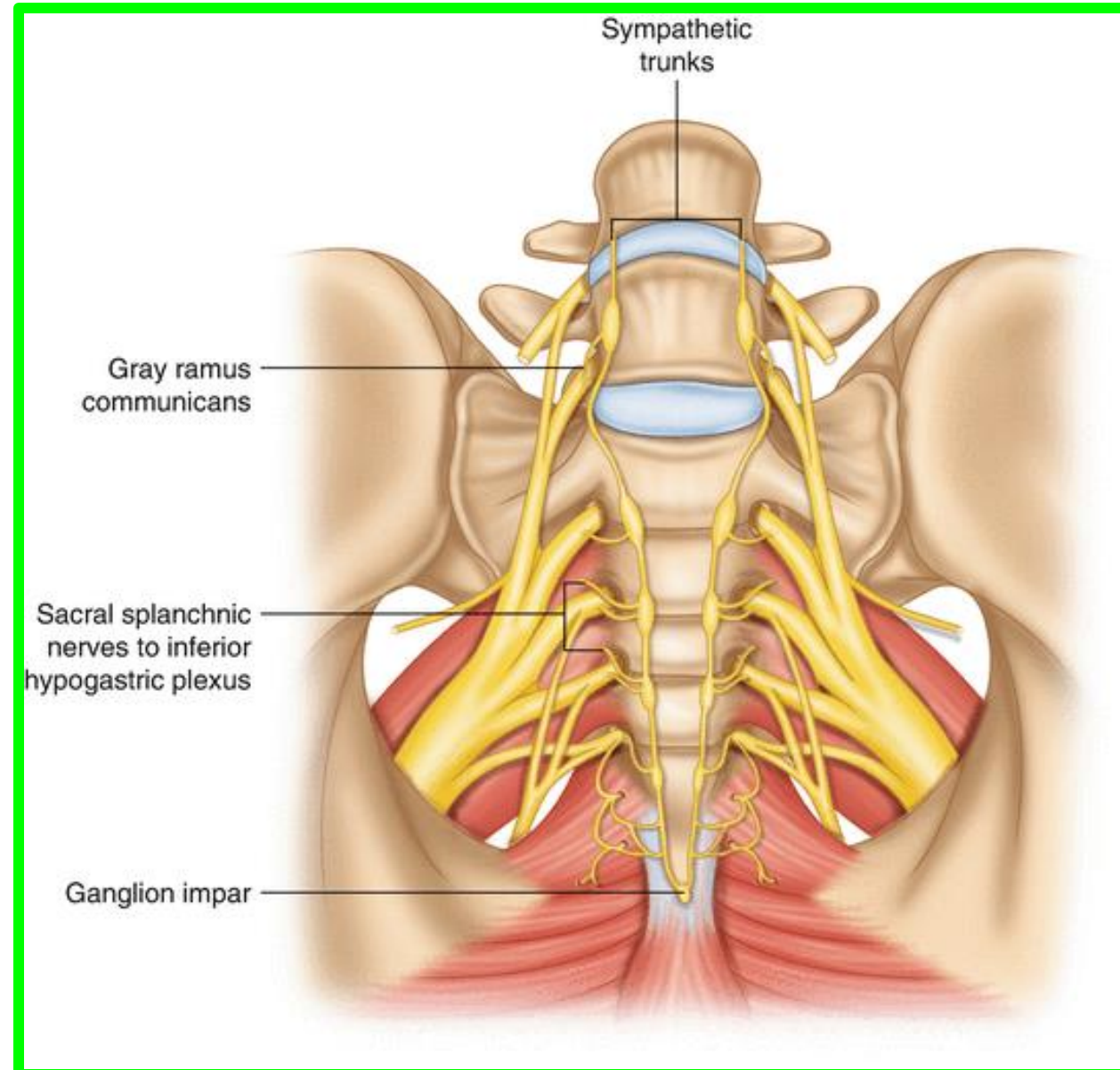
❖ The hypogastric and pelvic splanchnic nerves merge to form the **inferior hypogastric plexuses**, which thus consist of both sympathetic and parasympathetic fibers.



Dr. Aiman AL Maathidy

Pelvic Part of the Sympathetic Trunk

- ✓ It enters the pelvis by crossing the ala of the sacrum.
- ✓ The trunk descends on the pelvic surface of the sacrum behind the rectum.
- ✓ The two trunks join together in front of the coccyx to form **ganglion impar**.

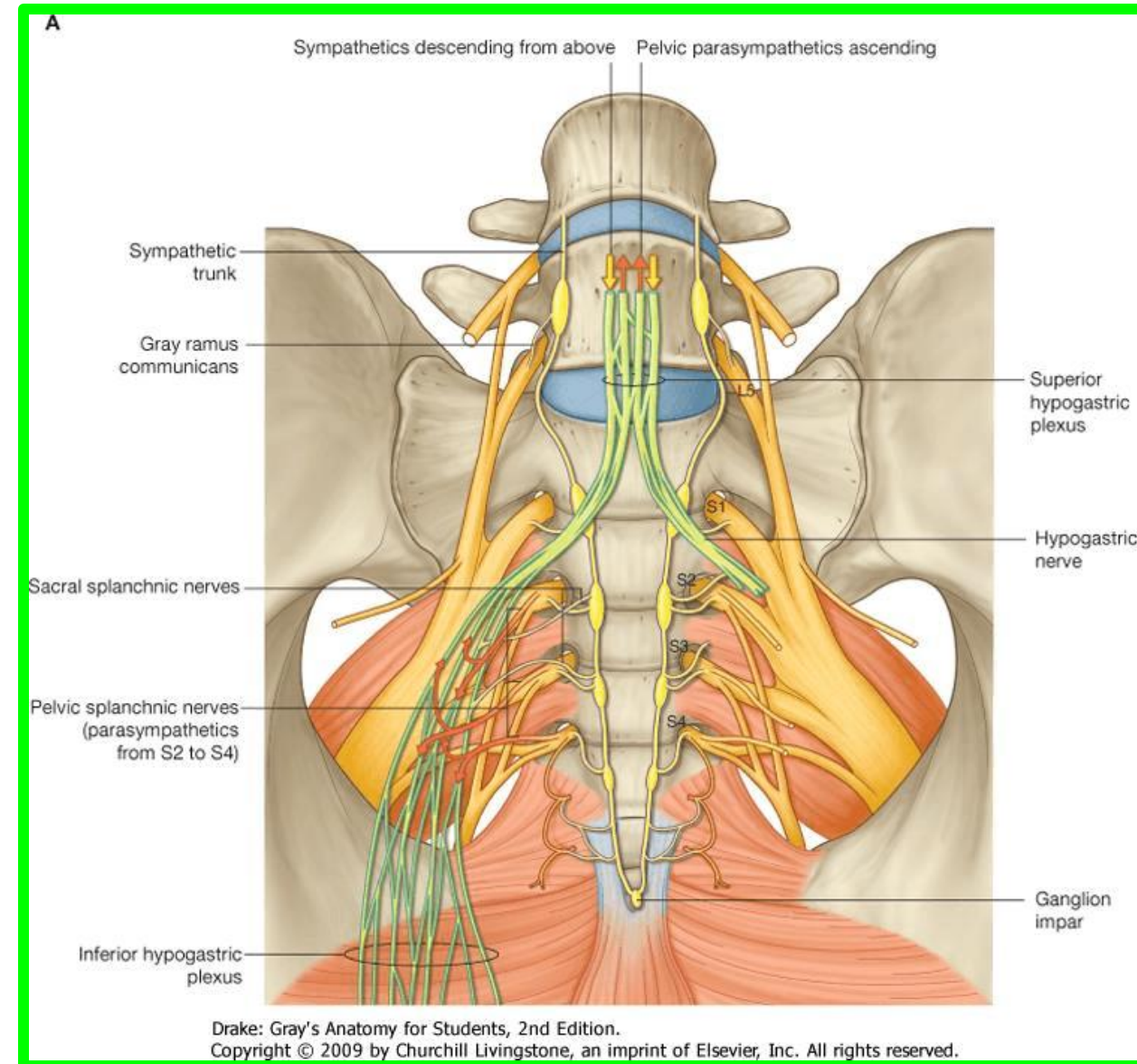


Pelvic Part of the Sympathetic Trunk

** Branches:

1. **Grey rami communicate** to the sacral and coccygeal nerves.
2. **Branches to the inferior hypogastric plexus.**

Dr. Aiman AL Maathidy
Sunday 3 May 2026



Dr. Aiman AL Maathidy

Sunday 3 May 2026

