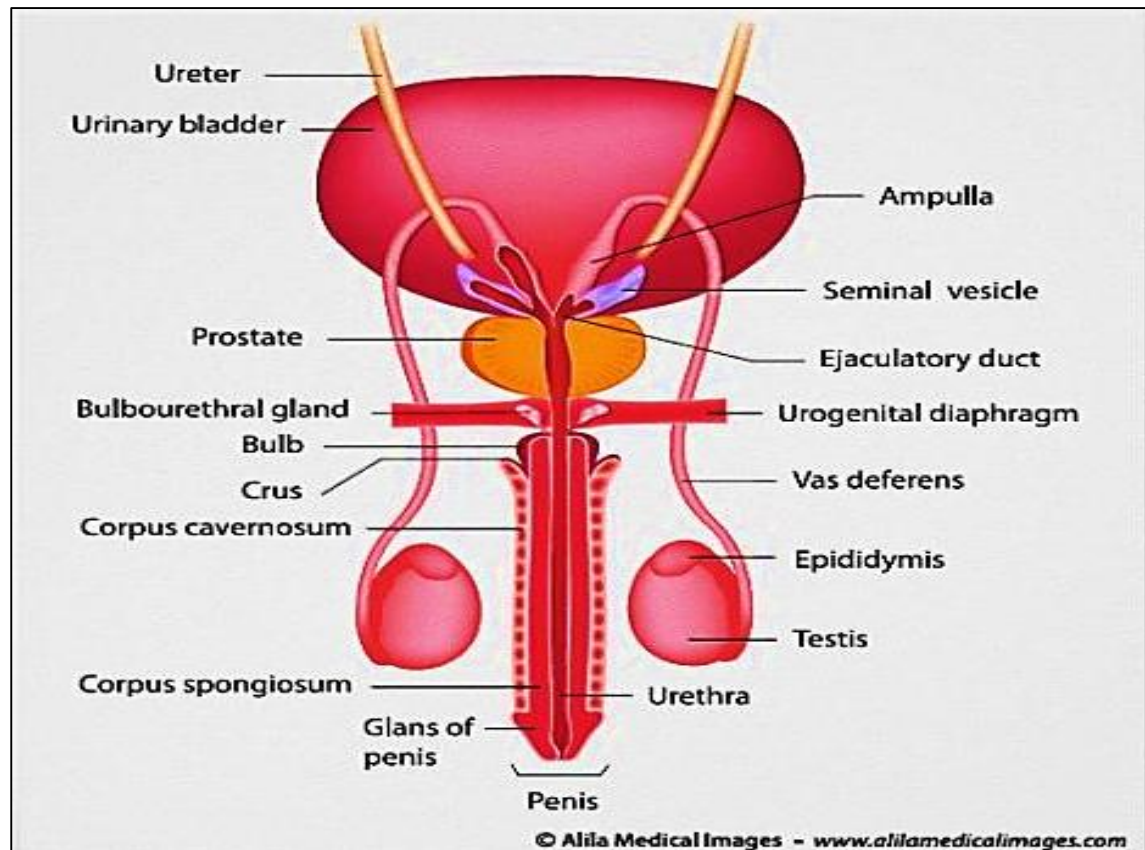


# Male Genital System

Professor Dr. Hala El-Mazar  
Medical Students / 3<sup>rd</sup> Year



# Male Genital system is formed of:

- **2 testes:**

Main glands; *formation of spermatozoa + synthesis & release of testosterone*

- **Genital ducts:**

*Collection, storage & transport of Spermatozoa*

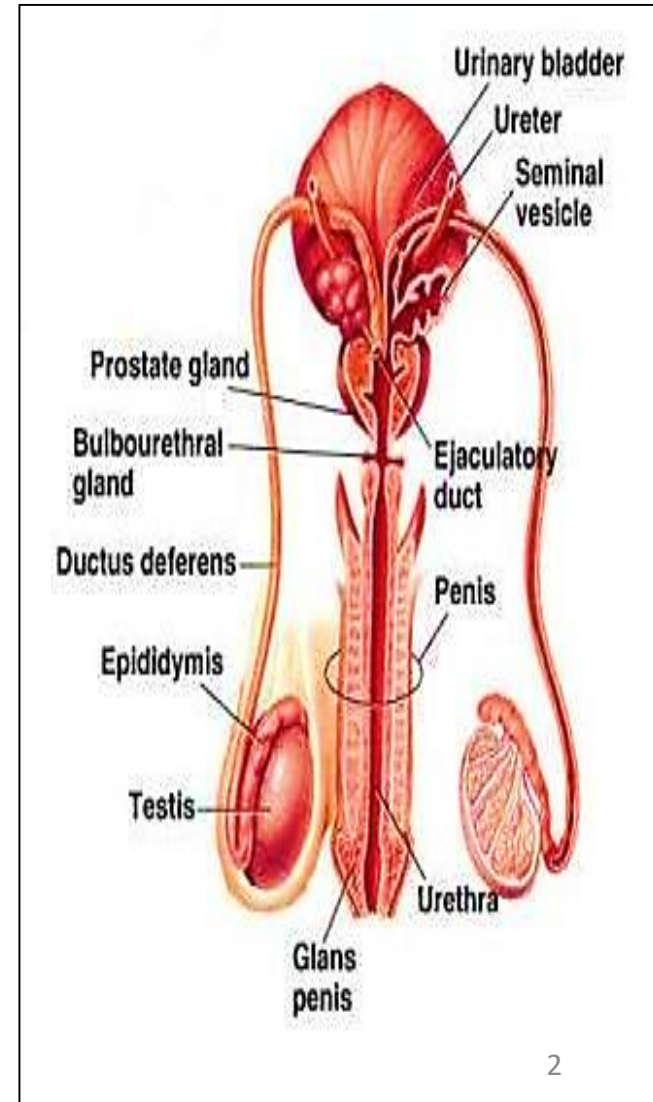
- **Accessory glands:**

- Two seminal vesicles
- One prostate gland
- Two bulbourethral (Cowper's) glands

*Formation of semen fluid*

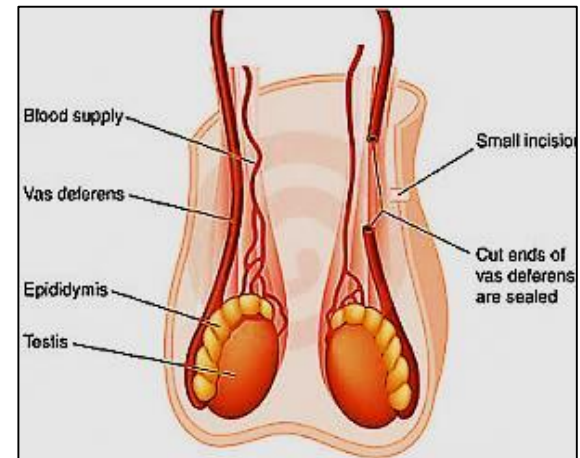
- **Penis:**

*delivery of the spermatozoa*



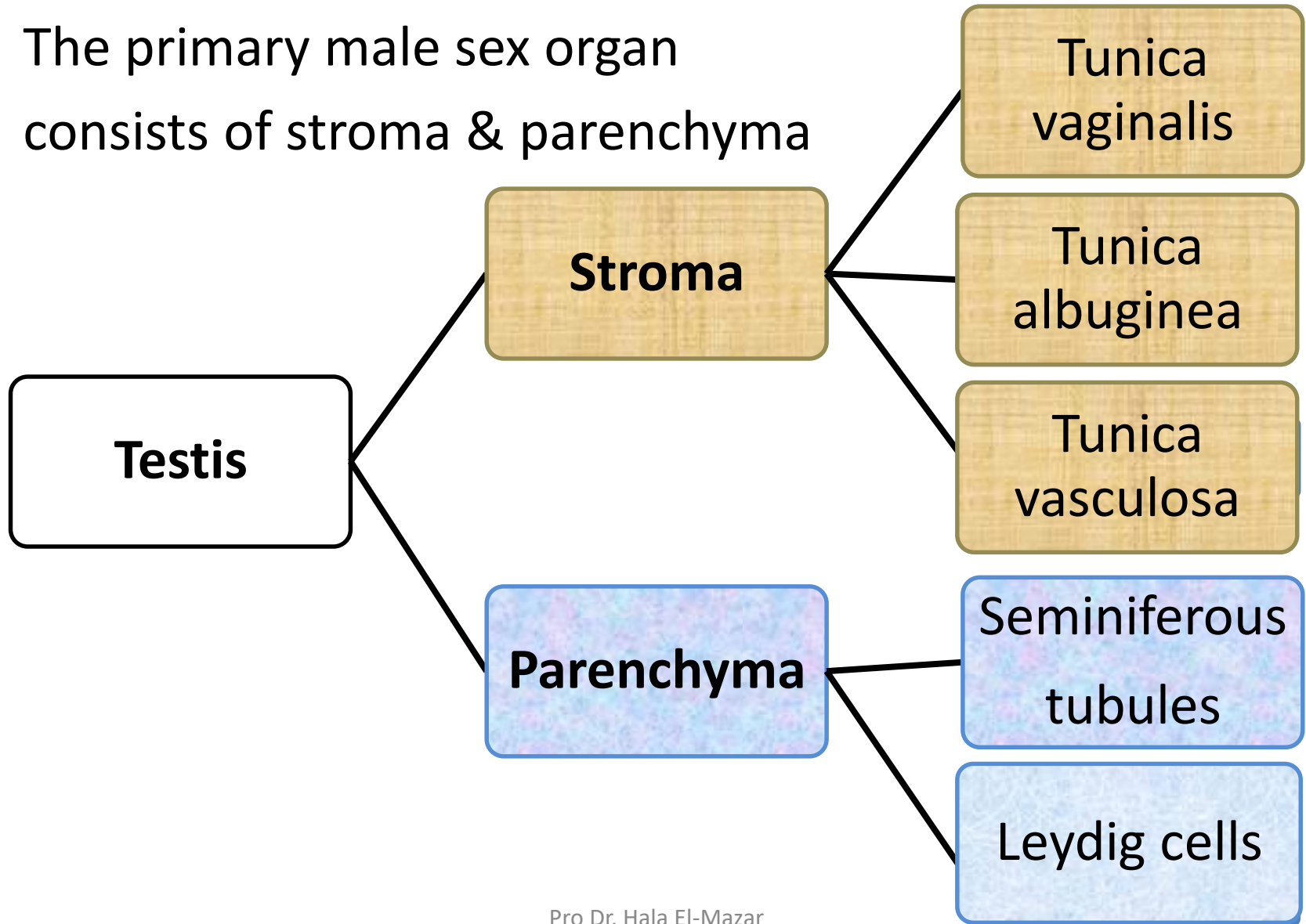
# The Scrotum

- Highly specialized **skin pouch** devoid of fat
- Maintain the testes **at 2-3 C below** body temperature (34-35C) which is **essential for spermatogenesis** ( normal development of sperms)
- It contains numerous sweat glands
- Its wall has random arranged smooth ms. fibers called **dartos muscle** . Plays a role in keeping the temperature of testis low



# The testis

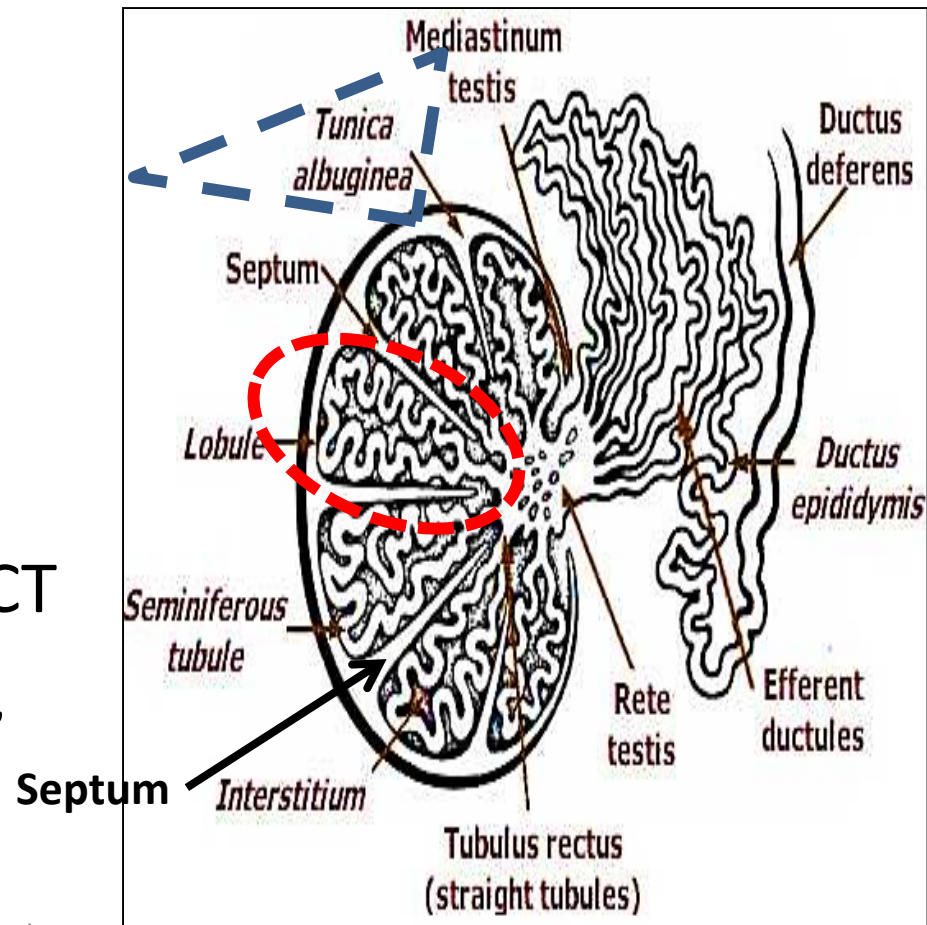
- The primary male sex organ
- consists of stroma & parenchyma



## Tunica albuginea:

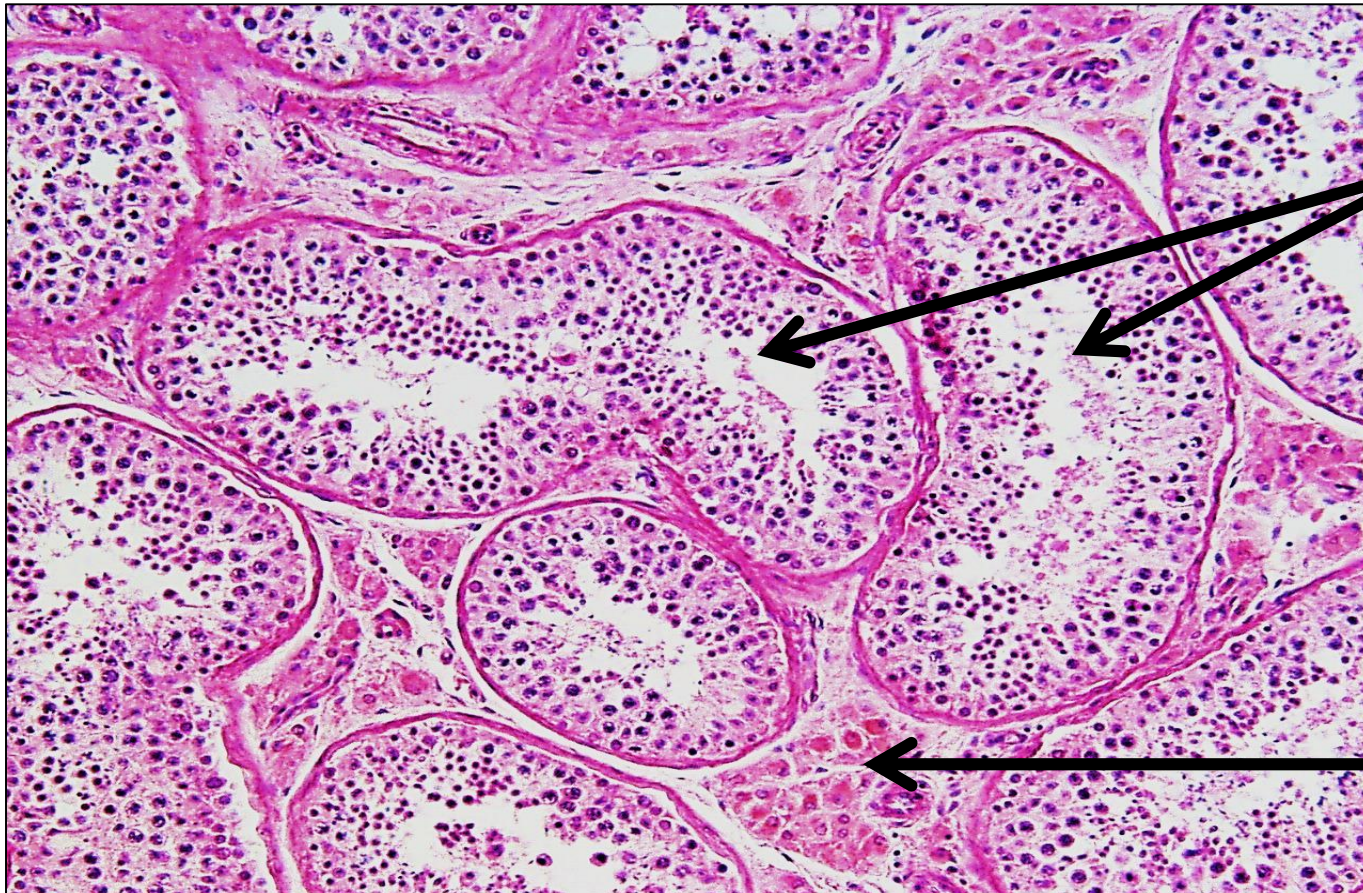- **Collagenous C.T. capsule** surrounds each testis , from which septa arise and divides the testis into testicular **lobules** ( about **250** testicular lobules)
- Each lobule contains:
  - **Seminiferous tubules (1-4)**
  - **interstitial cells of Leydig**

Both are embedded in loose CT rich in BV, lymphatics, nerves,



# Parenchyma

- A. Seminiferous tubules ( exocrine part ) → spermatozoa
- B. Interstitial cells of Leydig ( endocrine part ) → testosterone

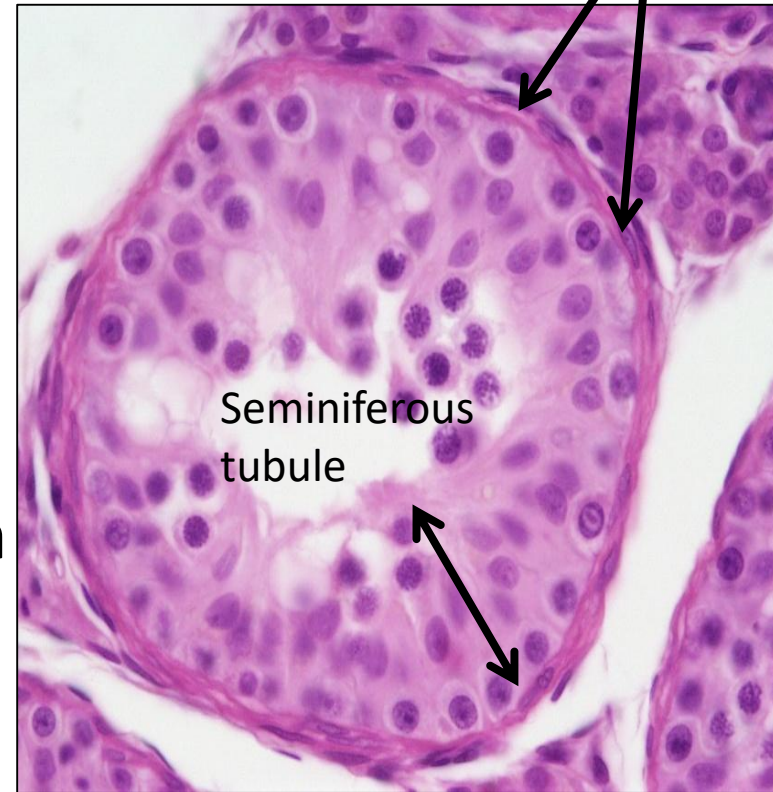


Seminiferous tubules

Interstitial cells of Leydig

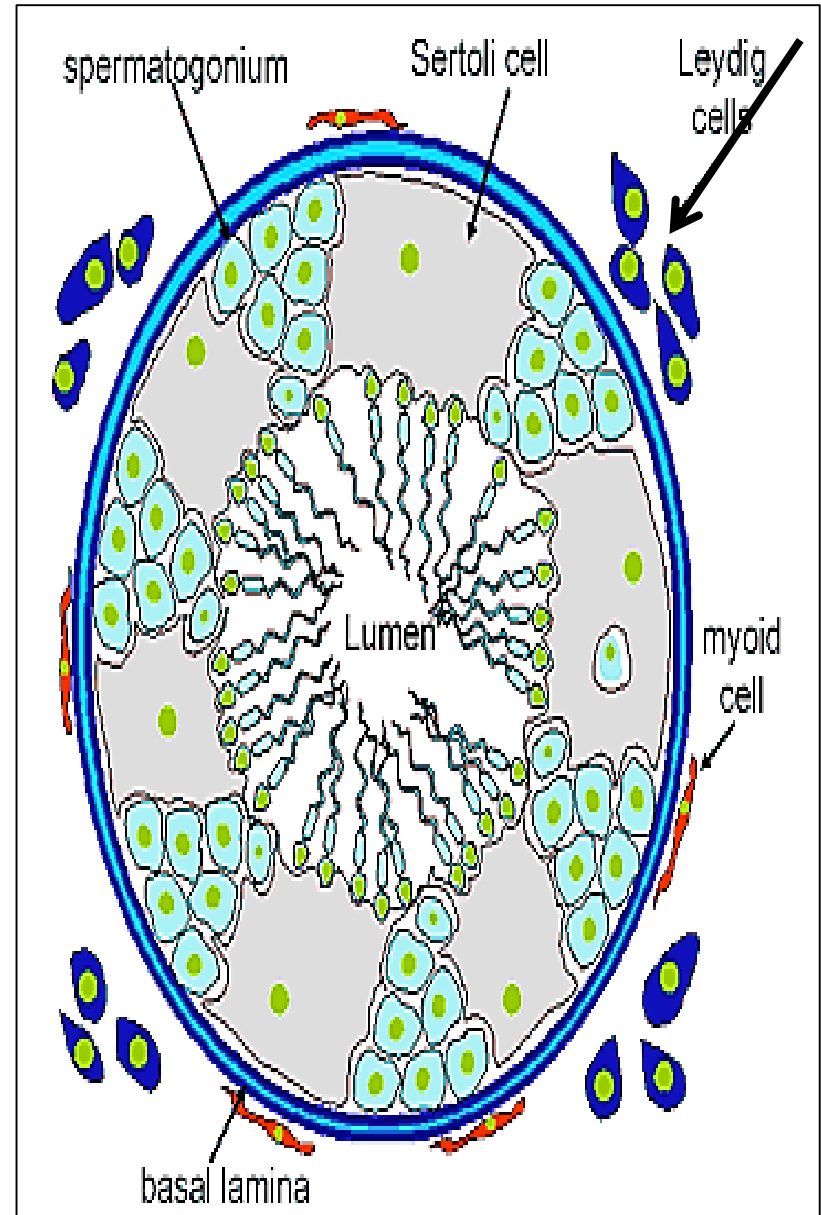
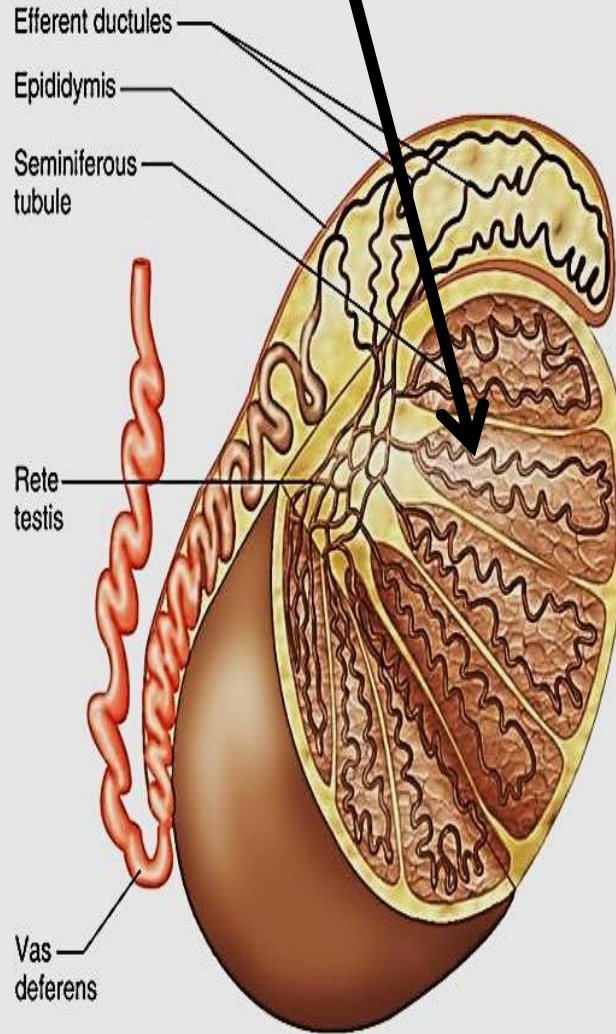
# Seminiferous tubules

- Site of production of spermatozoa
- Each testis has 250- 1000 ST
- Under control of **FSH**
- Highly convoluted e narrow lumen



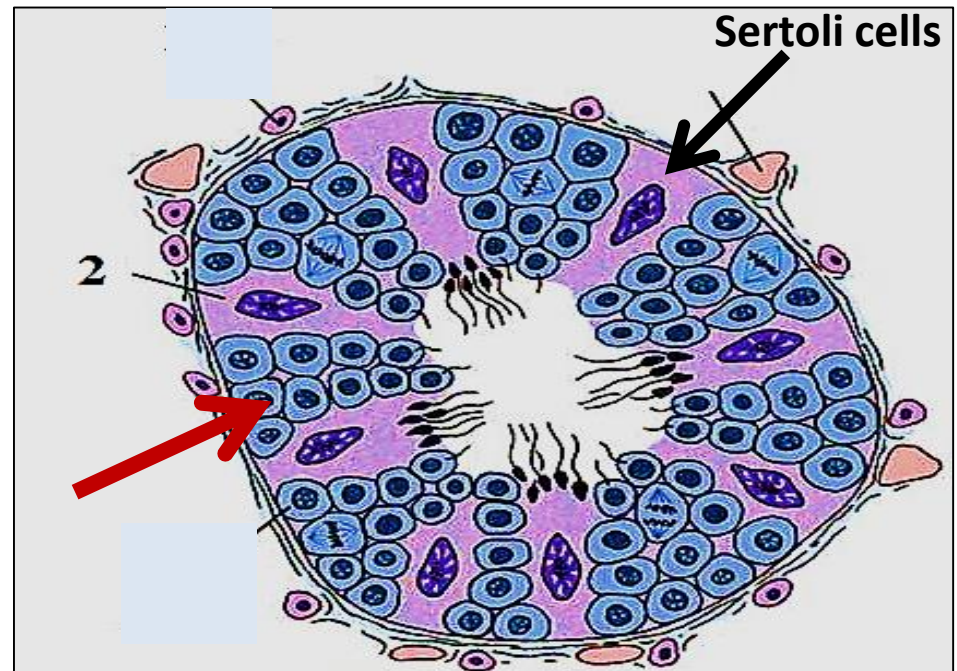
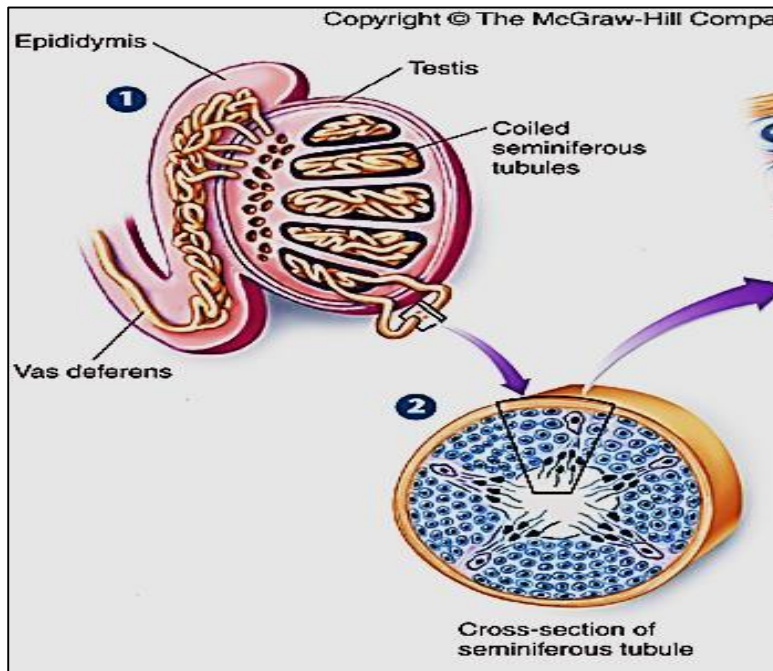
- **lined e stratified epithelium called spermatogenic epith.**
- The epith. rests on a clear basement membrane which surrounded with a layer of contractile **myoid cells**

# Testis & seminiferous tubules



# Spermatogenic epithelium

- The spermatogenic epithelium consists of 2 types of cells:
  - Spermatogenic cells
  - Sertoli cells
- The spermatogenic cells are arranged in 4- 8 layers



# spermatogenesis

At puberty, spermatogonia → spermatozoa

Divided into 3 phases:

**1- Spermatocytogenesis:** spermatogonia divide repeatedly by mitosis → 1ry spermatocyte

**2- Meiosis:** the 1ry spermatocyte → reduction division → spermatids

**3- Spermiogenesis:** spermatids undergo morphological changes → spermatozoa

# spermatocytogenesis

**Spermatogonia** → mitosis → 2 cells

1- spermatogonia *type A*

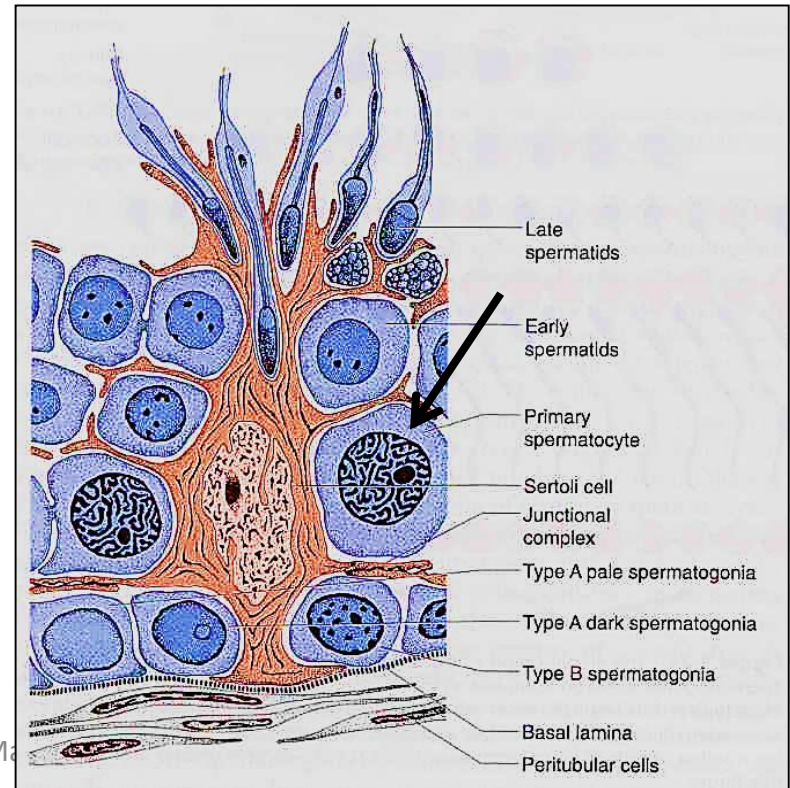
2- spermatogonia *type B*

remain as stem cells for further spermatogenesis

→ change to → 1ry spermatocyte

## **Primary spermatocytes**

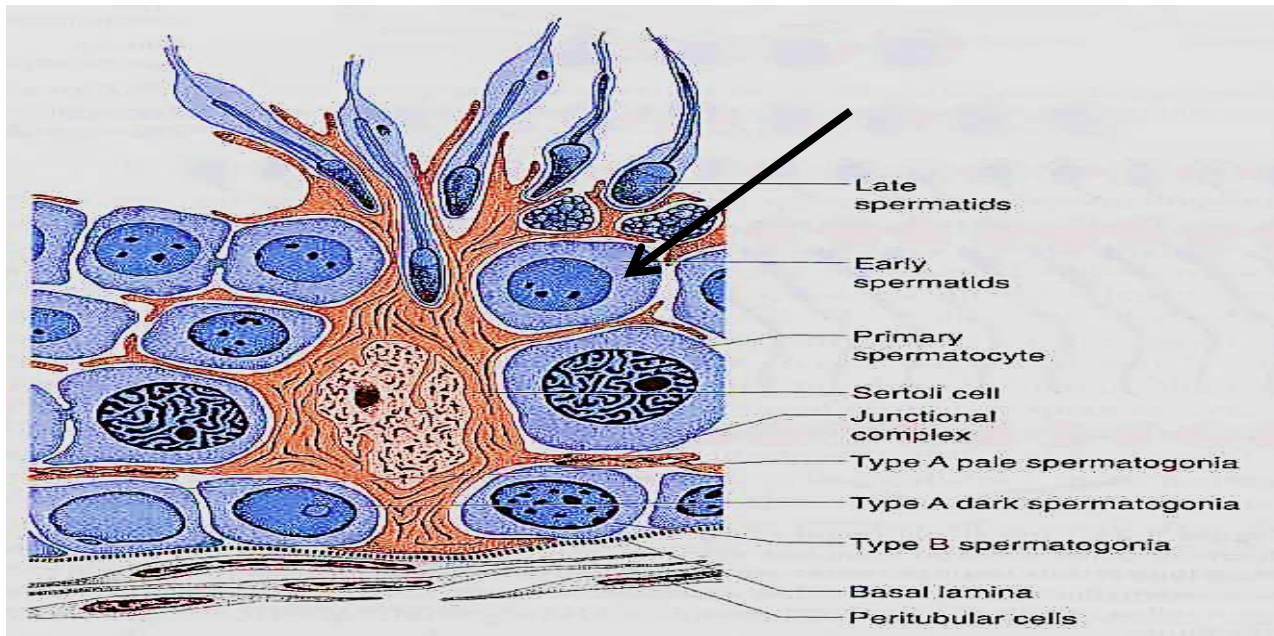
- largest cells of the Spermatogenic epithelium
- Contains 46 chromosomes (diploid # = 4cDNA)
- enter 1<sup>st</sup> meiotic division to give rise to 2ry spermatocytes



# meiosis

## 2ry spermatocytes:

- 2ry spermatocyte (haploid = 2cDNA)
- Short lived cells, quickly enter 2<sup>nd</sup> meiotic division → spermatids 1cDNA (23 ch.)

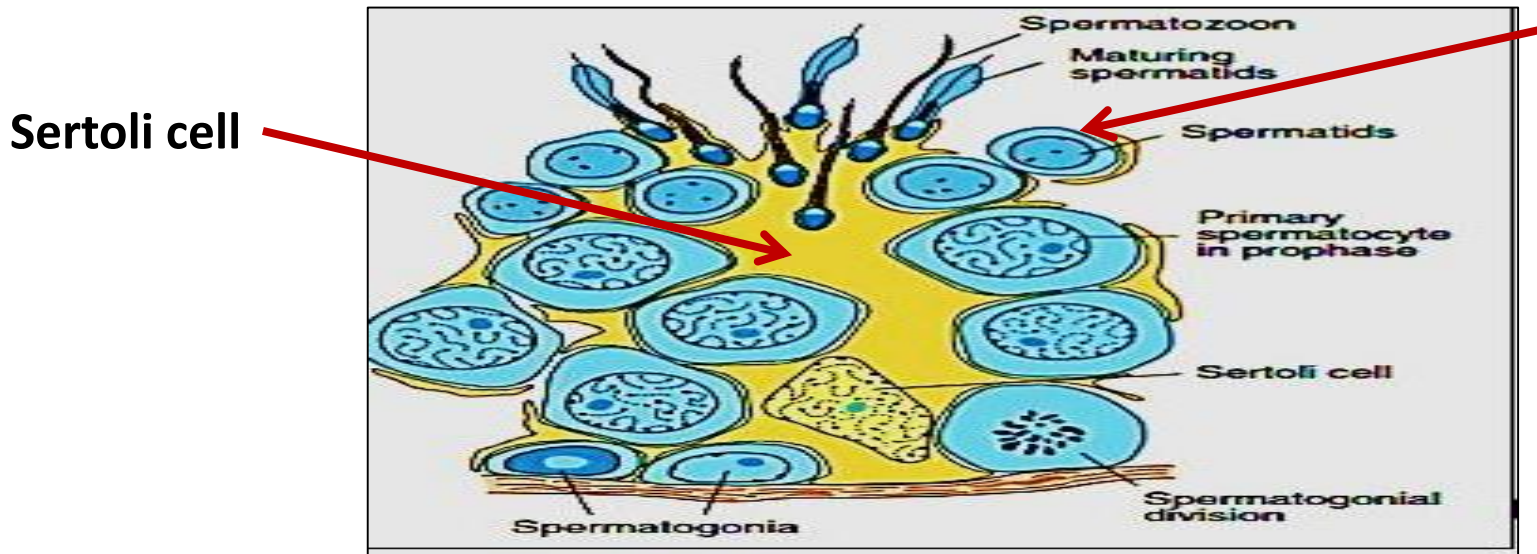


# Spermiogenesis

Is **Metamorphosis** process → transformation of  
**spermatids → spermatozoa (sperms)**

## Spermatids:

- Very small cells e central rounded dark nucleus
- Located near lumen of ST in intimate relation e Sertoli cells
- by their formation **no further cell division occurs**

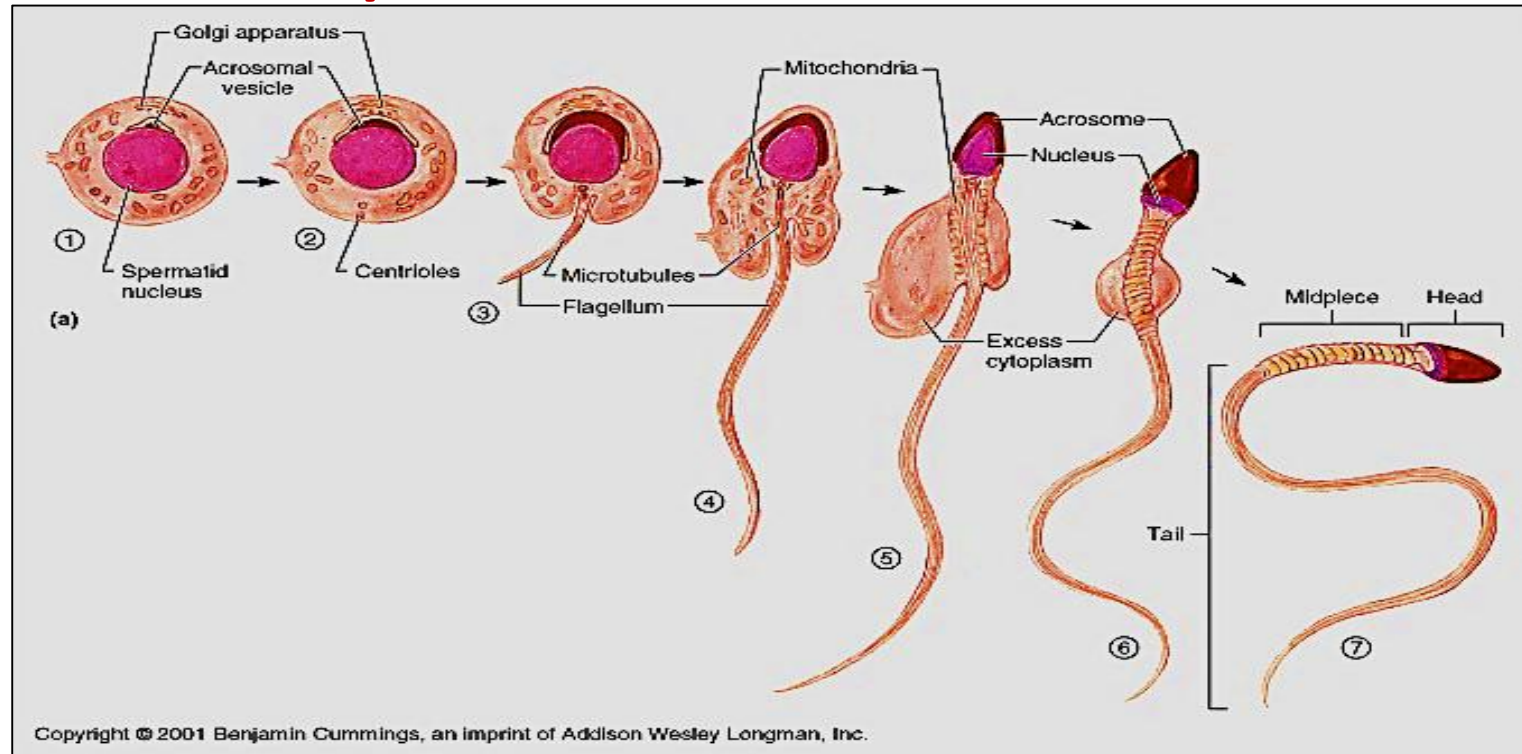


# Spermiogenesis includes 3 stages:

1) *Golgi phase*

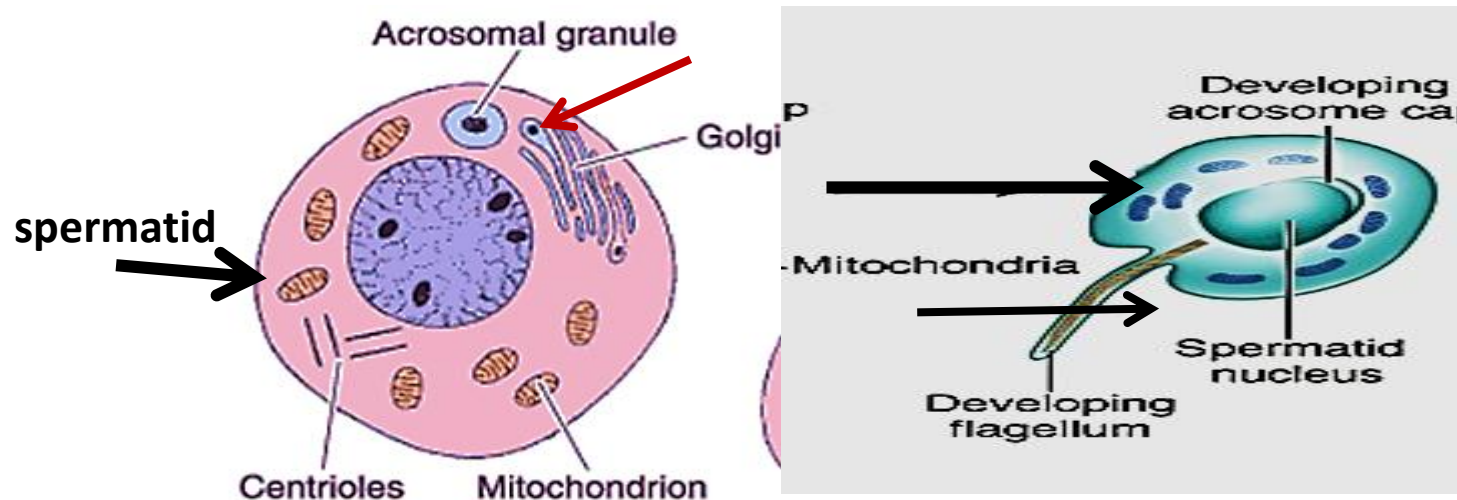
2) *Acrosomal phase*

3) *Maturation phase*



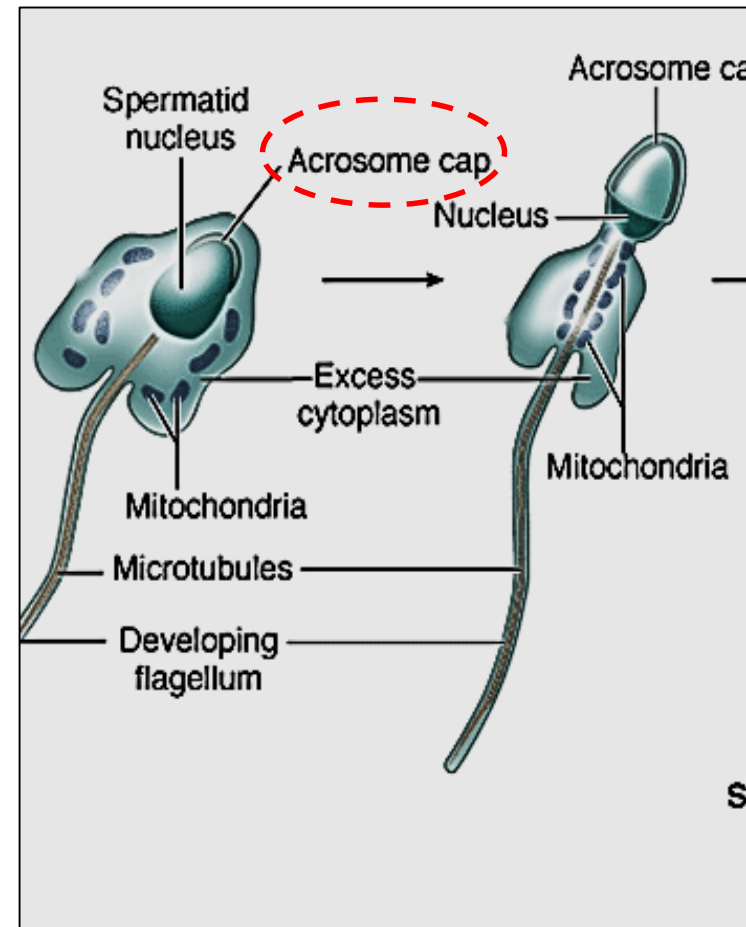
## Golgi phase

- rER form hydrolytic enzymes → packaged in Golgi apparatus to be released as small **pro-acrosomal granules**
- The granules fuse together → **single acrosomal vesicle** → at one pole of the nucleus
- At the same time 2 centrioles migrate to the opposite pole to form the developing flagellum



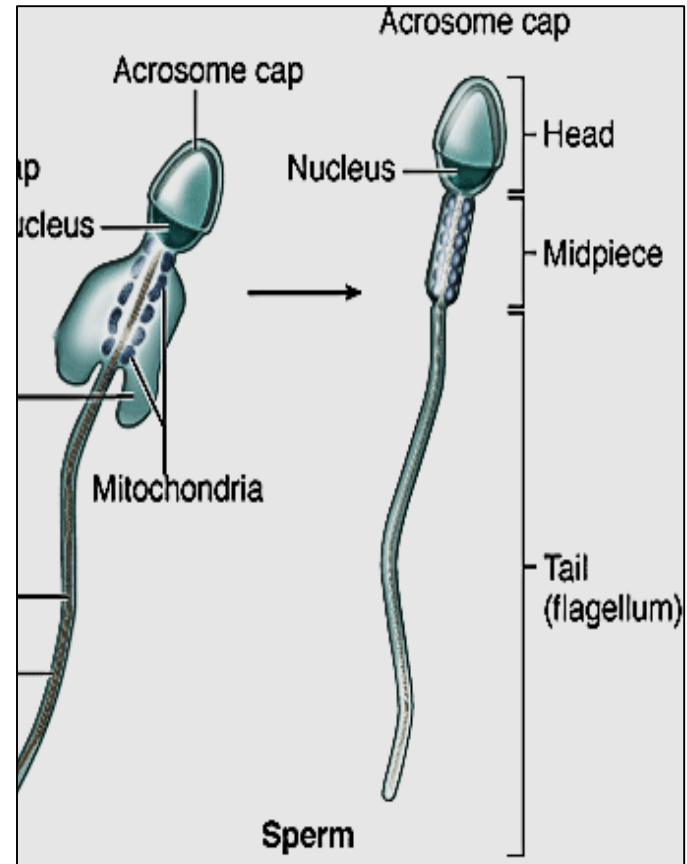
## Acrosomal phase:

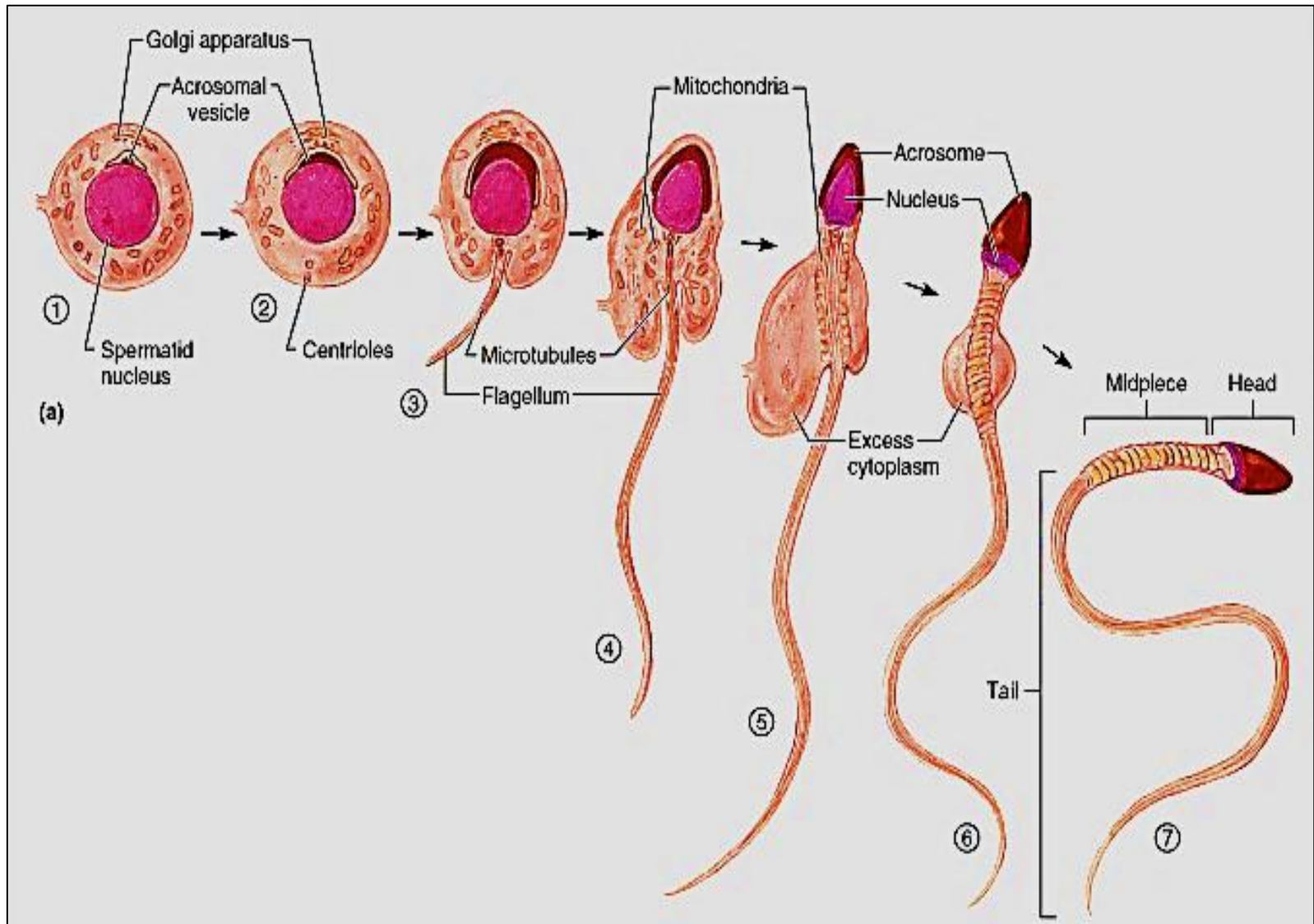
- The nucleus become elongated & condensed
- The acrosomal vesicle spread & cover the ant ½ of nucleus → **acrosomal cap**
- One of the centrioles → grows to form **flagellum**
- Mitochondria collect below the neck around the flagellum → form **middle piece**



## Maturation phase:

- The acrosome cap covers the ant. 2/3 of the nucleus & called **acrosome** and contains **hydrolytic enzymes**
- Excess cytoplasm is shed off → **residual bodies**
- The newly formed spermatozoa are released tail 1<sup>st</sup> into the lumen of ST
- Spermatozoa remain immotile until they leave the epididymis
- Capacitation occur in female reproductive tract





# Spermatozoa (sperm)

head , Middle piece & tail

## The head:

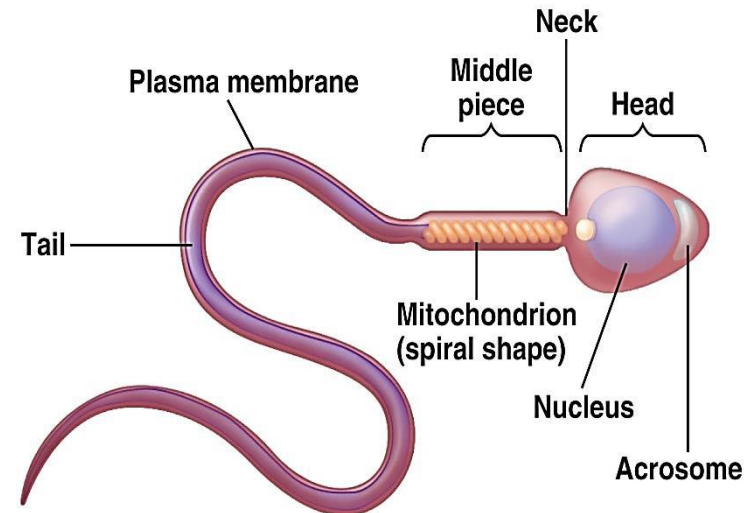
- Flat & elongated formed mainly of the **nucleus + acrosome** ( contains hydrolytic enzymes → facilitate penetration of oocyte)

## Middle piece:

- Formed of **flagellum + mitochondrial sheath**
- Is responsible for sperm motility

## The tail:

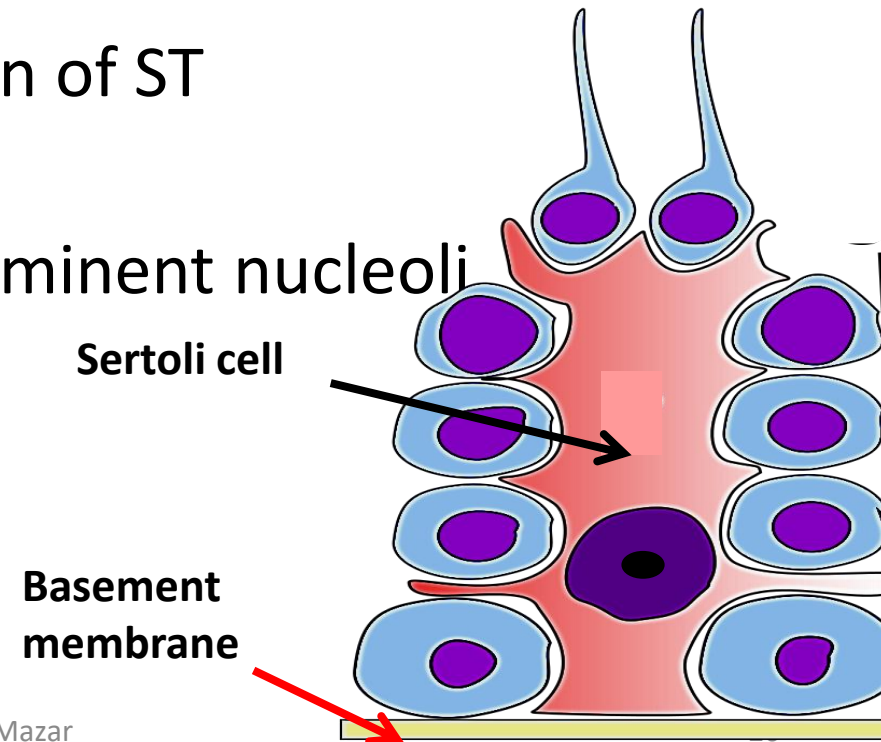
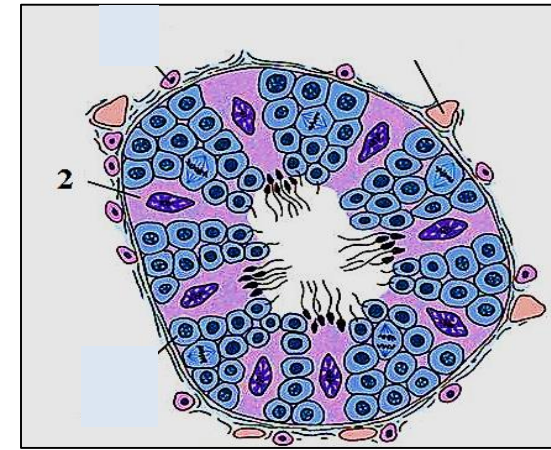
Formed of **flagellum + supporting fibers**



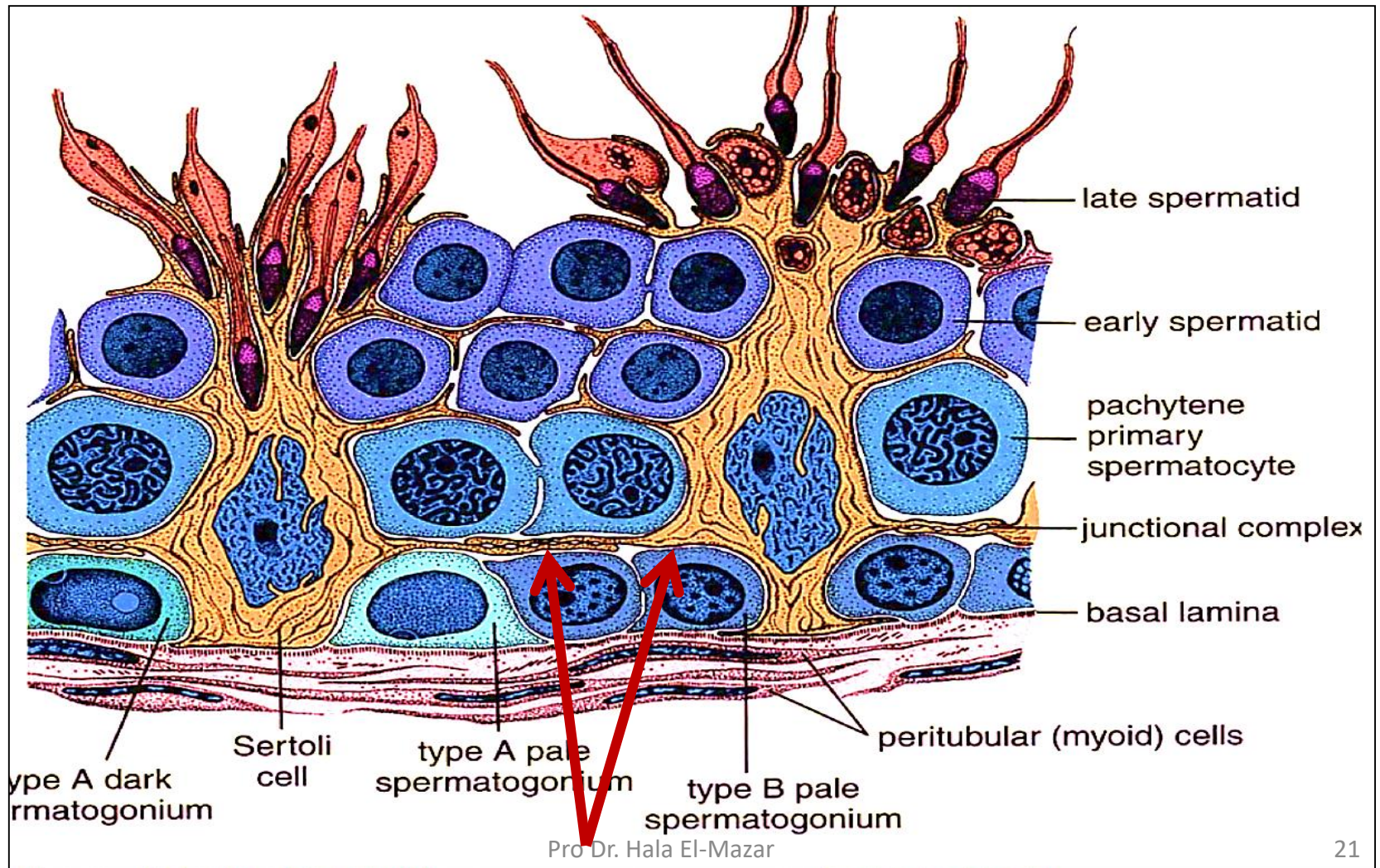
# Sertoli cells

## L/M:

- Tall pyramidal cells extend between the spermatogenic epith
- Their bases adhere to basement membrane
- Their apices extend into lumen of ST
- Have elongated nucleus + prominent nucleoli
- Have **ill defined** cell borders
- Cytoplasm pale acidophilic

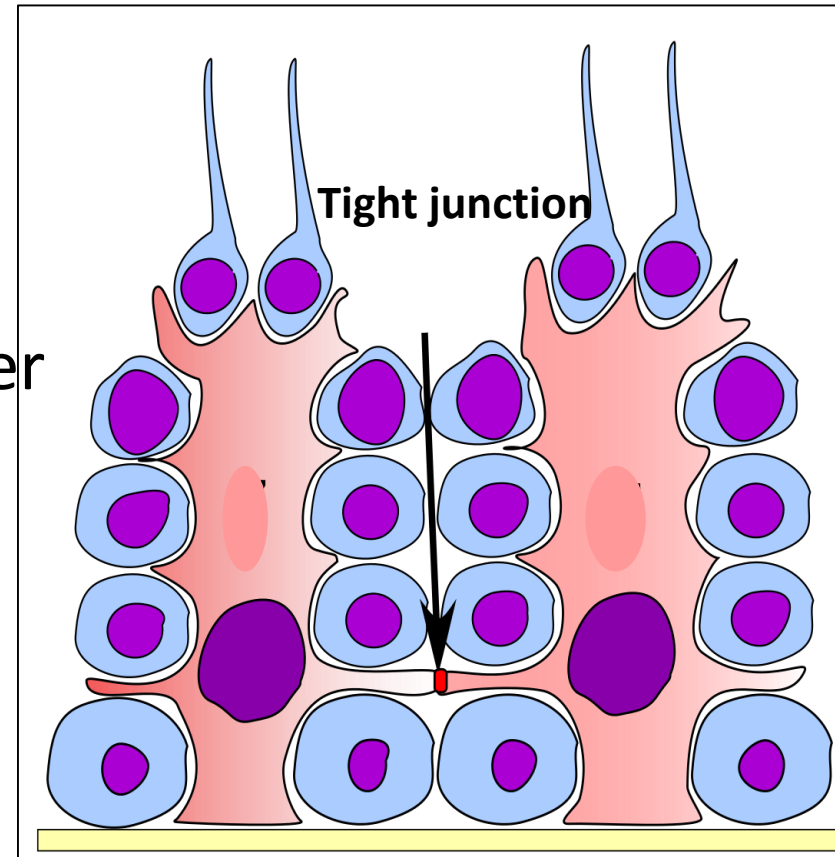


- **cytoplasmic extensions** from the basal part of Sertoli cells are bound together by tight junctions → form blood- testis barrier



## Function of Sertoli cells:

- Support , nourish, protect the developing spermatozoa
- Phagocytic function
- Formation of blood- testis barrier
- Secretion of fluid which is used for sperm transport

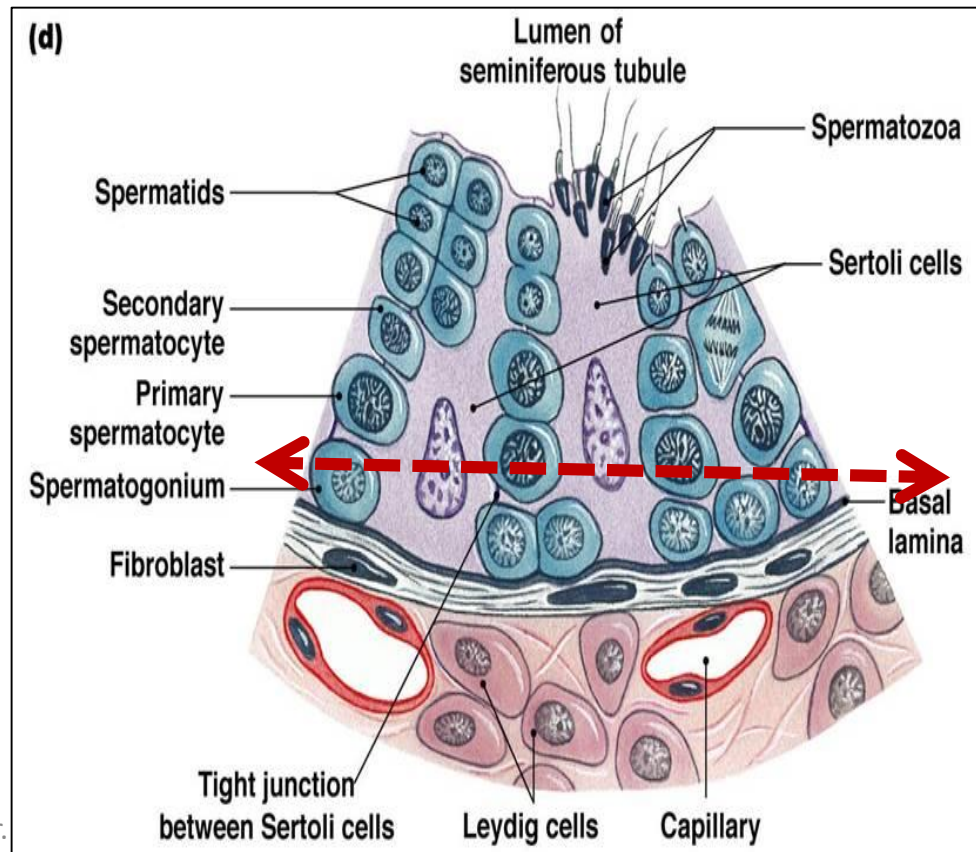


- Secretion of **androgen-binding protein**:  
(ABP combines e testosterone & concentrate it inside ST,  
(testosterone is necessary for spermatogenesis)
  
- Secrete **Inhibin** hormone: inhibit FSH → feedback control  
**the rate** of spermatogenesis
  
- **FSH act on Sertoli cells to secrete ABP**
- **LH stimulates interstitial cells of Leydig to produce testosterone**

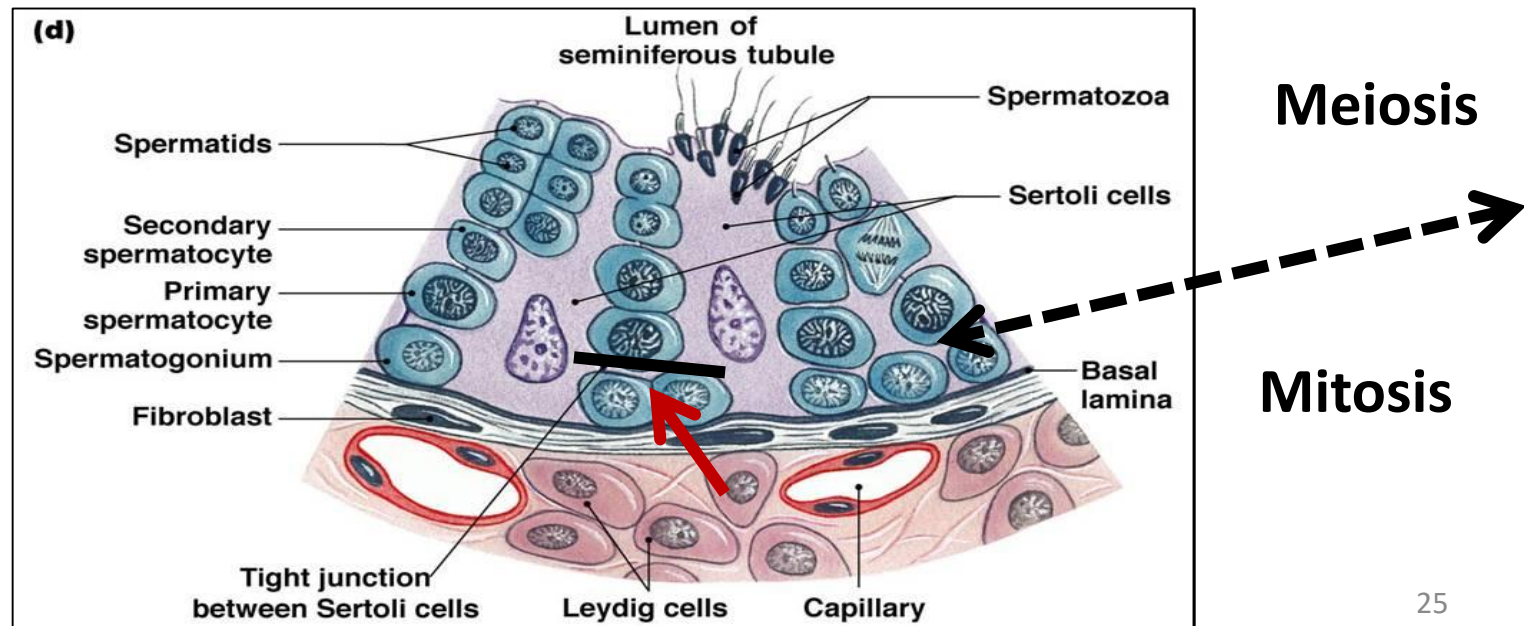
# Blood – testis barrier

- Is formed by the tight junction between **Sertoli cells**
- It divides the ST into **basal & adluminal** parts.

*Since the sperms are formed only after puberty, they are recognized as foreign cells to the immune system → barrier prevent autoimmune reaction*

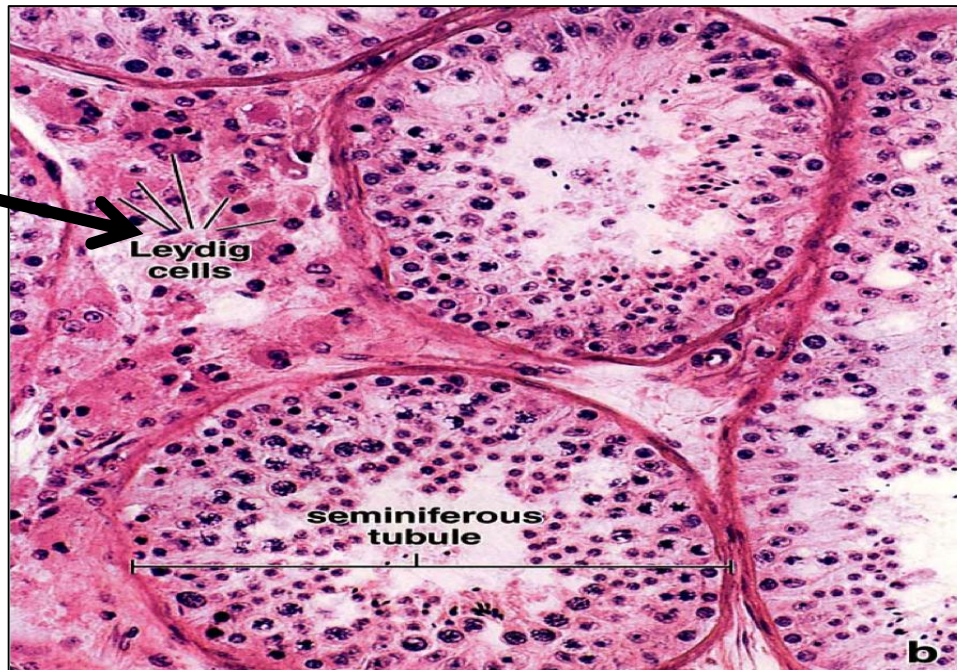


- in **the basal part** ( below the barrier) lie the **Spermatogonia** → so tissue fluid can directly reach them through penetration of basement membrane
- in **the adluminal part** ( above the barrier) lie **1ry & 2ry spermatocytes, spermatids & spermatozoa** → the passage of tissue fluid is controlled by BT barrier



# Interstitial cells of leydig

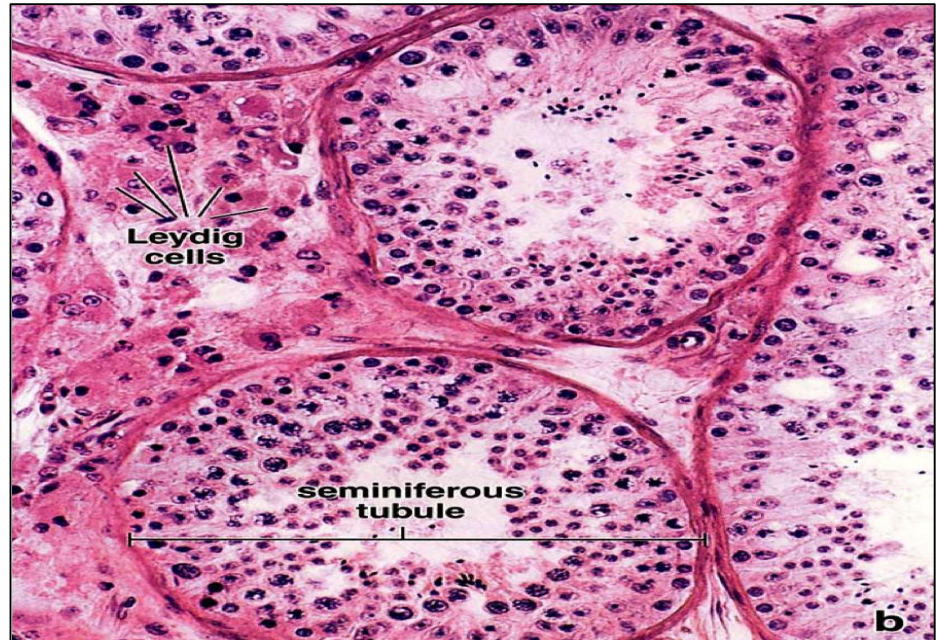
- Cluster of cells present in the spaces between seminiferous tubules
- The endocrine part of the testis
- Surrounded with fenestrated capillaries
- Secrete the male hormone **testosterone** under control of LH



# Interstitial cells of Leydig

## L/M:

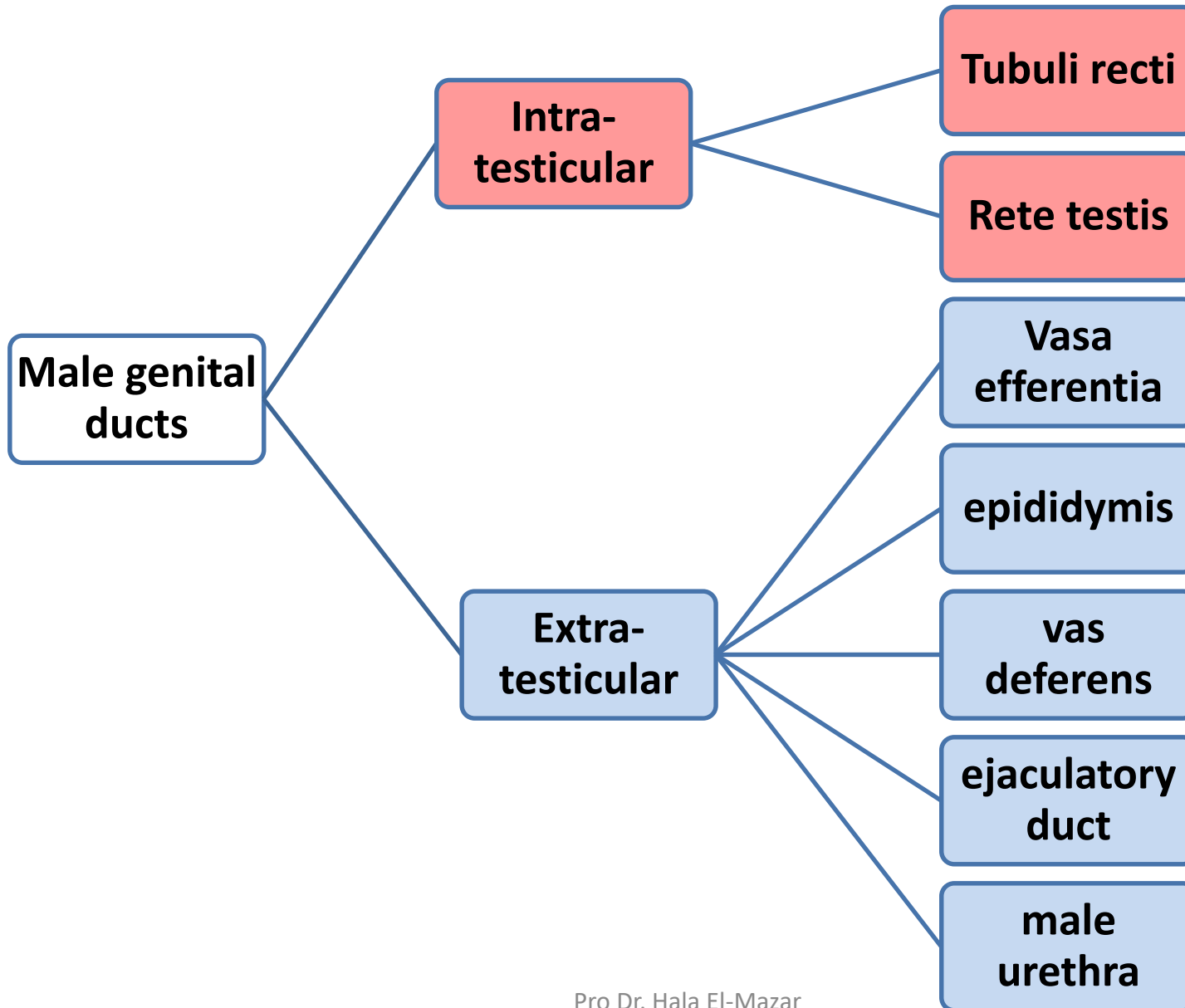
- Rounded cells e acidophilic cytoplasm rich in lipid droplets
- Central round nuclei



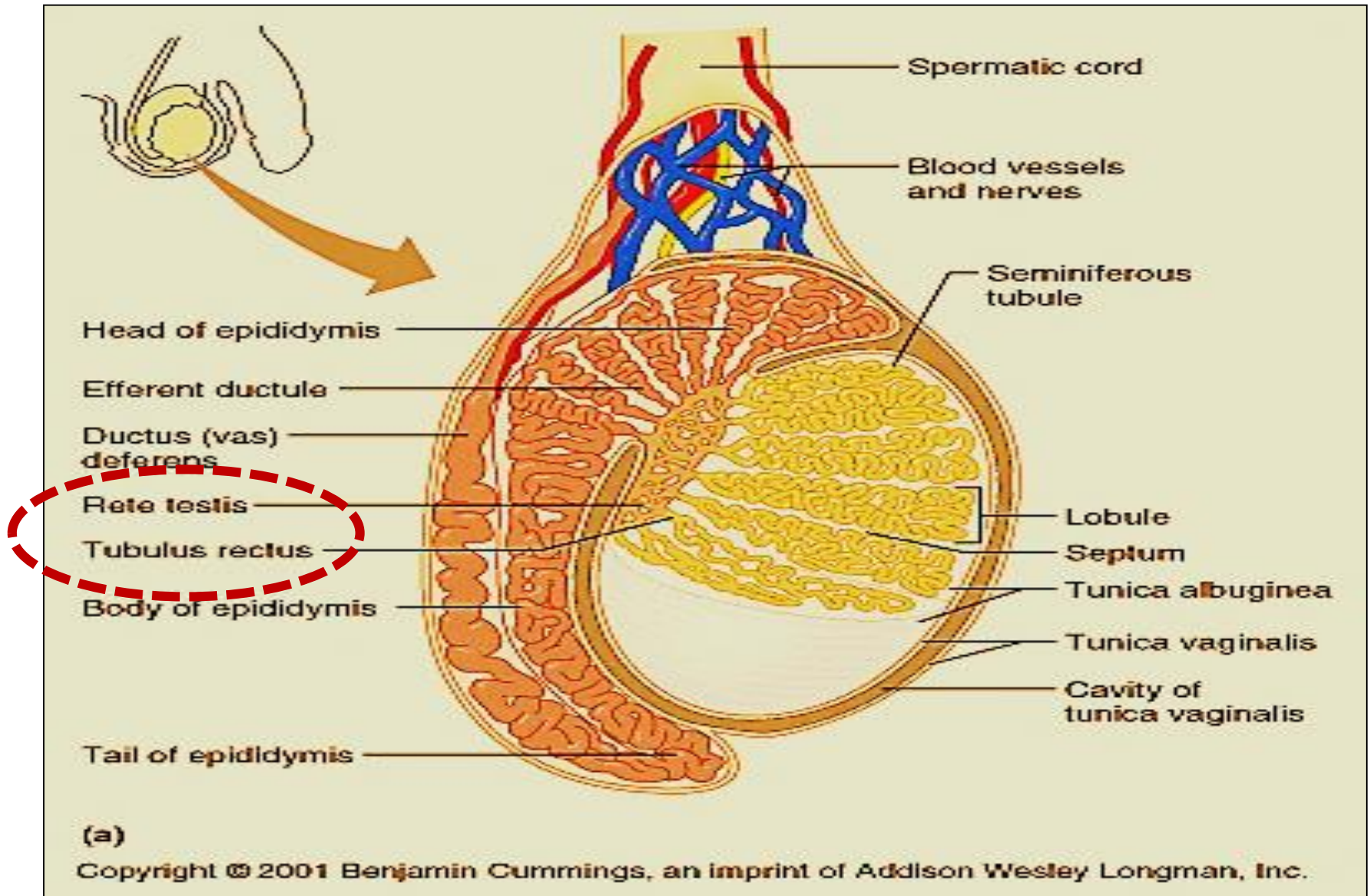
## E/M:

- Have the characteristics of **steroid secreting cells**
- ↑sER, mitochondria, lipid droplets

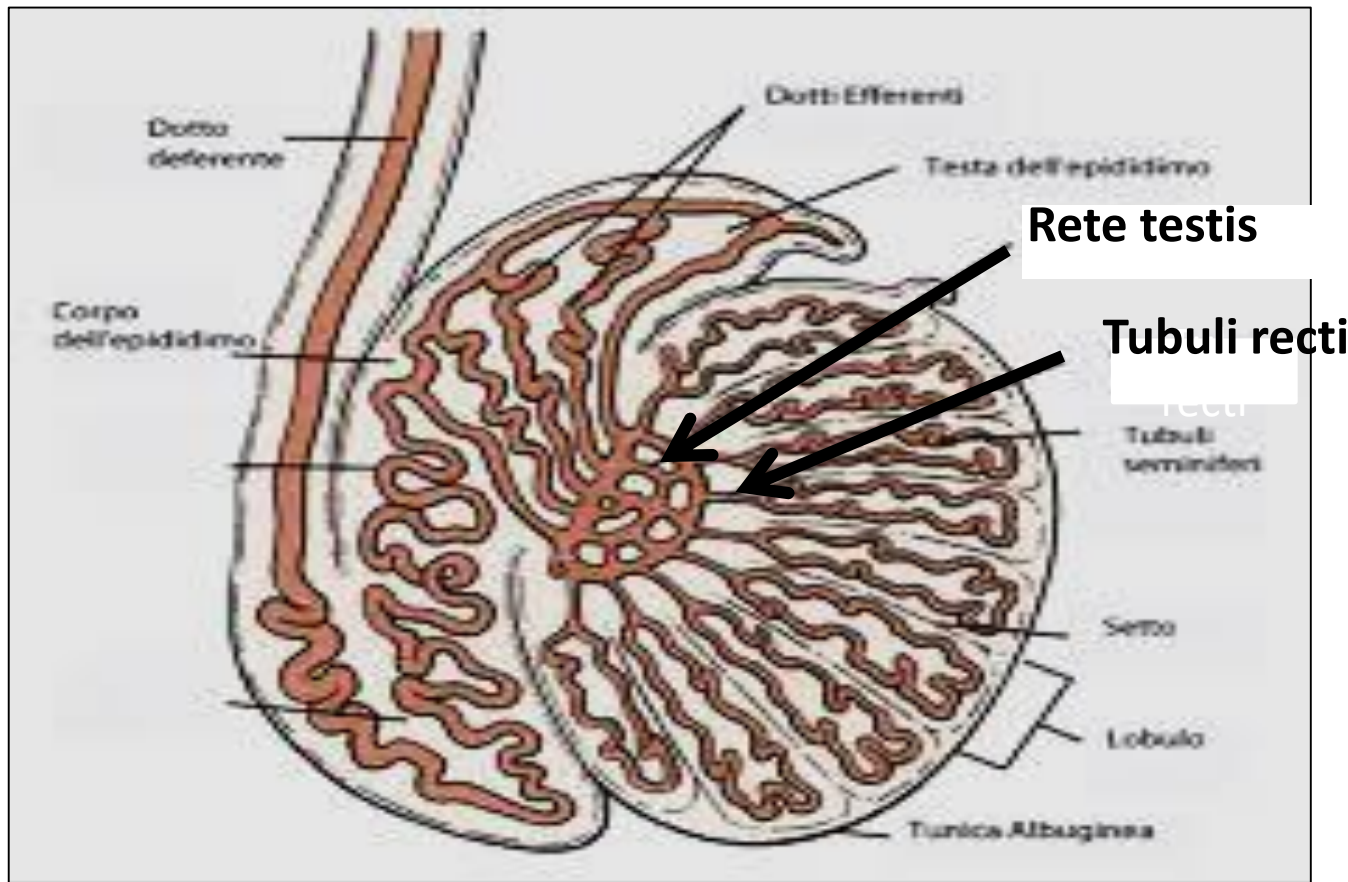
# Male genital ducts



# Male genital ducts

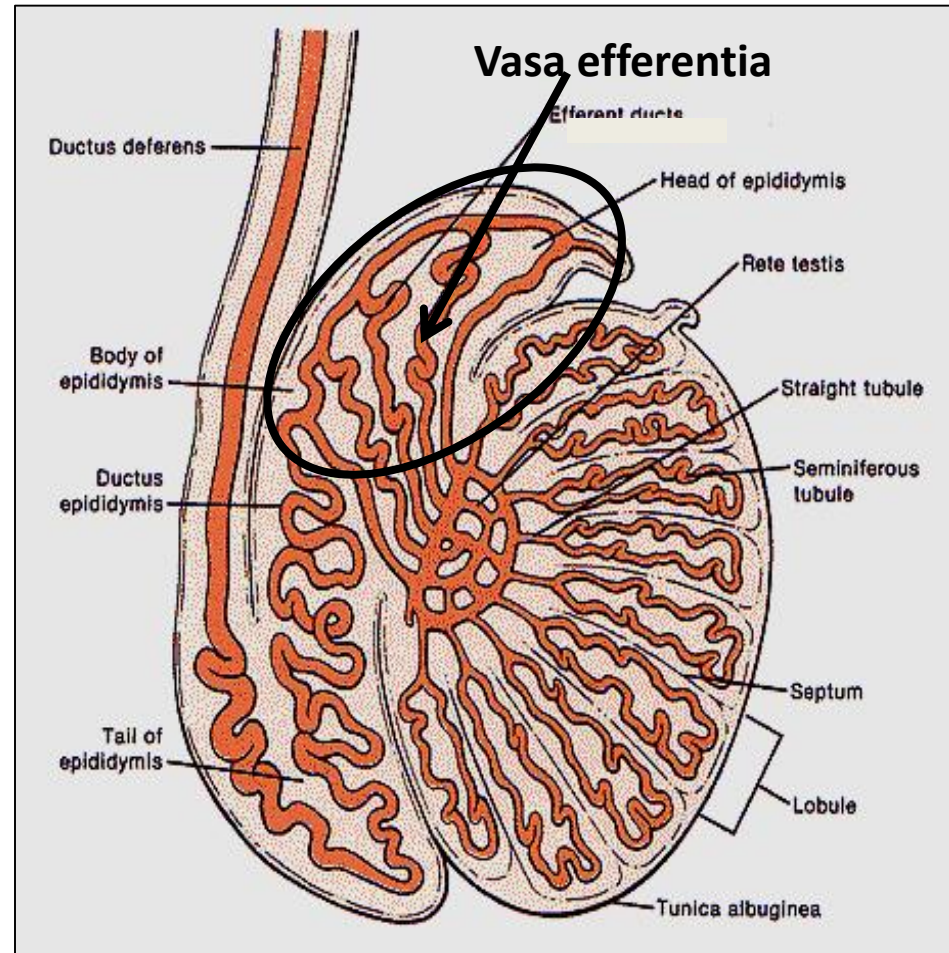


- **Tubuli recti**: straight ends of the seminiferous tubules, lined e Sertoli cells only
- **Rete testis**: anastomosing network of tubules lined e cuboidal cells



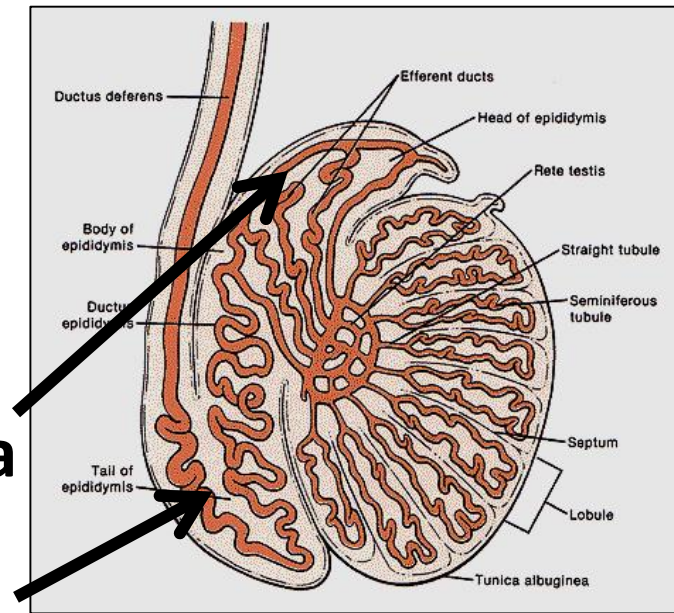
## vasa efferentia (ductus efferentia)

- **10-20** tubules , Lined e **simple cuboidal partially ciliated**
- Fuse with head of epididymis ( ductus epididymis)
- Move spermatozoa toward epididymis by the peristaltic contraction of smooth ms in their wall
- Absorption of most of the testicular fluid by the non- ciliated cells



# Epididymis

- **Single Coiled tubule** (4-6 meter)
- Divides into **head, body & tail**
- **Head** connects e the **Vasa efferentia** while **tail** connect e the **vas deferens**

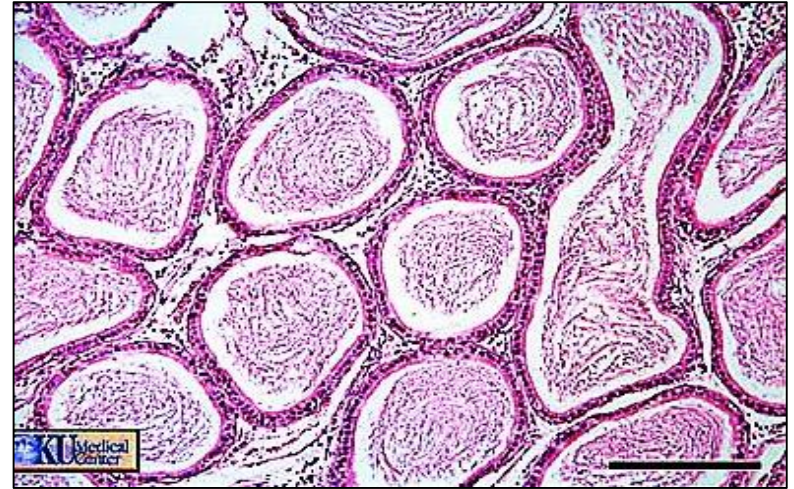


Lined e Principle cells: **pseudo-stratified columnar with stereocilia**) → Help in removal of 90% of testicular fluid

- Smooth muscles of its wall help to move sperms by peristaltic contractions
- Produces glycerol-phosphorylcholine → XX capacitation

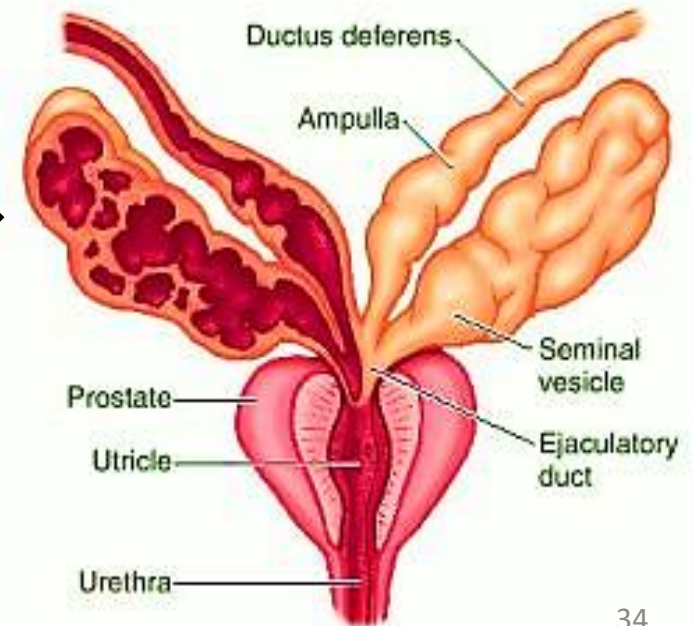
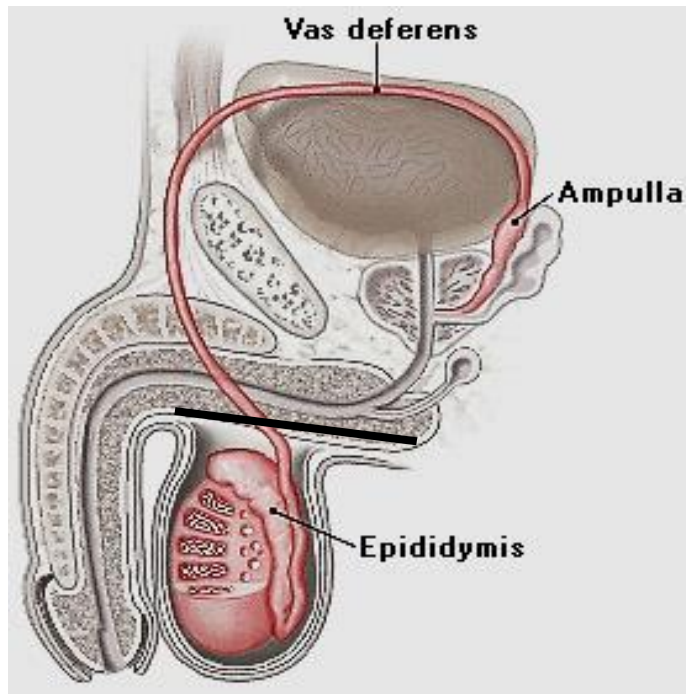
## Function of epididymis:

- **Storage:** of spermatozoa, gain motility
- **Secretion:** of glycoprotein play a role in control Capacitation of Spermatozoa
- **Absorption:** of remaining testicular fluid
- **Phagocytosis;** residual bodies & degenerated spermatozoa
- **Propelling :** of spermatozoa to vas deferens by peristaltic contraction of smooth ms in its wall

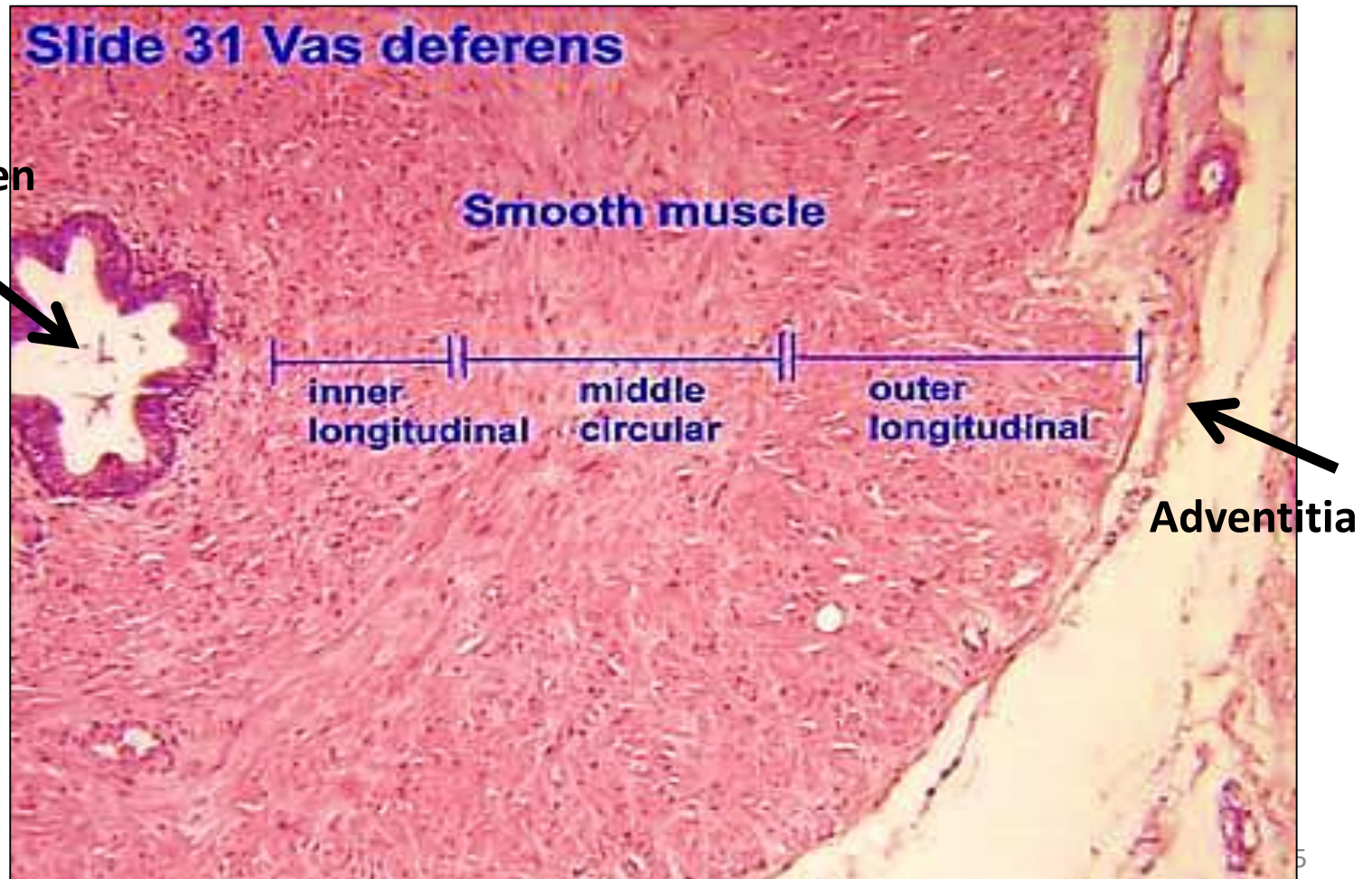


# Vas deferens

- **Single muscular tube**. Starts at tail of epididymis & ends by a dilated part called ampulla of vas
- The ampulla is joined by duct of seminal vesicle gland to form ejaculatory duct → prostatic urethra

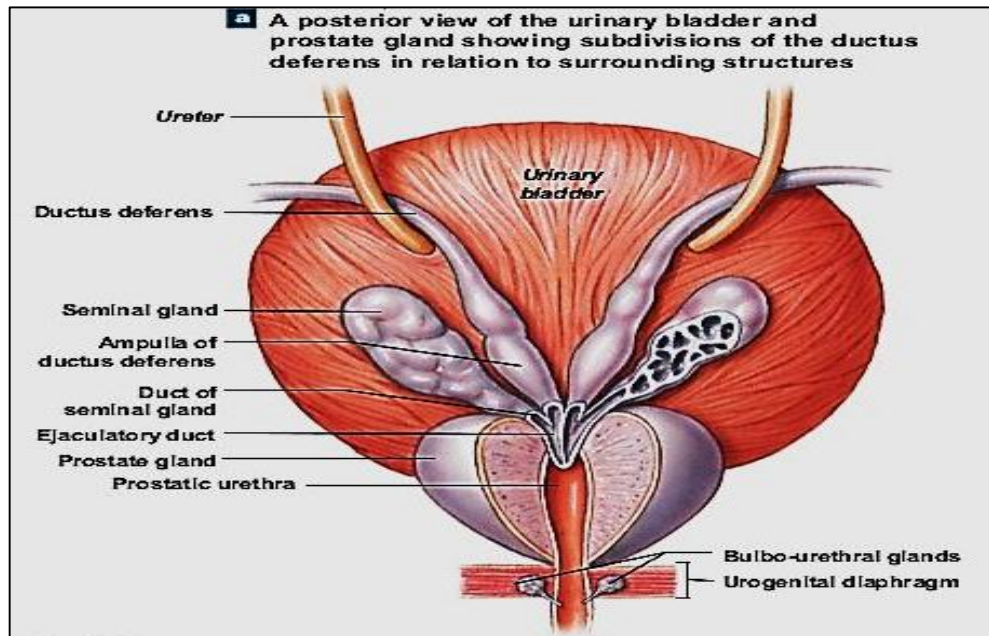


- Narrow lumen & thick layer of smooth ms
- Its mucosa covered e pseudostratified columnar e stereocilia



# The ejaculatory duct

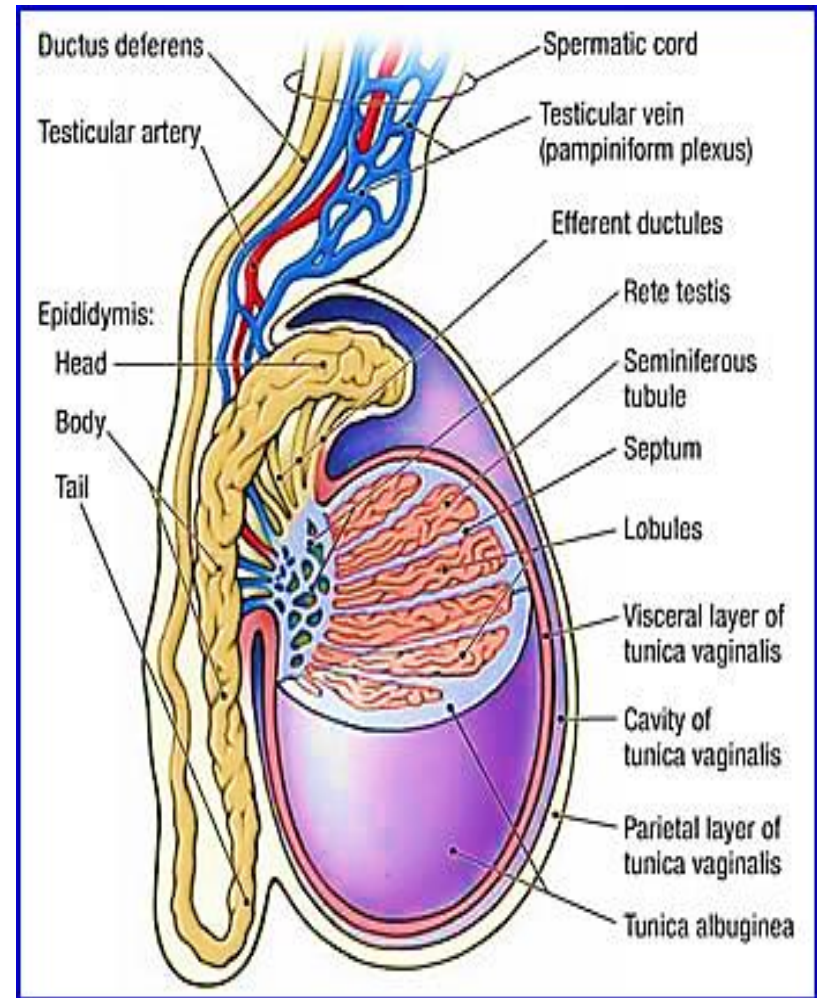
- Short duct = 1 cm
- Formed by union of ampulla of vas deferens & duct of seminal vesicle gland
- It pierce the prostate at the base of urinary bladder to open into the prostatic urethra
- **Lined e pseudo-stratified columnar epith.** ★



# Spermatic cord

Is composed of:

1. Vas deferens
2. Pampiniform plexus of veins
3. Testicular artery
4. Nerves
5. Lymphatic
6. Cremasteric muscle: LT fibers of striated involuntary ms.



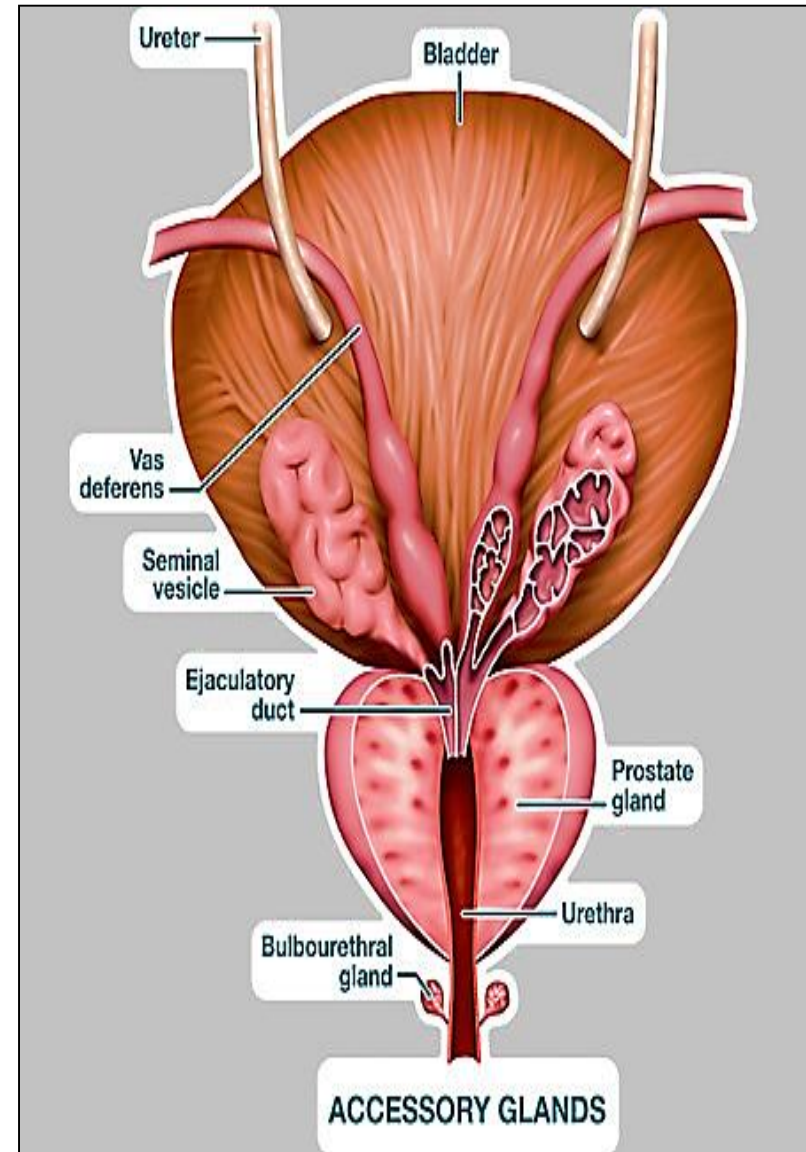
# Accessory glands

1. Seminal vesicles

2. Prostate

3. bulbo-urethral (cowper's)

(All regulated by testosterone)



# 1- Seminal vesicles

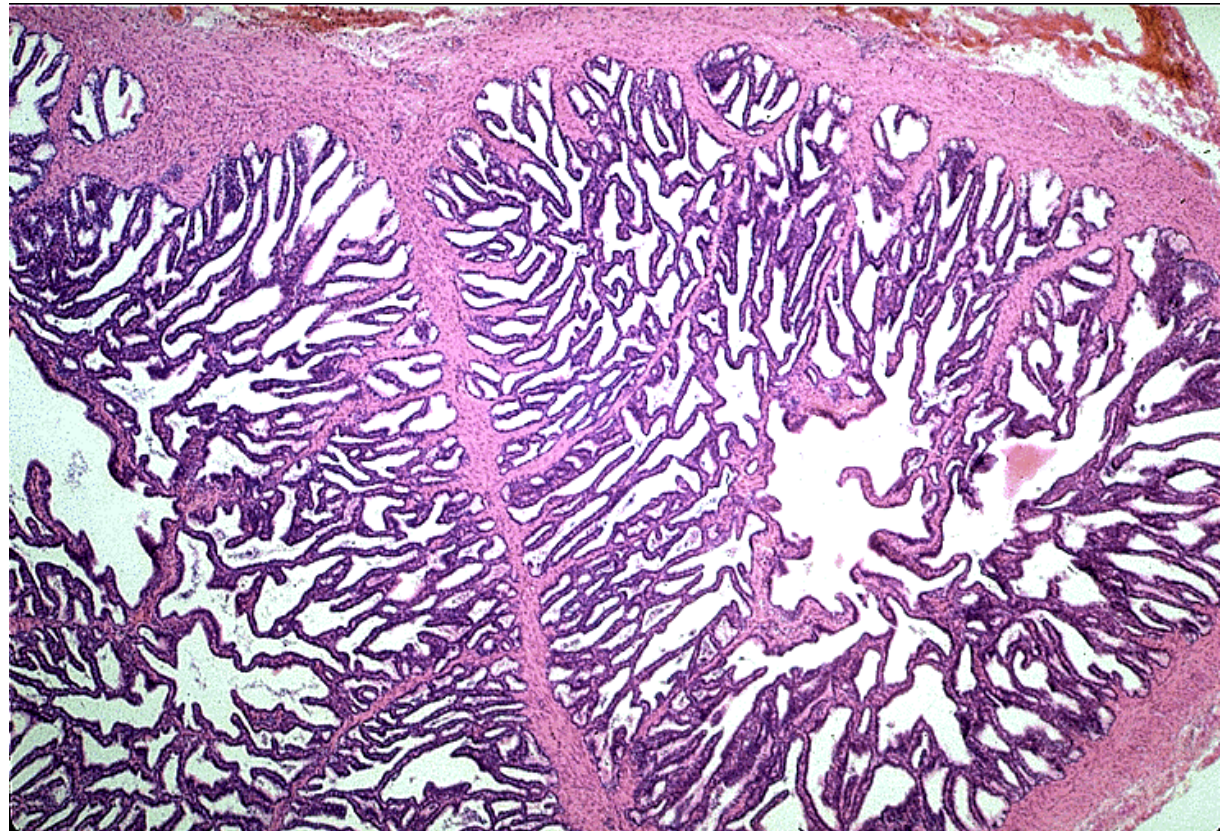
Mucosa:

- Extensively folded → ↑ surface area for secretion
- Lined e **pseudostratified columnar epithelium** with height that varies e testosterone levels

Function:

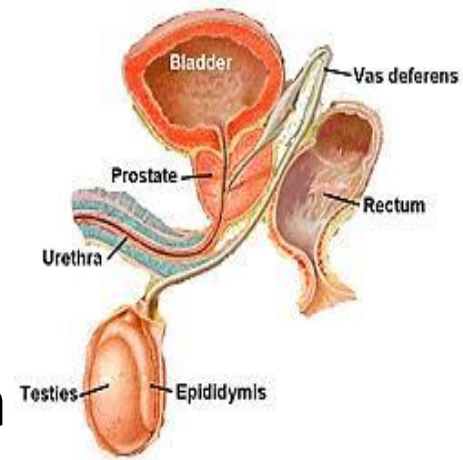
form **70% of the seminal Fluid**

( alkaline,  
yellow & viscid,  
rich in fructose)



## 2- Prostate

**Exocrine gland** surround the neck of bladder  
Parenchyma: 30 -50 branched tubular glands  
(acini – ducts) that open into prostatic urethra



### Prostate has 3 zones:

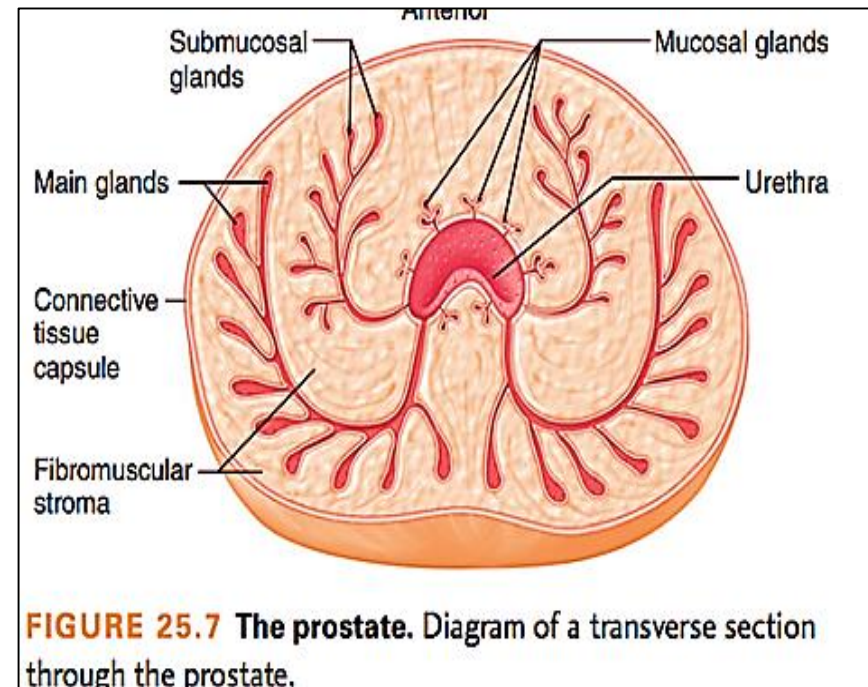
1- Transitional: 5%

Benign prostatic hyperplasia

2- Middle zone (central) : 25%

3- Peripheral zone (main): 70%

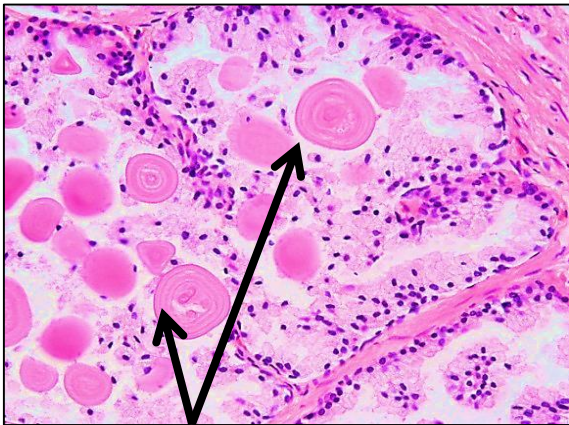
Site of prostatic cancer



**FIGURE 25.7** The prostate. Diagram of a transverse section through the prostate.

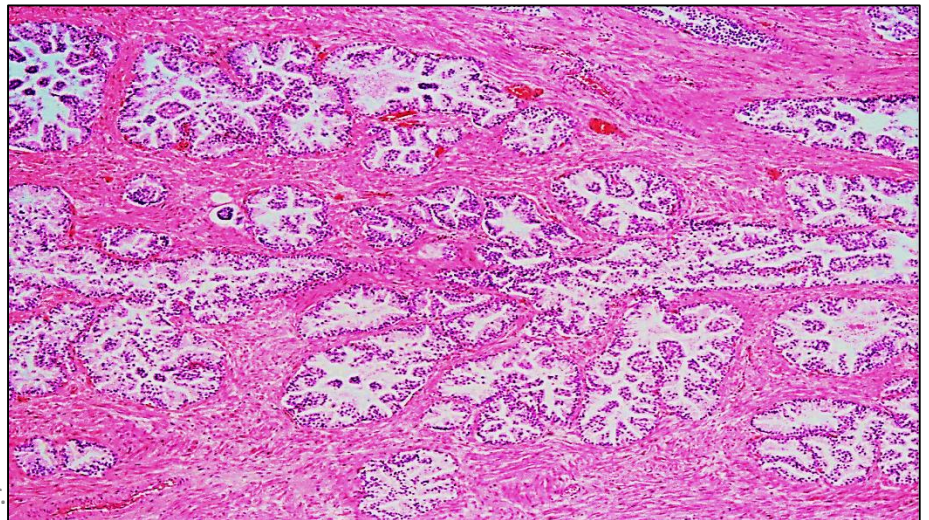
## L/m of prostatic acinus:

- Highly folded **pseudo-stratified columnar epithelium** produce prostatic fluid (thin & milky. gives semen its odor, ++ fibrinolysin → liquefy the coagulated semen after deposited in female genital tract)
- **Corpora amylacea (prostatic concretions):** rounded calcified glycoproteins found in lumen of prostatic acini. (its # ↑ with age)



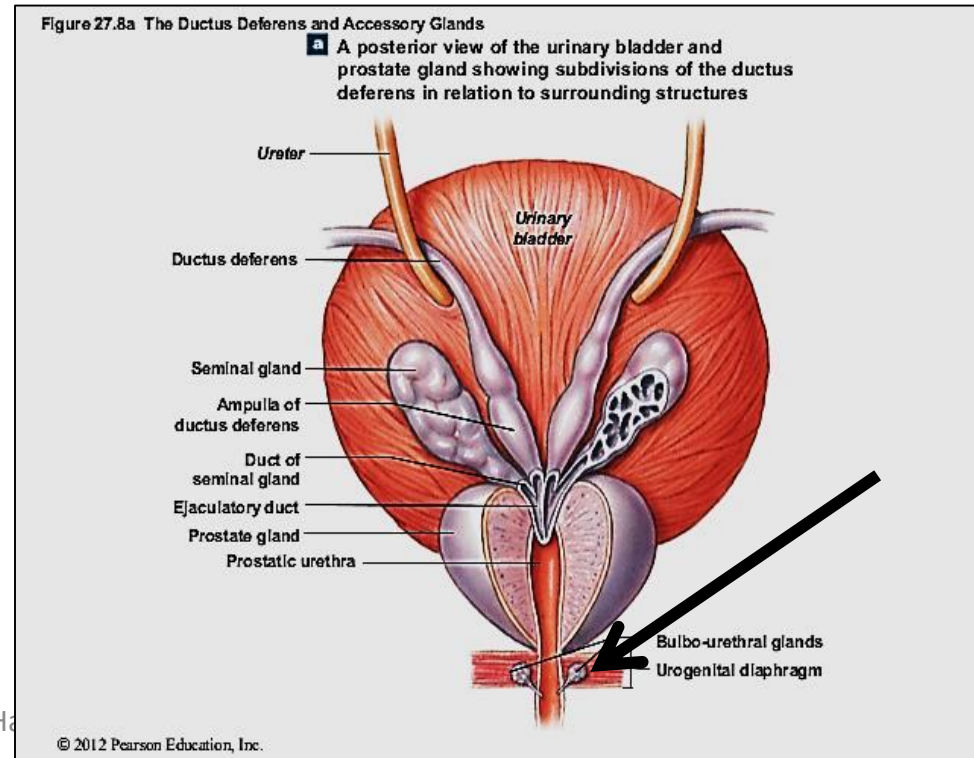
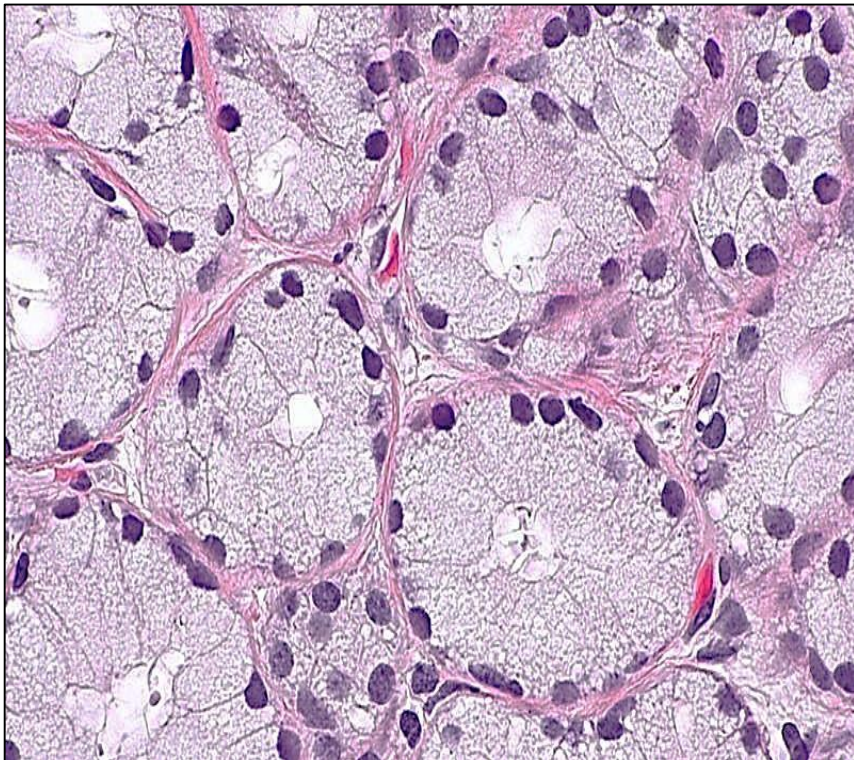
Corpora amylacea

Pro Dr.



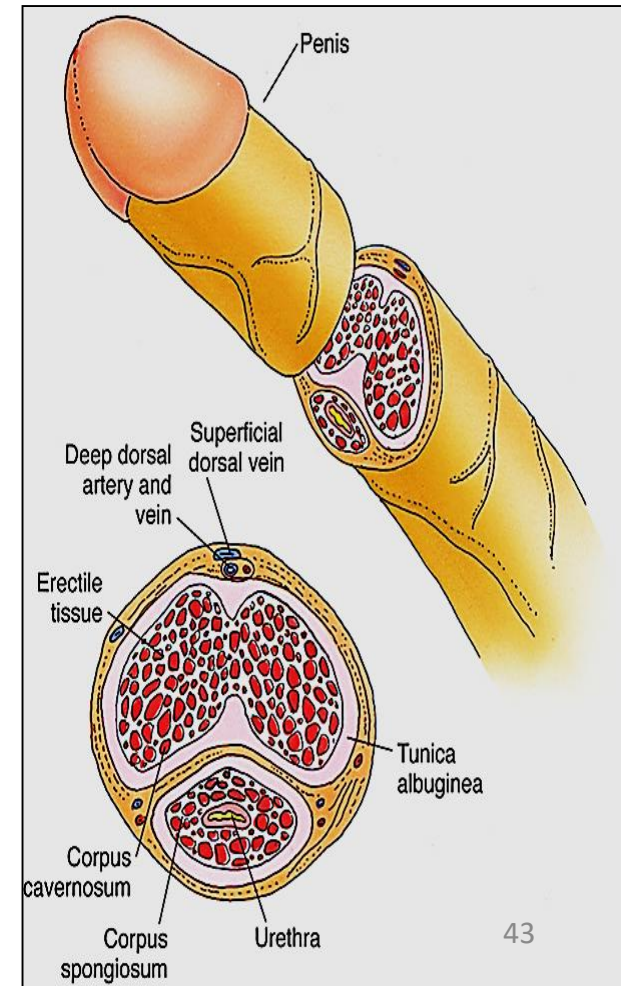
### 3- Bulbo- urethral ( cowper's ) glands:

- 2 glands. Open in proximal penile urethra
- Their acini lined with **simple cuboidal epithelium, mucus secreting** → mucus act as lubricant



# The penis

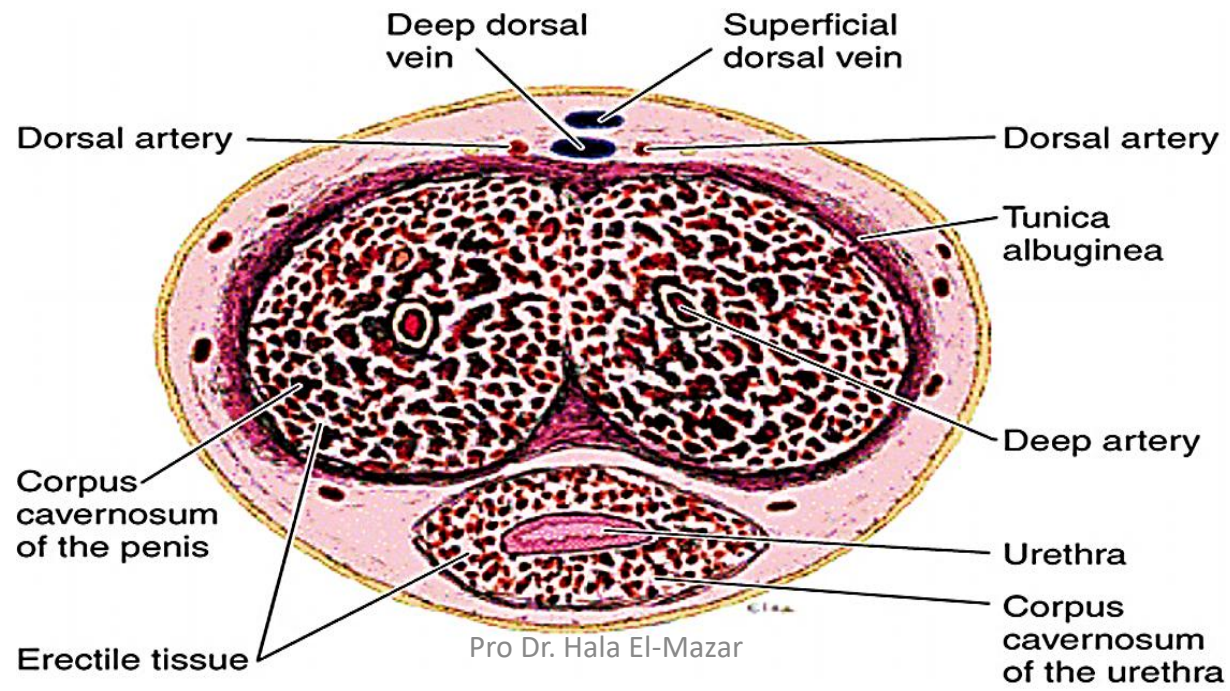
- the body composed of 3 masses of **erectile tissue**
- **2 corpora cavernosa** (dorsally) & **single corpus spongiosum** (ventrally) through which runs the penile Urethra
- At the end of the penis the Corpus spongiosum expands forming glans peins



- *Corpora cavernosa* surrounded by thick tunica albuginea (dense CT)
- *Corpus spongiosum* surrounded by a thin one

- **Erectile tissue:**

- Vascular spaces that become engorged with blood



# Thank you

