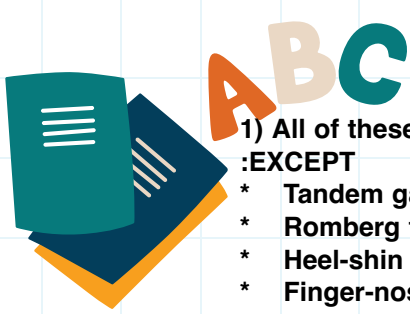
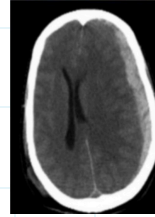
- 1) All of these tests are used specifically for coordination
:EXCEPT
- * Tandem gait
 - * Romberg test**
 - * Heel-shin test
 - * Finger-nose test
 - * Rapid alternating movements

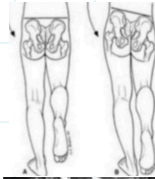2) patient with this CT scan shows:

1. Subarachnoid hemorrhage
2. Subdural hematoma**
3. Interstitial edema
4. Cytotoxic edema
5. Intracerebral hematoma



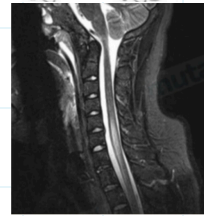3) What is the mechanism of this?

1. distal muscle weakness
2. proximal muscle weakness**
3. sciatic nerve pathology



4) All are manifestations of this condition except

2. Plantar response is Downward**
3. Clonus
4. Hyperreflexia
5. Sensory loss
6. Urine retention




5) One of the following is main feature of trigeminal nerve injury:

1. loss of sensation of the posterior 1/3 of the tongue
2. jaw hyperreflexia
3. loss of sensation of angle of mandible
4. tongue deviation
5. Deviation of jaw to abnormal side**

6) Based on localization of visual field, Where is the lesion?

1. Optic nerve
2. Optic chiasm
3. Optic tract
4. Occipital lobe**
5. Lateral geniculate body

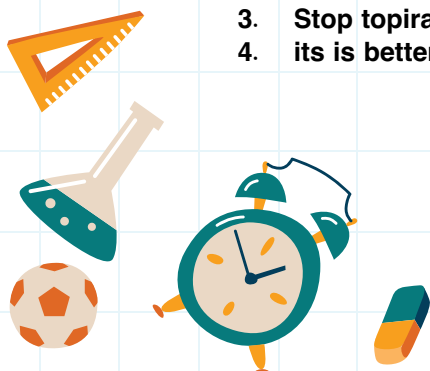


7) The possible lesion in facial palsy :

1. Tongue deviation
2. Loss of taste
3. Jaw hyperreflexia
4. Swallowing difficulty
5. Hyperacusis due to stapedius paralysis**

8) pregnant woman with epilepsy is taking lamotrigine and topiramate. What is the best management plan?

1. Stop lamotrigine
2. Advise her not to get pregnant
3. Stop topiramate
4. its is better switch to mono therapy before pregnancy**



9) Patient suffers from unilateral headache lasts less than 4 minutes with tearing and conjunctival injection, and it can occur up to 14 times a day, What is the treatment:

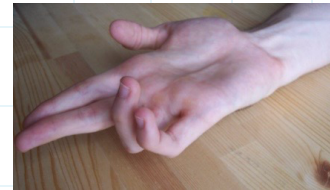1. Carbamazepine
2. Indomethacin**
3. Lamotrigine
4. High-flow oxygen
5. Sumatriptan

10) All of the following are related to glossopharyngeal and vagus nerve except:

- Inability to cough
- Nasal speech
- Tongue deviation**
- Loss of gag reflex

11) Patient hand in rest position,.....:

1. Ulnar nerve injury below elbow
2. Ulnar nerve injury below wrist**
3. Median nerve injury anastomosis with Ulnar nerve
4. Median cord lesion

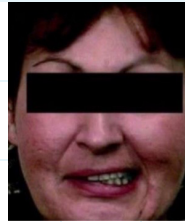

12) all of the following are used to assess the Vestibulocochlear nerve EXCEPT:

1. fukuda test
2. whisper test from behind
3. weber + Rinne test
4. Romberg sign**
5. head impulse test

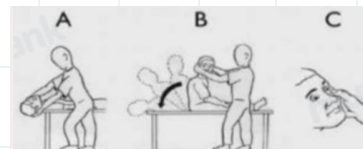13) Which nerve is affected ?

1. Right mandibular nerve
2. Left mandibular nerve**
3. Right Facial nerve
4. left facial nerve



14) This test is used to assess:

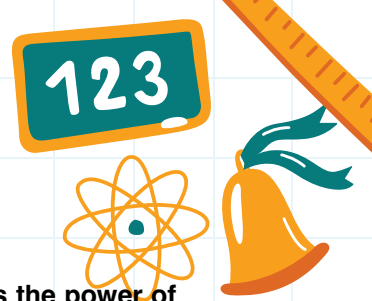

1. Otolith in posterior semicircular canal**
2. Otolith in lateral semicircular canal
3. Otolith in anterior semicircular canal
4. Excessive endolymph
5. Vestibular neuritis



15) are true about mini mental status examination except?

1. MMSE is 30 points screening tool
2. used to diagnose dementia
3. 100-7 → Registration**
4. score of 23 risk for mild dementia
5. It's affected by the patient education





16) On examination patient can flex arm but not against the gravity, what is the power of elbow flexors?

1. 1
2. 2**
3. 3
4. 4
5. 5

17) Which of the following is false regarding the oculomotor nerve?

1. Accommodation is usually normal in oculomotor nerve lesions
2. Ptosis is not always due to oculomotor nerve palsy
3. Not involved in the pupillary light reflex examination
4. Corneal reflex test is part of oculomotor exam **

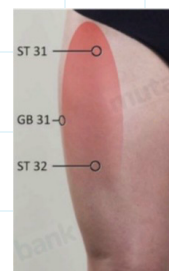
18) A patient presented with status epilepticus. He was given 10 mg of diazepam but didn't improve, and another dose 10 mg also failed.

What is the next step?

1. 20 mg of phenytoin + saline for 2 minutes
2. diazepam
3. 20 mg of phenytoin + glucose infusion
4. 20 mg of phenytoin + glucose for 2 minutes
5. 20 mg of phenytoin + saline infusion **

19) What is true about this picture:

1. do LSS MRI
2. knee reflex is normal**
3. peroneal nerve injury
4. sciatic nerve injury



20) Which type of Guillain-Barré syndrome (GBS) is associated with cranial nerve involvement?

1. Acute motor axonal neuropathy (AMAN)
2. Acute motor-sensory axonal neuropathy (AMSAN)
3. Miller Fisher variant**
4. Chronic inflammatory demyelinating polyneuropathy (CIDP)



21) Which of the following causes central vertigo?

1. Benign paroxysmal positional vertigo (BPPV)
2. Ménière's disease
3. Vestibular neuritis
4. Multiple sclerosis**


22) GSC of open eyes to pain, localize pain, confused

11





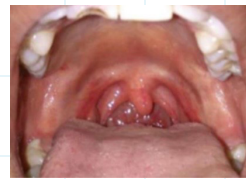23) Pic
common peroneal nerve injury :
A) loss of dorsiflexion and eversion



24) A 20-year-old patient came with weakness and numbness of lower extremities more than upper extremities. He was found to have high-stepping gait and areflexia. all of the following can be a cause of this except ?

1. diabetic neuropathy
2. Guillian-Barre syndrome
3. chronic demyelinating polyneuropathy
4. multiple sclerosis**
5. Charcot-Marie-Tooth

25) One of the following cause to this pt found
A. Rt vagus nerve injury ***
B. Lt vagus nerve injury



26) False matching:
1. upper and lower motor neuron signs: motor neuron disease
2. dystonia: sustained muscle contraction
3. Myasthenia gravis: fatiguability
4. UMNL >fasciculations**
5. Akathasia > antipsychotic use

27) 50 years old female with sudden headache come to ER her CT free what is your managment :

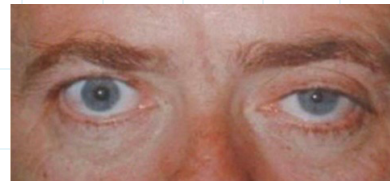1. Admitt her for exclude SAH
2. discharge her if ESR or CRP normal



28) All of the flowing are correctly matched except:

1. Athetosis is common in huntington disease
2. Intention tremor increase while getting closer to the target
3. Tic can be voluntary suppressd but not for long time
4. finger to nose test is normal in resting tremor
5. myoclonus jerks are regular sudden movements**

29) one of the followin is not a cause of this :

1. brainstem infarction
2. oculomotor nerve injury**
3. upper lung tumor
4. neck injury
5. carotid aneurysm





30) According to the sensory examination, one of the following is FALSE:

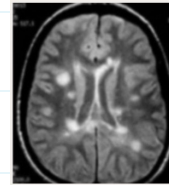
1. We should start examining distally then proximally
2. Small nerve neuropathy leads to balance problem**
3. If proprioception in toes is intact no need to examine proximally
4. Pain and temperature should be examined in Syringomyelitis

31) 50 yo female patient had severe headache, brain CT was normal, what is the next best step in management?

1. Admit to rule out subarachnoid hemorrhage**
2. give analgesia and discharge
3. do lumbar puncture and if csf analysis is normal discharge
4. If ESR + CRP normal discharge
5. give steroid if there is no eye problem

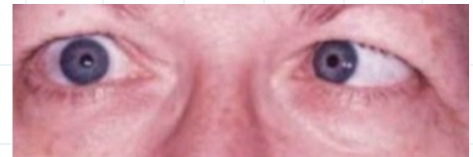
32) A female patient presents with lower limb stiffness past few days. Brain MRI without contrast is normal. What is the most appropriate next step?

1. do lumbar puncture
2. Oral prednisolone
3. Repeat MRI with contrast**
4. Repeat MRI after 6 - 12 months



33) the patient was asked to look to the right, the cause of this :

1. Horner's syndrome
2. intranuclear ophthalmoplegia
3. Increase intracranial pressure**

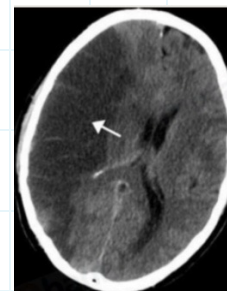



34) Patient complaining of eye pain and blurred vision (optic neuritis), all of the following could be found, except?

1. Defect color vision
2. Abnormal blind spot
3. Defect pupillary reflex
4. Fundoscopy may show distributed optic disc
5. double vision**

35) all are cause of this lesion except :

1. hypertension
2. patent foramen ovale**
3. atrial fibrillation
4. Valvular heart disease





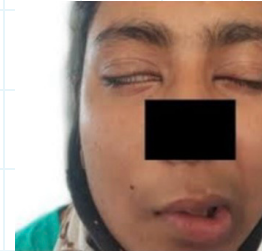36) Patient came with fever and headache, if this sign was positive. Choose the wrong answer.

1. Lumbar puncture is the definitive investigation for identifying the causative organism
2. brain imaging should be performed before CS analysis in patients with clinical signs of increased ICP
3. CS culture remains reliable after few days of antibiotic use**
4. steroids often given to reduce the inflammatory response



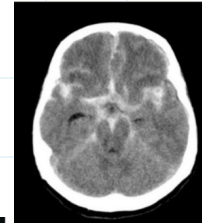
37) which of the following is true regarding this presentation :

1. Patient have a stroke
2. loss of left side face sensation
3. taste sensation could be affected**
4. brain MRI is necessary



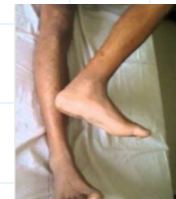38) all are used in management of this case EXCEPT:

1. strong analgesic
2. nimodipine
3. warfarin**
4. strict blood pressure management
5. antiepileptic drugs



39) this test is used to assess :

1. strength
2. reflexes
3. coordination**
4. sensation



40)

Which of the following is wrong about bulbar palsy?

1. Swallowing is affected
2. Speech is nasal or dysarthric
3. Jaw hyperreflexia**
4. Weakness of palate and pharyngeal muscles

