

“

# FORENSIC MEDICINE ARCHIVE

GROUP A '5/2025'

DONE BY:  
HANEEN AZZEH  
BAYAN MAHMOUD





Q1) scaled saw snake, correct:

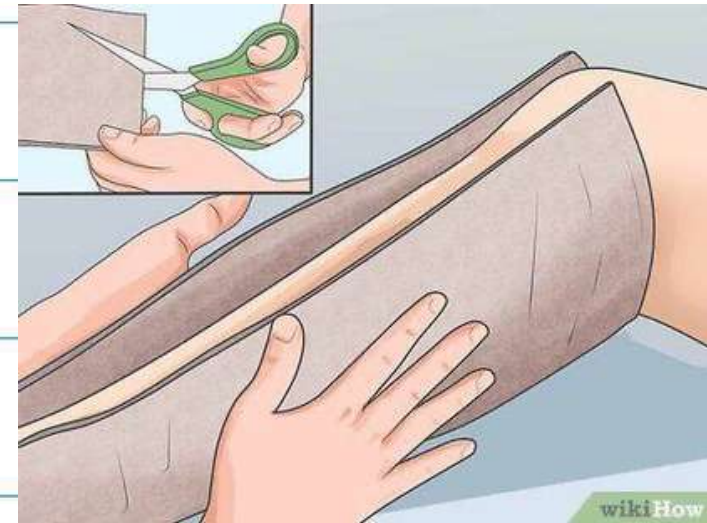
- A) not found in jordan
- B) cause of death is hemmorrhage
- C) local symptoms low or absent
- D) least toxic snake



ans:b

Q2) correct of this picture

- A) not indicated in animal bites.
- B) the secons most effective management
- C) most effective management
- D) don't make it with scorpione bites
- E) Prevent all dermal absorption



Ans:c

Q3)which cause dialted pupil not response to light:

- A) adrenaline
- B) amphetamine
- C) morphine
- D) atropine

Ans:d

Q4) A patient had a history of carbon monoxide (CO) poisoning and was treated with oxygen therapy. After 3 weeks, the patient developed memory abnormalities and cognitive decline. What is the most likely cause of these new symptoms?

- A) Stroke
- B) Delayed neurological sequelae (DNS)
- C) Post-traumatic stress disorder (PTSD)
- D) Residual hypoxia from incomplete treatment
- E) Medication side effect

ans:b

Q5) A patient was exposed to fire. He complains of severe headache and nausea, and his oxygen saturation is 98% on pulse oximetry.What is the most likely cause of his symptoms?

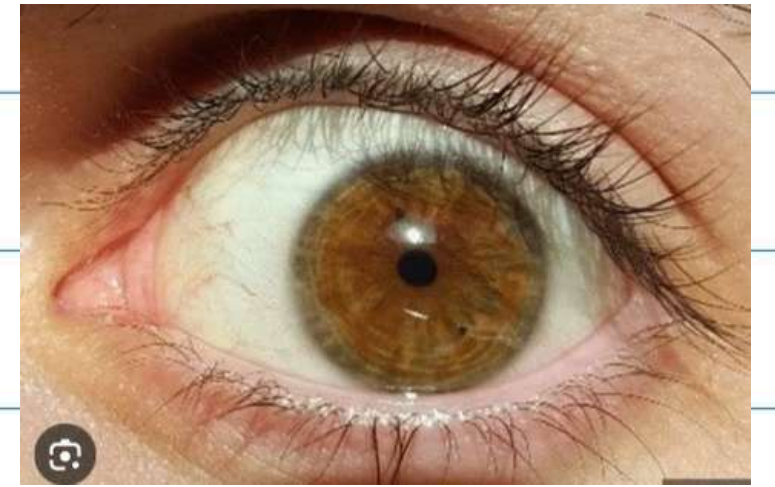
- A) Carbon monoxide (CO) poisoning
- B) Cyanide poisoning
- C) Smoke inhalation injury causing airway edema
- D) Hypovolemic shock due to fluid loss
- E) Panic attack from psychological stress

ans:a



6) An agricultural worker was exposed to insecticide and developed symptoms of toxicity. The physician administered atropine and oximes as treatment. Atropine was continued until the patient's pupils became dilated, although the initial finding was pupil constriction (miosis). Which of the following best reflects your opinion on this management?

- A) You agree with the physician's overall approach.
- B) You disagree with the physician's decision to wait for pupil dilation.
- C) You disagree with the overall management plan.
- D) You disagree with the use of oximes in this case.



ans:b

Q7) What is the key difference between carbamate and organophosphate (OP) poisoning in terms of treatment?

- A) Both atropine and oximes are used for treatment in both types of poisoning.
- B) Oximes are used only in organophosphate poisoning, not in carbamate poisoning.
- C) Atropine is ineffective in carbamate poisoning.
- D) Oximes are the first-line treatment for both poisonings

ans:b

Q8) A child is suspected to have been bitten by a scorpion. What is the most likely cause of death in such cases?

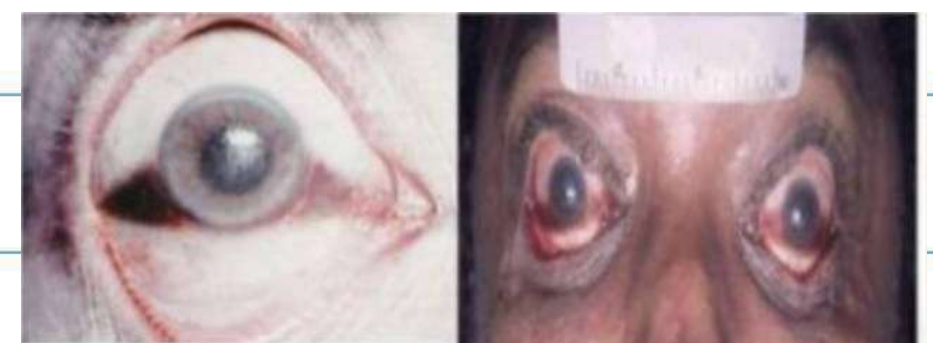- A) Renal (kidney) toxicity
- B) Cardiotoxicity
- C) Neurotoxicity
- D) Respiratory failure

Ans:b

Q9) which is correct ?

- A) early PM, its called tache noir
- B) petechial hemorrhage
- C) late PM

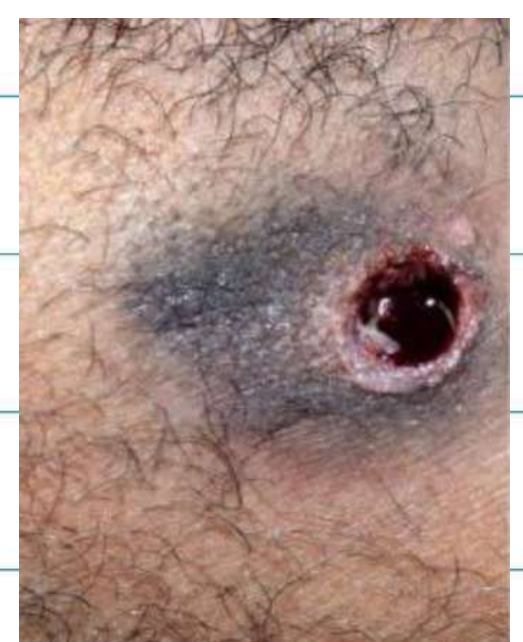Ans:a



Q10) Which of the following is TRUE regarding firearm (gunshot) entry wounds?

- A) The direction of firing can be determined based on the wound characteristics.
- B) All firing residues (firearm marks) can be completely wiped off.

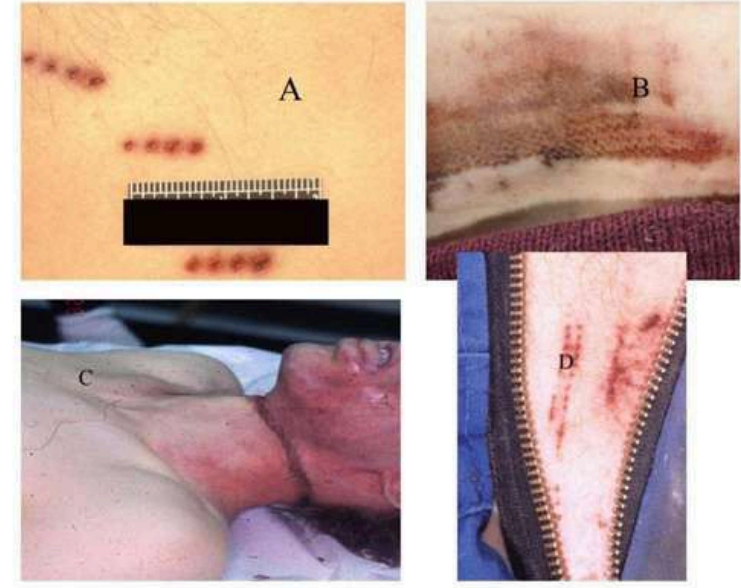
Ans:a





Q11) true about pictures

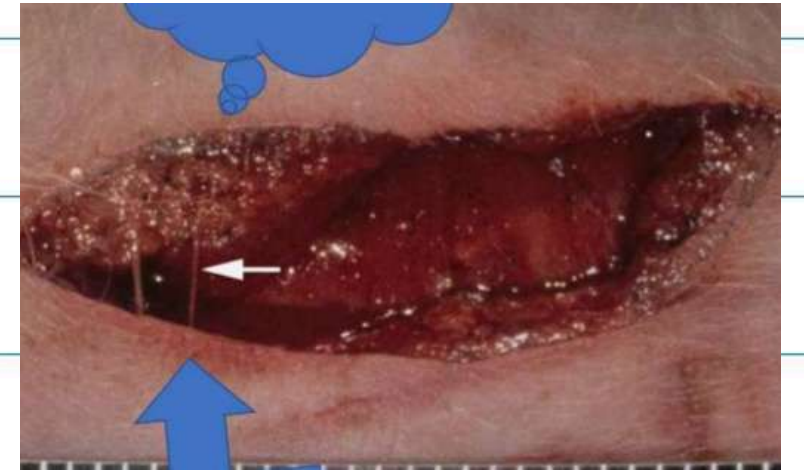- A) all are patterned wound
- B) all are patterned wounds with blunt object
- C) all are fabricated



Ans:a

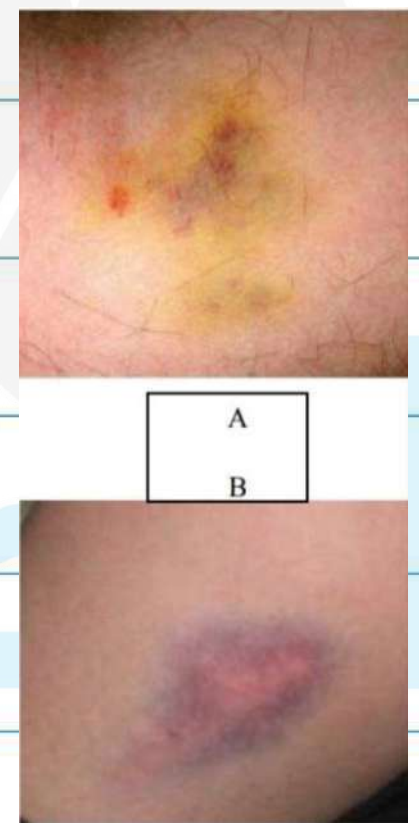
Q12)about this injury :

Contused wound that stimulate cut wounds



Q13) which is true :

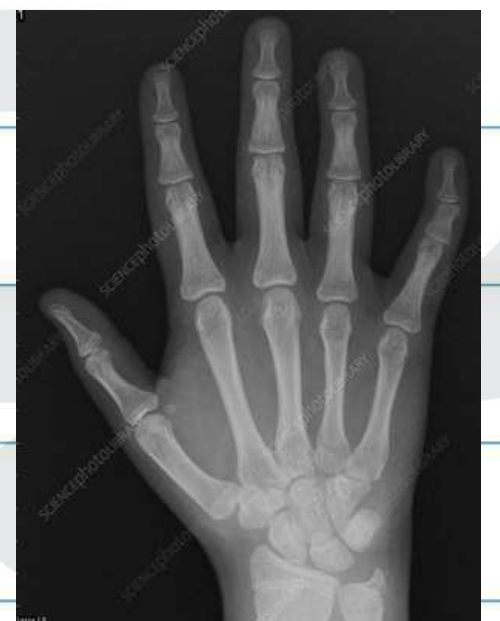- A) A is older than B
- B) B is older than A



Ans:a

Q14) this is X ray for Female patient , her age?

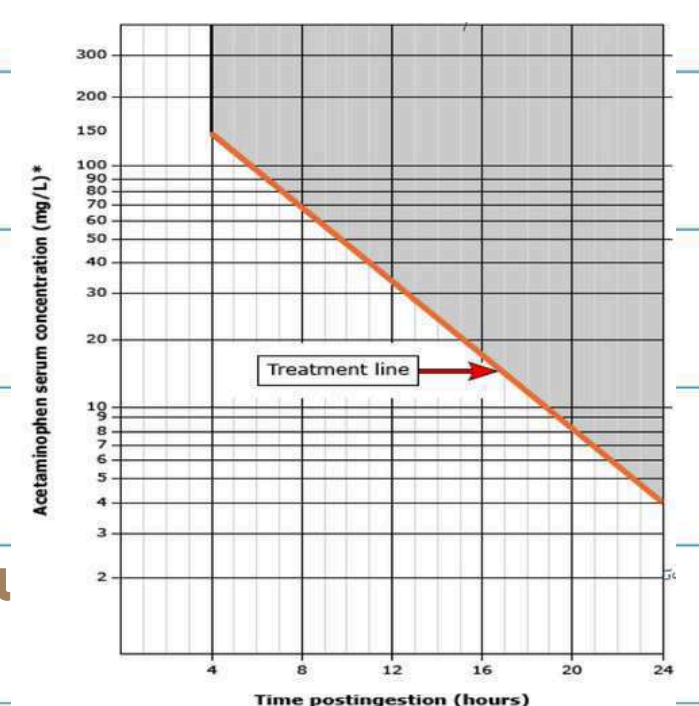
- A) above 20
- B) above 18
- C) 16 - 18



Ans:c

Q15)This test use for:

- A)to detect unknown ingested amount
- B) to determine amount of antidote
- C) to determine paracetamol concentration in serum
- D) for toxicity after appearance of clinical manifestations

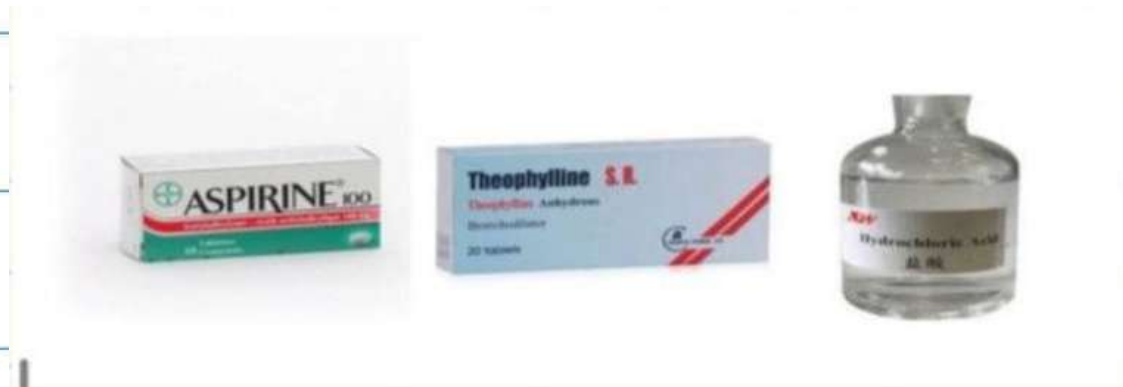

Ans:a



Q16) In which of the following toxin exposures is urine alkalinization indicated as part of the treatment?

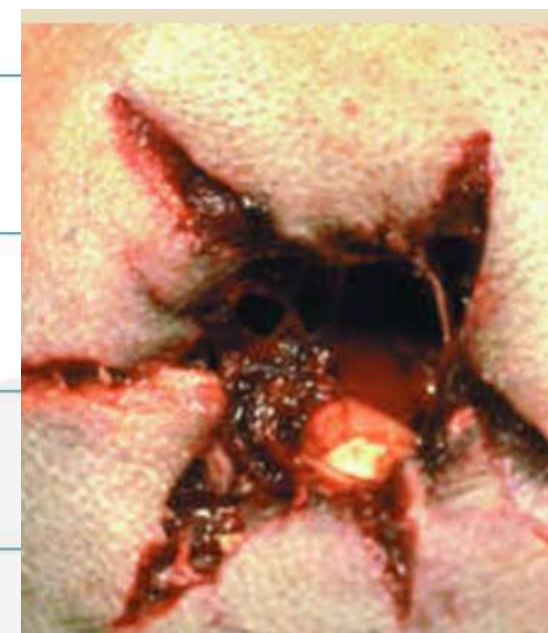- A) Theophylline
- B) Hydrochloric acid
- C) Salicylates (e.g. Aspirin)
- D) Aspirin and theophylline



ans:c

Q17) wrong about picture

It is commonly seen in intermediate-distance gunshot wounds



Q18) One is true regarding this :

- a) The visual identification is the most effective method
- b) it is open disaster
- c) it is closed disaster

Ans:b



Q19) A) all are cadaveric spasm

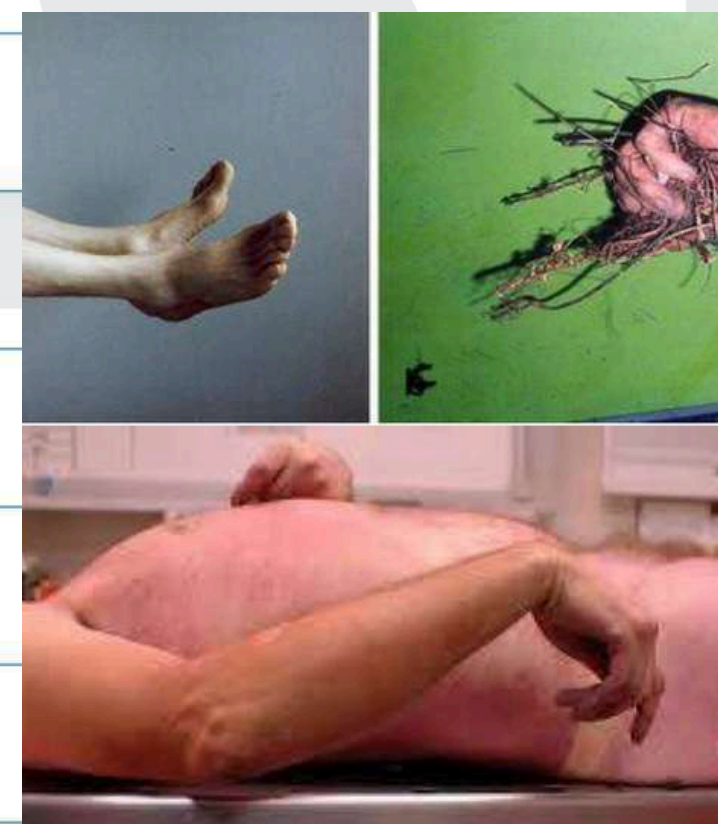B) all are rigor mortis

C) all occur at same time

D) all occur in all muscles, voluntary and non voluntary

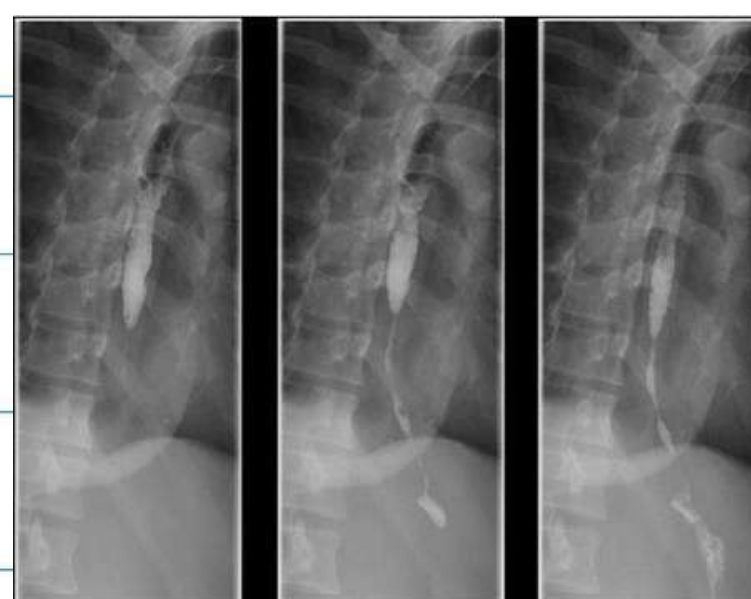
E) A&B occurs in all muscles, but C only in voluntary muscles.

ans:e



Q20) Barium swallow of child came to clinic after 5 WEEKS of ingesting a house Bleach material , what is best Next step in management :

1. Esophageal dilation therapy
2. Steroids & antibiotics
3. urgent Esophagectomy of this part
4. endoscopy with biopsy
5. Reassurance and discharge



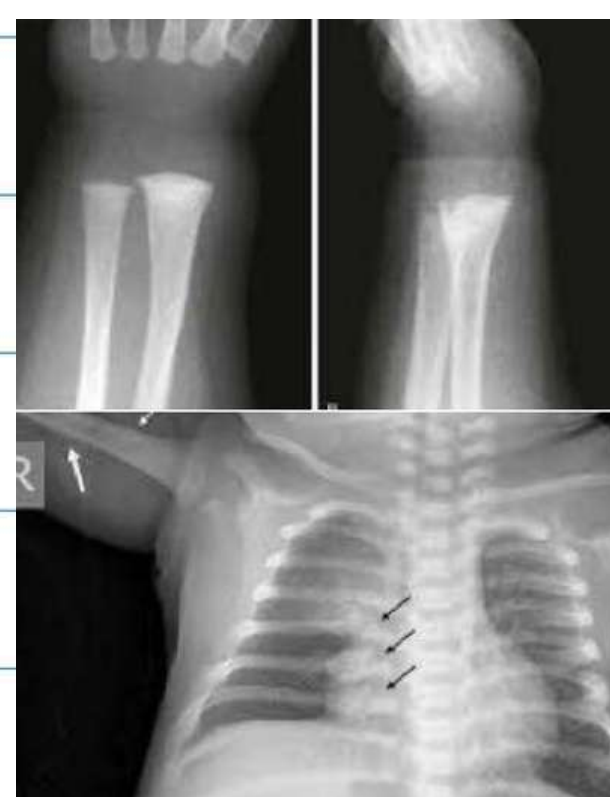ans:1



Q21) 6 years old female comes with fractures in .. limb, after few days she comes with her mother with other fracture, mother says "she felt from ...", X-ray revealed healed rib fracture, the next step you have to do:

- A) give analgesic and follow up.
- B) set with girl and ask about full story.
- C) call child protection. ( هيك اشي معناه مش متذكر الصيغة )
- D) follow up and report findings

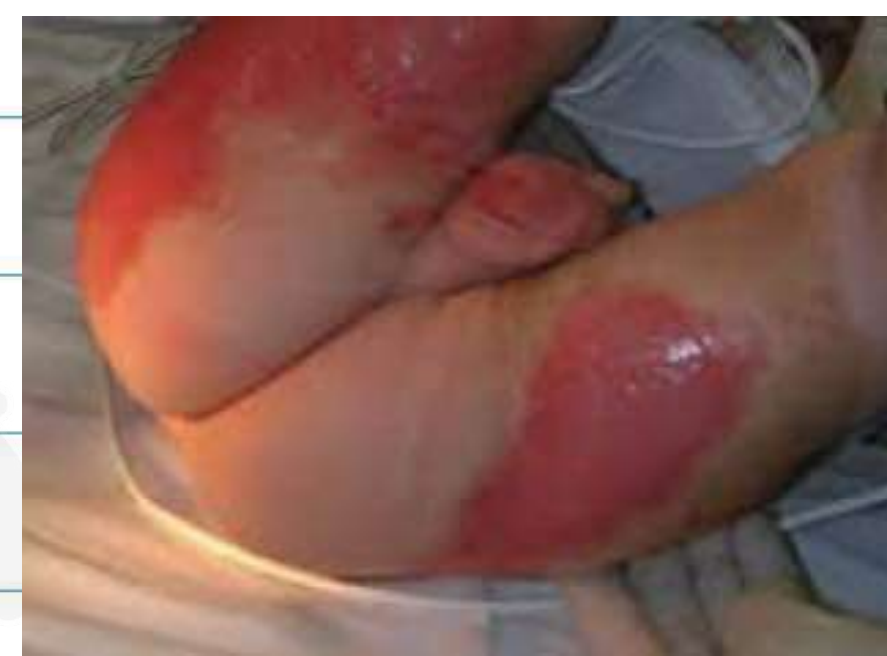Ans: c



Q22) A child presents with burn injuries. The mother claims he was accidentally burned with hot water. However, on examination, there are suspicious finger-shaped marks around the burn area. Which of the following findings would best support a non-accidental burn rather than accidental injury in this case?

- A) Well-demarcated burn margins
- B) Presence of blisters
- C) Splash marks with irregular borders
- D) Symmetrical immersion burns
- E) Clear line of demarcation with uniform depth


ans: a



Q23) true about picture

- A) hyoid fracture very common
- B) most commonly homicidal
- C) complete circle around neck
- D) hypostasis at the limbs

Ans: d



Q24) Patient with history of DM, Hypertension and IHD, complaining of dyspnea and severe chest pain, He died a few minutes after arriving, One of the following is true:

- a) circulatory failure due to myocardial infarction due to IHD
- b) circulatory failure due to IHD
- c) circulatory failure due to IHD due to DM
- d) circulatory failure due to ischemia due to HTN

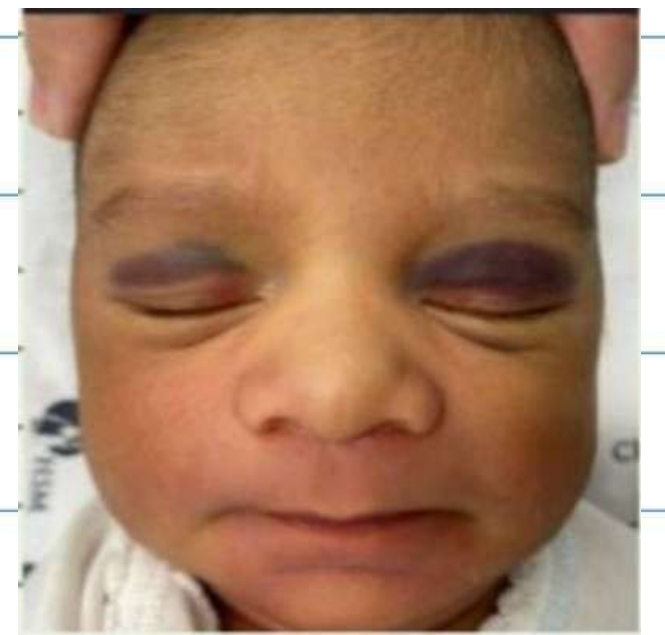Ans: a



Q25-Baby came to ER, what should you do:

- A Nothing, the baby is well
- B) Monitor the baby
- C) You should take CT images for the skull
- D/ Caused only by direct blow to his eye

Ans:c



Q26) A child accidentally ingested kerosene and subsequently developed repeated episodes of vomiting. Chest X-ray and CT scan show infiltrates predominantly in the right lower lobe. What is the most likely diagnosis?

- A) Neurogenic pulmonary edema
- B) Aspiration pneumonia
- C) Chemical pneumonitis due to aspiration
- D) Lobar bacterial pneumonia

Ans:c

Q27) A known chronic alcohol user presents to the emergency department. He had his last drink 24 hours ago and currently shows signs of tachycardia and restlessness. What is the most appropriate initial medication to administer?

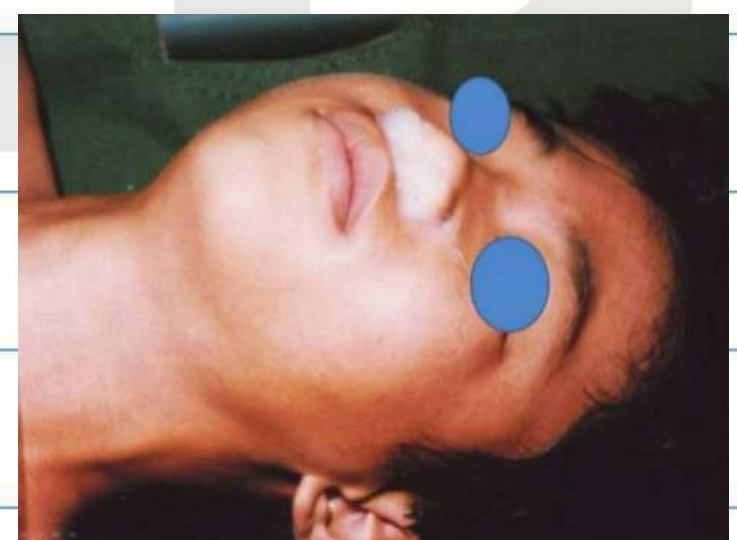- A) Thiamine
- B) Beta blocker
- C) Benzodiazepines
- D) Haloperidol

Ans:c

Q28) One is true about this sign:

- A) probably sign of drowning
- B) once wipe it, will not appear
- C) it has odour
- D) it's due to a deep inhalation under water

Ans:d





Q29) A 52-year-old man with a history of chronic alcohol use presents with confusion and difficulty walking. On examination, he has horizontal nystagmus, bilateral lateral rectus palsy, and ataxic gait. He was started on IV thiamine, but over the next few days, his confusion persisted. He is now unable to form new memories and frequently confabulates when asked about recent events.

What is the most likely diagnosis?

- A) Wernicke encephalopathy
- B) Korsakoff encephalopathy
- C) Delirium tremens
- D) Alcoholic hallucinogenic

مش نفس السؤال بالزبط بس فكرة وجود ال amnesia  
Ans :b

Q30) toxicity of methanol,, what we can use to inhibit its metabolism ?  
Ethanol

صبرُكَ الَّذِي تَظَمَّ بِهِ الْيَوْمُ؛  
يُروِيكَ غَدًا!



# نموذج من الكويز

1. Choose one correct answer:

1. As regard permanent teeth:

- a. There are 23 teeth.
- b. Start to erupt at the age of 12
- c. Start to erupt by teeth which were not present in mild dentation.
- d. Complete at the age of 12.
- e. Complete at the age of 15.

ans:c

2. Puncture wound:

- a. Blunt injury.
- b. Reach a body cavity.
- c. Reach hollow viscus.
- d. Reach solid organ.
- e. It is almost pattern wound.

Ans:e

3. Emesis:

- a. Routinely done in all toxic cases.
- b. The most effective method of GI decontamination.
- c. Absolutely contraindicated in sharp object ingestion.
- d. Indicated in hydrocarbon ingestion.

ans:c

4. The following are general external signs of asphyxia EXCEPT:

- A) Cyanosis.
- B) Bulging eyes with subconjunctival hemorrhage.
- C) Congested lungs.
- D) Bloody froth at mouth and nose.
- E) Protruded tongue, which may be bitten except in hanging with posterior suspension.

ans:c

5. type of violent asphyxia due to occlusion of mouth and nose:

- a. Hanging.
- b. Drowning.
- C. Mugging.
- d. Strangulation.
- e. Smothering.

ans:e

6. Hypostasis in drowning:

- a. Never occurs.
- b. Sure sign of drowning.
- c. Probable sign of drowning.
- d. Highly suggestive of drowning.

ans:c



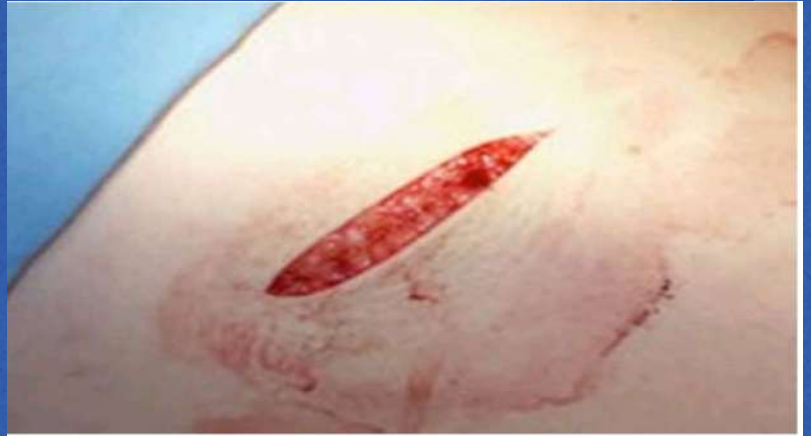# Forensic medicine archive !

Group B

Which of the following must be found in primary report for this injury??

- 1) Caused by sharp tool
- 2) need more than 21 day to heal.
- 3) this is lacerated wound.

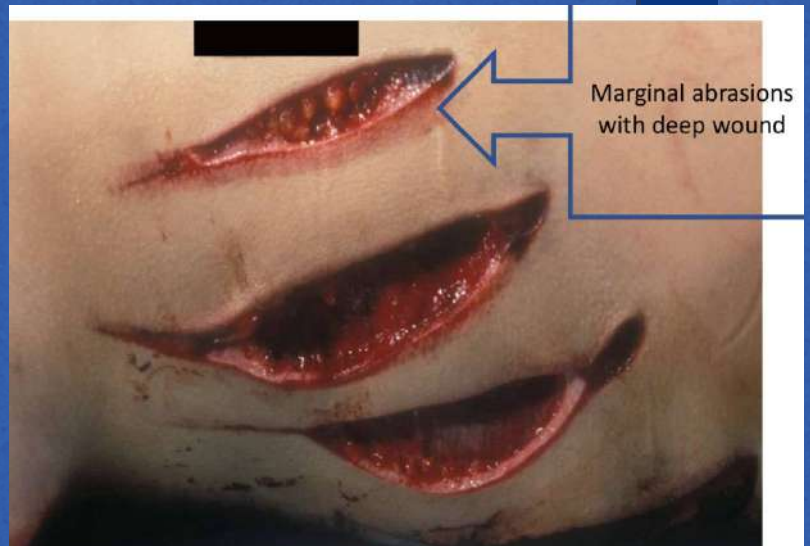
Answer = 1



type of wound ??

- 1) incised wound
  - 2) stab wound
  - 3) incised + lacerated
- which called = chop injury.

Answer = 3

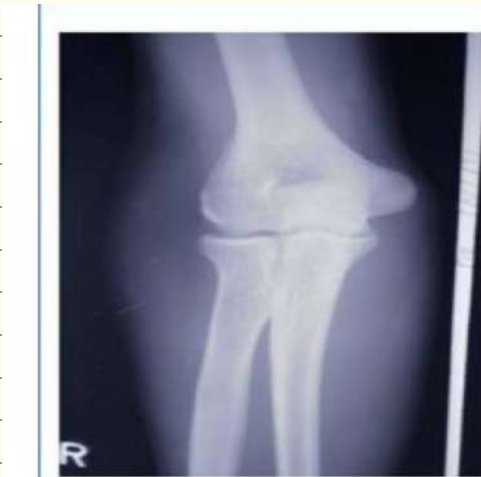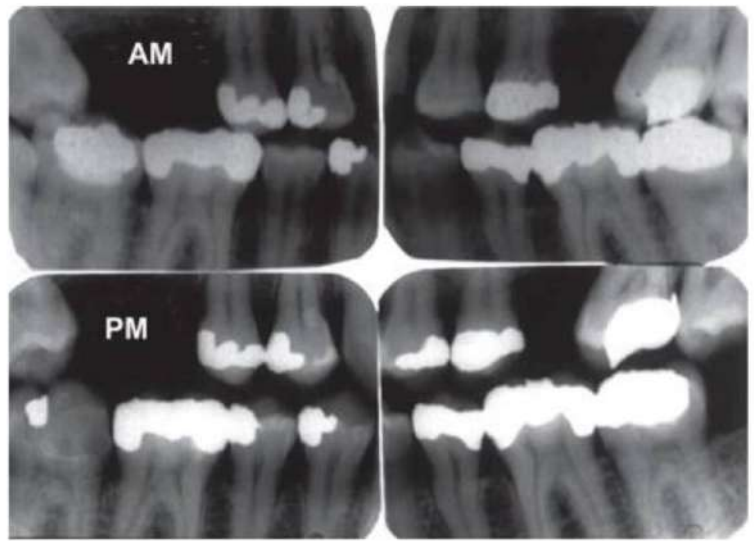




Can we use this to identify so

- 1 - sex
- 2 - sex and age
- 3 - personal identification

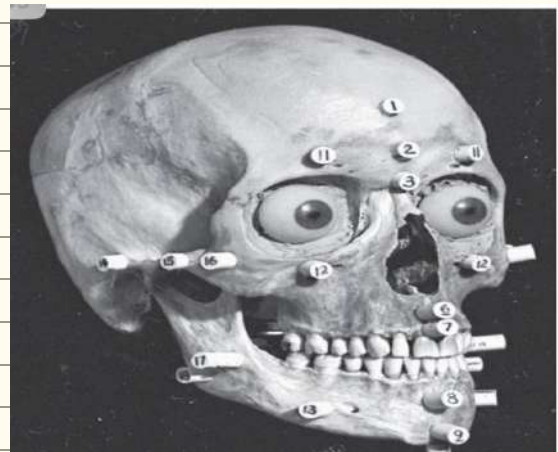
Answer = 2



this is Xray for male age ??

- 1 - above 12
- 2 - above 20
- 3 - above 17

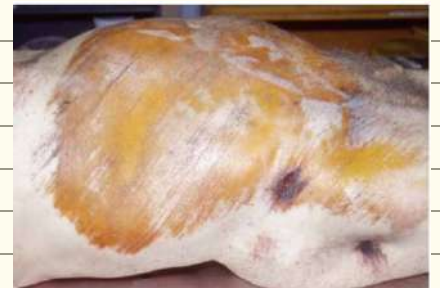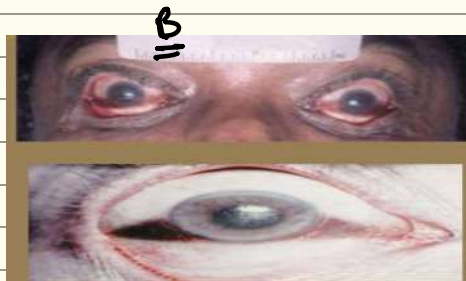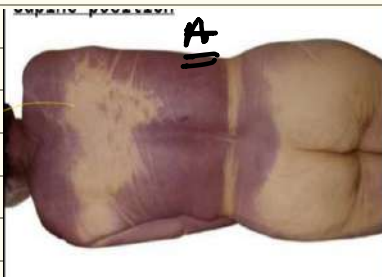
Answer = 3



this is process called so

- 1 - facial reconstruction
- 2 - facial recognition
- 3 - skull superimposition

Answer = 1



which of these picture suggest algor mortis !!

- 1) A
- 2) B
- 3) none

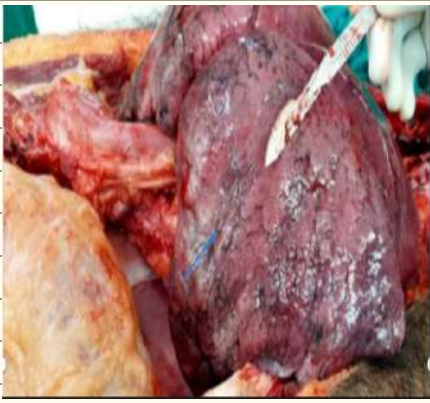Answer = 2

this picture suggest?

- 1 - PM abrasion
- 2 - PM bruise
- 3 - AM abrasion

Answer = 1

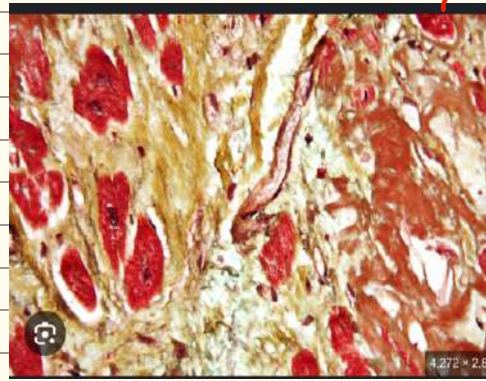




all of the following are true except ~~so~~

- 1) this is strangulation
- 2) pale volminous lung
- 3) lung is firm and rubbery.

Answer = 1

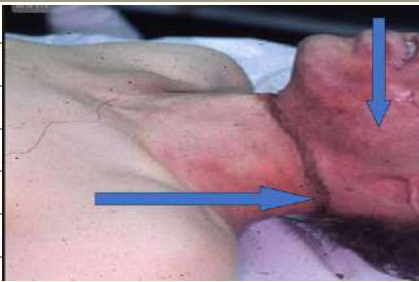

عمر بالزبط  
صلي  
لانها الصلبة  
من الشرحه

40 year old man suddenly death, No previous history of disease, but he is complain from HTN and DM, from picture What is the cause of death. ?

- 1) Cardiovascular failure due to MI
- 2) " " " " HTN
- 3) AS failure due to PE.

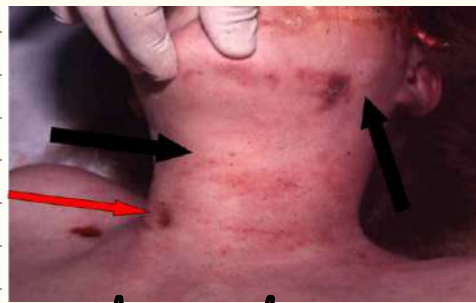Answer = 1



all of the following are false except about this picture?

- 1) hypostasis in the lower limb.
- 2) associated with hyoid fracture.
- 3) mainly homicidal.

Answers = 1



all of the following are true except ?

- 1) mainly homicidal.
- 2) petechiae and bruise are minimum
- 3) associated with hyoid bone fracture

Answers = 2

\* all of these drug are used in ethanol toxicity except:

- 1) benzodiazepam
- 2) amphetamine
- 3) B complex

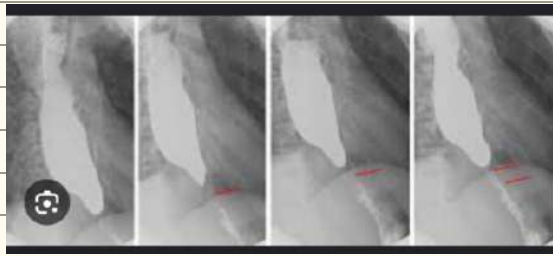
Answer: 2

\* most appropriate presentation to diagnose methanol toxicity !!

- 1) snow storm appearance
- 2) tachycardia
- 3) dilated pupil.

Answer = 1

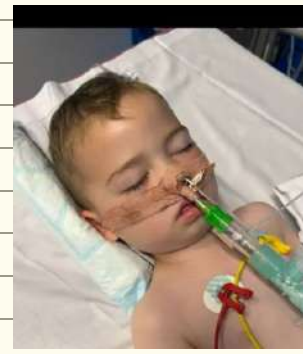



barium meal for someone ingest corrosive after 5 weeks what are the next step !!

- 1) esophageal dilatation
- 2) endoscopy and biopsy
- 3) surgery

Answer 1



baby come to emergency center and the mother said he is ingest a corrosive, what is the management !!

- 1) emesis and AC
- 2) IV fluid and analgesia
- 3) gastric lavage

Answer 2

\* What is the mechanism of AC !!

- 1) enhance elimination only
- 2) decrease absorption only
- 3) enhance elimination and ↓ absorption

Answer 3

\* What is the mechanism of Kerosene to cause respiratory failure?

- 1) chemical pneumonitis by aspiration.
- 2) neurogenic shock
- 3) surfactant overproduction

Answer: 1

\* specific sign and symptom to drug toxicity called!

- 1) toxic syndrome
- 2) toxic syndrome
- 3) pattern toxic syndrome

Answer 1

\* Case: با هذا الامر  
كان يحرق ملبس الكندر  
بطلق دخانه من  
جولة العج !!

oxyhemoglobin curve shifts to the same cold exposures

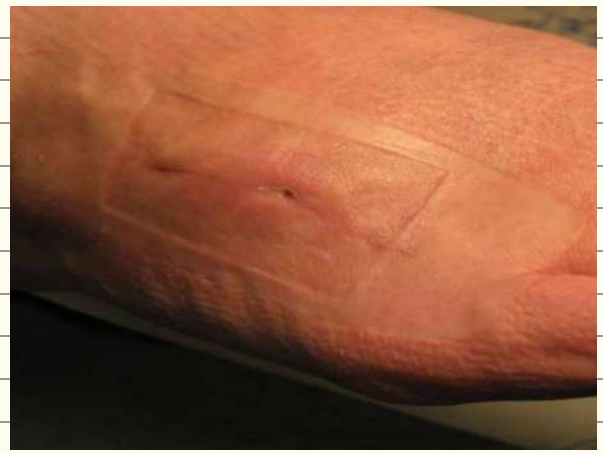\* \* Jalap root is !!  
drastic purgative





Which statement is false?

⇒ parathion moderately toxic.

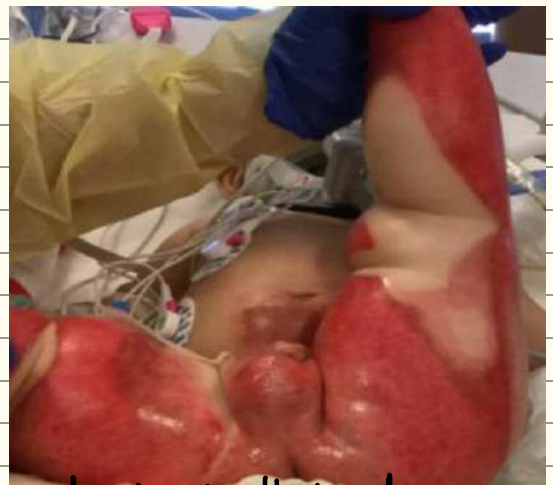

What is most appropriate next step?

application splint.

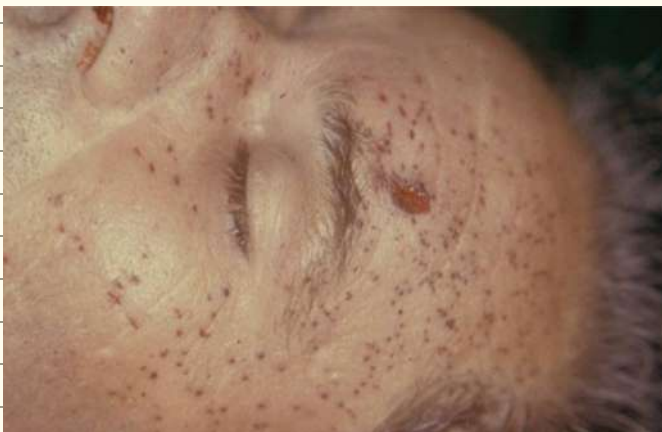

true about this picture?  
mainly neurotoxic.



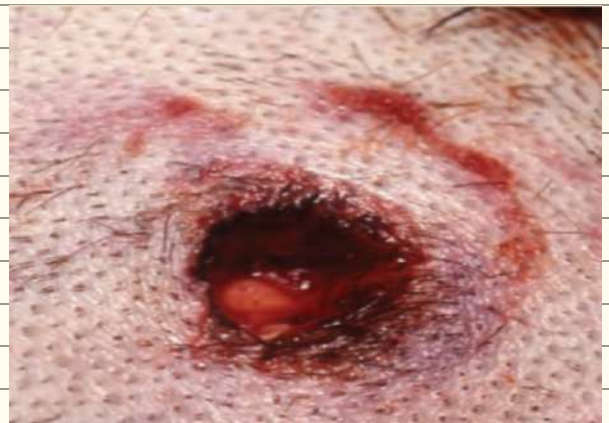best method to  
differentiate accidental from non  
accidental!!

⇒ sharply demarcated.



wrong statement!!

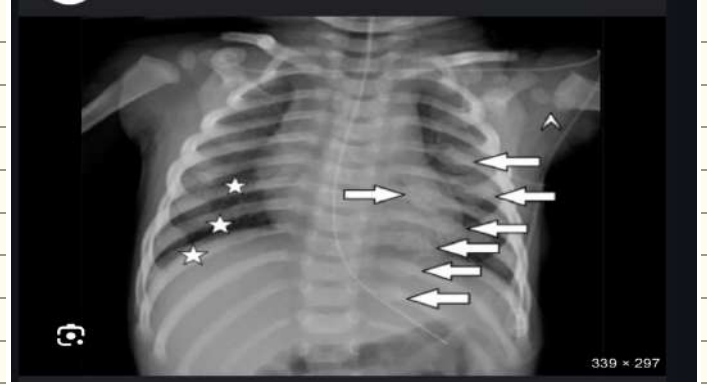
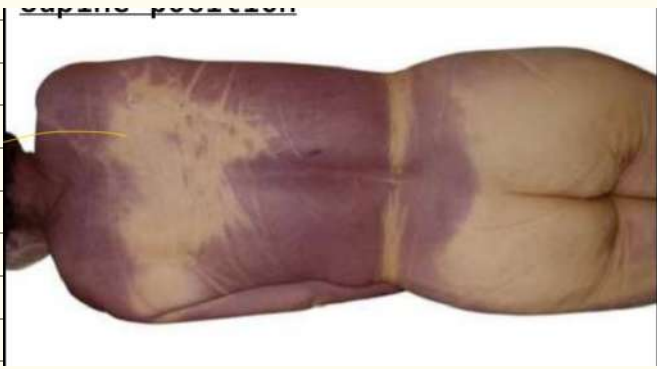firing from far distance.



true about this?

Contact firing.

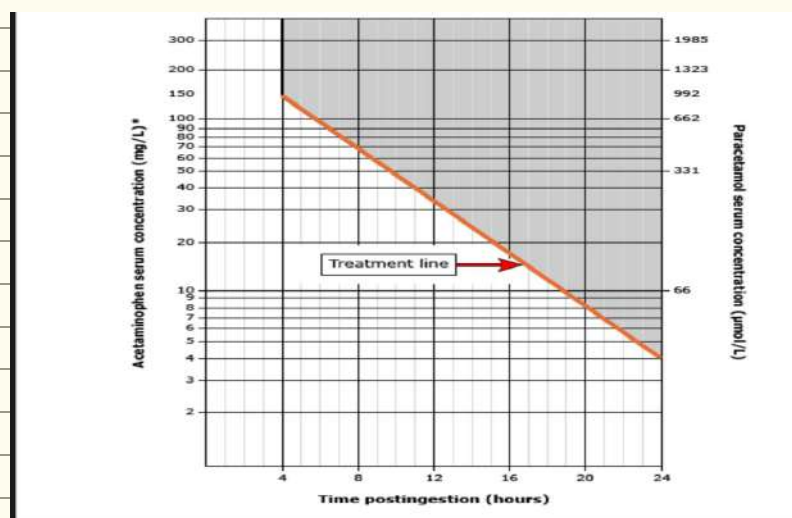




true about hypostasis  
 ⇒ fixed after 8h

6 year old girl come with her mother  
 and the mother said she fell  
 what is next step !!

⇒ Contact child service



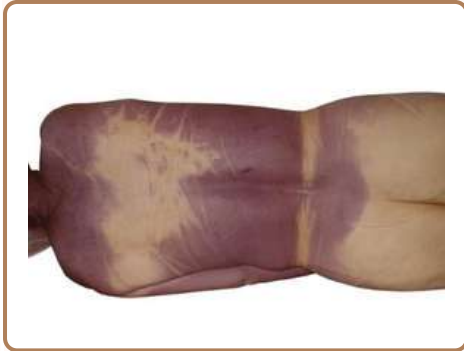this chart used for ?

✶ indication of NAC

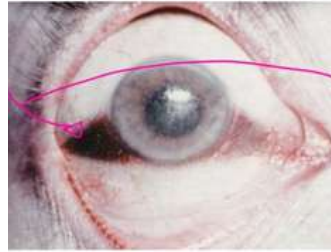


# Forensic & toxicology group C archive

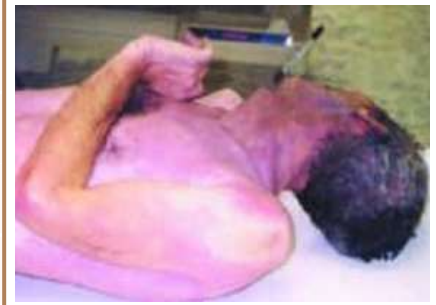Q1 :



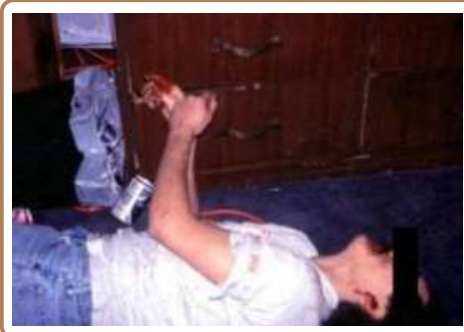Hypostasis



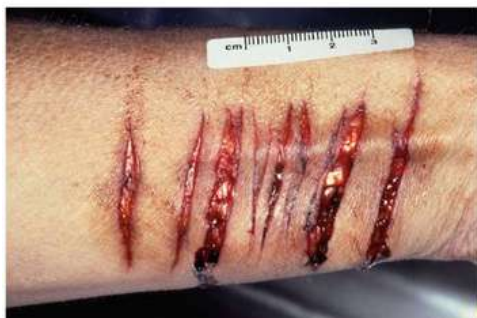Tach noire



Rigor mortis

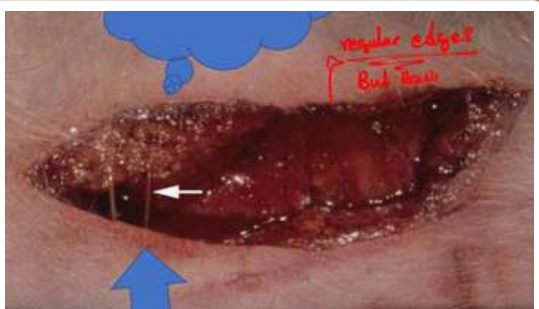


Q2 : .....?..??



Q3: One is true?

- A) suicidal, cut wound
- B) suicidal ,stab wounds
- C) accidental, cut wound
- D) accidental, stab wounds

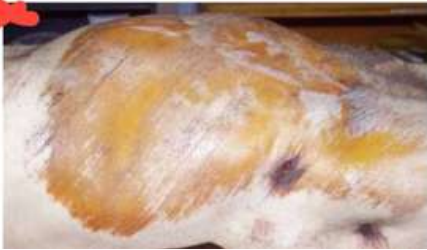

Q4 : One is true?

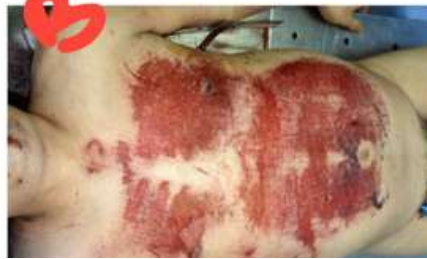- A) bridging tissue in cut wound
- B) bridging tissue in stab wounds
- C) bridging tissue in contused wound



A



B



Q5: One is true?

- A) a -am bruises b pm bruises
- B) a am abrasion b pm abrasion
- C) a am bruises b pm bruises
- D) a am abrasion b pm abrasions

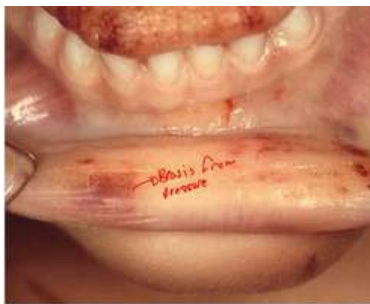

كانت صورة زيتها بس انه معلق حاله بالسرير

Q6:

وكان بده الصح

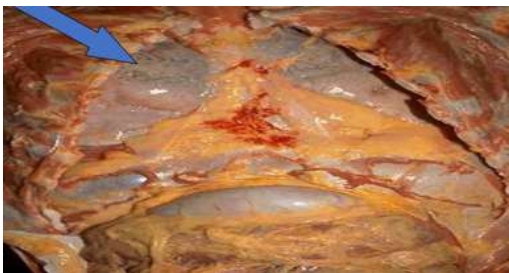- A) hyoid bone fracture common
  - B) petchial haemorrhage common
- وناسية باقي الخيارات



زي فكرة هاي الصورة وبده الصح

Q7:

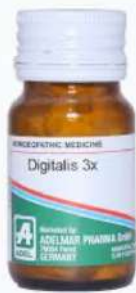- A) can occur even with soft material
- B) mostly accidental



Q8: one is false?

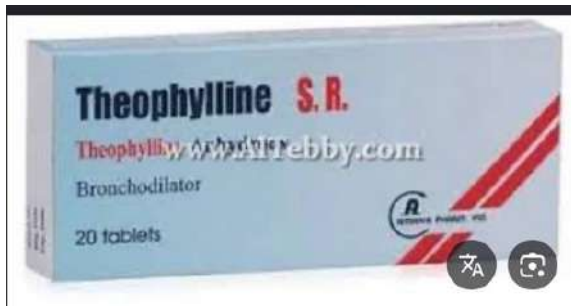- A) pale lung
- B) sure sign of drowning
- C) froth with characteristic smell
- D) rib marking





Q9: of the following is used chelating agents?

- A)iron only
- B)digitalis only
- C)both
- D)none



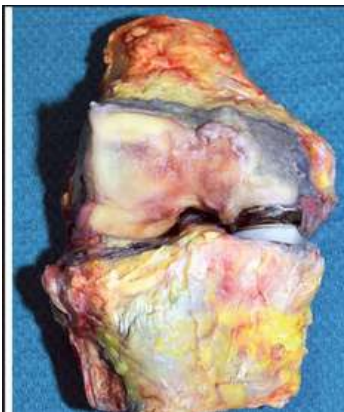Q10: one of the following used forced alkaline diuresis?

- A)all
- B)all except hcl
- C)thiophyllin only
- D)aspirin only

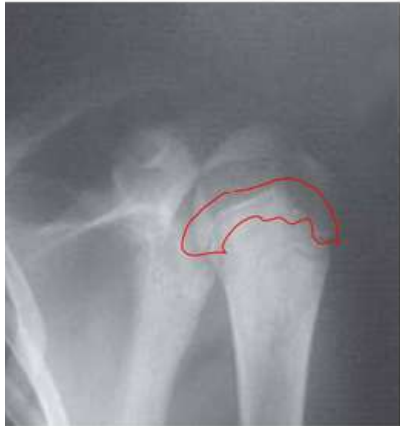

Q11: all of the following true except?

- A)atropin
- B)aspirin
- C)opioid
- D)organophosphrus



Q12: of identification?  
Medical records



**Q13: Age of this patient?**

- A)above 20**
- B)below 20**
- C)above 16**
- D)below 16**

A 20 years old male had rheumatic fever was admitted to hospital with severe dyspnea and palpitation, he had generalized edema and marked cyanosis. Echo was done revealing aortic stenosis. Treatment started but he died. Write death certificate

**Q14: one is true ?**

- A)manner of death accidental**
- B)mode of death cardiovascular failure**
- C)cause of death aortic stenosis**

كان عليها سؤال كيس طويل صراحة ناسيته شو كان بالزبط  
وكان بده الغلط

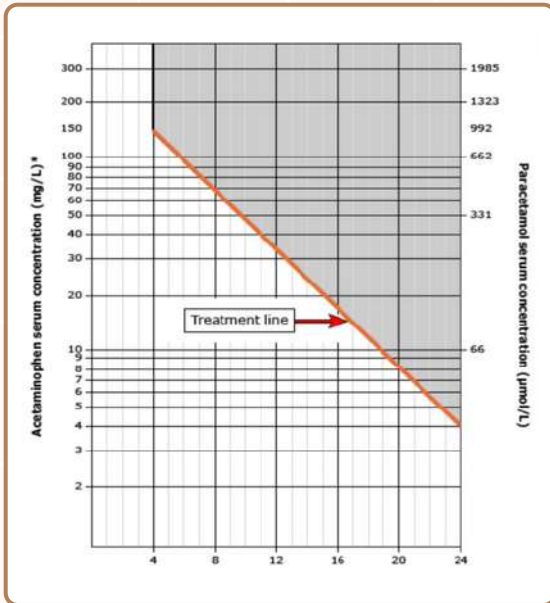
**Q15:**

- A)Type of anoxia is anemic**
- B)level of co above 70**
- C)red cherry asphyxia**
- D)the curve shift to rt**

**Q16 : One of the following not indicate chlid abuse?**

- A)corner fracture**
- B)knee abrasions**
- C)avulsion of metaphysis**
- D)lip frenulum**
- E)small circular burn in the back of hand**





Q17 : One is true?

A- At this line or above it we start NAC

B- we start treatment

C- starting liver transplant

D- starting hemodialysis



Q18: كان معها كيس طويل عن شخص يشتغل بالزراعة وشو اجراءات الطبيب معه والي كانوا انه وكمان عمل atropin and oxime الطبيب اعطاه gi decontamination

عشان يوقف pupil واستنى لحتى توسعت الالعلاج وكان بده الجواب الصح؟

بوافق الدكتور على كل شيء عمله A)

بوافقه على كل شيء عمله ما عدا انه اعطاه B) oxime

بوافقه على كل شيء عمله ما عدا انه اعتمد C) pupil على ال

كيس شخص اجى على الطوارئ خلال ساعتين kerson من استنشاقه

Q19 : شو الاجراء الصح؟

A)give strong analgesia

B)observe the patient

C)start emsis

D)activated charcoal

E)gastric lavage

Q 20: false about scorpion clinical pictures?

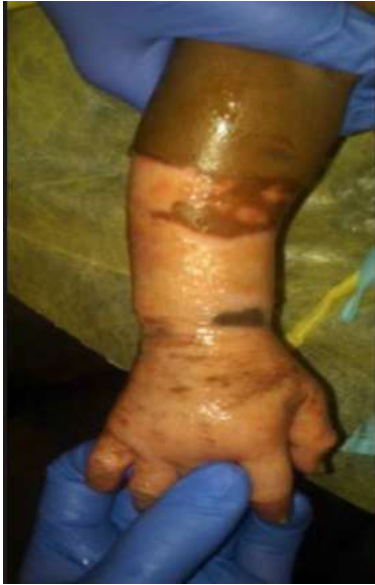A)pain and parathesia

B)tachycardia and hypertension

C)tachypnea

D)local leg swelling

E)hyperthermia



Q 21:

زي هاي تقريبا وبده الخطأ

A)no splash mark

B)geometric pattern

C)non accidental

D)vary in depth

Alcahol - ethanol

Q 22: smth about chronic alcoholism

Q 23:

withdrawal وسؤال عن ال





1) Some one has loss of consciousness we found obstruction of water heat vent pipe the cause of except?

- ☒ A) cerebrovascular stroke
- B) respiratory failure
- C) Dysarrhythmia
- D) Curve shift to left
- E) Anemic anoxia

2) - when there is methyl poisoning with no ethanol antidote available :

- ☒ A) Emesis
- B) Gastric lavage
- C) Hemodialysis
- ☒ D) Fomepiazole
- E) sodium bicarb

3) Activated charcoal

- A - enhance elimination of toxic only
- B - enhance absorption of toxic only
- C - decrease absorption of toxic only
- ☒ D - enhance elimination of toxic and decrease absorption

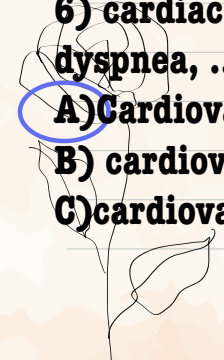

4) best hospital management for corrosive :

- A) Emesis
- B) Ac
- ☒ C) Secure the patient's air and endoscopy
- D) Milk and water

5- dry bite of this snake :

- A) Venomous
- B) Nonvenomous
- ☒ C) No poisoning or small

6) cardiac patient that comes with ischemic heart disease come with dyspnea, ..., but he died (death certificate)

- ☒ A) Cardiovascular failure due to MI due to IHD
  - B) cardiovascular failure due to IHD
  - C) cardiovascular failure due to IHD due to hypertension
- 
- 

7) what the most indication to make sure that child abuse burn (Pic)

- ☒ A) Pattern specific object
- ☐ B) Burn in forearm
- ☐ C) Small burn in the head

8- contusion that indicate child abuse (pic)

- ☐ A) Multiple at knee
- ☐ B) Small Contusion at head
- ☒ C) Multiple contusions with different healing stages

9)-head injury indicate child abuse (pic)

- ☐ A) Scalp hematoma with no other injuries
- ☒ B) Subdural and retinal hemorrhage
- ☐ C) skull fracture

10 - House in fire (pic) what poisoning:

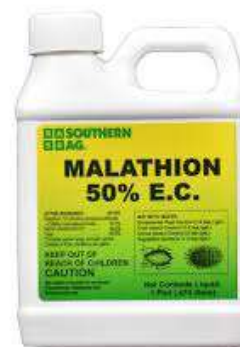- ☐ A) Co, cyanide
- ☐ B) Co only
- ☐ C) Cyanide only
- ☐ D) H<sub>2</sub>S, co
- ☒ E) H<sub>2</sub>S, co, cyanide

11) Primary side effect of acute ethanole toxicity C(11

- ☐ A ) hypoglycemia
- ☒ B ) respiratory failure
- ☐ C) Metabolic alkalosis
- ☐ D) hypercalcemia

12) )Wrong about pic?

- ☒ A) Very severe toxicity
- ☐ B) continue atropin unless pneumonia developed should be stoped
- ☐ C) SLUDGE muscarinic actions of drug





13) we found someone have metabolic acidosis with unknown causes?

A ) no toxic causes

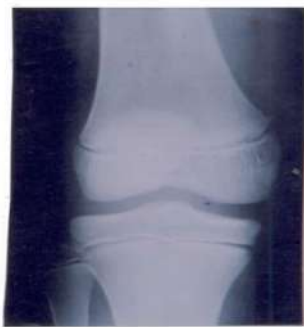B ) obtain blood sample for toxic analysis

C ) blood test if have history of addiction

14) Open disaster : 2

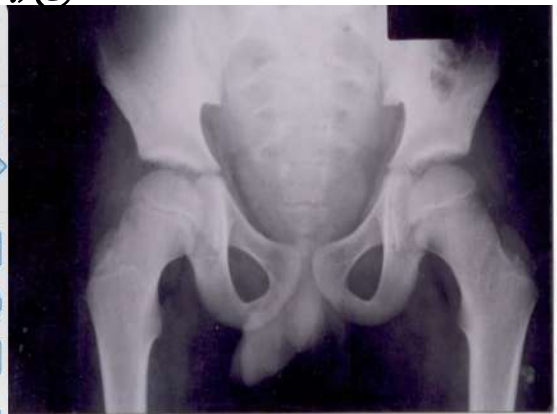

14) ③



X-ray of knee showing that the age is below 21 years due to nonunion of the distal end of femur and nonunion of proximal ends of tibia and fibula

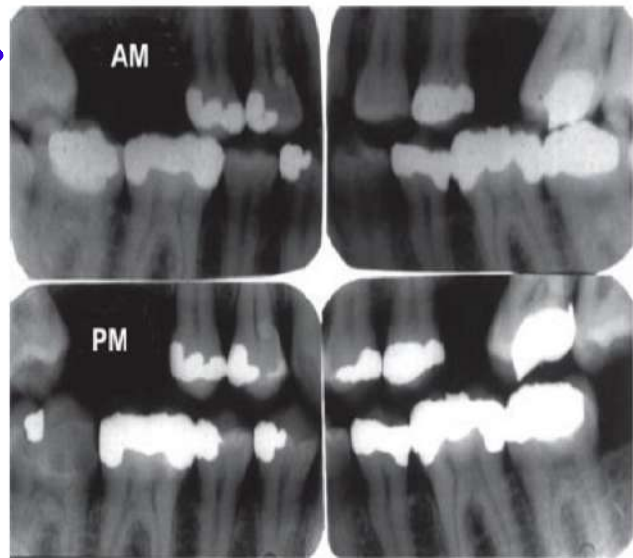
14) ④



X-ray of pelvis showing that the age is above 6 years due to union of the inferior ramus of pubis with the superior ramus of ischium , and below puberty due to nonunion of the 3 bones (pubis , ischium and iliac bones ) together at the acetabulum

15) Choses corect ID type of this pic

- A) Dental pulp dna
- B) Dental pattern**



16) What is the legal definition of abortion:

- A) expulsion of an embryo, viable, of 28 weeks of pregnancy
- B) expulsion of an embryo, before 24 weeks of pregnancy
- C) expulsion of an embryo, dead, of 28 weeks of pregnancy**
- D) expulsion of an embryo, viable or dead, of 28 weeks of pregnancy

17) Main mechanism of kerosine in rs

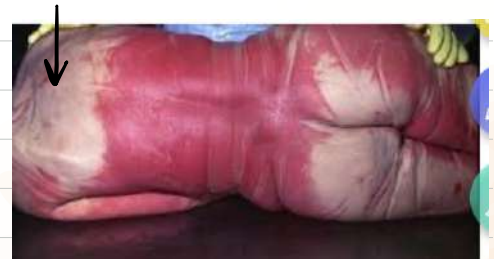- A) disrupt surfactant**
- B) chemical irritant
- C) pulmonary edema

18) priapism mean

Continous errection in male child cause by scorpion sting

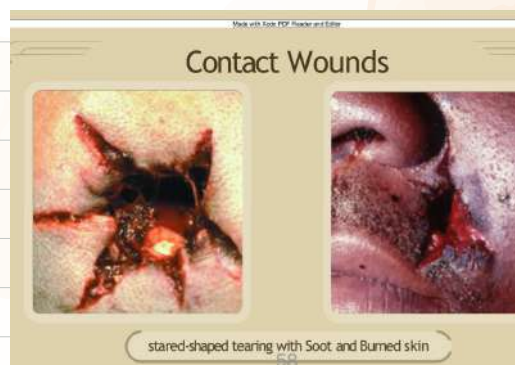-19) hypostosis picture) what is causing the arrow (on the A) white area )

- B) Algor mortis
- C) Flaccidity
- D) Cadveric
- E) Contact flattening**



21) firearm pic\* what is false:

- A) Intermediate distance**
- B) Stalliate shape
- D) Clothes internally
- (E) Breveled of bone** اتوقع كانت موجودة



stared-shaped tearing with Soot and Burned skin



20- fire arm pic

A) Multiple exit wound

B) Multiple inlet wound

22) pic of a firearm what the arrow presented

A) Abrasion chorl

B) Muzzle imprint

C) Blackining

D) Tattooing

23- صورة asphyxia chose wrong statement

A) Hypostosis in lower limb

B) Most common continuous around the neck

C) Unlikely to cause hyoid bone fracture

D) Commonly suicidal

24) Rumak mathew namogram :

A) Prediction of acetaminophen toxicity

25) peeling of skin

A) Immersion sign

B) Drowning sign

يوجد تكمة النيار



26- complication of acute ethanol poisoning that cause death commonly :

A) Metabolic alkalosis

B) Renal failure

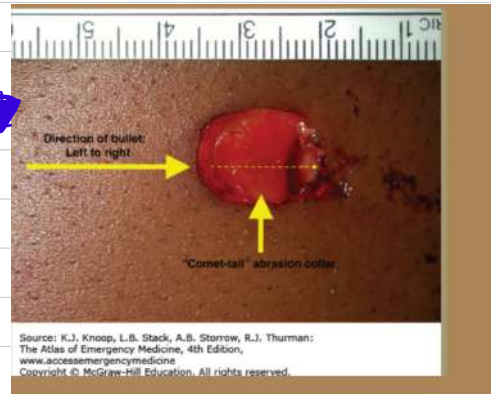
C) Respiratory depressive

27) pic of a wound

A) Am wound

B) Pm wound

C) Healed wound



28)- asphyxia chose wrong statement (hanging pic)

A) Hypostosis in lower limb

B) Most common continuous around the neck

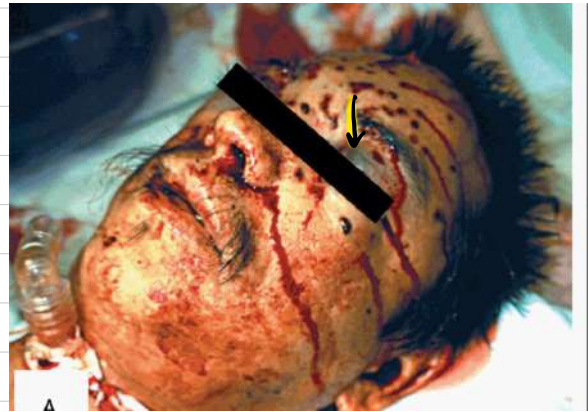C) Unlikely to cause hyoid bone fracture

D) Commonly suicidal

29) indicate to ?

A) basal skull fracture

raccoon eyes كانت واضحة اكثر





# **Mini-osce archive**

**Rouh-Group D**

## **Forensic medicine and toxicology**

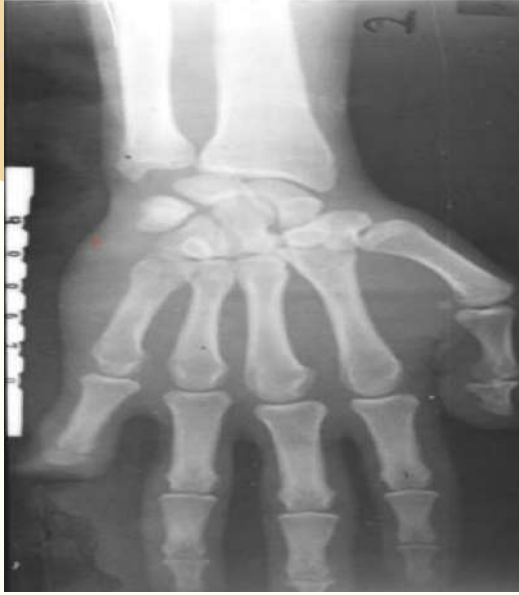**Done by Boshra Al-omoush**

**Abdelraheem alawneh**



## Identification;

### 1-X-ray for FEMALE,one is true:



**A)above 21**

**B)she can not married,under 18**

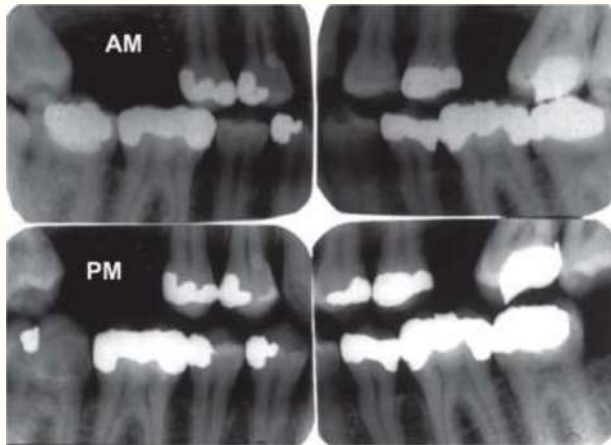
**C)she can not vote**

**D)can not estimate her age**

**E)Age of execution,If she makes Any crime needs execution**

**Answer:E**

### 2-Use it in identification for?



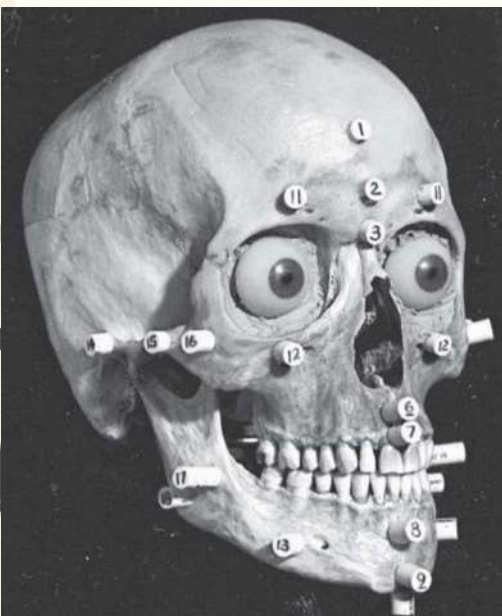
**A)positive person identification**

**B)age of person**

**C)sex of person**

**Answer:A**

### 3-Method used in identification:



**A)facial reconstruction**

**B)skull reconstruction**

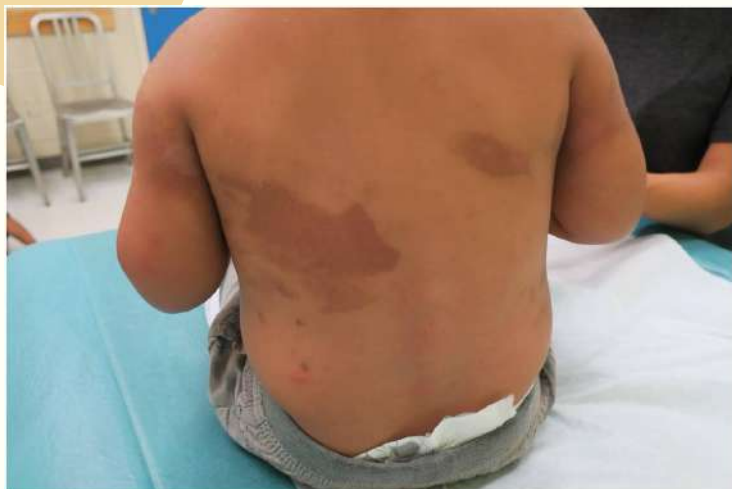**C)skull impostion**

**Answer:A**



## Child abuse ;

**4-Child with this truma coming to you after 5 days ,  
Telling authorities is:**

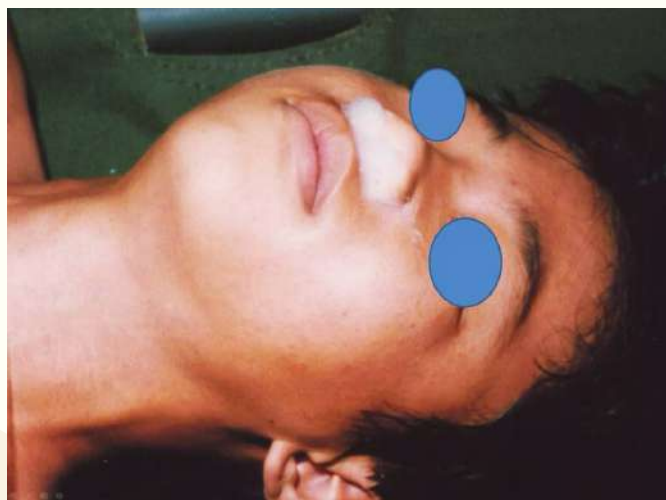

- A)elective**
- B)forbidd**
- C)depends on medical state  
Of child**
- D)Mandatory**

**Ansewer:D**

## Asphyxia&Drowning;

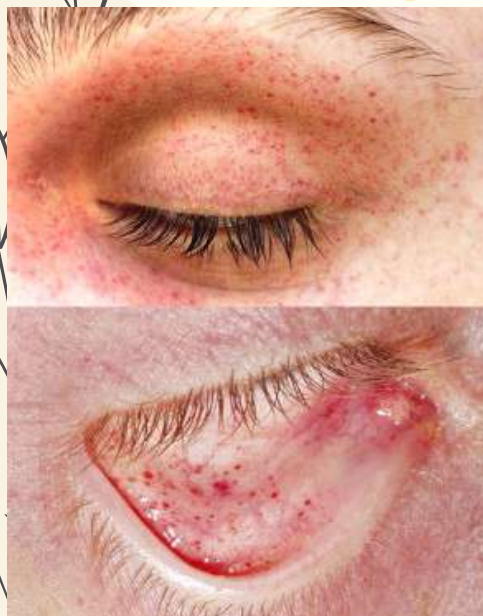**5-One is true about this sign:**



- A)probably sign of drowning**
- B)once wipe it,will not appear**
- C)it has odour**
- D)its due forcful deep  
inhalation under water**

**Ansewer:D**

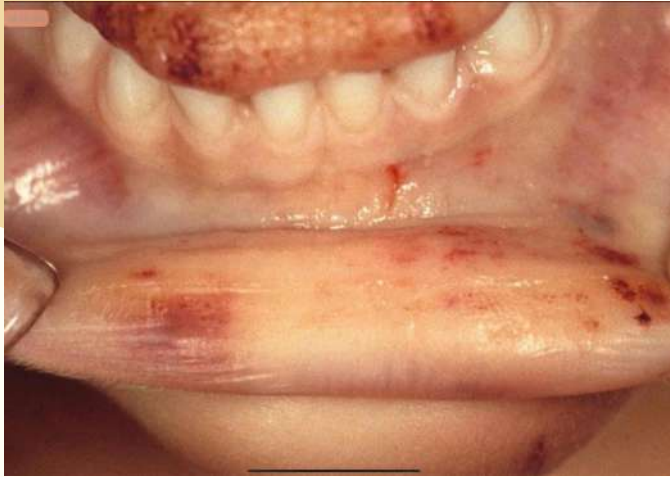**6-one is false regarding sign:**



- A)slower the death,less promenant apperance**
- B)obvious in fair skin**
- C)can be seen in vesicra and pleura**
- D)can be caused by another pathologic non-  
asphyxial causes**
- E)its mostly specefic for manual strangulation**

**Ansewer:**

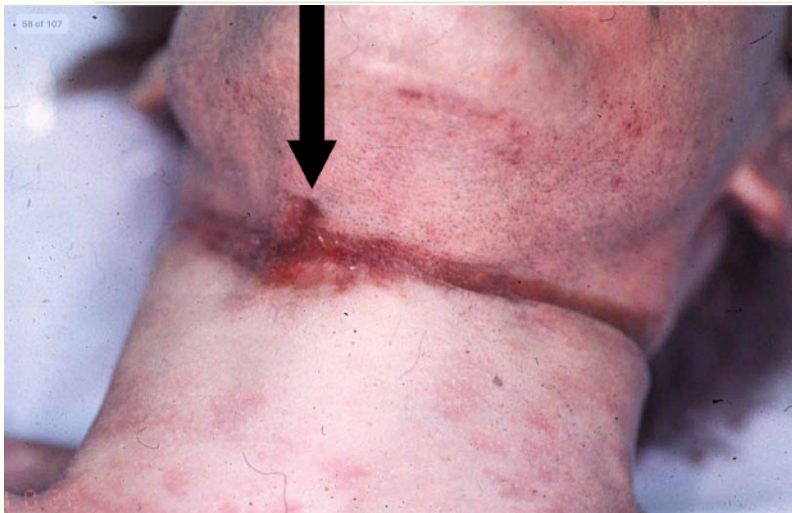**7-this finding seen with other sign mentioned(petechial hemorrhage),mechanism of these signs?**



- A)compression**
- B)cut**
- C)non of the above**

**Answer:A**

**8-True about the type of asphyxis:**

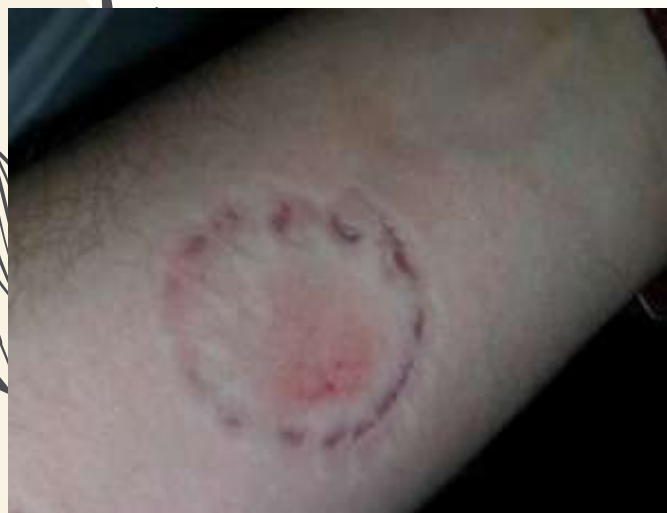

- A)hyoid bone fracture is common with hanging**
- B)ligature mark seen in n strangulation as homcidal manner**
- C)damage and contused to underlying tissue**
- D)commonly seen in manual strangulation**

**Answer:**

**Wounds;**

**9-mechanism ?**

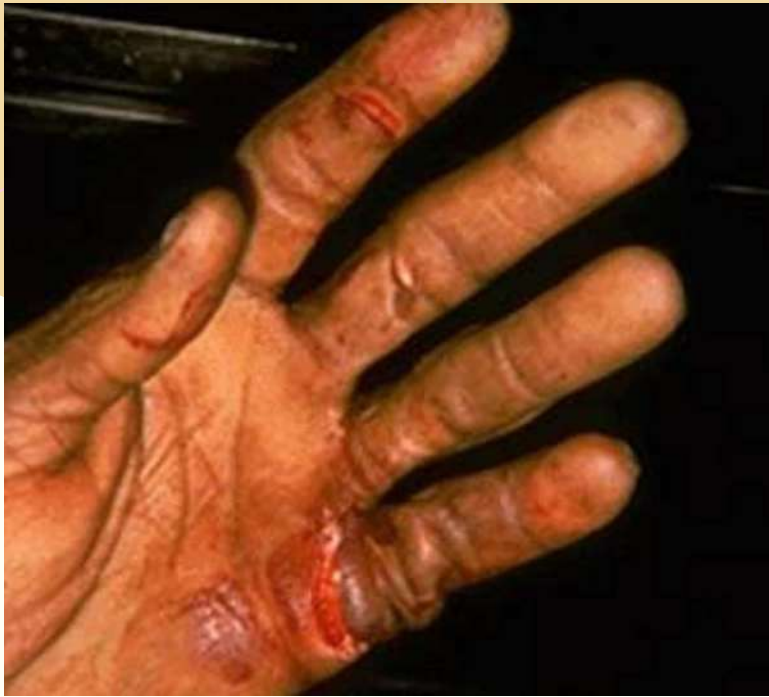

- A)pressure**
- B)negative pressure and suction**
- C)cut**

**Answer:A**



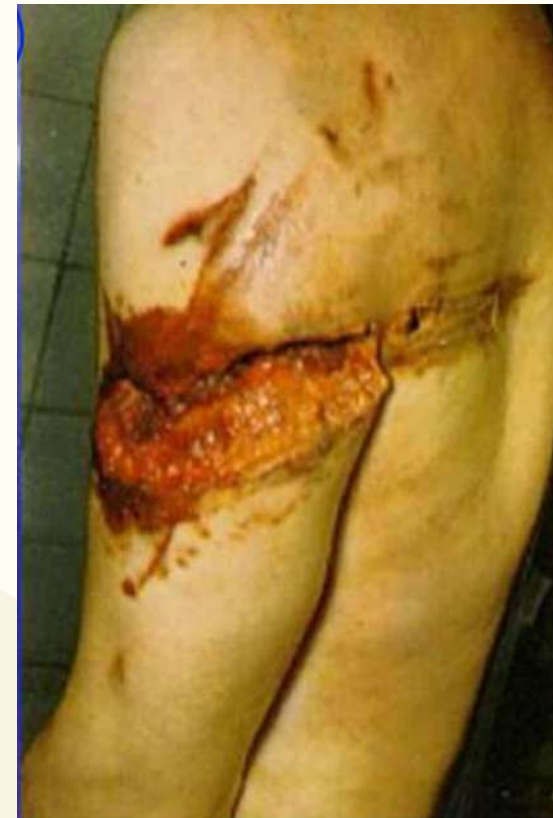## 9-Type of the wound?



- A)defensive wound**
- B)offensive wound**
- C)fabricated wound**

**Ansewer:A**

## 10-What the correct to be included in PRIMARY REPORT;

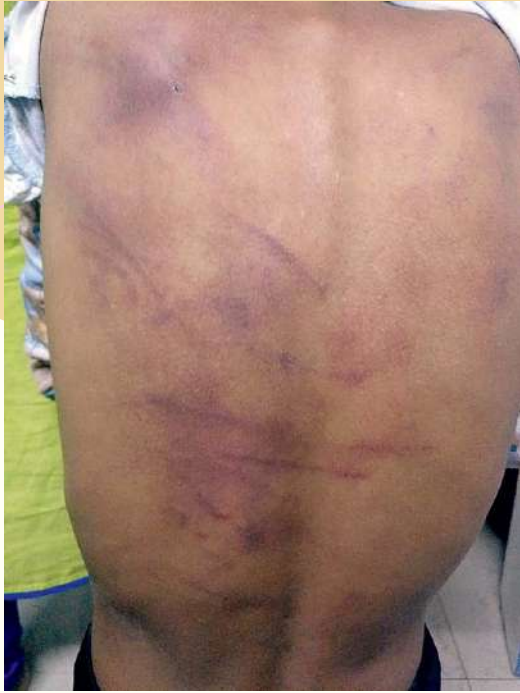

- A)incubatory time above 21 days**
- B)Dangerous wound**
- C)two seprated wounds**
- D)intermediary wound**
- E)happened from left to right**

**Ansewer:E**حسب جواب الدكتور مع انه مش مقنع

أهـاد الجرح وبـنفس  
المكان بس كان مـخيط

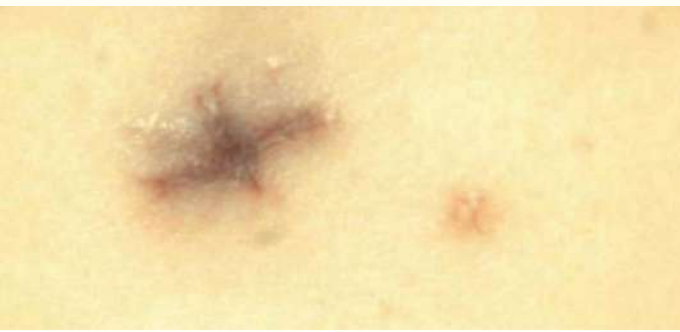**I 1-it caused by;**



- A)elongated blunt object**
- B)sharp force**
- C)puncture blunt object**

**Ansewer:A**

**I 2-Type of wound:**

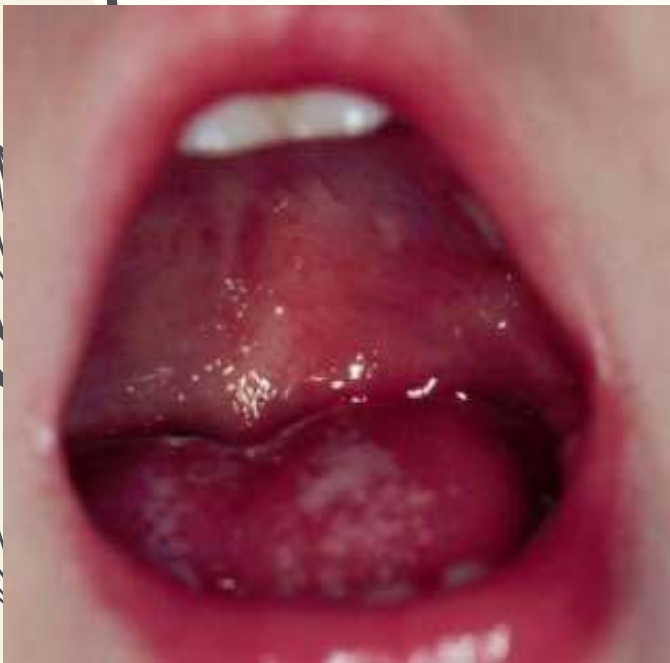

- A)stap injury**
- B)puncture patterend injury**
- C)nail injury**

**Ansewer:B**

**Corrosive;**

**I 3-Child ingested caustic agent and came after 5 days , managemnt?**



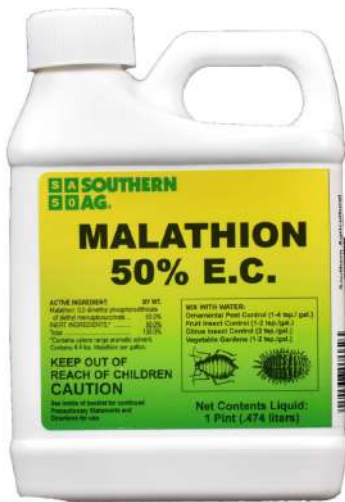- A)gastric lavage**
- B)activated charcol**
- C)emsis**
- D)benficial steroids**

**Ansewer:D**



**OPI;**

**14-Smell of?**



- A)onion**
- B)better almond**
- C)garlic**

**Answer:C**

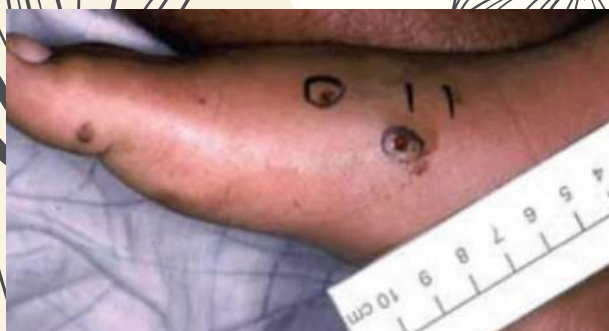**15-Case study;45 years old , male , farmer .. his family brought him to hospital unconscious after his family saw him sprays by liqiud in farm-- presentation : unconscious,pulmonary secretion,lacremation,miosis Vital sign;respiratory rate=30,heart rate=45,oxygen saturation=88%.. all of the following used in managemnt the patient , except?**

**Answer:E**

- A)IVfluid**
- B)Atropine**
- C)Pralidoxime**
- D)oxygen**
- E)gastric lavage,emsis,AC**

**Snake bite**

**16-The best managment?**



- A)Incision and oral suction**
- B)Cryotherapy**
- C)Tourniquets**
- D)splint**

**Answer:D**

## General toxicology and treatment

**17- 26 years old female ingested her father's pills (antiplatelet drug) in large doses and came to hospital after 6 hours , the best management:**

**A)forced alkaline diuress**

**B)emsis**

**C)hemodialysis**

**D)activated charcol**

**E)gastric lavage**

**Ansewer:A**

## Abortion;

**18-Jalap planet used in :**



**A)purgative in abortion**

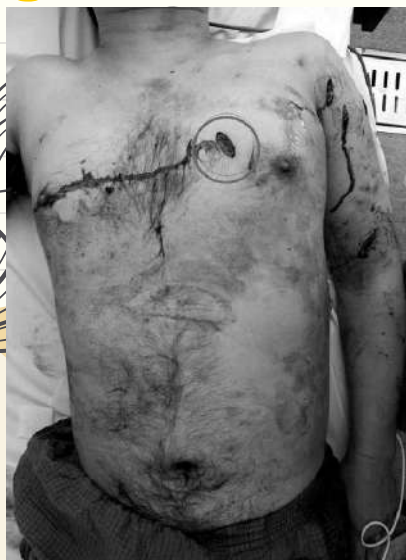**B)theraputic abortion**

**C)poisoning**

**Ansewer:A**

## Death certifcate;

**19-How to write death certifcate regarding this case ,family brought him died in emergency room**



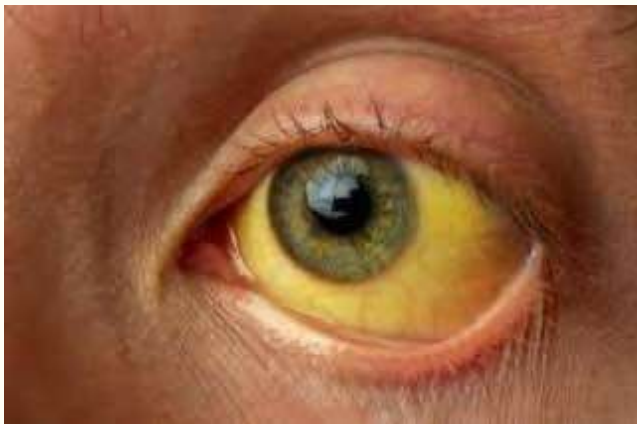

- A)emergency doctor writes its due to hemorrhagic shock**
- B)forensic doctor writes its the manner of death is circulatory failure**
- C)emergency doctor writes it quickly due to aggrasive behavior of family**
- D)emergency doctor referes the case to forensic medicine and writes its due circulatory failure**
- E)forensic doctor by external examination writes its due circulatory failure due to hemorrhagic shock due to stapping**

**Answer:**

**Paracetamol;**

**20-the method used in:**

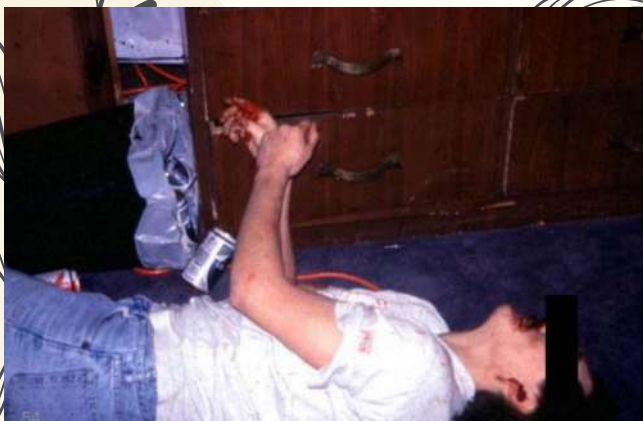

- A)NAC**
- B)gastric lavage**
- C)hemodilysis**
- D)emsis**

**Answer:A**

**Death and Postmortem changes**

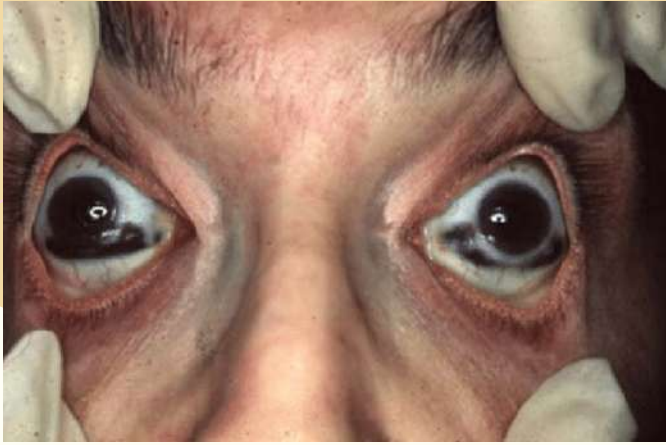
**21-the body is warm,the death time:**



- A)3-8 hours**
- B)earlier than 3 hours**
- C)more than 8 hours**
- D)more than 36 hours**

**Answer:B**

**22- happened in ;**



- A)early PM,its called tache noire**
- B)petechial hemorrhage**
- C)late PM**

**Answer:A**

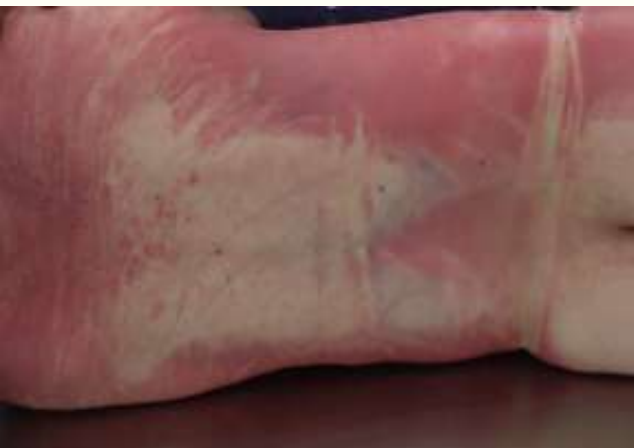**Co poisoning**

**23-In cold december night,5 family members came to hospital with weak muscle,headache after they uses kerosene heaters..what is correct?**

- A)its due influnza**
- B)antidote is oxygen**
- C)food posioning**

**Answer:B**

**24-one sentence is TRUE:**



- A)Deoxygeneted blood level increases**
- B)curve shift to right**
- C)Anemic hypoxia**

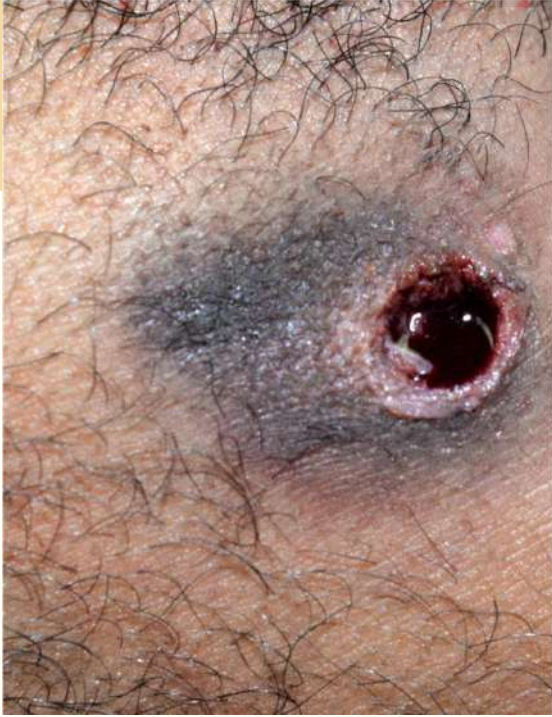**Answer:C**





## **Firearm injury;**

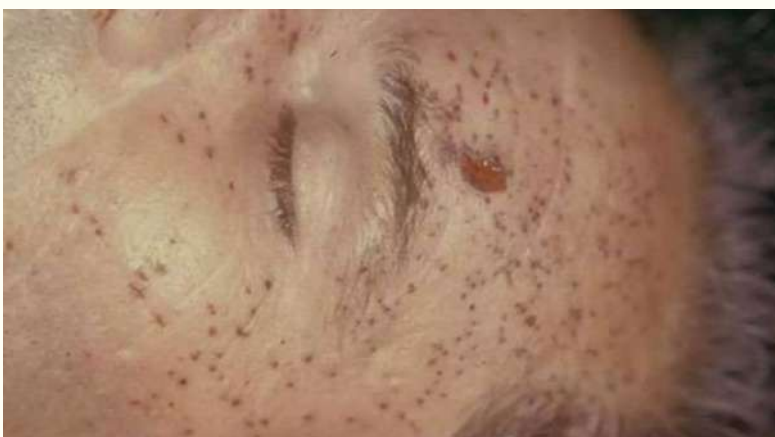**25-one is TRUE regarding fire mark**



- A)Direction of firing**
- B)all firing mark can be wiped**

**Ansewer:A**

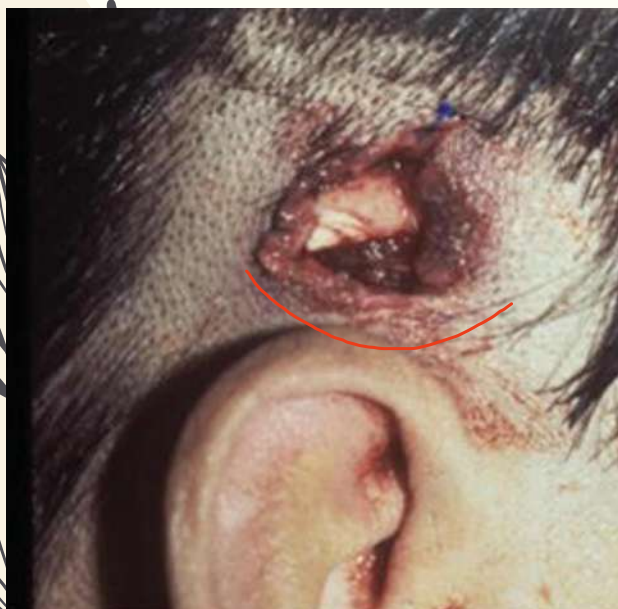**26-one is FALSE:**



- A)from intermediate distance**
- B)firing mark can not be washed**
- C)bullet wipe can be seen from this distance**
- D)the outlet is regular with this distance**
- E)the shooting is mostly perpendicular**

**Ansewer:D**

**27-Firing arm in temporal bone**

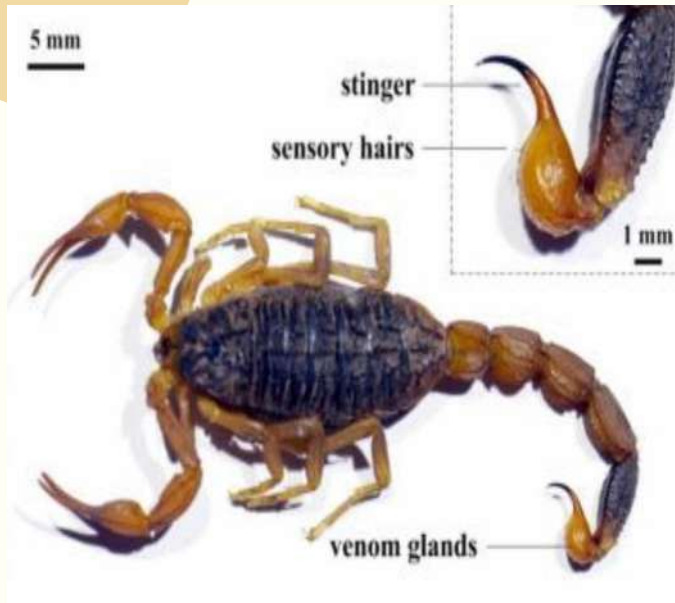


- A)stelele shape is specific for entery wound**
- B)external beveling is founded in entery wound**
- C)the cause of death is severe hemorrhage**
- D)lower half of injury imprint abrasion**

**Ansewer:D**

## **Animal poisoning;**

**28-The toxin here is:**



- A)desending paralytic**
- B)neurotoxic**
- C)vasulotoxic**

**Ansewer:B**

## **Methanol;**

**29-mechanism of action of alcohol in methanol**

- A)enhance methanol metabolite**
- B)decrease methanol metabolite**
- C)increase absorption of methanol**

**Ansewer:B**





# Quiz

## 1- The best method in GI decontamination?

- A) emesis
- B) AC\*\*
- C) Gastric lavage
- D) Gut dialysis

## 2- Histiation mark is?

- A) cut wound\*\*
- B) fabricated wound
- C) defensive wound

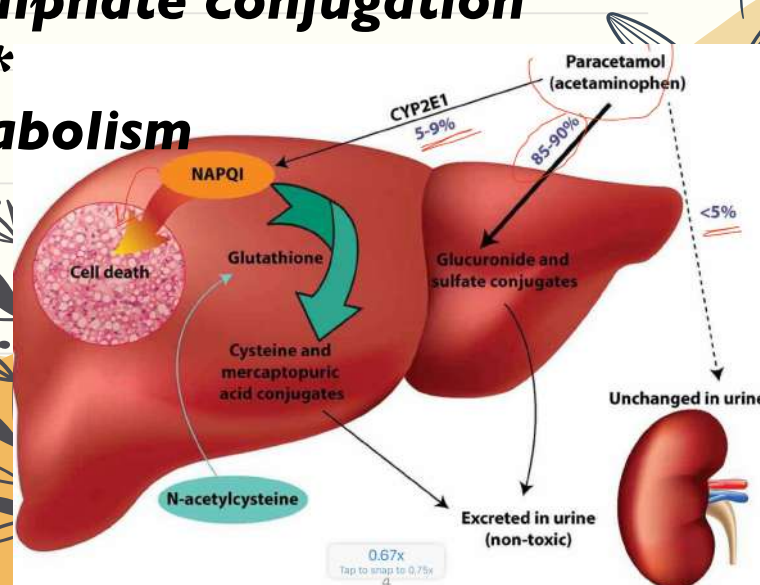
## 3- unreliable historians?

- A) victim suicide \*\*
- B) mental retardation
- C) all poisoned patient
- D) children
- E) relatives

## 4- mechanism of action of NAC?

- A) inhibit binding to hepatocell
- B) increase glucuronide and sulphate conjugation
- C) enhance kidney excretion\*\*
- D) decrease paracetamol metabolism

كثير ناس لخبطت بهاد السؤال



**5-Emphysma aquosum is ?**

- A)sure sign of drowning\*\***
- B)probably sign of drowning**
- C)not a sign of drowning**

**6-geese skin is?**

- A)drowning**
- B)immersion\*\***

**7-all of the following are characteristic for non-**

- A)no splash marks**
- B)sharply demarcated**
- C)variable burn depths\*\***

**8-true about paracetamol**  
**Hepatotoxic**

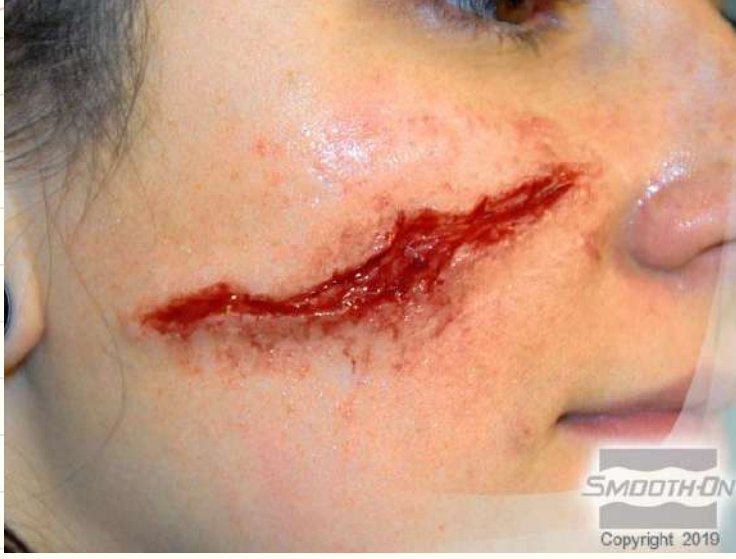**9-false statement:**

**Patients always correctly name of the drug they**



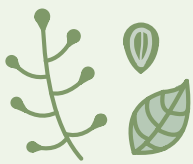

## Primary report



كانت صورة قريبة من هاي وجوابها جرح قطعي مع خدش كان وعلى الوجه وباقي التفاصيل  
...





# Forensic Archive (C)



1-What is the legal definition of abortion:

- A)expulsion of an embryo, viable, of 28 weeks of pregnancy
- B)expulsion of an embryo, before 24 weeks of pregnancy
- C)expulsion of an embryo, dead, of 28 weeks of pregnancy
- D)expulsion of an embryo, viable or dead, of 28 weeks of pregnancy

Answer: C

2- An old man had **primitcarb** poisoning (which is a carbamate), he suffered from dyspnea and other symptoms less than 24h which one of these statements is true:

- a) give him oximes as soon as possible
- b) don't give oximes
- c)give oximes only when the condition is severe

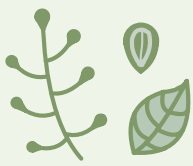Answer: B

3-a Palestine viper has bitten Ali, and Noah tried to suck the venom through the bite mark, 3 hours later symptoms appeared on Ali so Noah took him to the ER, the physician gave both Ali and Noah antivenom as he believed it's a prophylactic measure:

- a)Physician is right
- b)Physician is wrong, he shouldn't have given Noah as the antivenom has no effect nor Ali as he only has local effect
- c)Physician is wrong, he shouldn't have given Noah as the antivenom has no effect on him but giving to Ali is right
- d)Physician is wrong as Noah is asymptomatic

Answer: C





#### 4-What's false concerning wounds:

Blackening around the wound isn't related to the **distance** of firearm.

#### 5-What's the correct answer about target site for corrosive damage : (السؤال) (محدد انه المدة كانت قصيرة)

We can see esophagus and stomach by hot **endoscopy**

#### 6-Baby came to ER, what should you do:

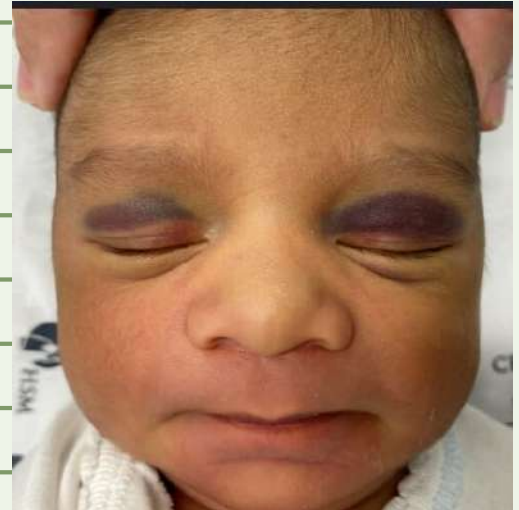A)Nothing, the baby is well

B)Monitor the baby

C)You should take CT images for the skull

D)Caused only by direct blow to his eye

Answer:C

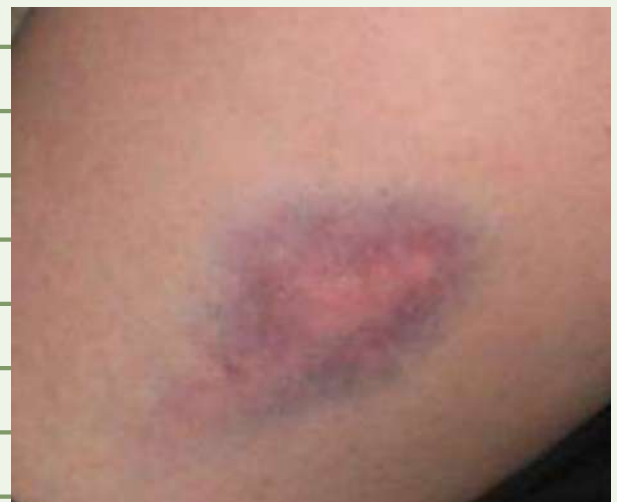

#### 7-What's true about this bruise in a dead patient:

A)the colour of bruise determines the accurate time of death

B)Bruise indicates undergoing physical pressure and we have to transfer him to the forensic medicine

Answer:B



(صورة تقريبية لأكثر من  
كرمة)



**8-Picture shows a child, who misses his classes and has erratic behavior:**

A) physical abuse, should do more investigation about the family home condition

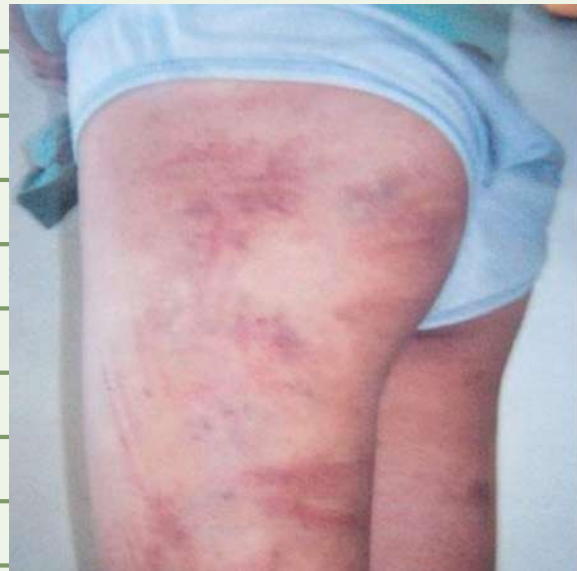B) his abuse is more of physical more than sexual

C) accidental injury

D) his abuse is more of psychological than physical

E) his abuse is more of emotional than physical

Answer: A



(صورة تقریبه)

**9-A man was found dead near the fireplace in his farm what's the wrong assumption:**

It's definitely suicide (it could be accidental)

**10-a man took a long shower, and the water heater was on and he was later found dead in the shower, what's the correct answer:**

A) Suicide

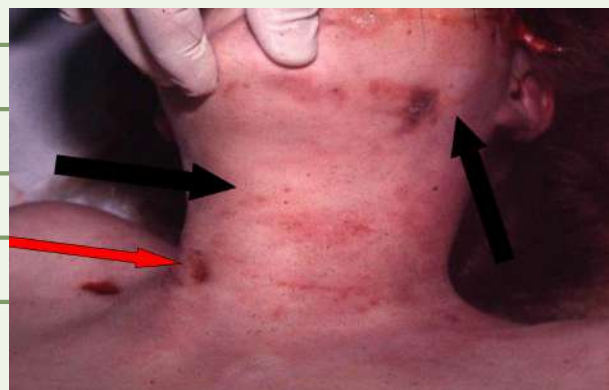
B) Cyanide poisoning case

C) O<sub>2</sub> dissociation curve shifted to the left

Answer: C

**11-Choose the correct answer :**

Hyoid bone fracture is most likely involved







**12- When to stop giving atropine to a person who has been poisoned:**

A) When **respiratory** secretions are cleared

B) When all manifestations stop

C) Change in pin point pupil size

Answer: A

**13- Pic of dead man whose neck and upper half of his back was tensed & his head was elevated:**

A) cadaveric spasm

B) rigor mortis

C) flaccidity

Answer: B

**14- As shown in this picture, choose the case that doesn't cause it:**

Throttling, CO poisoning, haemorrhage, hanging

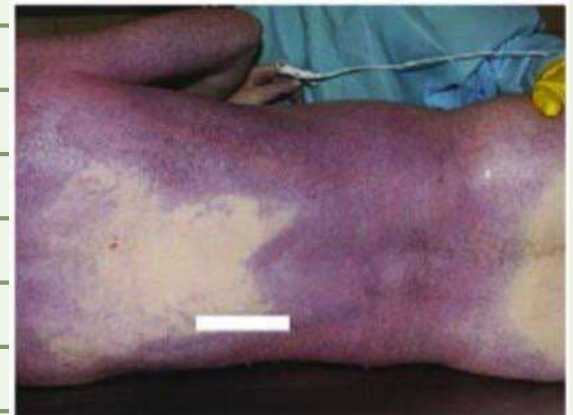A) all except co poisoning

B) all except hanging

C) All

D) all except haemorrhage

Answer:





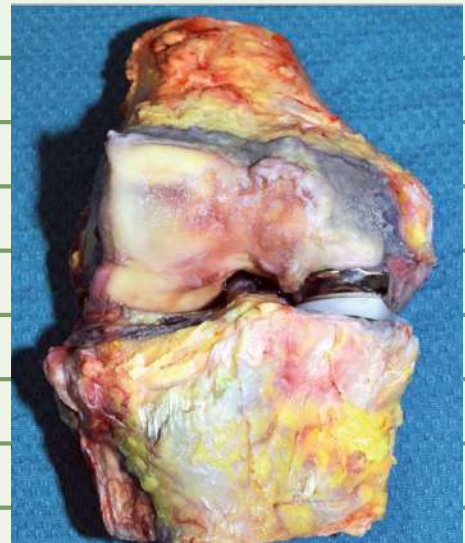15- This person could be identified by:

A) DNA

B) X-ray

C) Medical record

Answer: C



16- choose the right answer

A) closed mass disaster

B) open mass disaster

C) closed open mass disaster

Answer: A



17- A 20 years old male with rheumatic fever was admitted to hospital with severe dyspnea and palpitation, he had generalized edema and marked cyanosis. Echo was done revealing aortic stenosis. Treatment started but he died. Write death certificate:

السبب المباشر للوفاة : هبوط حاد بالدورة الدموية

المرض الاصل: حمى روماتيزمية

الحالة المرضية: تضيق في الصمام الاورطي



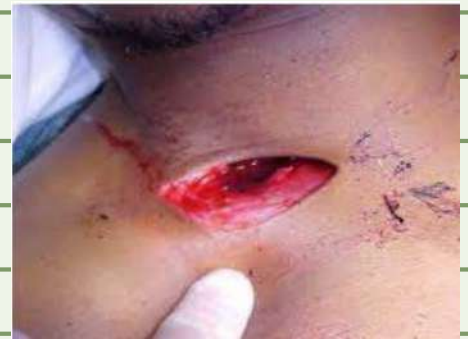**18-A man came to ER poisoned by ethanol after 1 hour, what is the correct measure:**

- A) IV fluid
- B) gastric lavage
- C) emesis

Answer: A

**19-Picture shows:**

Stab wound



**20-man came with chronic constipation what's the poisonous material that he was exposed to?**

- A) chronic lead toxicity
- B) Paracetamol toxicity
- C) Arsenic toxicity

Answer: A

**21-Pic of yellow eyes (jaundice), a man ingested a large amount of paracetamol, what should you do:**

Give antidote and treat the liver injury

**22- A case of acute ethanol poisoning, what is the correct answer:**

Give Naloxone





**23-Presentation that is correct concerning methanol:**

Snow storm appearance

**24-A clean stab wound in chest, that is 5cm wide, 2cm deep, directed downwards, the victim was unable to struggle. Choose the correct answer (الضحية ما كان عنده مجال للمقاومة)**

A)homicidal

B)accidental

C)suicide

Answer:

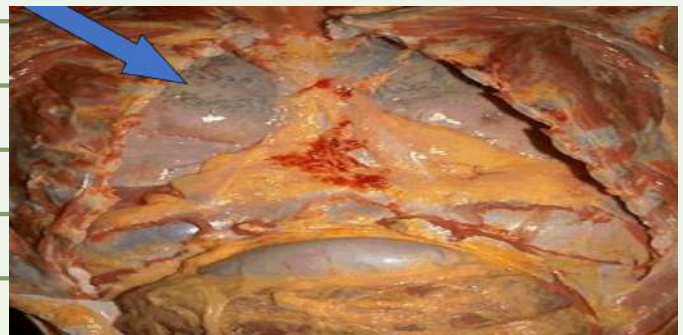**25-Pic shows emphysema aquosum, choose the wrong answer:**

A)Shows rib markings

B)Lots of froth

C)Has certain odor

Answer: C



**26-Regarding acidification of urine for amphetamine, choose the wrong answer:**

A)complicated by metabolic acidosis

B)not used nowadays

C)significantly enhances toxin removal

D)done on weak bases

Answer: C

بسم الله الرحمن الرحيم

ارشيف الشرعي

Done by : Eiman Alrfou & Afnan bassam

MCQ questions

Q1. uncontrolled hyper emises gravidum indicate :

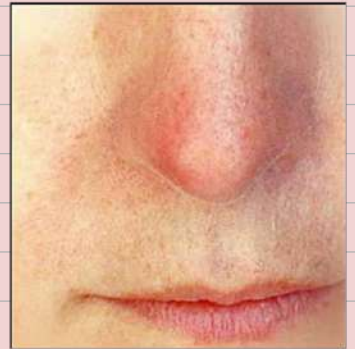- A. Spontanoues abortion
- B. Theraputic abortion
- C. Illegal abortion
- D. Criminal abortion

Answer : B

Q2. Which one of the follwing is true about this picture:

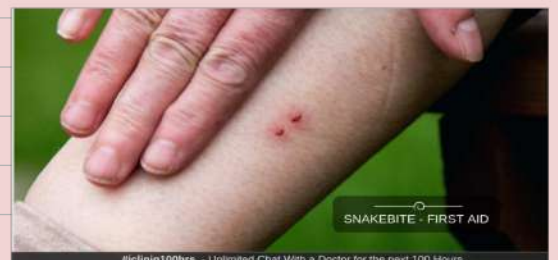- A. Acute alchol intoxication
- B. Rinorrhea
- C. Rhinophyma

Answer: C



Q3. The patient in this picture has a "snake bite" all of the follwing measure can do except :

- A. apply ice on the site of bite
- B. Immobilize the injured part of the body



#icliniq100hrs - Unlimited Chat With a Doctor for the next 100 Hours

C. Fashion a splint out of any rigid object

D. avoid walking at the site of injury

Answer : A

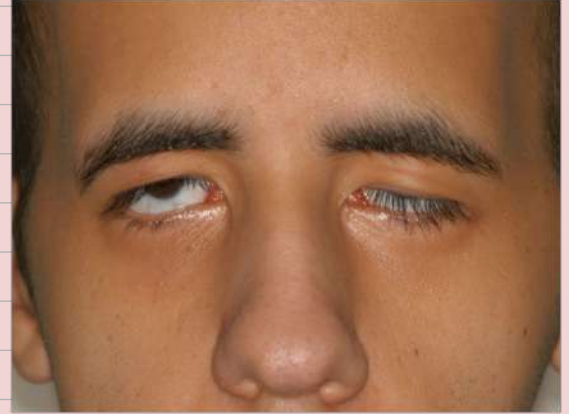Q4. The following manifestaion caused by :

A. Bite from copra

B. Bite by palestinian snake

C. Bite frome the viperidae familiy

D. Caused vasculotoxic effect mostly



Answer : A

Q5. Which of the follwing about this device true:

A. Used in paient with co2 toxicity

B. Used when level of oxygen below 10%

C. Used 100% oxygen at normal atmospheric pressur

D. 100% oxygen indicated in pregnancy ,coma and myocardial ischemia



Answer : D

Q6. Case study about methanol ..... which of the follwing drug not indicated

In methanol toxicity:

A. Hemodialysis

B. 4 metyl pyrazole



C. Ethanol

D. Sodium bicarbonate

E. calcium gluconate

Answer : E

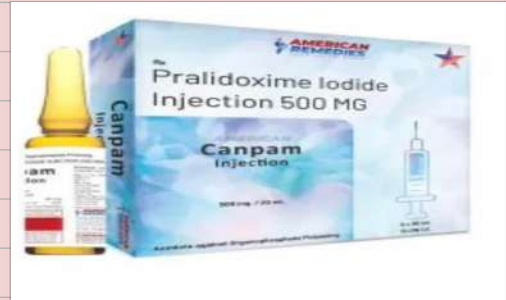Q7. One of following is mostly true :

A. Used in malathion before 48 hour

B. Used in malathion and carbamate

C. Used in malathion after 48 hour

D. Used in carbamate before 48 hour



Answer : A

Q8. One of the following is true about picture :

A. Patent print

B. Latent print

C. 3d print

D. Plastic print

Answer : B



Q9. The method of identification used in this picture :

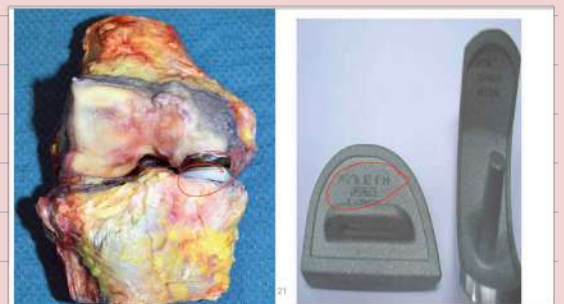A. Dental identification

B. age estimation

C. X ray

D. Medical record

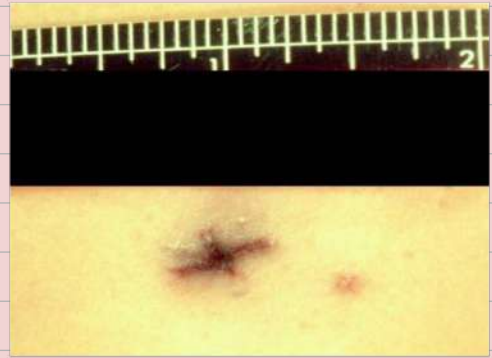
Answer : D



Q 10. This injury most likely considered :

- A. Penetrating wound
- B. Transfixing wound
- C. Perforating wound
- D. Pattern wound

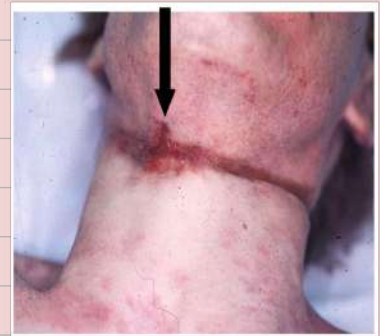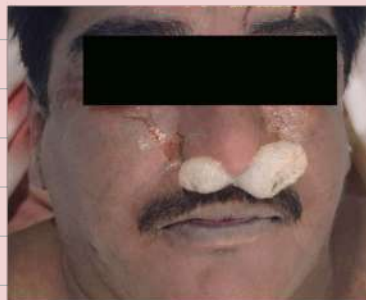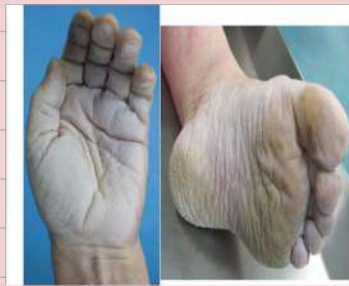Answer : D



Q 11. Chose the correct answer :

- A. immersion, froth, strangulation
- B. Drowning , froth , strangulation
- C. Immersion, froth , hanging
- D. Drowning , froth, hanging

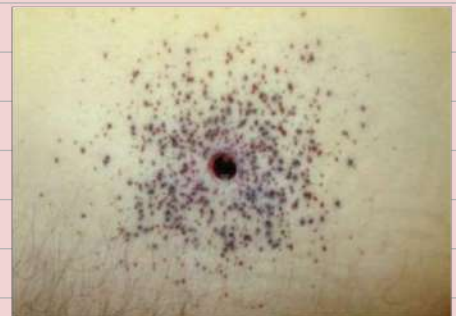
Answer : A



Q 12. The distance of this firearm injury :

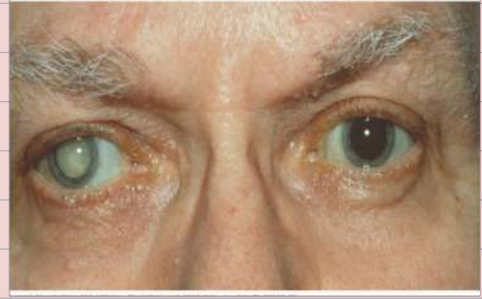- A. Less than 6 m
- B. Less than 1 m
- C. Less than 6 Km
- D. More than 3 m

Answer : B



Q 13. This effect mostly due to :

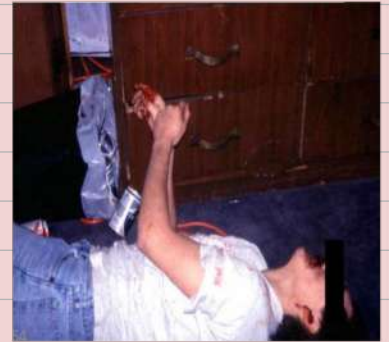- A. Simple blunt object
- B. Simple sharp object
- C. Dangerous blunt object
- D. fatal blunt object



Answer : C

Q 14. This picture show "cadaveric sign" the estimated time of death :

- A. More than 8 hour
- B. Less than 6 hour
- C. More than 36 hour
- D. Less than 3 hour early

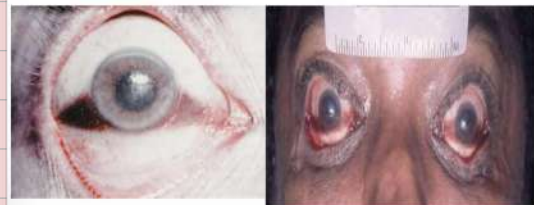


Answer: D

Q 15. Chose the correct answer :

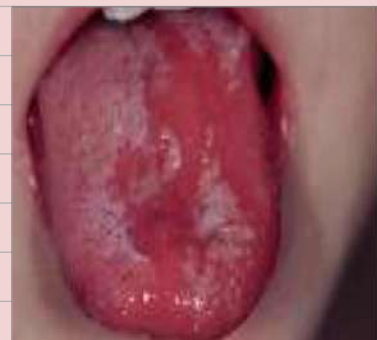Early change on eyes postmortem

**Tache noire:** where the sclera remains exposed to air, two black triangular spots appear at each side of the cornea (due to drying).



Q 16. Choose the most correct answer

Steroid can be used





## Essay questions

Arabic questions

كتابة تقرير اصابة أولي :

One cut wound in face by sharp object

السؤال الأول

كتابة شهادة وفاة :

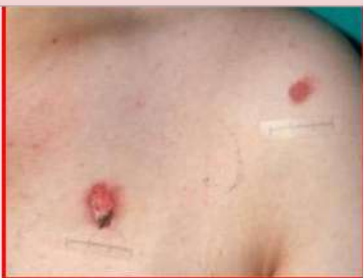السؤال الثاني

44 old female come to hospital suffer from dyspepsia and heart burn was diagnosed Peptic Dodenal ulcer after adimtion she developed pertonitis and septicemia after this she died

English questions

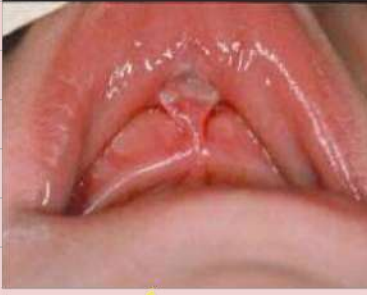## The first question

Identification the type of injury into accedental and non accedental ,justify your ansvar



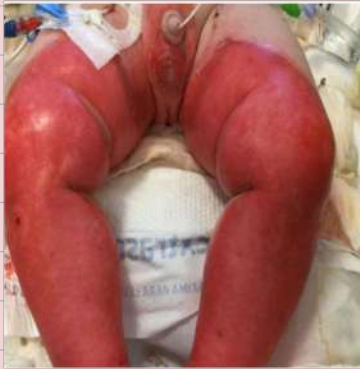Non accedntal , multipel ciggrate burn injury from singel cause

A



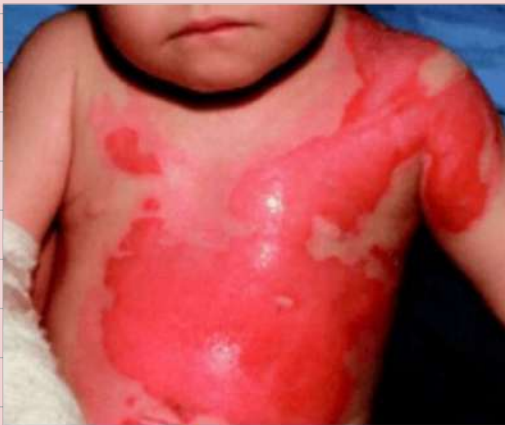Non accidental , avulsion of frenulum due to direct blow to child's mouth

B



Non accidental , no splash mark sharply demarcated burn margin

C



ملاحظة : ما اجت هاي الصورة حرق في بيت قريبة منها وبنفس المبدأ

Accidental, splash mark , atypical margin

D

## The second question

Case study about patient come to hospital with paracetamol toxicity after three hour

Write: Most effective method of decontamination  
Signs and symptoms  
Antidote used and route of administration

# Forensic

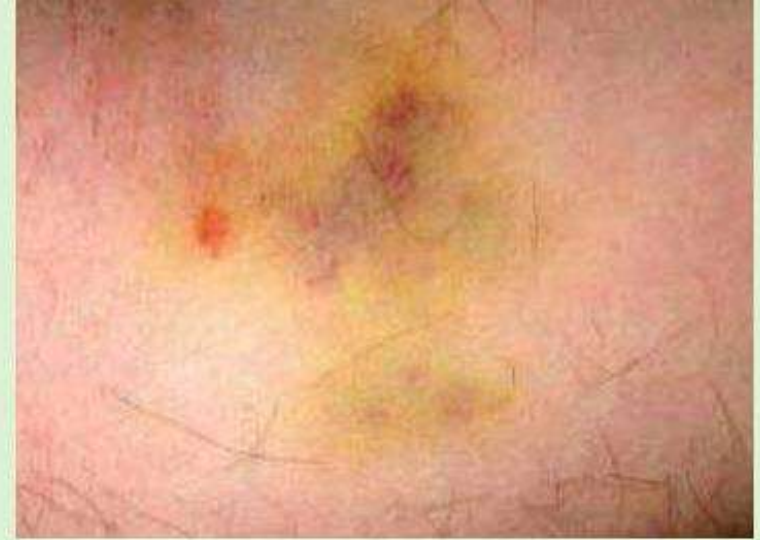**Group B**



• 21) which of the following is true?

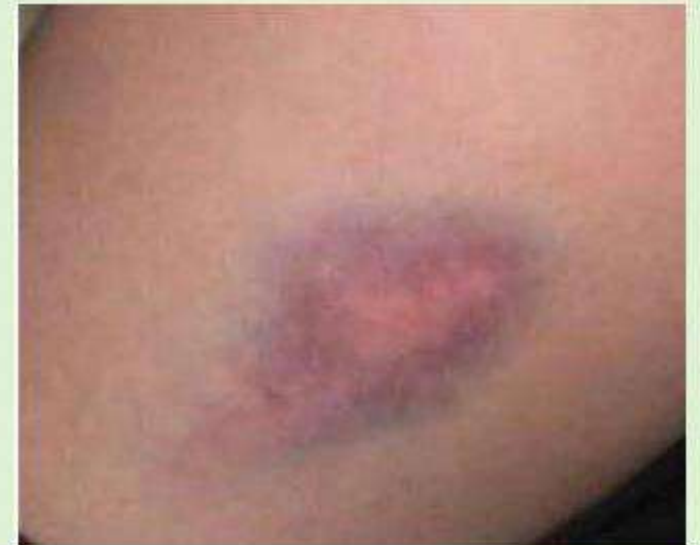- a. A is older than B
- b. B is older than A

Answer: A



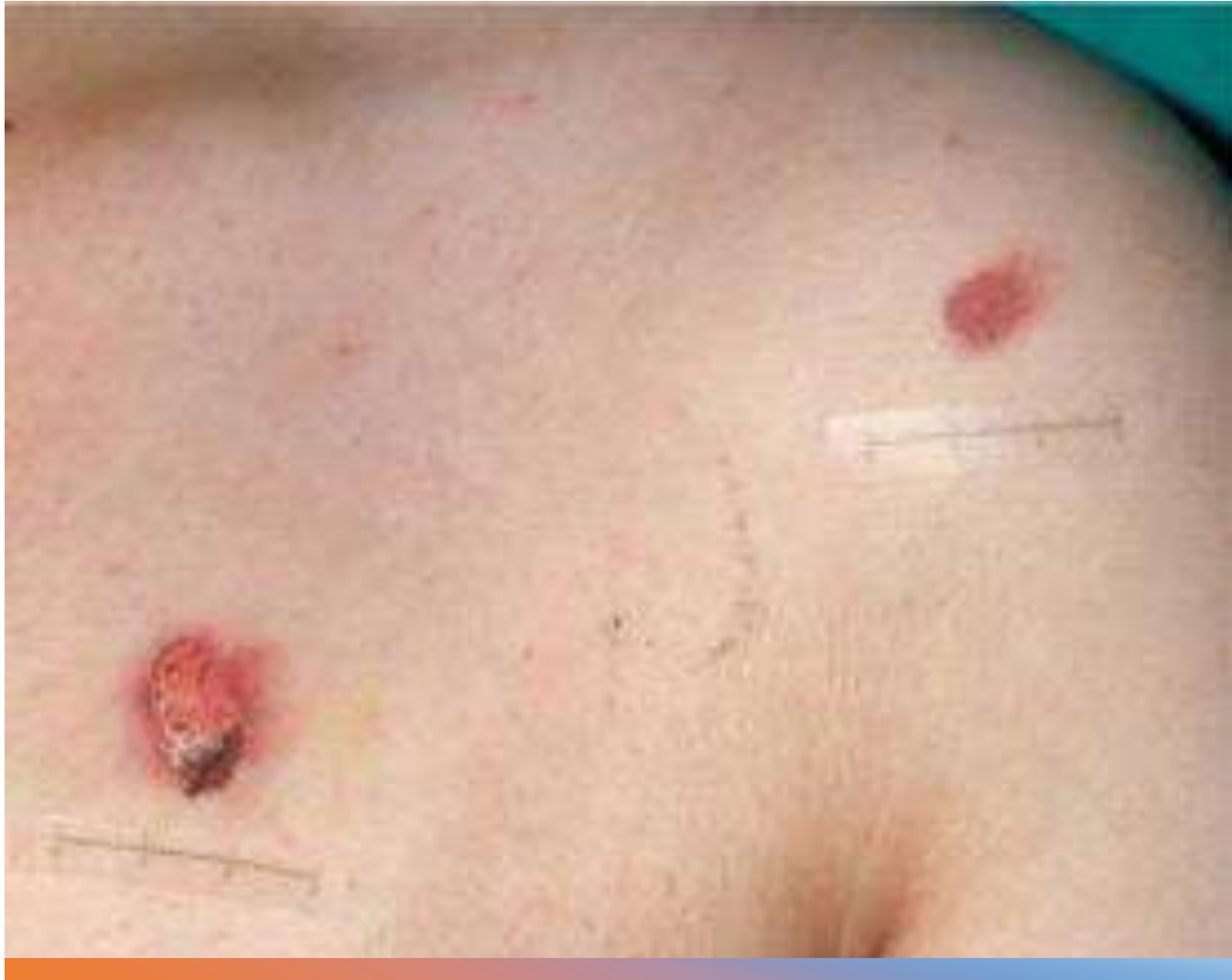A

B



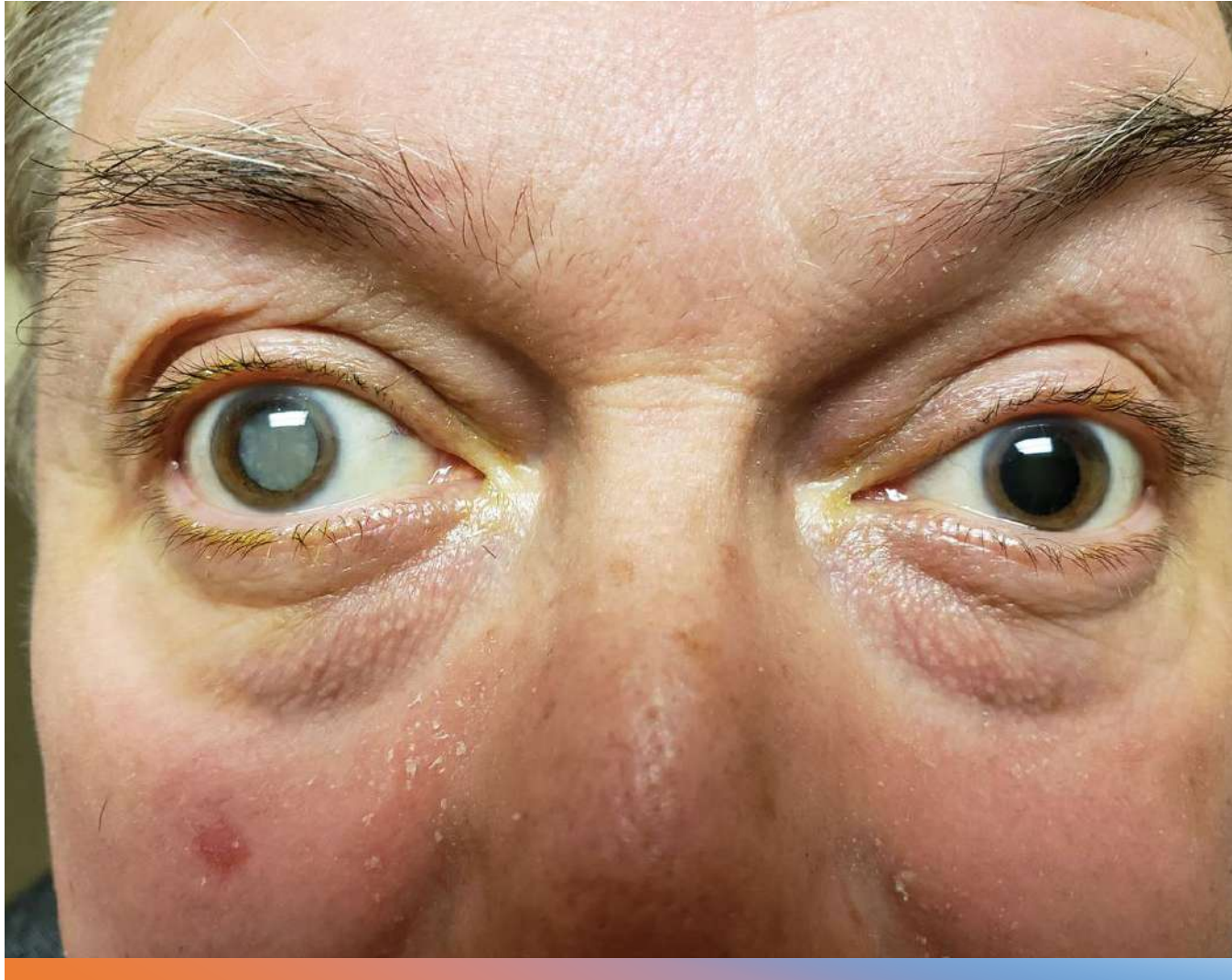


- **100% oxygen with pressure**



- **Child abuse because multi injury from single Cause**





Permanent  
infirmity

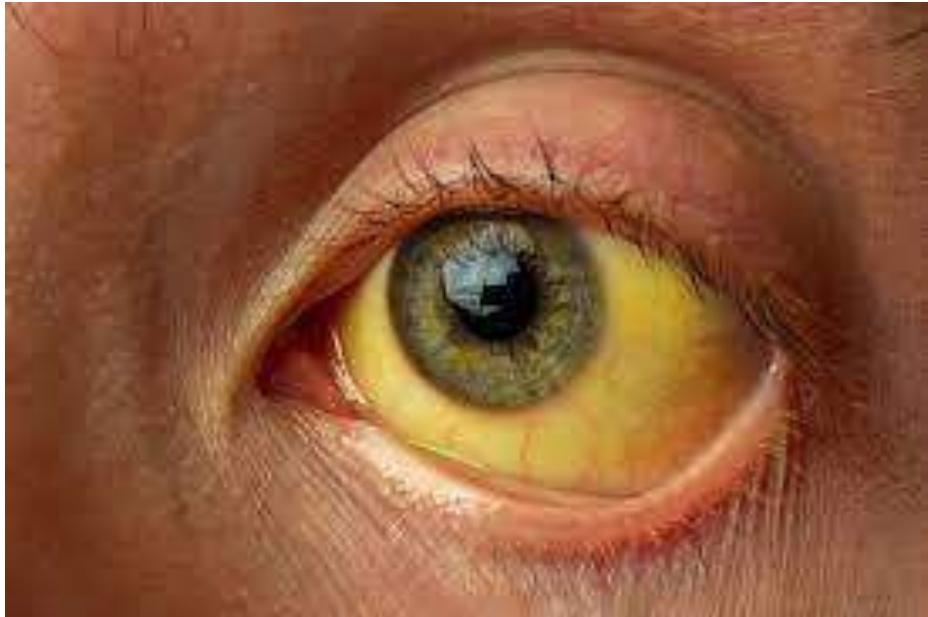

**Mugging**



Live reffiling

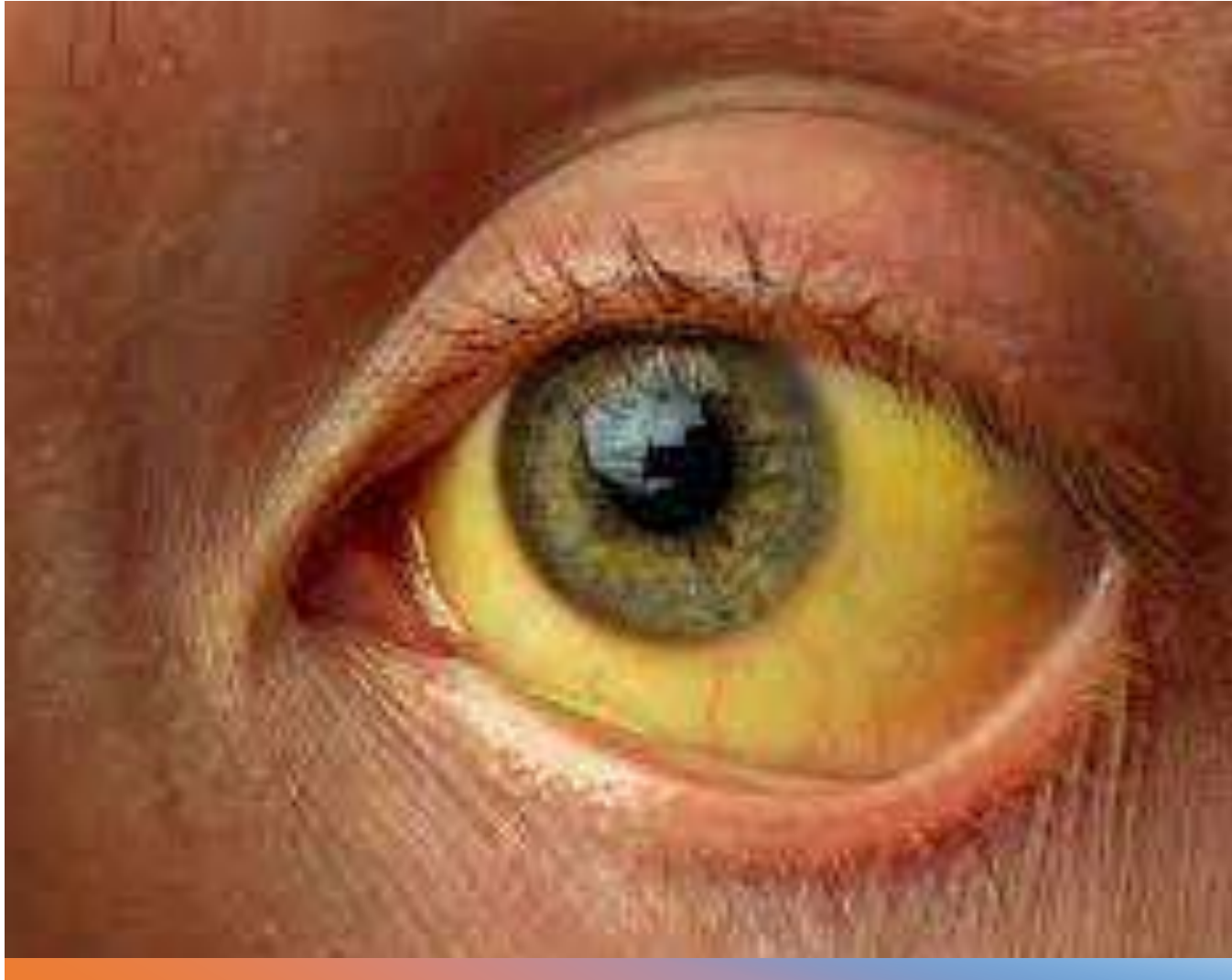



which of the following cause  
this condition?

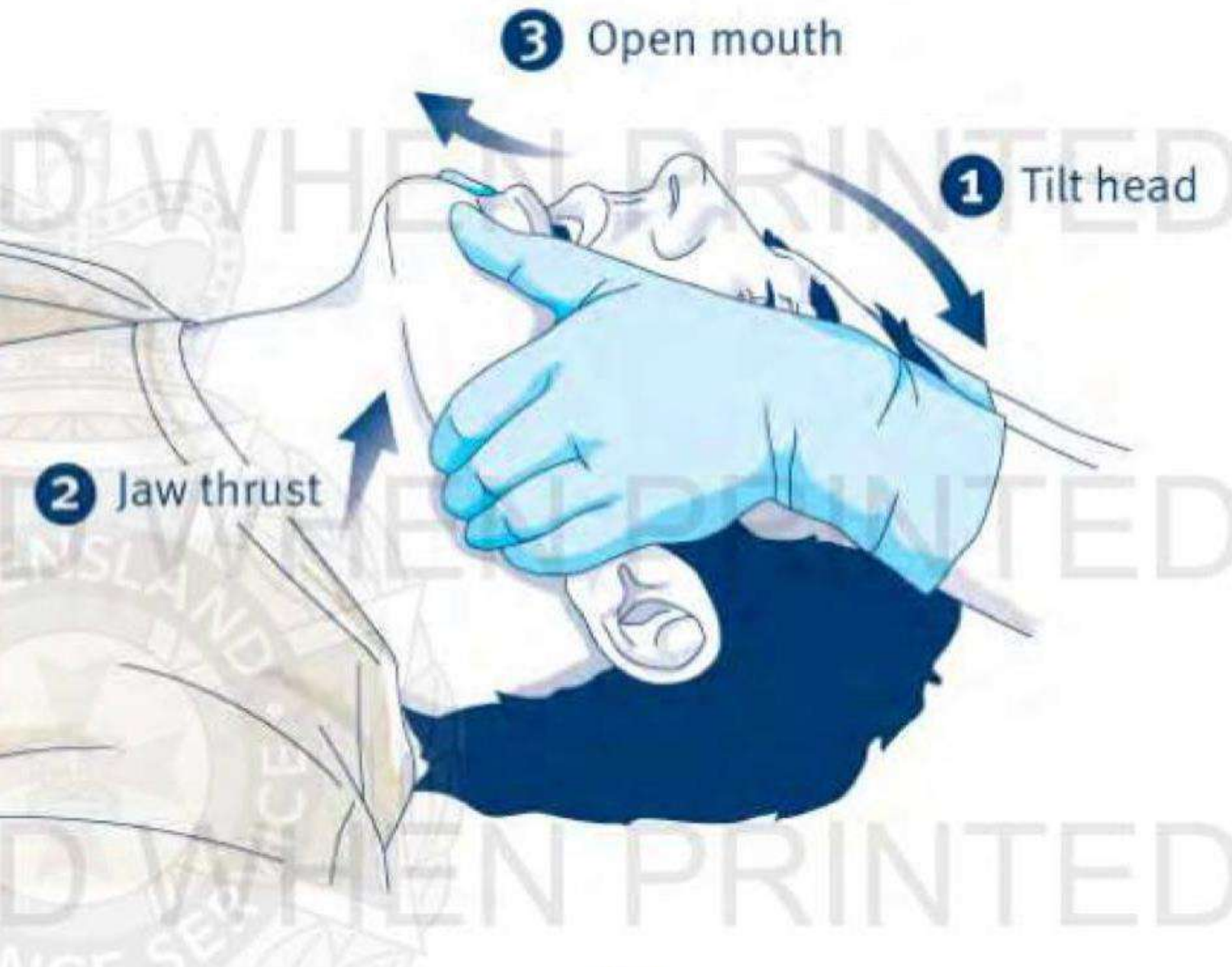
Answer:

**Iron ,Paracetamol ,Alcohol ,Phosphorus**



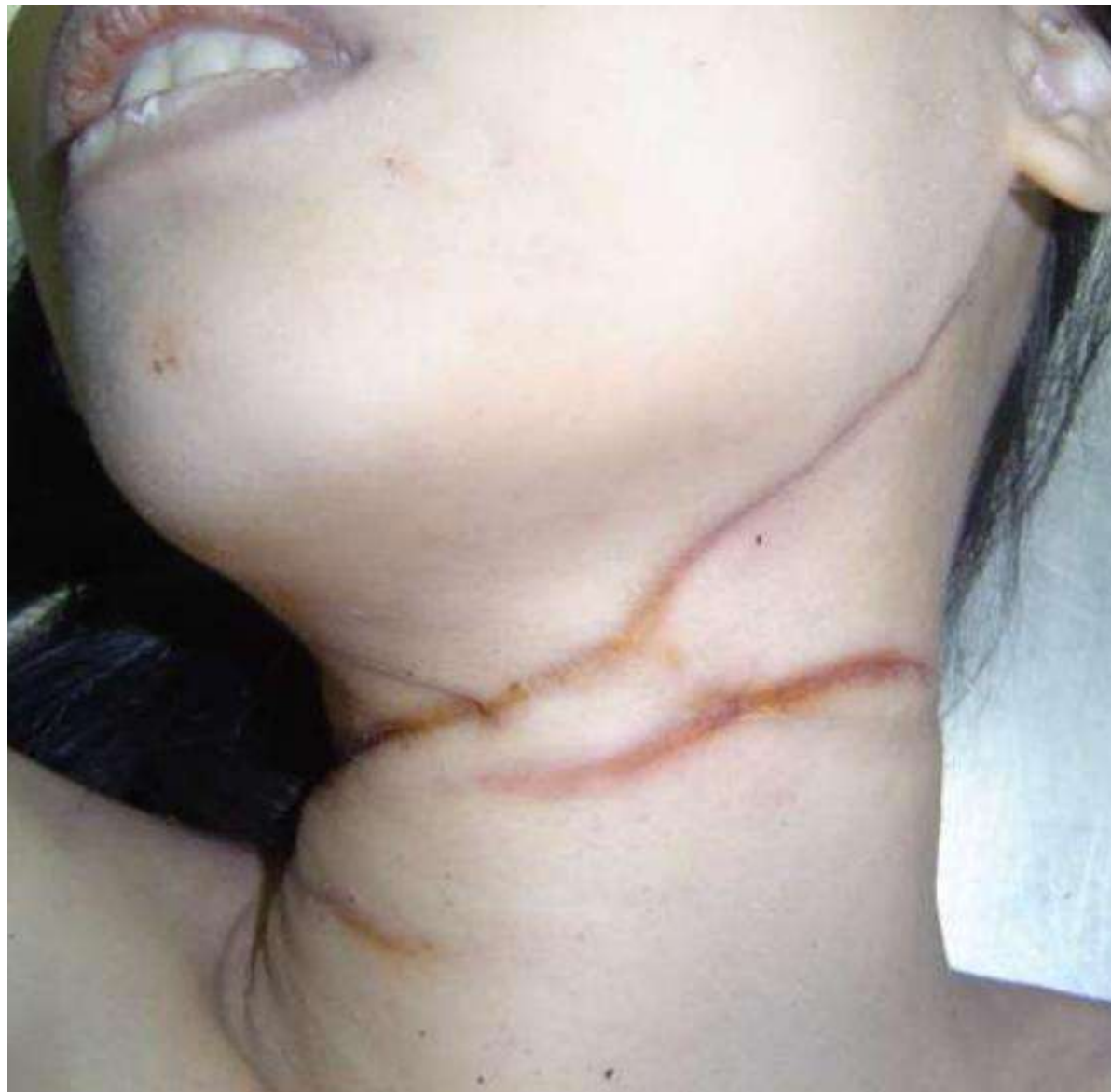All of this can use to treat this case ,except:

- A. oral N-Acetylcysteine
  - B. IV N-Acetylcysteine
  - C. decontamination
  - D. life support
- Answer: **C**

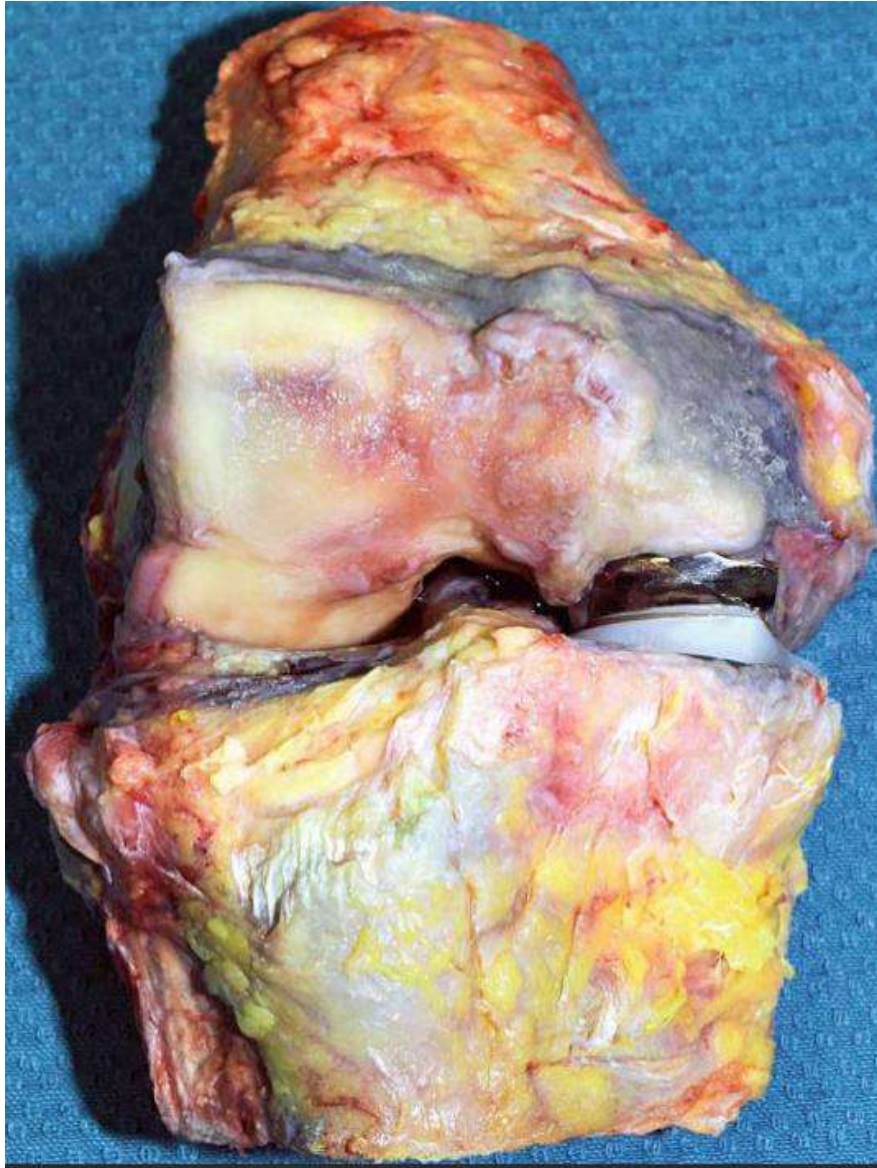


- Triple airway manoeuvre for Airway opening

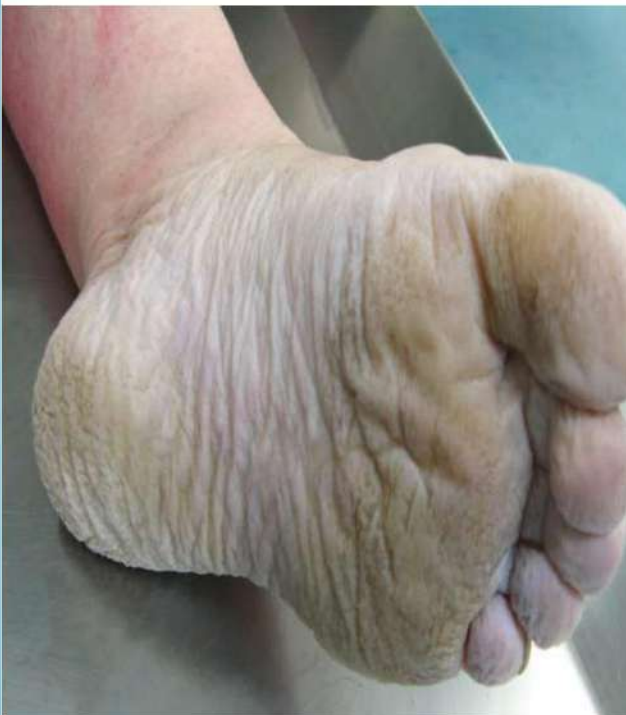
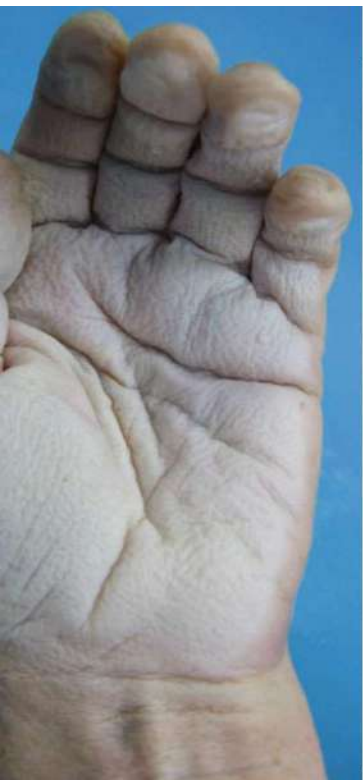


hangging

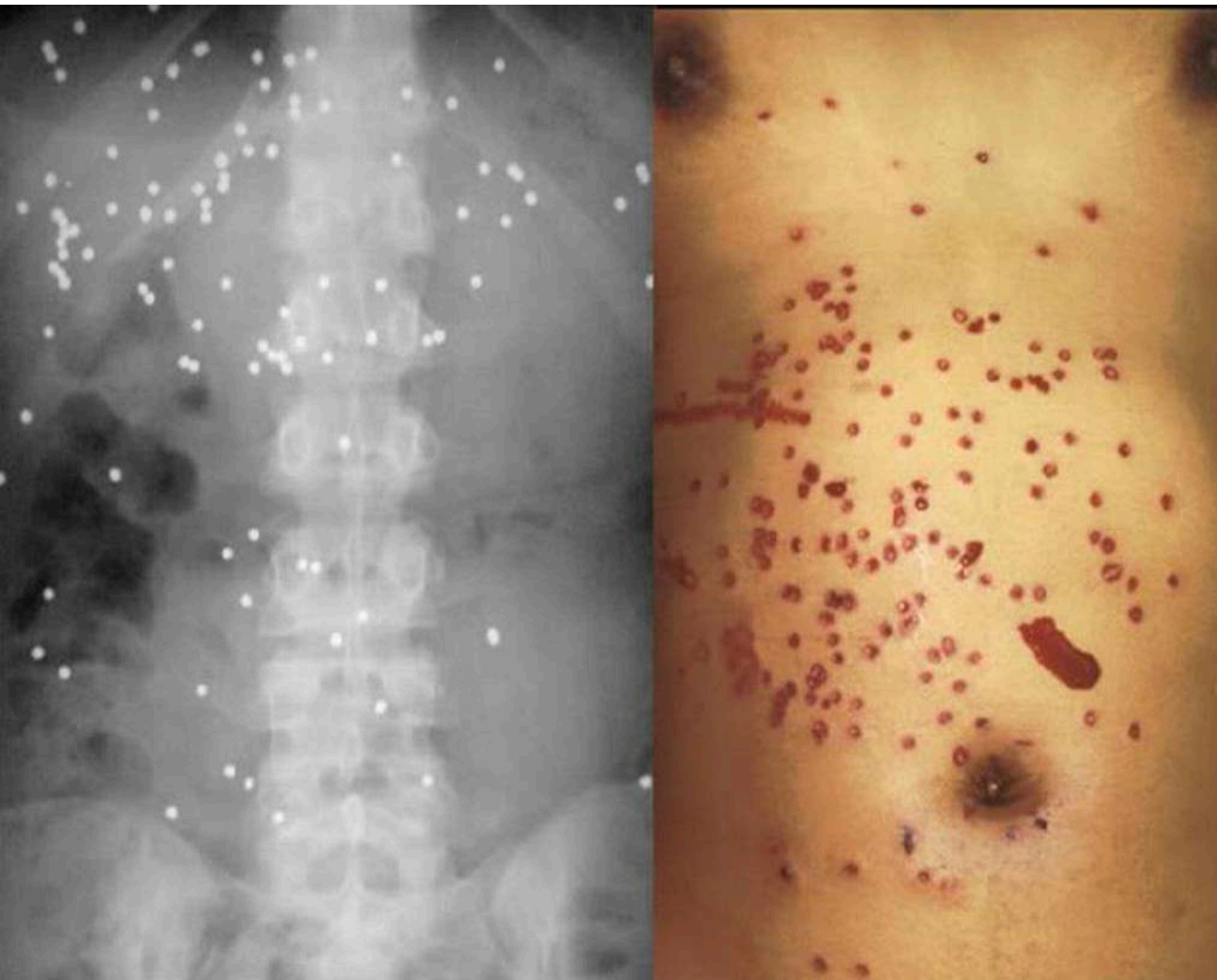

medical  
record



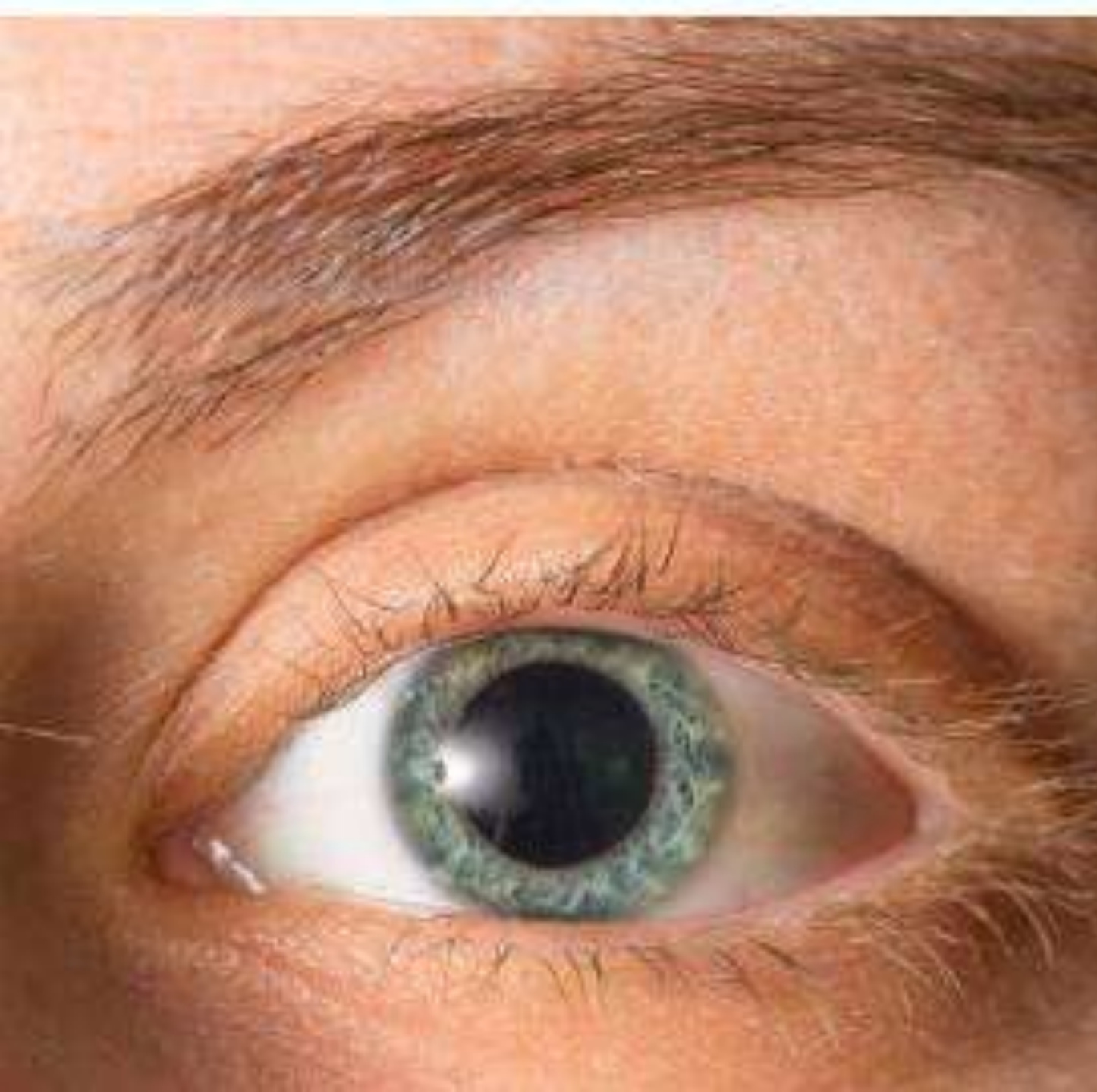- 
- Sure signs of drawing
  - May be drawing





Not the same

Non rifle, less than 4m

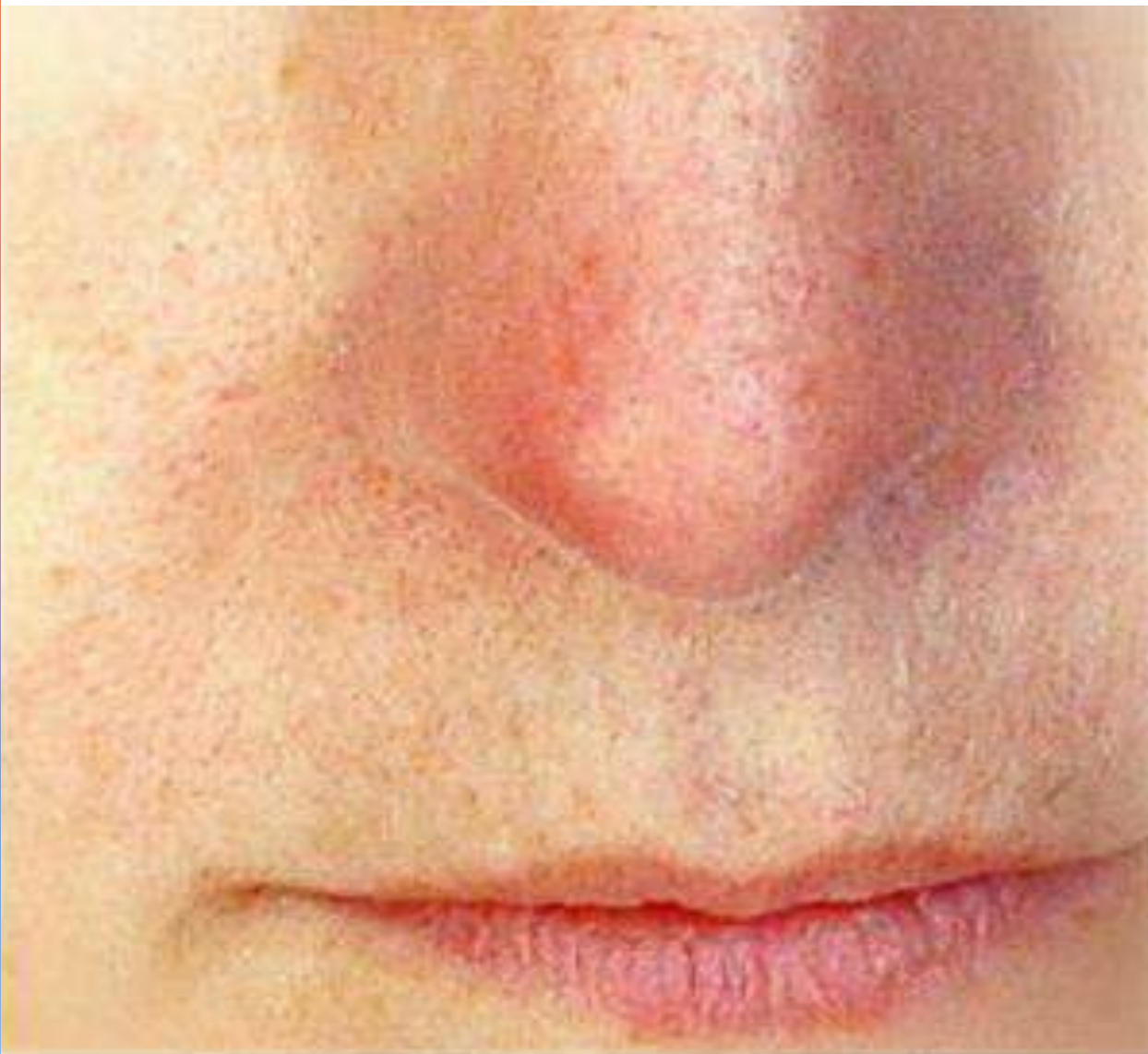

- **Non reactive dilated :  
which of the following  
cause this condition?**
- **Anticholinergic**

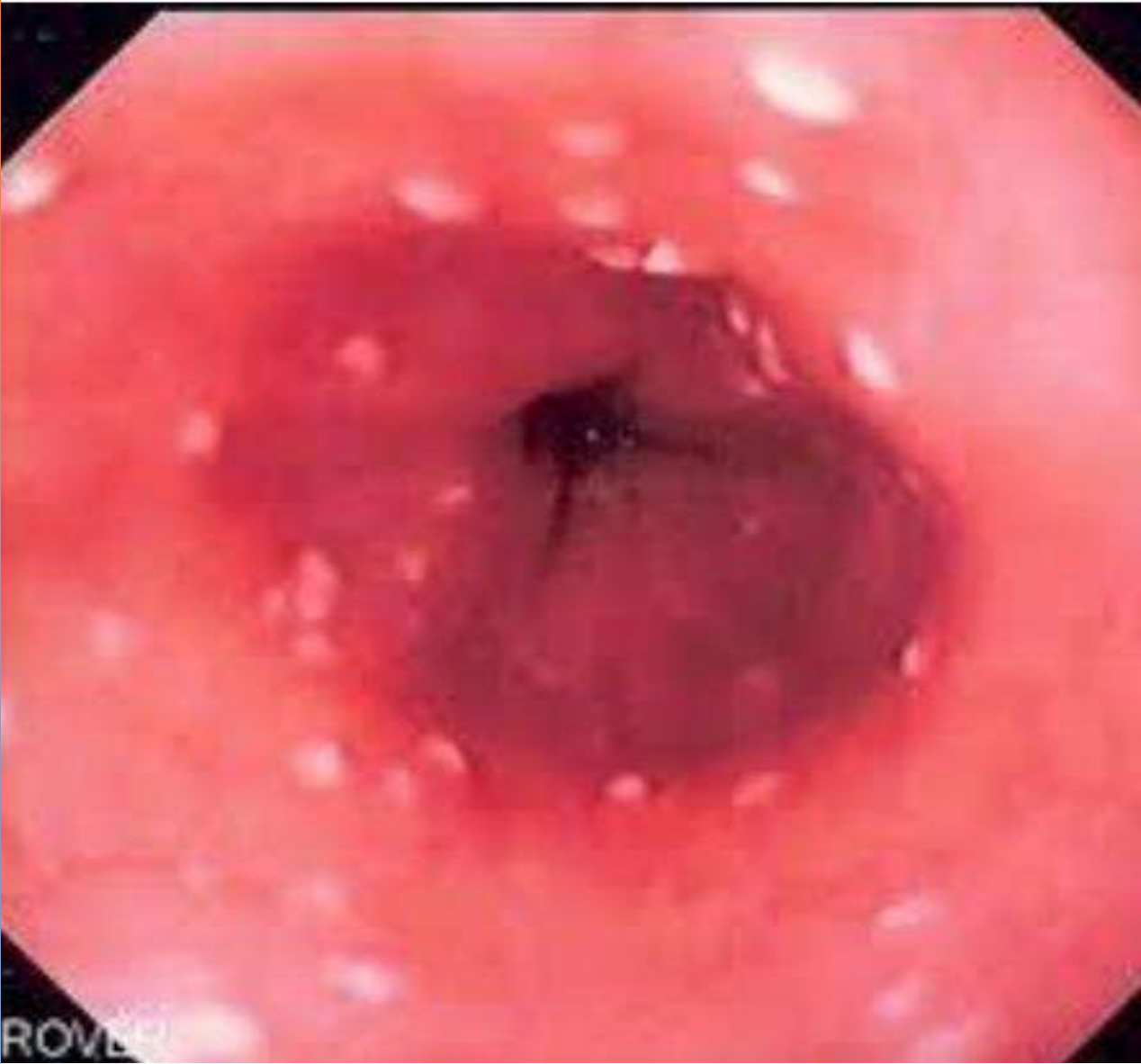

- Patent prints

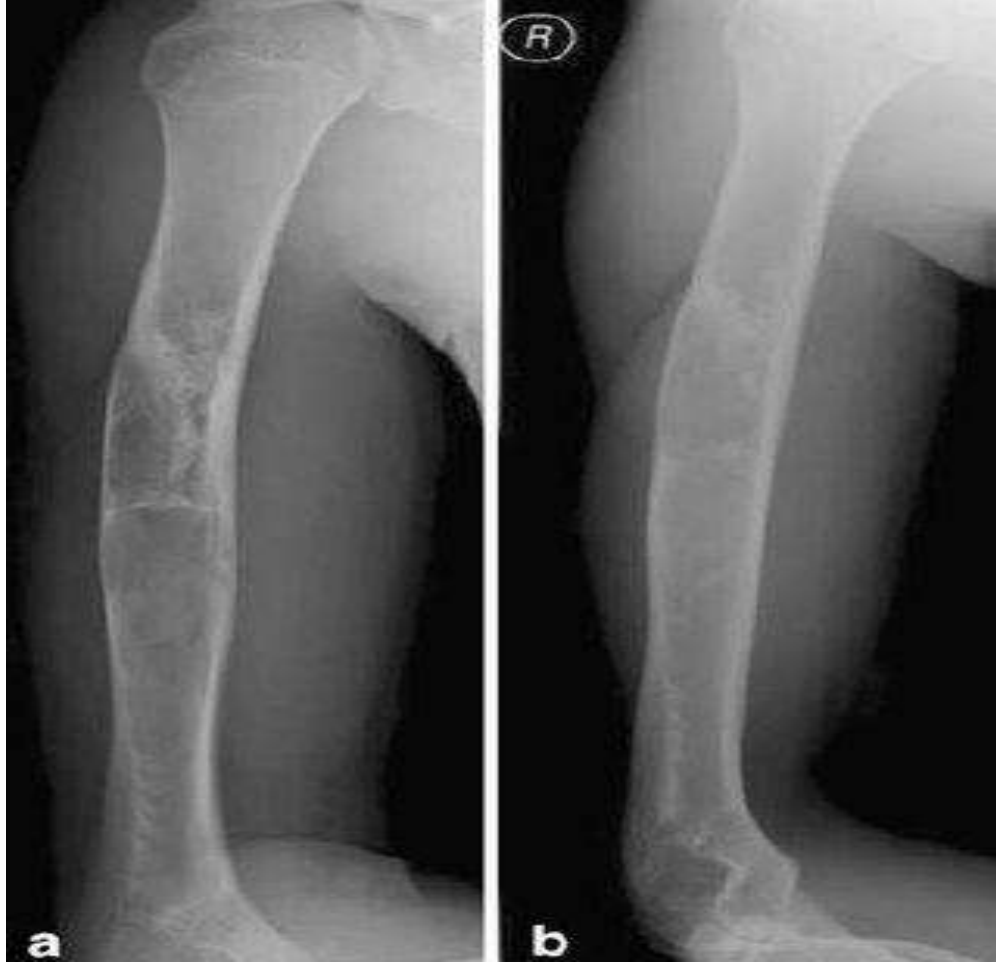



- Rhinophyma



- Hot endoscopy in 1st 24 hr



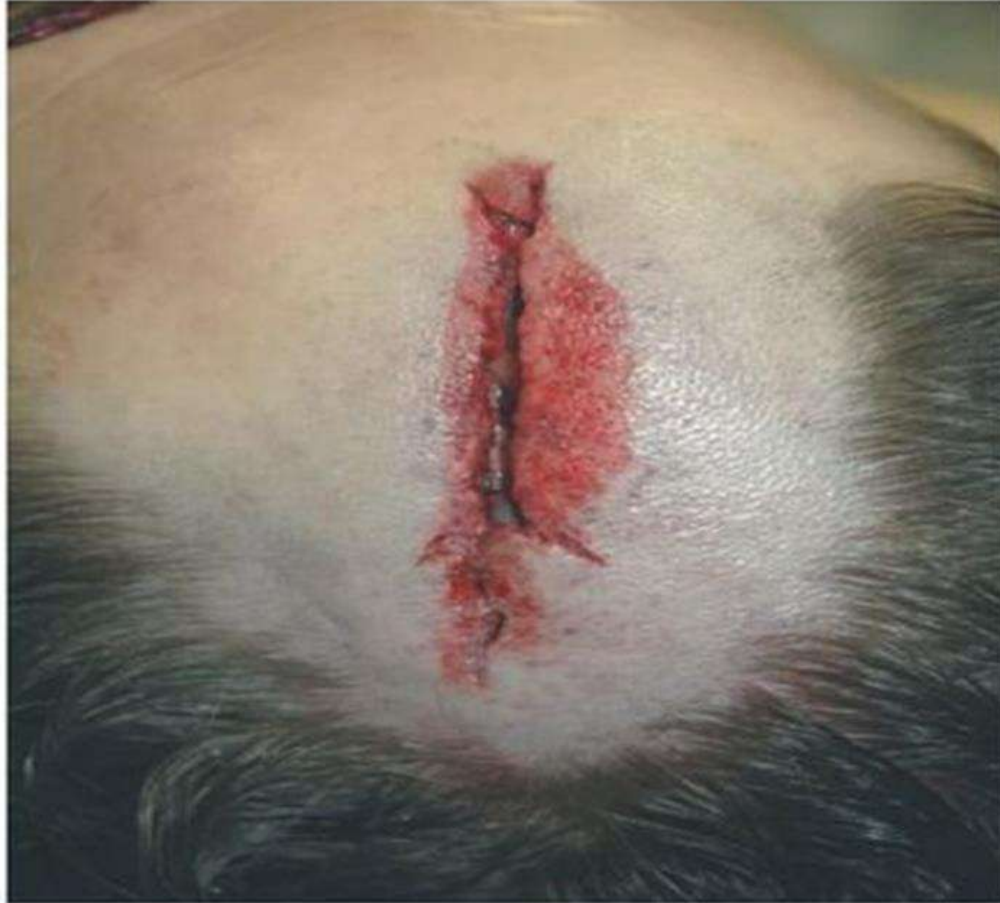- **Less than 16**

صورة تقريبية للكتف والكوع



- A patient came with .... and decreased visual acuity and Hyperemia of optic disc . What is the cause ? Methanol
- Red hypostasis ?? Co , cyanide, hypothermia

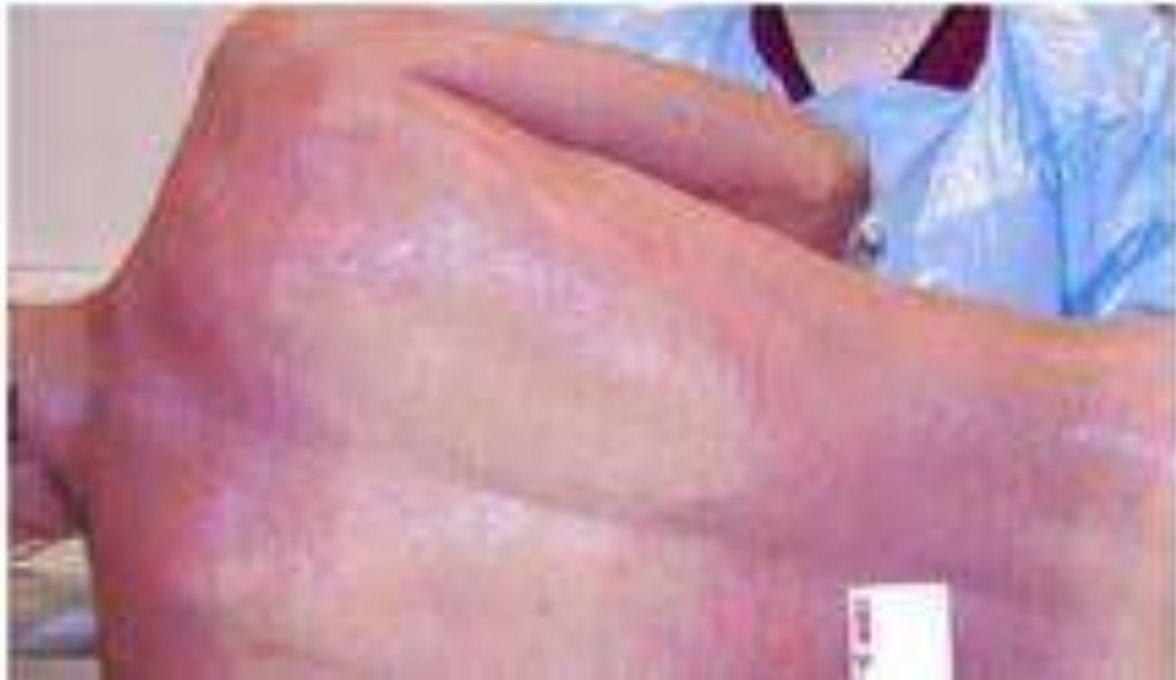اسئلة الكتابي



Write a wound report  
بالعربي ,



- 10 y male with high fever , he dignosia as viral encephalitis ,later spread to mid brain , coma, ventilator for 3 day and die
- death certification?



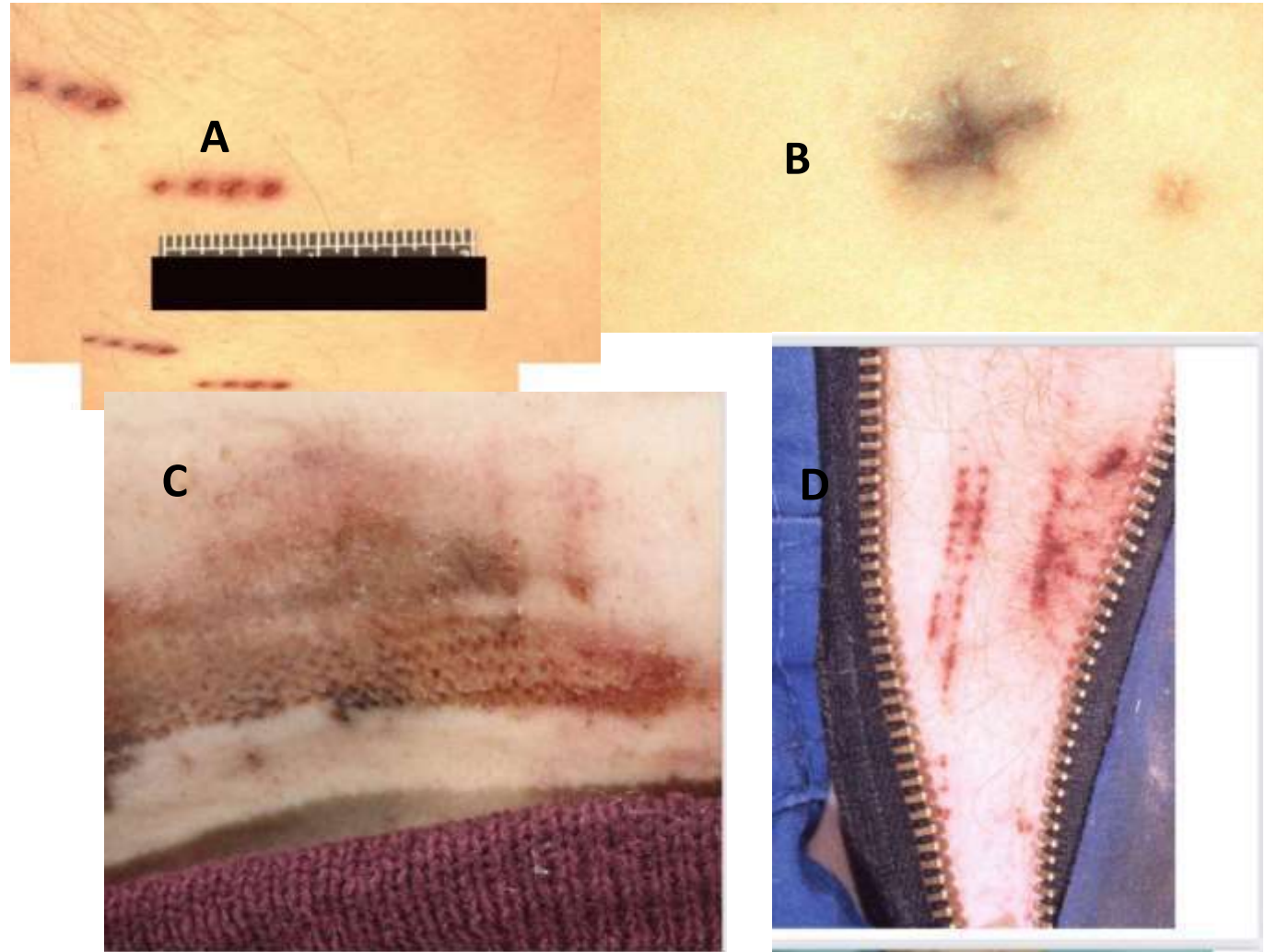
what is PM change??  
what is the interval of cadaveric warmth??

hypostasis  
(3-8)h

Forensic

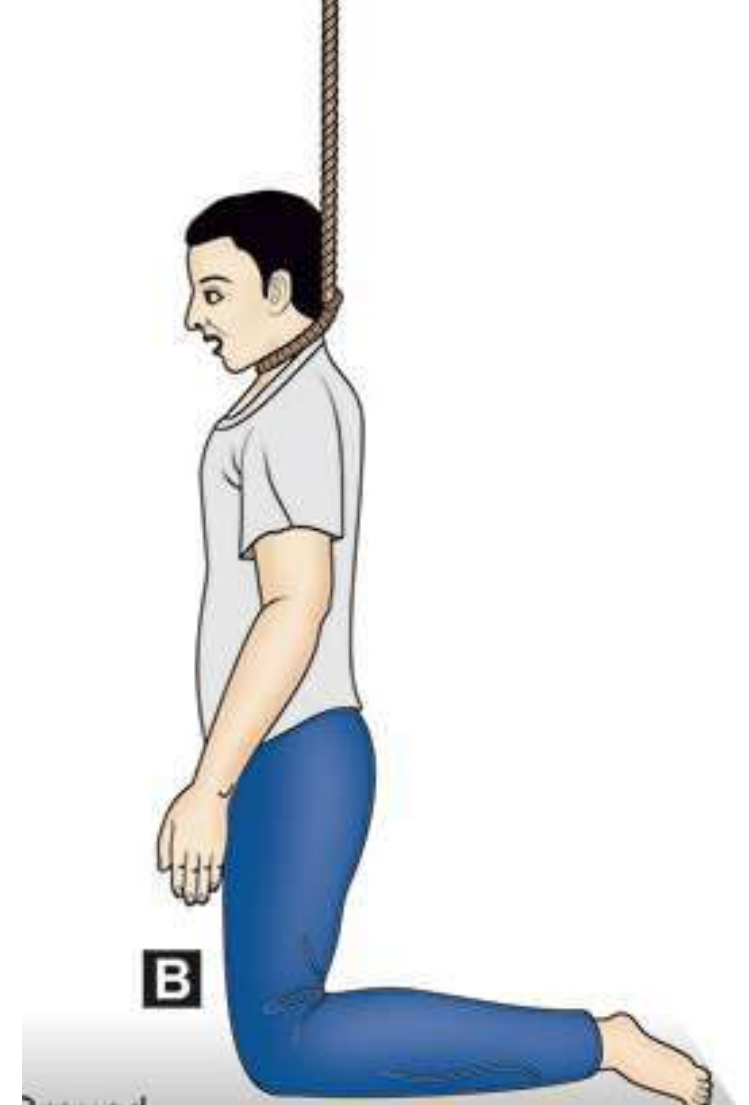


- a) All blunt
- b) All blunt except d
- c) **All patterned**
- d) All patterned except a



صورة تقريبية بس ما كانوا  
كل رجليه عالارض كانوا يا  
دوب الاصابع

**Typical incomplete hanging**



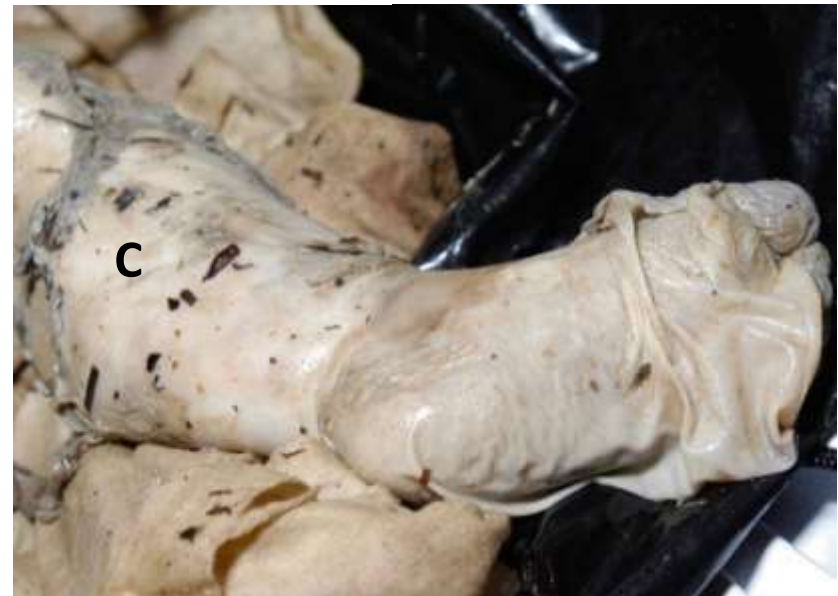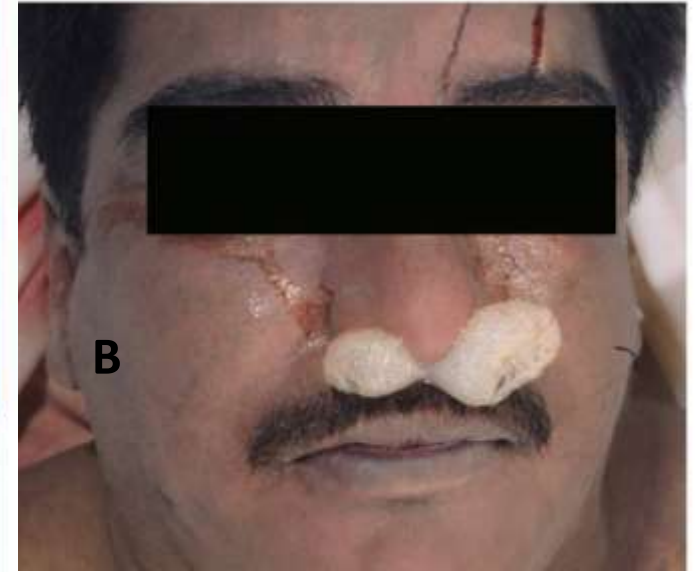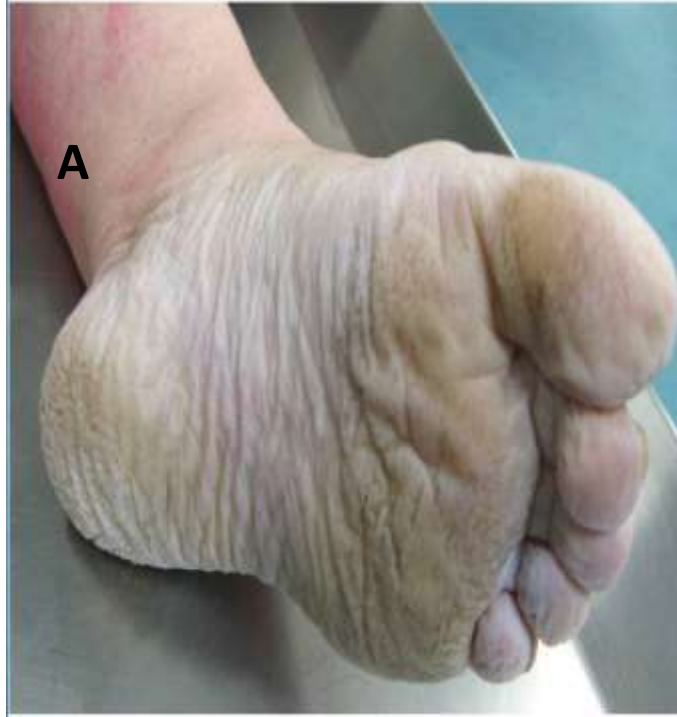All these pic represent to:

السؤال عليه خلاف باعتبار انه

A not sure sign

**a) All Sure signs of drowning**

**b) Sure signs of drowning except a**





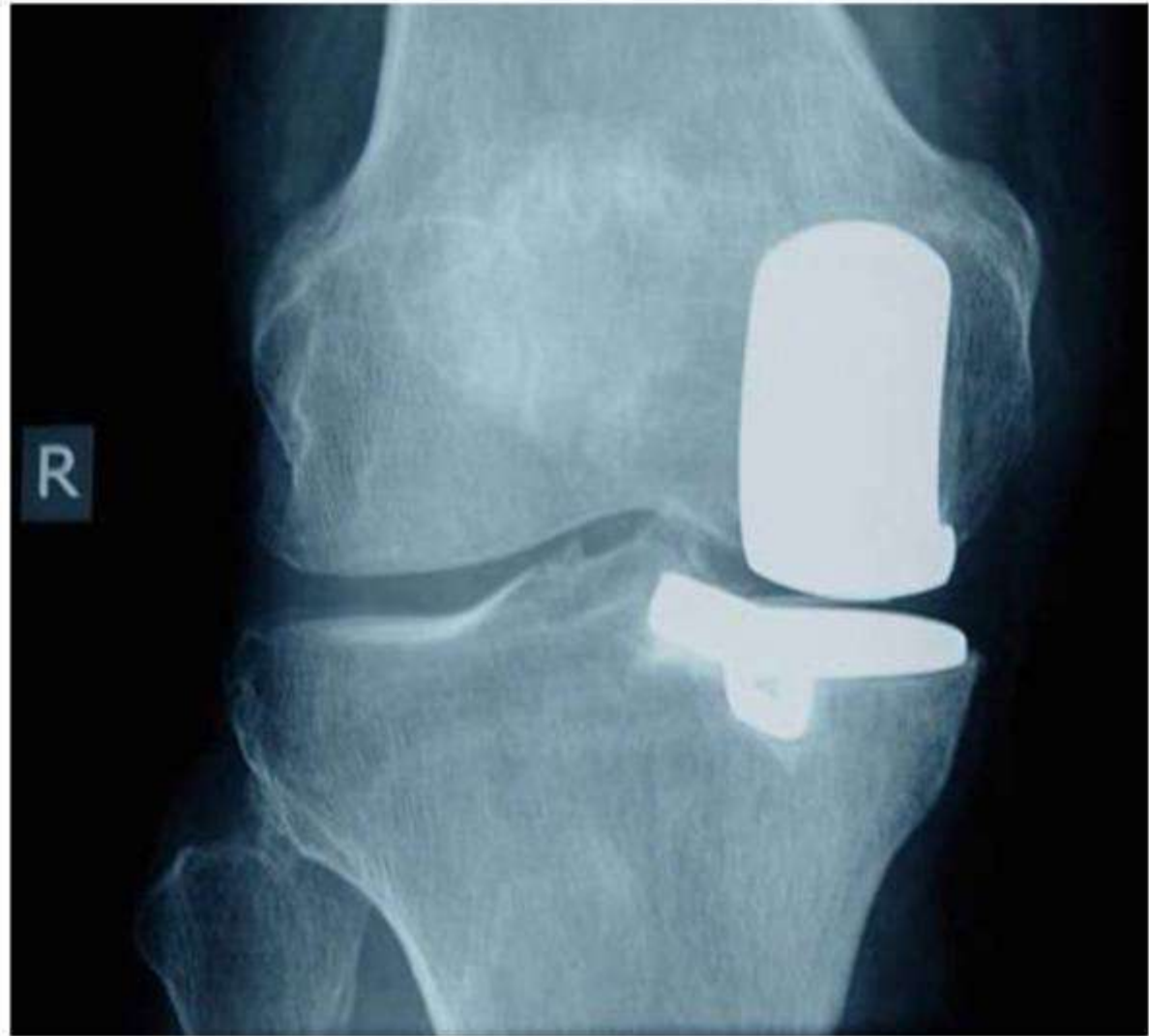
**a) Medical record**

**b) Visual ID**

**c) Social status**

**d) dental ID**

**e) Congenital anomalies**



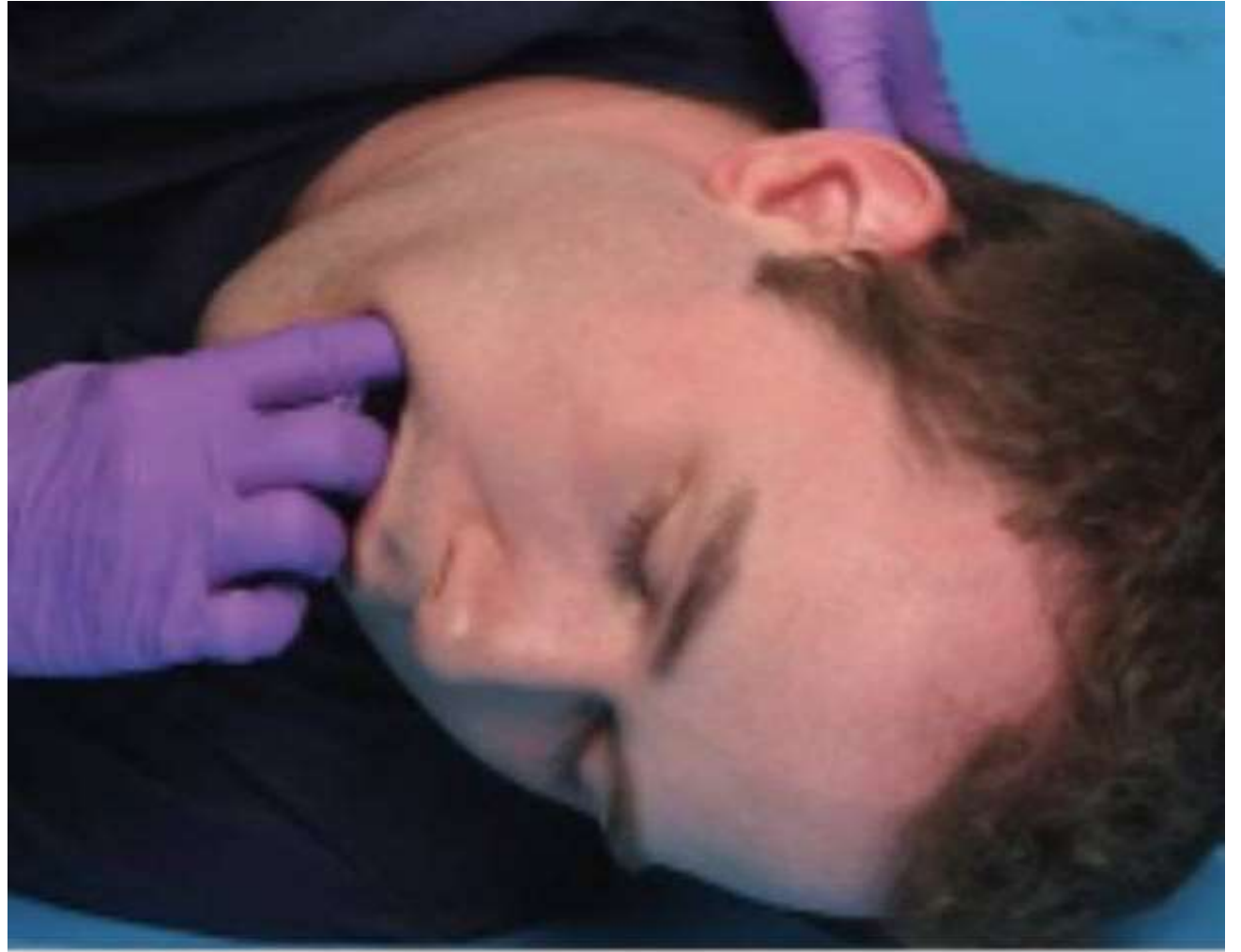**Patent prints**

**Latent prints**

**Plastic prints**



**We do this to  
open airway**





a) **Need LFT + NAC**

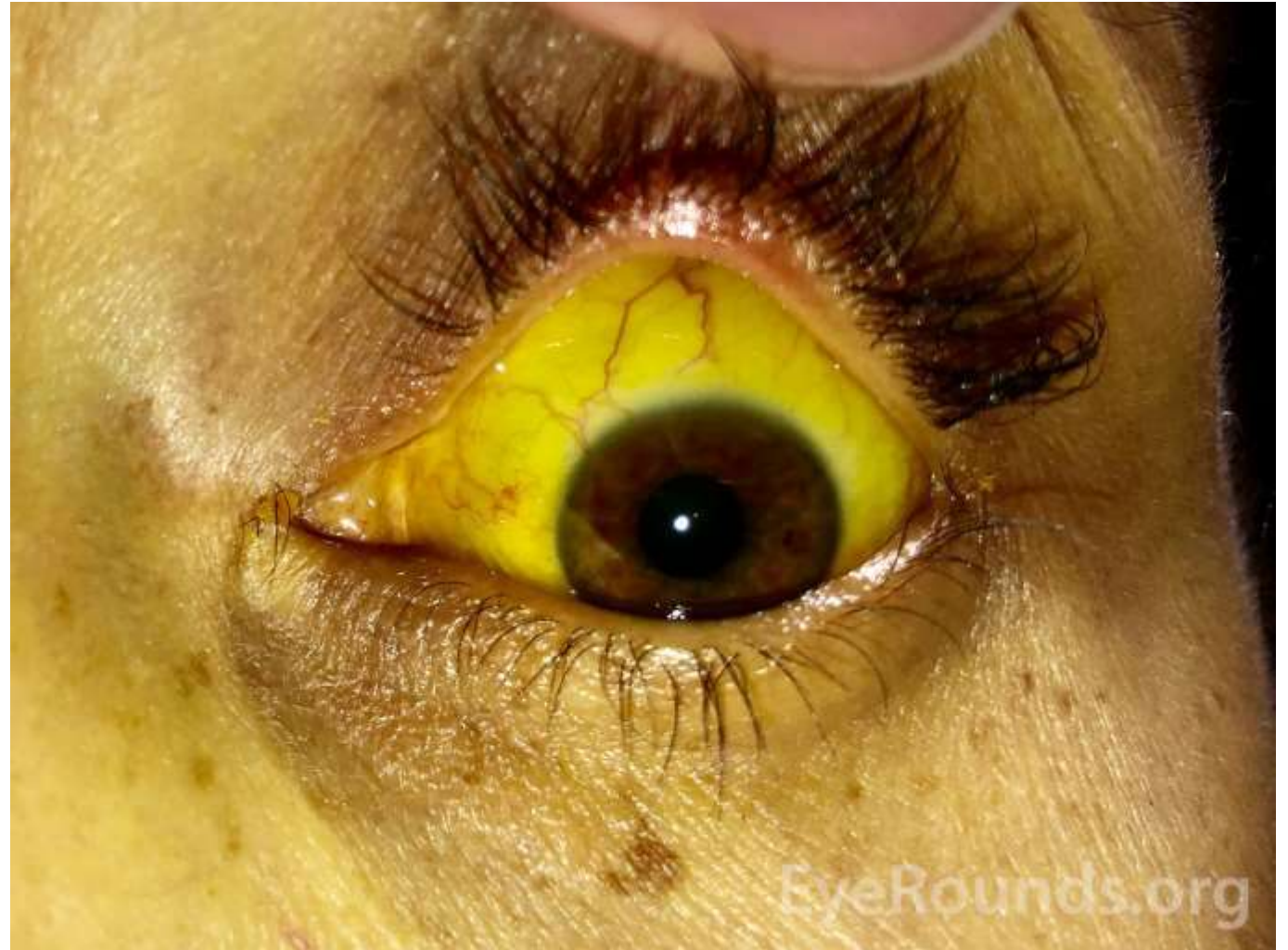b) LFT is enough

c) NAC is enough

الدكتور مرة حكي انه

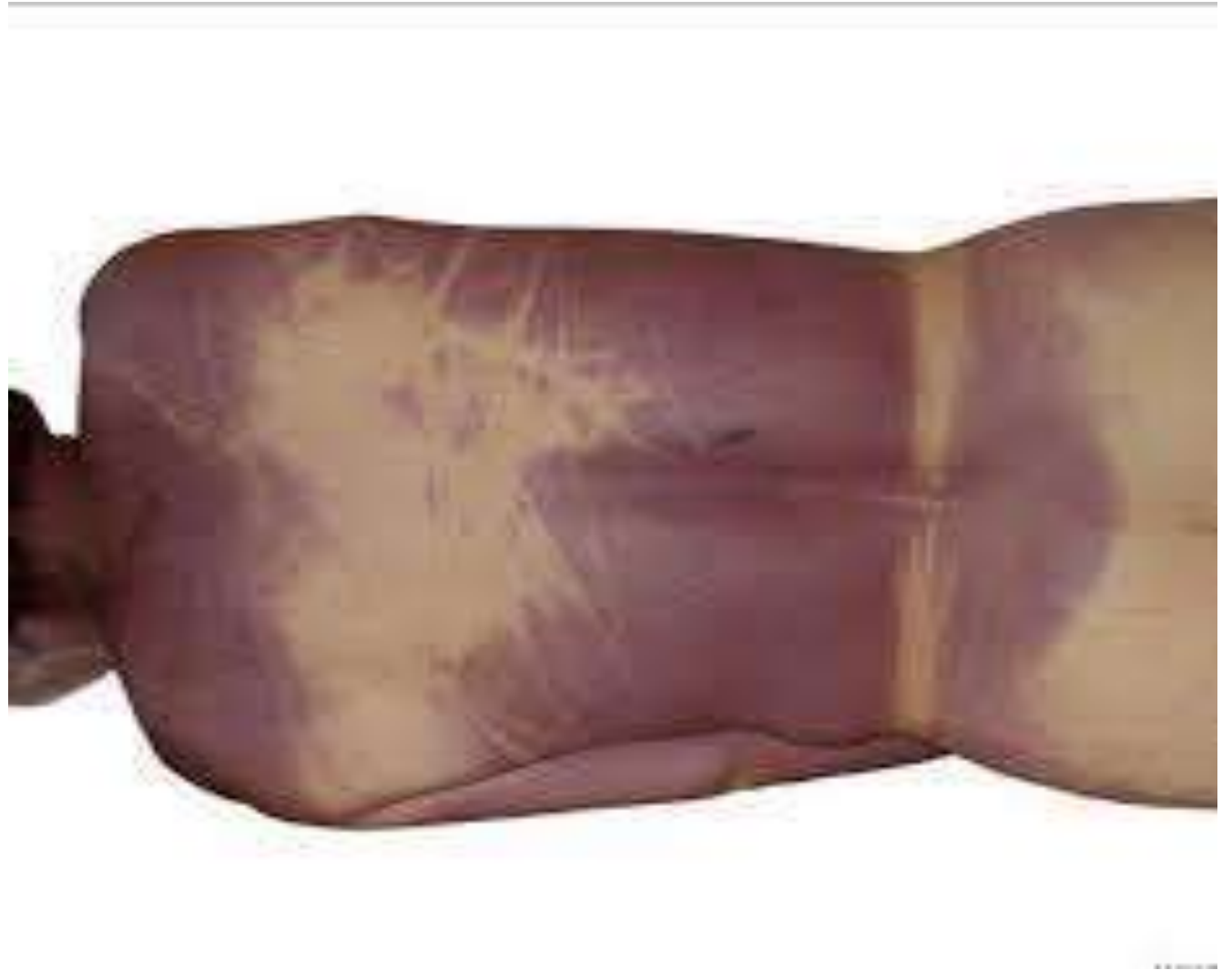**NAC**

شو ما تأخرنا ممكن انه نعطييه



**He died when  
he was on back**

**Supine position**



Pt came to ER with snake bite with no local or systemic manifestation what you will do:

- Nothing
- 3-5 vials
- 5-10 vials
- 10-150vials



# Fetal causes which indicate abortion consider as:

- Spontaneous abortion
- Induced abortion
- Therapeutic abortion
- Criminal abortion

# Percent of alcohol in Jordan

- 0.08%
- 0.05%
- 0.02%
- 0.01%

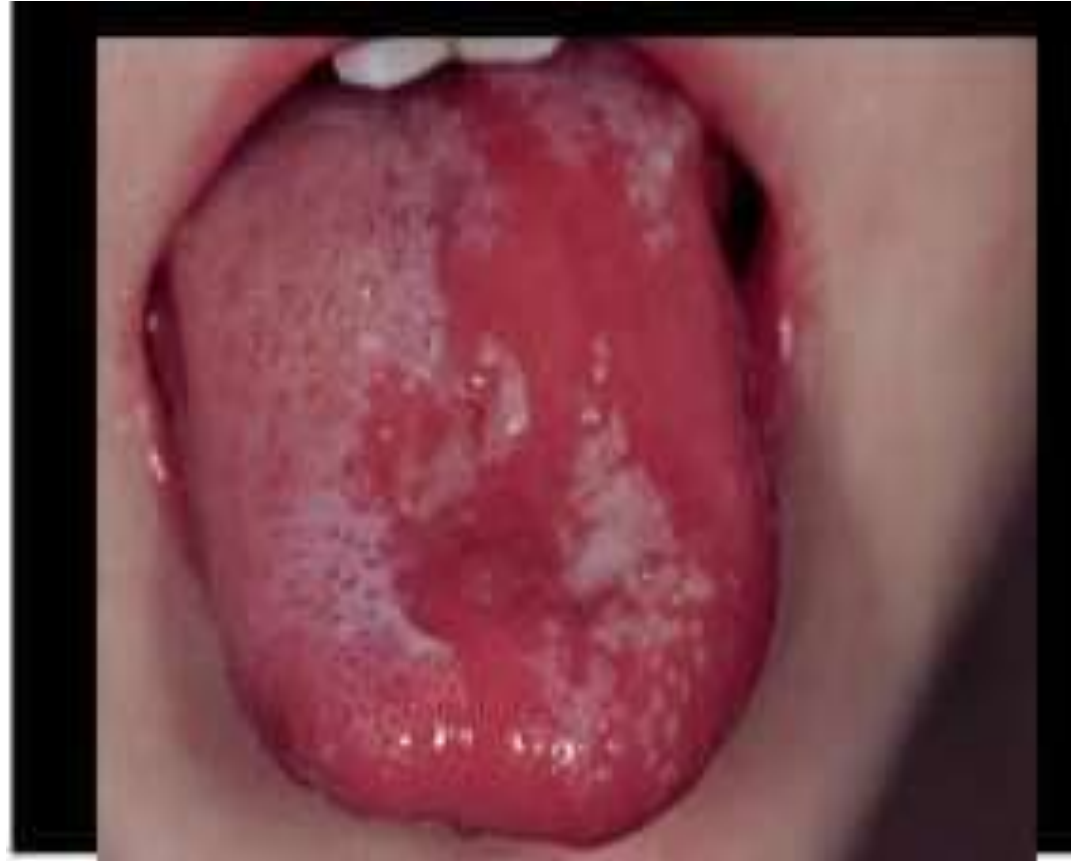# What you can do:

**a) Analgesia**

**b) Emesis**

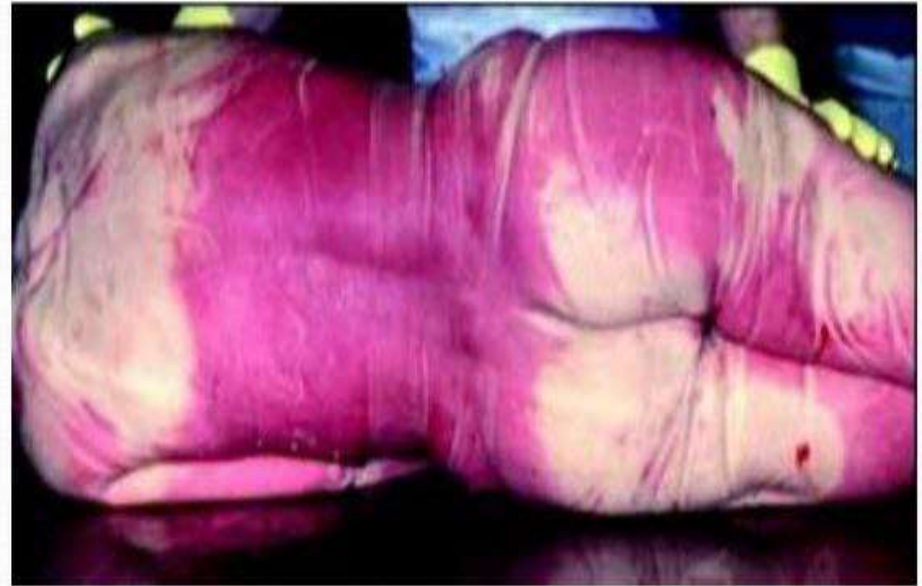**c) Gastric lavage**

**d) AC**



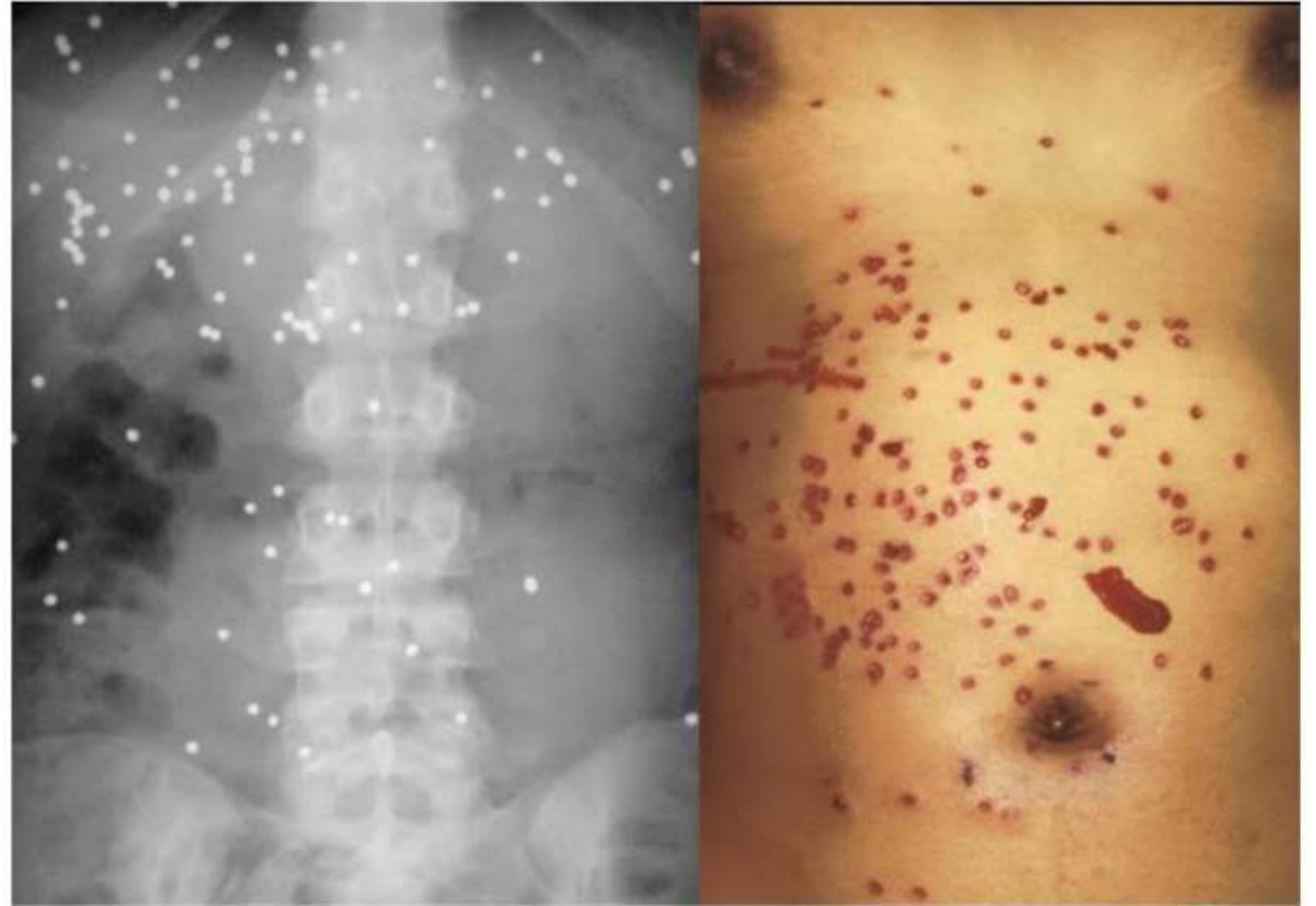

**Hypostasis due to  
death at cold or  
cyanide toxicity**

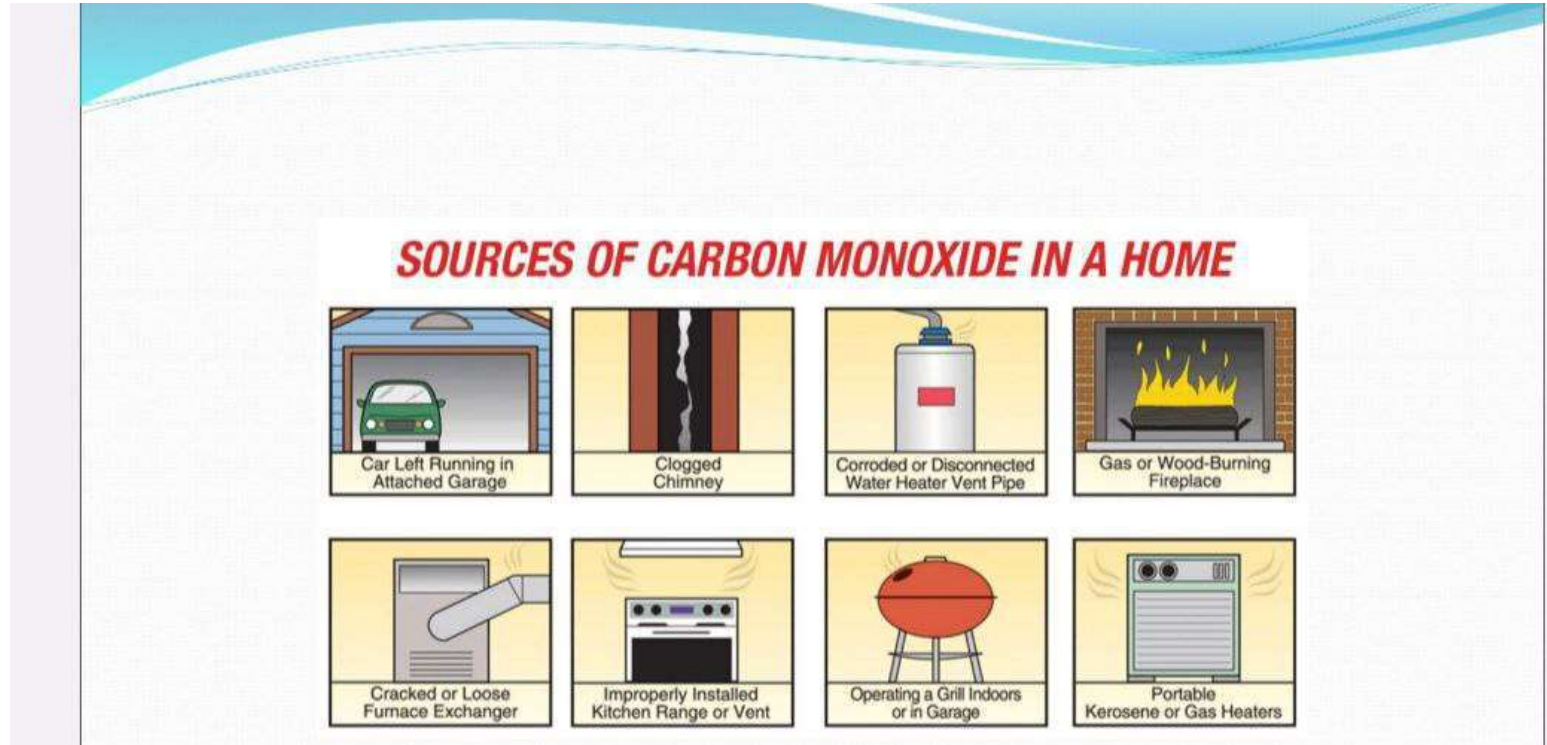


**a) Smooth weapon ,  
more than 4m**

**b) Smooth weapon ,  
Less than 4m**



**First line of  
treatment  
100%o2**



All of them are related to child abuse except:

A

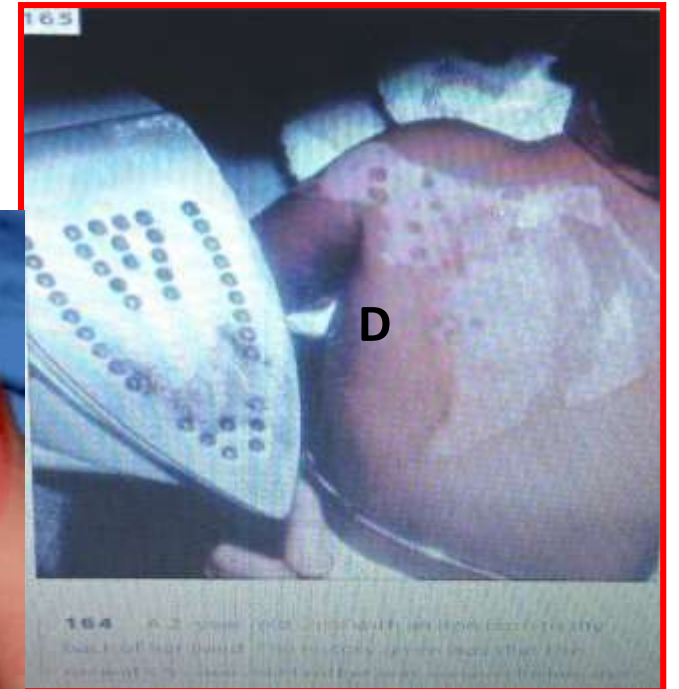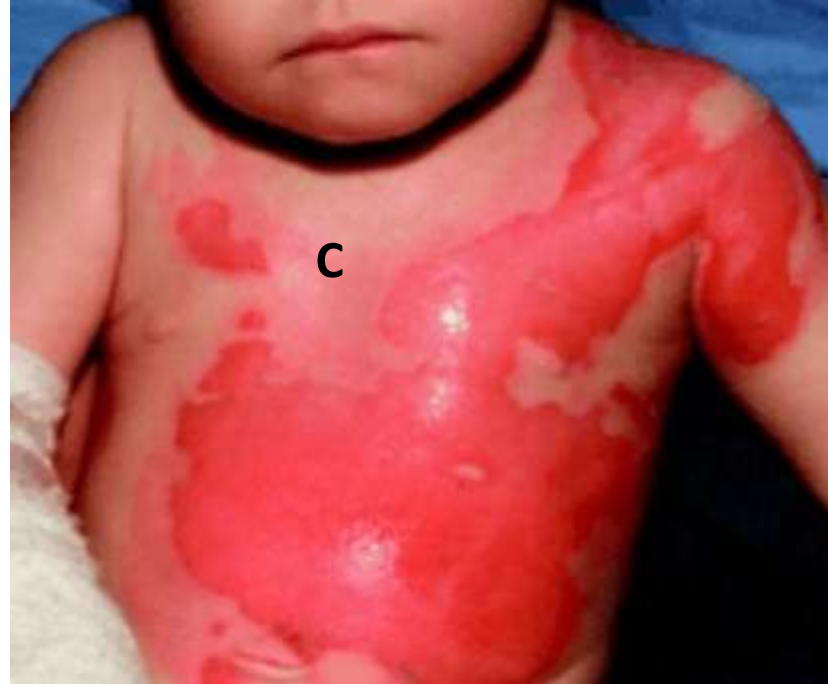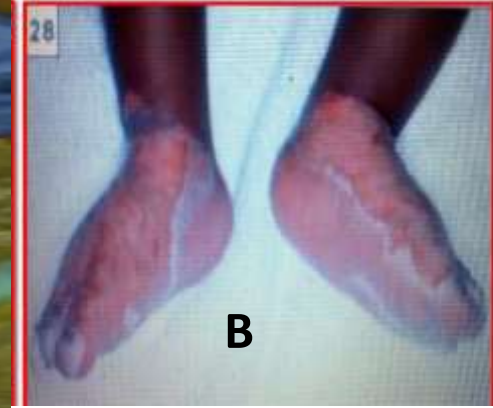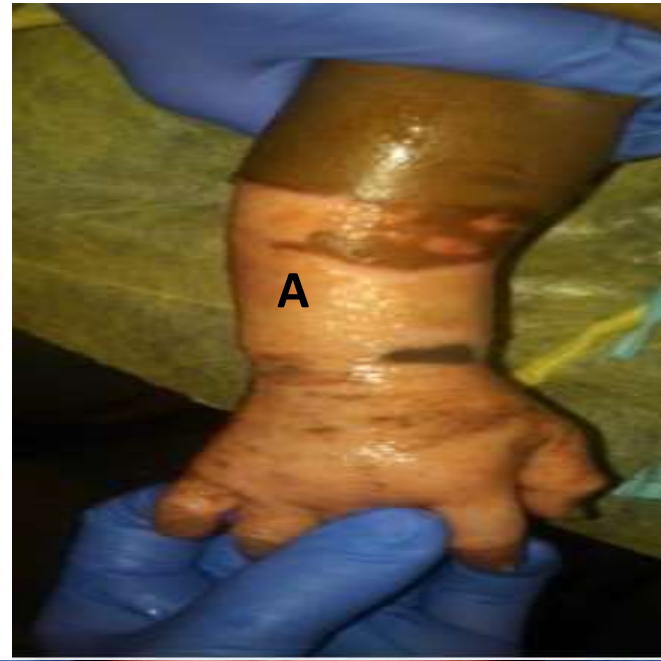
B

C

D

مش بالزبط كانت الصور هاي كلها  
بس الاجابة كانت قريبة من  
الصورة

C





# **SHAKEN BABY SYNDROME**

- a) characterized by retinal, subdural just
- b) characterized by retinal, subdural  $\pm$  subarachnoid hemorrhages
- c) characterized by retinal, subdural  $\pm$  subarachnoid hemorrhages and fracture

## كانت الصور اوضح

- a) Emesis is contraindicated in all cases except D : organophosphorus
- b) Emesis is contraindicated in all cases
- c) Emesis is contraindicated in all cases except A
- d) Emesis is contraindicated in all cases except B
- e) Emesis is contraindicated in all cases except C

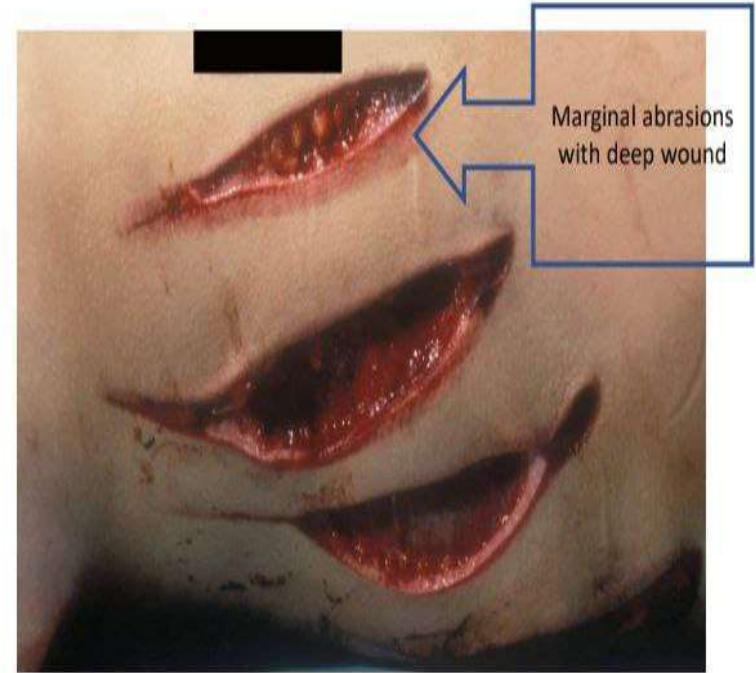


- a) Active ,Rifled weapons
- b) empty Rifled weapons
- c) **Active ,non Rifled weapons**
- d) empty non Rifled weapons



كان في زي هذا الجرح بالوجة

Cut  
laceration





Case: Flush , non  
reactive dilated pupil :

- a) Organophosphorus
- b) alcohol
- c) atropine

One is false  
:MISMATCHING

**COBRA: central  
respiratory failure**

كانه هيك كان الخيار بس  
باقي الخيارات الصحيحة  
كانت واضحة ف بالاستثناء  
ممکن

اسئلة الكتابي

1-Injury report: Multiple bruising at the left side chest  
above nipple



2-Identification: boy age more than 18 less than 20 based on the distal part of metacarpal and distal end of radius and ulna

جاء صورة كان بدها تدقيق وكان في فرعين  
\*كم العمر المتوقع مع التبرير  
\*في اي محكمه سيحاكم المتهم

Case presented with clinical pic of OP :  
Toxicology: organophosphorus  
poisonous

ما كان معطينا نوع السم بس معطينا الاعراض

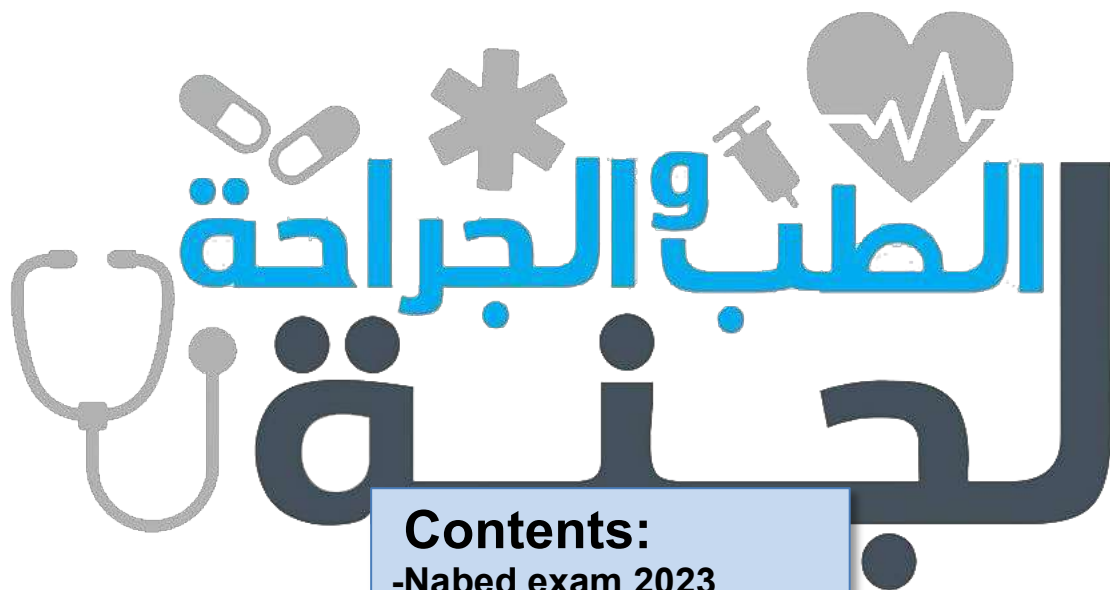1. Toxidrom                      ans: organophosphorus poisonous
2. decontamination
3. antidote

death certificate

DM & obesity presented with  
chest pain  
MI and death

# Forensic Medicine

## Final MCQs



### **Contents:**

- Nabed exam 2023
- Wareed exam 2022
- Serotonin exam 2021
- Watan exam 2020
- Exam 2018



## Nabed 2023-final MCQs

1. Seventeen year old male presents to your emergency department after accidentally ingesting a large amount of methanol. He is not suicidal. He denies any coingestion, and the paramedics did not find any pills or substances in the house. The ingestion occurred approximately four hours prior to the call to EMS. He is currently complaining of blurred vision and nausea. The following are important in the management of this case:

select one:

- a. Ethanol or fomepizole
- b. Emesis, gastric lavage, and ethanol or fomepizole
- c. Emesis, gastric lavage, activated charcoal, NaHco<sub>3</sub>, and ethanol or fomepizole
- d. Ethanol or fomepizole and NaHco<sub>3</sub>**
- e. ethanol and fomepizole

2. The following are indications of hyperbaric oxygen in CO poisoning, except:

- a. coma
- b. pregnancy
- c. Myocardial ischemia
- d. presence of neurological sequelae.
- e. Routinely indicated as it is highly effective**

3. All of the following is true about rifling except:

- a. seen by special microscope**
- b. decrease effect of gravity on bullet
- d. increase penetration power

4. wound caused by instrument with blunt edge and pointed end:

- a. punctured wound**
- b. penetrating wound
- c. transfixing wound
- d. perforation wound

5. sure sign of antemortem hanging:

**saliva dribbling**

6. Death from drowning in fresh water occurs in 3-4 minutes because of ventricular fibrillation, what is the cause of this?

**Hemodilution, overload of heart, hemolysis and release of potassium**

7. scorpion antivenom given in:

**local and systemic symptoms**

8. Body is found stiff and warm, what is the expected time of death?

**3-8 hours ago**

9. Not true about non accidental scald burn:

**ill defined margins**

10. One of the following is correct:

**simple wound does not cause permanent disability and takes less than 21 day to heal**

11. Emesis is indicated in one of the following:

a. Adult female with purpura ingested 10g of paracetamol came 1h after ingestion.????

b. child swallowed a needle

c. 5 month old swallowed 3500 mg paracetamol tablets

d. 6 year old swallowed 7g of paracetamol came after 5h

e. 6 year old swallowed 3 or 5 antihypertensive tablets came after 1h

Maybe E

12. false about fabricated wounds:

**hesitation marks**

13. Main cause of death in methanol toxicity:

**metabolic acidosis**

14. Cut wound can stimulate contused wound in:

**Axilla**

15. Hair can be used for identification of all of the following except:

**differentiation between abrasion and bruises**

16. Hyperthermia can be caused by all of the following except:

**benzodiazepine toxicity**

17. Pinpoint pupils happen in all except:

**atropine**

18. Atropinization:

**known by drying of respiratory tract secretions**

19. Incorrect matching:

**pralidoxine/carbamate**

20. Wrong about paracetamol:

**antidot can be oral or intramuscular**

21. Wrong about Wernicke's encephalopathy:

**irreversible**

22. All indicate male age 21 year except:

**iliac crest**

23. Identification of a burned body except:

**Hair**

24. Odourless substance:

**CO**

25. Wrong about ligature strangulation:

**incomplete ligature**

26. Vegetative state:

cortical death

27. Annular elastic hymen:

intercourse without rupture

28. postmortem wound:

clot usually absent if present soft

29. Wrong statement:

identical twins have identical fingerprints

30. Causes ptosis:

elapidea bite

31. postmortem lividity:

dependent parts except pressure areas

32. Not a characteristic of firearm injuries:

kinetic energy

33. Activated charcoal:

large doses of salicylate

34. Caffey syndrome:

retinal, subdural, subarachnoid hemorrhage and acute encephalopathy

35. Kerosine about gut dialysis:

coingestion with intubation

36. Abortion

all true except 4 (4 was physician, true obstetrician)

37. CO poisoning

all are true

38. Primary flaccidity:

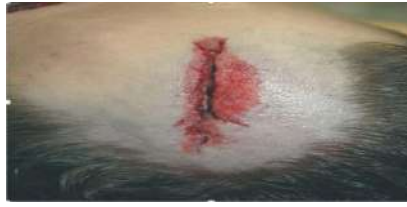all muscle voluntary and involuntary

39. Tattooing:

untuned particle

40. تقرير الاصابة: جرح رضي بأداة راضه ٥ سم بحاجة لمراقبة ٤٨ ساعة





## Wareed 2022 – final MCQs

Collected by : Monther Al-qatawneh

1- All the following characters are true for the inlet wound except:

Select one:

- a. More loss of tissues with bruising.
- b. Presence of powder marks
- c. Blood from wound tissues is positive for CO
- d. Tattoo
- e. Beveling is external XXX

2- All are characters of uterine rupture due to obstructed labour except:

- a. the site of rupture is in the lower segment
- b. it is transverse
- c. it is at the site of previous scar
- d. it is due to massive uterine contraction
- e. it is longitudinal XXX

3- All are manifestations of child abuse except:

- a. multiple lesions of cigarette burns
- b. multiple bruises of different colors
- c. sexual abuse
- d. all are correct answers XXX

4- All are manifestations of child abuse except:

- a. multiple lesions of cigarette burns
- b. multiple bruises of different colors
- c. sexual abuse
- d. all are correct answers XXX

5- All are immediate causes of death in abortion except:

- a. hemorrhage
- b. air embolism
- c. septic instrumentation XXX

6- True about composition of scorpion venom

-mainly neurotoxic XXX

7- True about snake antivenom:

- a. given to all cases of snake bites

- b. given only to systemic manifestations
- c. given in local or systemic manifestations XXX

8- True about snake antivenom:

- a. given to all cases of snake bites
- b. given only to systematic manifestations
- c. given in local or systemic manifestations XXX

9- Person hanged himself with a knot to the back of his neck, this is:

- a. typical hanging XXX
- b. Atypical hanging

10. In drowning lungs are :

- a) Congested.
- b) Pale.
- c) Congested voluminous. ???
- ☒ d) Pale voluminous. ???
- e) Pale small

11- Wrong about drowning in fresh water:

- a. hypovolemia XXX
- b. hyperkalemia
- c. causes arrhythmias
- d. death occurs faster than in salty water

12- Regarding the following: 1-Kerosine/ 2-paracetamol/ 3- corrosives/ 4- iron. Which one is an contraindication for gastric lavage:

- a. only 2 is correct
- b. 2 and 4 are correct
- c. 1 and 3 only XXX

13- One is a sure sign of drowning:

- a. coolness of the body
- b. hypostasis
- c. froth from nostrils XXX

14- In toxicology, the term "SATS" is referred to as:

-substance, amount, time, symptoms.

15- Patient came to ER with his family, complaining of confusion, agitated gait, dilated pupils and dry and hot skin.

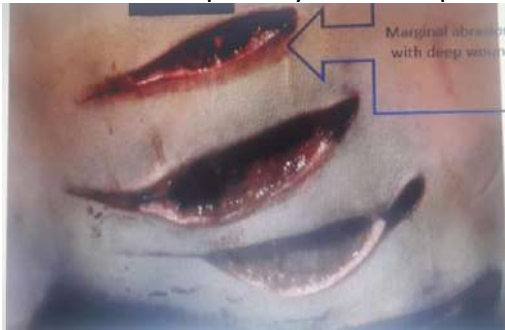Diagnosis is:

-atropine poisoning.

16- Gut dialysis is indicated in all of the following except:

- a. Theophylline
- b. salicylate
- c. digoxin
- d. barbiturate
- e. alcohol XXX

17- The correct primary wound report in Arabic is :



.....جرح قطعي متهتك باستخدام آلة راضة لها طرف حاد عدد ٣ في منطقة الإبط الأيمن ١٠ سم

18- Number of teeth for 3 years old baby ?

-20

19- Toxic effects by their metabolites except?

- a. Paracetamol
- b. OPI
- c. Methanol
- d. CO XXX

20- First line of CO toxicity?

- O2 XXX

21- Hesitation wound ?

- a. Suicidal XXX
- b. Homicidal

22- Molecular death definition?

- Molecular death is death of cells and tissues that occurs after somatic death

23- 18 female age identification?

Wrist XXX

Knee

Elbow

24- Antifreeze agent toxicity Antidote:

- Ethanol XXX

“antifreeze = methanol”

25- Internal Hemorrhage ?

- Stab wound

26- dead man in summer for 20 days ... How we identification?

- Frontal sinus XXX ... صار للمريض تعفن
- Could not be identified

27- Brain stem death ?

- Endocrinal

28- Muscarinic manifestations of organophosphates are treated with

Select one:

- a. Atropine XXX
- b. Nicotine
- c. Morphine
- d. Naloxone
- e. N-Acetylcystein

29- Cadaveric spasm :

- a. Found in all dead bodies
- b. Found only in some types of death XXX
- c. Affect all the muscles of the body
- d. Occurs sometimes after death

30- The following are indications of hyperbaric oxygen in CO poisoning, except:

- a. Coma.
- b. Pregnancy.
- c. Myocardial ischemia.
- d. Presence of neurological sequelae.
- e. Routinely indicated as it is highly effective. XXX

31- wound in eyelid healed within 20 days:

- Dangerous wound XXX
- ☒ Simple wound

32- Causes of death in hanging include all the following EXCEPT :

- a) Cerebral anemia.
- b) Reflex vagal inhibition.
- c) Laryngeal spasm. XXX
- ☒ d) Fracture first cervical vertebra.
- e) Pushing the tongue base against the posterior pharyngeal wall.

33- Oximes are:

- a) Cholinesterase reactivators that should be used within 24-48 hours after carbamate or organophosphate exposure.
- b) Competitive antagonists to acetyl choline that are used in organophosphate toxicity only
- c) Cholinesterase reactivators that should be used within 24-48 hours after carbamate exposure.
- d) Competitive antagonists to ACh that are used in organophosphate and carbamate toxicity within 24-48h.
- e) Cholinesterase reactivators that should be used within 24-48 hours after organophosphate exposure only. XXX



## Final Forensic 2021

1- All the following characters are true for the inlet wound except:

Select one:

- a. More loss of tissues with bruising.
- b. Presence of powder marks
- c. Blood from wound tissues is positive for CO
- d. Tattoo
- e. Beveling is external XXX

2- The following are considered as conditions of true consent in rape except:

Select one:

- a. Sane
- b. Full conscious.
- c. No fraud.
- d. No thread.
- e. Age below 18 years old XXX

3- Fabricated wounds are characterized by the following except:

Select one:

- a. Multiple and superficial.
- b. Sparing the clothes.
- c. At safe area within the reach of the hands.
- d. Eye injury is rare to occur.
- e. May be of different depths.XXX

4- Fomepizole is:

Select one:

- a. Antidote for ethanol toxicity.
- b. Antidote for cyanide toxicity.
- c. Cheap antidote in comparisons with other antidotes.
- d. Has CNS depressant effect.
- e. Not easily available XXX

5- Traumatic rupture of uterus due to criminal abortion is characterized by the following Except:

Select one:

- a. It is longitudinal
- b. It is transverse XXX
- c. The site of rupture is usually the fundus
- d. It usually takes the shape of the instrument
- e. It is due to insertion of foreign body into uterus

6- Death due to H<sub>2</sub>S exposure is a type of:

Select one:

- a. Histotoxic anoxia. XXX
- b. Stagnant anoxia.
- c. Anoxic anoxia.



- d. Anemic anoxia.
- e. Irritant anoxia.

7- The following are types of sharp force injuries except:

Select one:

- a. Stab wound.
- b. Cut wound.
- c. Puncture wound.
- d. Hesitation marks.
- e. Fabricated wounds. XXX

8- Mummification occurs when the climate is

Select one:

- a. Dry
- b. Dry and hot XXX
- c. Moist and warm
- d. Moist and cold
- e. Cold

9- After a quarrel between 2 young males, one of them with injured that lead to amputation of the distal phalanges of the little finger of the left hand. The wound healed in 18 days. This wound is:

Select one:

- a. Fatal wound.
- b. Simple wound.
- c. Dangerous wound. XXX
- d. Stab wound.
- e. Lacerated wound.

10- Death certificate is forbidden to be issued in the following except:

Select one:

- a. Suicide
- b. Accident
- c. Death of unknown cause
- d. Death in which physician wasn't in attendance XXX
- e. Death appears as criminal act

12- As regard CO toxicity: 1- Common in winter. 2- Symptoms correlate with carboxy Hb level. 3- Easily misdiagnosed. 4- Binds to iron containing proteins

Select one:

- a. All are true.XXX
- b. All are true except 3.
- ☒ c. All are true except 2.
- d. All are true except 2 and 3.
- e. All are true except 2 and 4.

13- Putrefaction is accelerated in death from

Select one:

- a. Septic abortion
- b. Gas gangrene

- c. Septicemia
- d. Burial in clay moist soil
- e. All mentioned answersXXX

14- Hypostasis becomes fixed?

Select one:

- a. At moment of death.
- b. One to two hours after death.
- c. About eight to ten hours after death.XXX
- d. One to two days after death.
- e. About eight to ten days after death.

15- The following could be a source of cyanide exposure except

Select one:

- a. Certain plants as apple seeds.
- b. Fire.
- c. Antihypertensive drugs.
- d. Button battery. XXX
- e. Fumigants.

16- Miosis are found in all the following, except

Select one:

- a. Carbolic acid
- b. Atropine XXX
- c. Organophosphates
- d. Opiates
- e. Alcohol

17- Powder marks are present:

Select one:

- a. Around the inlet only XXX
- b. Around the exit only
- c. Around both inlet and exit
- d. Deep in the tissues at the injury.
- e. Around the inlet and cloths covering it.

18- Fingerprints at the scene of the crime may be: 1-plastic. 2- patent. 3-latent. 4- sure. 5-probable

Select one:

- a. Yes all are true.
- b. Yes all are true except 4 and 5. XXX
- c. Yes all are true except 1, 2, and 3.
- d. All are false.
- e. All are false except 2 and 3 are true.

19- An disoriented patient who opened eyes to pain and had decerebrate extension, his Glasgow coma score is?

Select one:



- a. 7
- b. 8 XXX
- 8.9
- d. 10
- e. 11

20- All the following characters are true for the inlet wound except:

Select one:

- a. More loss of tissues with bruising.
- b. Presence of powder marks
- c. Blood from wound tissues is positive for CO
- d. Tattoo
- e. Beveling is external XXX

21- Treatment of kerosine poisoning includes the following except

Select one:

- a. demulcent ingestion
- b. Artificial respiration
- c. Gastric lavage with endotracheal intubation XXX
- d. Antibiotics for treatment of infection
- ☒ e. Forced diuresis

22- A male was stung with a scorpion. His age was 32 years old. His vital

signs were blood pressure: 130/70, pulse: 85/min regular, respiratory rate: 13/min, and temp: 37 C. no local or systemic manifestations. For prophylactic purposes, the physician gave him 3 vials of antivenom IV over 10 mins. As regard this management:

Select one:

- a. Is true as antivenom is indicated for all scorpion stings.
- b. Is true as scorpion sting is very dangerous in adult.
- c. Is false as no antivenom is indicated non manifested case. XXX
- d. Is false as only one vial indicated as prophylactic treatment.
- e. Is false as 3 vials is indicated IM only.

23- Cholinergic toxidromes include all the following, except

Select one:

- a. Salivation, lacrimation, diarrhea and urination
- b. Muscle fasciculation
- c. OpisthotonusXXX
- d. miosis
- e. Emesis

24- Corrosive acid poisoning is best treated by:

Select one:

- a. Stomach wash
- b. purgatives
- c. Dialysis



- d. Emesis
- e. None of all mentioned answersXXX

25- The following are true regarding Wernicke's encephalopathy except:

Select one:

- a. Triad of eye muscles affection and ataxia, confusion, and amnesia.XXX
- b. Vitamin B1 deficiency.
- c. Vitamin B6 deficiency. A and C
- d. Chronic ethanol intoxication.
- e. Reversible .

26- In a case of suicidal firearm wound in the right temple, the direction is suspected to be

Select one:

- a. To the left and upwardsXXX
- b. To the left and downwards
- c. To the right and upwards
- d. To the right and downwards
- e. Downward through chin

27- Muscarinic manifestations of organophosphates are treated with

Select one:

- a. AtropineXXX
- b. Nicotine
- c. Morphine
- d. Naloxone
- e. N-Acetylcystein

28- The following are sure signs of drowning except:

Select one:

- a. Froth.
- b. Cadaveric spasm.
- c. Diatoms.
- d. Foreign bodies in the respiratory passages.
- e. Rapid rate of cooling of the bodies.XXX

29- Cadaveric spasm

Select one:

- a. Found in all dead bodies
- b. Found only in some types of deathXXX
- c. Affect all the muscles of the body
- d. Occurs sometimes after death

30- Tracheal intubation is essential before gastric lavage except

Select one:

- a. Kerosine poisoning
- b. ParacetamolXXX
- c. Comatose patient



- d. Convulsion
- e. Patient with absent gag reflex

31- Seventeen years old male presents to your emergency department after accidentally ingesting a large amount of methanol. He is not suicidal. He denies any coingestion, and the paramedics did not find any pills or substances in the house. The ingestion occurred approximately four hours prior to the call to EMS. He is currently

complaining of blurred vision and nausea. The following are important in the management of this case: Select one:

- a. Ethanol or fomepizole. XXX
- b. Emesis, gastric lavage, and ethanol or fomepizole.
- c. Emesis, gastric lavage, activated charcoal,  $\text{NaHCO}_3$ , and ethanol or fomepizole.
- ☒ d. Ethanol or fomepizole and  $\text{NaHCO}_3$ .
- e. Ethanol and fomepizole.

32- Manifestations of acute pesticide toxicity appear more rapid after

- a. InhalationXXX
- b. Ingestion
- c. Skin contact
- d. Rapidity is similar in all routes of exposure.
- e. None of all mentioned

33- Young female was found dead in the desert. Forensic expert reported that she was raped before death and the cause of death was due to head trauma that cause intracranial hemorrhage.

The forensic expert ascertained that she was under 15 years old. This was due to:

- a. X ray on the pelvis showed nonunion of pubis, ischium, and ilium. XXX
- b. X ray on the pelvis showed union of Y shaped suture in the acetabulum.
- c. X ray of the wrist joint showed union of metacarpal bone.
- d. Dental examination showed erupted wisdom teeth.
- e. No given answer is correct.

34-The following are signs of postmortem suspension except:

- a. Cause of death is other than hanging.
- b. History of threatening by enemies.
- c. Hypostasis in the back.
- d. Presence of signs of struggle.
- e. Dribbling of saliva.XXX

35- The following are manifestations of habitual passive sodomite except

- a. The anus is funnel or conical in shape.
- b. There may be healed or active anal fissure.
- c. Presence of usual mucosal folds.XXX
- d. Anal sphincter loses its tone.
- e. Rectal swab may contain traces of lubricant or semen

36- One of the following is not the immediate cause of death in criminal abortion:

- a. Hemorrhage
- b. Septic instrumentationXXX
- c. Reflex vagal inhibition of the heartd. Amniotic fluid embolism.

e. Air embolism

37- As regard Palestine snake bite, 1-Vasculo-toxic. 2- Clotting profile should be monitored. 3- Monovalent antivenom are used in Jordan. 4- Local effects are common. 5- Local tourniquet is highly effective.

- a. All are true except 3.
- b. All are true except 3 and 5.XXX
- c. All are true except 4 and 5.
- d. All are true except 3, d and 5.
- e. All are true.

38- The following are indications of hyperbaric oxygen in CO poisoning except.

Select one:

- a. Coma.
- b. Pregnancy.
- c. Myocardial ischemia.
- d. Presence of neurological sequelae.
- e. Routinely indicated as it is highly effective.XXX

39- As regard the union of epiphysis and metaphysis of long bone:

Select one:a. Occurs in all bones at the same time.

- b. Occurs in distal and proximal end of the same bone at the same time.
- c. Occurs in same limb at the same time.XXX
- d. Can be seen on both X ray and by naked eye examination.
- e. Is not accurate method of estimation of age in adolescent.

40- Limb injuries in child abuse doesn't include?

Select one:

- a. Avulsion of metaphysis.
- b. Ring fractureXXX
- c. Spiral fracture.
- d. Fractures at any site in diaphysis, may be multiple
- e. Slipped epiphysis

## Final Forensic 2020

Done by: Abrar Sarairah

1- Young female was found dead in the desert. Forensic expert reported that she was raped before death and the cause of death was due to head trauma that cause intracranial hemorrhage. The forensic expert ascertained that she was under 15 years old. This was due to:

- a) X-ray on the pelvis showed nonunion of the Y shaped suture in the acetabulum. XXX
- b) X-ray on the pelvis showed union of Y shaped suture in the acetabulum
- c) X-ray of the wrist joint showed union of metacarpal bone.
- d) Dental examination showed erupted wisdom teeth.
- e) No given answer is correct.

2. Traumatic rupture of uterus due to criminal abortion is characterized by the following Except:

- a) It is longitudinal
- b) It is transverse XXX
- c) The site of rupture is usually the fundus
- d) It usually takes the shape of the instrument
- e) It is due to insertion of foreign body into uterus

3. The following are true regarding cadaveric spasm except:

- a) It occurs after death XXX
- b) Occurs in group of muscles only
- c) Lasts till putrefaction occurs.
- d) May indicate the cause of death.
- e) Does not occur in involuntary muscles

4. The following could be a source of cyanide exposure except:

- a) Certain plants as apple seeds
- b) Fire.
- c) Antihypertensive drugs
- d) Fumigants.
- e) Button battery. XXX

5. Causes of death in hanging include all the following EXCEPT

- a) Cerebral anemia.
- b) Reflex vagal inhibition.
- c) Laryngeal spasm. XXX
- d) Fracture first cervical vertebra.
- e) Pushing the tongue base against the posterior pharyngeal wall.

6. An disoriented patient who opened eyes to pain and had decerbrate extension, his Glasgow coma scale score is?

- a) 7
- b) 8 XXX
- c) 9
- d) 10
- e) 11



7. Death due to CO<sub>2</sub> exposure is a type of:

- a) Histotoxic anoxia.
- b) Stagnant anoxia.
- c) Anoxic anoxia. XXX
- d) Anemic anoxia.
- e) Irritant anoxia.

8. Cut wound may simulate lacerated wound:

- a) If occurs in scrotal area or by sharp weapon with irregular edge as broken glass XXX
- b) if has marginal bruises.
- c) If has crushed hair at the wound edges.
- d) If has severe bleeding.
- e) Cut wound never simulate lacerated wound.

9. In drowning lungs are :

- a) Congested.
- b) Pale.
- c) Congested voluminous. XXX
- ☒ d) Pale voluminous.
- e) Pale small

10. Edges of inlet of bullet are everted in all of the following cases Except?

- a) Contact firing
- b) Near firing
- c) Ricocheting bullet XXX
- d) Fatty area
- e) After putrefaction

11. A patient presented with the following symptoms and signs: diarrhea, urination, miosis, bradycardia, bronchospasm, sweating. It is mostly representing:

- a) Opioid toxidrome
- b) Cholinergic toxidrome. XXX
- c) Sympathomimetic toxidrome
- d) Anticholinergic toxidrome.
- e) No given answer is correct.

12. Seventeen years old male presents to your emergency department after accidentally ingesting a large amount of methanol. He is not suicidal. He denies any co-ingestion, and the paramedics did not find any pills or substances in the house. The ingestion occurred approximately four hours prior to the call to EMS. He is currently complaining of blurred vision and nausea. The following are important in the management of this case:

- a) Ethanol or fomepizole. XXX
- b) Emesis, gastric lavage, and ethanol or fomepizole.
- c) Emesis, gastric lavage, activated charcoal, NaHCO<sub>3</sub>, and ethanol or fomepizole.
- ☒ d) Ethanol or fomepizole and NaHCO<sub>3</sub>.
- e) Ethanol and fomepizole.

13. Fabricated wounds are characterized by the following except:

- a) Multiple and superficial
- b) Sparing the clothes
- c) At safe area within the reach of the hands
- d) Eye injury is rare to occur.
- e) May be of different depths XXX

14. Among the conditions in which a female is examined for signs of virginity is- are

- a) Alleged rape.
- b) Alleged impotence of the husband.
- c) Alleged non virginity of the wife.
- d) Alleged rape or impotence of husband or non-virginity of the wife. XXX
- e) Fimbriate hymen.

15. The following are true regarding Wernicke's encephalopathy except:

- ☒ a) Triad of eye muscles, ataxia, and confusion.
- b) Vitamin B1 deficiency.
- ☒ c) Vitamin B6 deficiency. XXX
- d) Chronic ethanol intoxication.
- e) Reversible.

16. The following are true regarding bruises except:

- a) Always appear at the site of trauma. XXX
- b) May take the shape of the causal instrument.
- c) Type of the covering skin affect its size.
- d) Type of underlying tissue affect its size.
- e) Undergoes color changes.

17. Rope marks in strangulation are

- a) Less marked than in hanging. XXX
- b) Oblique symmetrical.
- c) Transverse asymmetrical
- d) High in the neck.
- e) Incomplete.

18. All of below are characteristic to lacerated wound EXCEPT...

- a) Abrasions and bruises at edges
- b) More liable to sepsis
- c) Profuse bleeding. XXX
- d) Crushed hair at the edges.
- e) Caused by blunt instrument.

19. The commonest type of hymen.....?

- a) Semilunar. XXX
- b) Cribriform.
- c) Septate.
- d) Imperforate.
- e) Arche.

20. Limb injuries in child abuse doesn't include?

- a) Avulsion of metaphysis
- b) Ring fracture XXX
- c) Spiral fracture.
- d) Fractures at any site in diaphysis, may be multiple
- e) Slipped epiphysis

21. You have examined these children in emergency department, which one is mostly

not exposed to physical abuse:

- a) Child with a fracture of the left ulna with burn in the right leg.
- b) Child with 3 bruises in back, right arm, and leg with different ages.
- c) Child with 2 separate cigarettes burn in the shoulder.
- d) Child with rupture frenulum
- e) Child with fracture of left tibia. XXX

22. Oximes are:

- a) Cholinesterase reactivators that should be used within 24-48 hours after carbamate or organophosphate exposure.
- b) Competitive antagonists to acetyl choline that are used in organophosphate toxicity only
- c) Cholinesterase reactivators that should be used within 24-48 hours after carbamate exposure.
- d) Competitive antagonists to ACh that are used in organophosphate and carbamate toxicity within 24-48h.
- e) Cholinesterase reactivators that should be used within 24-48 hours after organophosphate exposure only. XXX

23. Characters of contused wounds don't include:

- a) Multiple angles
- b) Brushed hair
- c) Irregular angles
- d) low liability to sepsis XXX
- e) Abraded edges

24. Postmortem hanging is characterized by the following EXCEPT:

- a) Dribbling of saliva XXX
- b) Signs dragging of the body
- c) Signs of struggle
- d) Another cause of death other than hanging.
- e) Hypostasis may not be in the lower limb.

25. The following are true regarding CO poisoning except:

- a) It does not cause cyanosis. XXX

- b) It is easily misdiagnosed.
- c) It is treated only with hyperbaric oxygen.
- d) It is a silent killer.
- e) It is common in Jordan.

26. Therapeutic abortion:

- a) Done only in hospitals, with written consent, reports indicate the cause of abortion, and done by specialist XXX
- b) With reports indicating the cause of the abortion, it could be done in any clinic.
- c) Done in hospital by specialist only whatever the cause of abortion.
- d) Could be done for pregnant female with down syndrome infant.
- e) No given answer is correct.

27. One of the following is not the immediate cause of death in criminal abortion:

- a) Hemorrhage
- b) Septic instrumentation XXX
- c) Reflex vagal inhibition of the heart
- d) Amniotic fluid embolism
- e) Air embolism

28. Stippling present around firearm entry wound is due to:

- a) Unburned particles. XXX
- b) Grease.
- c) Hot gases.
- d) Smoke.
- e) Flame.

29. Induction of emesis is contraindicated in the following conditions except:

- a) Coma.
- b) Child less than 6 months.
- c) Corrosives ingestion.
- d) Hyperthermia. XXX
- e) Foreign body ingestion.

30. As regard for a case of rape, the conditions in which consent is true, she must be.....

- a) Above 18 years without threatening Sane.
- b) Above 16 years without threatening Sane.
- c) Above 18 years without threatening Sane and conscious. XXX
- d) Above 16 years without threatening Sane and conscious.
- e) Above 16 years without threatening Sane and conscious.

31. Twenty-five aged female patient admitted to Poison Center with following vital signs; BP 70/40, pulse 140, T 36°C, RR 30/min. He ingested organophosphates. The first line of treatment is?

- a. GIT decontamination
- ☒ b. ABC.
- c. Atropine administration XXX
- d. Atropine and oximes. Oximes only.

32. Diagnosis of brain death is dependent upon all of the following EXCEPT:

- a. Dilated fixed pupil
- b. No spontaneous breathing



- c. Flat ECG XXX
- d. Flat EEG
- e. Absence cranial nerve reflexes

33.The following true regarding hypostasis except:

- a. A sure sign of death
- b. Its site depends on the position of the body.
- c. In drowning, it occurs in the lower part of the body. XXX
- d. Helps in estimation of the time of death.
- e. Becomes brown in death due to methemoglobinemia

34. At the age 18 in female, all the following will be found in X-ray EXCEPT.....?

- a. Union of medial epicondyle of humerus.
- b. Union of metacarpal bones.
- c. Union of head of femur.
- d. Union of lower end of tibia with shaft.
- e. Union of iliac crest. XXX

35.As regarding dental print, the following are true except:

- a. It is cheap, accurate, and rapid method.
- b. Need antemortem record.
- c. Depends on the comparison of antemortem record and postmortem record.
- d. Useful in every case. XXX
- e. Dentist's records are essential.

36.Digital examination of the passive partner of habitual sodomy reveals the following EXCEPT:

- a. Loss of elasticity and tone of anus
- b. Lax and patulous anus
- c. Loss of anal sphincter reflex
- d. Funnel shaped anus XXX
- e. Absence of pain

37.During covid-19 pandemic, a 5 years child accidentally drink a small amount of chlorine which is widely used as a household disinfection. His family rapidly transferred him to emergency department to Karak Hospital. Emergency physician rapidly admitted the child and a gastric tube was applied to perform gastric wash. As regard the physician practice:

- a. It is a good practice to prevent absorption and decrease toxicity.
- b. It is a good practice, but physician should give activated charcoal at the end of the lavage.
- c. No, gastric lavage is not indicated in this case as the child drink small amount.
- d. No, gastric lavage is not indicated for fear of aspiration and more esophageal injury. XXX
- e. No, as gastric lavage is contraindicated in age less than 6 years.

38.The Following true regarding disadvantages of visual identification of a victim except:

- a. Psychic shock.
- b. Not suitable in severe burn.
- c. Need confirmation by scientific method.



- d. Is not useful in closed disaster. XXX
- e. Not useful in severe trauma.

39. After a quarrel between 2 friends, one of them was injured that lead to amputation of the distal phalanges of the little finger of the left hand. The wound heals in 18 days. This wound is:

- a. Fatal wound.
- b. Simple wound.
- c. Dangerous wound. XXX
- d. Stab wound.
- e. Lacerated wound

40. The following are sure signs to diagnose drowning as a cause of death except:

- a. Planktons.
- b. Foreign bodies in respiratory tracts.
- c. Rapid rate of cooling of the body.
- d. Pale lung. XXX
- e. Unpalatable water in the stomach.

## Final 2018

- 1 - Wrong about fractures in child abuse : ring fracture
- 2 - Investigation not used in child abuse : fundoscopy
- 3 - Affinity of CO to myoglobin: 60 times
- 4 - Case ... child with decrease visual acuity: methanol toxicity
- 5 - Action of DMAP : increase methaemoglobin
- 6 - Contracted pupils, state of narcosis, pupils back to normal after pinching the neck ; alcohol toxicity
- 7 - Wrong about inspection of passive partner of sodomy ; Sphincter by inspection
- 8 - Age 23 years ; xray of clavicle & iliac crest
- 9 - Wrong about liver support in acetaminophen toxicity; administration of vitamin E
- 10 - Everted inlet in firearm wound except; ricocheting bullets
- 11 - Radiographic sign of intrauterine death except ; collapse of the spine
- 12 - Antidote of inhalation route ; amyl nitrite
- 13 - Trucking sign ; eyes
- 14 - Rigor mortis start in : eyelids
- 15 - Features of OPI except; mydriasis
- 16 - Wrong about alcohol toxicity; hyperreflexia
- 17 - Wrong about contused wound ; low liability for sepsis
- 18 - Most common sign in strangulation : Bleeding from mouth and nose
- 19 - Wrong about muscarinic activity except: salivation :: يعين لك الجاابت غلط بس هاي حص
- 20 - Temperature 31 , Time since death: 4 hours
- 21 - Stippling around the inlet in firearm wound ; unburned particles
- 22 - Treatment for OPI: Airway .. fluid .. atropine... pralidoxime
- 23 - Wrong about bruises; intravascular
- 24 - Rat hole >> firearm distance >> (.15-2m )
- 25 - Reactive dilated pupil in sympathomimetic

- 26 - Traumatic uterus rupture wrong >> transverse
- 27 - In hemorrhage death except >>> relaxed spleen
- 28 - Wrong about scalds in child abuse : unusual sites Rectal temperature changes after : Non of the above
- 29 - GCS 10 " Eye pain 2 , Disoriented 4 , Pulls hand 4 "
- 30 - Froth leathery >> drowning
- 31 - Salivation ante-mortem sign of hanging
- 32 - Fimbriate symmetrical
- 33 - Septate no medicolegal importance
- 34 - Pin point pupil morphine
- 35 - Constricted pupil with stimulation alcohol
- 36 - Sniffing cocaine
- 37 - Child drink liquid methanol
- 38 - First sign of death corneal opacity
- 39 - Somatic death constricted pupil
- 40 - Site of fracture in child abuse : parieto-occipital

- 33 y male who bite by snake (frank bite)and not notified it , his family membrane apply ice on site of bite then take him to ER,the doctor say that he is completely free , give him single dose of antivenom and discharge him.
- mention 2 wrong behaviour
- what is the antivenom that use in jordan??
- Why did he not show any symptoms even though the snake bit him?

- 1) give him single dose of antivenom(no symptom)/ apply ice on site of bite (cryotherapy)
- 2) polyvalent
- 3) Non-venomous viper/dry bite





Archive forensic medicin

Wateen

الطبيب والجراحة  
لجنة



1)Blackening ?

- a. Smoked ...
- b. Flamed
- c. Muzzle

2)Primary rifled ?

- a.Longitudinal Signs on bullet after fired ...
- b. Signs on inlet
- c. Signs on inner non-rifled barrel
- d. Signs on inner rifled barrel

3)18 years old - male , incorrect ... ?

- a. Head of femur
- b. Phalanges
- c. Metacarpals
- d. Lower head of radius ....

4)Gloves and stockings hypostasis ?

- a.Drowning
- b.Hanging .....

5)1st site in putrefaction??

Right iliac fossa

6)False in fingerprint ??

Genetic determines the print

7) Palestine snake all true except?

- a.bulbar palsy...
- b.Local manifestation
- C.Edema



8) All are competitive antagonists except??

- a. Atropine/nerve gases
- b. Atropine/organophosphorus
- c. Naloxone/opioids
- d. Flumazenil / benzodiazepines
- e. Oximes/organophosphorus.....

8) Organophosphorus poisoning..2 hours

- 1 Induce emesis
  - 2 Oxygen
  - 3 Ingesting large amount of milk
  - 4 Xray
  - 5 Barium swallow
  - 6 Endoscopy
- a. All true
  - b. Only 2,4,6 true....
  - c. All true except 1,5

9) Ethanol found in body after death due to:

- a) Antemortem ingestion.
- b) only in diabetic patient
- c) Postmortem fermentation ...

10) True about salicylate??

Liver toxicity by metabolite ...

11) Early complication of corrosive :

- a. Neurogenic shock ....
- b. Strictures
- c. Cancer

12) the scorpion stings are dangerous more in children , because ?

- a.Hypersensitivity reaction
- b.Thin skin
- C.Delay to seek treatment
- d.Low body weight....

13)Drug toxicity case with tachycardia and dry skin and non reactive dilated pupils

This case of ?

anticholinergic toxicity...

14)Tram track (//) appearance injury iduced by?

- a.Coin
- b.Tram
- c.Rod....

15)Alcohol when given as antidote for methanol , what is the mechanism of action?

- a.Reduce methanol metabolites....
- b.Increase methanol metabolites
- c. Increase secretion of methanol

16)Case of organophorous poisoning(with its signs )

All can be given except?

- a.Atropine
- b.Oxime
- c.O<sub>2</sub>
- d.Fluid
- E. AC....

17)All are signs in of hanging except?

- a.Transverse ....
- b.Incomplete
- C.Patterned ligature
- d.Situated above thyroid

18) Goose skin sign of ?



- a.Drowning
- b.Immersion....

19)Subdural hematoma and subarachnoid hematoma and retinal involvement with encephalopathy

Its case of ?

- a.Called shaken baby syndrome and indicates child abuse ✓
- b.Called shaken baby syndrome and when accompanied with corner or bucket handle fracture indicate child abuse

21)Lady comes to ER due to trauma and vaginal hemmorage

And when you examined her the uterus appears enlarged

What you suspecte?

- a.Criminal abortion due to trauma....
- b.Spontaneous abortion
- c.Therapeutic induce abortion
- d.Hydatiform mole

)Traumatic rupture uterus site ,one is true?

- a.Longitudinal in fundus .....
- b.Longitudinal in lower segment
- c.Transverse in fundus
- d.Transverse in lower segment
- E.Anywhere

23) CO poisoning, 55 years old, o2 99%, unconscious:

- 1- Oxygen 100%
- 2- Oxygen not indicated
- 3- Hyperbaric oxygen due to coma.....
- 4- Hyperbaric oxygen due to the age of patient

24)Drowning in fresh water or salty water case?

faster death in Fresh water

25)Gut dialysis for salicylate?

- a.Elimination, decrease absorption
- b.Decrease absorption
- c.Treat acidosis
- d.Decrease absorptionTreat acidosis