

# Archive Ortho 7

1) What is this dermatome indicate (L3)

A. Ankle jerk  
B. Dorsiflexion  
C. Knee jerk


Ans : C



2) What is the type of this fracture


A. Transitional fracture  
B. Segmental fracture  
C. Communitied fracture

Ans : B



3) Case of lumbar canal stenosis what is the difference between vascular and neurovascular claudication (Choose the correct answare)


Ans : Downhill more painfull



4) What is the managment of this fracture

A. Short cast  
B. Long cast  
C. Closed reduction  
D. Closed reduction , wires and cast

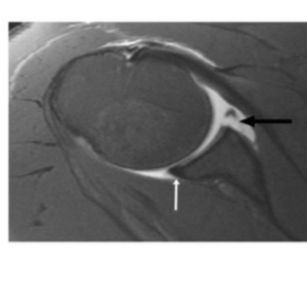
Ans : D



5) On of the folloving true about this lesion

A. Anterior inferior labrum , bankart lesion  
B. Anterior inferior labrum , hill sach lesion  
C. Anterior superior labrum , bankart lesion


Ans : A



6) 1-What is false about the condition in this picture ?

A-flexed posturing of the involved digit  
B-tenderness to palpation over the tendon sheath  
C-marked pain with passive extension of the digit  
D-fusiform swelling of the digit  
E-presence of superficial tender nodules on the palm of the hand

Answer : E

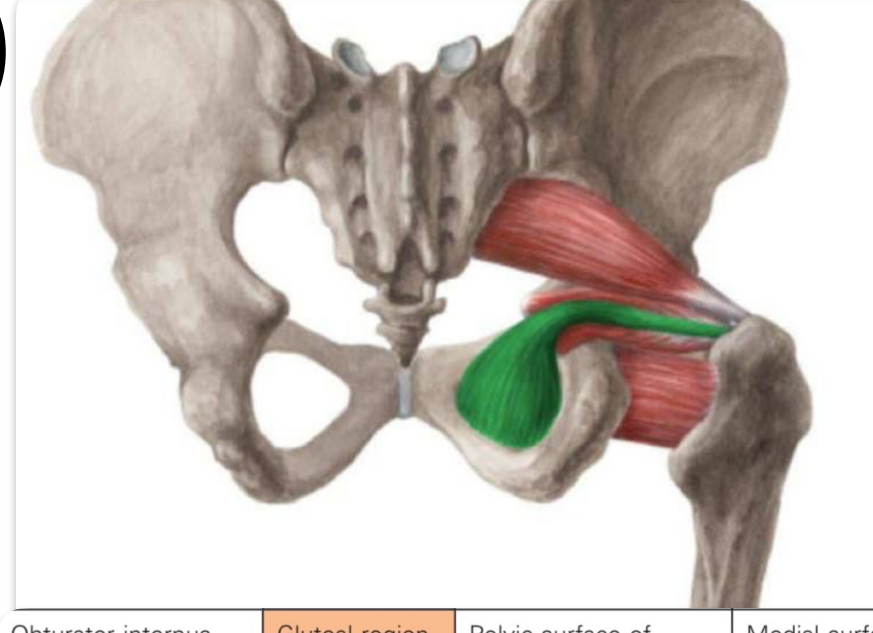


7) Child came to the ER with his parents complaining of hip pain since 24 hours, he is stable , he has slightly high temperature, wbc:120000,ESR:80 , what is the first thing you will do

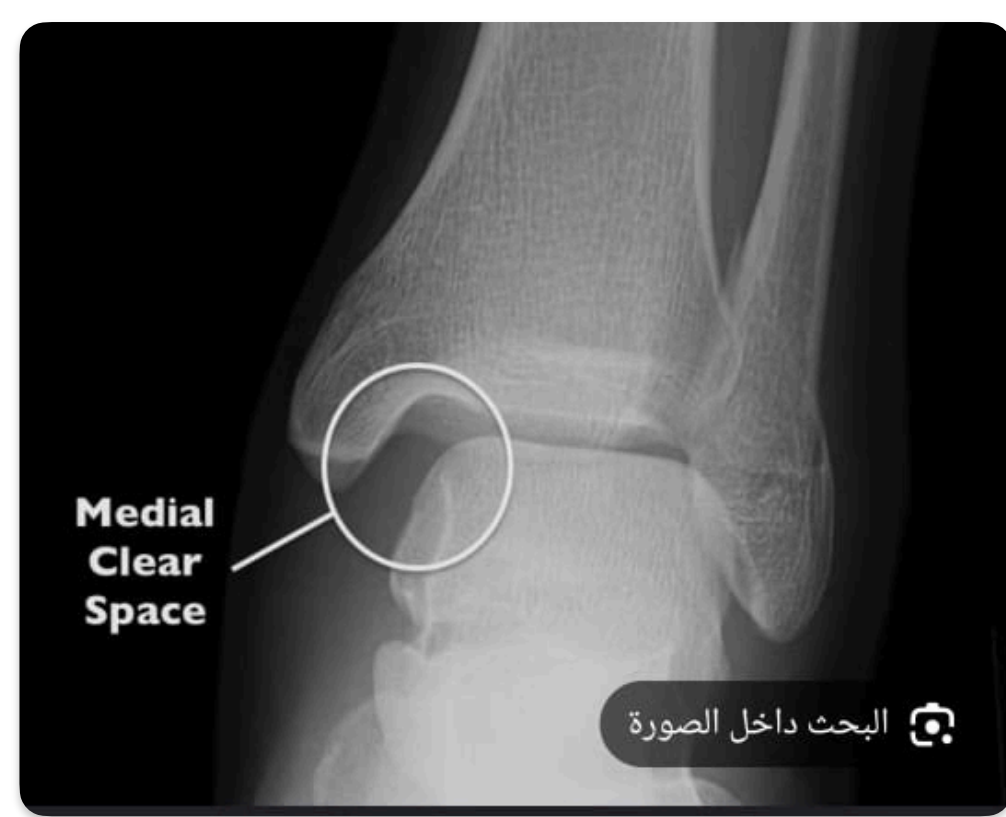a-admission  
b-antibiotic  
c-admission and observation  
d-arthrotomy and wash out  
e-analgesia



8)

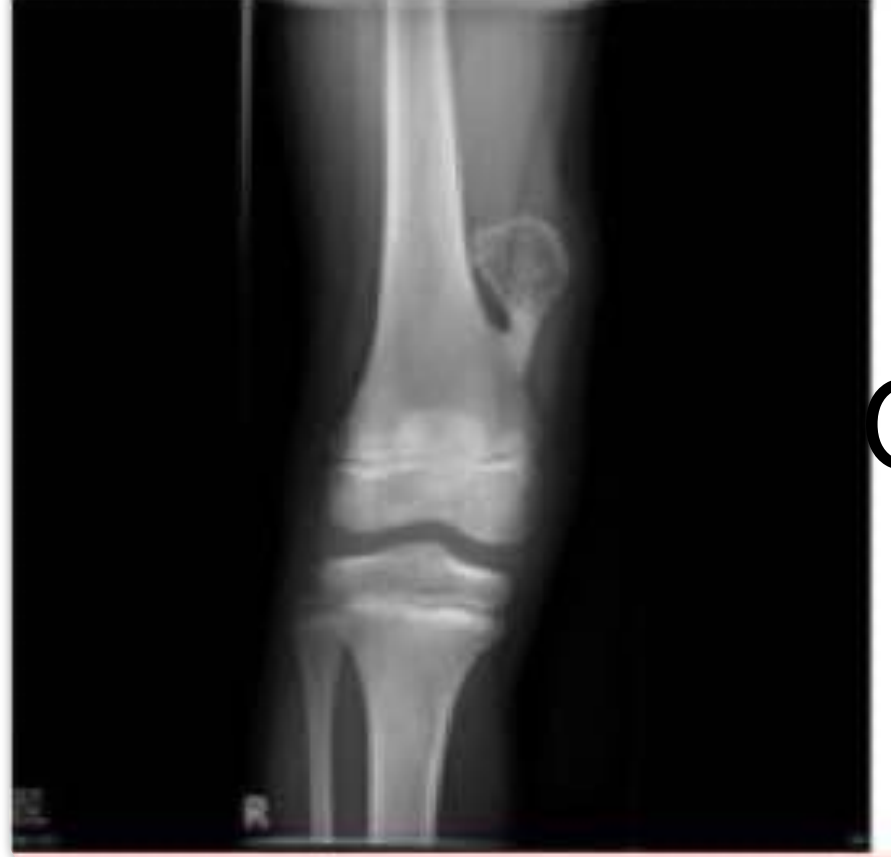

Obturator internus    Gluteal region    Pelvic surface of obturator membrane and surrounding bone    Medial surface of greater trochanter of femur    Nerve to obturator internus muscle



9) ligament affected??

Anterior talofibular ligament  
Posterior talofibular ligament  
Deltoid ligament

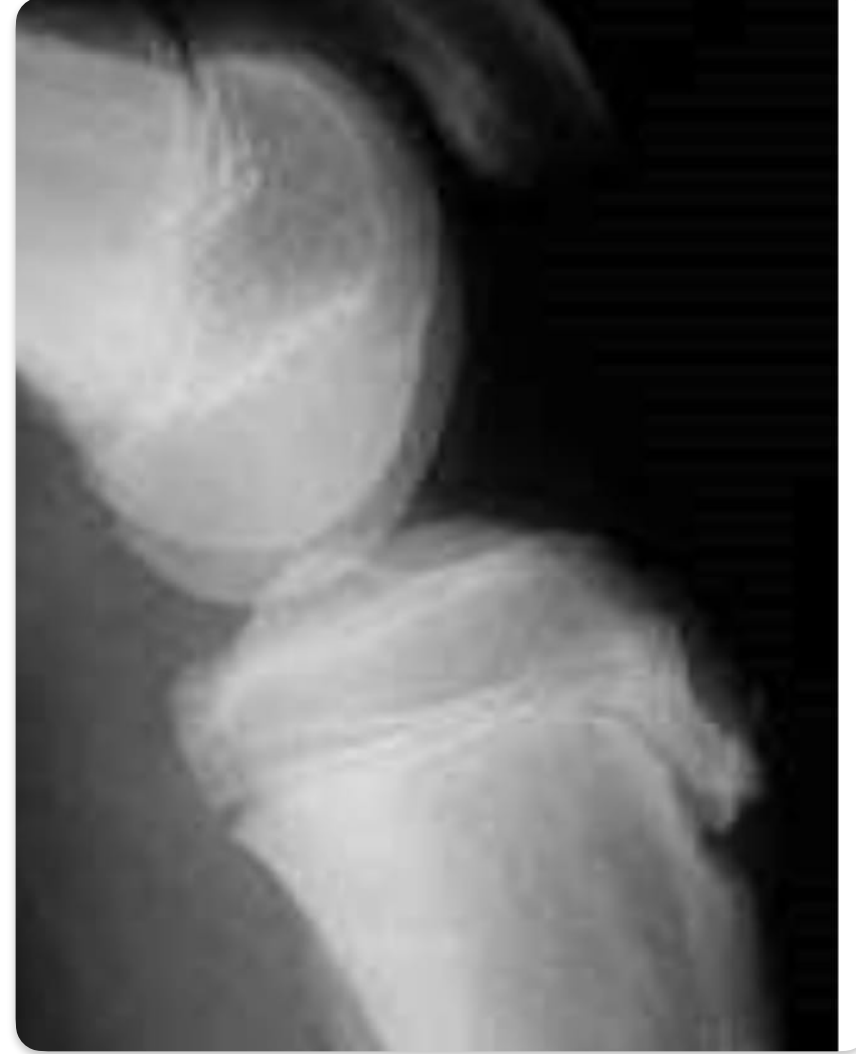


10) diagnosis??

Osteochondroma

11)

Fracture type	Mechanism	Examination/ deformity	Classification
Calcaneus	High energy axial loading (fall from height)	- delayed function loss (inversion & eversion) ارتشيف	Senders



12) clinical finding??


Tibial tuberosity tenderness

13)

5-In what position is the shoulder locked in this picture ?

A-adduction  
B-abduction  
C-external rotation  
D-internal rotation  
E-extension

Answer: not sure but I think it is abduction



14) one is false about achilis tendinitis ??  
Compromised dorsiflexion of foot

Patient with a trauma history

What is your diagnosis ?  
Ruptured Achilles tendon

Muscles of the affected structure are  
Superficial posterior muscles

Which of the following is not associated with Achilles tendon tear ?  
a. Positive squeeze test  
b. Palpable gap at the site of rupture  
c. Compromised dorsiflexion of the foot

Management  
Achilles tendon rupture repair



15)


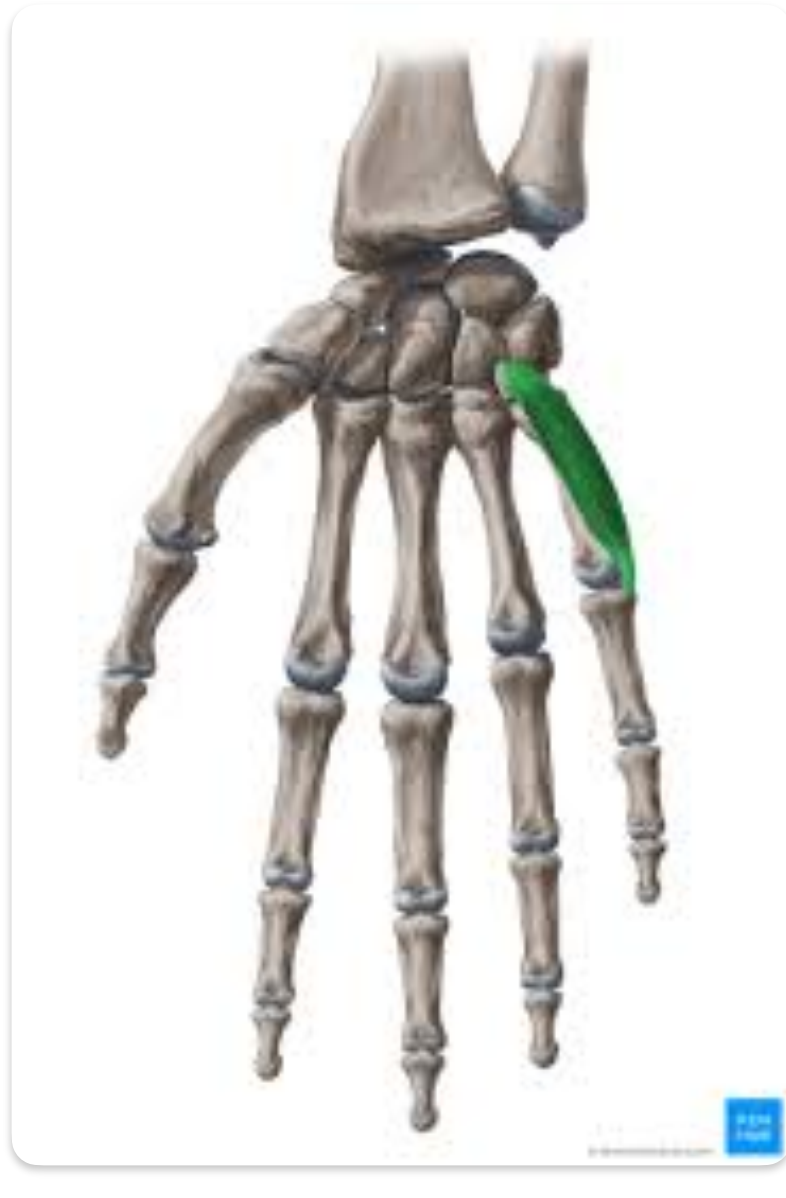
13 - salter Harris type 2

16) What is the most likely diagnosis

A. Acute SCFE  
B. Perthes  
C. DDH  
D. Osteonecrosis

Ans : A




17)true about this muscle ??

Cause flexion and lateral rotation

18)elderly with hip fracture, the most effective treatment???

Total hip replacement

19) false about rickets??

Treatment mainly by surgery