

Radiology final exam MCQs

Done by: abdullah hattab

1) The most reliable sign of direct lobar collapse:

- A) Hilar displacement.
- B) Elevation of the diaphragms.
- C) Crowding of vascular markings.
- D) Displacement of the interlobar fissure.*****
- E) Shift of mediastinal structures.

2) The following represent anterior mediastinal masses, except:

- A) Lymphoma
- B) Thymic tumor
- C) Retrosternal goiter
- D) Bronchogenic cyst*****
- E) Morgagni hernia

3) MRI is the technique of choice for imaging the following except :

- A) Spinal cord
- B) Acute brain Hemorrhage******
- C) Ligaments
- D) Tendons
- E) White matter disease.

4) The use of gastrografen is indicated in the following, except:

- A) Suspected bowel perforation
- B) Meconium ileus in neonates
- C) In Barium swallow if the patient is at risk of aspiration*****
- D) In Barium enema study for volvulus
- E) Post operative patients for leakage.

5) Which of the following is correct causing small bowel fluid level:

- A) Small bowel obstruction
- C) Paralytic ileus.
- D) Hypokalemia.
- E) Gastro- enteritis.
- F) All of the above.*****

6) Vesico-ureteric reflux is frequently associated with :

- A) Acute pyelonephritis
- B) Chronic Pyelonephritis*****
- C) Bladder tumor
- D) Cystitis
- E) Emphysematous cystitis

7) The best imaging test to diagnose the complication of appendicitis is :

- A) Plain Abdomen film erect and supine*****
- B) Ultrasound

- C) CT scan with contrast
- D) Barium Enema
- E) Barium follow through

8) Gall-bladder wall thickening can be caused by the following , except:

- A) Acute cholecystitis
- B) sclerosing cholangitis
- C) Liver cirrhosis
- D) **Ascites*****
- E) Gall bladder cancer

9) The following statements are correct except:

- A) The gastro-duodenal artery lies postero-medial to the first part of the Duodenum.
- B) **In brain CT, contrast enhancement is essential in the acute post- Trauma scan.*****
- C) C) The apex of the heart is usually elevated when the right ventricle is enlarged
- D) In infantile hypertrophic pyloric stenosis , the length of the pyloric Channel should be more than
15 mm.
- E) Renal cell carcinoma is increased in patients with polycystic kidney Disease.

10) Which of the following congenital renal anomaly predispose the kidney to infection and stone

formation :

- A) Ectopic kidney
- B) **Horse-shoe kidney*****

- C) Crossed ectopia
- D) Renal Duplication
- E) Renal hypoplasia

11) The following are intra-axial posterior fossa tumors in children except:

- A) Astrocytoma
- B) Ependymoma
- C) Medulloblastoma
- D) Epidermoid tumors*****
- E) Brain stem glioma.

12) The following statement are correct except:

- A) Subdural hematoma is a collection of blood between the dura and arachnoid membrane.
- B) Brain metastasis is most common at the grey-white matter junction.
- C) Bronchiectasis in the upper lobes occur mainly in cystic fibrosis.
- D) The polycystic kidney disease of the new born appear on ultrasound as enlarged kidneys with multiple cysts of varying size.*****
- F) In multiple sclerosis, MRI is the first line imaging investigation

13) The following statements are correct except:

- A) In chest x-ray, a pneumonia that obliterate the heart border is located In the lingular segment of the upper lobe.

B) In Ba. Swallow, the marked dilatation of the esophagus with "beaked" narrowing distally indicate esophageal tumor.***

C) The tip of the endotracheal tube should be at least 5cm above the carina.

D) CBD usually joins pancreatic duct as a common duct within the duodenal wall.

E) In plain abdomen film, the presence of small bowel obstruction and gas in the biliary tree indicate

gallstone ileus.

14) The use of intra-venous contrast medium is contra indicated in:

A) Patient with bronchial asthma.

B) Patient with high blood urea and creatinine*.**

C) Elderly patients

D) Diabetic patients.

E) Small children.

15) Which of the following is correct about epidural hematoma.

A) most often occur as a result of venous injury

B) Typical appearance of concavo-convex on CT scan

C) Collection of blood between the skull vault and the dura*.**

D) Usually located at the fronto-temporal region

E) Usually associated with Subarachnoid hemorrhage.

16) The following are radiological features of rheumatoid arthritis except:

A) Subcondral sclerosis*.**

B) Soft tissue swelling.

- C) Joint space narrowing.
- D) Erosions at the joint margins.
- E) Subluxations.

17) The presence of gas in the wall of the urinary bladder indicate:

- A) Cystitis.
- B) Vesico- intestinal fistula.
- C) Following instrumentation.
- D) Large bladder tumor.
- E) Emphysematous cysti***

18) The following are characteristic of degenerative disc disease except:

- A) Disc prolapsed***.
- B) Osteophytes formation.
- C) Subcondral sclerosis.
- D) Narrowing of the disc space.
- E) Gas formation within the degenerated disc.

19) All the following are true except:

- A) Tc DTPA is the best for dynamic kidney scan.
- B) Tc DMSA is the best for static kidney scan.
- C) Tc DMSA is the best for dynamic kidney scan.
- D) Tc DTPA scan is an indication for renal artery stenosis.
- E) Tc DTPA scan is an indication for transplant kidney.

20) All the following are true except:

- A) Tc-99m half- life is 6 hrs.
- B) Tc-99m Gamma ray have 140 Kev.
- C) Tc-99m can be used for thyroid scanning.
- D) Tc- DMSA can be used for static kidney.
- E) Tc- DTPA scan can be used for thyroid scan.

21) Unilateral elevated hemidiaphragm can be caused by the following except:

- A) Phrenic nerve palsy.
- B) Eventration.
- C) Subphrenic abscess.
- D) Collapse in the lower lobe.
- E) Large ascites***.

22) The following are characteristic of Degenerative disc disease except:

- A) Disc prolapse.***
- B) Narrowing of the disc space.
- C) Osteophytes formation.
- D) Subcondral sclerosis.
- E) Gas formation within the degenerative disc.

**23) Subarachnoid hemorrhage means hemorrhage in all the following structures
Except:**

- A) Basal cisterns.
- B) Cerebral sulci.
- C) Brain parenchyma***.
- D) Sylvian fissure.
- E) Interhemispheric fissure.

24) Which is the correct answer:

- A) Tc- MDP bone scan is the best for multiple myeloma.
- B) X- Ray is the best for multiple myeloma.
- C) X- Ray is the best for bone metastasis.
- D) Tc- DTPA is the best for multiple myeloma.
- E) Tc- MDP scan is the best for renal artery stenosis.

25) All the following are true except:

- A) Osteoporosis in dexta scan is when T- scan - 2,7
- B) Osteopenia in dexta scan is when T- scan -1,5
- C) Osteopenia in dexta scan is when T-scan + 2***
- D) Normal dexta scan is when T- scan more than + 1
- E) Normal dexta scan is when T- scan -,2

26) In congenital dislocation of the hip, the following are correct except:

- A) The femur is displaced supero-laterally from the acetabula.
- B) More common in breech babies.
- C) More common in girls than boys.

D) The angle of the acetabular roof should be less than 30 degrees***.

E) The vertical line (Perkins line) should not intersect the femoral metaphysis.

27) Which is the correct answer:

A) Tc MDP bone scan is indicated in Osteoid osteoma.

B) Tc MDP bone scan is indicated in Paget's disease.

C) Tc MDP bone scan is indicated in Ewing sarcoma.

D) Tc MDP bone scan is indicated in Ca prostate.

E) All of the above. ***?

28) The following statements are correct except:

A) Malignant gastric ulcers are more commonly in the greater curvature.

B) Giant ulcers (> 3cm) are mostly benign.

C) The majority of duodenal ulcers occur in the first part of duodenum.

D) The most common location of duodenal diverticulum is in the second part of the duodenum.

E) Malignant gastric ulcers usually project beyond the gastric contour***.

29) Ba.enema is contra- indicated in the following except:

A) When there is free intraperitoneal air.

B) If toxic megacolon is suspected

C) In peritonitis

D) When bowel perforation is suspected.

E) In suspected obstructing lesion.***

30) In appendicitis, the following are correct except:

- A) On ultrasound, the appendix is dilated (> 7mm) and non compressible.
- B) On plain film, lumbar scoliosis convex to the left side usually present.
- C) On plain film, local ilius in right lower quadrant usually seen.
- D) Enlarged and clustered lymphadeopathy in mesentery and right lower quadrant seen in CT****.
- E) Periappendiceal fat changes are usually present in CT.

31) The following statements are correct except:

- A) The jejunal loops are usually larger than the ileal loops.
- B) Ultrasound is the best test to diagnose gallstones.
- C) The superior mesenteric vein lies to the right of the superior mesenteric artery.
- D) In intravenous urogram (IVU), prone film usually demonstrate the ureters more successfully.
- E) Hirschsprung's disease is caused by the presence of ganglion cells in the wall of a portion of the colon***.

32) In emphysema, the following are correct excpt:

- A) The lungs appear expanded and more radiolucent.
- B) There is reduction in the size and number of small vascular markings.
- C) The heart shadow is long and narrow.
- D) The postero- anterior diameter of the chest is increased.
- E) The diaphragms are high and convex in shape.***

33) Which of the following statements is correct ?

- A) The small cell tumors of the lungs are frequently associated with mediastinal and hilar adenopathy.***
- B) Pneumocystis carini pneumonia is particularly common in patients following Solid organ transplant.
- C) Metastases in the lung usually present with irregular margin.
- D) The plain CT scan (without intravenous contrast) is commonly used to evaluate intra-abdominal injury.
- E) Pulmonary tuberculosis is frequently present in the posterior segments Of the lower lobes.

34) The radiological signs of brain atrophy on CT / MRI are the following except :

- A) Dilated ventricles.
- B) Increased cerebro-spinal fluid space.
- C) Loss of grey- white matter differentiation.***
- D) Widening of the brain sulci
- E) Dilated basal cisterns

35) The following statements are correct except :

- A) in bacterial pneumonia all the radiographic abnormalities should resolve after 4--6 weeks of appropriate antibiotic therapy***
- B) A normal appearing pancreas on Ultrasound exclude pancreatitis.
- C) Lung metastasis tend to be at the bases and periphery of the lungs.
- D) The early findings of ulcerative colitis on barium enema is mucosal granularity.
- E) CT is not a good test for diagnosing acute cholecystitis.

36) ALL the following are signs of heart failure on chest x-ray except :

A) Cardiomegaly

B) Pericardial effusion***

C) Interstitial / alveolar edema

D) Kerly B line _ Horizontal septal lines in the lower zone.

E) Cephalization of blood flow.

37) The following statements are correct except: ?

A) The valvulae conniventes are circumferential transverse folds found in the Jejunum.

B) In suspected toxic toxic megacolon, barium enema is contraindicated.

C) Oxygen toxicity cause pulmonary edema.

D) CT is the imaging modality of choice for diagnosis splenic injuries.

E) Cephalization of blood flow seen in chest x-ray is one of the radiographic signs of pulmonary arterial hypertention.

38) The following statements are correct except:

A) The left kidney, may normally be 2cm longer than the right kidney.***

B) In acute pyelonephritis, the enhanced CT scan reveal enlarged kidney with areas of markedly decreased enhancement.

C) MRI of the brain is contraindicated in a gunshot injury.

D) The acute subdural hematoma appear on CT scan as hyperdense collection with concave medial border.

F) The most common intracranial findings of child abuse is intra-cerebral hemorrhage.

39) The following statements are correct except:

- A) Cysts in the liver are frequently associated with polycystic kidney disease.
- B) The normal caliber of the abdominal aorta should not exceeds 3cm.
- C) The most common cause of bladder outlet obstruction in infant boy, is posterior urethral valve.
- D) Active plaques of demyelination in multiple sclerosis usually enhance with contrast medium.
- E) Patients with polycystic kidney disease who are undergoing dialysis are not at risk for development of renal malignancy.****

40) The following statements are correct except:

- A) The preliminary (control) film is usually not required for Ba. Enema examination.

- B) In hyaline membrane disease the volume of the lungs are decreased.
- C) Voiding (micturating) cystogram is the gold standard for imaging posterior Urethral valve
- D) The vascular structure present immediately behind the pancreas is the Splenic vein.
- E) Plain abdomen film reveal about 10 to 20% of stones in the gallbladder as they are radio-opaque.

41) all the following are true about radiological features of Rickets, except:

- a. widened metaphysis
- b. bowing of the legs.
- c. thinning of periostium.
- d. enlarged end of ant ribs
- e. multiple healed fractures may be present

42) The following are true regarding intussusception in children, except:

- a. barium enema is diagnostic and therapeutic.
- b. ileo-ileal type is commonest type.
- c. pseudo-kidney sign is seen transversely on U/S
- d. presented with abdominal pain and red current jelly stool
- e. hypertrophied peyer's patches is the usual cause.

43) The following are false regarding pyloric stenosis, except:

- a. CT abdomen is the imaging study of choice.
- b. Pyloric diameter of 10 mm is diagnostic.
- c. Double bubble sign on plain film
- d. presented 8 to 12 weeks with gastric outlet obstruction
- e. Shouldering sign with severe stenosis.

44- All the following are true regarding urinary tract imaging, except :

- a. gas within the bladder wall is seen in diabetics with cystitis
- b. Calcified bladder wall is seen in leishmaniasis
- c. Cystitis is often caused by hematogenous spread of infection.
- d. Micturating cystogram is best imaging for VU reflux
- e. For bladder tumours staging CT is performed

45- Regarding renal stone disease, all the following are false except

- a. hypercalcaemia is a prominent finding
- b. Cystine stones are not visible on CT.

- c. 80-90% of stones are seen on plain KUB.
- d. Dilated pelvicalyceal system is seen on plain film
- e. Staghorn calculi can be easily missed on IVU

46- In renal tumours, all are true except :

- a. Polycystic kidney disease and chronic renal failure predispose to renal cell carcinoma.
- b. Hypernephroma is the most common malignant renal tumour
- c. RCC is bilateral in 7% of cases.
- d. On CT, RCC appears as a poorly defined hypodense area.
- e. Bening renal tumour appear hyperdense on CT

47- All the following are true in G.I.T imaging, except :

- a. Barium sulfate is the most common used contrast media
- b. If leakage or perforation is suspected, gastrografin contrast is used.
- c. Double contrast barium meal can identify peptic ulcer disease
- d. In sliding diaphragmatic hernia, the gastro-esophageal junction is in place
- e. In infants, Barium swallow is done using non ionic contrast media.

48- In small bowel obstruction, the following is true except :

- a. Dilated loops of jejunum show valvula conniventes
- b. Most common cause is postoperative adhesions.
- c. Air-fluid levels appear on supine plain film
- d. Absent gases in the colon
- e. Dilation of small bowel up to 3 cm is considered normal.

49- All the following are radiological of osteoarthritis, except :

- a. Joint space narrowing.
- b. Loose bodies may be seen within the joint
- c. Bony spurs at the margin of joint.
- d. Subchondral thinning and osteopenia
- e. 2ry cystic degenerations

50- All the following are true regarding skeletal system imaging, except:

- a. Soft tissue swelling is the earliest sign of osteomyelitis
- b. Normal finding excludes acute osteomyelitis
- c. Staphylococcus aureus is the most common cause.
- d. CT or MRI is required for accurate diagnosis
- e. Plain film may show periosteal reactions

Final exam - wateen

By: Ammar Adaileh & Tareq Abu Lebdah

1- Image of normal CT scan , what is the wrong correlation :

Splenium of corpus callosum (the arrow was on genu of corpus callosum)

2- Image of CT scan of territory of anterior cerebral artery infarction , what is true regarding

that :

It is due to occlusion of anterior cerebral artery

3- Scenario of 44 year old had sudden loss of consciousness Image of subarachnoid hemorrhage , what is wrong regarding that :

Normal ventricular system

4- Scenario of motorcycle accident and CT image of depressed fractures and contusions and

edema at brain , what is wrong about that :

bilateral anterior infarction

5- Image of CT angio what is diagnosis :

basillar artery stenosis

6- Image of Ultrasound at upper pole of kidney with hypo-echoic lesion what is wrong about

that :

there is cyst at lower pole of kidney.

7- Image of ultrasound with Paracalyceal Cyst , true regarding that :

Paracayceal cyst (Not sure)

8- Image of horse shoe kidney , what is dx ?

horse shoe kidney

9- Image of staghorn stone , What is true regarding that :

staghorn stone

10- Image of CT or MRI (not sure) of abdomen with points of calcification (not sure if it is stone at ureter or phlebolith at vein) , what is true :

This is image of MRI Abdomen ??!!! or left renal stone ?!!!

11- Image of cystogram grade 4 (الجواب و الخيارات ناسي)

12- True regarding lymph node involvement at Sarcoidosis :

bilateral hilar lymphadenopathy

13- most common cancer associated with lymphadenopathy :

Small cell lung cancer

14- Radio-opacity scilouting left border of heart :

lingular segment of upper lobe of left lung

15- Not sign of pulmonary edema : Pericardial effusion

16- not cause of infant respiratory distress :

dextrocardia

17- not risk factor for allergy from contrast :

TB

18- Not true regarding chest xray :

miliary tb mainly affect upper lobes

19- most common segment of lower lobe affected by tb :

superior segment

20- not a cause of unilateral elevation of diaphragm :

huge ascitis

21-not cause of obstructed type of lung collapse :

pleural effusion

22-most common injury associated 1st ribs fracture :

vascular injury

23-most common complication of middle ribs injury :

pneumothorax

24-not a cause of posterior mediastinal mass :

ascending aorta aneurysm

25- true regarding barium swallow :

esophageal study

26- wrong regarding radiological finding of rickets :

there is no osteopenia

27- wrong regarding CDH :

right is more common than left

28 -most common cause of large bowel obstruction :

cancer

29-best initial test for skeletal trauma :

plain xray

30- most common cause of air underdiaphragm :

perforated bowel

31- wrong regarding xray of abdomen :

gas at biliary tree with intestinal obstruction exclude gallstone ileus

32- wrong regarding mammogram :

screening mammogram for detecting unusual changes of the breast

33-wrong statement : normal thoracic aorta diameter :

3.5-4 cm

34- true regarding Nuclear medicine :

tc-99m half life is 6 hour

35- most common cause of small bowel obstruction :

adhesion

36- wrong regarding nuclear medicine :

TC-99m DMSA used for bone scanning

37- True regarding isotopes :

TC-99m half life = 6 hours ++ Iodine 131 half life = 8 days

38-barium meal used for following except :

colon cancer

39- multiple myeloma is :

cancer of plasma cell

40- Chest xray with pneumothorax and air-fluid level at costophrenic angle , what is the dx :

Hydropneumothorax

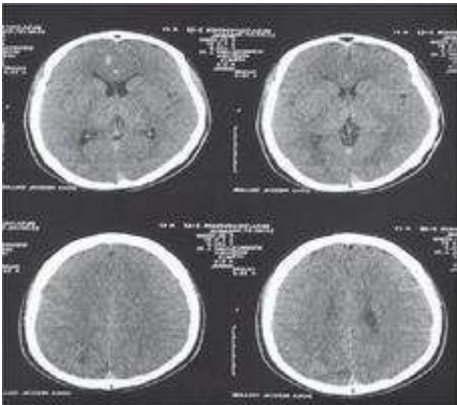
Radiology final exam - Serotonin 2021

1-A 39 YO women has intermittent right upper quadrant pain, which is worse after meals. Which of the following ultrasonographic signs is most diagnostic of acute cholecystitis?

Select one:

- a. Fluid around the gallbladder.
- b. A thickened gallbladder wall of 0.5 cm.**
- c. Gallbladder distension to 8 cm.
- d. Gas within the gallbladder wall.
- e. Cholelithiasis.

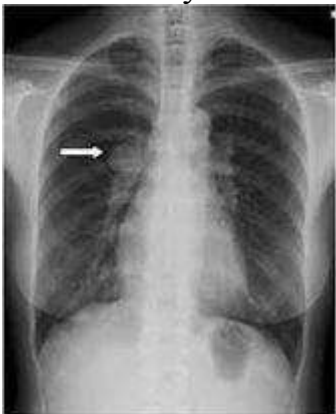
2-REGARDING THIS BRAIN CT ONE IS TRUE:



Select one:

- a. THERE IS NORMAL VENTRICULAR SIZE.
- b. IT IS A NORMAL BRAIN CT FOR PEDIATRIC AGE GROUP.
- c. SYMMETRICAL NORMAL SULCI IN BOTH SIDES.
- d. NORMAL DENSITY OF THE GREY/WHITE MATTER BILATERALLY.
- e. IT IS A CRITICAL FINDING.**

3-in this xray one is true



Select one:

- a. IT IS AP CHEST XRAY.
- b. IT IS A CASE OF ESOPHAGAL ATRASIA.
- c. THERE IS RT MEDIASTINAL MASS SILLHOUTING RT PARATRACHAL LINE.**
- d. THE INFLAMMATORY CAUSE IS NEVER BE A CAUSE FOR THIS RT MASS.
- e. IT IS MIDDLE MEDIASTINAL MASS.

4-One of the following is not a predisposing factor of contrast-induced nephrotoxicity:

Select one:

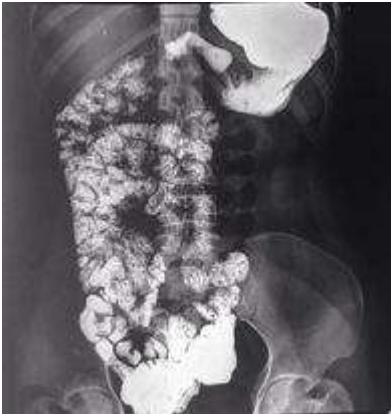
- a. Dehydration.
- b. Diabetes mellitus.
- c. Hypertention.
- d. Multiple myeloma.
- e. Very large dose of contrast media.

5-Best imaging modality for posterior urethral valve is:

Select one:

- a. Ultrasound
- b. Ct scan.
- c. Voiding cystourethrogram.
- d. IVU.
- e. MRI.

6-REGARDING THIS IMAGE ALL THE FOLLOWINGS ARE FALSE EXCEPT ONE



Select one:

- a THE PATIENT PRESENTS USUALLY WITH BILLIOUS VOMITING
- b. THE PATIENT USUALLY DIAGNOSED INCIDENTALLY
- c. THERE IS SMALL BOWEL OBSTRUCTION
- d. IT IS ILEAL ATRESIA
- e. IT IS A CROHNS DISEASE

7-Which one of the following radiological examinations does not need contrast media:

Select one:

- a. CT abdomen to rule out renal stone.
- b. CT abdomen to rule out renal tumor.
- c. CT abdomen to rule out liver metastasis.
- d. MRI to rule out Brain Abscess.
- e. Chest CT scan to rule out pulmonary embolism.

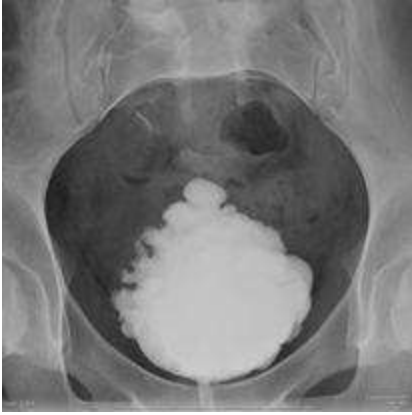8-All of the followings are TRUE except one:

Select one:

- a. 99m Tc-DTPA can be used for kidney function scan.

- b. 99m Tc-DTPA can be used for bone scan.
- c. 99m Tc-MAG3 can be used for kidney function scan.
- d. Renal stenosis can be diagnosed by 99m Tc-DTPA or 99m Tc-MAG3.
- e. 99m Tc-DTPA can be used for transplant-kidney scan if there is an infarction.

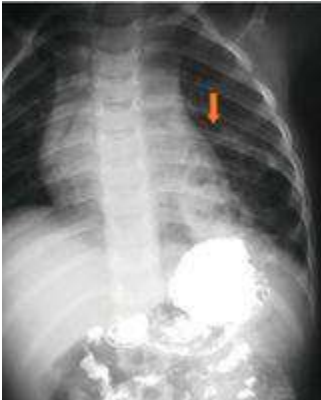9-REGARDING THIS PELVIC VIEW, ALL THE FOLLOWINGS ARE FALSE EXCEPT ONE:



Select one:

- a. IT IS NEUROGENIC BLADDER.
- b. THERE IS LARGE URINARY BLADDER STONE.
- c. IT IS IVU STUDY.
- d. IT IS URETHROGRAM STUDY.
- e. THE PATIENT USUALLY PRESENTS WITH ROLLING PAIN.

10-IN THIS CHEST ABDOMEN PELVIS VIEW ,ONE IS TRUE:



Select one:

- a. NON OF THE OTHER ANSWER CHOICES IN THIS QUESTION IS TRUE
- b. IT IS A BARUIM MEAL STUDY
- c. IT IS A CYSTIC FIBROSIS OF RT LUNG
- d. DIAPHRAGM SURGICAL REPAIR IS RECOMMENDED
- e. DIFFERENTIAL DIAGNOSIS AFTER THIS STUDY IS CCAM AND DIAPHRAGMATIC HERNIA

11-A 55-year-old man presents with 3 days of severe epigastric pain. His lab investigations show mild leukocytosis and elevated lipase and amylase levels. What imaging should you obtain next in the evaluation of this patient at this time?

Select one:

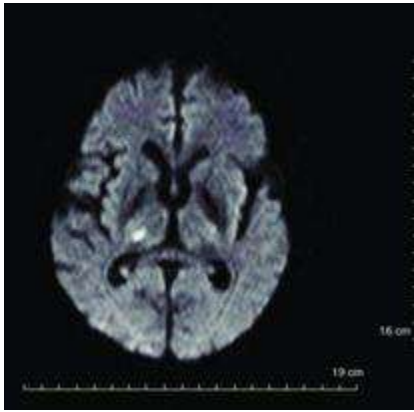
- a. Contrast enhanced abdomen and pelvis MRI
- b. Small bowel follow-through series.
- c. PA chest X-ray.
- d. Abdomen ultrasound.
- e. Barium enema.

12-The most common cause of pneumothorax is:

Select one:

- a. Chest injury.
- b. Lung tumor.
- c. Pneumonia.
- d. Fibrosis.
- e. TB.

13-Select the true statement :



Select one :

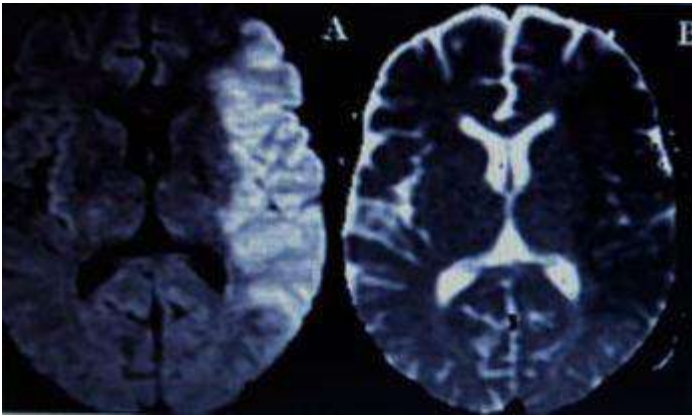
- a. THIS IS RT THALAMUS INFARCTION !!
- b. THIS IS RT THALAMUS HEMORRHAGE
- c. THIS IS RT INTERNAL CAPSULE INFARCTION
- d. THIS IS BASAL GANGLION HEMORRHAGE
- e. IT IS AROUND 2 WEEKS AGE INSULT

14-MOST common cause of large bowel obstruction :

Select one:

- a. Tumor of the large bowel.
- b. Inflammatory bowel disease.
- c. Adhesions.
- d. Ischemia.
- e. GB stone.

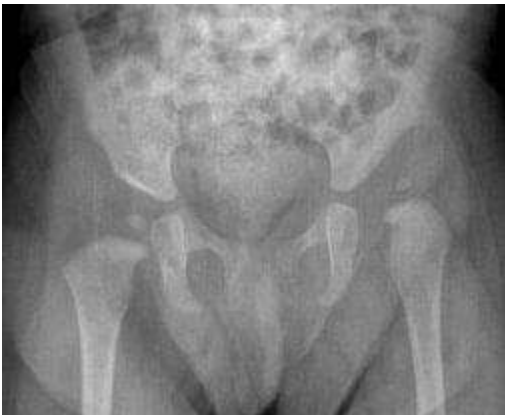15-REGARDING THIS IMAGE ALL ARE FALSE EXCEPT:



Select one:

- a. THERE IS HEMORRHAGE IN THE RT PARIETAL LOBE.
- b. THERE IS HEMORRHAGE IN THE LT PARIETAL LOBE**
- c. THERE IS INFARCTION IN THE RT PARIETAL LOBE
- d. THERE IS INFARCTION IN THE LT PARIETAL LOBE
- e. THE ONSET OR CHRONICITY CAN'T DETERMINED BY THIS IMAGE AT ALL

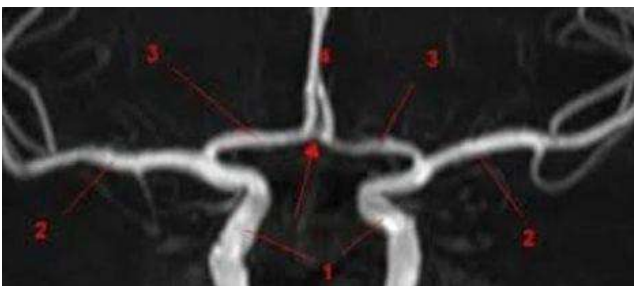16 -REGARDING THIS PELVIS XRAY ONE IS TRUE:



Select one:

- a. IT IS LT PERTHS DISEASE.
- b. IT IS LT SLIPPED CAPITAL FEMURE EPIPHYSIS
- c. IT IS LT DDH**
- d. IT IS RT DDH.
- e IT IS RT PERTHS DISEASE

17-ALL THE FOLLOWINGS ARE FALSE EXCEPT ONE:

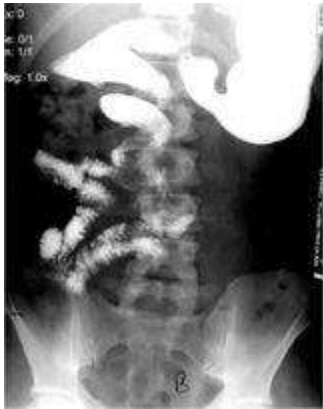

Select one: ?

- a. THIS IS DIGITAL SUBTRACTION ANGIO.
- b. NUMBER ONE RELATED TO VERTEBRAL ARTERIES.

- c. NUMBER THREE RELATED TO PCOM.
- d. NUMBER FOUR RELATED TO ACA
- e. THERE IS NO STENOSIS IN THE RT INTERNAL CAROTID ARTERY.

18-REGARDING THIS IMAGE ONLY ONE IS TRUE:



Select one:

- a. THE PATIENT PRESENTS USUALLY WITH BILLIOUS VOMITING.
- b. THE PAIENT USUALLY DIAGNOSED INCIDENTALLY
- c. BA MEAL IS NOT CONTRAINDICATED IF THERE IS SUSPECTED PERFORATION.
- d. THE PATIENT PRESENTS USUALLY WITH NON BILLIOUS PROJECTILE VOMITING.
- e MANAGEMENT BY (WAIT AND SEE)

19-All of the followings are TRUE except one:

Select one:

- O a. 99m Tc-MDP can be used for bone -metastasis treatment.
- b. 99m Tc-MDP can be used for bone -scanning.
- c. 99m Tc-HDP can be used for bone -scanning.
- d. 99m Tc-MDP can be used for bone -metastasis detection.
- e. The dose of 99m Tc-MDP for bone -scanning is 15-25 mCi IV. injection. (RIGHT 15-20)

20.One is a primary feature of degenerative disc disease:

Select one:

- a. Disc space widening.
- b. Reduced vertebral height.
- c. Osteophyte formation.
- d. Early lysis of the end plates.
- e. Pars interarticularis defect.

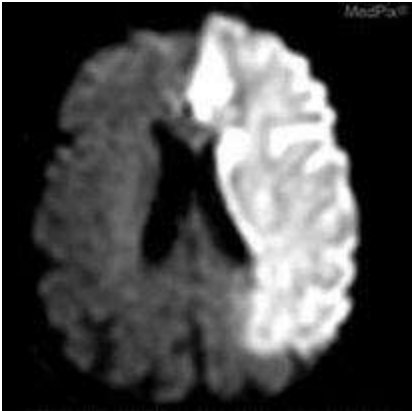
21-In a patient with back pain, plain x-ray can detect all of the following EXCEPT:

Select one:

- a. Degenerative disc disease.
- b. Sacralization.
- c. Disc herniation.
- d. Facet joint osteoarthritis.

e. Spondylolisthesis.

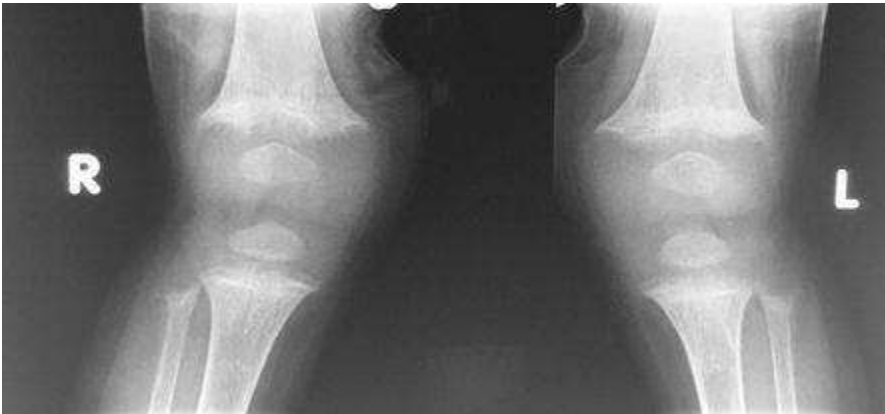22-56 YEAR OLD MALE WITH RT HEMIPARALYSIS, ALL THE FOLLOWINGS ARE FALSE EXCEPT:



Select one:

- a. IT IS RT ICA INFARCTION
- b. IT IS NON HEMORRHAGIC CONTUSION
- C. IT IS LT VERTEBRAL INFARCTION
- d. IT IS RT MCA INFARCTION
- e. IT IS LT ICA INFARCTION

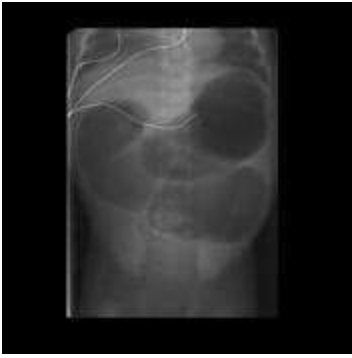23-REGARDING THIS KNEE XRAY ALL THE FOLLOWINGS ARE FALSE EXCEPT ONE:



Select one:

- O a. THERE IS BONY LYTIC LESION.
- O b. IT IS A CASE OF NON ACCIDENTAL TRAUMA.
- C. THERE IS METAPHYSAL FRACTURE.
- d. IT IS NORMAL XRAY FOR SUCH AGE
- e. IT IS A CASE OF RICKET.

24-NEW BORN BABY PRESENTED WITH VOMITING AFTER FEEDING ,ONE OF THE FOLLOWINGS IS TRUE:



Select one:

- O a. IT IS A DOUBLE BUBBLE SIGN.
- b. IT IS JEJUNAL ATRESIA.**
- c. IT IS HYPERTROPHIC PYLORIC STENOSIS.
- d. IT IS ILEAL ATRESIA,
- O e. IT IS NORMAL ABDOMEN XRAY.

25-The radiographic finding most correlative with pneumonia is:

Select one:

- a. Cavities.
- b. Air Bronchograms.**
- c. Asymmetric Disease on chest x-ray.
- d. Interstitial Disease.
- e. Fibrosis.

26-All of the followings are FALSE except one:

Select one:

- a. On DEXA-scan when T-score is +2, there is Osteopenia.
- b. On DEXA-scan when T-score is -1.5, there is Osteoporosis.
- c. On DEXA- scan the normal T-score is -1.6
- d. On DEXA-scan when T-score is -2.9, there is Osteoporosis.**
- e. On DEXA- scan the normal T-score is -1.4

27-All of the followings are TRUE except one:

Select one:

- a. Iodine-131 (I-131) has a half-life of 8 days.
- b. Iodine-131 (I-131) can be used for treatment of thyroid hyperfunction.
- c. Iodine- 131 (I-131) can be used for treatment of thyroid cancer.
- d. Iodine-131 (I-131) can be used for treatment of bone cancer.**
- e. Iodine- 131 (I-131) emits - beta and gamma radiation.

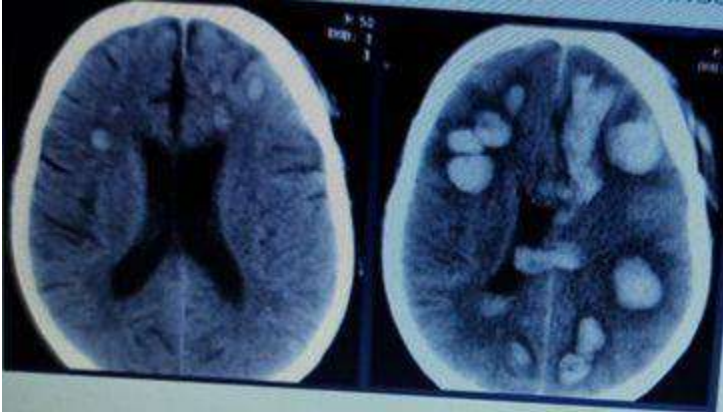28-Anterior mediastinal masses are all except:

Select one:

- a. Lymphoma (Terrible lymphoma).
- b. Thyroid (Retrosternal goiter).
- c. schwannoma.**

- d. Thymic tumor.
- e. Teratoma...

29-35 YEAR OLD MALE POST RTA, ONE OF THE FOLLOWINGS IS TRUE:



Select one: ?

- a. THERE ARE MULTIPLE HEMORRHAGIC INFARCTIONS.
- b. IT IS DIFFUSE AXONAL INJURY
- c. IT IS MOSTLY MULTIPLE HEMORRHAGIC METS**
- d. NO INTRAVENTRICULAR HEMORRHAGE
- e. NO MASS EFFECT

30-All of the followings are FALSE except one:

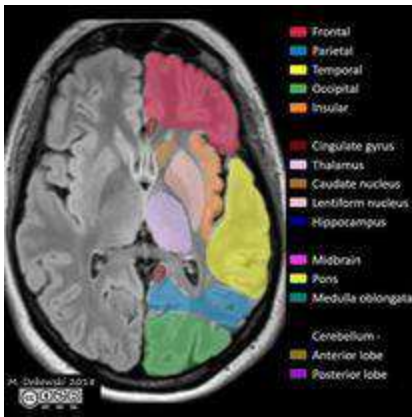
- a. Tc-99m has a half life of 10 days.
- b. Tc-99m has energy of 200 keV.
- c. Tc-99m is a diagnostic isotope.**
- d. Tc-99m can be used for treatment of thyroid cancer.
- e. Tc-99m can be used for treatment of hyperthyroidism.

31-A 33-year-old man presents to the emergency department with right-sided back pain that radiates to the right groin. The pain began 2 hours ago and is relatively constant in intensity. Microscopic hematuria is found on laboratory examination. What is the most appropriate imaging test at this time?

Select one:

- a. Ultrasound.
- b. IVP.**
- c. Abdominopelvic CT with oral and intravenous contrast.
- d. KUB X-ray.
- e. MRI of the abdomen.

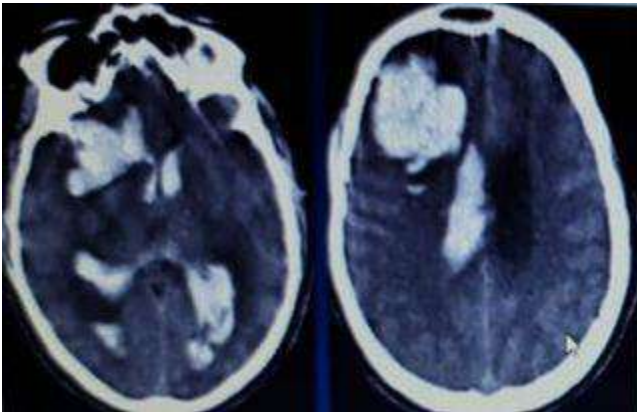
32-IN THIS BRAIN NEUROANATOMY ALL THE FOLLOWINGS COMBINATIONS ARE FALSE EXCEPT



Select one:

- a. purple- caudate
- b. orange – thalamus
- c. red – temporal lobe
- d. green – cerebellum
- e. brown – caudate

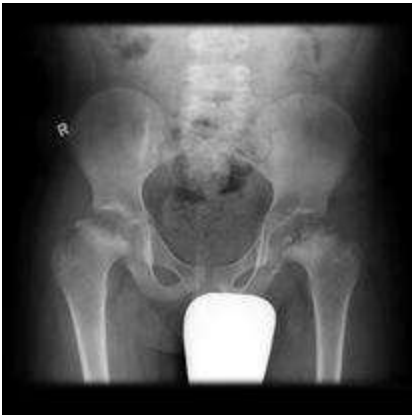33-NO TRAUMA HISTORY FOR THIS ICU PATIENT,ALL THE FOLLOWINGS ARE TRUE EXCEPT:



Select one:

- a. THERE IS HYDROCEPHALUS.
- b. THERE IS IVH.
- c. THERE IS MASS EFFECT OVER VENTRICULAR SYSTEM.
- d. THERE IS ICH.
- e. THERE IS LARGE RT FRONTAL EIDURAL HEMATOMA

34-REGARDING THIS PELVIS XRAY ONE OF THE FOLLOWING IS TRUE:



Select one:

- a. IT IS A NORMAL PELVIS FOR SUCH AGE.
- b. IT IS URGENT FOR INTERNAL FIXATION SURGICAL TREATMENT
- c. IT IS BILATERAL PERTHES DISEASE
- d. NO COXA MAGNA SEEN.
- e. NO COXA PLANA SEEN

35-Best imaging modality for posterior urethral valve is:

Select one:

- a. Ultrasound
- b. Ct scan.
- c. Voiding cystourethrogram.
- e. MRI

36-Common causes of bronchial obstruction causing collapse are all except:

Select one:

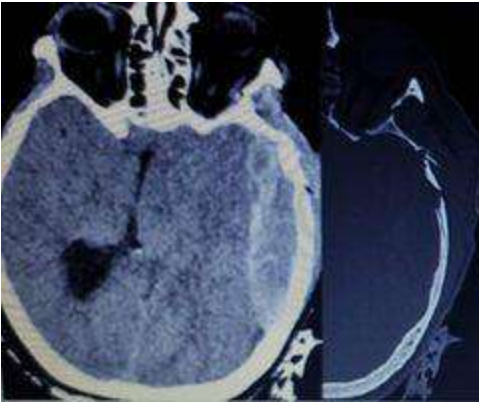
- a. Bronchial carcinoma.
- b. Mucus plug (pneumonia, postoperative).
- c. Foreign body.
- d. Malpositioned endotracheal tube.
- e. Chronic TB

37-The most common cause of spontaneous pneumothorax is:

Select one:

- a. Chest injury.
- b. Pulmonary hemosiderosis.
- c. Rupture of sub-pleural emphysematous bullae (bleb).
- d. Lung mass.
- e. Foreign body.

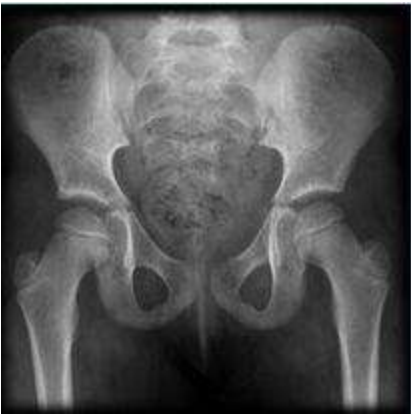38-32 YEAR OLD FEMALE POST TRAUMA, ALL THE FOLLOWINGS ARE FALSE EXCEPT:



Select one:

- a. THERE IS A LARGE RT SIDED EPIDURAL HEMATOMA
- b. THERE IS A LEFT SIDED SUBDURAL HEMATOMA
- c. THERE IS A RT TEMPORAL FRACTURE
- d. THERE IS LT ADUTE EXTRA AXIAL HEMORRHAGE**
- e. THERE IS NO MIDLINE SHIFT

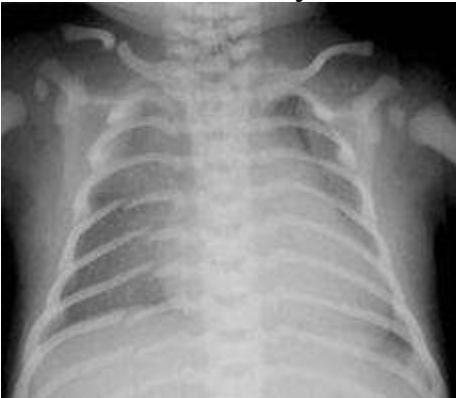39-REGARDING THIS PELVIS XRAY, ONLY ONE ANSWER IS TRUE:



Select one:

- a. IT IS DDH
- b. IT IS NORMAL PELVIS XRAY**
- c. IT IS SLIPPED CAPITAL FEMORAL EPIPHYSIS
- d. IT IS PERTHS DISEASE
- e. IT IS BILATERAL FEMURE FRACTURE

40- in this chest xray one is true :



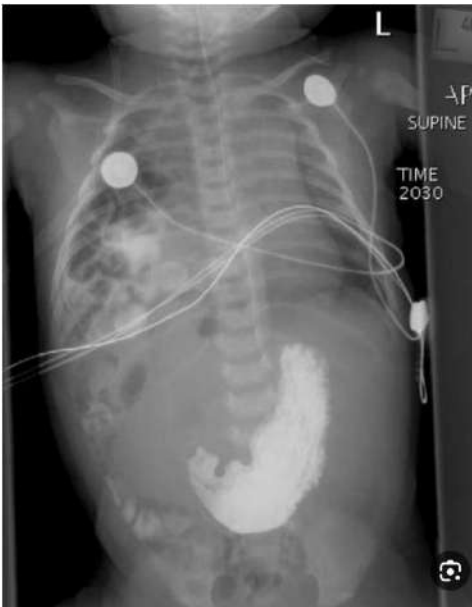
Select one :

- a. There is bilateral clavicle fracture
- b.skeletal survey may be requested**
- c.it is a case of heart failure
- d.it is most likely accidental trauma
- e.normal cartilagenous defect of ribs

Nabed final exam- 2023

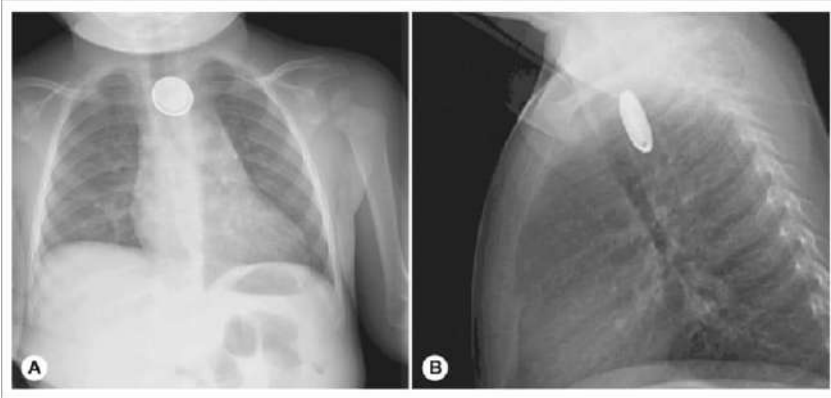
By: Mona Al-Zoubi

1.



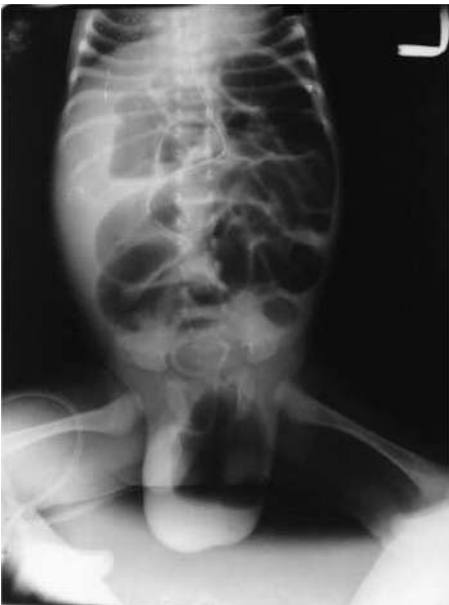Congenital diaphragmatic hernia

2.



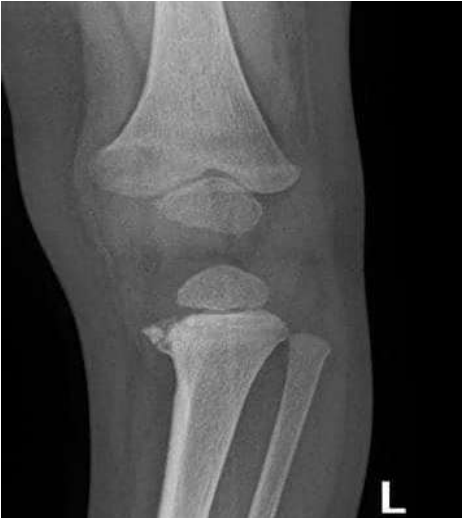Battery in the esophagus (foreign body with 2 shadows)

3.



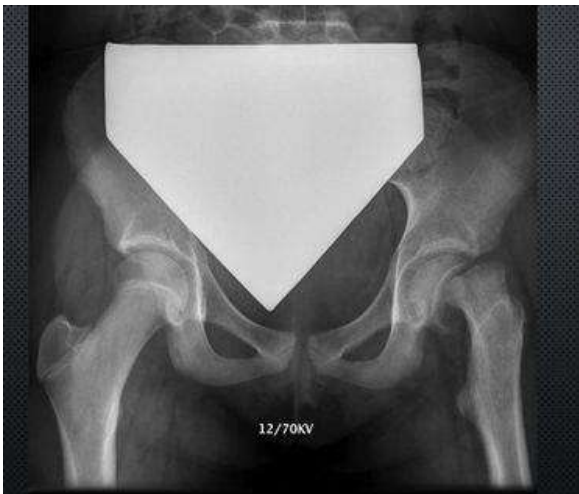Incarcerated inguinal hernia

4.



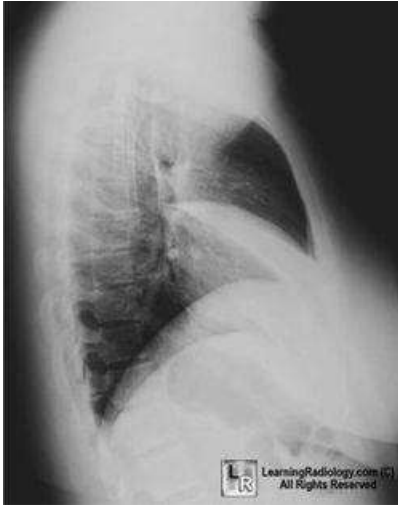Metaphyseal corner fracture

5. Wrong?!



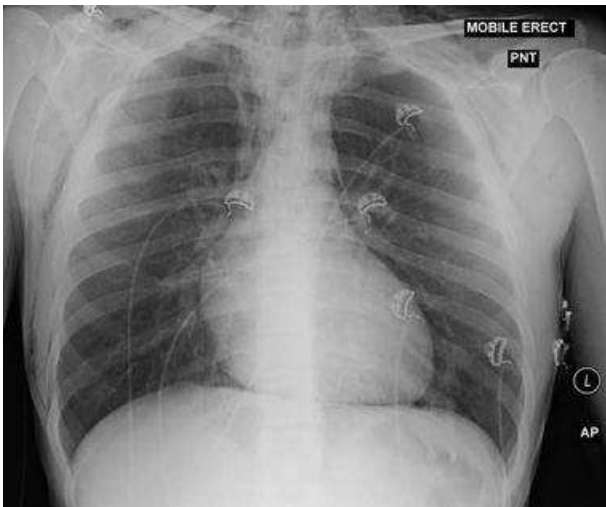Underweight

6.



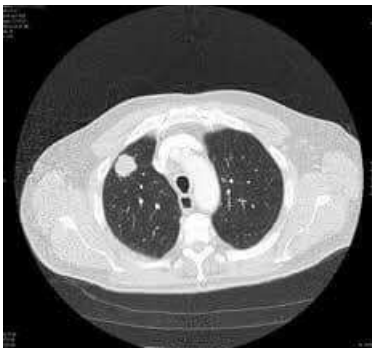Right middle lobe atelectasis

7.



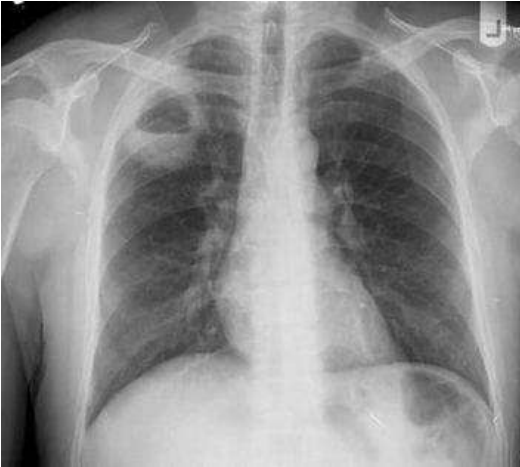Pneumopericardium

8.



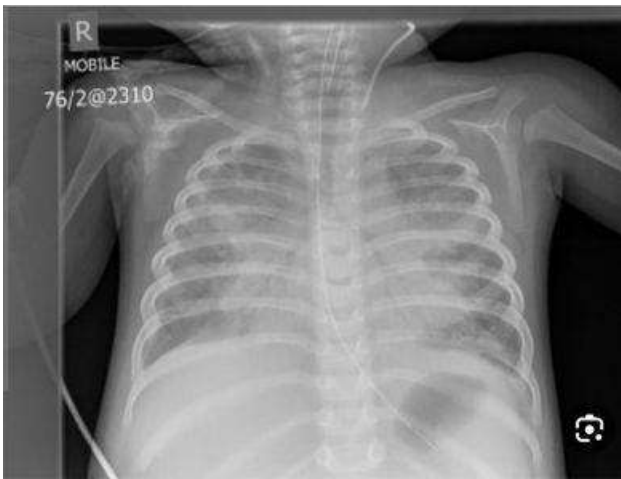Lung cancer

9. Pt. with fever



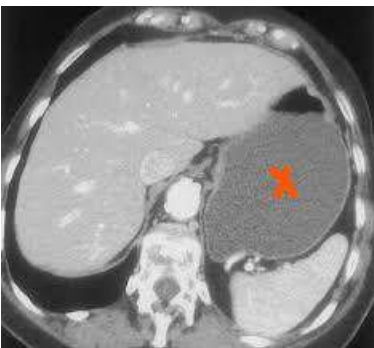
Lung abscess

10. Premature baby with respiratory distress syndrome, true?



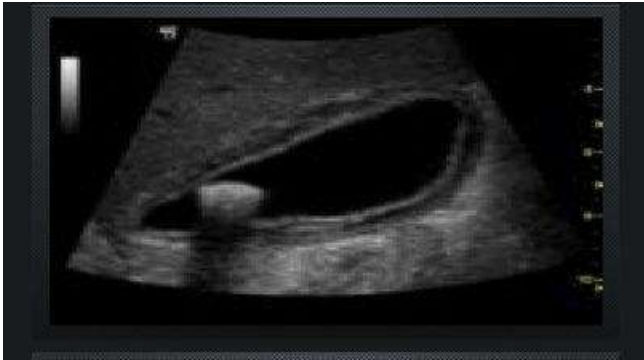Surfactant deficiency

11.



Stomach

12.



Acute calculus cholecystitis

13. Less diagnosis by KUB:

Radiopaque kidney stone

Small IO

Large IO

Cecum volvulus

Acute appendicitis XXX

14. Regarding SBO characteristics, one is false:

Diameter of small bowel > 9mm

15. Pt. with right lower iliac ... (picture of appendix) with target sign on US

Acute appendicitis

16. Pt. postop. cholecystectomy with abdominal pain, diameter of CBD= 1.5cm, left hepatic duct cm, right hepatic duct 9mm, with MRCP picture, one is false:

CBD Stone

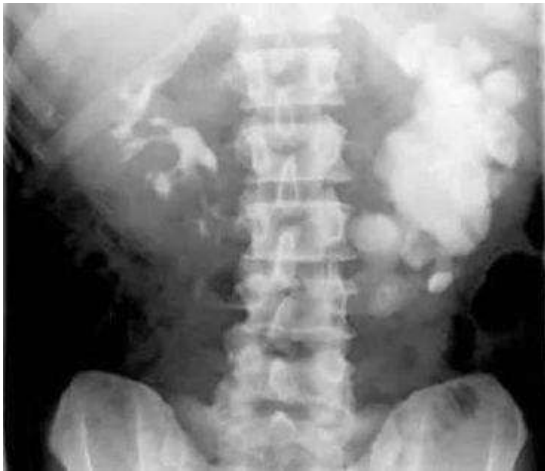CBD Dilated

Left hepatic duct dilated

Right hepatic duct dilated

Use contrast XXX

17. One is wrong:



Staghorn sign XXX

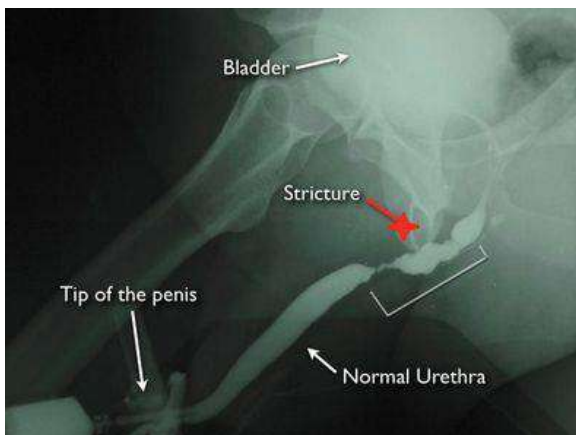
IVU

Horseshoe kidney

Hydronephrosis

Malrotated kidney

18. One is wrong:

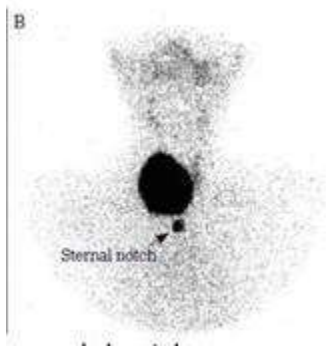


Intact distal penile urethra

Stricture at bulbar urethra


Leak at membranous urethra XXX

19.



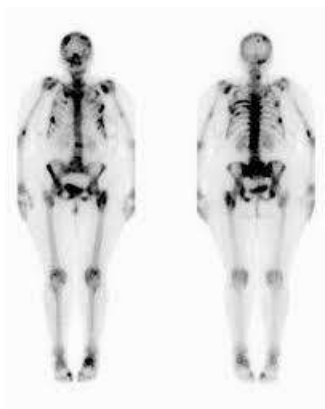
Autonomous nodule

20.



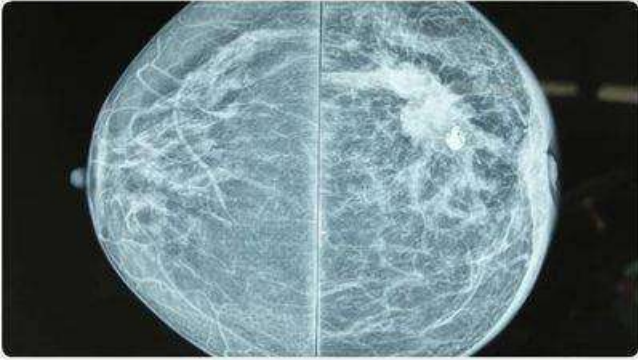
Multinodular goiter

21.



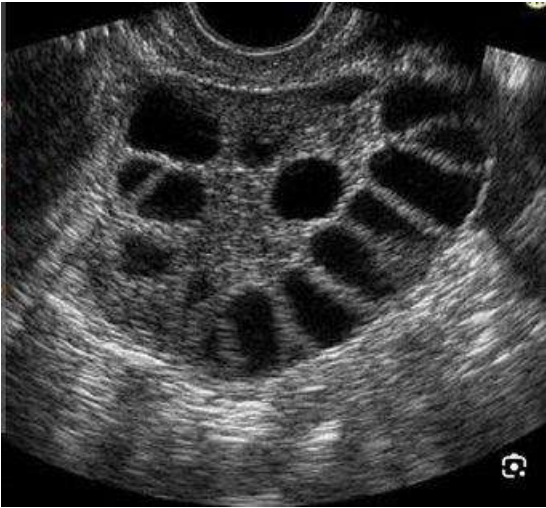
Bone mets due to breast cancer

22. Wrong:



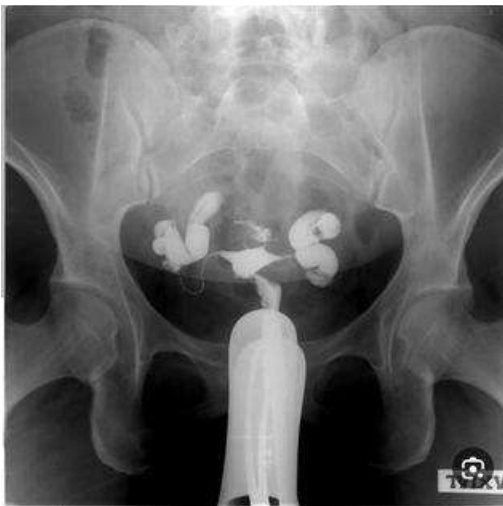Benign lesion

23. **Informative case scenario which will guide you for: PCOS**



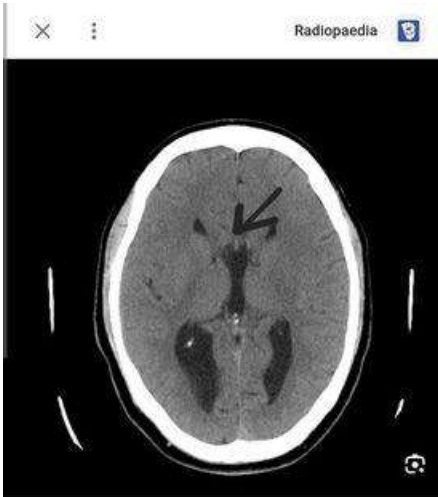Polycystic ovarian syndrome

24.



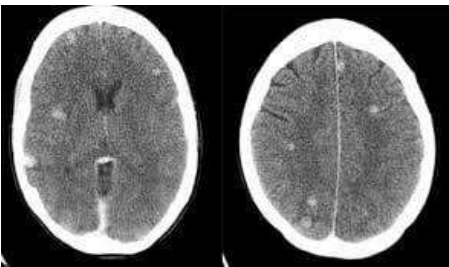
Bilateral hydrosalpinx

25.



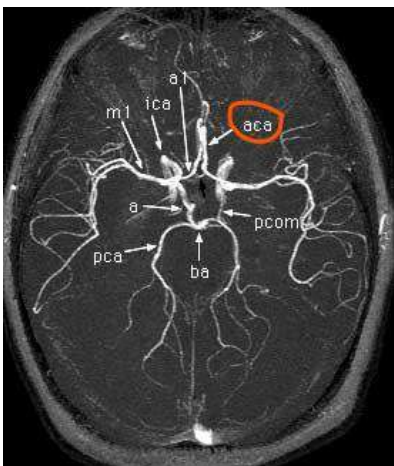
Corpus callosum

26. 55 y/o pt. complains of headach, dx?



Mets

27. **More complicated pic. and difficult to detect the correct answer**



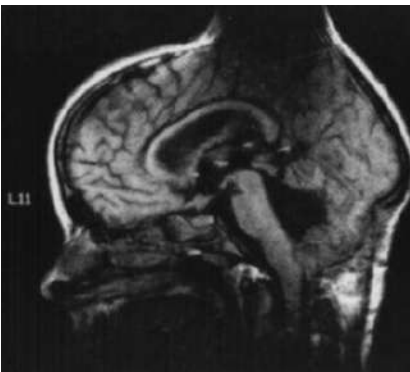
Anterior cerebral artery

28. cause?



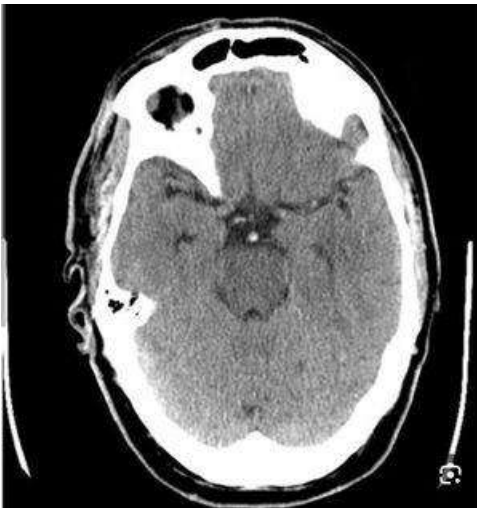Wheelchair is not suitable

29.



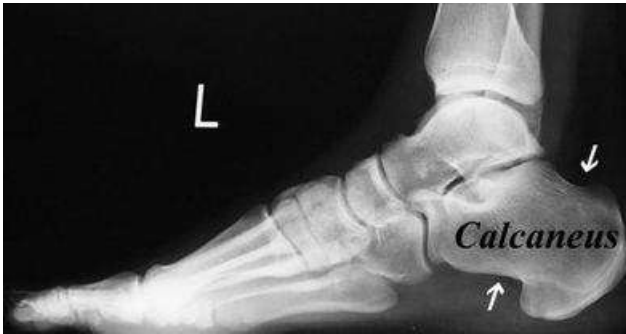Metallic artifact

30.



Basilar vein thrombosis

31. Name the largest tarsal bone



Calcaneus

32. Spine MRI with lytic lesion, one is wrong:

Lytic lesion with prostate cancer (prostate cancer form sclerotic lesions)

33. One is a primary feature of degenerative disc disease:

Osteophyte formation

34. Image of air bronchogram.

35. Image of pneumothorax (difficult one which you might consider it as a normal x- ray).

36. Image of pleural effusion.

37. Brain CT, all are found except: subdural hematoma.

38+ 39. **T score for females, Z score for males and children**

You can answer these 2 Q by these information in addition to color of osteopenia, osteoporosis and normal bone.

40. Image of kidneys, one is false:

Partial obstruction

Complete obstruction

TC-99m DTPA 15-30 mci XXX



Osteoporosis: A BMD greater than 2.5 standard deviations from the normal (T score less than or equal to -2.5) defines osteoporosis.

1 comment



Like



Comment



محمود برکات



31 May 2022 ·

all the following are bone scan indications except:

Fractures

Paget's disease

Malignancies

Infection

Prolapsed disc



1



Like



Comment



محمود برکات



31 May 2022 ·

all the following are contraindications for thyroid scan except

-Patient on thyroxine 50mg

-Patient taking amiodarone

-Pregnant women

-Breastfeeding women

-Acute thyroiditis attack



1



Like



Comment



محمود برکات



Respond ▼





محمود بركات

31 May 2022 · 📷



Which of the following is the most common cause of bone sclerotic metastasis

Breast

Prostate ←

Lung

Kidney

Lymphoma



1



Like



Comment



محمود بركات

31 May 2022 · 📷



سؤال على هذا

Findings

- **Normal:** A bone BMD is considered normal if the T-score is within 1 standard deviation of the normal young adult value. Thus a T-score > -1 is considered a normal result.
- **Osteopenia (Low bone mass):** A BMD defines osteopenia as a T-score between -1 and -2.5 . This signifies an increased fracture risk but does not meet the criteria for osteoporosis.
- **Osteoporosis:** A BMD greater than 2.5 standard deviations from the normal (T score less than or equal to -2.5) defines osteoporosis.

1 comment



Like

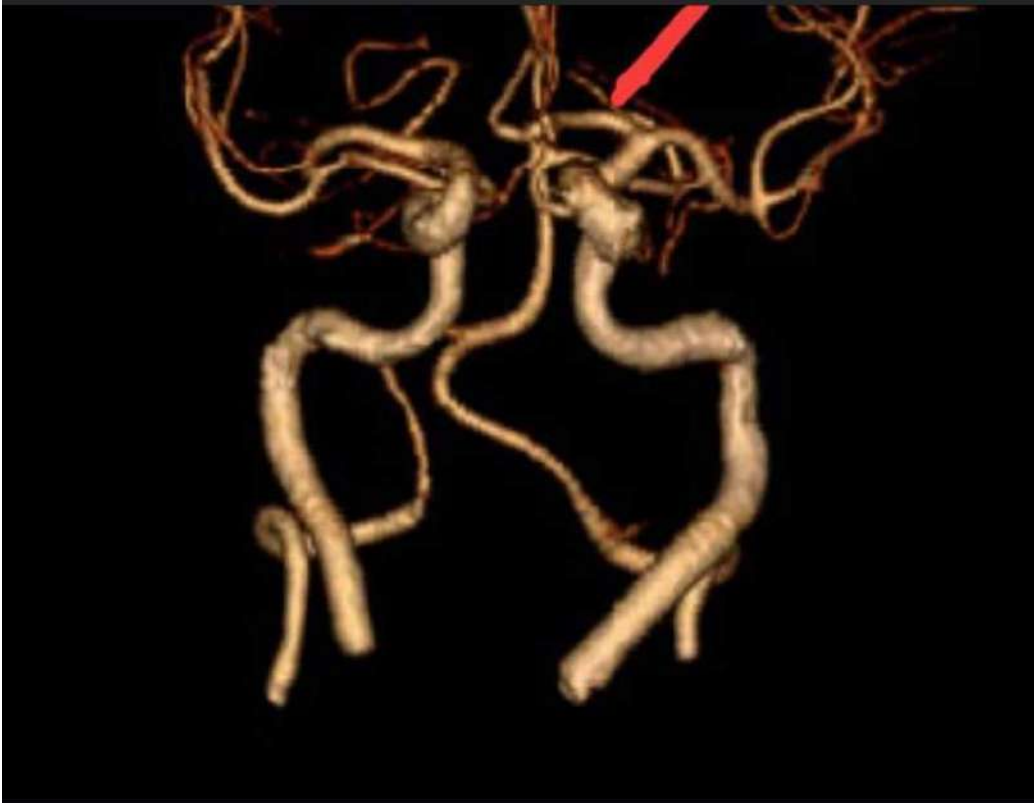

Comment



Respond ▼





3 comments



Like



Comment



محمود برکات

31 May 2022 · 📷



All of the following are correct about isotopes except:

- the same chemical properties
- the same atomic number
- different number of neutrons
- different mass numbers
- They have no clinical use ↩



Like



Comment

[Respond ▼](#)



7 COMMENTS



Like



Comment

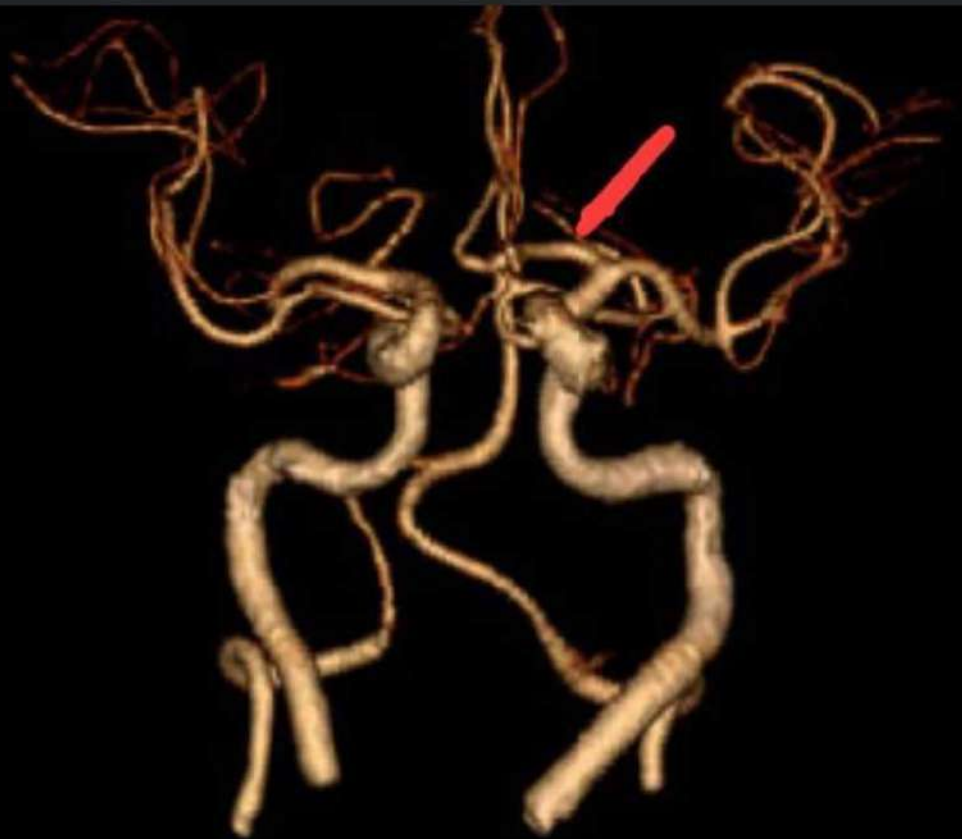


فاطمة هشام

31 May 2022 · 🌐



جابت صورة CTA reconstruction وحاطة عدة أسهم وبدها الخطأ
أحد الأسهم لونه رمادي كان محل اللي بالصورة وعنده Left MCA
على ما أعتقد



2

3 comments



Like



Comment



محمد بكات



Respond ▼





Like



Comment



فاطمة هشام

31 May 2022 ·



Female patient with acute central abdominal pain and repeated vomiting. All should be done except:
Chest X-ray with supine position?

حدا متذكر خيارات السؤال شو كانت؟

4 comments



Like



Comment

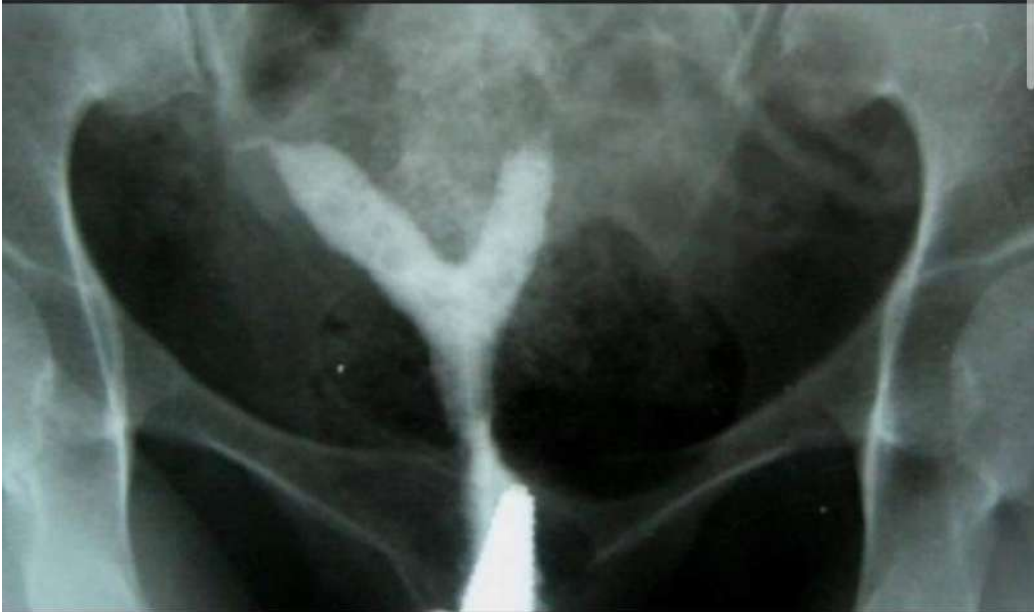

فاطمة هشام


31 May 2022 ·



Bicornuate uterus



7 comments



Like



Comment

Respond ▼





Like



Comment

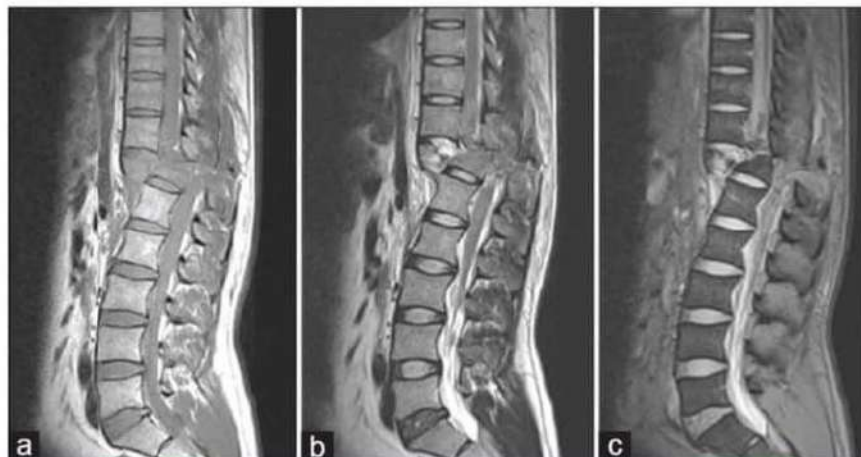**Laith F Najada**

31 May 2022 · 🌐



- The largest tarsal bone : calcaneus
- Ultrasound of renal cell carcinoma
- CT scan of kidney stone
- MRI of spine زي اللي بالصورة :
الغلط كان انه الكسر عند L2/L3
- No needed for bone scan: prolapse of disk

Figure 1: Sagittal T1-weighted (a), T2-weighted (b), and gradient echo (c) images showing comminuted fracture of D12 vertebral body with posterior translation. There is complete transection of distal thoracic cord at this level with blooming on gradient echo sequence, representing cord hemorrhage



4 comments



Like



Comment

**فاطمة هشام**

31 May 2022 · 🌐



Respond ▼

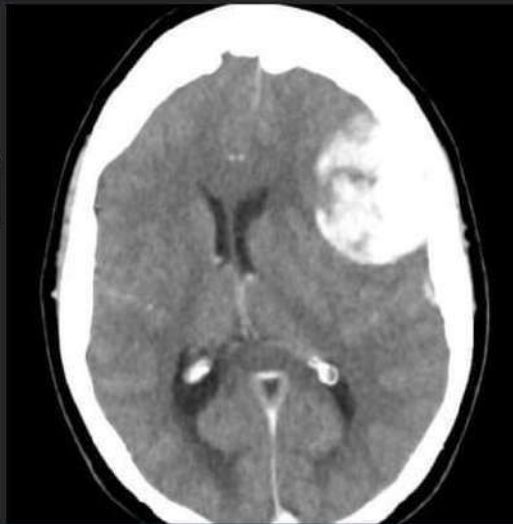

**Laith F Najada**

31 May 2022 · 📷



Brain tissue



Like



Comment

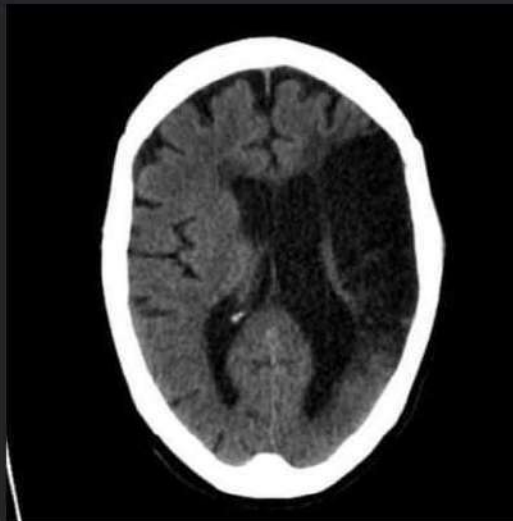
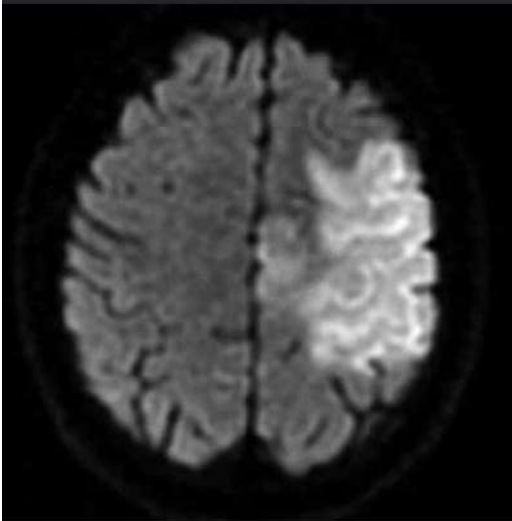
**Laith F Najada**

31 May 2022 · 📷



Left parietal lobe infarction

مش نفس الصور بس تشبهها



1

Respond ▼





Like

Comment

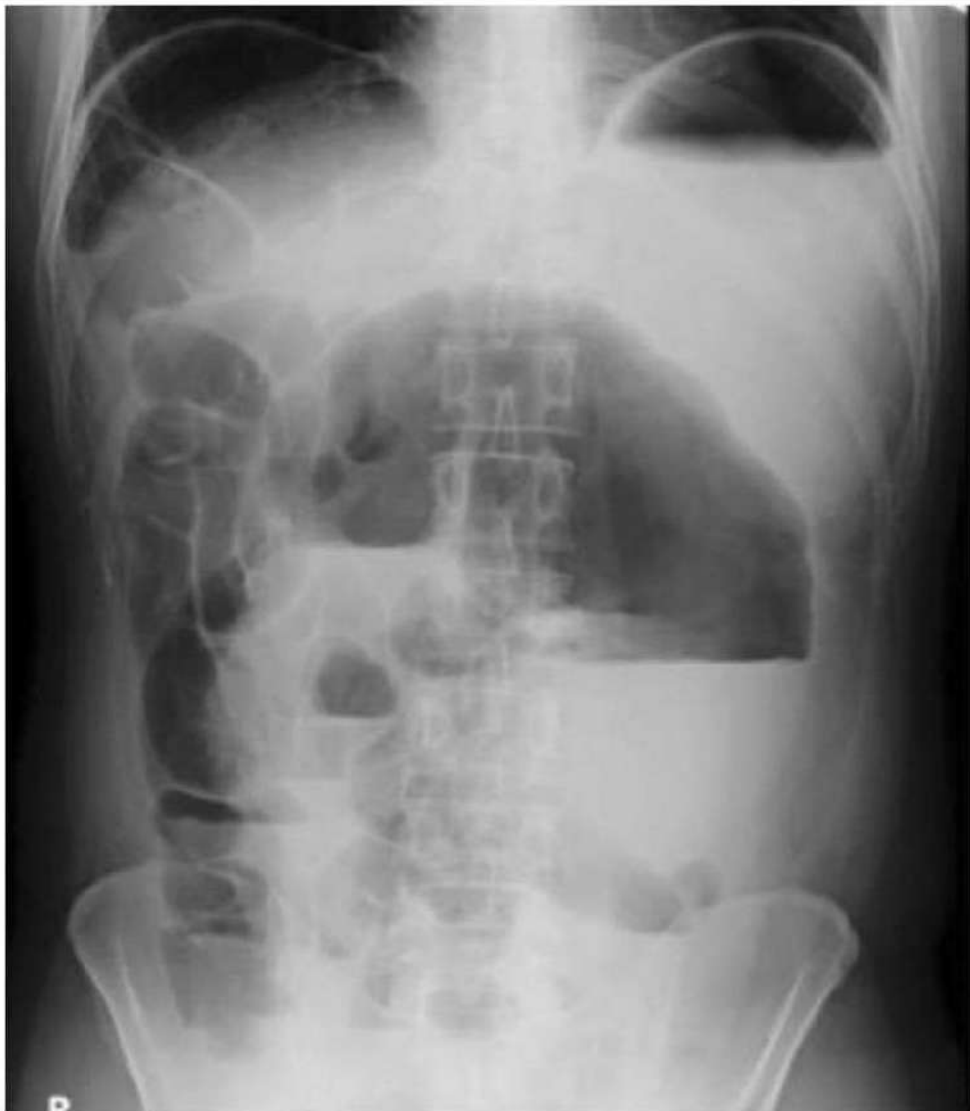**Laith F Najada**

31 May 2022 ·



-Small intestinal obstruction, one is false:
Diameter is 9cm

-one is true regarding this image:
Multiple air fluid level (كانت مكتوبة fluid fluid level)



1

Respond ▼



**Sondos Ziyad Alabbadi**

31 May 2022 · 📷

Most common cause of
pneumothorax?

Chest trauma or injury ✓



Like



Comment

**Sondos Ziyad Alabbadi**

31 May 2022 · 📷

Anterior mediastinal masses, False?

-lymphoma

-schwannoma ✓



Like




Comment

**Sondos Ziyad Alabbadi**

31 May 2022 · 📷

The largest of the tarsal bones is?
Calcaneus 😊



Like



Comment

**Laith F Naiada****Respond ▼**



Supine abdominal x-ray demonstrates a large **pneumoperitoneum** which outlines the falciform ligament giving the classical appearances of **football sign** and **falciform ligament sign**.



Like



Comment

**Sondos Ziyad Alabbadi**

31 May 2022 · 📷

Air bronchogram commonly?

-pneumonia ✓

First sign of degenerative disk disease?

-osteophytes

-...

5 comments



Like



Comment

**Sondos Ziyad Alabbadi**

31 May 2022 · 📷

Most common cause of pneumothorax?

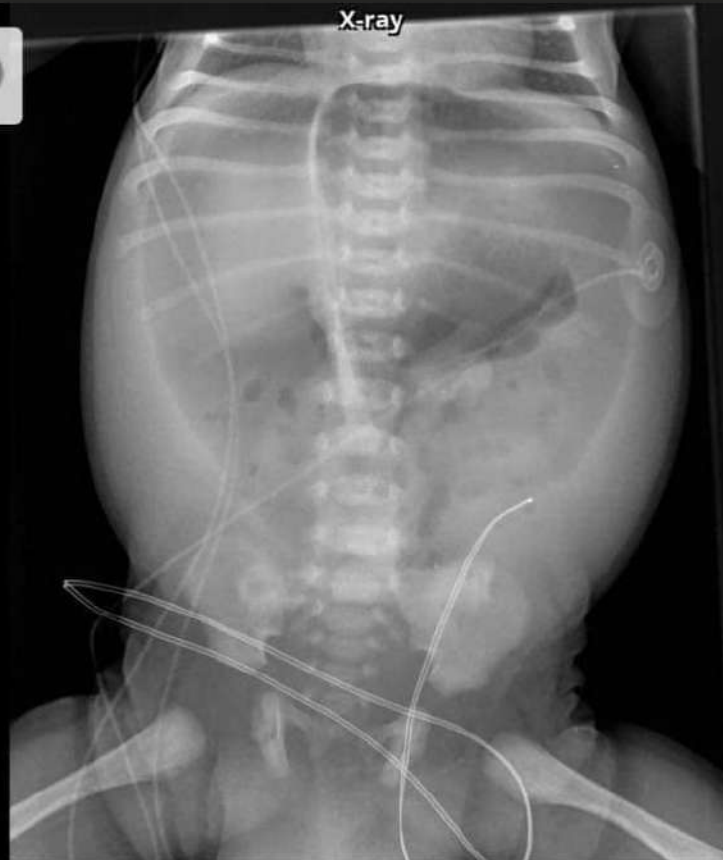Chest trauma or injury ✓

Respond ▼



**Izzat Ababneh**

31 May 2022 · 📷



Frontal

Supine abdominal x-ray demonstrates a large **pneumoperitoneum** which outlines the falciform ligament giving the classical appearances of **football sign** and **falciform ligament sign**.



Like



Comment

Respond ▼



-Acute thyroiditis attack



1



Like



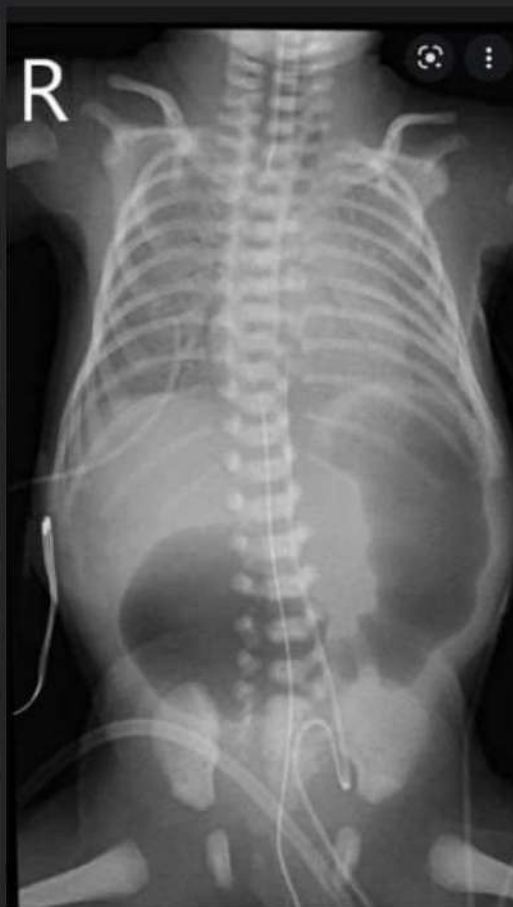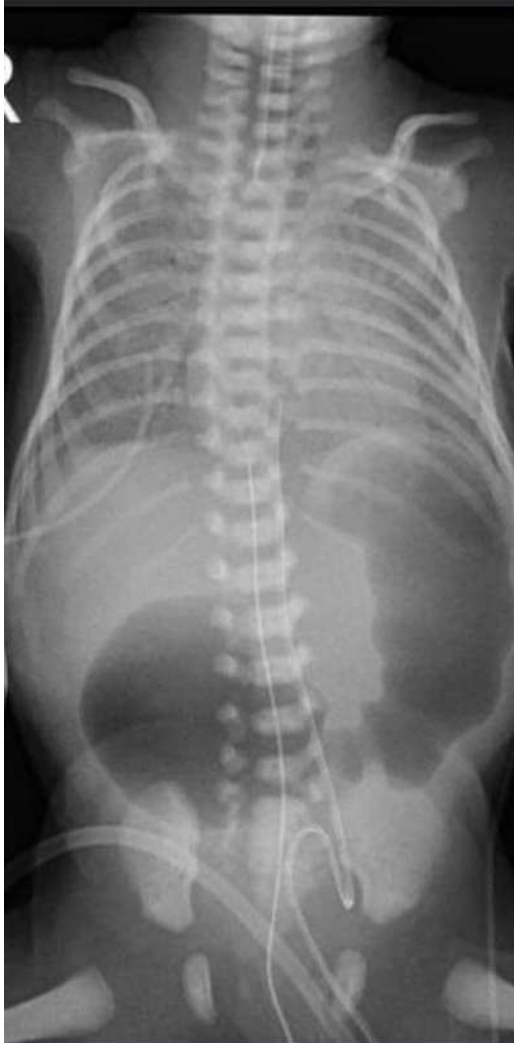Comment



محمود بركات

31 May 2022 ·

تعديل هاي الصورة



able sign (duodenum) | Radiology Reference Article |
ia.org

be subject to copyright. Learn More

9 comments



Like



Comment

Respond

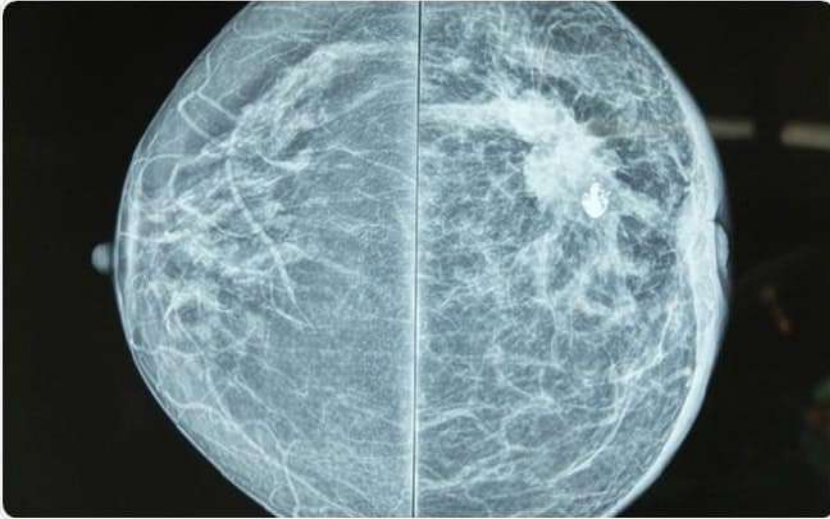


Radiology final exam MCQ

Done by : Yosor Alajaleen

✓ الامتحان كان كله صور

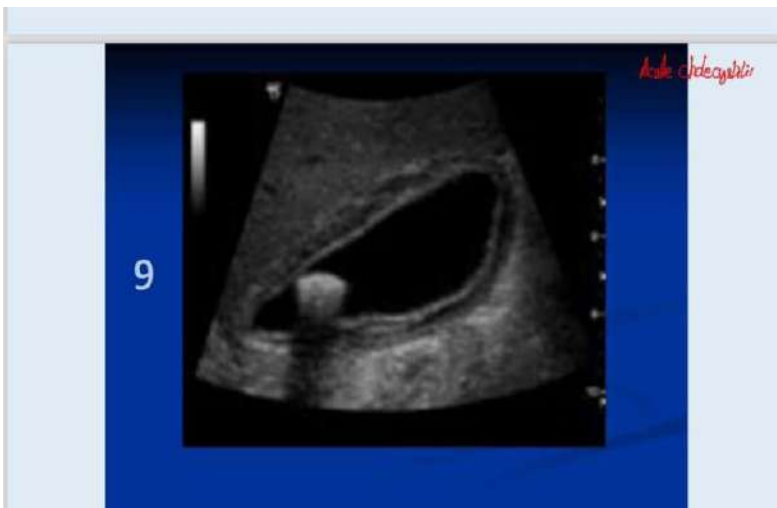
1)



A) malignancy ✓

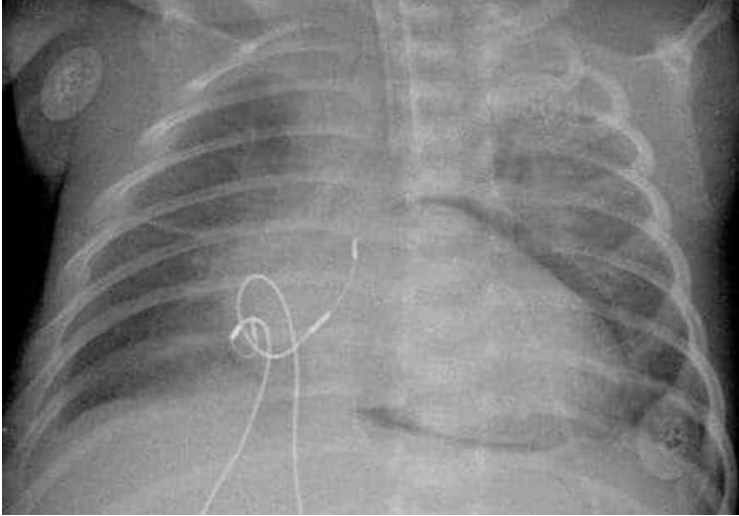
B) benign

2)




Acute cholecystitis ✓

3)



Pneumopericardium ✓

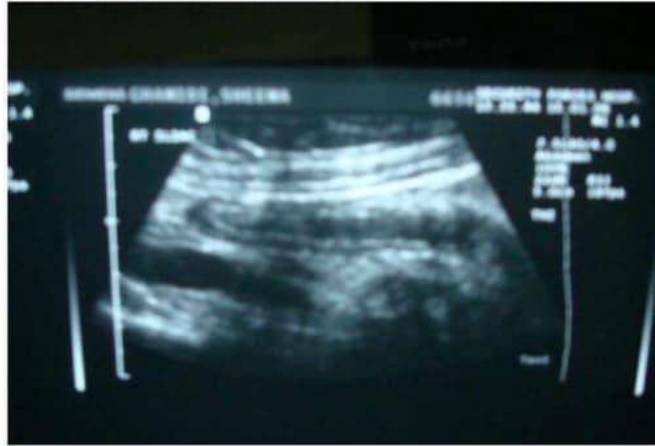4)



- A) **MRCP** ✓
- B) **ERCP**
- C) **MRI LIVER**

5)

Acute appendicitis



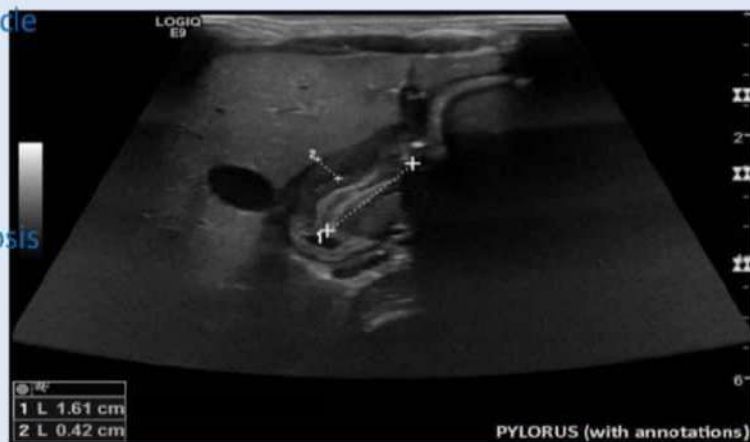6) HPS

Name of study :
ultrasound of pyloric region

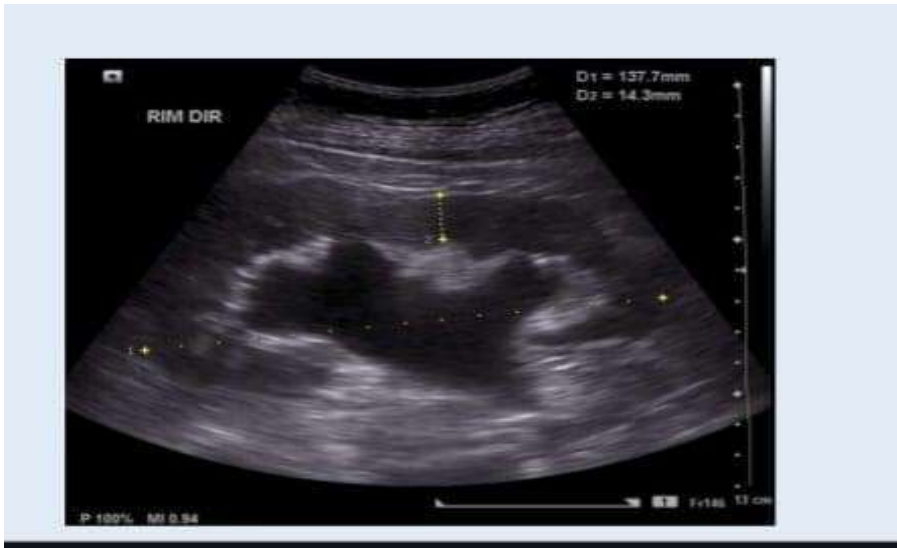Q6

Findings :
Increase in the single muscle
thickness and length

Diagnosis :
hypertrophic pyloric stenosis

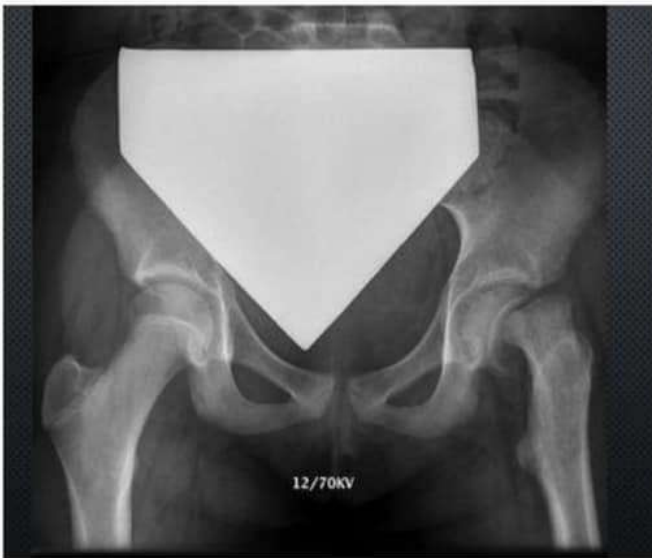

7)



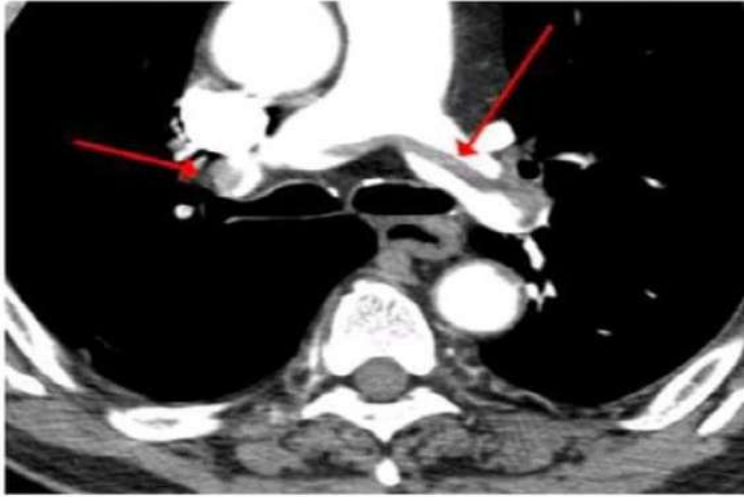Hydronephrosis without stone

8)



Slipped capital femoral epiphysis

9)

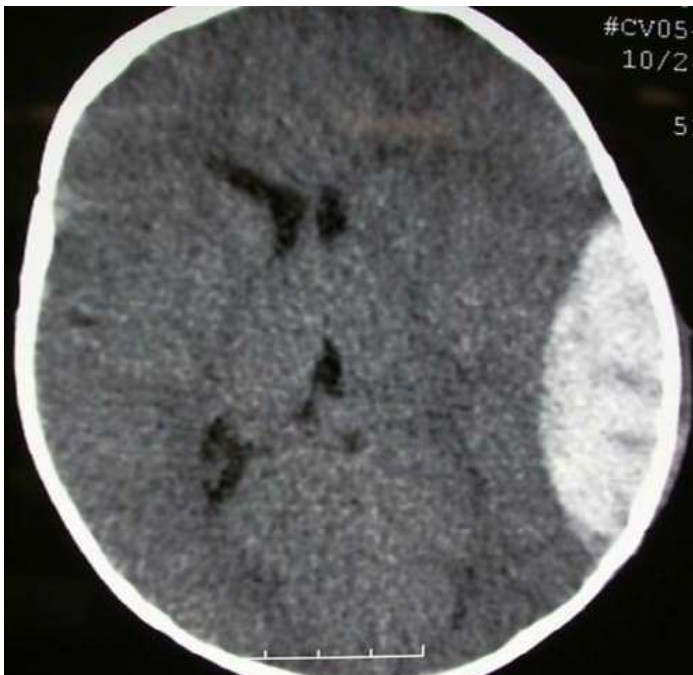

A)major PE ✓

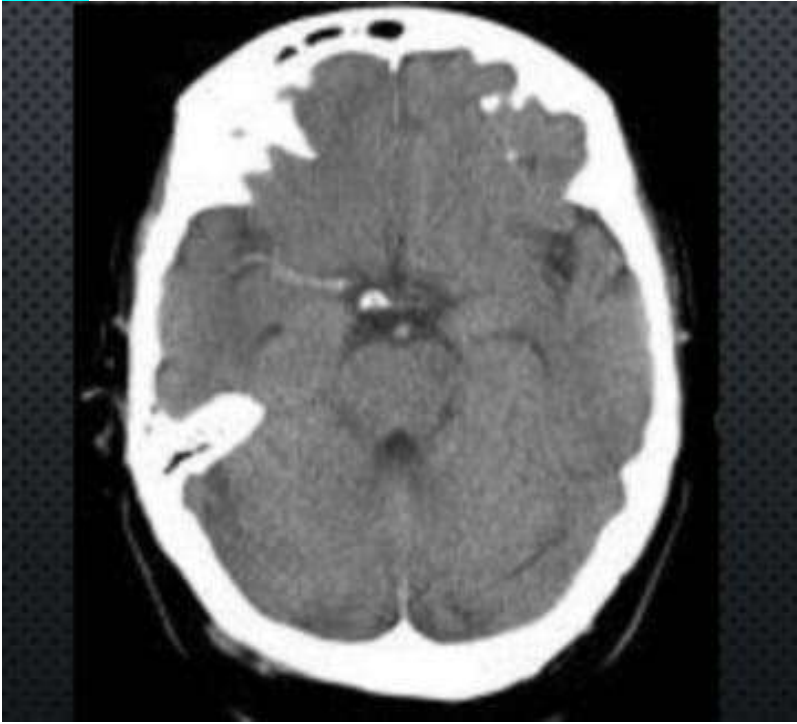B)minor PE

10)

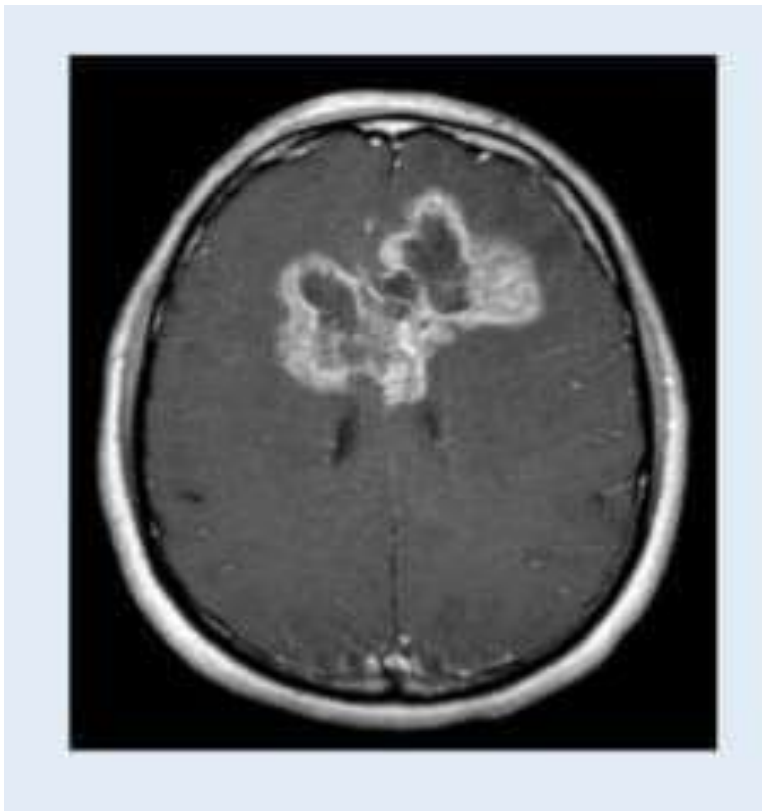
Acute epidural hematoma.



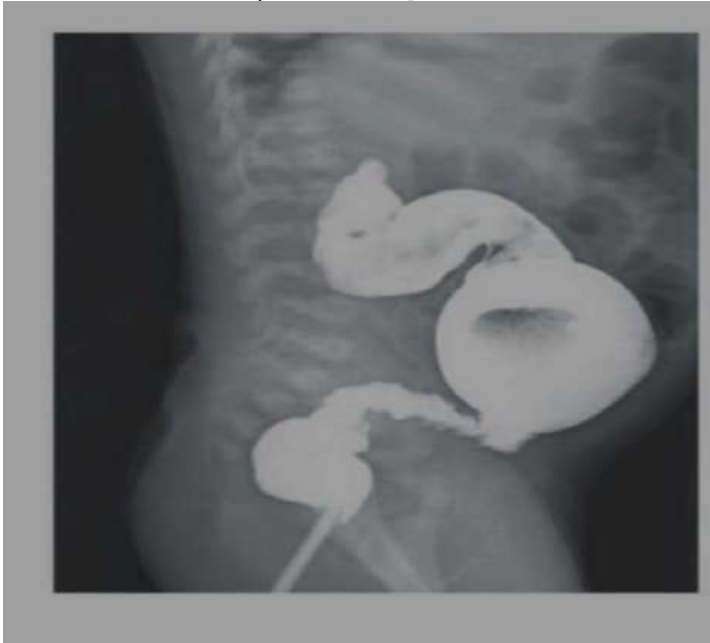
11) MCA Thrombosis



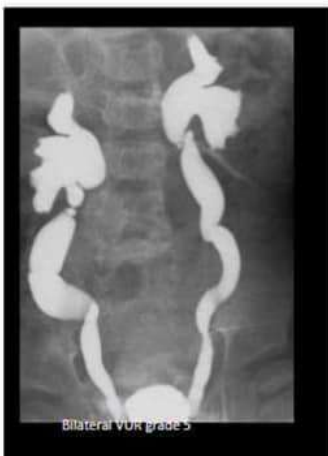12) glioblastoma multiform (high grade glioma)



13) Hirsch sprung disease



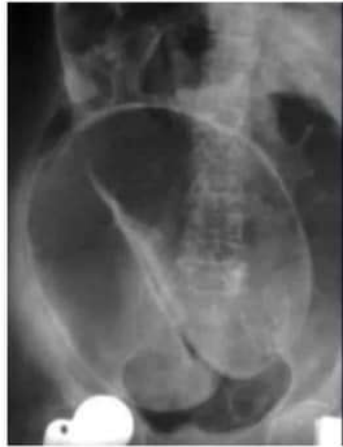14)



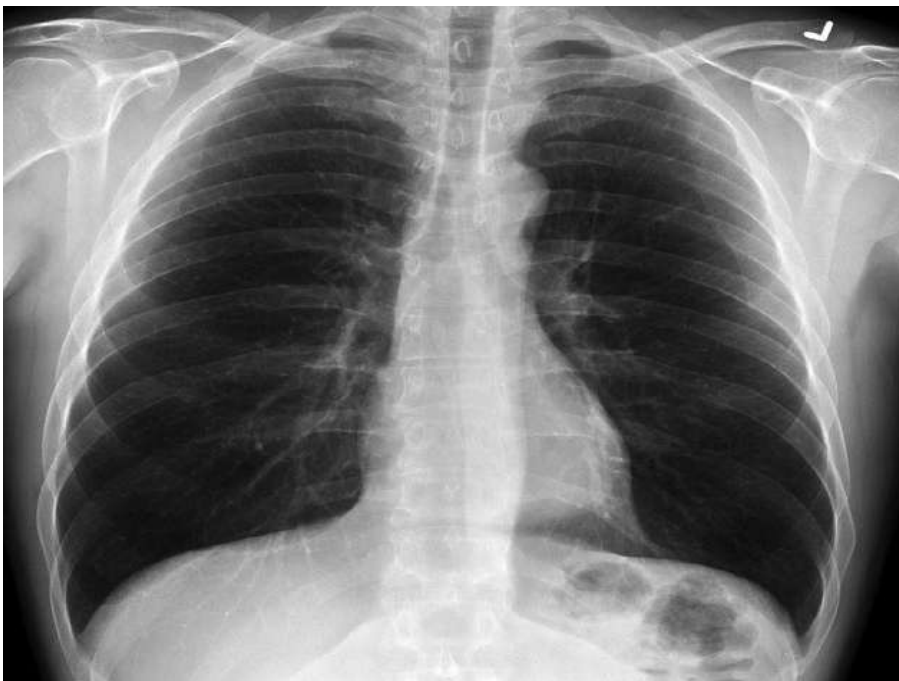stage 5 VUR

15)

Sigmoid valvula

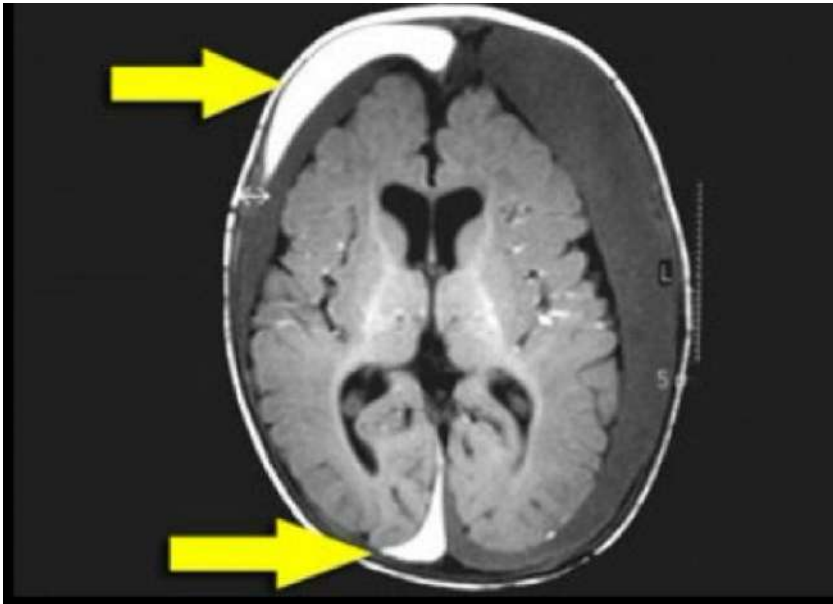


16)



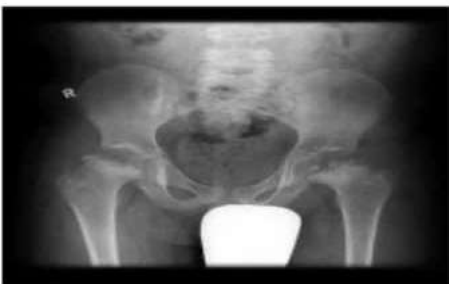Normal CXR

17)



- A) just epidural hematoma
- B) child abuse ✓

18)

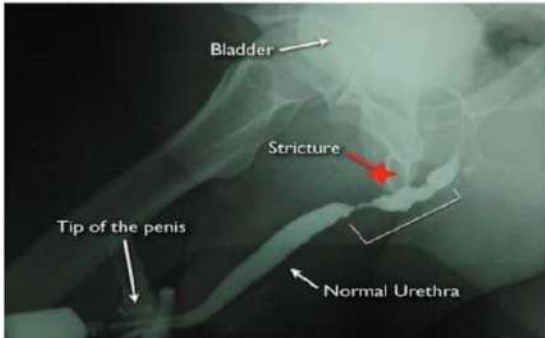


Select one:

- a. IT IS A NORMAL PELVIS FOR SUCH AGE.
- b. IT IS URGENT FOR INTERNAL FIXATION SURGICAL TREAT
- c. IT IS BILATERAL PERTHES DISEASE
- d. NO COXA MAGNA SEEN.
- e. NO COXA PLANA SEEN

19)

18. One is wrong:



Intact distal penile urethra

Stricture at bulbar urethra

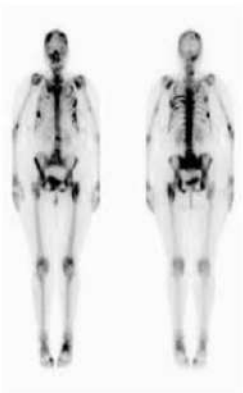
Leak at membranous urethra XXX

The Q : where is the stricture

- A) **Bulbar** ✓
- B) **Membranous**

20)

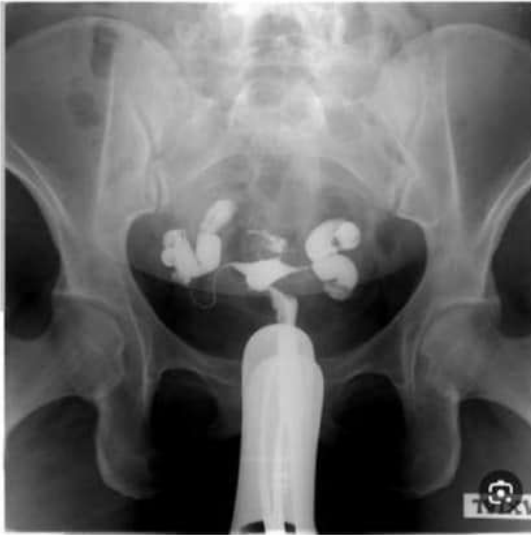21.



Bone mets due to breast cancer

21)

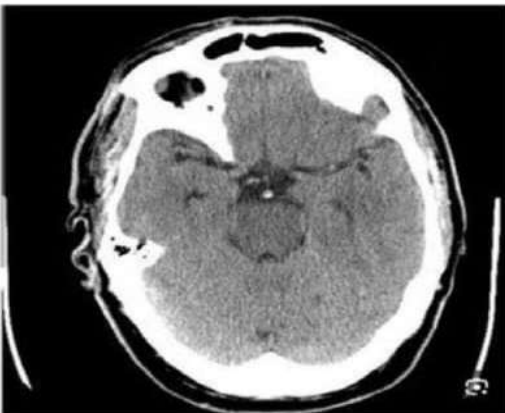
24.



Bilateral hydrosplinx

22)

30.



Basilar vein thrombosis

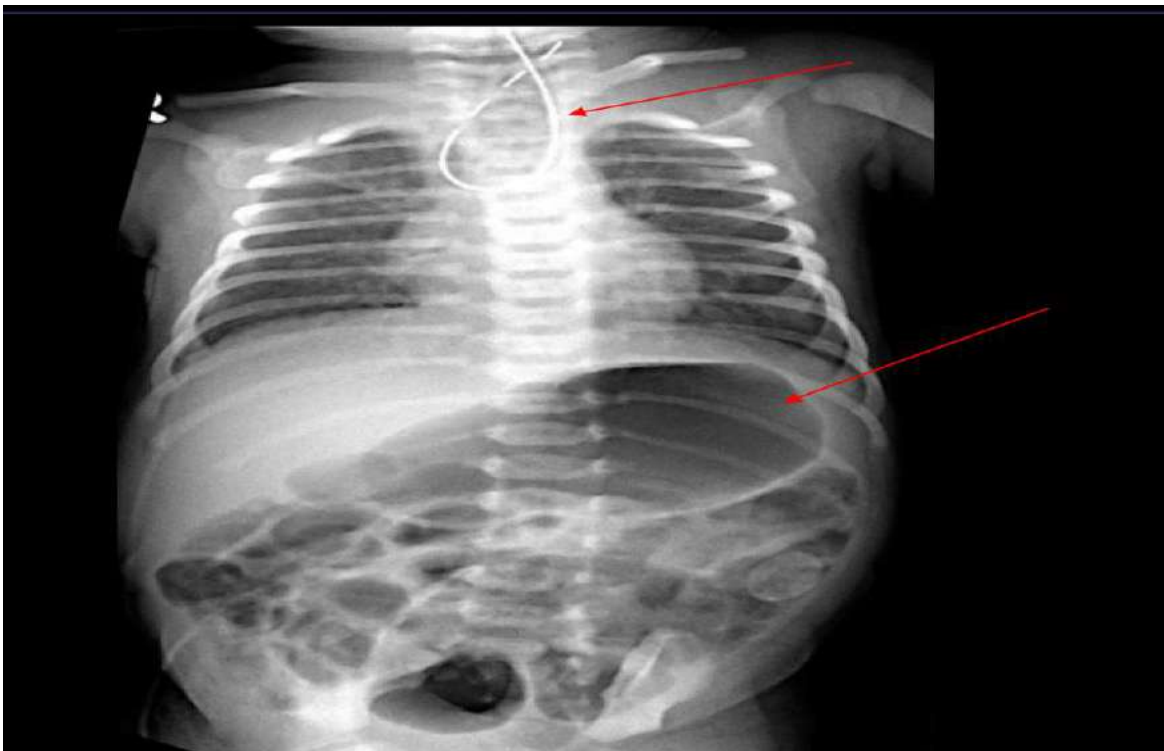
23) dexta scan

وكانوا 1- .. 1- .. 0.5 .. 0.5- .. 0.8-

NORMAL

بتوخذ اقل رقم من الأرقام وبناء عليه بتجاوب

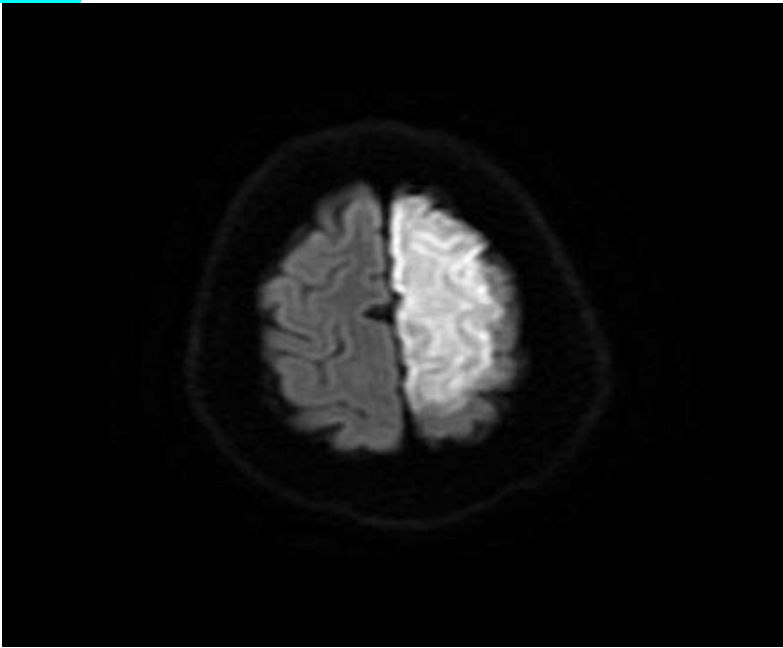
24)



A) Esophageal atresia without fistula

B) Esophageal atresia with fistula ✓

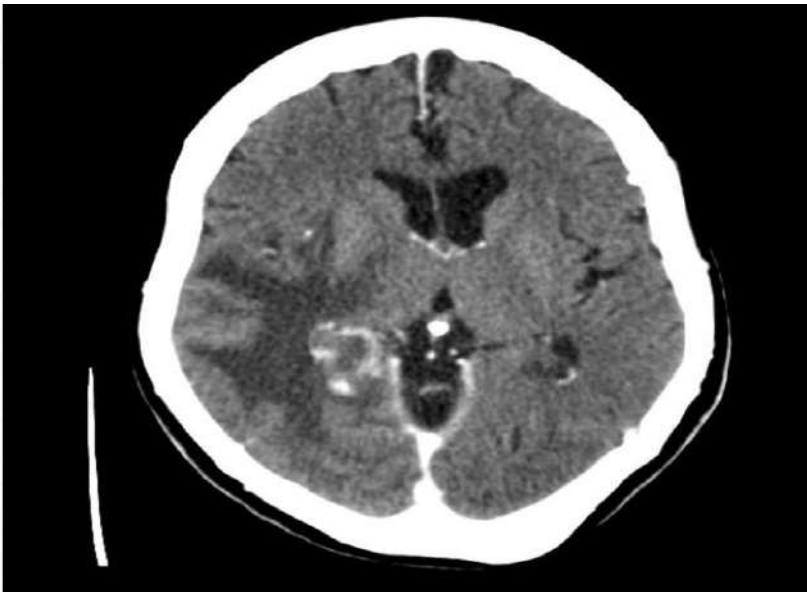25)



A) ASA infarction ✓

B) MSA infarction

26)



A) Metastasis ✓

B) meningioma

C) high grade glioma

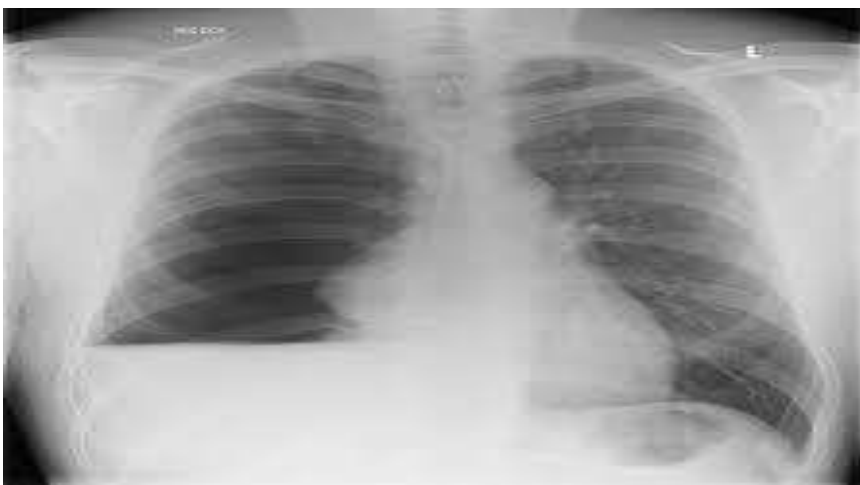
27) ultra sound machine



28) “aprone” used by radiologist in:

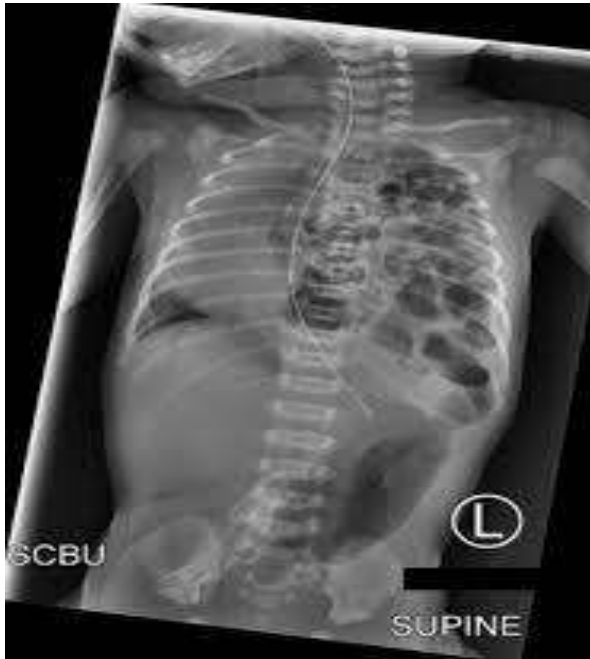- A) MRI
- B) CT ✓
- C) US

29)



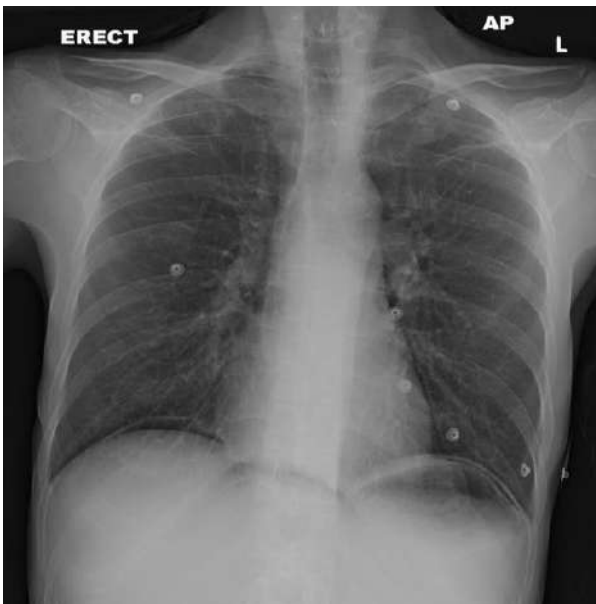
Hydro pneumothorax ✓

30)

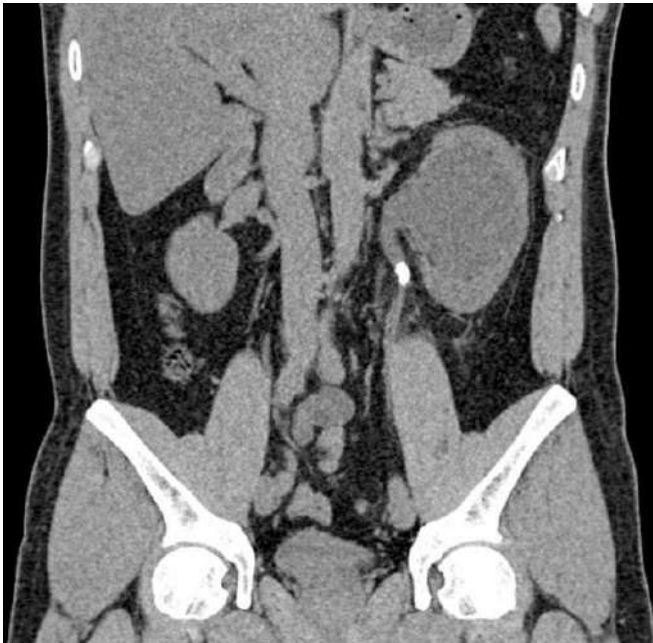

Diaphragmatic Hernia ✓

31) Pneumoperitoneum

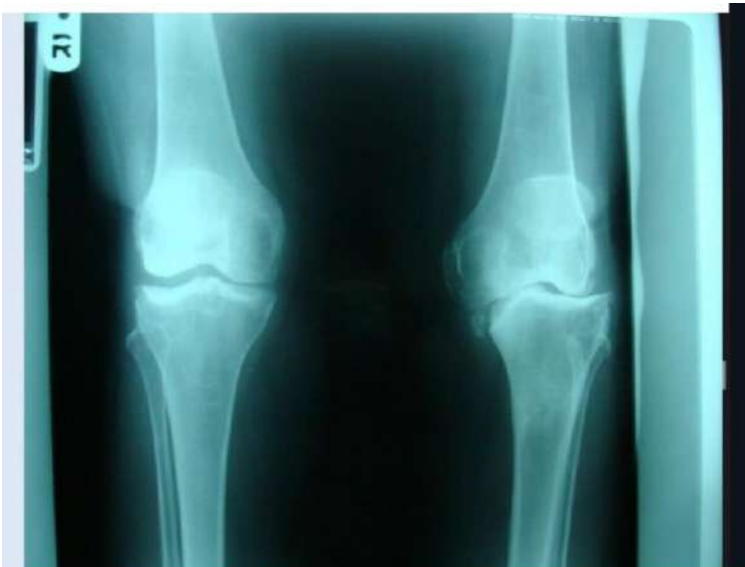

32)

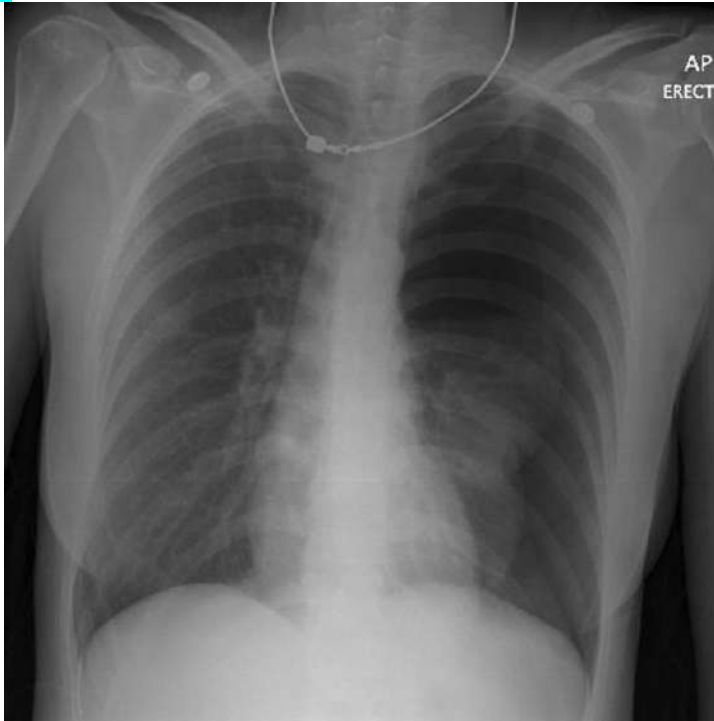

- A) ureteric stone ✓
- B) tumor in the lt kidney
- C) Incomplete duplication of both kidneys.

33) Degenerative osteoarthritis ✓



34)



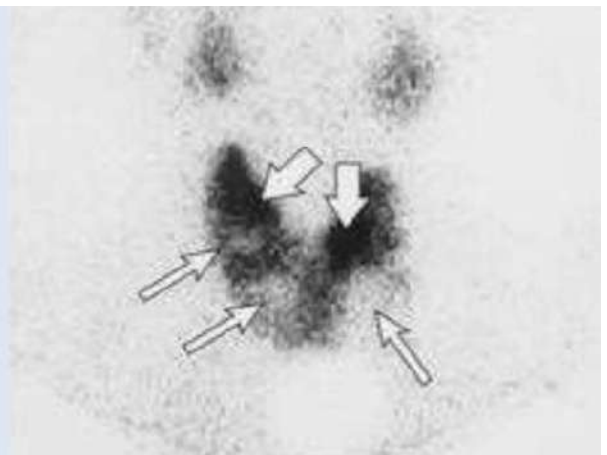
A) tension pneumothorax ✓

B) non tension

الصورة ما كانت واضحة هيئك

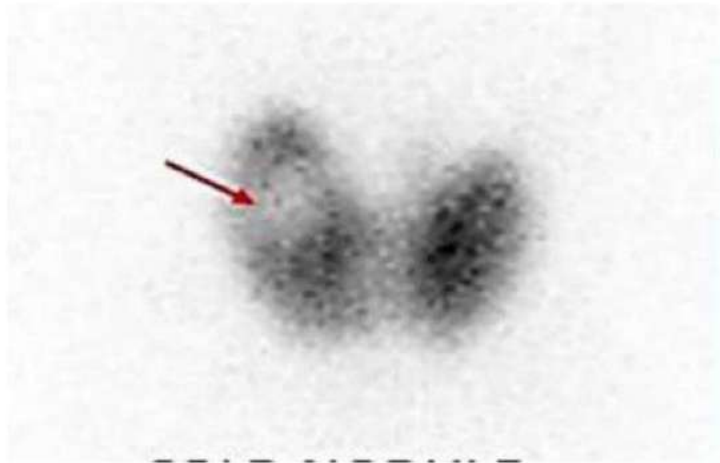
35)

- 1-polysystic kidney
- 2-multinodular goiter
- 3-cold nodule
- 4-gravis disease



36)

- a) **Cold nodule**
- b) Hot nodule
- c) Normal thyroid
- d) Graves' disease

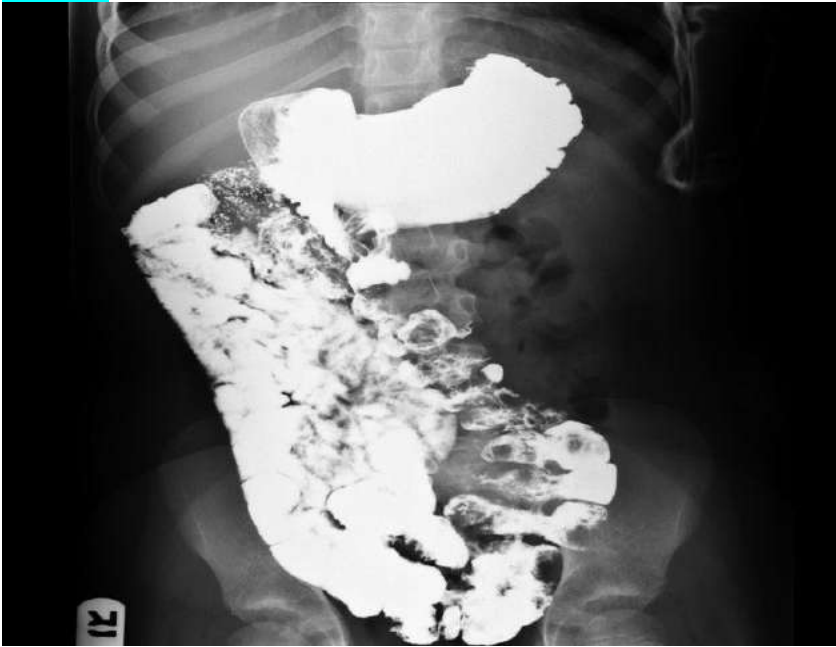

37)

- a) Normal thyroid
- b) **Graves' disease**
- c) Kidney image

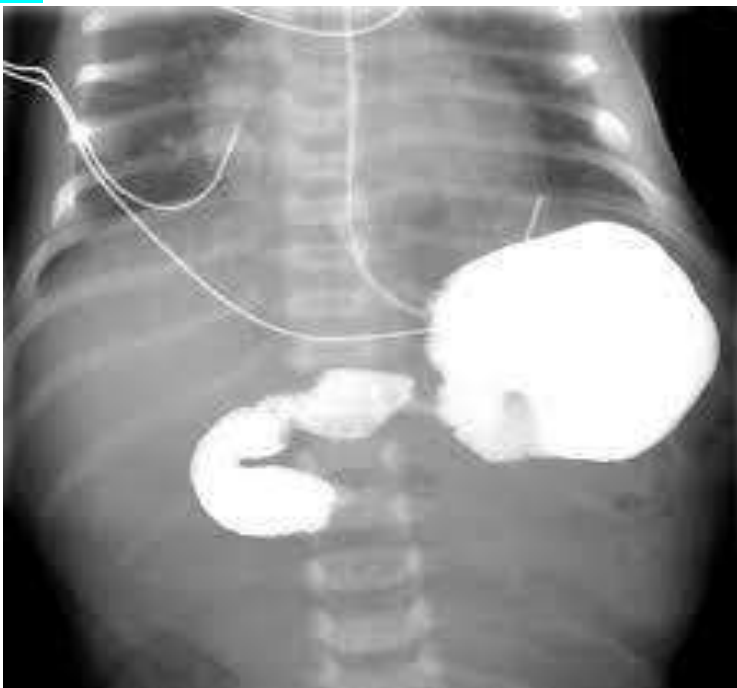


38)



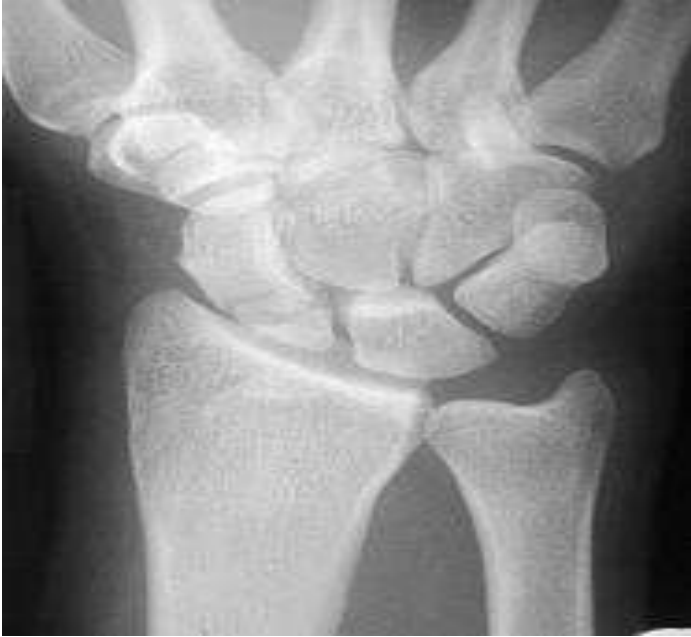Intestinal malrotation ✓

39)



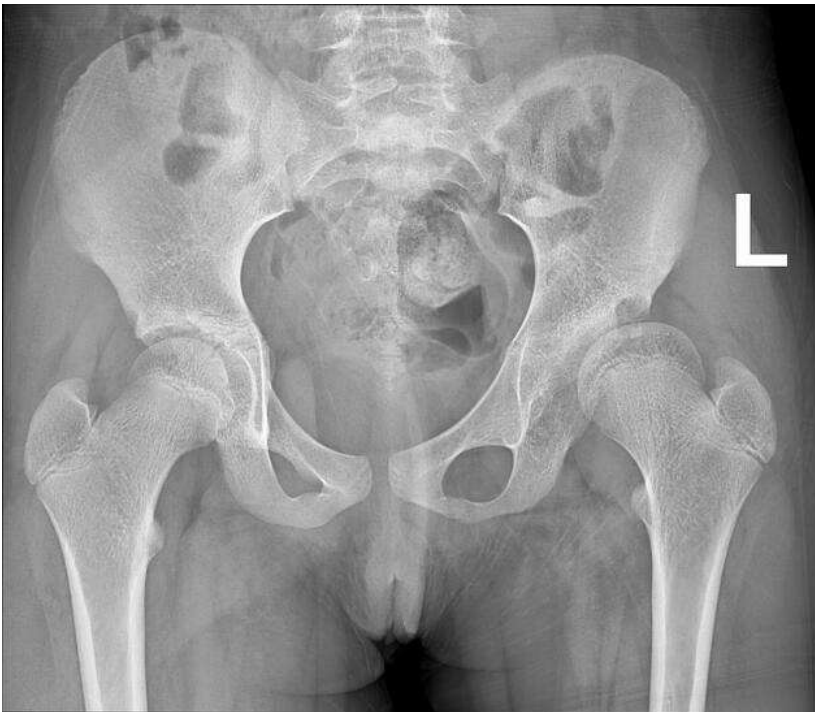
Midgut valvulus ✓

40)



Scaphoid fracture ✓

41)



DDH ✓