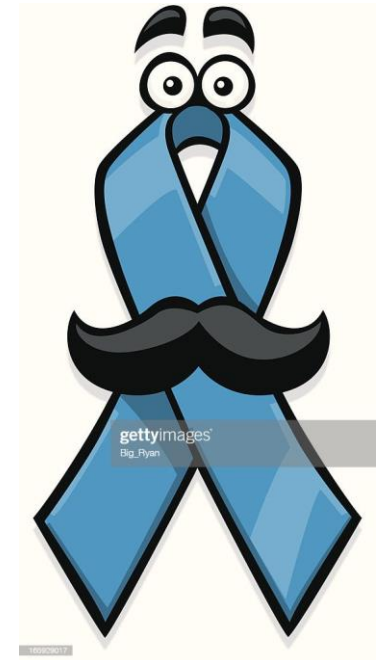

# urogenital system: Male pathology: Prostate



Dr.Eman kreishan, m.d.

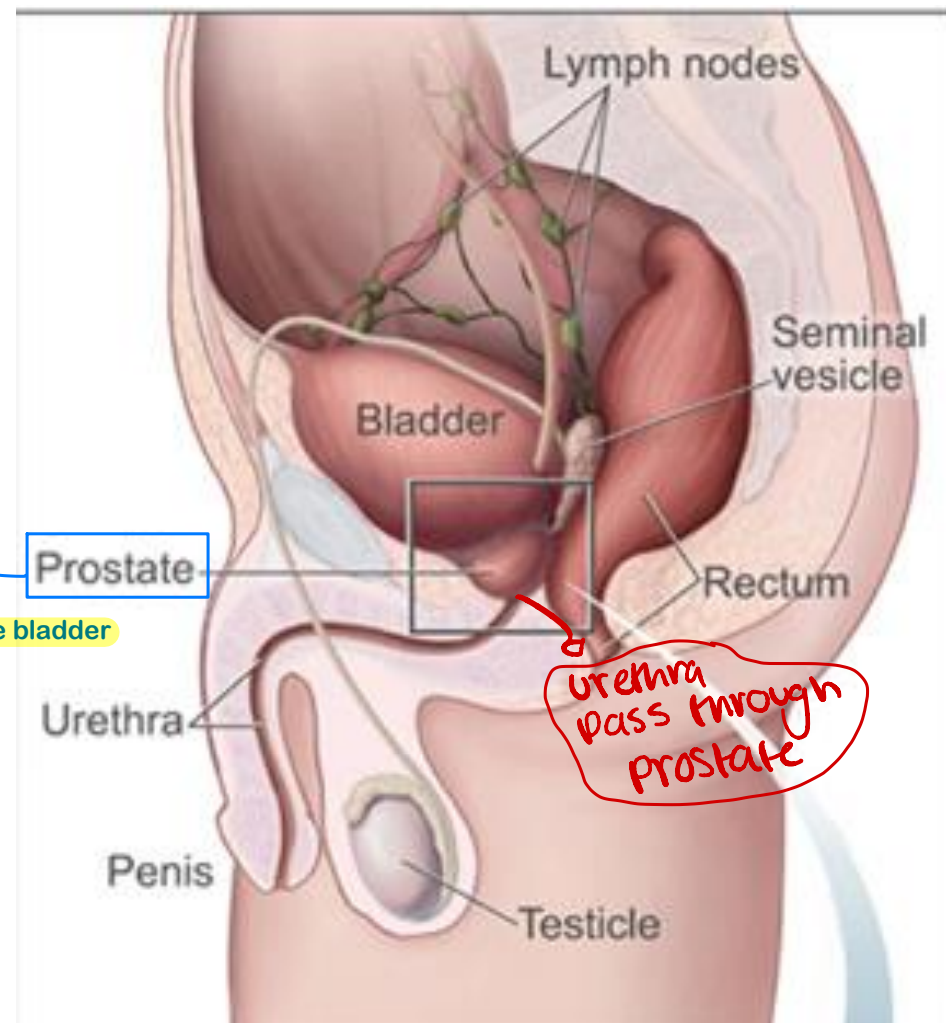
30/4/2025.

# Prostate ..anatomy

accessory  
exocrine gland

لو بدي أوجع شكلها فيه عبارة عن

- 1) Reverse pyramidal structure.
- 2) exist within the pelvis under the bladder
- 3) It's an accessory gland of the male reproductive system



- Anatomical location?

exist within the pelvis  
under the bladder

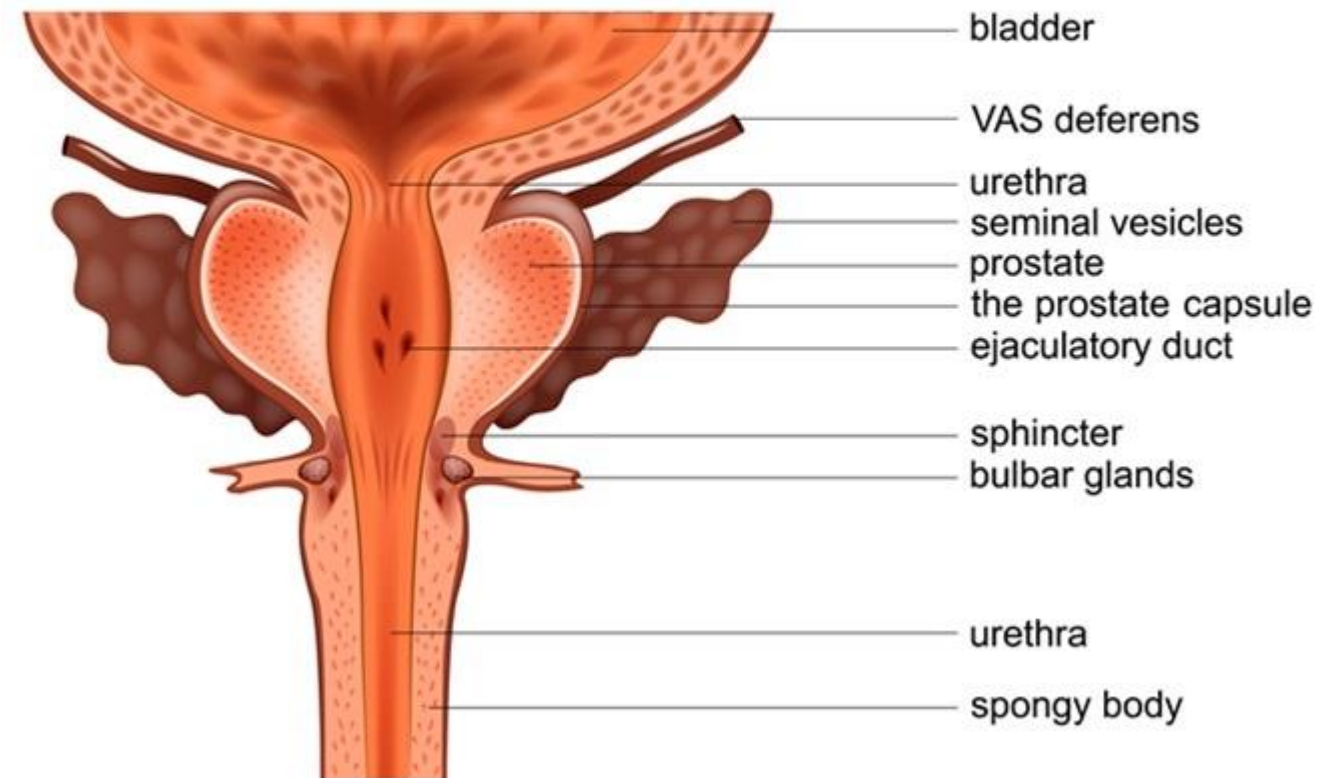
- Weight? ~ 11g

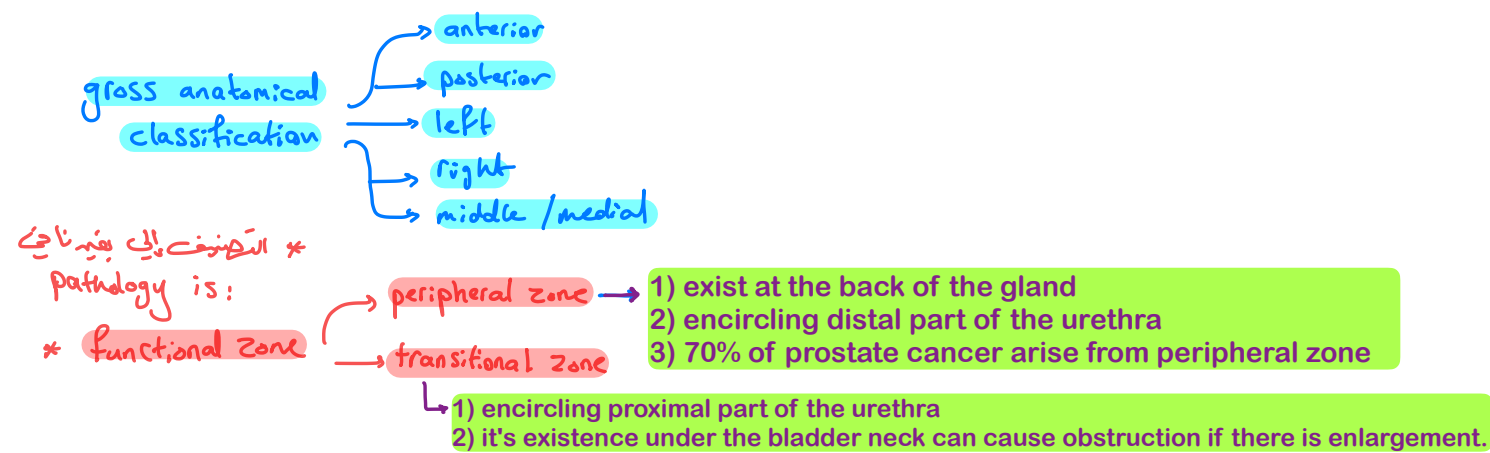
↑ weight w/ age

← مع الزيادة والتقدم في العمر يزداد

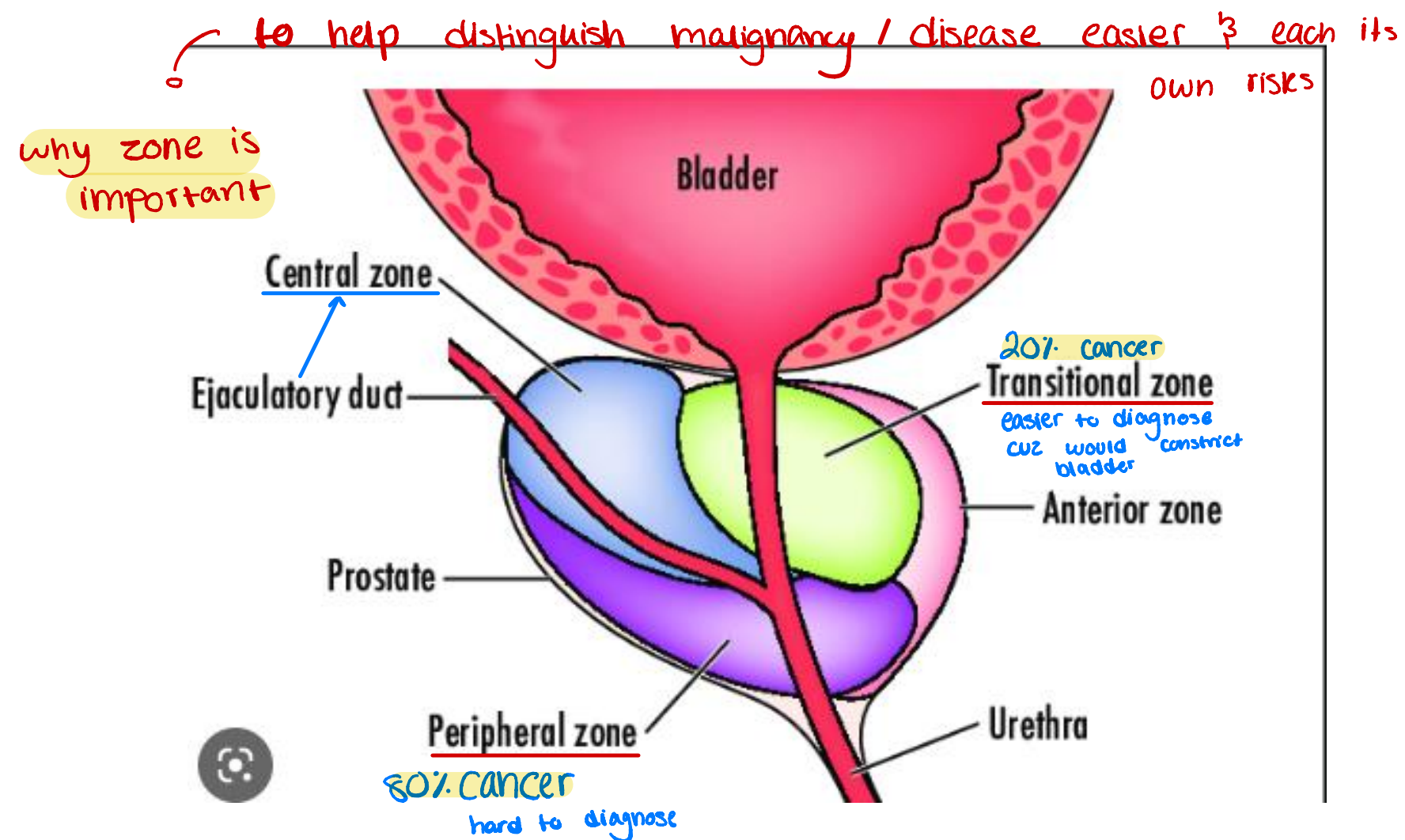
weight of prostate

## PROSTATE





- can be divided into biologically distinct regions, the most important of which are the peripheral and transition zones. ] 2x functional zones





كل المصحة موصلة  
جداً

# Histology

consists of:

glandular tissue  
+  
supporting stroma

هذا prostate gland  
هو

types of epithelium

1) @ center: secretory / columnar

2) @ base: basal cells (single dark stained layer)

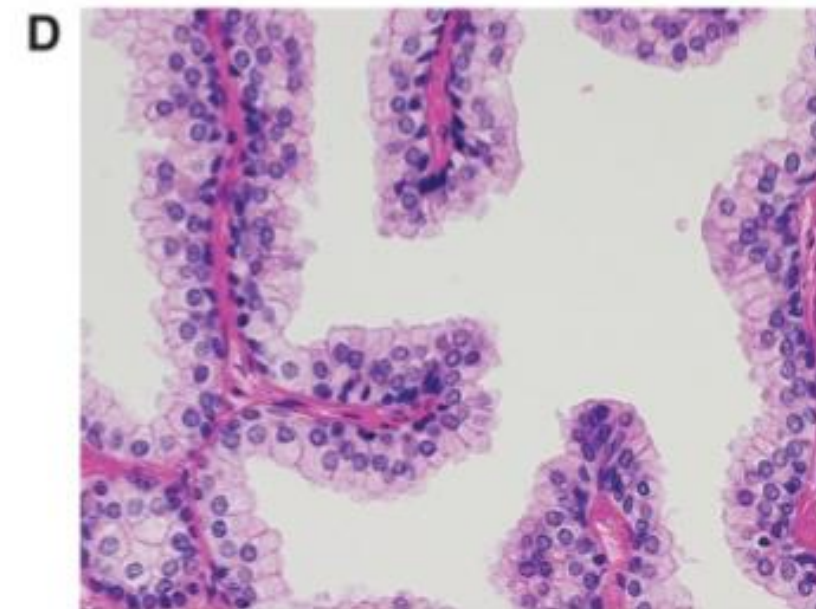
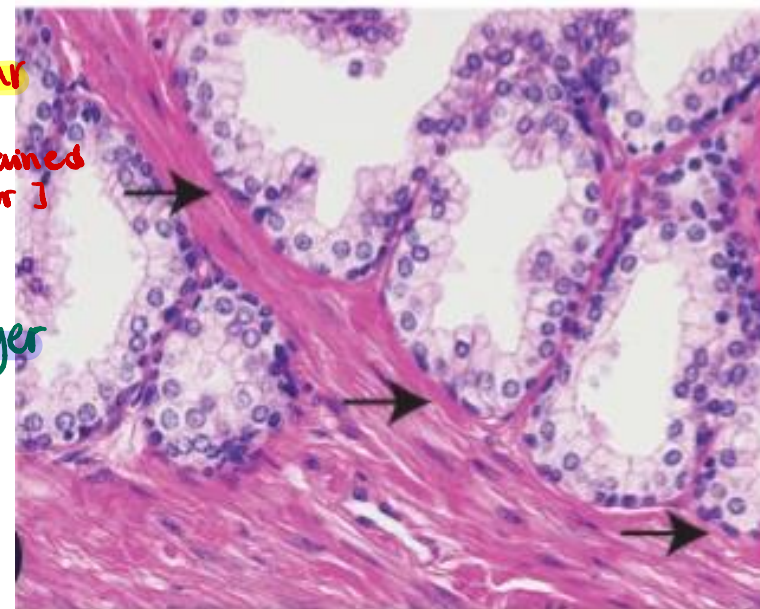
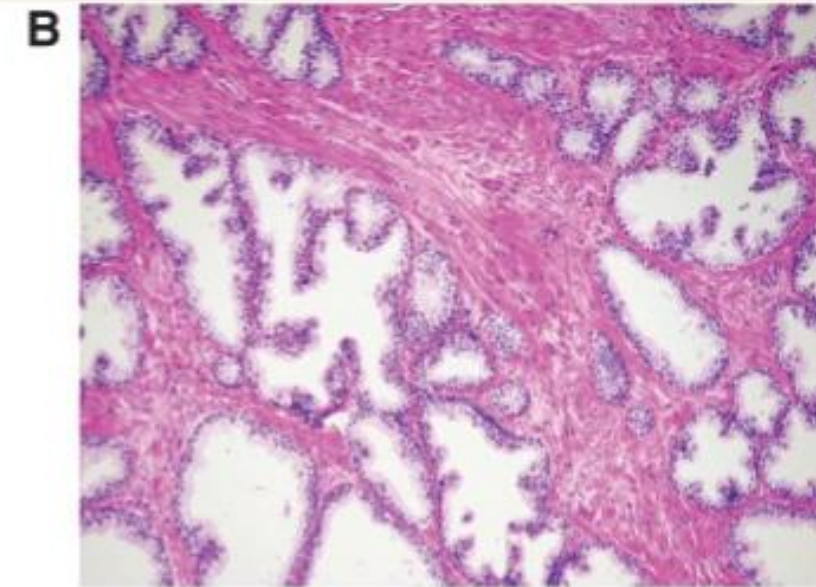
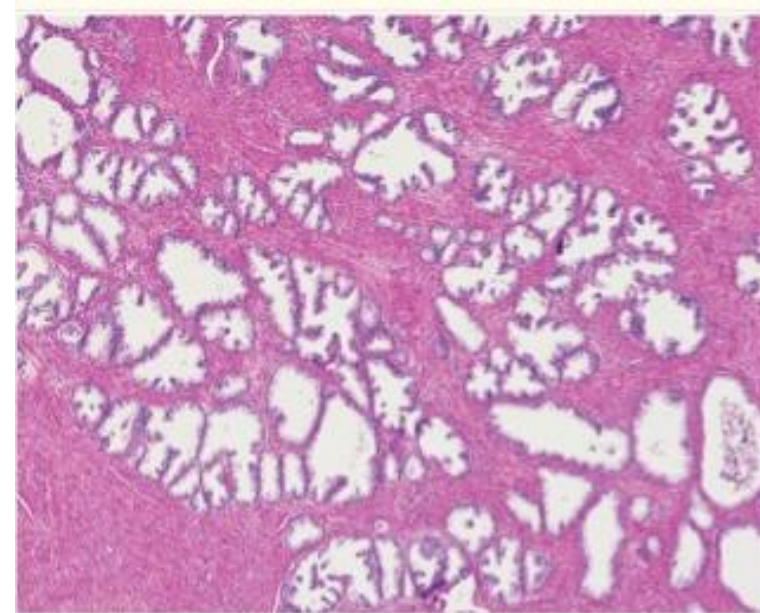
Basal cells  
هو cancer ليس malignant

cancer → basal cell layer

intact  
benign

lost  
malignant

! immune stain highlights basal cell layer → B63 + benign  
- malignant

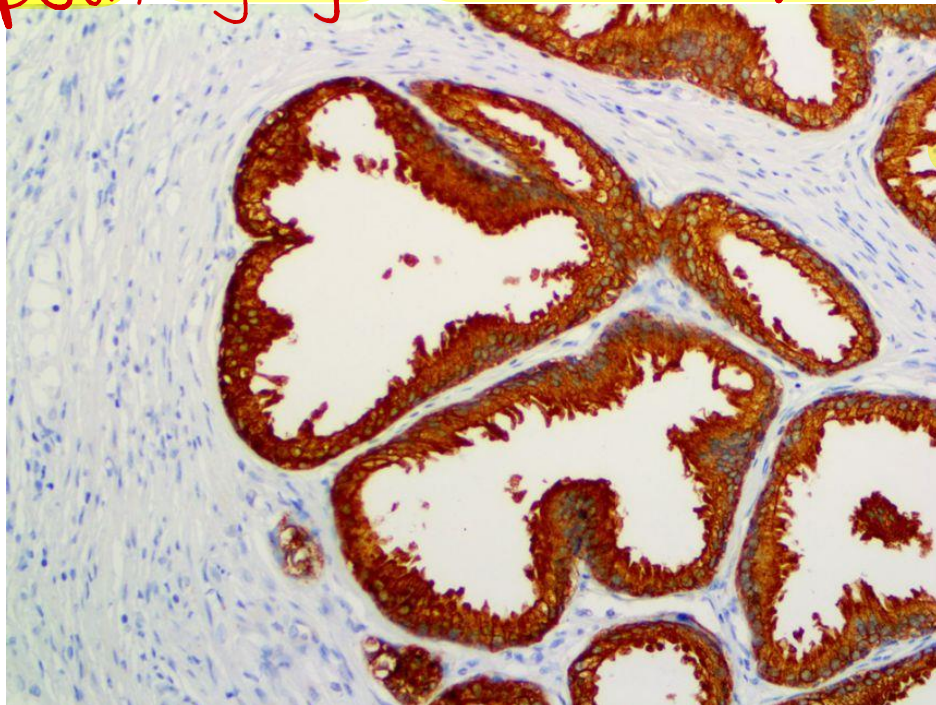




# Prostate— Histology

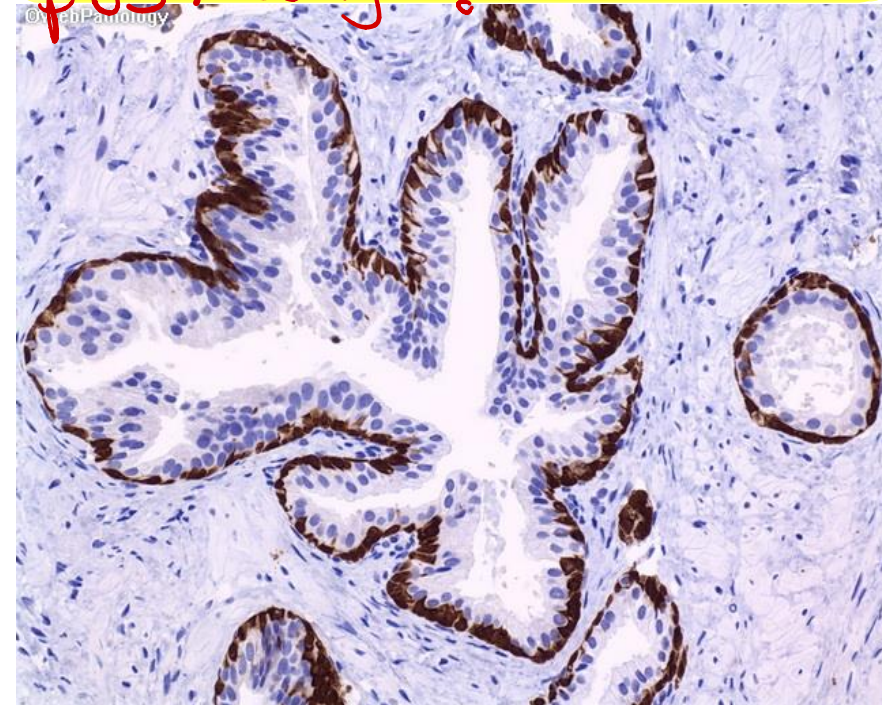- Normal prostate contains **glands** with **two cell layers**, **a flat basal cell layer** & **an overlying columnar secretory cell layer**.
- Surrounding prostatic **stroma** contains a **mixture of smooth muscle and fibrous tissue**.

psa, highlight columnar epith



w/  
mets  
malignant  
cancers  
[secretory]

p63, benign [basal cell layer]



PSA stain (specific for prostatic tissue)

P63 stain

In these two pictures we have used immunostains

\* في عندي مريض old-age أجأ عالجواي، هو ربه حورة  
X-ray وشخت إنه في mass موجودة على lung، في جاعة  
حكو إنه هاي malignant mass وبخوف، شو الخطوة الثانية؟!  
→ we have taken biopsy  
→ to confirm that this mass has a prostatic  
origin we stain it with PSA stain.

- **Prostatic disorders can be classified as:**

- ❖ Hyperplastic lesions

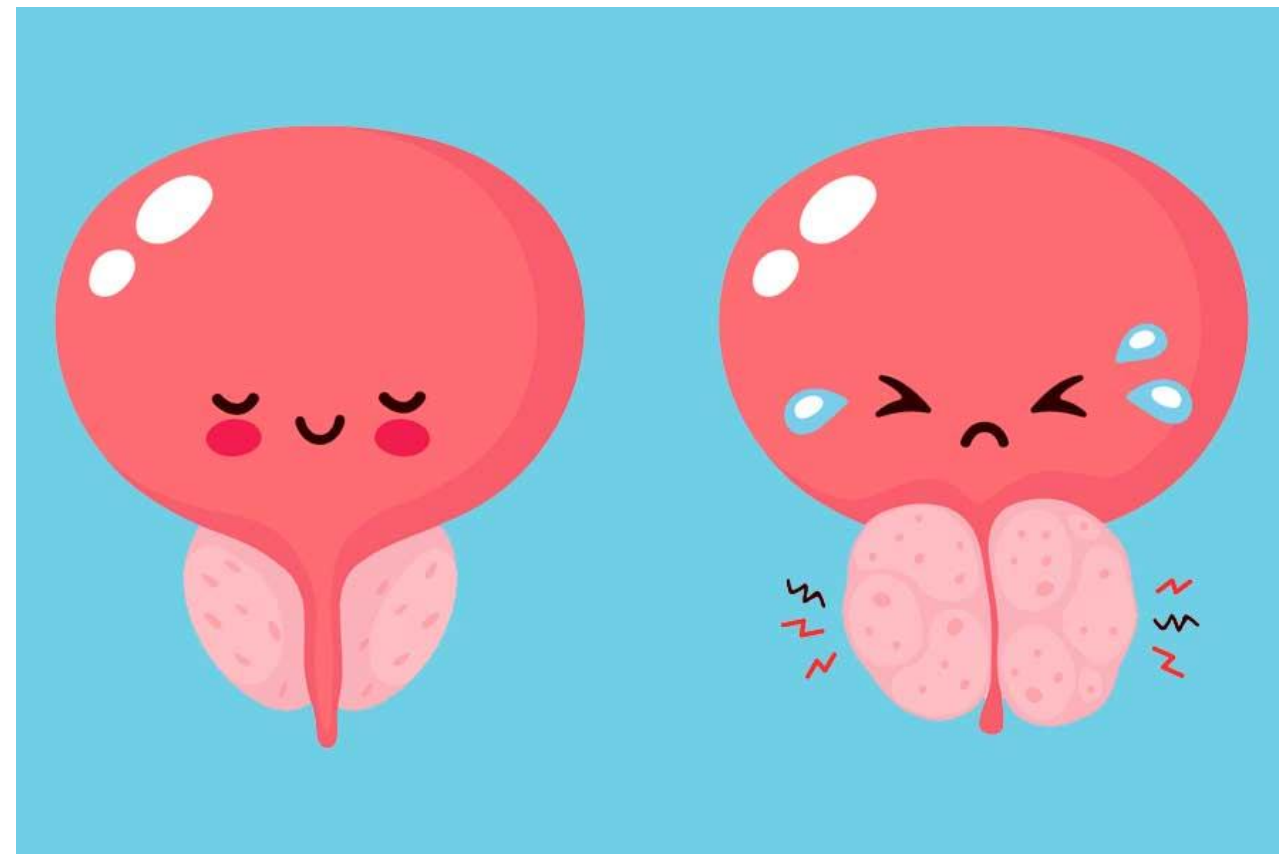
- Most arise in inner transition zone.
- Causes urinary obstruction. → @ proximal part

- ❖ Carcinomas

- 70%–80% arise in peripheral zones.
- Often detected by rectal examination since its @ posterior of the gland

# Hyperplastic lesions from transitioned zone

increase number of cells, benign, that will compress neck of urethra (leading to distension of bladder "painful condition")  
\*\*obstruction increase risk for infections

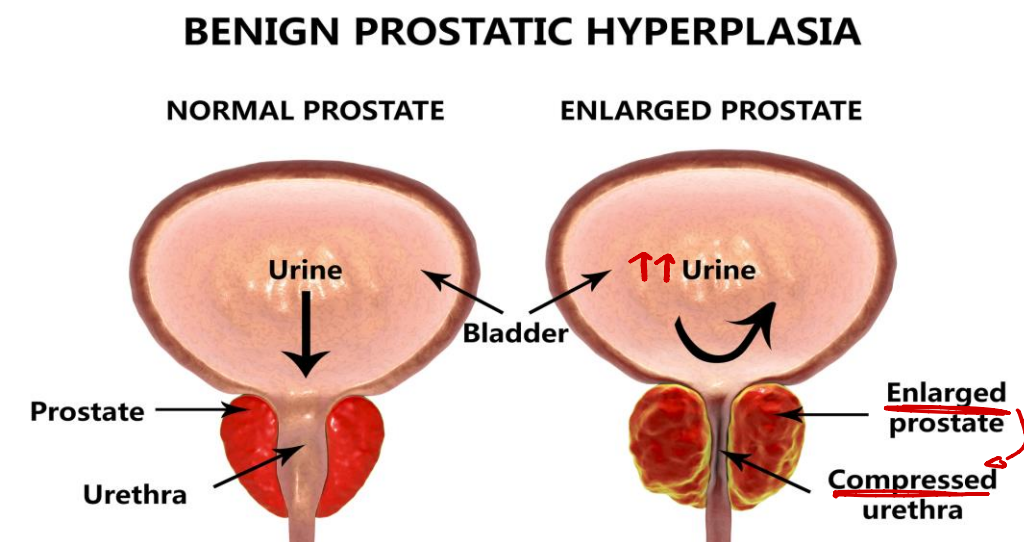




# 1. Benign Prostatic Hyperplasia

- An extremely common cause of prostatic enlargement by the age of 40 years.
- An important cause of urinary obstruction.
- Although the cause of BPH is incompletely understood, excessive androgen-dependent growth of stromal & glandular elements has a central role.
- Does not occur in males castrated before the onset of puberty.

↑  
neuter / removed  
testicles

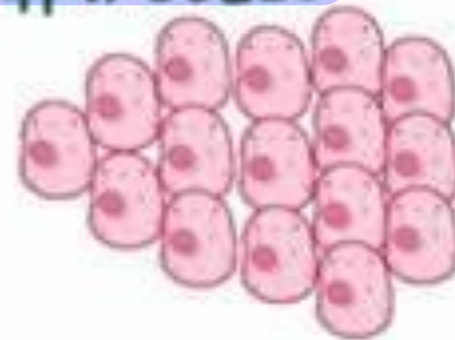

# BENIGN PROSTATIC HYPERPLASIA (BPH)

CELLS AREN'T  
MALIGNANT

PROSTATE  
GLAND

↑ # of CELLS

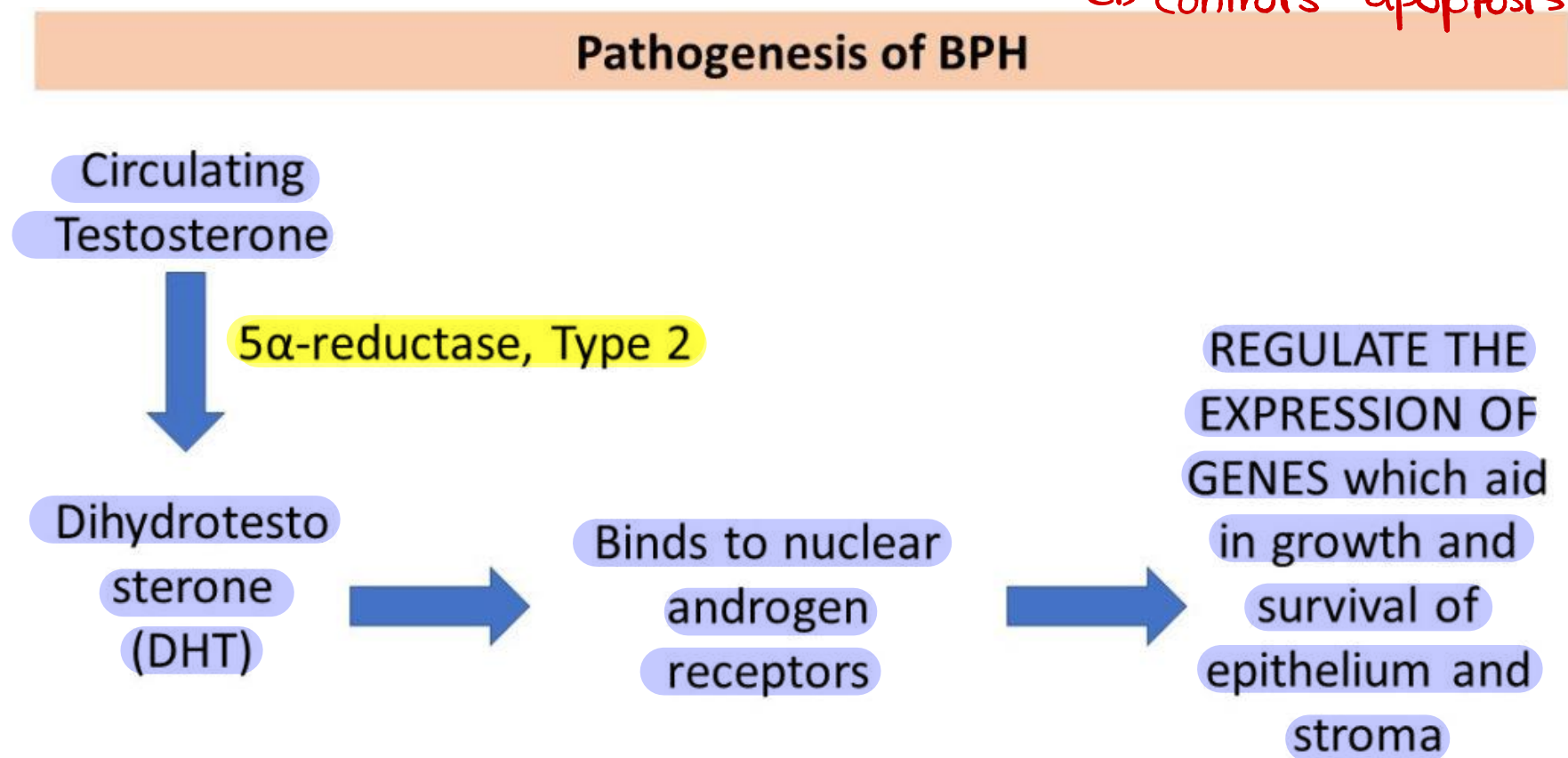


- \* COMMON in MEN OVER 50
- \* OFTEN CONSIDERED a NORMAL PART of AGING

# Pathogenesis

- DHT(Dihydrotestosterone )-induced growth factors act by increasing the proliferation of stromal cells & decreasing the death of epithelial cells.

↳ controls apoptosis

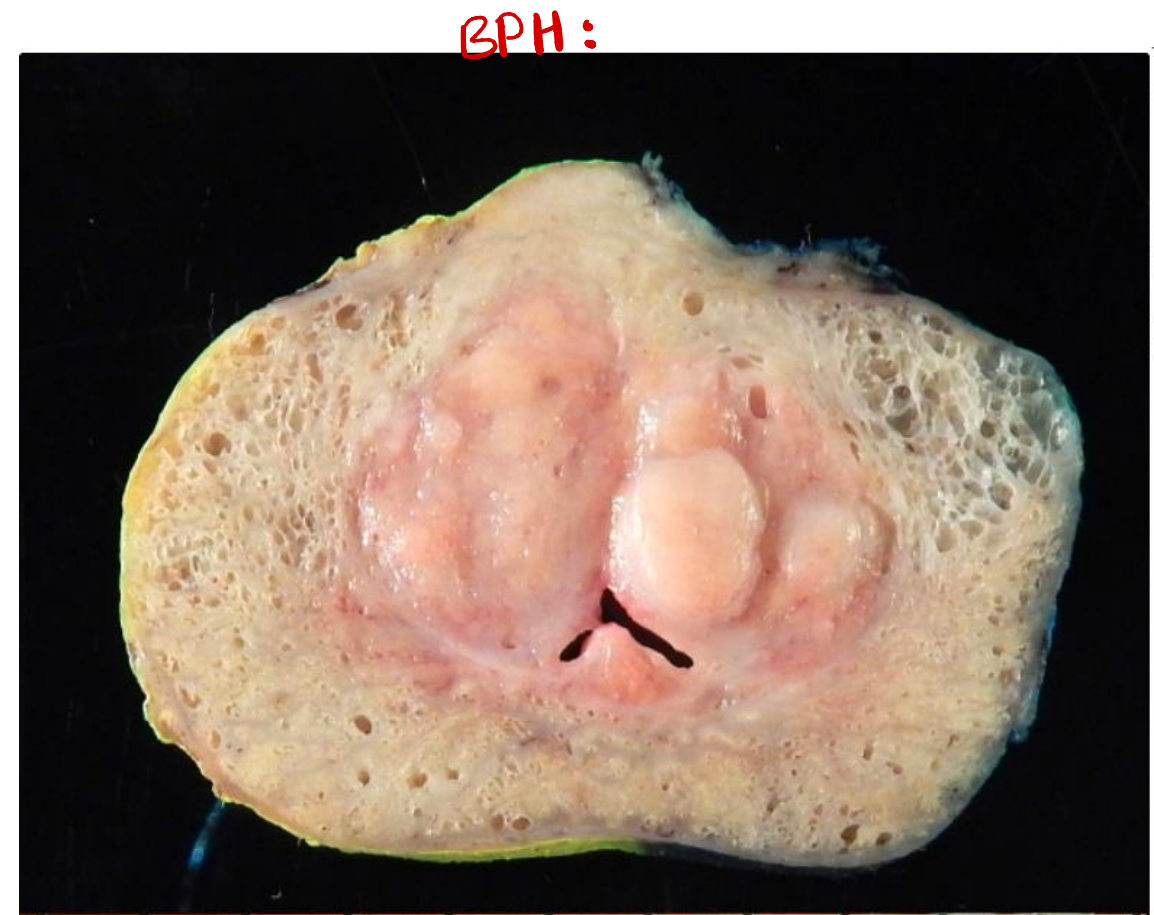
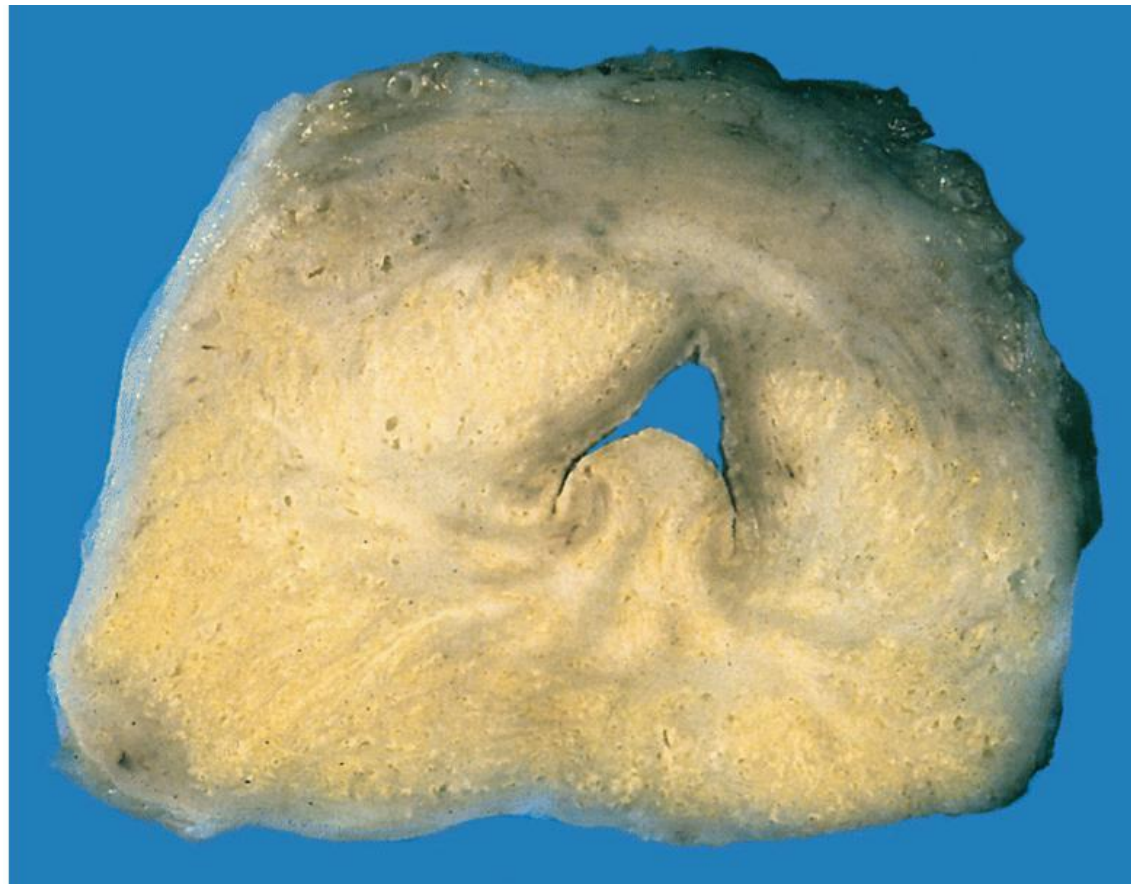



# Macroscopic

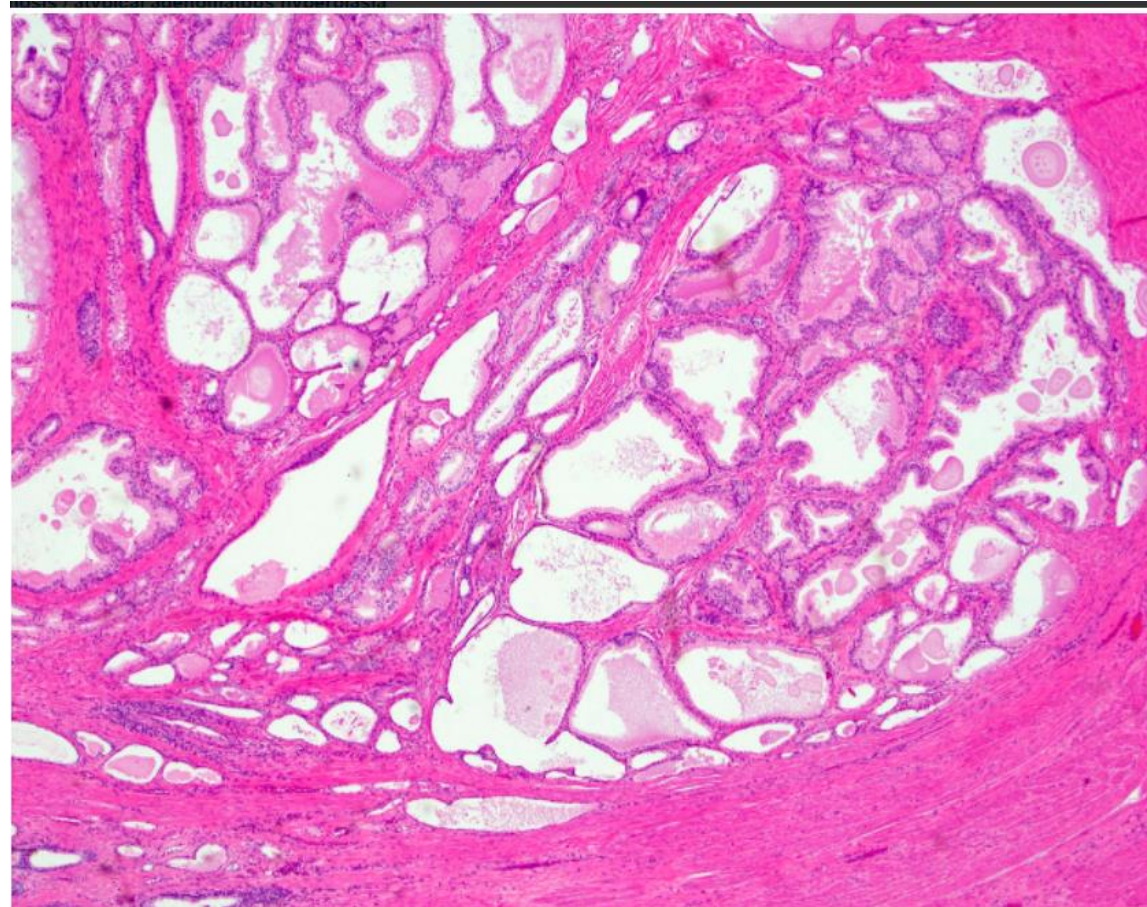
Benign prostatic hyperplasia nodules  
around the urethra bulge above the cut surface in a cross section of the prostate gland.

excessive  
proliferation



# Microscopic

- Epithelial hyperplasia is characterized by nodular lesions composed of variably sized glandular structures lined by basal and secretory cells



# Clinical Features

❖ Symptoms:  
(occur in only 10% of cases) and include:

- urgency, sudden need to pee
- frequency,
- Nocturia (with increased risk of urinary tract infections). @ night

↑↑ bacteria in constricted urine

• Treatment:

❖ Initial pharmacologic; agents inhibit formation of DHT. !

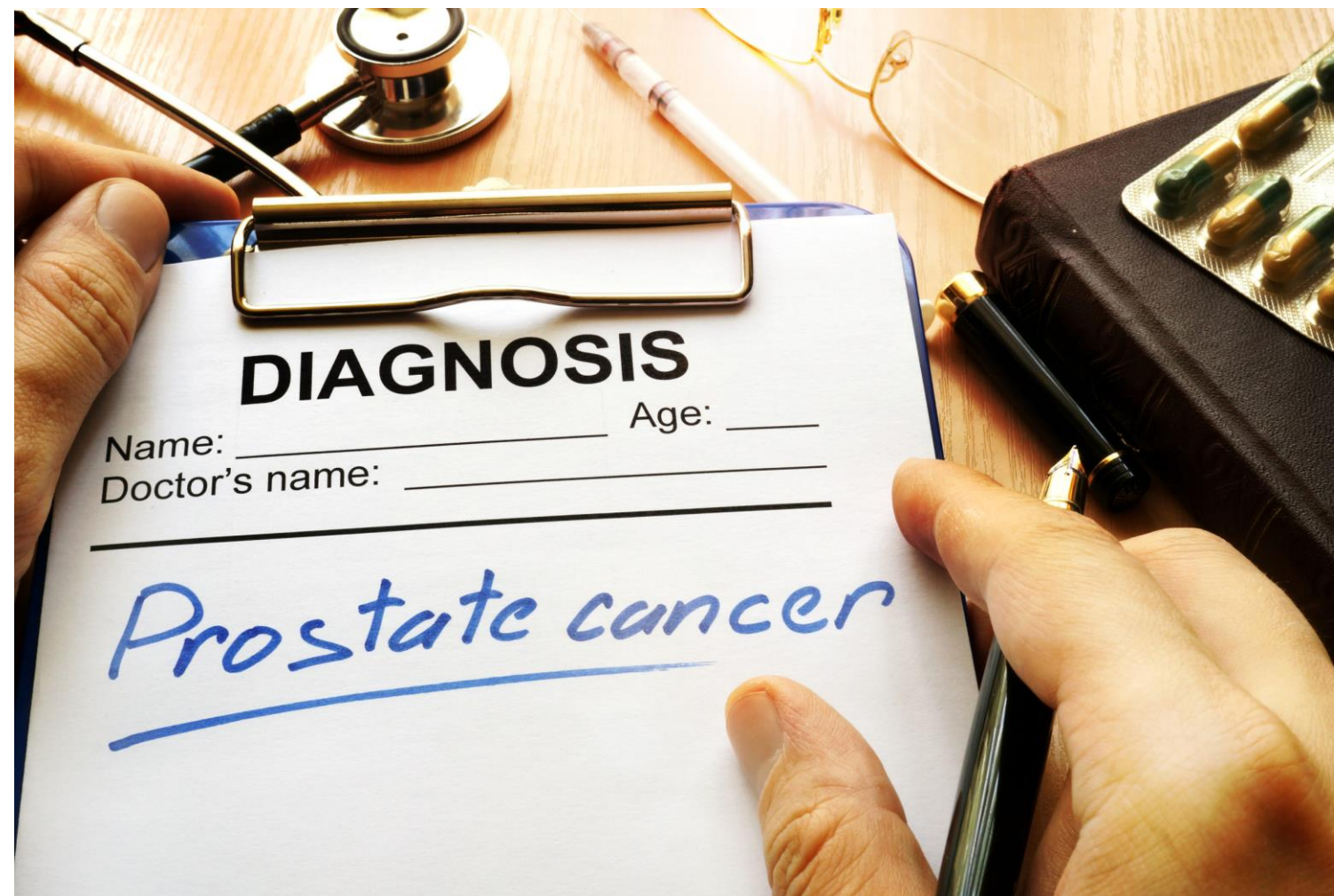❖ Surgical treatment for :

- severely symptomatic cases.
- resistant to medical Rx (Transurethral resection of the prostate (TURP)).

Prostate  
excision

↓ به خوا بنظر عن طريقه از Urethra و بشيوا از nodules  
الموجوده .





# Carcinoma of the Prostate

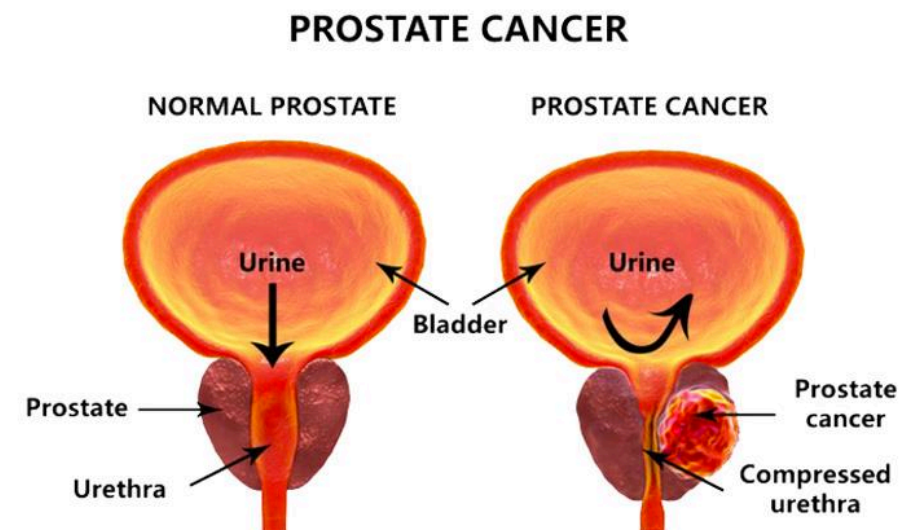
air glandular

- Adenocarcinoma of prostate is the most common form of cancer in men.
- Age: older than 50 years.
- Significant drop in prostate cancer mortality → increase detection of disease through screening.

~ 8  
risk of  
colon cancer  
w/ old age is  
HIGH

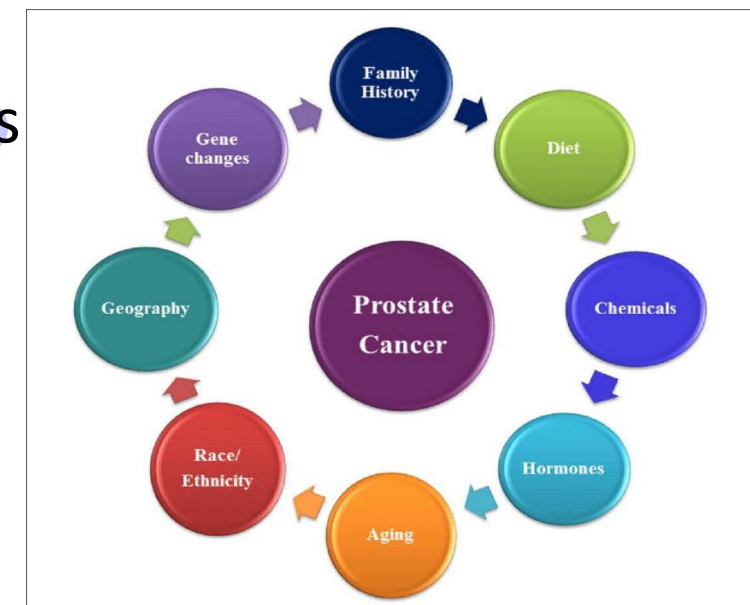
PSA  
Stain  
first,  
since  
P63 is  
expensive

+ colonoscopy



## ❑ Pathogenesis

- Androgens: are of central importance; evident by
- Cancer of the prostate doesn't develop in males castrated before puberty.
- Cancers often regress for a time in response to surgical or chemical castration.
- Heredity.
- Environment:
  - geographical variations that may be due to dietary variations
  - Acquired somatic mutations:
  - + TMPRSS2-ETS fusion genes are found in ~ 50% of cases.



غالباً ما يصير الأمر إذا  
كان في ما الأهل  
\* genetic background

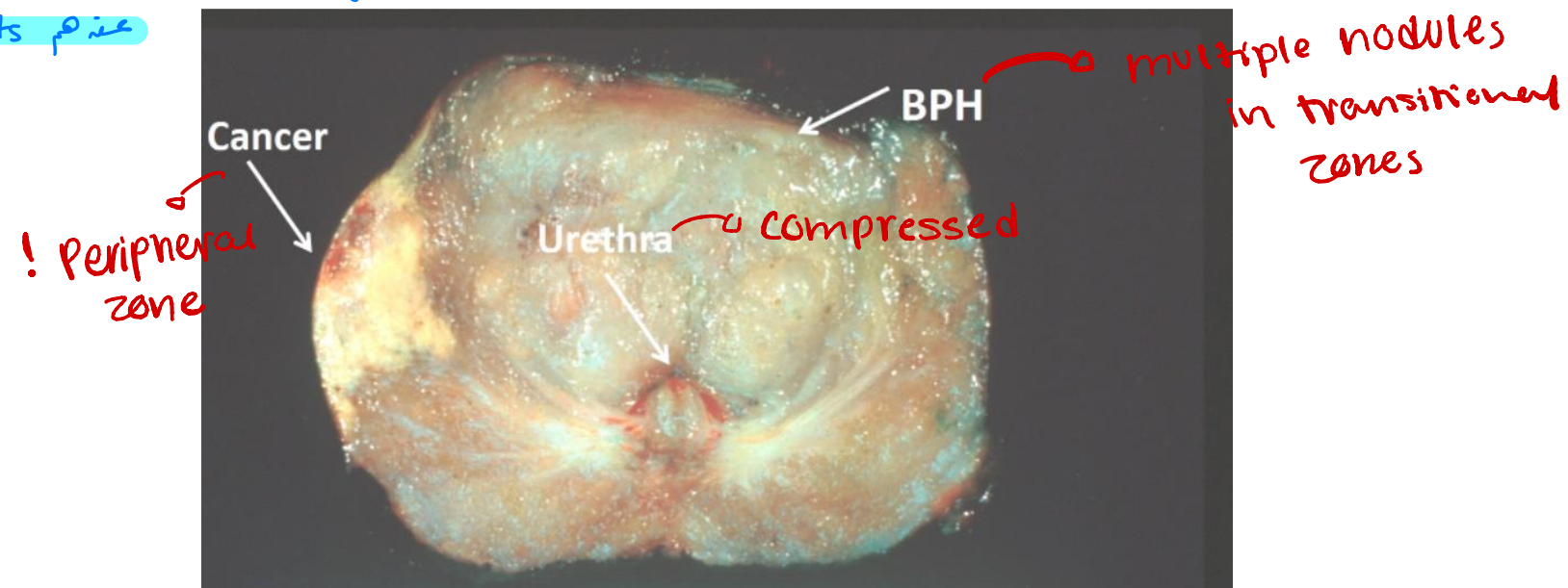


# Morphology

- GROSS: firm, gray-white lesions with ill-defined margins.
- Most tumors are multifocal. *so radiotherapy is needed*
- 75 - 80% are posterior / posterolateral peripheral zone

وجودها في peripheral zones بأكثر من ١٠٪ asymptomatic لا نكتشفهم بدون PSA

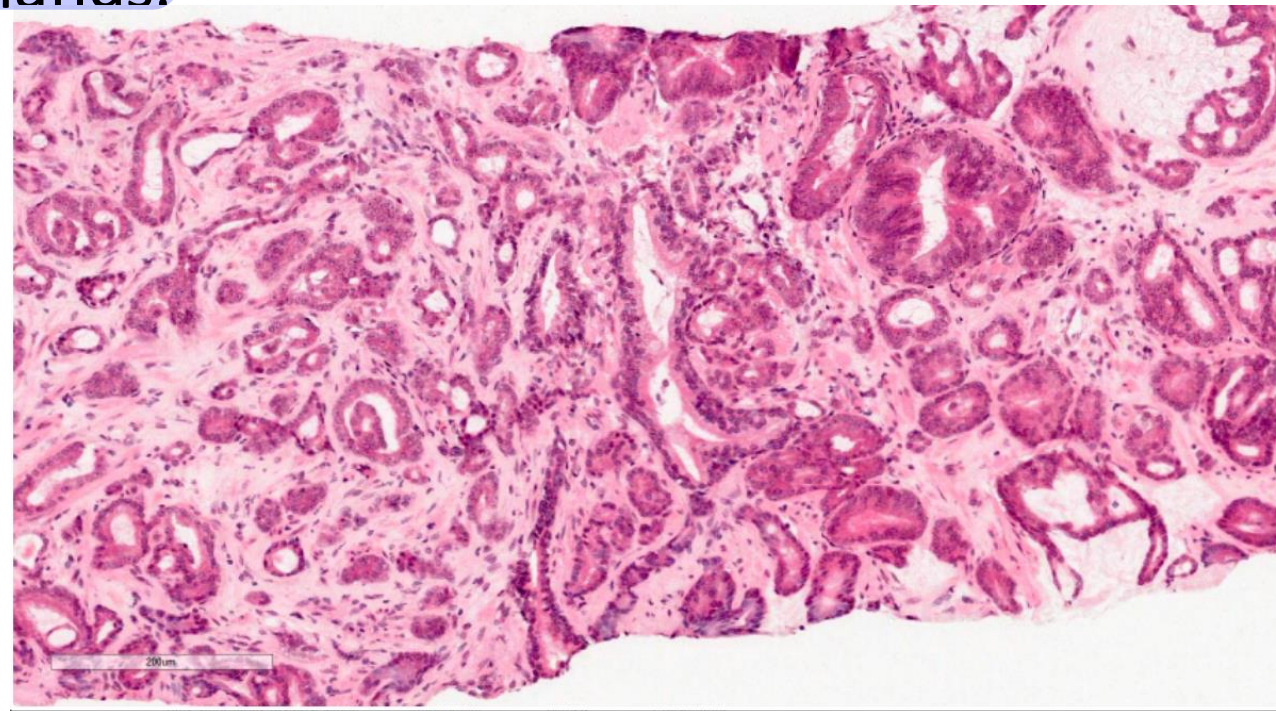
عندهم mets



# Microscopically



- well-defined glands, typically smaller than benign glands and are lined by a ~~single~~ uniform layer of cuboidal epithelium, lacking basal cell layer seen in benign glands.

since its  
malignant



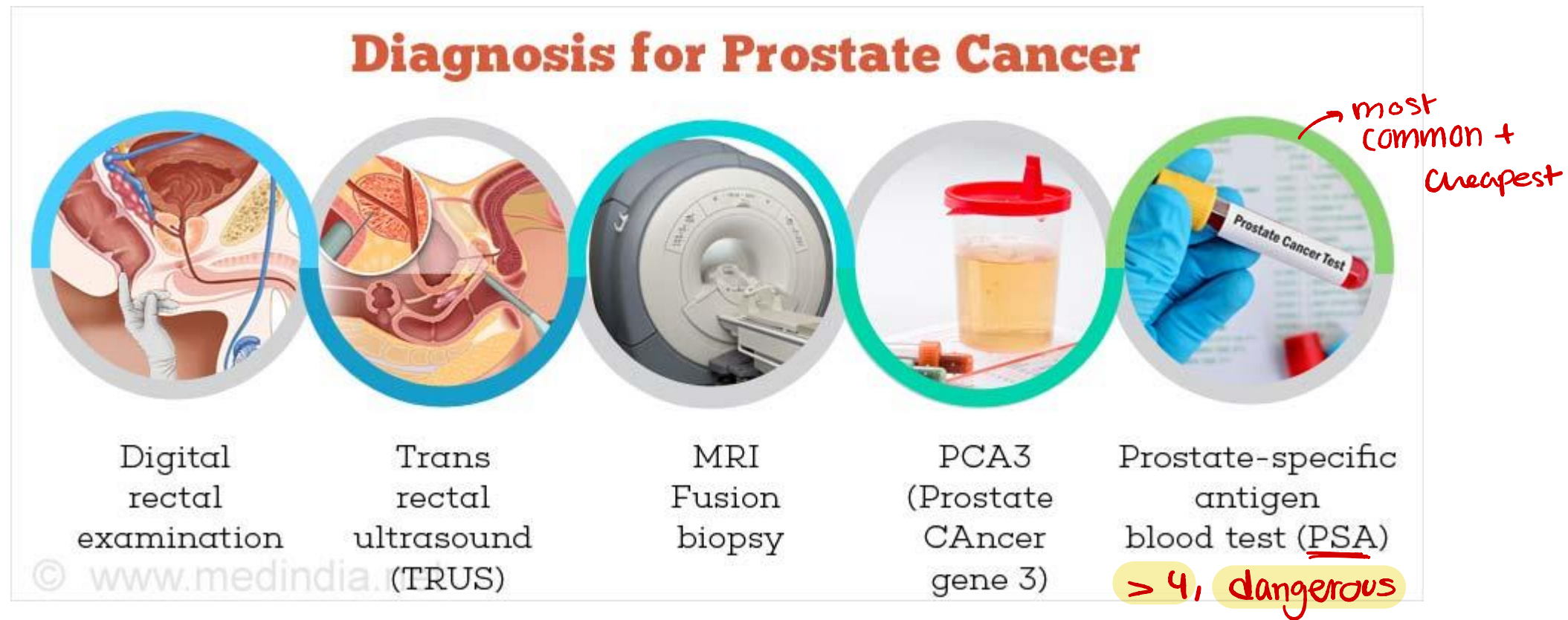
P63 stain will give a negative result

# clinical features

- Generally asymptomatic unless locally advanced or metastatic
- Often discovered following investigation of nonspecific lower urinary tract symptoms.
- Serum screening tests: elevated prostate-specific antigen (PSA) level. 
- Digital rectal examination (DRE): prostate may feel normal or may be enlarged / asymmetrical.
- Bone metastases, particularly to the axial skeleton, are frequent late in the disease and typically cause osteoblastic  (bone-producing) lesions.



# Diagnosis

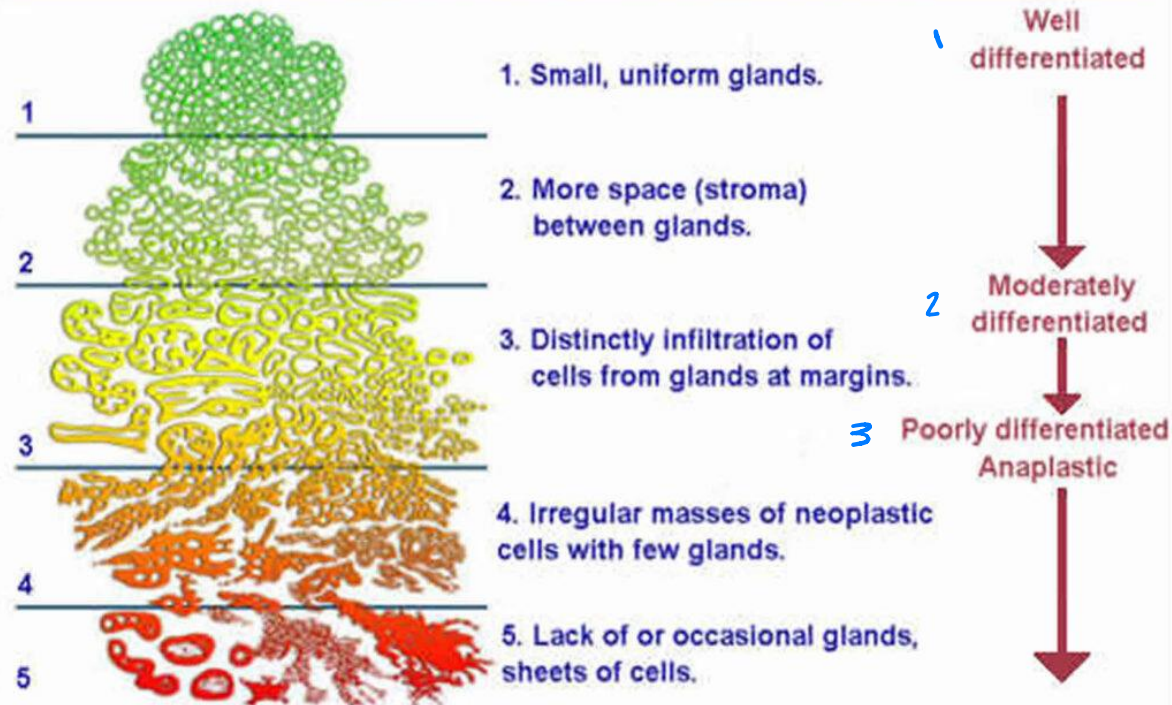


# Treatment.

- The most common treatments for clinically localized prostate cancer are radical prostatectomy and radiotherapy.  
↳ multifocal lesions
- The prognosis after radical prostatectomy is based on:
- the pathologic stage<sup>1</sup> → mets.
- the margins<sup>2</sup> of the resected specimens are free of tumor or not.
- Gleason grade<sup>3</sup> (grading system on the basis of glandular patterns of differentiation)  
↳ similarity to its original form

مست حفظ  
بس للفهم

## Gleason's Pattern Scale



## PROSTATE CANCER STAGES

- Stage I** - the cancer is small and only in the prostate
- Stage II** - the cancer is larger and may be in both lobes of the prostate but is still confined to the prostate
- Stage III** - the cancer has spread beyond the prostate to close by lymph glands or seminal vesicles
- Stage IV** - the cancer has spread to other organs such as the bone and is referred to as metastatic cancer. If prostate cancer spreads, or metastasizes, to the bone, you have prostate cancer cells in the bone, not bone cancer

For a detailed description of each stage, see the information at the bottom of the page.  
Detailed Staging, adapted from [www.cancer.gov](http://www.cancer.gov).