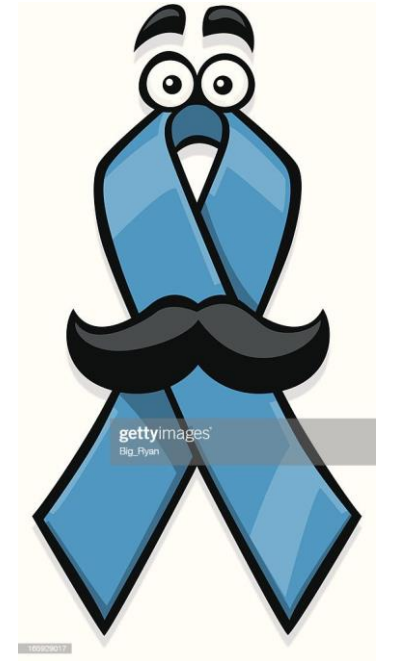

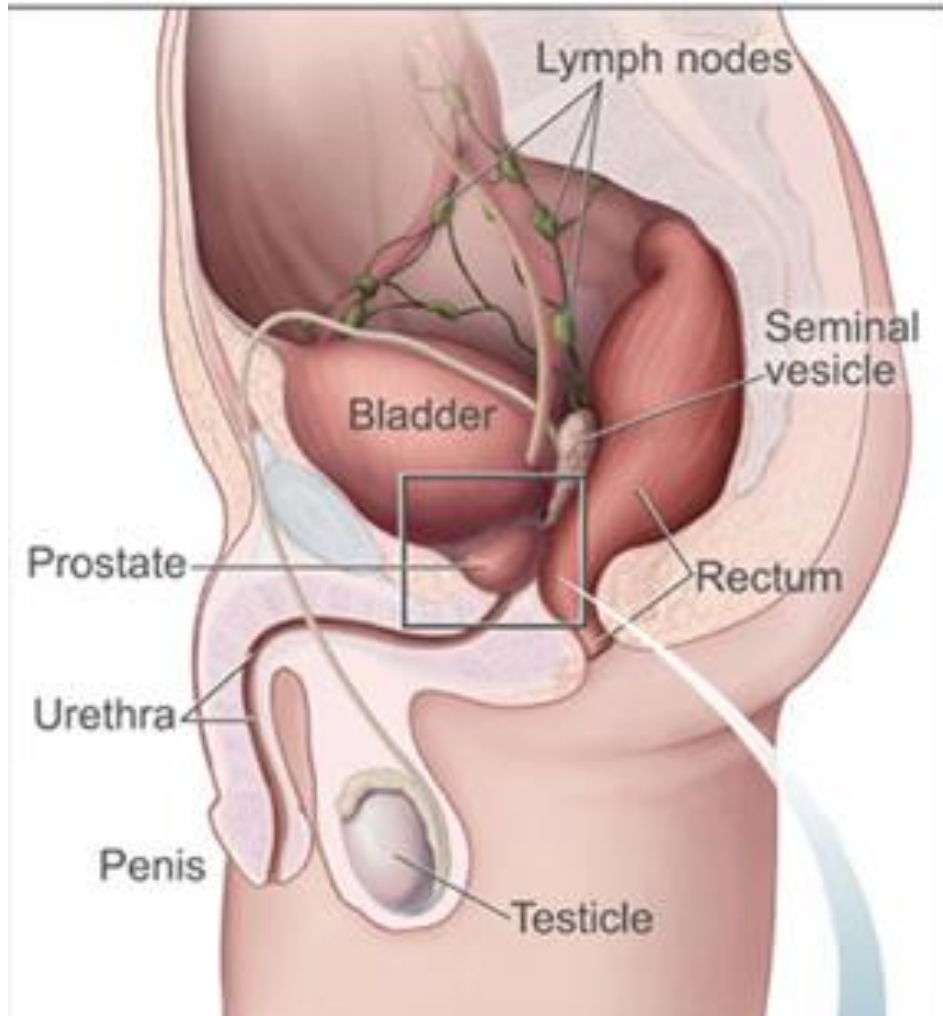
urogenital system: Male pathology: Prostate



Dr.Eman kreishan, m.d.

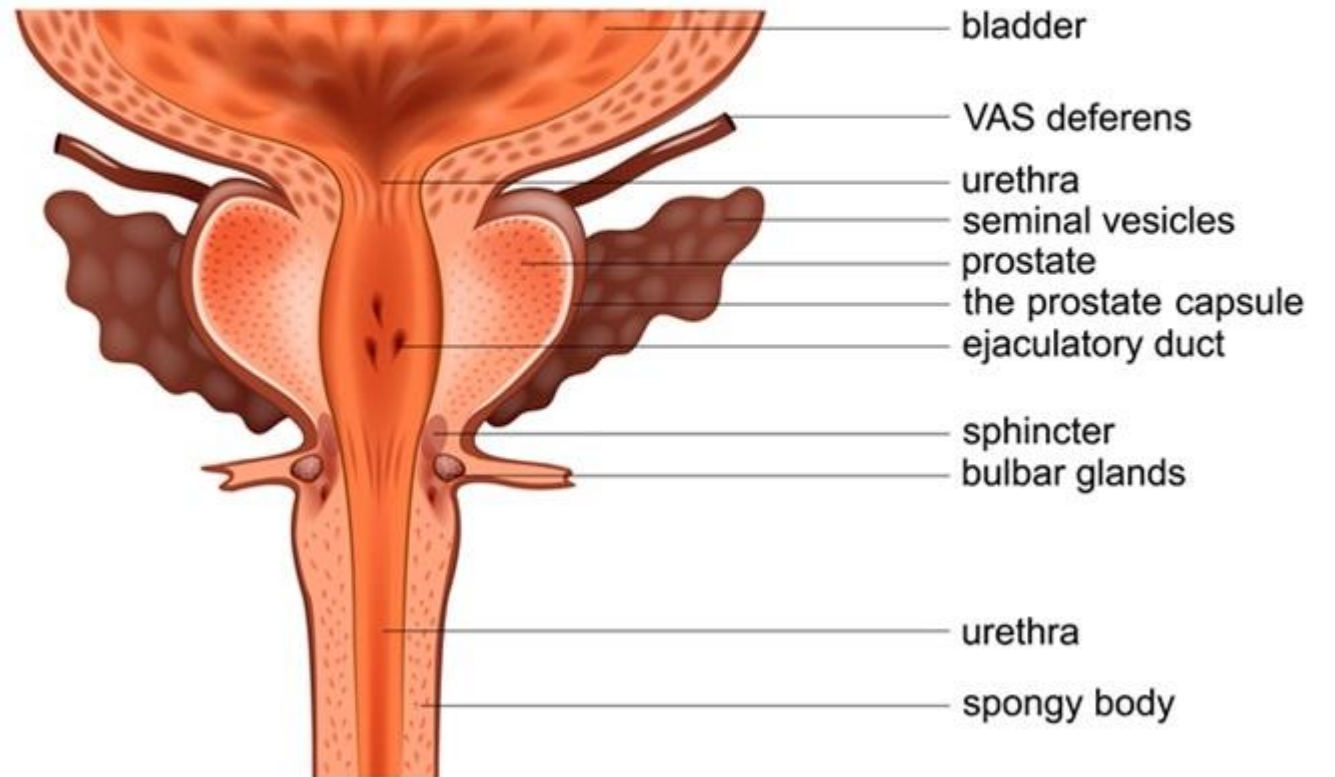
30/4/2025.

Prostate ..anatomy

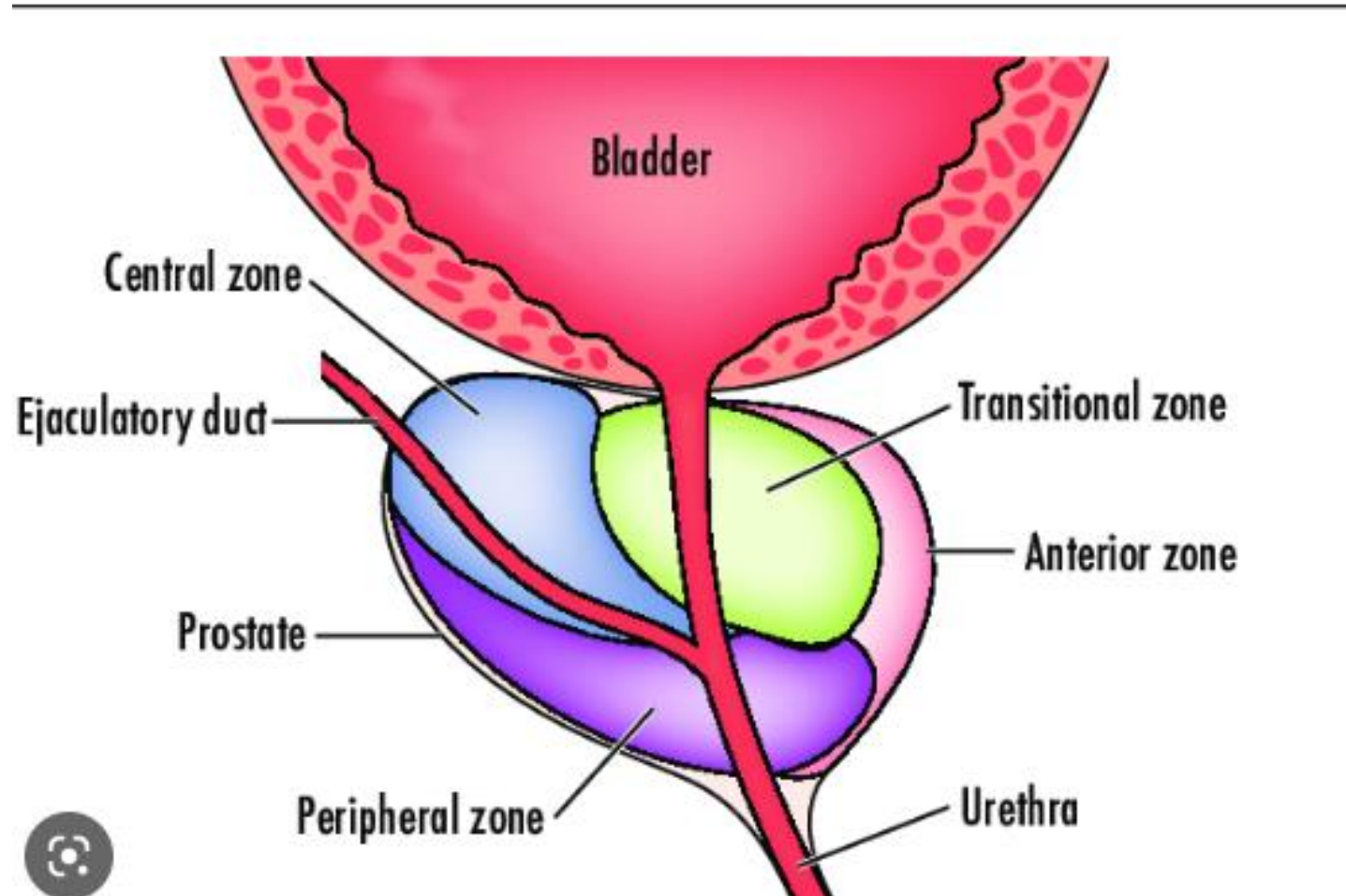


- **Anatomical location?**
 - **Weight?**

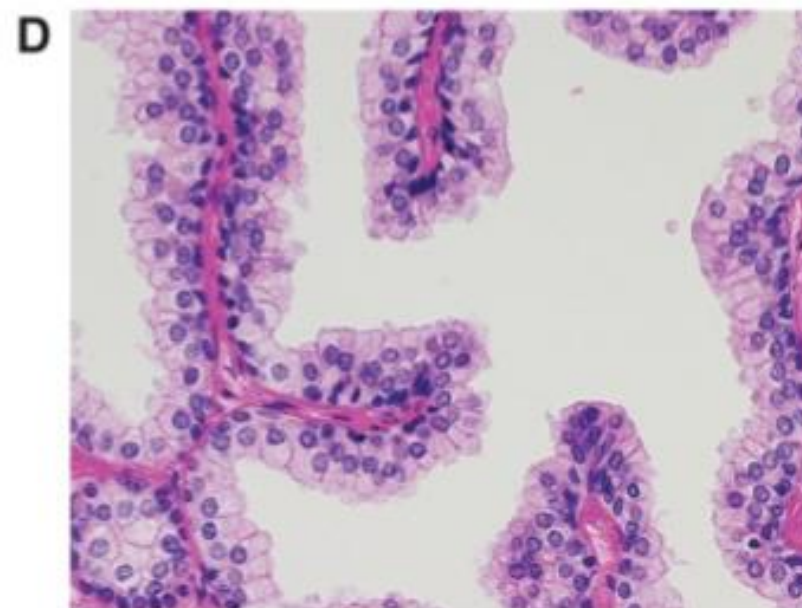
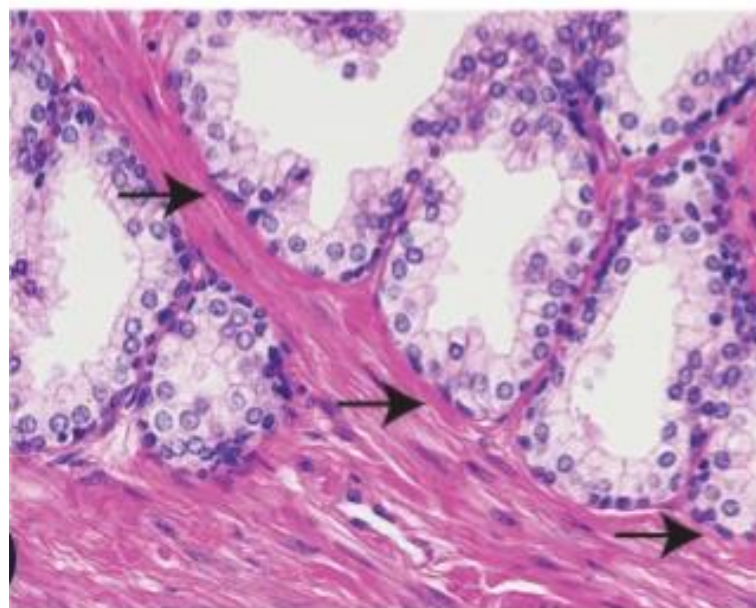
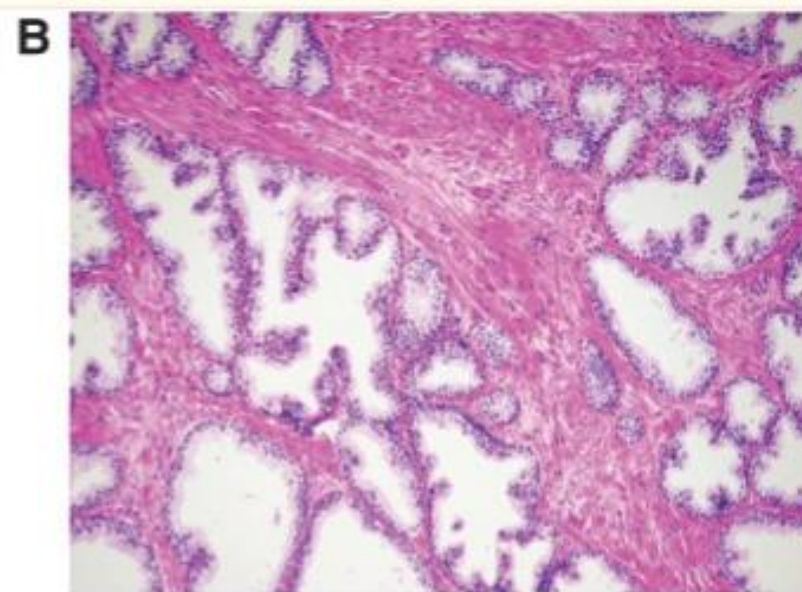
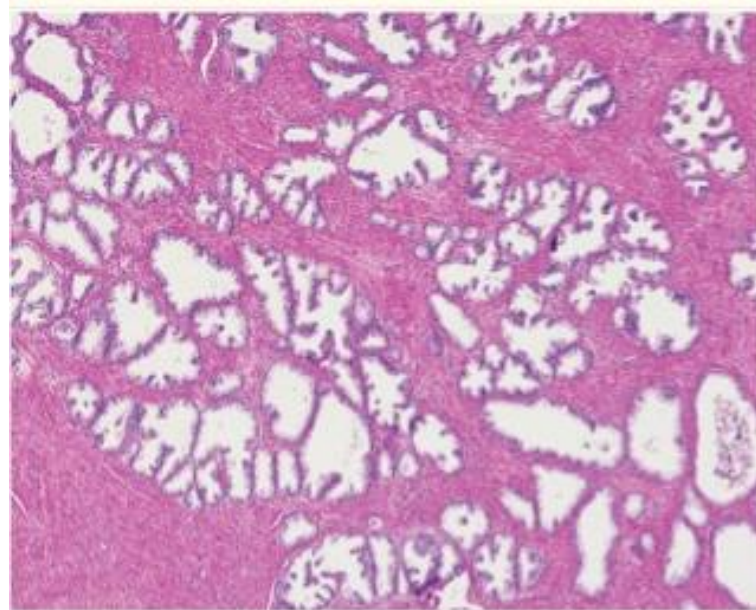
PROSTATE



- can be divided into biologically distinct regions, the most important of which are the peripheral and transition zones.

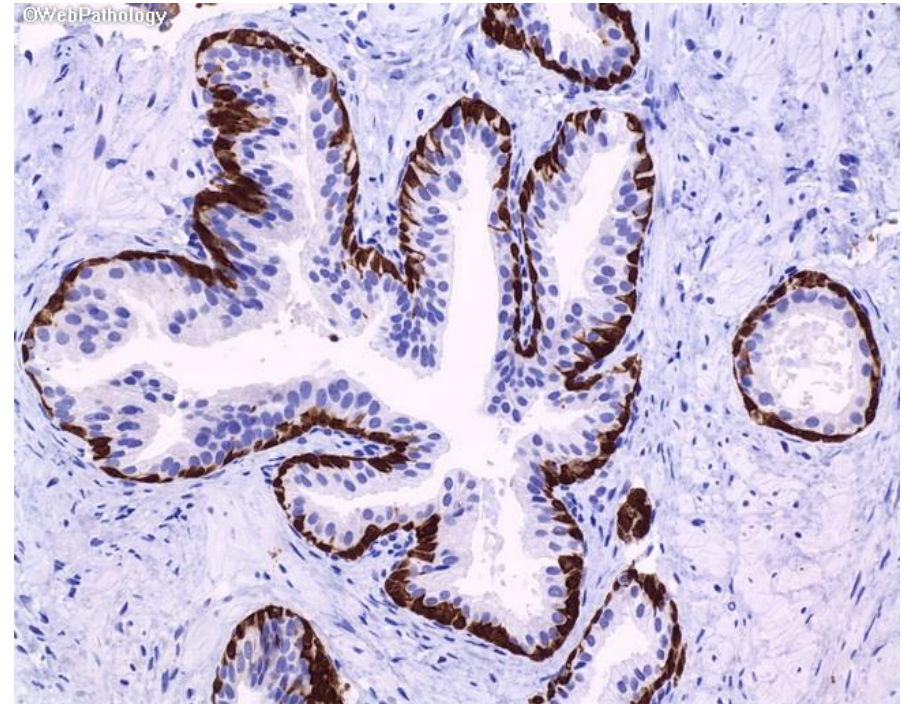
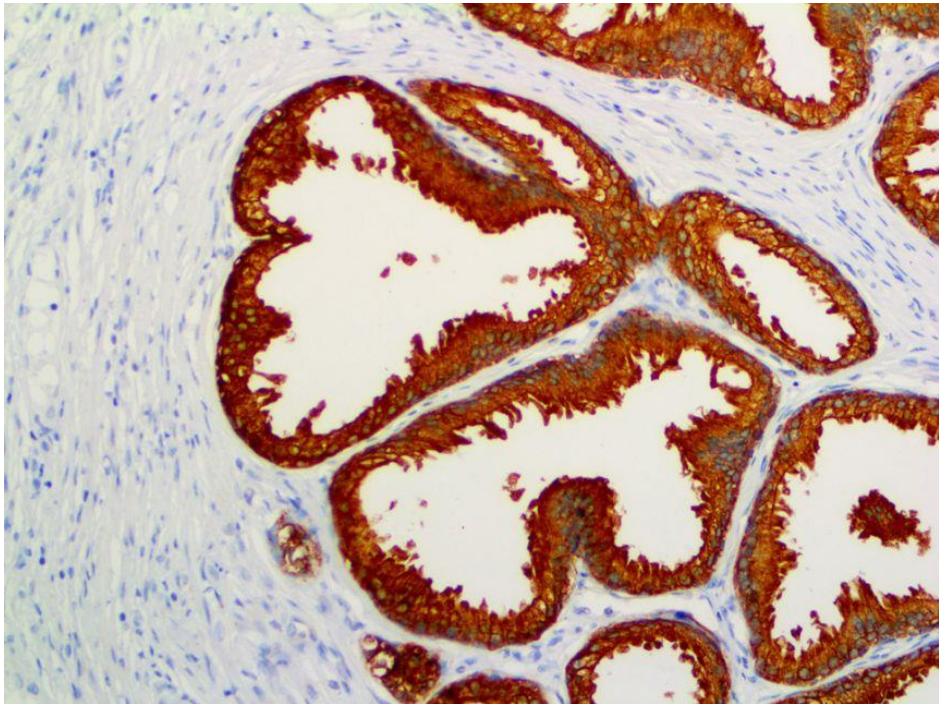


Histology



Prostate– Histology

- Normal prostate contains glands with two cell layers, a flat basal cell layer & an overlying columnar secretory cell layer.
- Surrounding prostatic stroma contains a mixture of smooth muscle and fibrous tissue.



- **Prostatic disorders can be classified as:**

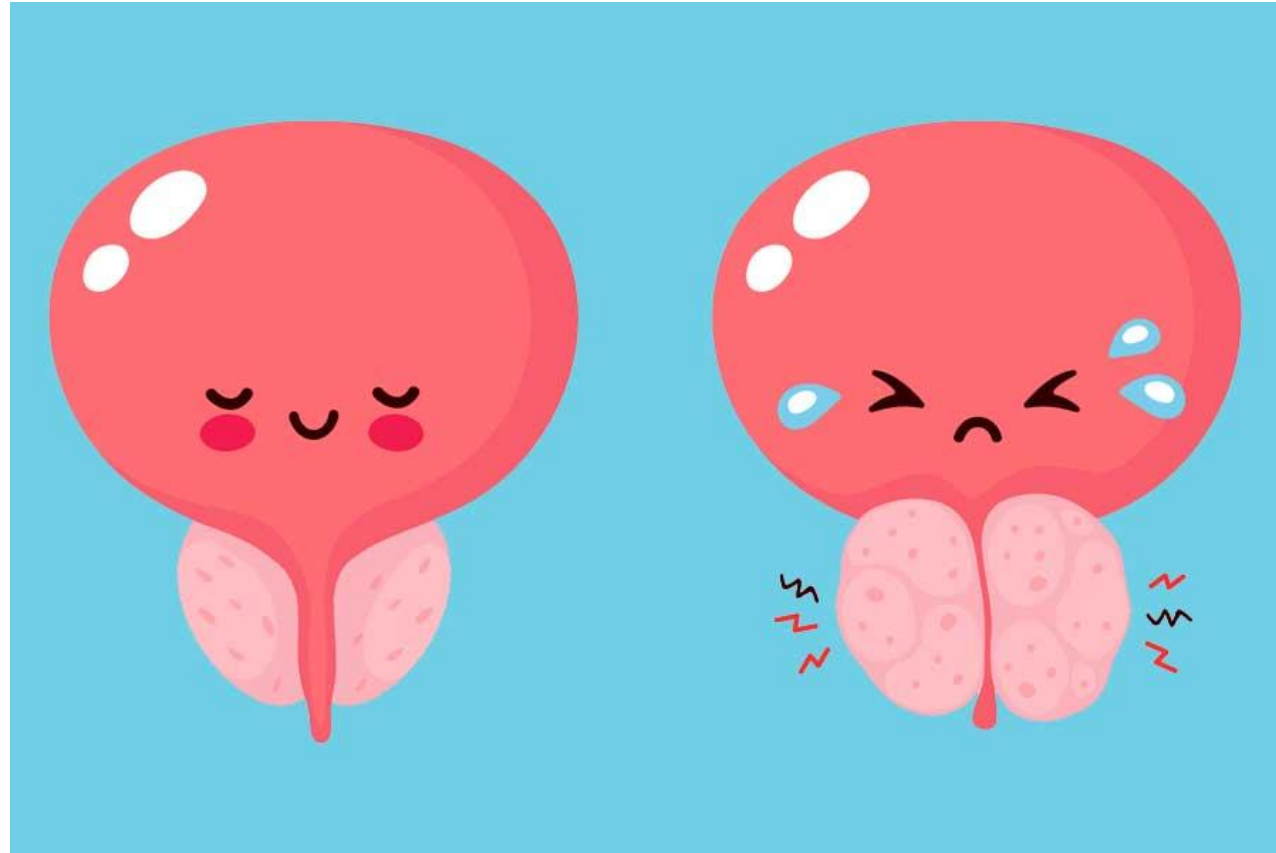
- ❖ Hyperplastic lesions

- Most arise in inner transition zone.
- Causes urinary obstruction.

- ❖ Carcinomas

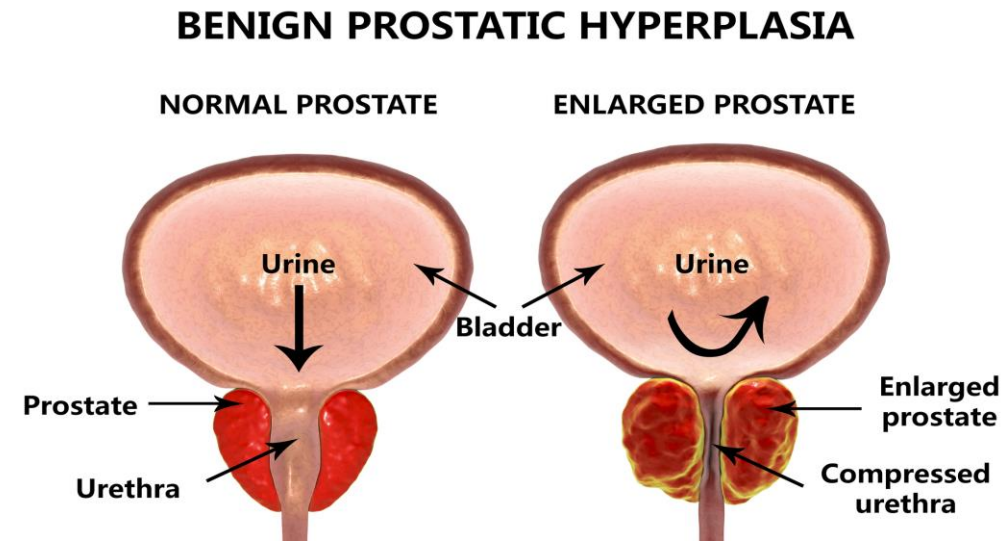
- 70%–80% arise in peripheral zones.
- Often detected by rectal examination

Hyperplastic lesions



1. Benign Prostatic Hyperplasia

- An extremely common cause of prostatic enlargement by the age of 40 years.
- An important cause of urinary obstruction.
- Although the cause of BPH is incompletely understood, excessive androgen-dependent growth of stromal & glandular elements has a central role.
- Does not occur in males castrated before the onset of puberty.



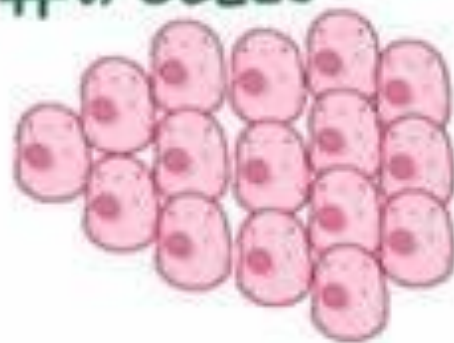BENIGN PROSTATIC HYPERPLASIA (BPH)

CELLS AREN'T
MALIGNANT

PROSTATE
GLAND



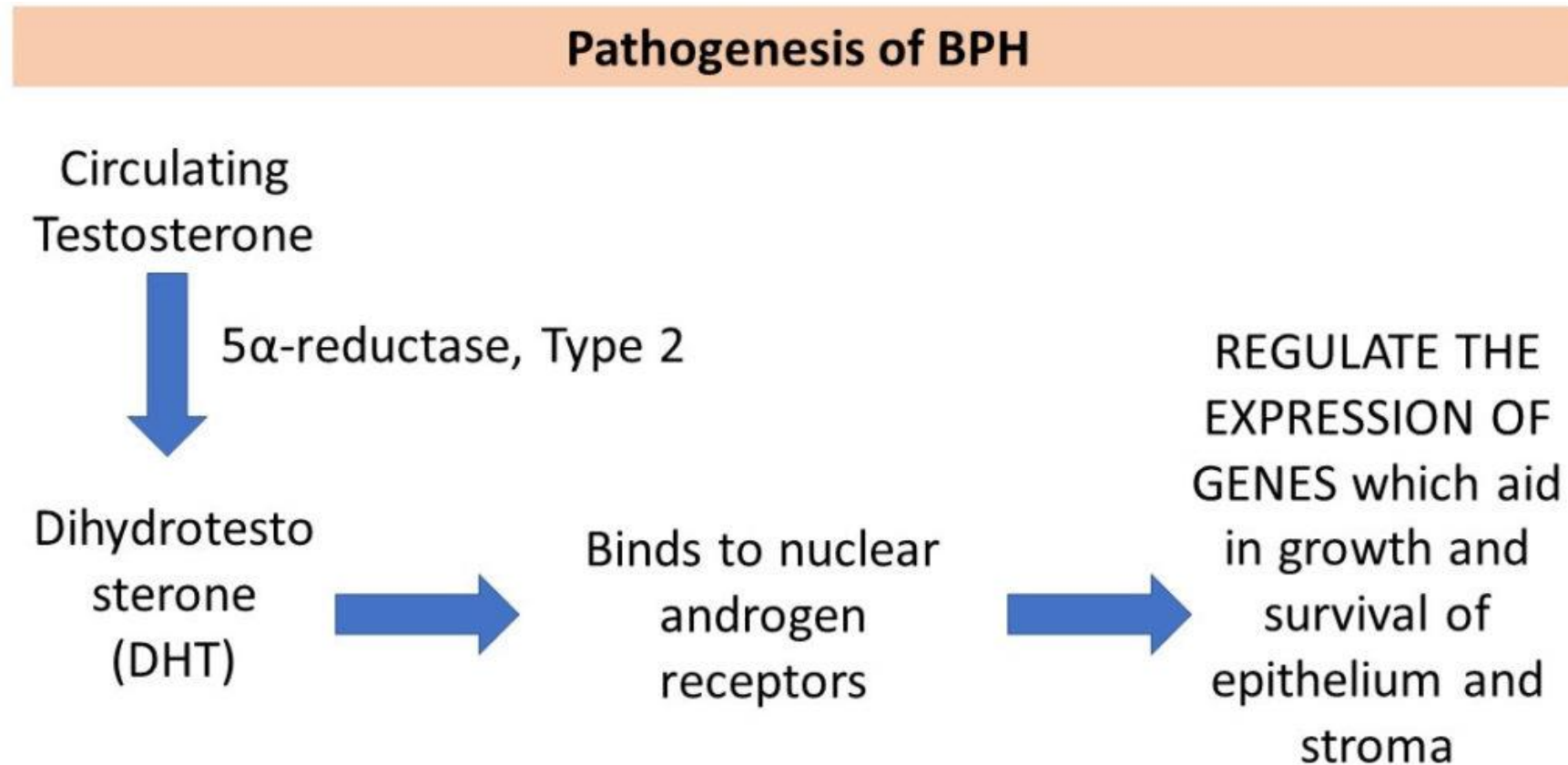
↑ # of CELLS



- * COMMON in MEN OVER 50
- * OFTEN CONSIDERED a NORMAL PART of AGING

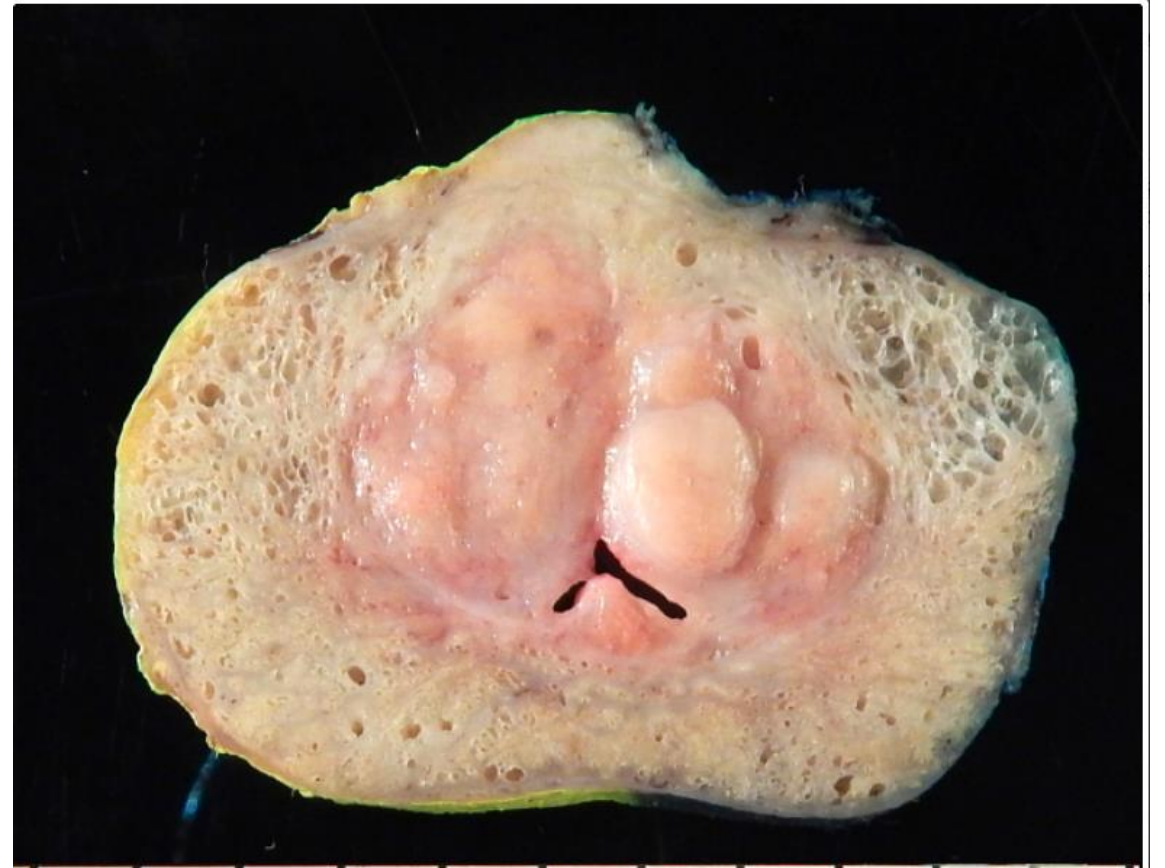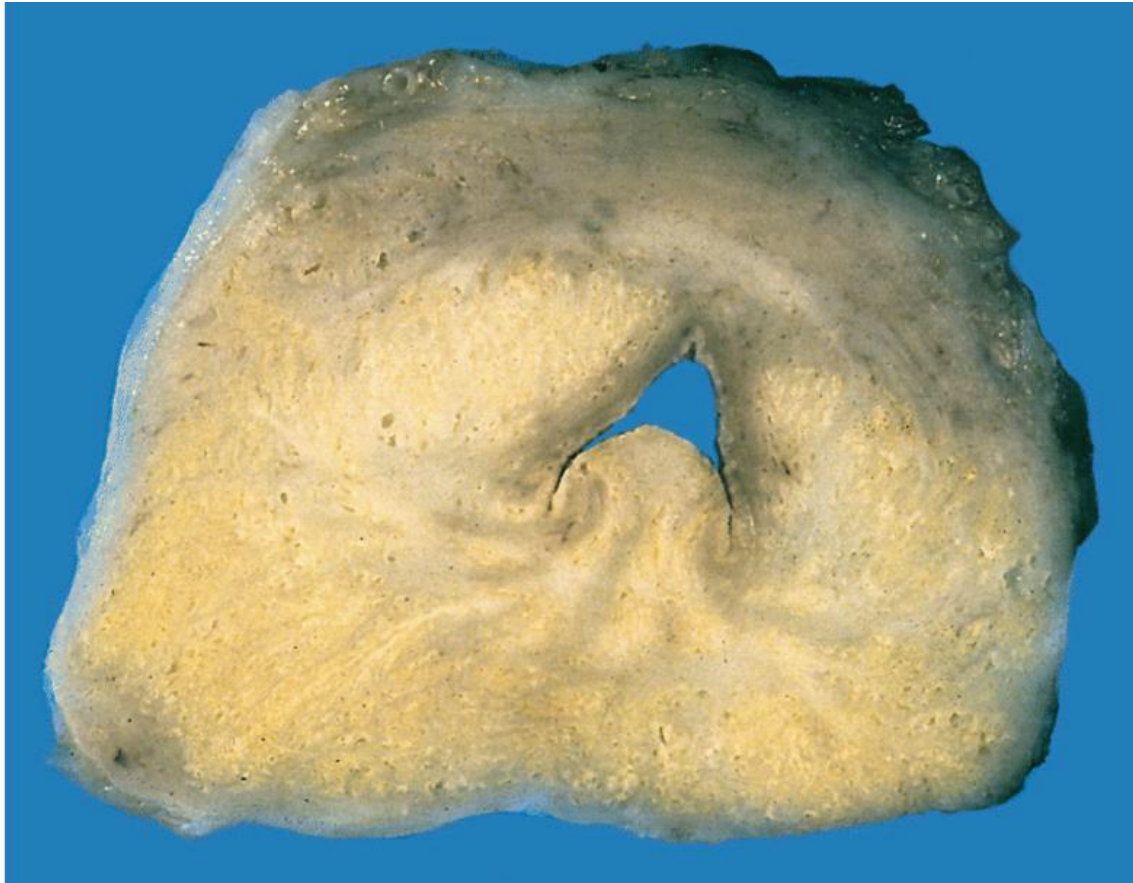Pathogenesis

- DHT(Dihydrotestosterone)-induced growth factors act by increasing the proliferation of stromal cells & decreasing the death of epithelial cells.



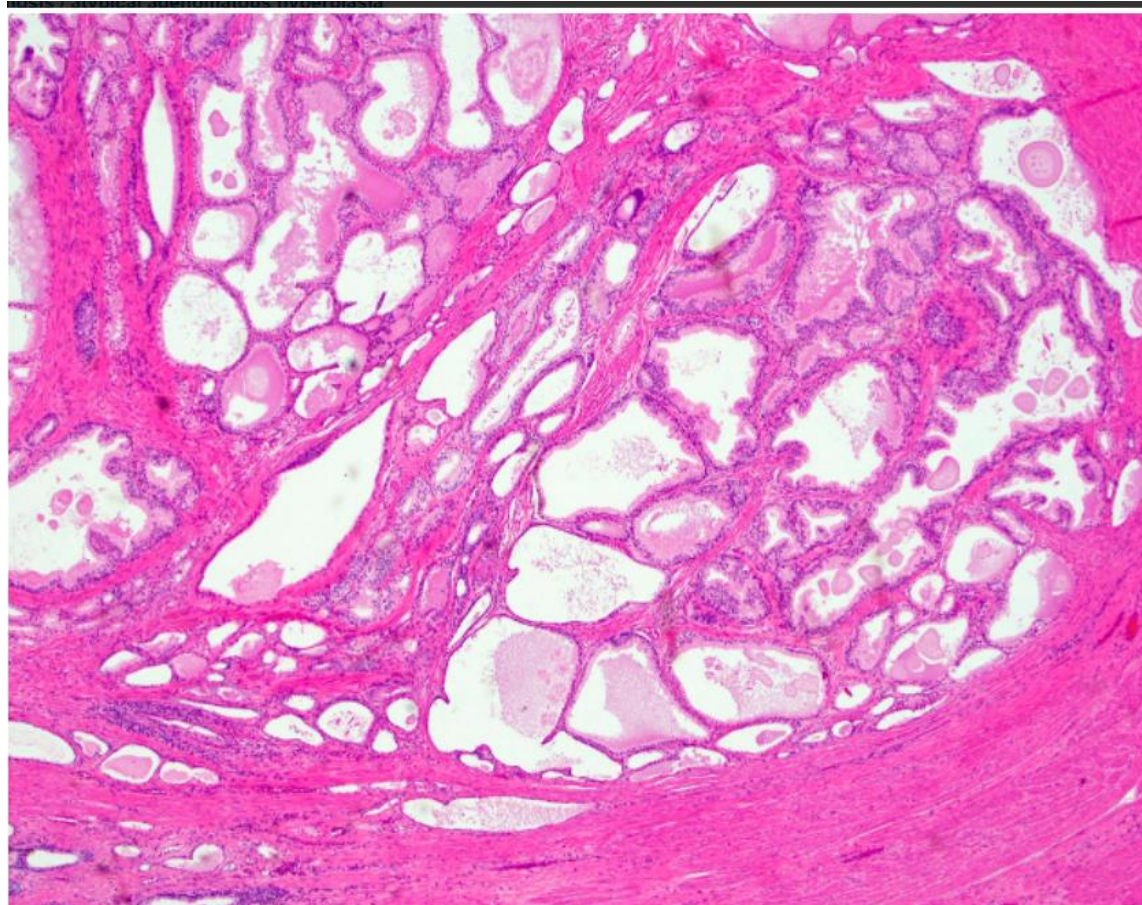
Macroscopic

Benign prostatic hyperplasia nodules
around the urethra bulge above the cut surface in a cross section of the prostate gland.



Microscopic

- Epithelial hyperplasia is characterized by nodular lesions composed of variably sized glandular structures lined by basal and secretory cells



Clinical Features

❖ Symptoms:
(occur in only 10% of cases) and include:

- urgency,
- frequency,
- Nocturia (with increased risk of urinary tract infections).

• Treatment:

❖ Initial pharmacologic; agents inhibit formation of DHT.

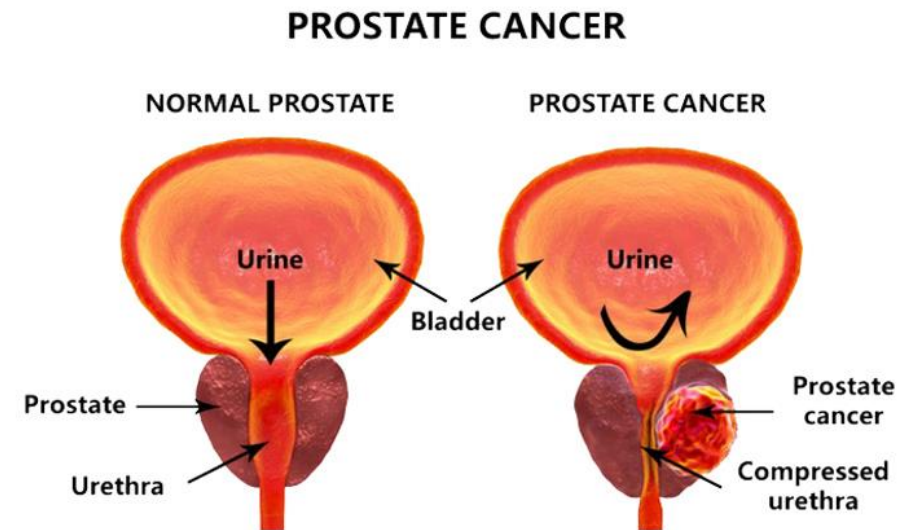
❖ Surgical treatment for :

- severely symptomatic cases.
- resistant to medical Rx(Transurethral resection of the prostate (TURP)).



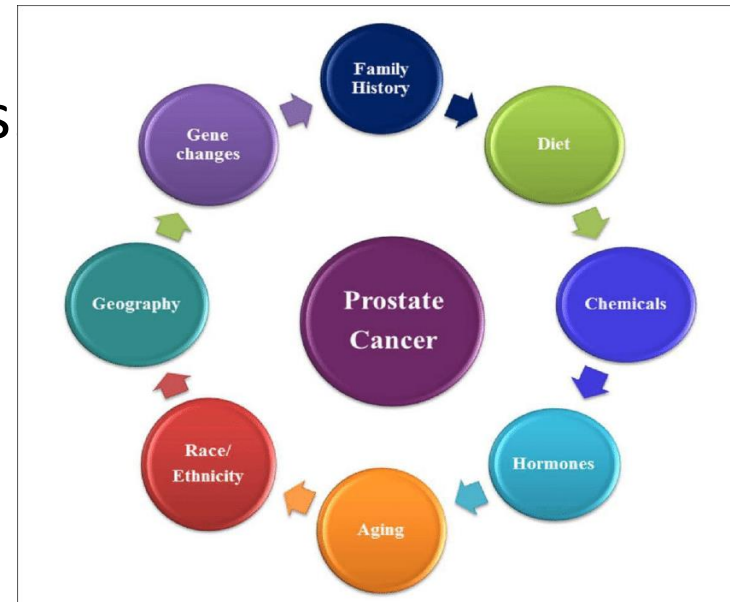
Carcinoma of the Prostate

- Adenocarcinoma of prostate is the most common form of cancer in men.
- Age: older than 50 years.
- Significant drop in prostate cancer mortality → increase detection of disease through screening.



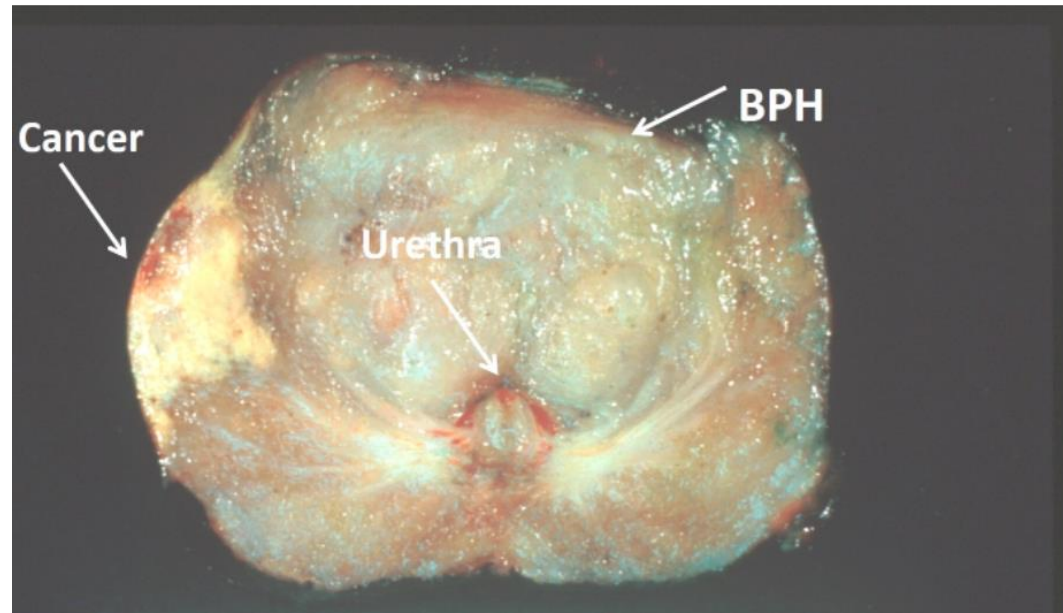
❑ Pathogenesis

- Androgens: are of central importance; evident by
- Cancer of the prostate doesn't develop in males castrated before puberty.
- Cancers often regress for a time in response to surgical or chemical castration.
- Heredity.
- Environment:
- geographical variations that may be due to dietary variations
- Acquired somatic mutations:
- + TMPRSS2-ETS fusion genes are found in ~ 50% of cases.



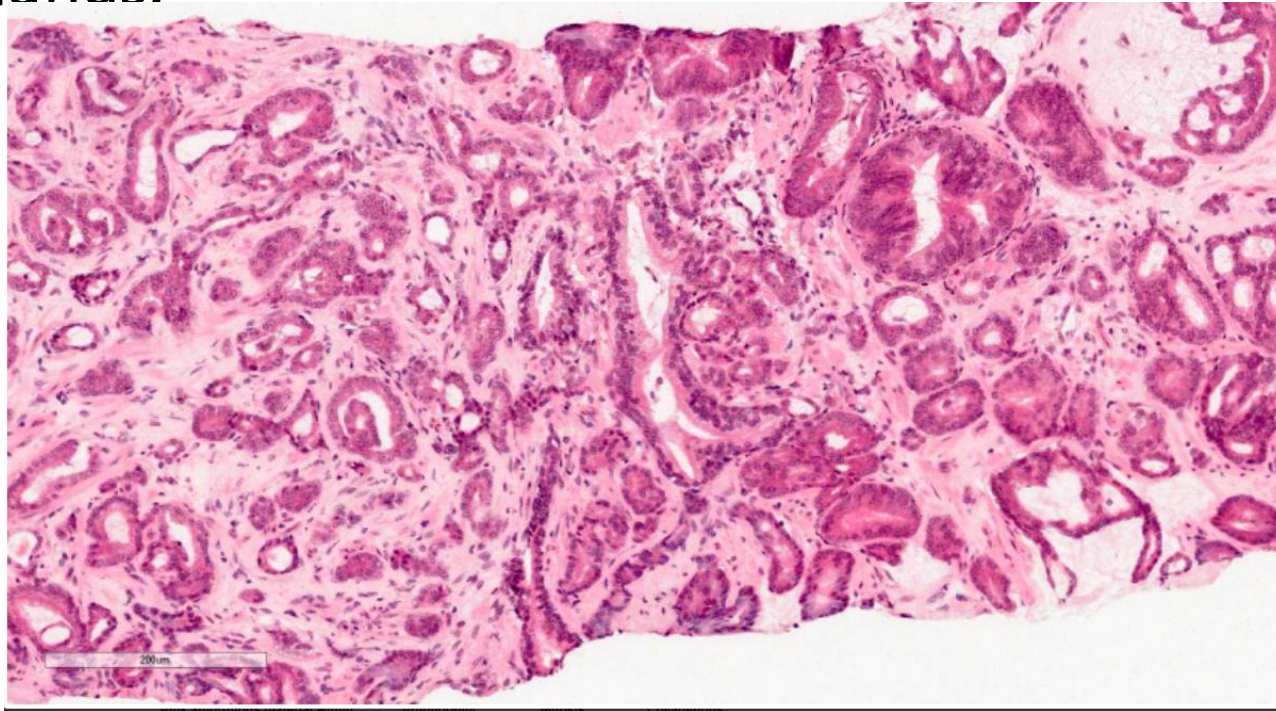
Morphology

- GROSS: firm, gray-white lesions with ill-defined margins.
- Most tumors are multifocal.
- 75 - 80% are posterior / posterolateral peripheral zone



Microscopically

- well-defined glands, typically smaller than benign glands and are lined by a single uniform layer of cuboidal epithelium, lacking basal cell layer seen in benign glands.

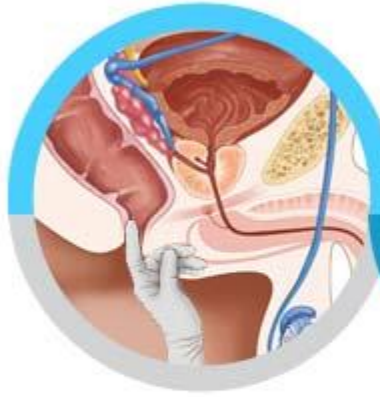

clinical features

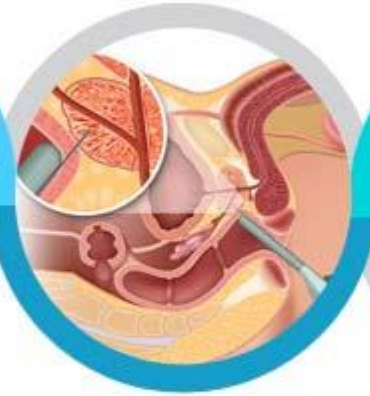- Generally asymptomatic unless locally advanced or metastatic
- Often discovered following investigation of nonspecific lower urinary tract symptoms.
- Serum screening tests: elevated prostate-specific antigen (PSA) level.
- Digital rectal examination (DRE): prostate may feel normal or may be enlarged / asymmetrical .
- Bone metastases, particularly to the axial skeleton, are frequent late in the disease and typically cause osteoblastic (bone-producing) lesions.

Diagnosis

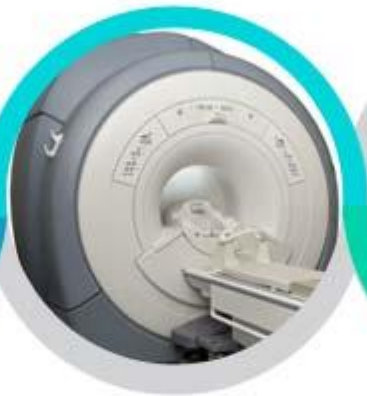Diagnosis for Prostate Cancer



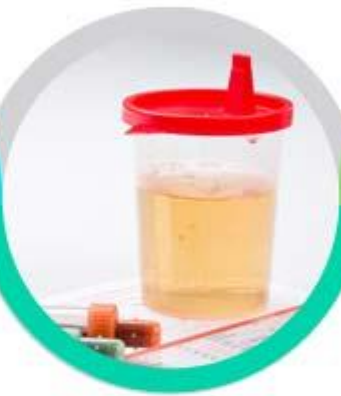Digital
rectal
examination



Trans
rectal
ultrasound
(TRUS)



MRI
Fusion
biopsy



PCA3
(Prostate
CAnceR
gene 3)

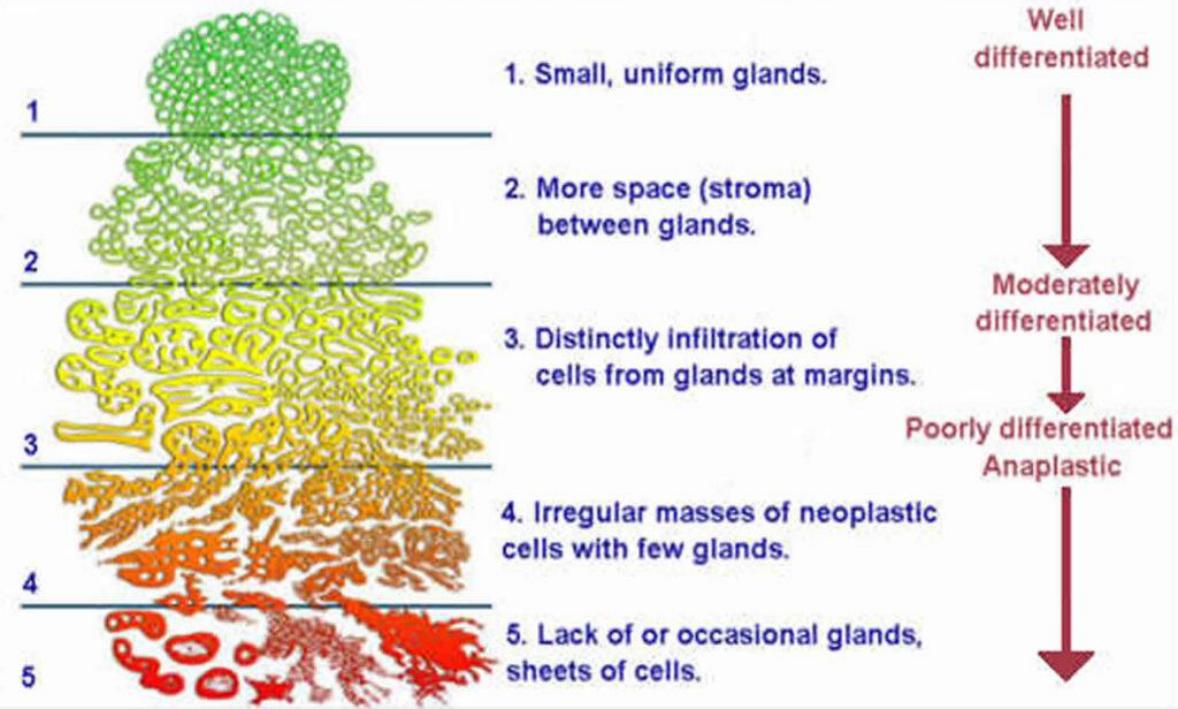


Prostate-specific
antigen
blood test (PSA)

Treatment.

- The most common treatments for clinically localized prostate cancer are radical prostatectomy and radiotherapy.
- The prognosis after radical prostatectomy is based on:
 - the pathologic stage.
 - the margins of the resected specimens are free of tumor or not.
 - Gleason grade (grading system on the basis of glandular patterns of differentiation)

Gleason's Pattern Scale



PROSTATE CANCER STAGES

- | | |
|------------------|---|
| Stage I | - the cancer is small and only in the prostate |
| Stage II | - the cancer is larger and may be in both lobes of the prostate but is still confined to the prostate |
| Stage III | - the cancer has spread beyond the prostate to close by lymph glands or seminal vesicles |
| Stage IV | - the cancer has spread to other organs such as the bone and is referred to as metastatic cancer. If prostate cancer spreads, or metastasizes, to the bone, you have prostate cancer cells in the bone, not bone cancer |

For a detailed description of each stage, see the information at the bottom of the page.
Detailed Staging, adapted from www.cancer.gov.

THANK
you