



GIT – Anatomy

Archive

Lecture(7)

peritoneum

Done by :

Aya Ayman

Anatomy-Lecture(7)

1. The mesentery that divides the infra-colic compartment into right and left:

The mesentery of the small intestine

2. Behind the right lobe of the liver and in front of the right kidney is the?

- A. Right infracolic space
- B. Morison Pouch
- C. Right anterior subphrenic space
- D. Left anterior subphrenic space
- E. Lesser sac

ANSWER: B

مهم الدكتور حكاية بالاب وركز عليه 😊

3. In an open surgery of the abdomen, the doctor was dealing with stomach and he pass his finger behind it by getting inside a peritoneal opening. Considering the entrance to the space posterior to stomach, what is the structure posterior to the doctor's finger within this opening (entrance)?

- A. Duodenum
- B. Portal artery and vein
- C. Caudate process of caudate lobe
- D. Inferior vena cava
- E. Head of pancreas

answer : d

Anatomy-Lecture(7)

4. A surgeon performed an operation and put his finger in epiloic foremen, the posterior relation is:

- a. First part of duodenum
- b. inferior vena cava
- c. hepatic artery
- d. portal vein

Answer: b

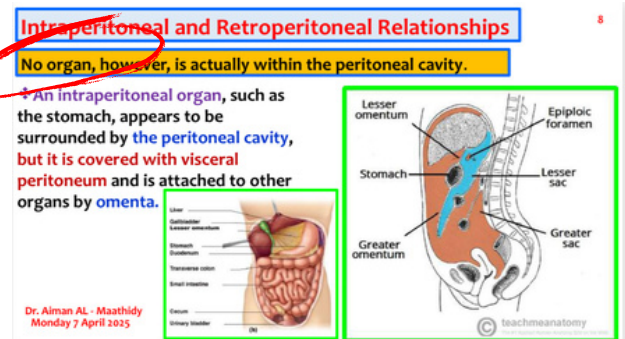
انذكر مرتين ارشيف وبرضو الدكتور ركز وذكرها بأكثر من محاضرة

5. Which one is false : Which one is false:

- a. Some organs within peritoneal cavity
- b. The peritoneum is a thin serous membrane
- c. The peritoneal cavity is the largest cavity in the body
- d. the peritoneal fluid, which lubricates the surfaces of the peritoneum and allows free movement between the viscera.

Answer: a

هاد حرفي من السلايد



Anatomy-Lecture(7)

6. One of the following is correct regarding the relations of the lesser sac :

- A- Small and lies behind the duodenum.
- B- It's left margin formed by the splenicorrenal ligament.
- C- It extends downward as far as diaphragm.
- D- It's opening bounded inferiorly by inferior vena cava.
- E. Separates the stomach from anterior border of the pancreas.

Answer: E

هذا السؤال وارد فيه الخيار الاول لأنه فعلاً وراء اول جزء منه بس الاول مش الـ duodenum كامل وهذا اللي رجح الاختيار الاخير