


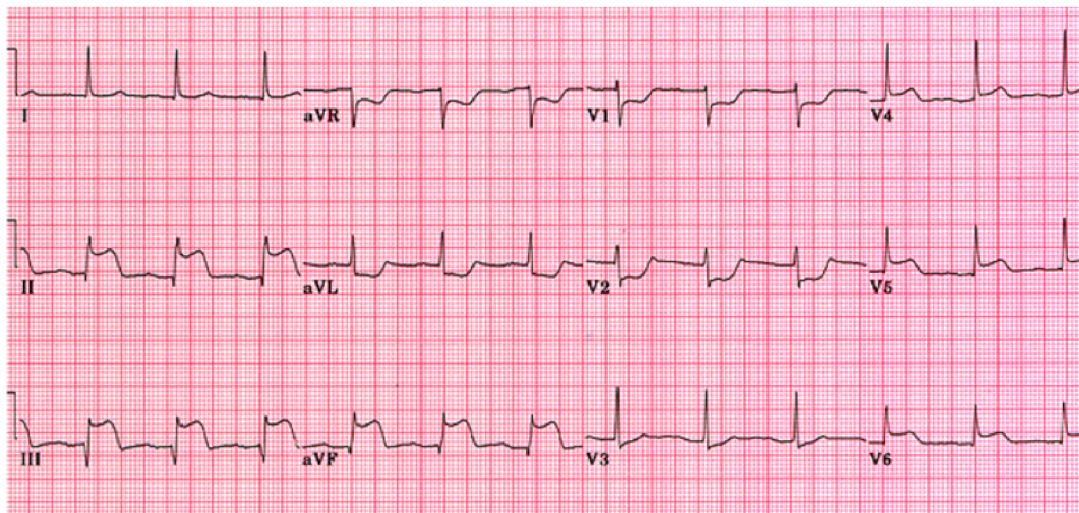
Wateen 2nd semester mini - OSCE

**Jood Allan
Hala Mahasneh
Ayyad Qawaba'a**



من استصعب عليه أمر " اللهم لا سهل إلا ما جعلته سهلا وأنت تجعل الحزن إذا شئت سهلا "

“رب اشرح لي صدري ويسّر لي أمري وألهمني الصّواب”



1- three findings from ECG ?

ST elevation in leads (I , II , aVF)

ST depression in other leads

T wave inversion

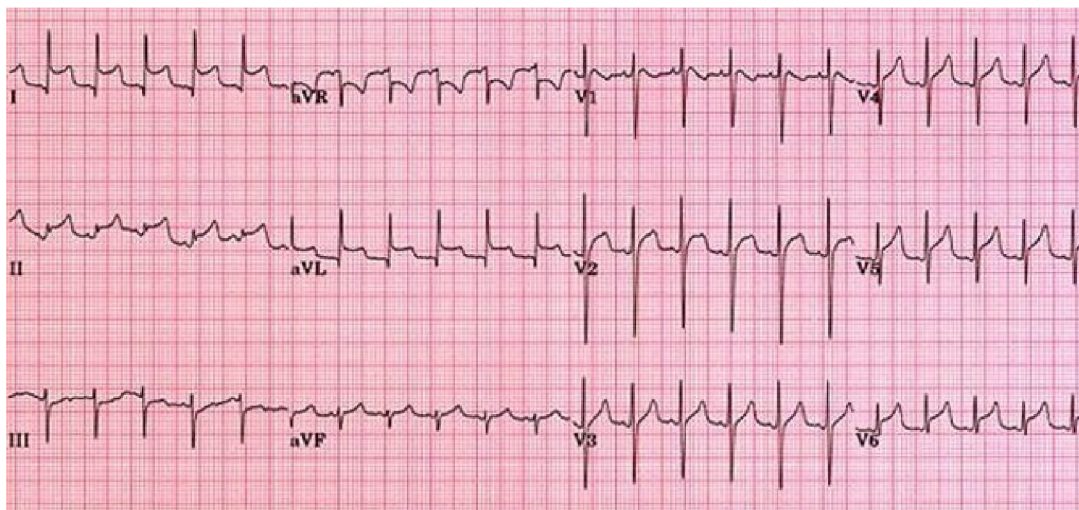
2- diagnosis ? inferior MI

3- tow investigations ?

echo , cardiac enzymes

4- for line treatments ?

thromvolytic , PCI , oxygen , Aspirin ..



1- two findings from ECG ?

PR interval depression

ST elevation in other leads

2- diagnosis ?

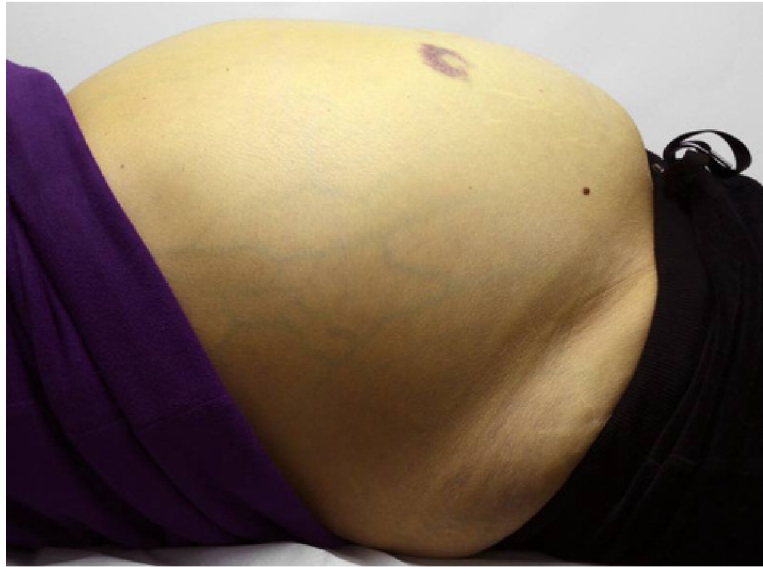acute Pericarditis

3- 4 lines if treatment ?

anti-inflammatory medication (colchicine), NSAIDs , O2

صورتين ال ECG اجو من هذا الموقع ::

<https://elentra.healthsci.queensu.ca/assets/modules/ts-ecg/pericarditis.html>



1- what is the most likely Dx for (fresh hemat emisis)is ?

Esophageal varices

2-The likely cause of this Presentation is ?

liver cirrhosis (portal HTN)

4-emergency mangment ¿

iv fluid .. terlipressine

3-other 3 investigations ?

LFT(albumin..bilirubin)..coagulatinbprofile..upper endoscopy..parietocentesis

4-manegment to prevent recurrent ?

banding ?

44 year old patient with dyspnea , bloody cough , weight loss...

1- what is the diagnosis ? **TB**

2- 2 differential diagnosis ?

Lung cancer

Lung abscess

3- Specific test for diagnosis ?

PPD?

و فيه طلاب جاوبوها

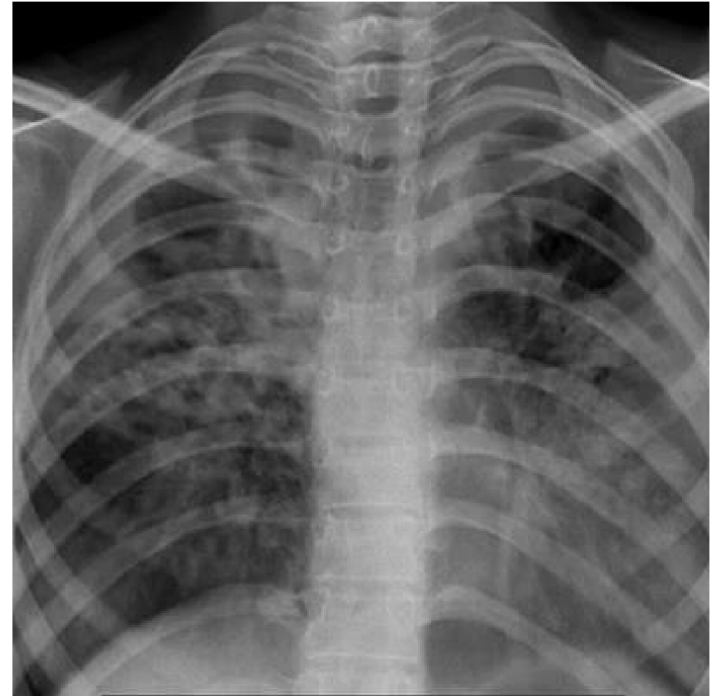culture

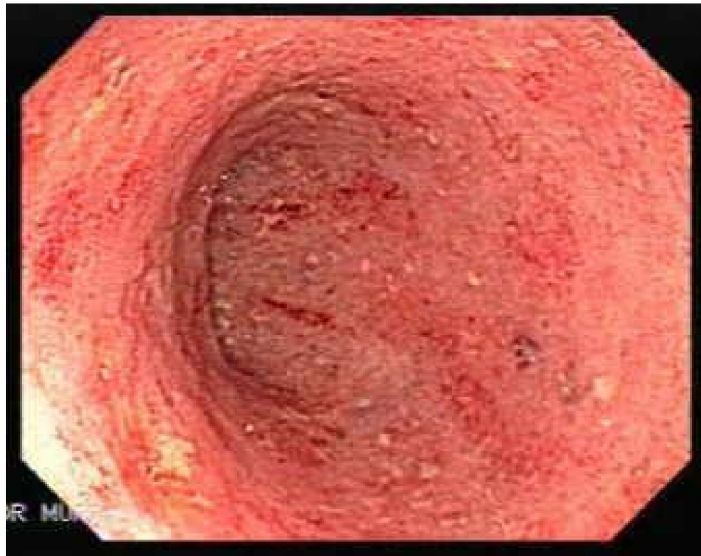
4- 2 regiment of treatment ?

6 months regimen :

- Initiation phase: Rifampicin + INH +
pyrazinamide + ethambutol. → for 2 months.

- Continuation phase :Rif + INH for 4 months





44 year old patient with dyspnea , bloody cough , weight loss...

1- diagnosis ? **Ulcerative colitis**

2- 2 skin manifestation ?

pyoderma gangrenosum , erythema nodosum

3- 2 investigations ?

colonoscopy , PANCA

4- treatment ?

Sulfasalazine , Oral glucocorticoids , TNF inhibitors (infliximab, adalimumab)

1- diagnosis?

cushing disease

2- what you see in lab test ?

BMP : hypernatremia,

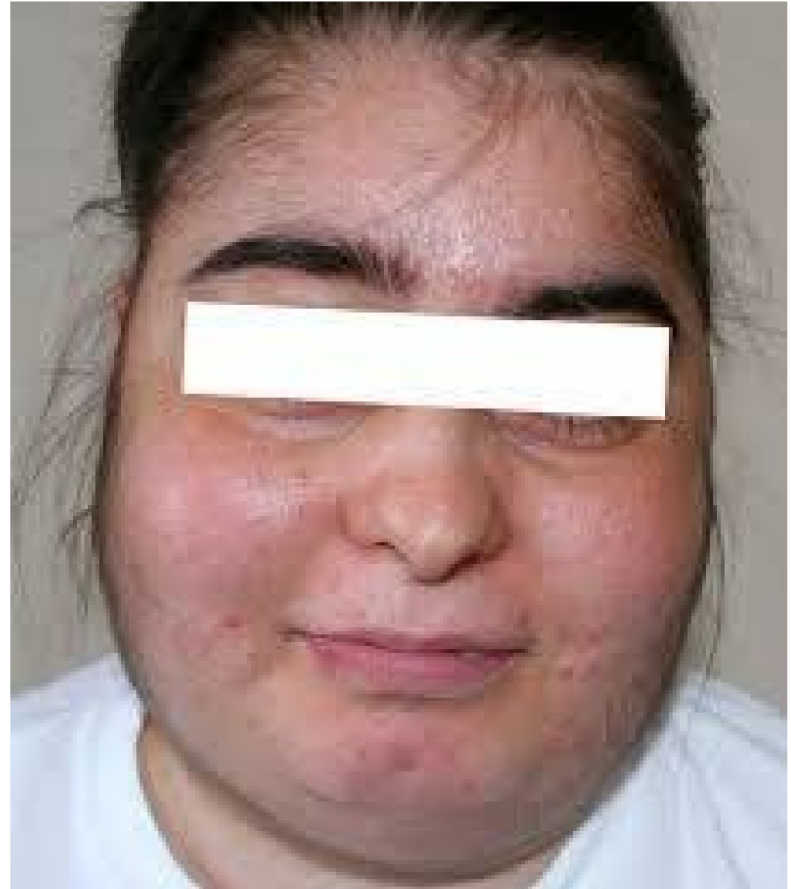hypokalemia

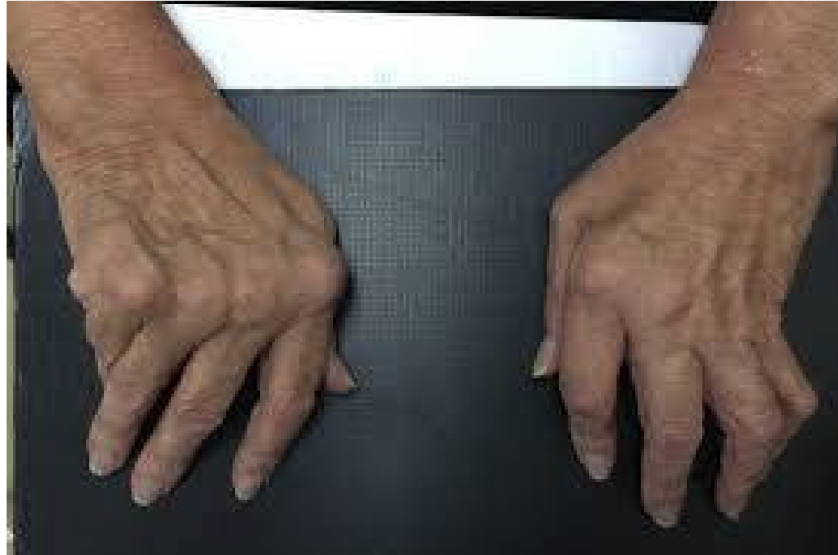Hyperlipidemia

Cbc: lymphocytopenia, neutrophilia

3- how to confirm diagnosis ?

24 hour collection urin





1- diagnosis?

RA

2- three findings ?

nodules , ulnar dev. , swan neck deformity

3- two investigation ?

anti CCP , RF , x-ray

4- two treatment ?

Methotrexate , corticosteroids

patient with fatigue , contraption...

1- diagnosis ?

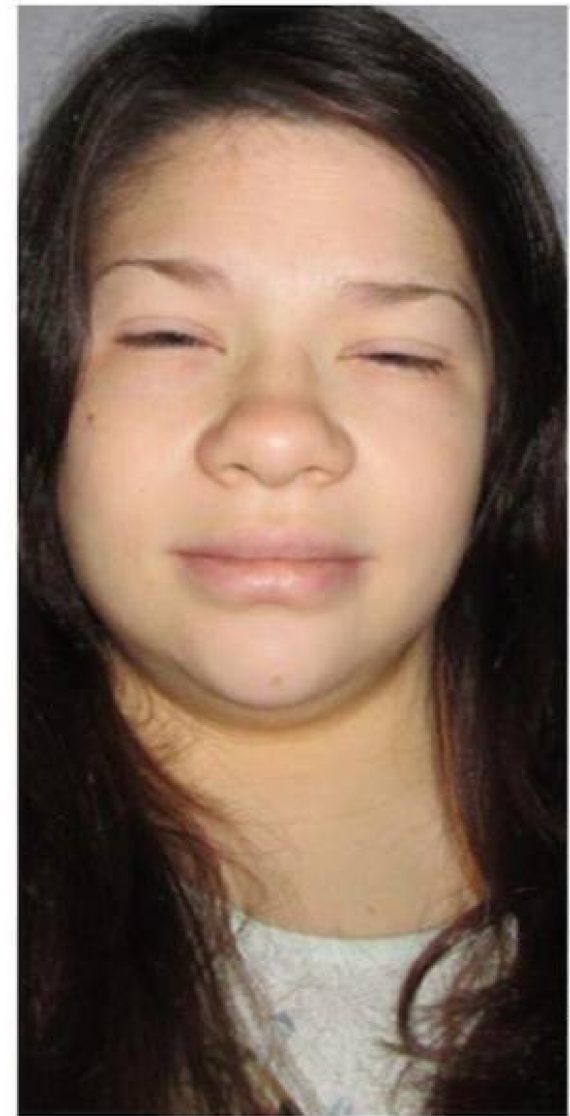hypothyroidism

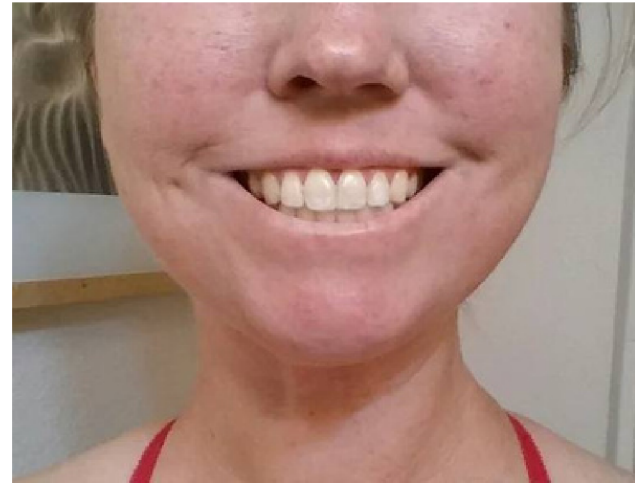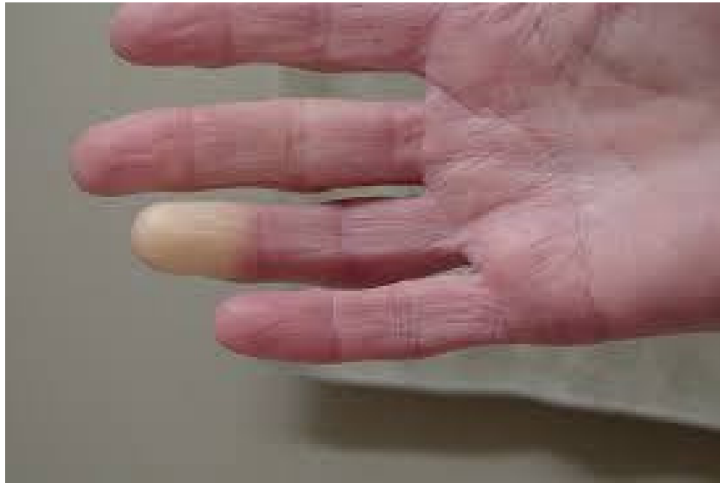2- investigations ?

TSH , T3 , T4

3- complication ?

bradycardia , hypotension





1- diagnosis ?

scleroderma

2- findings in the pictures ?

(Microstomia, raynaud)

3- other 3 findings ?

mask face ,...

4- treatment ?

Raynoud: CCB

Kidney and HTN: ACEI

K=6.6
Na=132
Cl=100
HCO₃=20
Urea=27
Creatinine=4.2

Patient with HTN and DM , come with abdominal pain and diarrhea .
He diagnosed with interogastritis , according to following table ;

1- diagnosis ?

Acute kidney injury

2- what emergent finding ?

hyperkalemia

3- treatments ?

Calcium gluconate

insulin with glucose

Diuretics

dialysis

Diagnosis?

Macrocytic anemia

1- lab finding?

cbc..blood.film..

b12/intrinsic factor /folate

2- 2 underlying causes ?

B12 def..folate def ?

or

malabsorption , crohn's disease ?

3- 2 investigations

Peripheral smear , intrinsic factor

Hb→ low

Hct→ low

MCV→109

MCHC→low

*The values were written with the normal range

55 y Smoking patient for long time with chronic productive cough , before 3days come to the ER with fever and yellowish sputum SOB and cough..

1. describe pft

obstructive lung disease

2- diagnosis ? اعتمادا على الهستوري لانه ما كان في نسبة ال COPD
change for FEV1 , FEV1/FVC<70% , low FVC , low FEV1

3- what is your further investigations ?

Sputem culture

chest x.ray

abg

4- 3 line treatments ?

laba,saba,steroid

Spirometry			
	Prod	Pre	%Pred PRE
FVC L	3.88	5.08	131.0
FEV1 L	3.09	3.89	126.0
FEV1/FVC %	58	50	96.9

ممکن نضيف antibiotic كونه اخر برزنتيشن مبین انفسیکشن



لأجل هذه الليالي الكشف هيبقى غالي