



الطبيب والجراحة



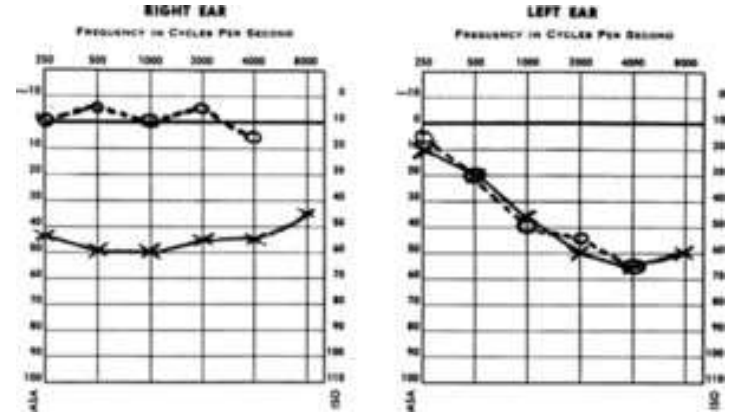
لجنته

# Ent archive

By :  
malak hamasha  
Rand smadi  
Sara almasri  
Walid ayoub

The exam was two station :  
First one contain 5 pic and write the answer

1. What we should exclude ?  
**vestibular schwannoma acoustic neuroma**
2. Investigation ?  
**cerebellopontine angle CT or MRI**



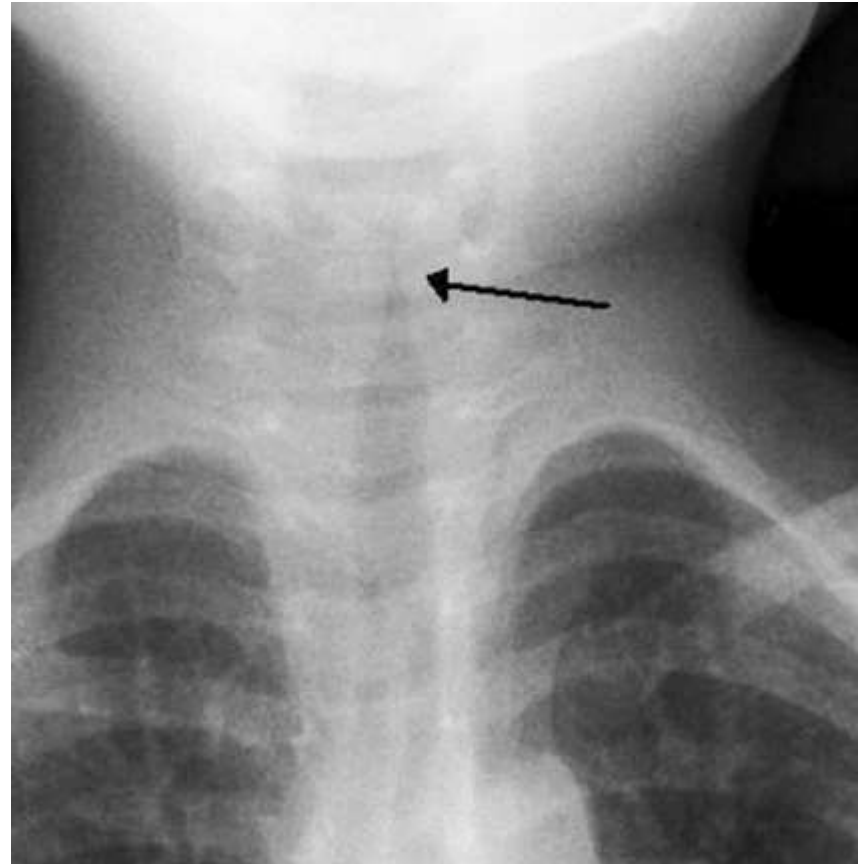
مش نفس الصورة بس الفكرة انو وحدة  
unilateral  
profound sensorineural والتانية  
hearing loss

3. Name of this sign ?

steeple sign

4. Diagnosis ?

croup

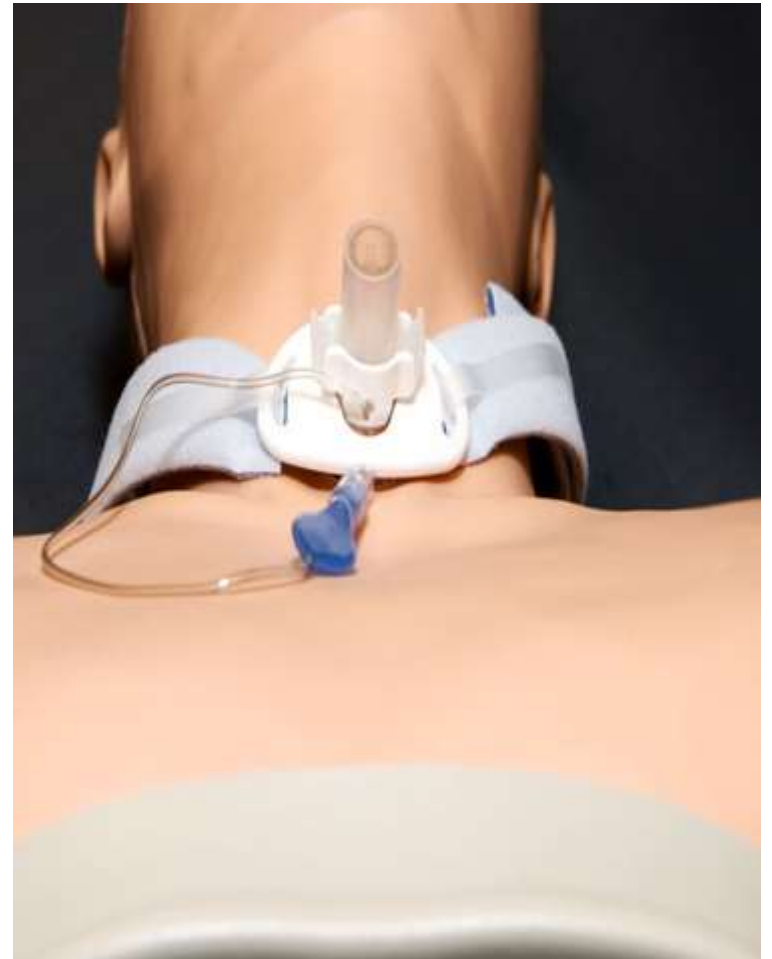

5. most common indication?

**prolonged endotracheal intubation**

6. most common complication?

**bleeding**

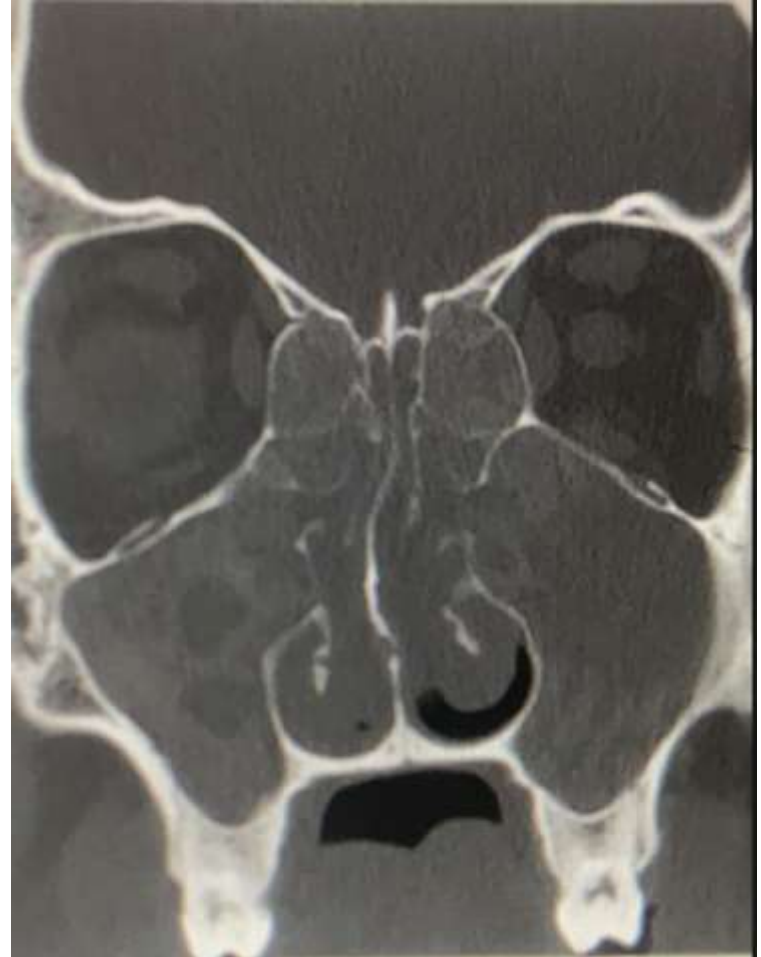

7. What is the name of this study?

Coronal paranasal CT scan

8. Diagnosis ?

Chronic sinusitis



بدون صورة السؤال

3 year old child came to the ER with stridor, drooling, and temp 38.7C

9. Most common diagnosis ?

Peri tonsillar abscess **علي الاغلب** or acute epiglottitis

10. Investigation to confirm ?

CT or lateral x ray

Second station was 5 pics  
and each pic contain 4 mcq  
question :

1. Most predisposing factor ?

**yelling**

2. Management ?

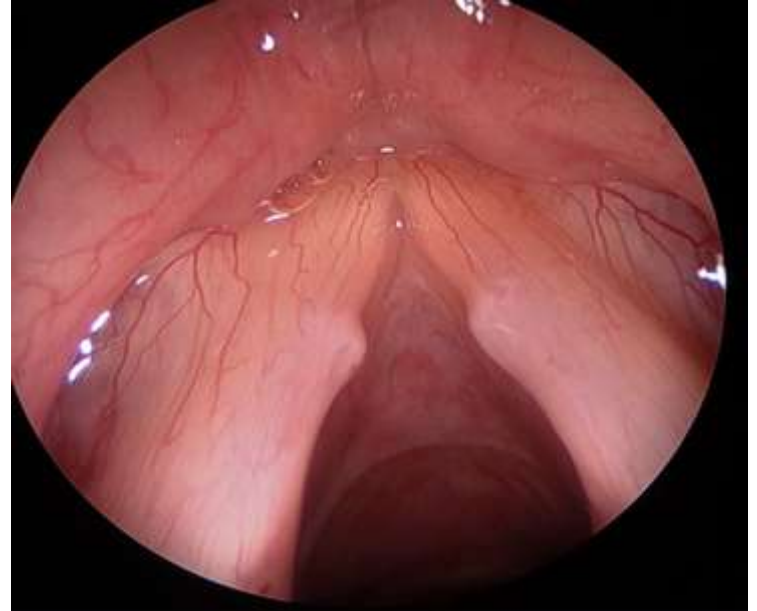
**Voice rehabilitation**

3. Location ?

**Bilateral Anterior and middle 2/3**

4. Most common symptom ?

**Horsens of voice**





1. Correct statement ?

Bacterial is most common causes

2. Rinne test ?

Right negative

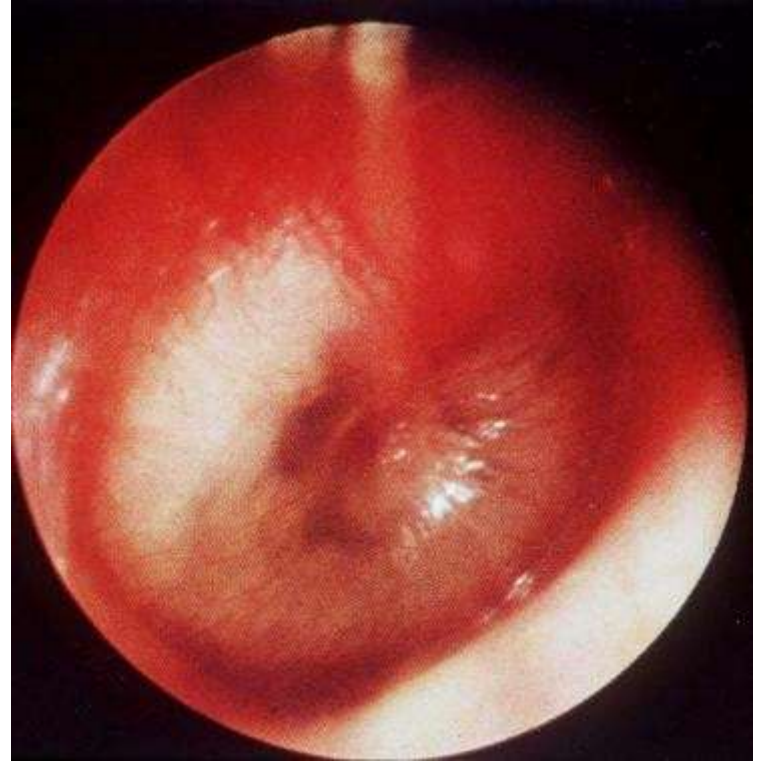3. All of this management except ?

Watchful waiting / adenoidectomy مش

متأكدة أي وحدة

4. Correct answer ?

Right ear bulging and congestion



1. Type of hearing loss ?

**conductive hearing loss**

2. Tympanometry ?

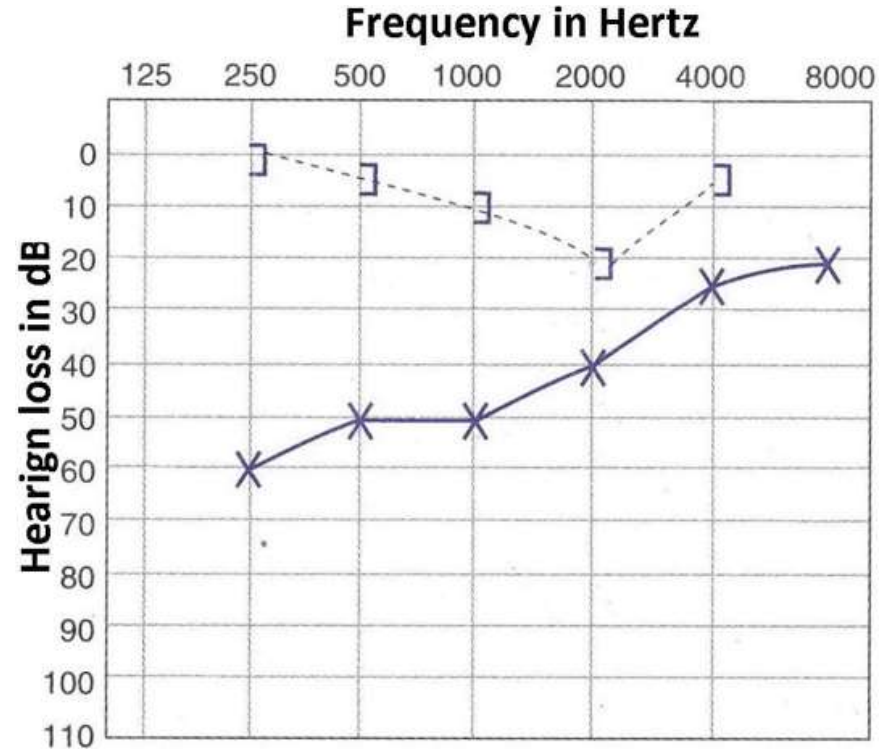
**Type As**

3. All management except ?

**Ossicular reconstruction**

4. The history of this patient ?

- a. 70 years old and complain of retired health
- b. 30 female and complain of vertigo and tinnitus
- c. 27 years dentist and work with loud machine
- d. **30 years female has baby and his cousin complain of same case**



1. Nasolacrimal duct drain in ?

A

2. Wrong answer ?

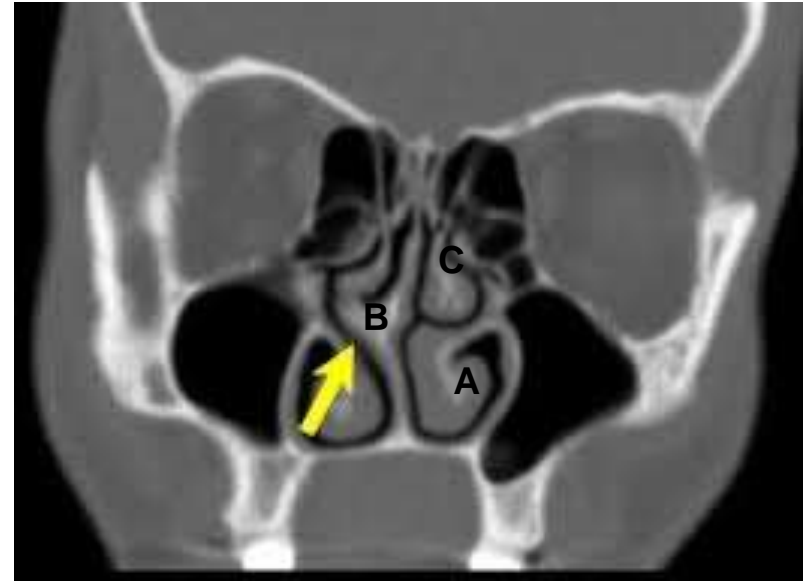
B lead to frontal sinuses

3. Correct answer ?

This patient have anatomical deformities that will cause chronic sinusitis

4. All are symptom of rhinitis except ?

Lacrimation/ nasal pain مش متأكدة



1. All of the following are dx except?

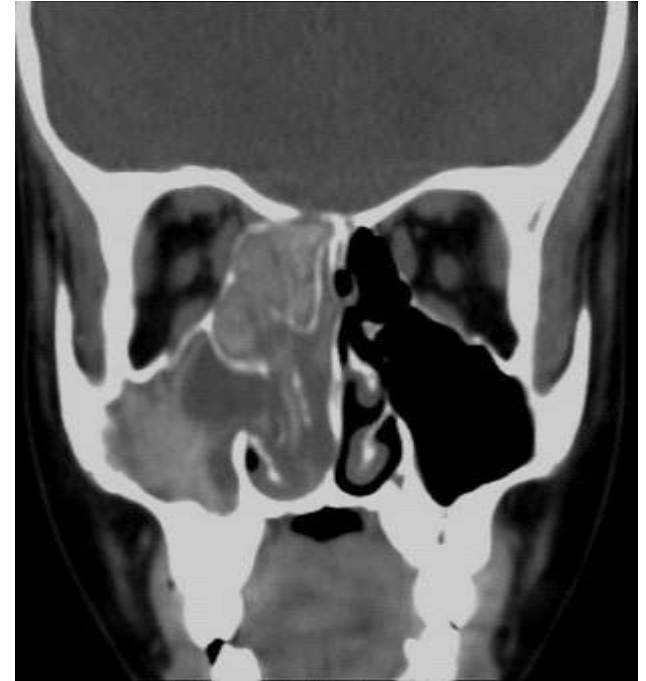**Nasothmoidal encephalocele**

2. Management ?

**Functional endoscopic sinus surgery**

3. Which is true regarding this condition?

**Recurrence is exceptional**



# Mini OSCE

## الجروب الثاني صيفي

MCQ الامتحان كله

One way

مش متذكرين الخيارات كلها

الخيارات كانت تخربط كثير ف انتبهوا

الصور مش نفسهم ولكن شبههم

By إسلام صدقه

# Station 1

- Picture of paranasal CT for a 25 YO male :
- Q1 : what's true about the CT ?this view shows middle and inferior and middle conchae (مش متأكدين)
- Q2 : what's the treatment ?A.FEES B.steroid
- Q3 : all are ddx except? A. allergic fungal sinusitis B. Adult C. angiofibroma polyp d. في كمان بس مش متذكر
- Q4 : What's true about Treatment : A. Doesn't recur B. Recurrence according to pt health state C. Always recur
- Q5 : What's true about The lesion: A. presence of bone erosion B. Origin from maxillary sinus

## Station 2

- Picture of retracted tympanic membrane ( perforated كانت مبين انها )  
بعضه ف ما بنعرف شو الصح 😊
- Q1 :what's wrong about the pic ? The membrane is centrally perforated ?
- Q2 : what's the pointed structure ?A is the malleus
- Q3 : all cause this case except ?
- Q4 : weber and Rinne test ?
- Q5 : tympanometry ? Type B

# Station 3

Picture of semicircular canals (الصورة بس منظر محطوطة)

Q1. Pathophysiology of BPPV ?

Q2. What's the treatment?

Q3. Wrong about the vertigo ?

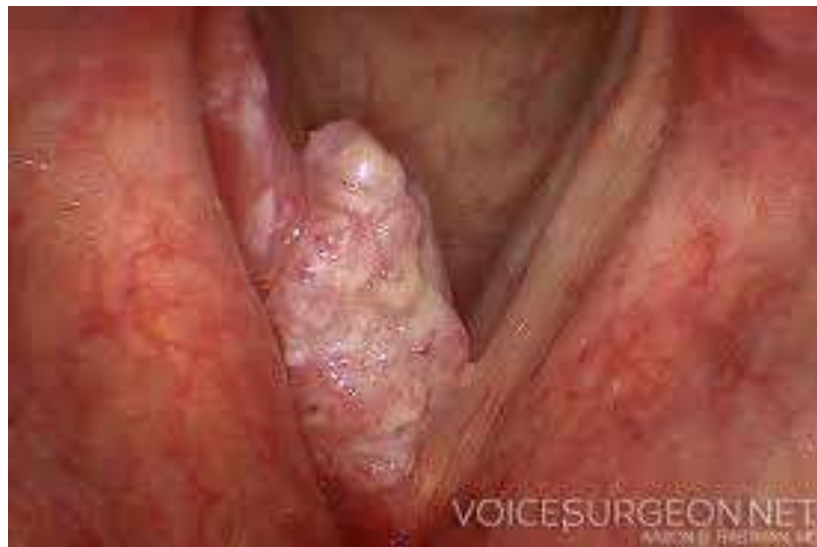Q4.



# Station 4

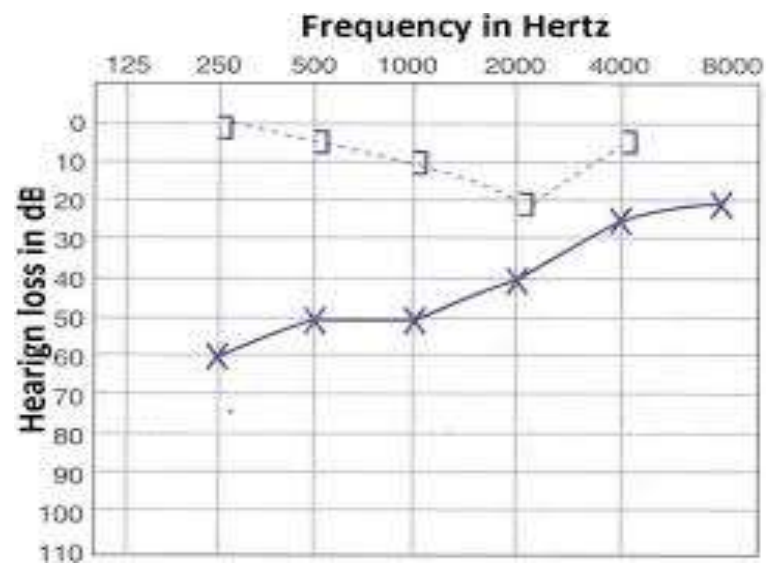
- Picture of CT

# Station 5



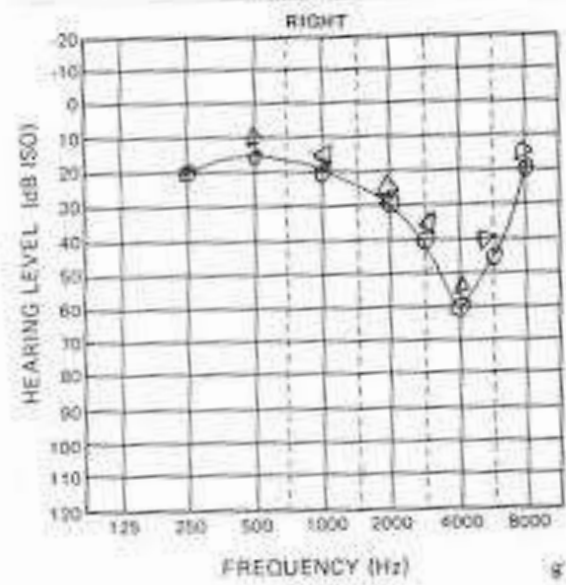
# Station 5

- Case of laryngeal CA
- Q1. Site of the lesion? A. Right vocal cord B. left vocal cord C. posterior commissure
- Q2. Staging ? A. T1a B. T1b C. T2 D. T3
- Q3 . What's the most important risk factor ? A. GERD B. Smoking C. Alcohol D. Radiation
- Q4. What's wrong about Treatment? A. Radiation B. Surgery C. Laser excision D. Surgery and post op Radiation



# Station 6

- Case of audiogram
- Q1. what's the dx
- Q2. What's the treatment
- Q3. Weber and rinne
- Q4. Tympanometry
-

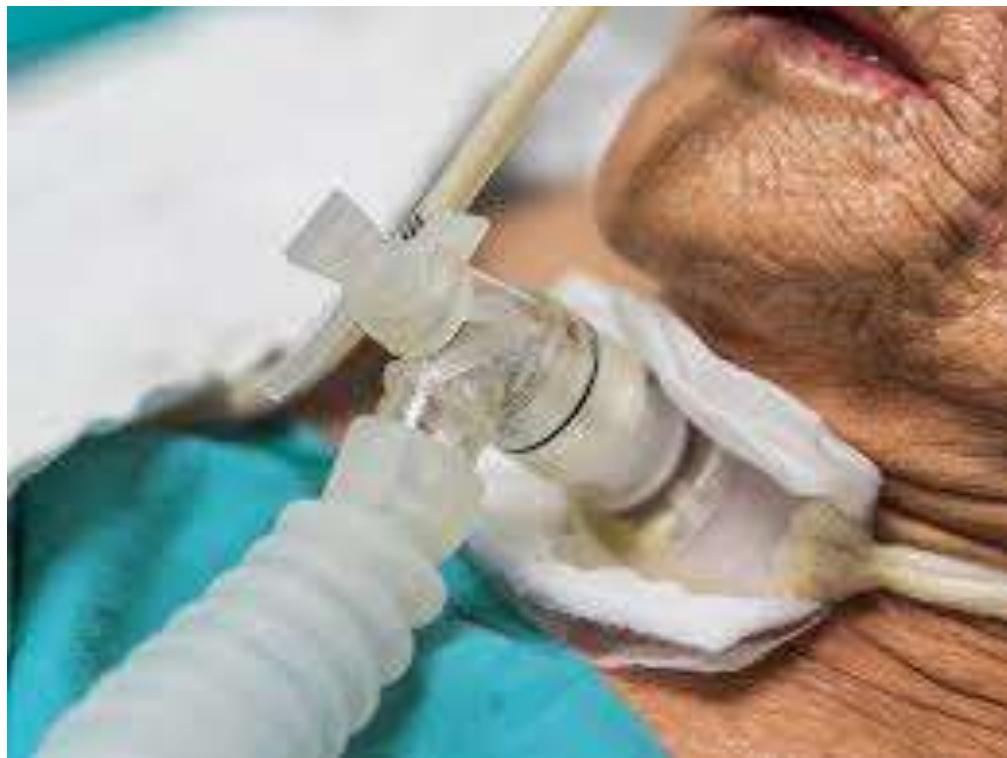

# Station 7

## Case of audiogram

- Q1. What's true ? A. Left B. Bilateral C. Right
- Q2. Rinne and weber ?
- Q3. Tympanometry ?
- Q4. Which scenario fits the case ?

## Station 8

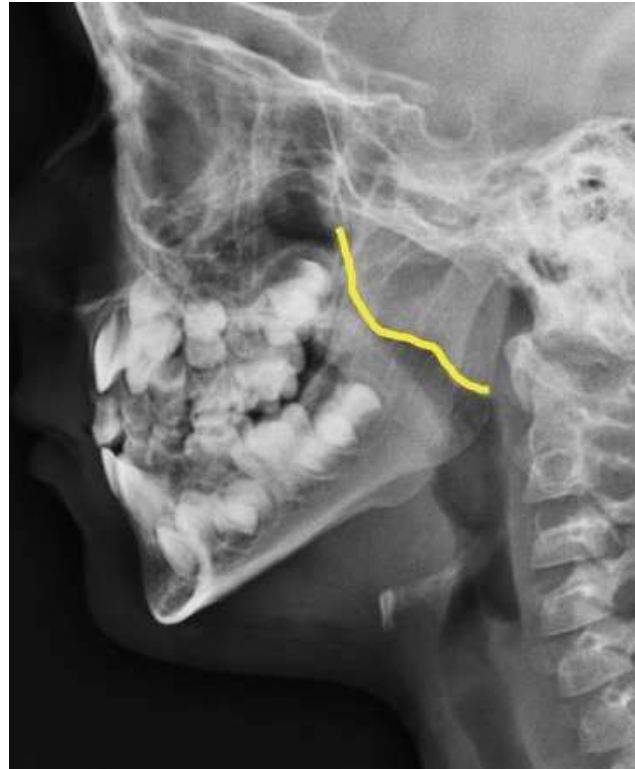



# Station 8

- Picture of Trachea
- Q1. What's the most common complication
- Q2. One of the following is indication for it ?
- Q3. What's correct about anatomy of trachea

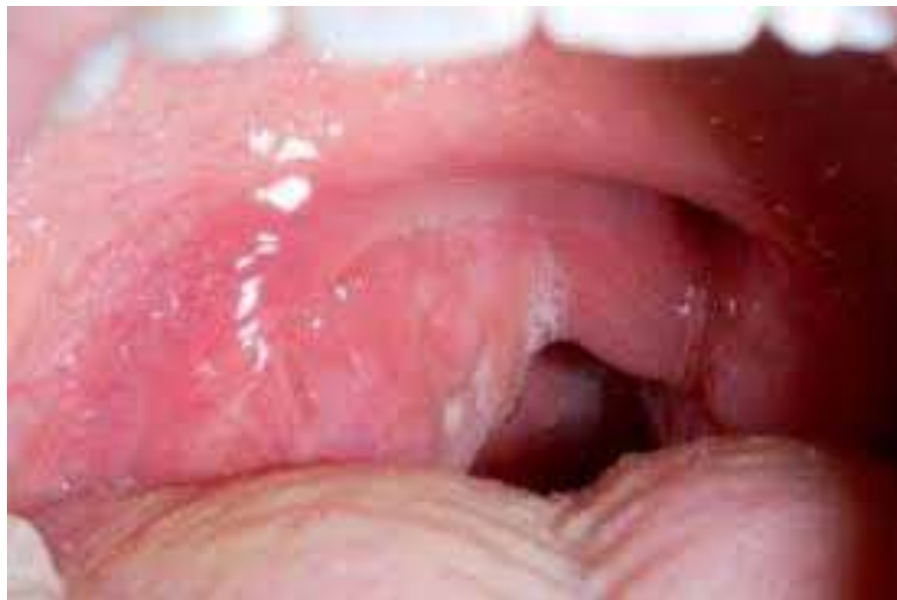# Station 9



# Station 9

- Picture of adenoid x ray
- Q1. What's the name of this study ?
- Q2. What's the absolute C/I ? A. Hemoglobin 10 B. Cleft palate C. Bleeding
- Q3. We can view the adenoid with All of these procedures except ? A. Rigid nasal endoscopy B. Fiberoptic C. Laryngeal mirror ?
- Q4.

# Station 10



# Station 10

- Picture of abscess
- Q1. Which one is not necessary as a first step ? A. CT B. Test for EBV C.
- Q2. What's the causative organism ?
- Q3. Anatomy of the abscess? A. Intracapsular B. Between the crypts C. Between the capsule and lateral border of superior constrictor muscle.

# ENT. Mini-osce

نبأ الحباشنة

تمارا المحادين

ساجدة المقابلة

1. The causative agent?

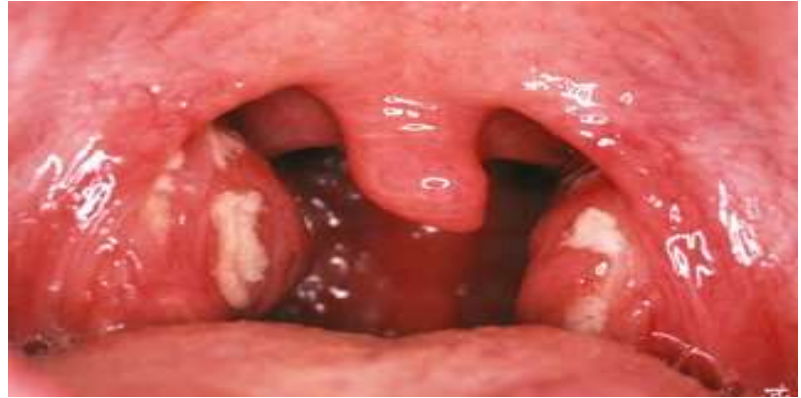group A beta hemolytic streptococcus

2. If the pt resistant to penicillin what the alternative drug?

Erythromycin

3. Most complication?

Quinsy.

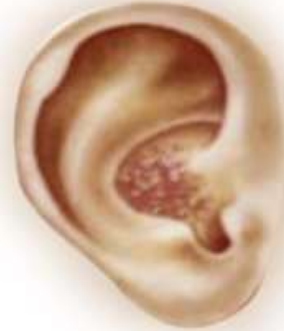

4. what is the Cause :

- A. Idopathic
- B. Autoimmune
- c. viral
- D. itragenic

5. All the following is symptom except:???

- A. Facial parasthesis
- B. otolagia
- c. hyperacusis?
- D. hemotympanum
- E. hearing loss



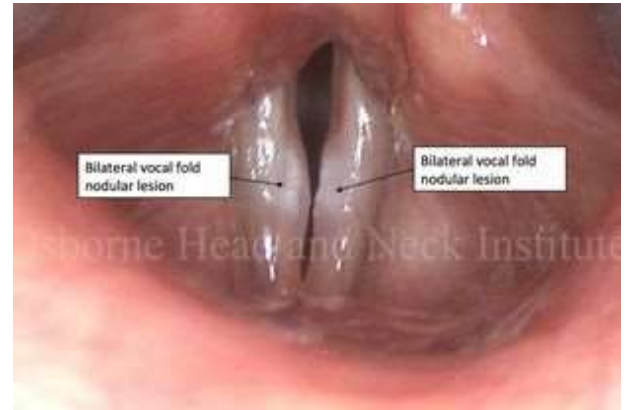


6. What is the cause?

Phonotrauma

7. Management?

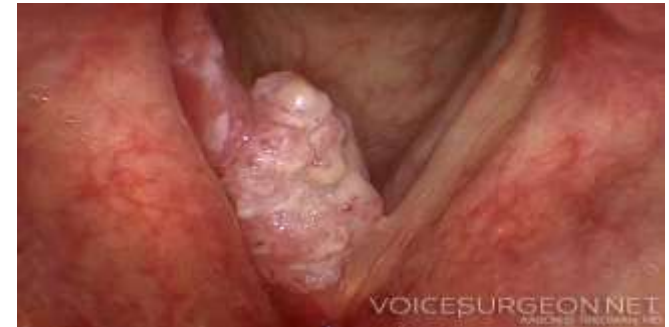speech therapy and education



8. vocal cord tumor, extends to supraglottic area, and there is vocal cord limitation, N0, M0.. what is the stage?

stage 2

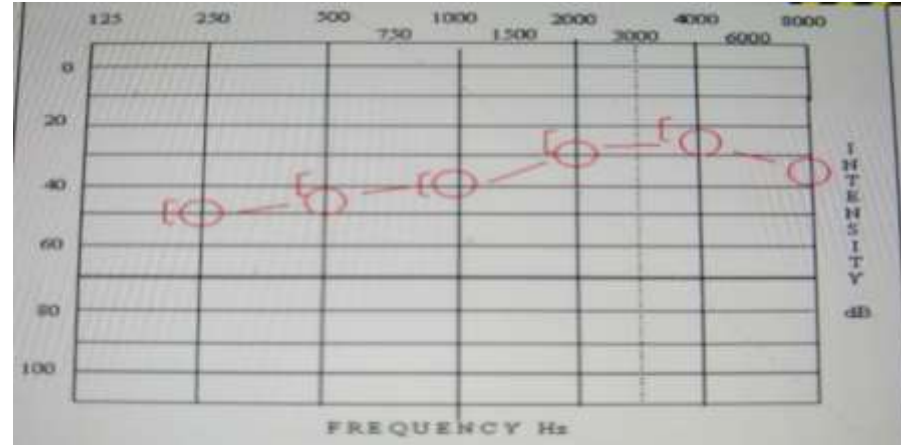
9. What is the best modality of treatment?



## 10. Audiogram

Right sensorineural hearing loss

11. Management all of them except??



## 12. Repositioning maneuver

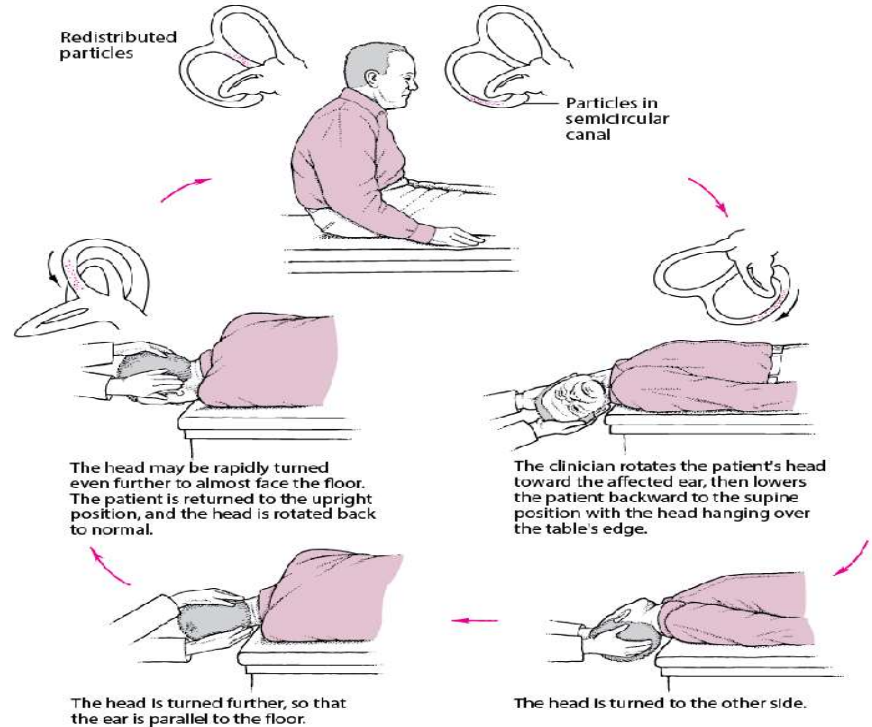
13. All the following are symptoms related to this condition except?

Vertigo

nausea

nystagmus

tinnitus



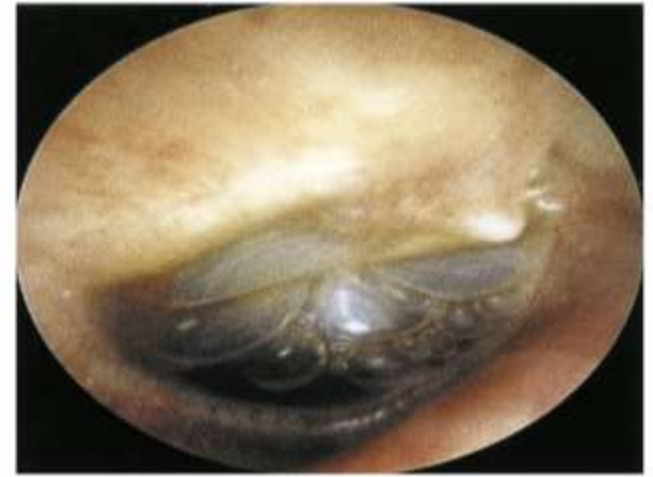
14. what is the picture present?

A. Right ear retracted with bubbles??

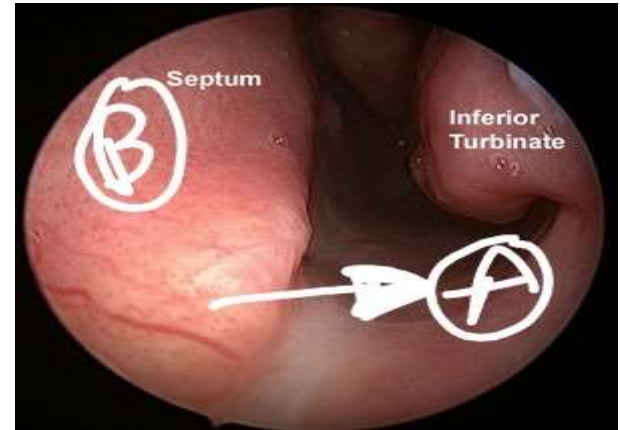
B. right ear bulgging with bubbles

c. left ear bulgging wiath bubbles

D. left ear retracted with bubbles



15. The common pathology arise from it???



16+17 )photo(CT scan of something filling the right maxillary sinus+large excised tumor) .... the scenario is:15 year old male complaint from unilateral nasal obstruction with nasal bleeding( this is typical scenario of angiofibroma

الفرع الاول

What is wrong..... we should take biopsy immediately??

الفرع الثاني

What is right.....

احترنا بين شغلتيين

When we do the surgery for this tumor we do adenoidectomy with it

Or

We do internal carotid CTA or MRA before surgery( عالاغلب هذا الجواب واحنا بنعمل

هيك عشان نتأكد أنه أصل هذا الورم مش من ال

(brain)

# *Group 4*

Leen & Rand Mbaidin

**Q1)** which is false about epistaxis?

Posterior epistaxis could be seen by nasal speculum and head light

**Q2)** pic of papillomatosis?

Most likely cause?

Which of the following not used in tx?

**Q3)** case of patient came to ER for the second time complaining of rhinorrhea headache

And 3 pic of CT multiple views?

What is the proper management? خيارات طويلة ودقيقة جدا

..  
**Q4)** pic of tympanic membrane?

Best site for myringotomy?

..  
**Q5)** pic of Tympanogram

Which is right dx : bilateral moderate sensory neural hearing loss

..  
**Q6)** pic rhinn test...answer profound sensory neural hearing loss

**Q7)**pic of nasal cavity

Which is false

- A..septum
- B..inferior turbinate
- C..polyp

Which is true? Most lesion are asymptomatic

**Q8)**pic ?

Name of the test ? Dix-Hallpike maneuver

All the following true about central vertigo except? من حكي الدكتورة اسلام

**Q9)**pic of Tympanogram

What is dx : Bilateral moderate hearing loss at 44000hz

Presbycusis

Tx ? Hearing aid

**Q10)**

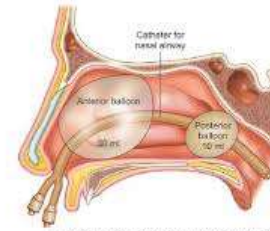


ENT

november

## 1. Pic of nasal packing, All true about this method except?

- used only when other methods of tx failed
- Needs continuous monitoring
- Used to compress littels area
- Almost always give abx



Epistaxis balloon. Smaller (10 ml) posterior balloon and bigger (30 ml) anterior balloon are inflated. Channels of catheter provides airway for nasal breathing

## 2. all of the following are complications of nasal packing except?

### Cuffed tracheostomy tube pic arrow was on the cuff

## 3. The function of arrowed structure?

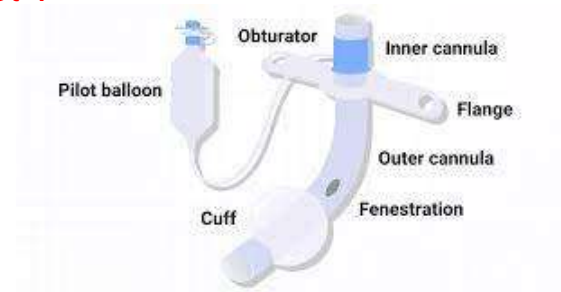To keep it in place

## 4. All of the fowllloing are unfavourable for tracheostomy except ?

- obese
- Child pt.
- Emergency
- well demarcated Neck anatomy
- laryngeal hypoplasia

## 5. Most common indication for tracheostomy?

- emergency
- Obstructive sleep apnea
- 



## Pic. Of nose with unilateral nasal purulent discharge

6. Most likely not the cause ?

Ear foreign body

7. If it was foreign body all are complications except?

- sinusitis
- Epiglottitis
- Septal perforation

-tinnitus

## Pic of perforated ear drum & arrow on handle of malleus

8. What is the arrowed structure

9. Dx?

- chronic otitis media of right ear
- acute Serous otitis media
- Cholesteatoma

# Audiometry

10.what is the diagnosis?

unilateral SNHL

11.treatment?

hearing aids

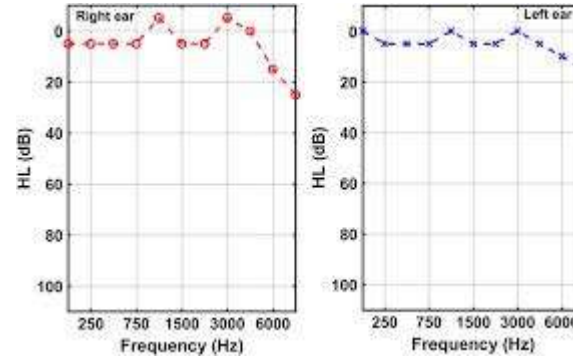
12.how to xclude retrochlear pathology?

-OAE X

-...

...

...



ضرورة تعبيرية

كانت الصورة فيها تخطيط الاذن  
اليمين O والشمال X على نفس الصورة والنتيجه  
كانو air conduction بس الفرق بين كل اذن  
اكثر من عشرة ف الاغلب فكرها  
👉 hearing loss  
7:24 PM

**Symbols used in audiogram**

Modality	Ear	
	Right	Left
AC unmasked	○	×
AC masked	△	□
BC unmasked	<	>
BC masked	⌈	⌋
No response	⊙	⊗

7:25 PM

## Case of vertigo w/ headache photophobia n&v

13. What you will find in examination

- pure horizontal nystagmus
- vestibulo- ocular reflex abnormalities
- 

14. not suitable treatment?

## Pic. Of paranasal ct w/ bilateral maxillary air fluid lvl.

15. All are ddx except

- Acute rhinosinusitis on top of chronic
- Inverted papilloma
- Invasive fungal sinusitis
- Nasal polyp
- 

16. all investigations done except

- IGE Titer
- ASO titer

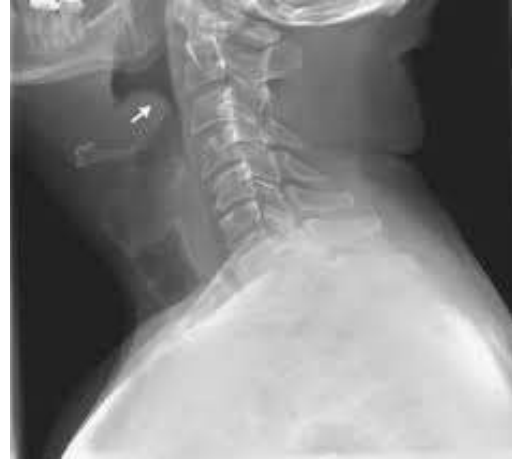17. this view show all the following except

- patent external acoustic complexes?
- not deviated septum
- Thickened maxillary sinus mucosa

## Lateral X-ray shows thumb sign

18. What is the name of this sign

19. What does it indicate? Epiglottitis

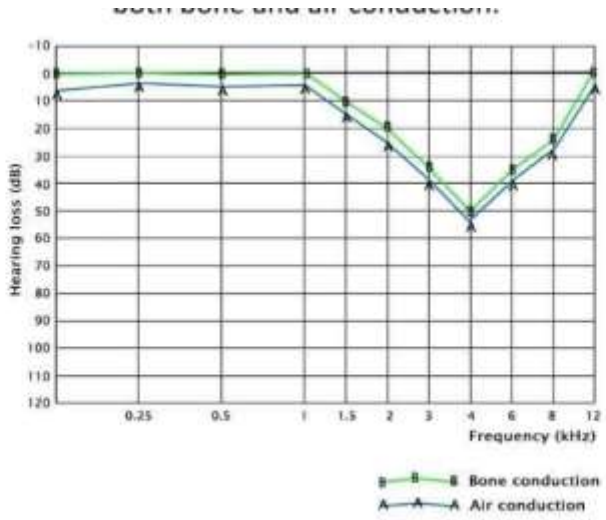


December  
All MCQs  
25 min  
One way

- 1)what is your diagnosis?
- Bilateral sensory neural hearing loss on high frequencies

- 2)what do you think the cause is?
- Work in loud area

- 3)what is the stage of hearing loss?

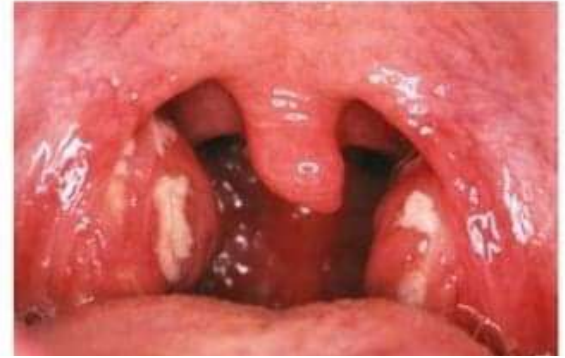




- 4) what is your diagnosis?

- Follicular tonsillitis

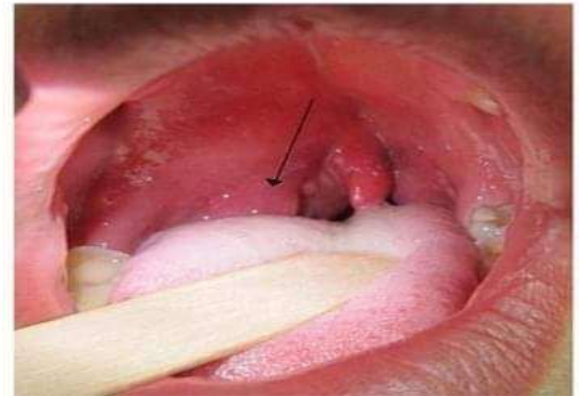
IS



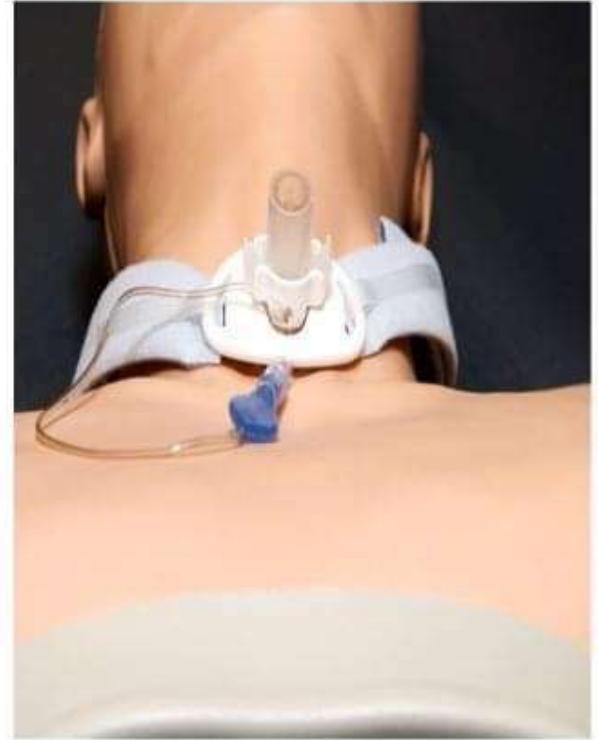- 5) what is this complication of tonsillitis?

- -peritonsillar abscess ✓

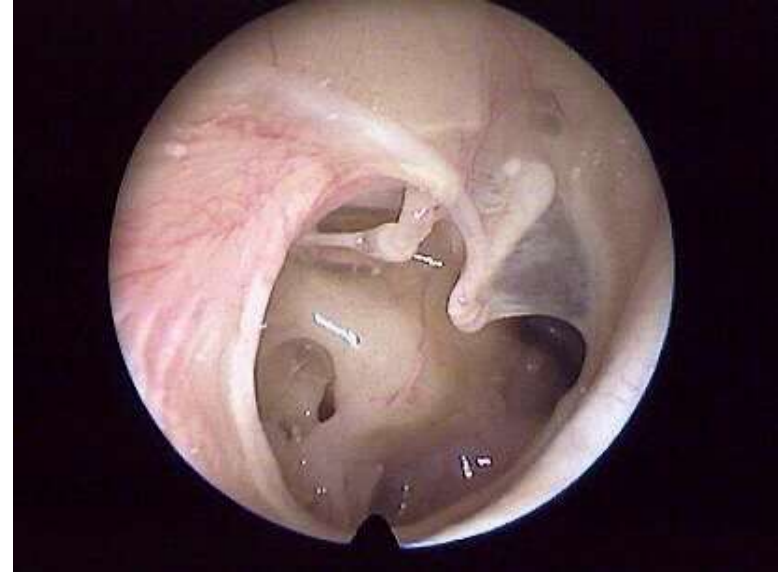- -paratonsillar abscess



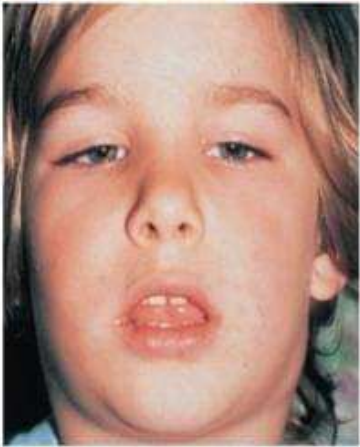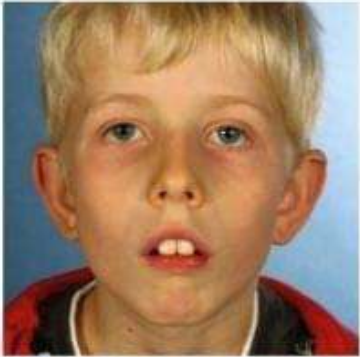- 1)all of the following are indications except
- 2)on of the following not a land mark
- 3)why you may favor it above the surgery?
- -less laceration
- -easier decannulation
- -in critically ill patients who cannot go to operation room



- 1)describe what you see:
- Subtotal dry perforation on (Lt,Rt) ear
- 2)you should do all of the following except:
- -watch and see
- -surgery
- -keep eye dry
- 3)type :
- -atticoantral
- -tubotympanic
- -serous



- 1) regarding to this pic all of the following are correct except:
  - Long upper lip
- 2) investigation you should not do?

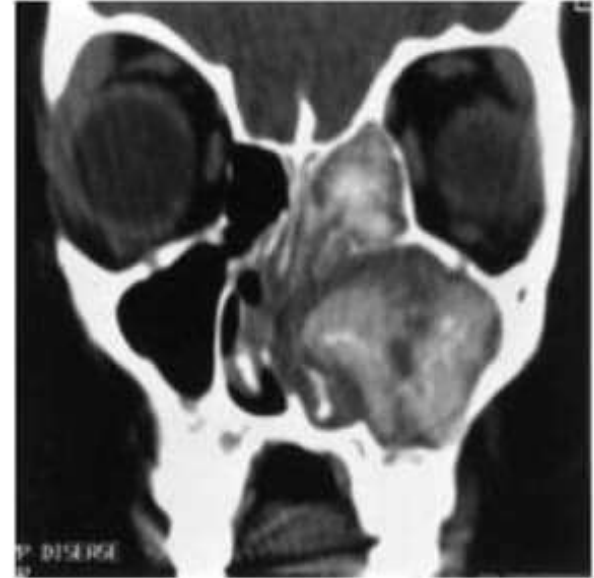

1)if the patient came with high IgE all of the following are differential diagnosis except:

- fungal ball
- allergic rhinitis
- mucocele

2)female suffer from fever ,nasal discharge ,headache  
We can use all the following except ?

- Isotonic saline
- Macrolides
- Antihistamine



- Pic for laryngeal cancer
- 1)stage of the cancer( the doctor give us TNM)
- 2)what is the appropriate investigation ?
- biopsy

# ENT archive

By : Heba saraireh

Rahma saraireh

20q in 25m

2024/2/7

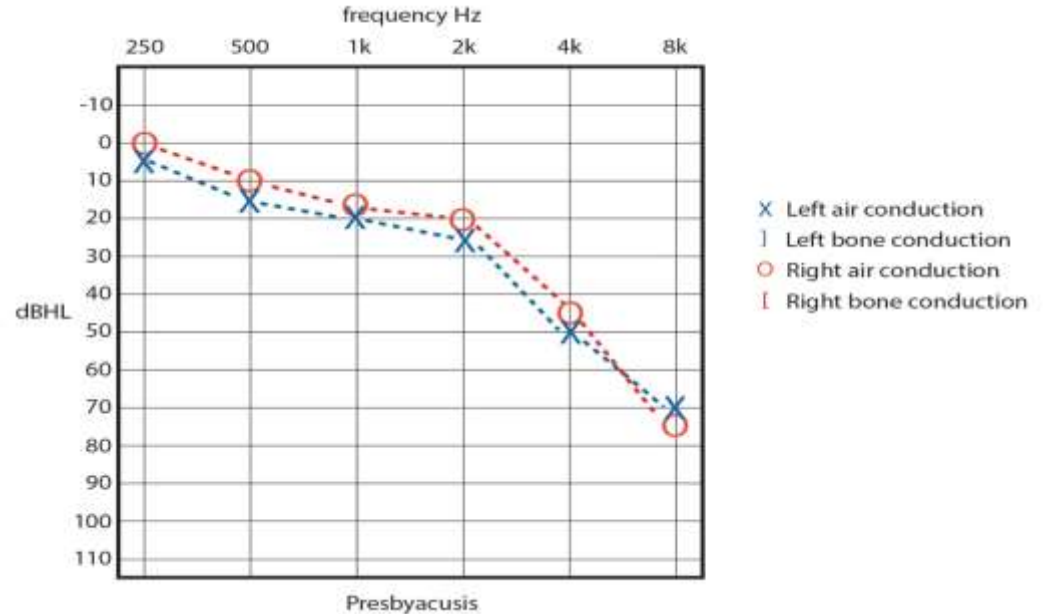
1. what is the diagnosis? **bilateral SNHL**

2. what do you think the cause ?

- a. **age related**
- b. Otosclerosis
- c. Meninger disease
- d. Normal

3. Treatment except

- a. **Diuretic**
- b. Hearing aid
- c. Cochlear implant
- d. Language training





4. DDx :

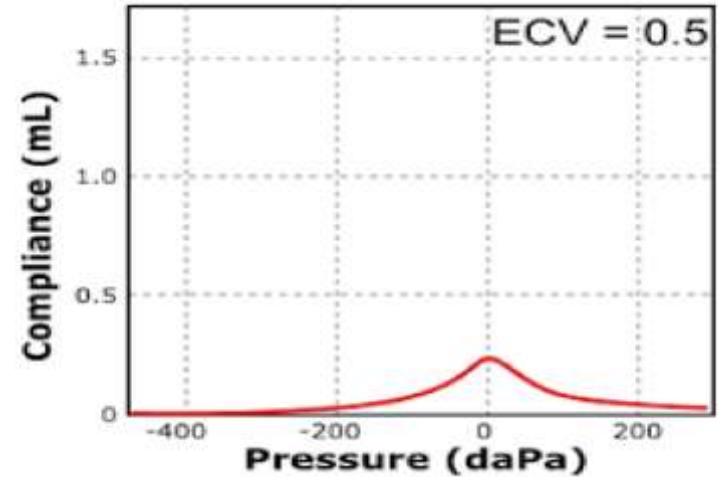
Scared tympanic membrane

5. If patients normal left :

a. right Renine negative

b. right Weber centralized

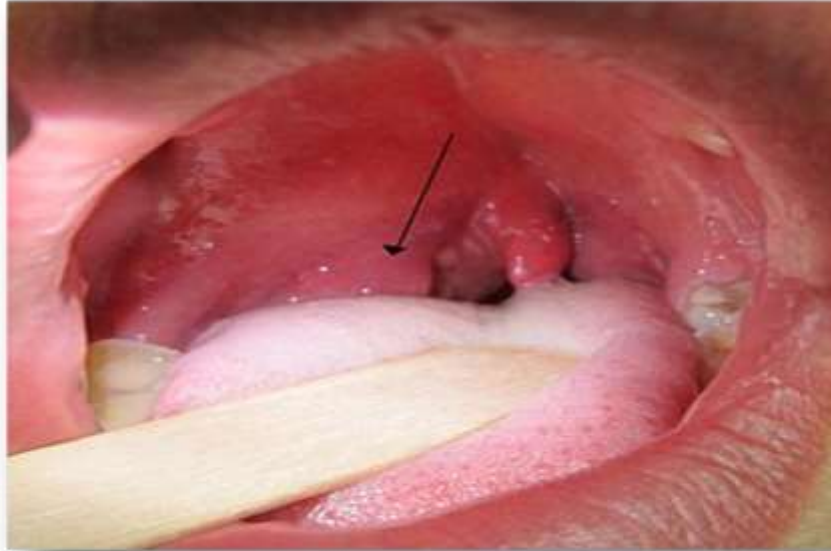
c. Renine left normal



Right ear

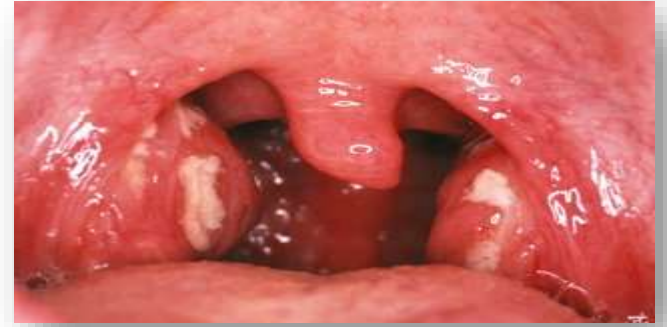6. What is your diagnosis ?

Peritonsillar abscess



## 7. The most likely diagnosis

Follicular tonsillitis



## 8. Indications for surgery:

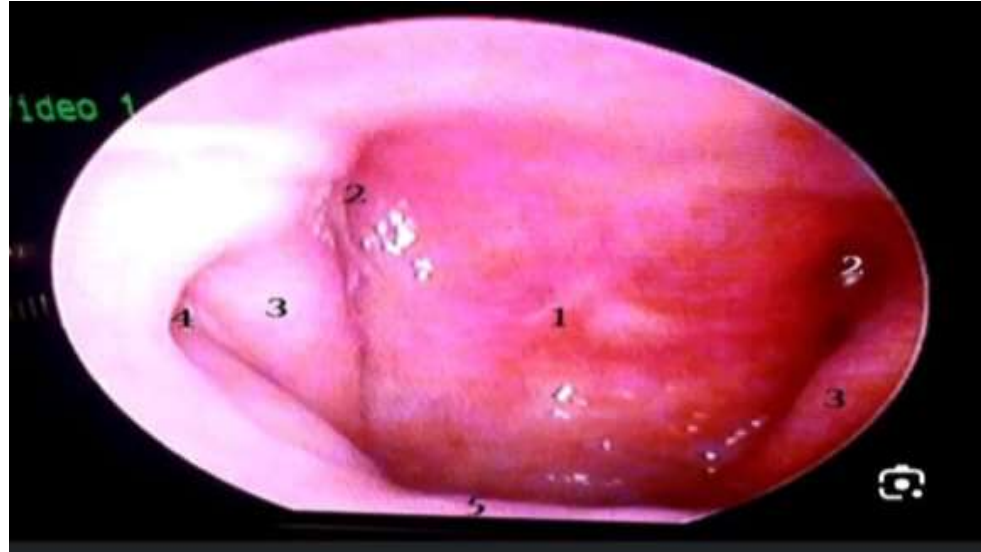
- a ) Recurrent infection of throat (7 or more in 1 year)
- b) Recurrent infection of throat (5 per year for 2 years)
- c) Recurrent infection of throat ( 3 per year for 3 years).
- D)Airway obstruction (OSA).

E) All of the above

9) Pathology that result to abnormal Pneumatic Endoscopy except :

- a) Perforation tympanic membrane??
- b) Otitis media with effusion
- c) Auditory cortex infraction??

- 10) Location nasopharynx cancer 4  
11) otitis media with effusion 2



بالامتحان انتبهوا ممكن يغير  
ترتيب الارقام

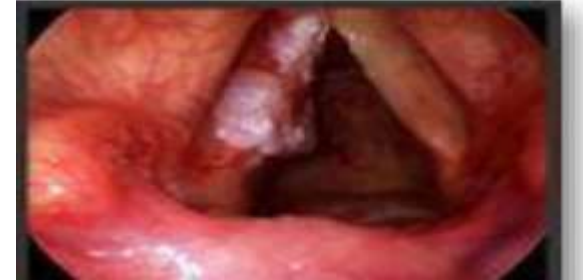12. Stage T2N1M0 ? Stage 3

13. Investigation of laryngeal cancer expect

- a) Ct of neck
- b) Needle Aspiration
- c) Coronary angiography??
- d) Gastroesophaduodenscopy
- e) Liver with albumin??

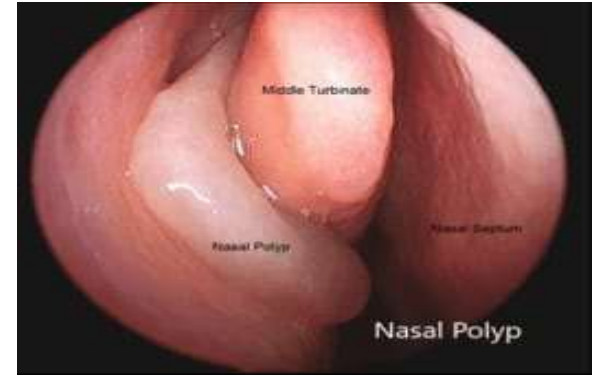
14. Risk factor of laryngeal cancer is expect

- a) Voice abuse
- b) HPV
- c) Age
- d) Smoking
- e) Radiation



15) Symptoms of picture

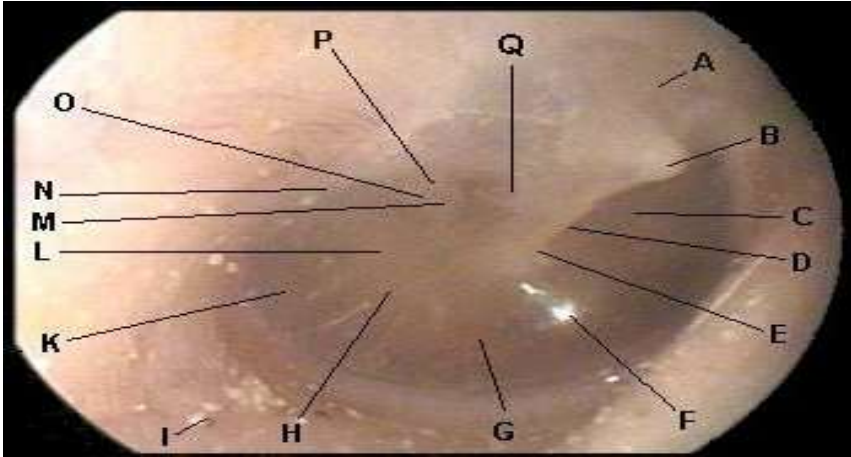
- a) Rhinorrhea sneezing congestion    ??فيه أشهر كان
- b) Unilateral nasal obstruction??
- c) Facial paralysis



16 ) Treatment if patients resistance method Is

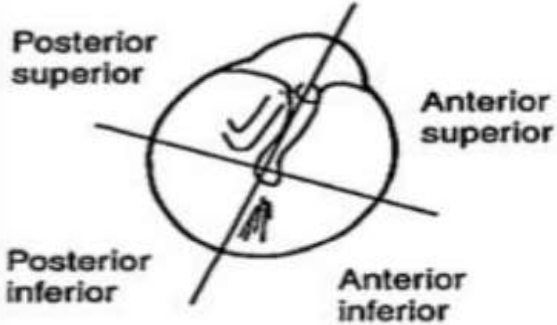
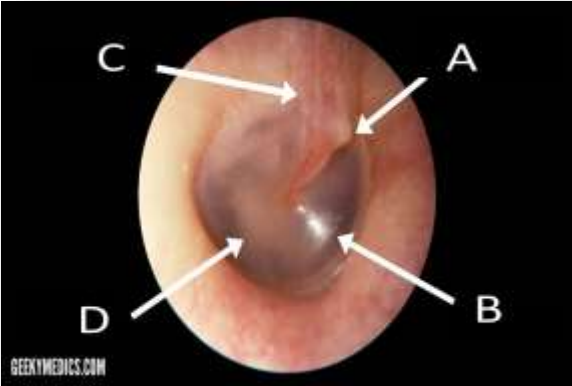
- a) **Funtional Endoscopy (FESS)**
- b) sinus Saline irrigation
- c) Antibiotics
- d) Steroid

17 ) all true except:



احفظوا الاماكن وتقسيمة الارباع

- A. Lateral process of the malleus
- B. Cone of light
- C. Pars flaccida
- D. Pars tensa
- E. manubrium of malleus



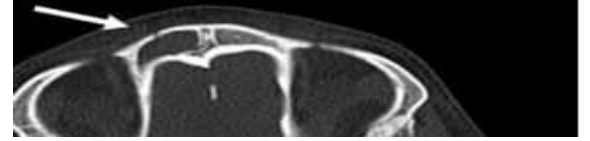


18) All true except :

**Coronal view of paranasal sinus**

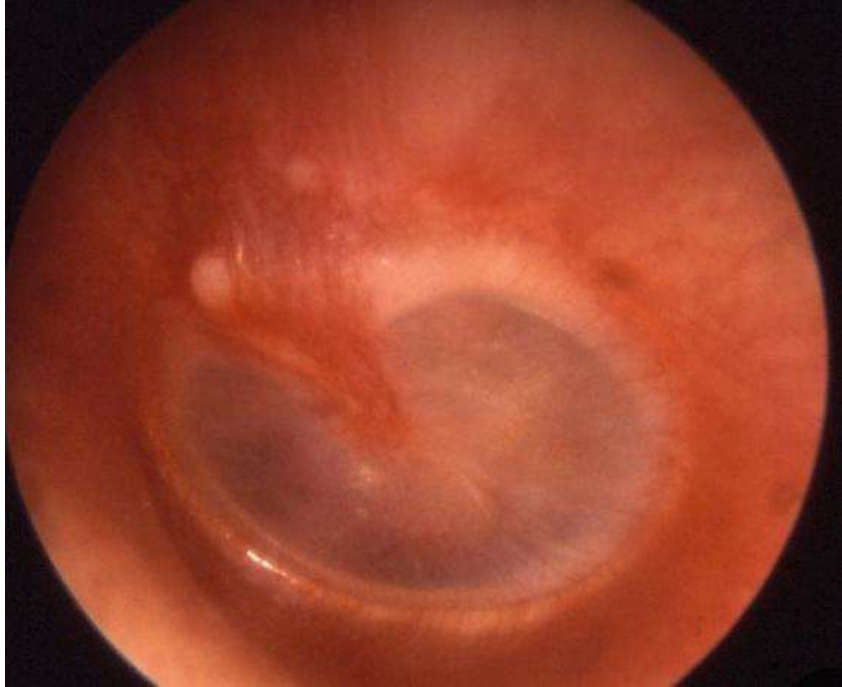
كأخلاق الصورة

19) About treatment:



# ENT ARCHIVE

Done by: omya anwar albadaineh  
khozama saadah



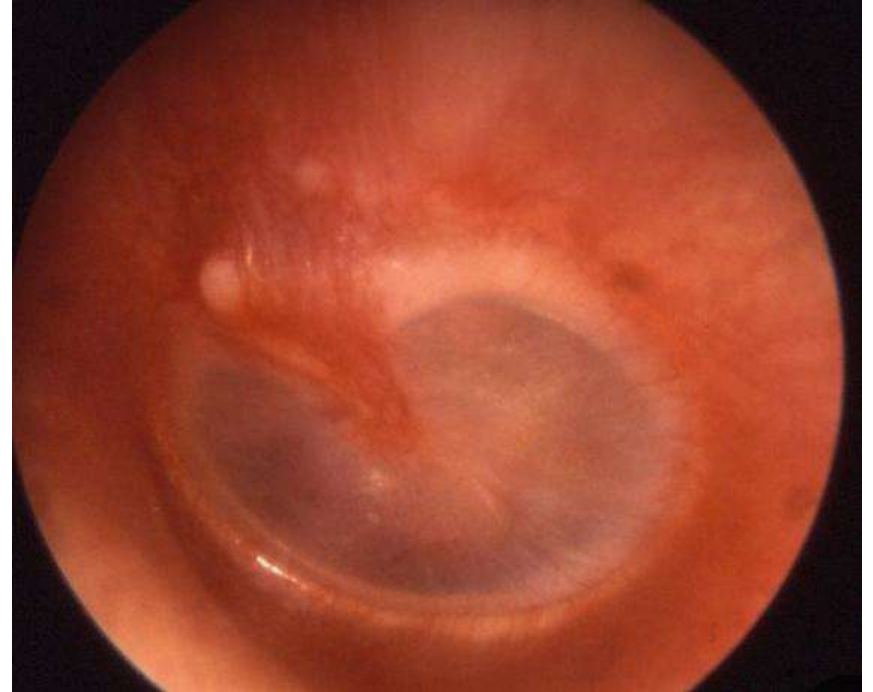
**Q1) One of the following is a presentation for 32y old pt come with ear dullness:**

- A. Left side retracted tympanic membrane ✓
- B. Right side bulging tympanic membrane
- C. right side retracted tympanic membrane
- D. left side bulging tympanic membrane
- E. right side perforated tympanic membrane

**Q2) Definitive treatment is:**  
a. Myringotomy with grommet insertion ✓

Q3 ) one of the following is not an investigation that should be done for this case :

- A. pneumatic otoscopy
- B. tympanometry
- C. temporal CT ✓
- D. MRI and CT
- E. Audiometry

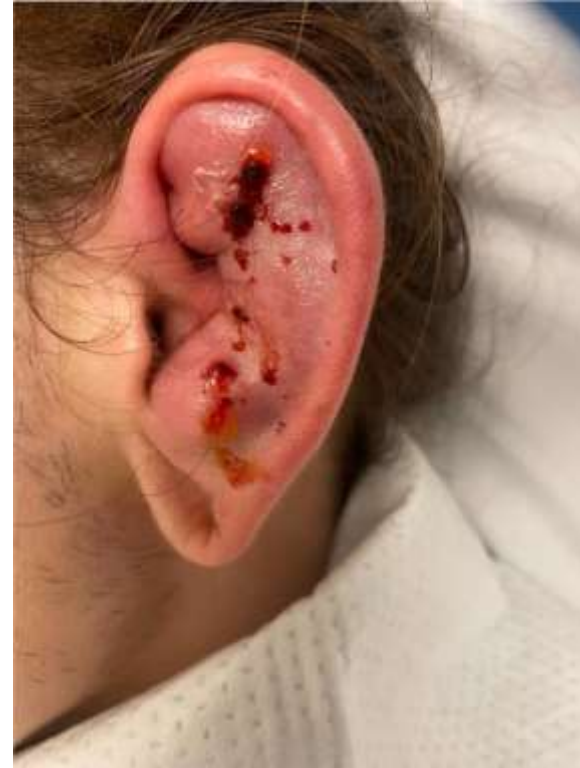

Q4) One of the following is not considered the best DDx for this Pt :

- A. Perichondritis
- B. Eryispelas
- C. Bollus myringitis ✓✓
- D. Auriculohematoma

Q5) The most appropriate management is:

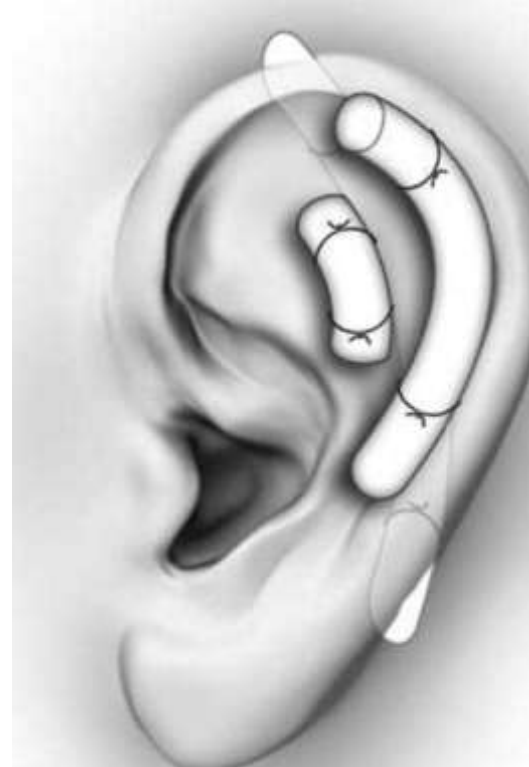- A. incision and drainge ✓✓
- B. Leave to heal spontaneously
- C. compression dressing.



Q6) After incision and drainage, the purpose of covering?

- A. Decrease dead space and prevent reaccumulation✓
- B. For disinfectant
- C. protection and coverage

مش نفس الصوره كانت لمريض واقعي بس نفس  
الdrain

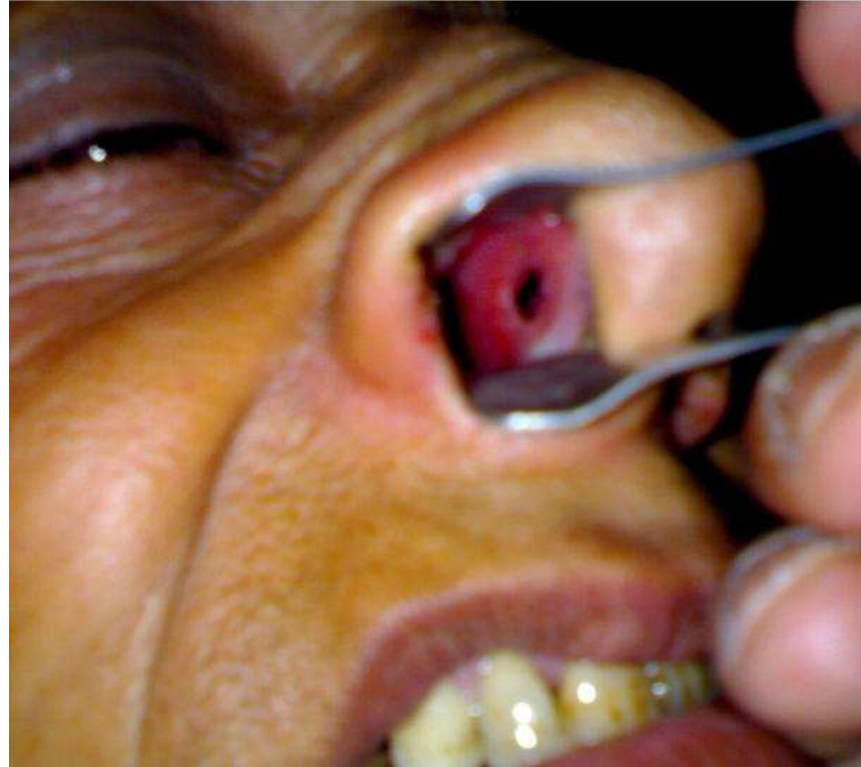

Q7) The name of this procedure is:

- A. Anterior rhinoscopy ✓
- B. posterior rhinoscopy

Q8) One of the following is not considered a cause of this pathology :

- A. Syphilis
- B. kartegnar syndrome ✓✓
- C. septoplasty
- D. cocain abuse
- E. Foreign body



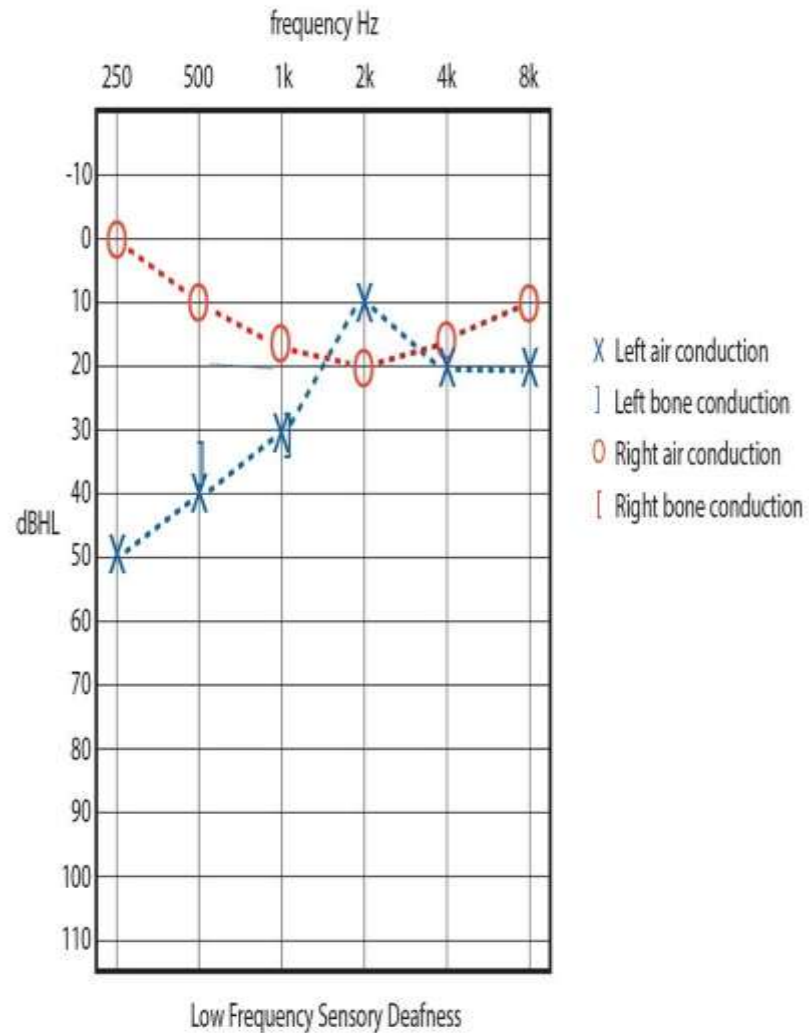
Q9) 54 years old male come with progressive hearing loss, which is resulting from

- A. right side SNHL
- B. left side SNHL ✓✓
- C. left side CHL
- D. right CHL
- E. left side mixed hearing loss

Q10) all of the following confirm the diagnosis except :

- A. positive Dix hallpike test ✓□
- B. rinne's test
- C. tympanometry
- D. audiometry

Q11) Answer: cerebellopontine angle CT, not the best modality for diagnosis





Q12) what's Your DDX :

- A. Laryngomalacia
- B. acute epiglottitis ✓✓
- C. laryngeal mass
- D. lymphadenopathy

Q13 ) The most common age of presentation is:

- A. 6 months to 2 years
- B. 2 years to 7 years ✓

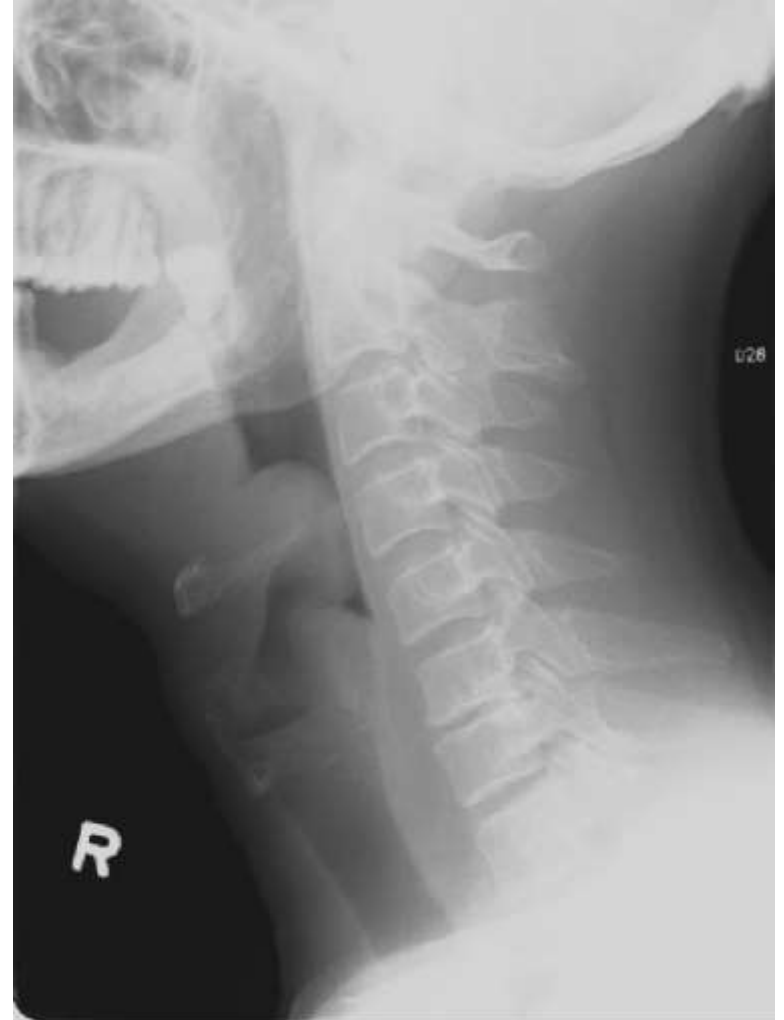
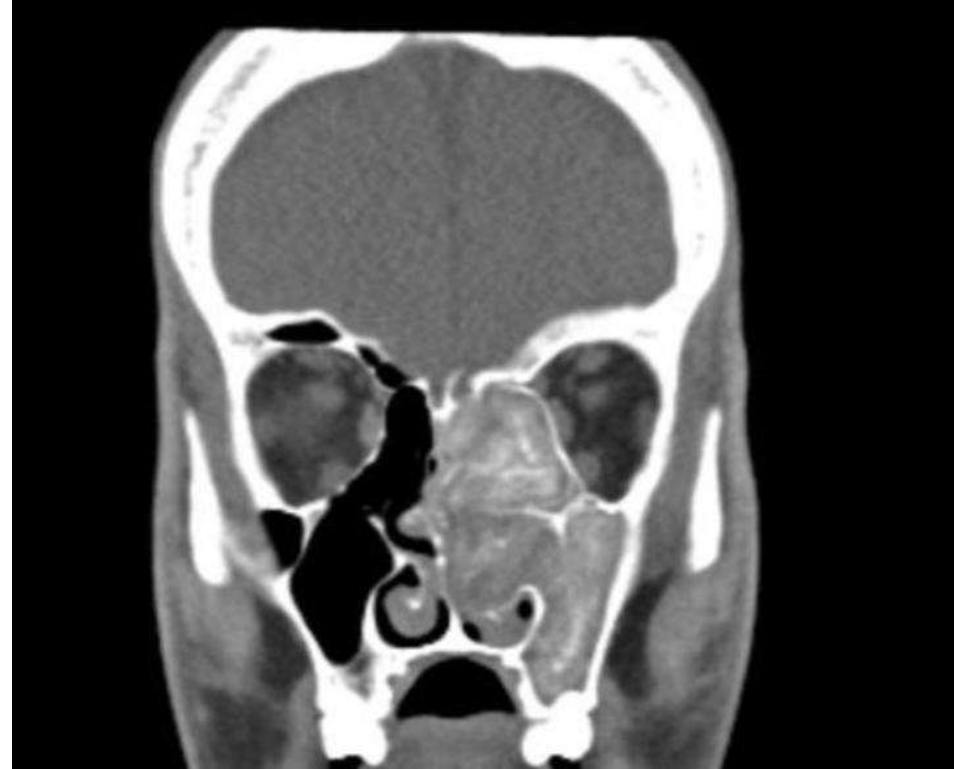
Figure 1 X-ray features of adult acute epiglottitis with

Q14 ) One of the following is TRUE( case of 44years old male with headache and nasal congestion )

- A. invasion of the orbit by ethmoidal sinus content
- B. change in the shape and structure of the bones and thinning of the sinus mucosa
- C. non contrasted coronal CT for paranasal sinus and posterior ethmoid sinus ✓✓  
( CORONAL ما بتبين في ال POSTERIOR VIEW في AXIAL )

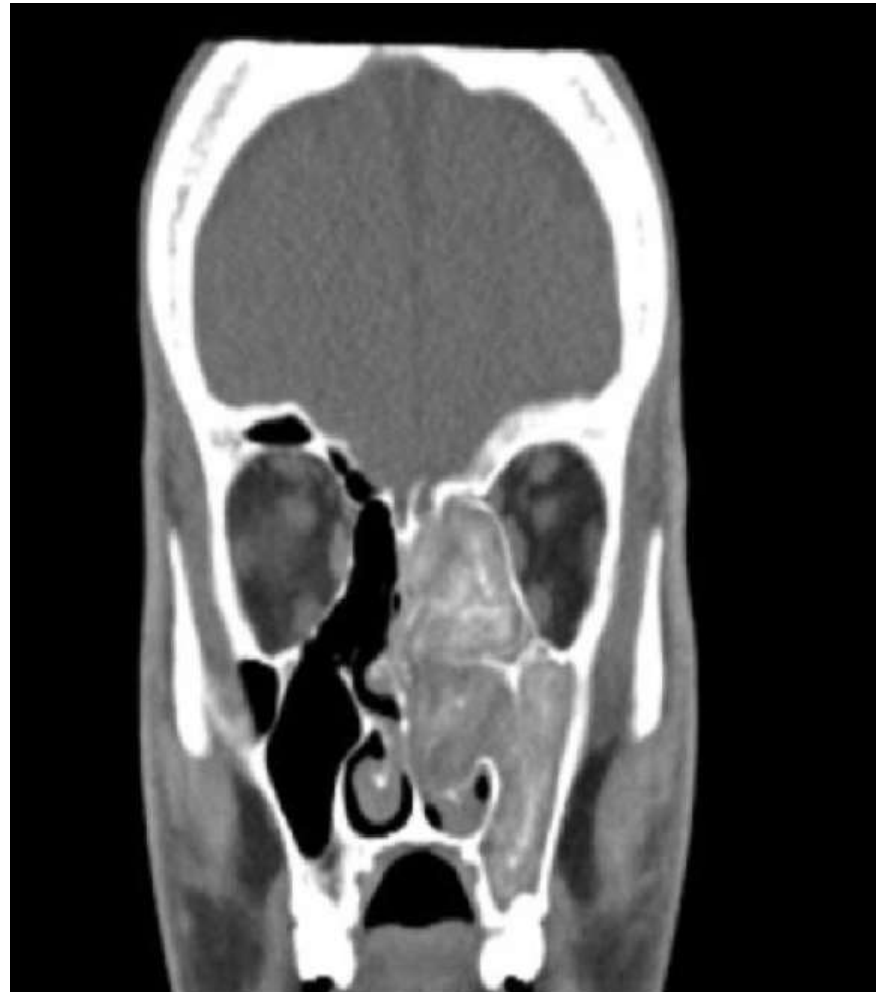

Q15) one of the following will not be present in the past medical history of the patient :

- A. pt takes immunosuppressive drugs after kidney transplant
- B. asthma (جواب د اسلام) ✓
- C. past family And/Or individual Hx of the same case
- D. allergy
- E. working with perfumes and strong smells

Q16) The first thing to do is:

- A. Iv Amphotricin b
- B. surgical treatment ✓✓
- C. local steroids spray

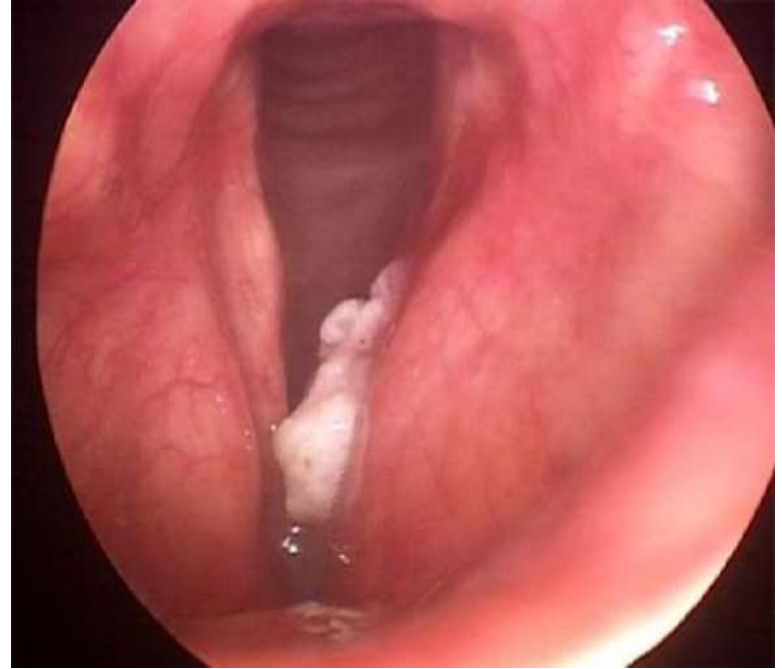

Q17) One of the following is not considered the cause of this pathology:

- A. voice abuse ✓✓
- B. fungal infection
- C. leukoplakia
- D. laryngeal cancer
- E. papillomatosis

Q18 ) The stage of this tumor with T2N1M0 is

- A. Stage 1
- B. stage 2
- C. stage ✓✓ 3
- D. stage 5
- E. stage 4

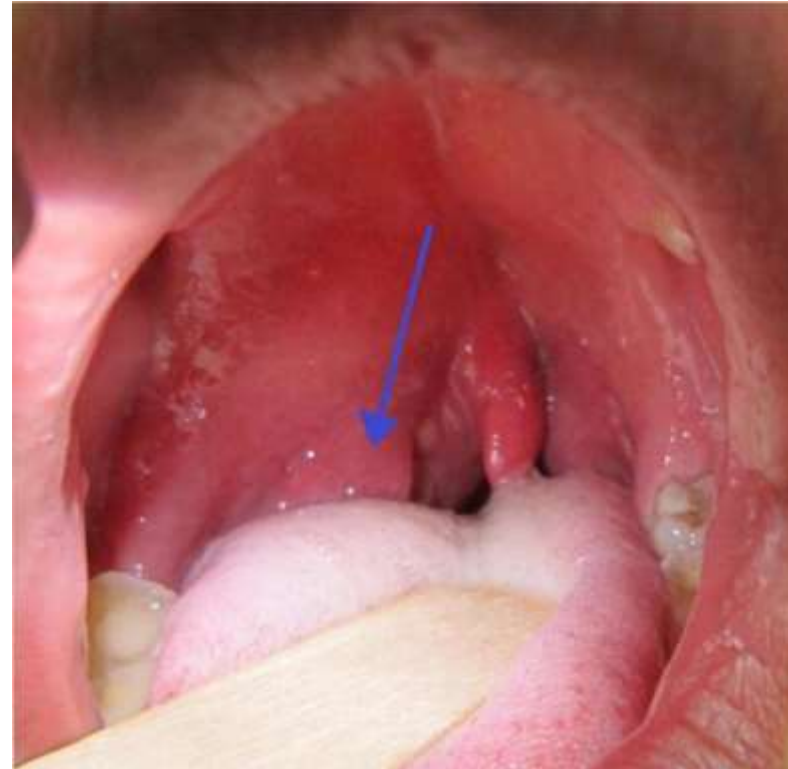

Q19) The main DDX is

- A. Peritonsillar abscess ✓✓
- B. paratonsillar abscess
- C. retropharyngeal abscess
- D. lymphoma
- E. peritonsillar cellulitis

Q20) One of the following is not an absolute indication for tonsillectomy

- A. febrile convulsion ✓□
- B. obstructive sleep apnea
- C. 7 episodes in 1 year
- D. 5 episodes in the year for 2 years
- E. 3 episodes in the year for 3 year



# ENT Mini-OSCE

الله صح كان عليه ٢ صح؟

10:03 AM

Hemorrhagic telangectesia what is wrong about it

Autosomal recessive اعتقد

Epistaxis 'cuz of (HHT) Should not be treated by chemical silver اشي

صورة فيها pneumatized اشي (concha) الي هي

Traumatic tympanic perforation

مع

Tympanogram

10:03 AM

Ct scan :

1. Right pneumatic middle turbinate
2. Parasthesia and ophthalmology

10:03 AM



You

You

بدون الاجابة 🤔🤔

بس حاسة الاسئلة انشطيت من راسي

2 centeal vertigo

3 laryngomalacia

1 vocal cord lesion

1 polyp

2 audiometry - CHL

2 perotonsillar abscess

Traumatic tympanic perforation , Location

10:01 AM

ك عناوين هاد اللي متذكرته 🤔🤔

10:01 AM

ما يعرف الاجوبة للاسف

Edited 10:01 AM

2 centeal vertigo

3 laryngomalacia

1 vocal cord lesion

Tonsillitis

10:02 A



مجموعة 1

peritonsillar ما في  
asymmetric tonsillar enlargement كان

10:07 AM

peritonsillar ما في  
asymmetric tonsillar enlargement كان

ما يعرف والله

10:08 AM

indications of surgery ال  
في تبعون ال

10:08 AM ✓

You

indications of surgery ال  
في تبعون ال

Failure to thrive

10:09 AM

peritonsillar ما في  
asymmetric tonsillar enlargement كان

هاي ايش كان الجواب تذكرت الصورة

10:09 AM ✓

مجموعة 1

صورة ال CT paranasal عليها سؤالين كان

10:06 AM

واحد جوابه pnumatized  
والثاني كيف يكون ال  
presentation تبع  
المريض

10:06 AM

Ct scan :

1. Right pneumatic middle turbinate
2. Parasthesia and ophthalmology

اه هاد نفسه اللي هون

10:06 AM

ايوا اه

10:07 AM

لاشي نسيته برضه  
Diagnostic criteria  
Peritonsillar

اعتقد

10:07 AM