



MGMC batch memories

3 January 2014 at 13:36 · 🌐

Mnemonic#3

Portocaval Anastomoses

BLU APL (blue apple)

B-Bare area of liver

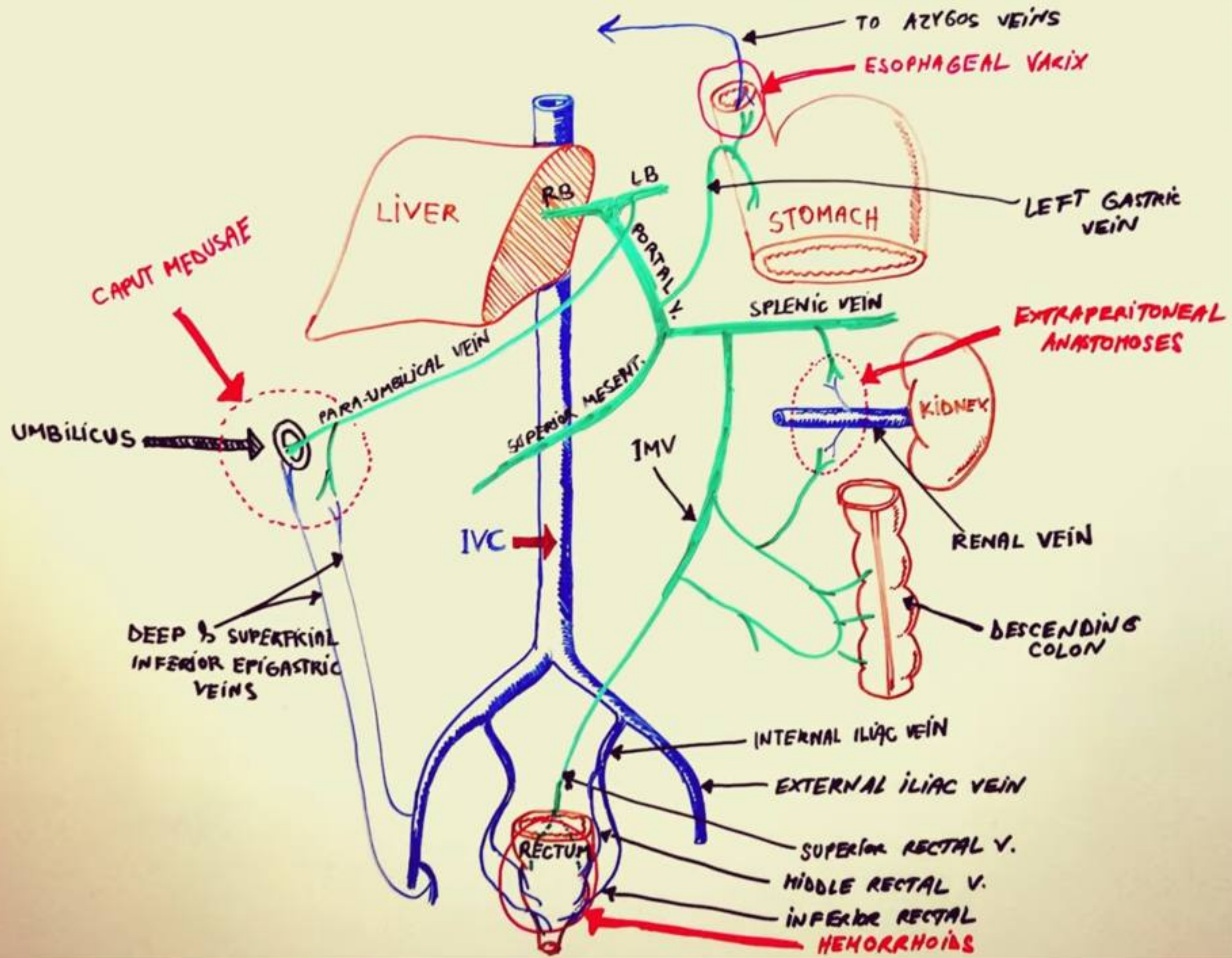
L-Liver

U-Umbilicus

A-Anal canal

P-Posterior abdominal wall

L-Lower end of oesophagus



Hepatic portal system

to heart

© ALILA MEDICAL MEDIA. All rights reserved

Purchase a license to use this video at

www.AlilaMedicalMedia.com

GI tract (lower esophagus
to upper anal canal)
spleen
pancreas

