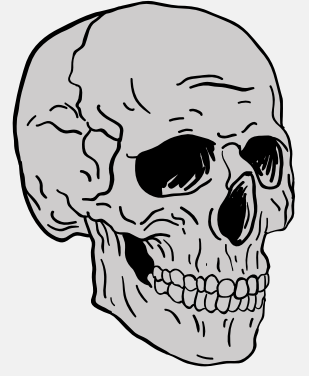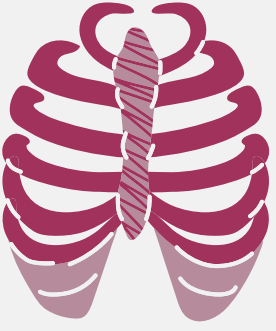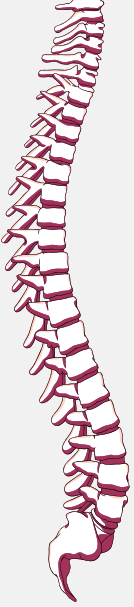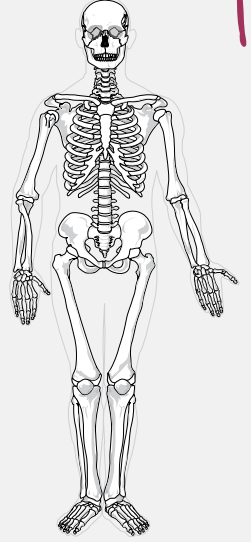


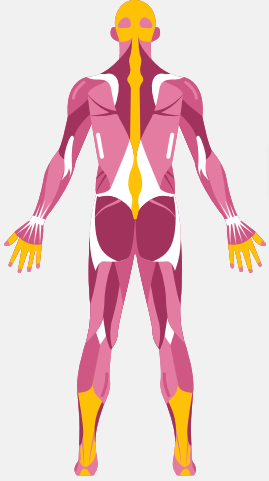
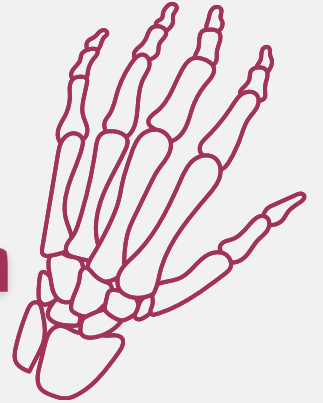# MSS MODULE LAB EXAM



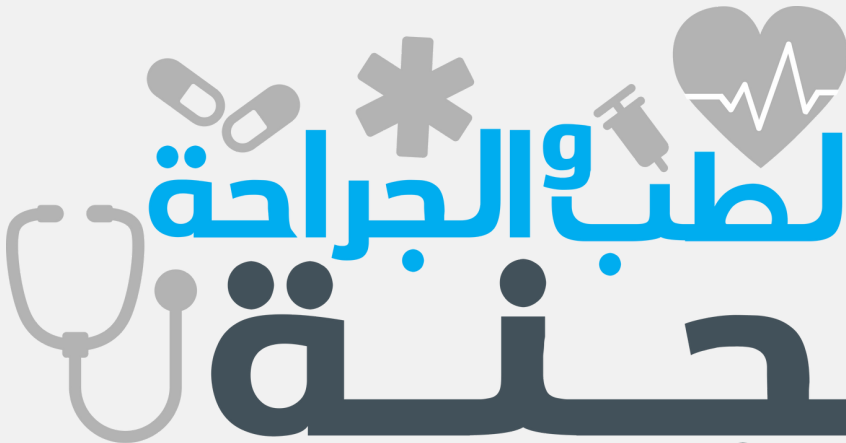زوح 2021

Done by:

- Shahd Alayouben

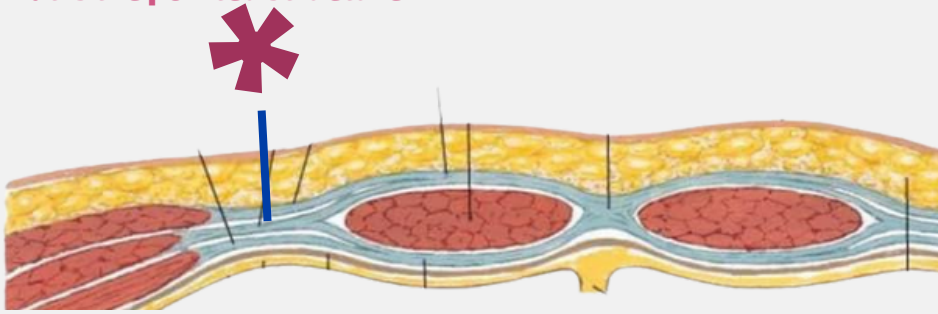


الطب والجراحة  
لجنة



# ANATOMY

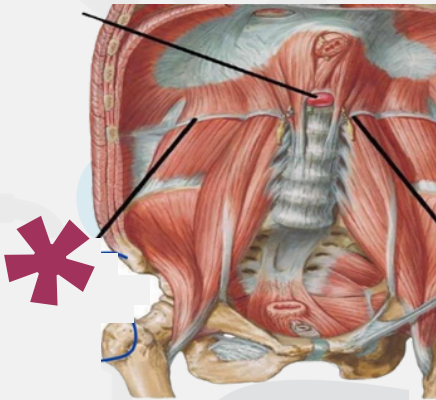
1. What is the pointed structure:



- A. Aponeurosis of transversus abdominis muscle
- B. Aponeuroses of external oblique muscle
- c. Aponeuroses of internal oblique muscle
- d. Anter layer of rectus sheath

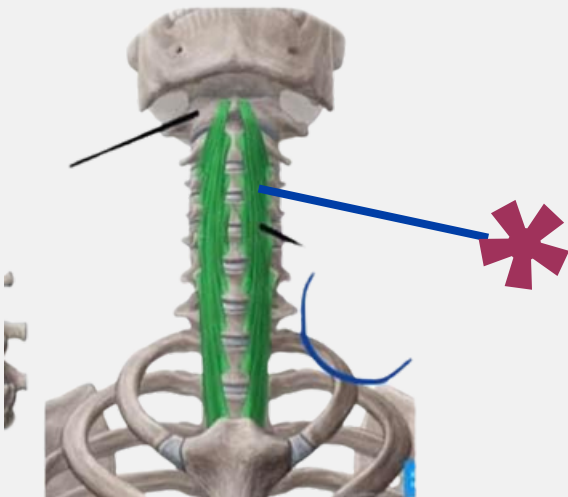
Answer: c

2. What is the pointed structure:

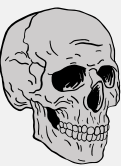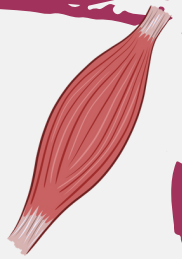


- A. Letral arequate ligament

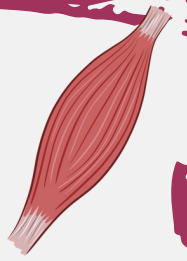3. What is the pointed structure:



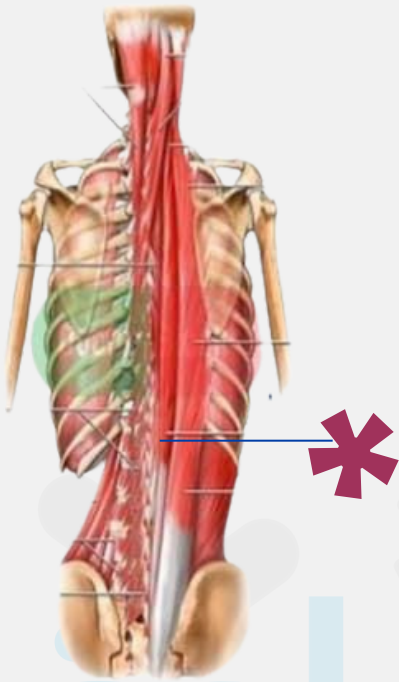
- A. Longus coli



# ANATOMY



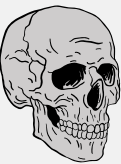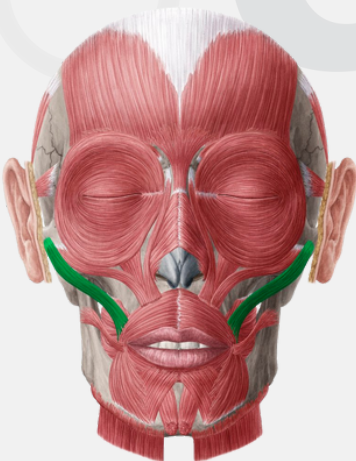4. What is the name of this muscle:



- A. iliocostals thoracis
- B. Iliocostals lumborum
- c. Longissimus cervicis
- d. Longissimus thoracic

Answer: d

5. What is the name of this muscle:

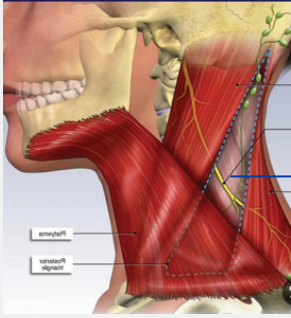


- A. Zygomaticus minor
- B. Masseter
- c. Levator labii superuosis
- d. Zygomaticus major

Answer: d

# ANATOMY

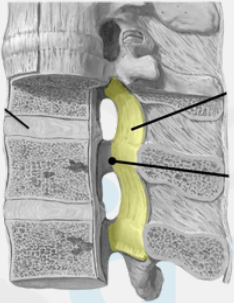
6. Name the pointed nerve



- A. Spinal Accessory nerve
- b. Hypoglossal nerve
- c. Facial nerve

Answer: A

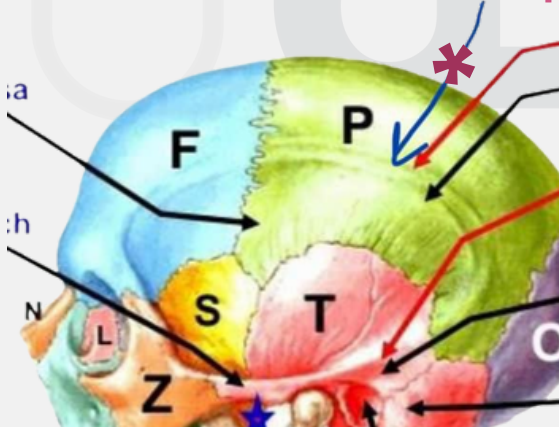
7. Name the colored structure:



- A. Intervertebral disc
- b. Ligamintum flavum
- c. Posterior longitudinal ligament
- d. Inter transverse ligament

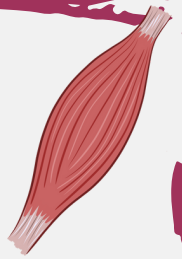
Answer: B

8. Name the muscle attached to the pointed structure



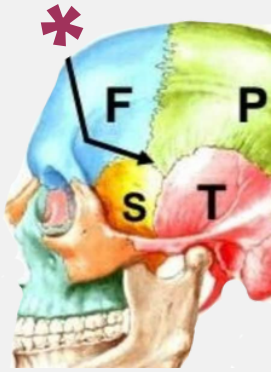
- A. Occipitofrontalis
- B. Temporals

Answer: A



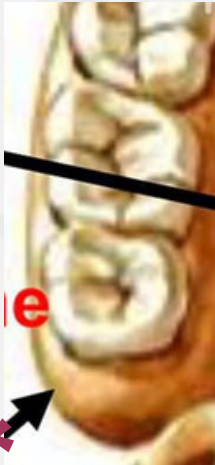# ANATOMY

9. all the following are bone make the pointed structure EXCEPT:



A. mastoid process of temporal bone

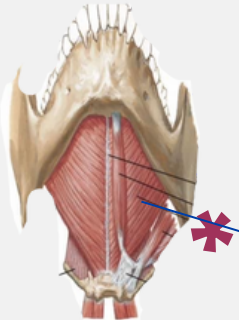
10. The pointed bone origin for which muscle :



- A. lateral pterygoid muscle
- b. Deep head of medial pterygoid
- c. Superficial head of medial pterygoid
- d. Masseter muscle

Answer: c

11. The innervation for the pointed muscle is :

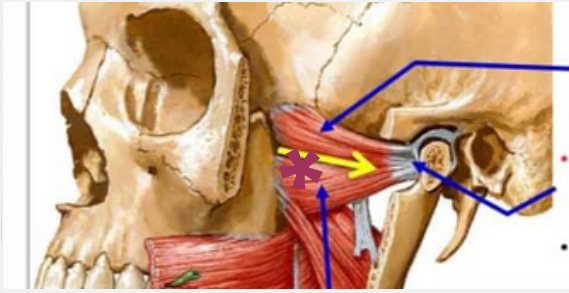


A. nerve to mylohyoid



# ANATOMY

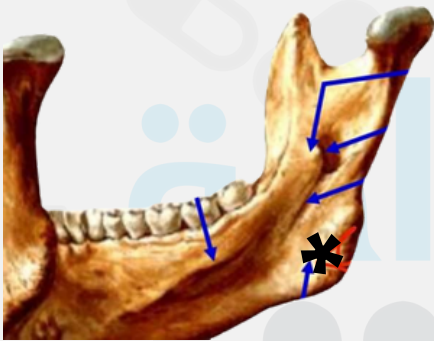
12. Origin of the pointed structure:



- A. Lateral surface of the lateral pterygoid muscle
- b. Deep head of lateral pterygoid

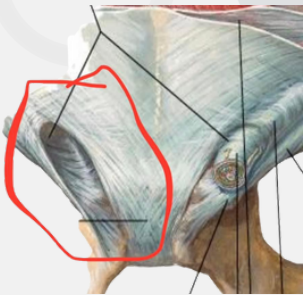
Answer: A

13. Name the ligament that attach to the pointed structure:



- A. Stylomandibular ligament

14. At its margin give extension to?

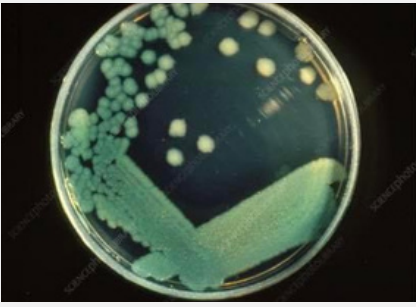

External spermatic fascia



# MICRO

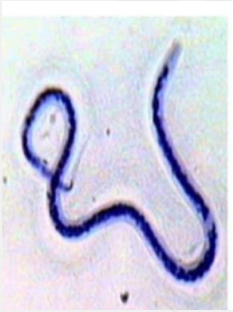15. This culture for which bacteria :



- A. *Pseudomonas aregnosa*
- b. *S. pyogenes*
- c. *S. agalaciae*
- d. *S. aureus*

Answer: A

16. Wrong about this:



- a. The adult female shorter than male
- b. Found in blood

answer: b

17. The bacteria for this culture

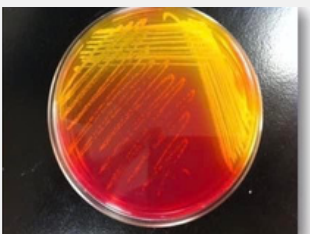

- a. *Staphylococcus epidermis*
- b. *Staphylococcus aureus*
- c. *S. Pyogenes*



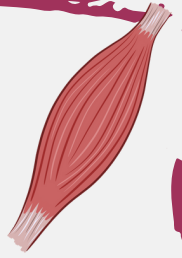
answer: b

18. This culture reffer to:

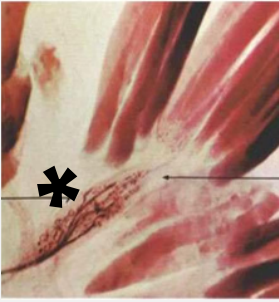


A. *S. aureus* on mannitol salt agar

# HISTO



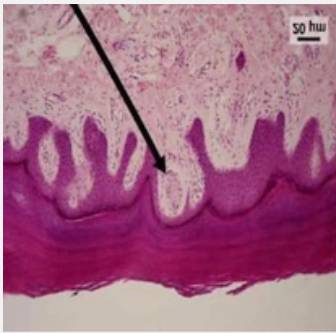
19. The function of the pointed structure :



A. Tension & counteract muscle spindle

20. What is the pointed structure:

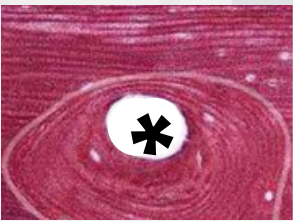
ملاحظة: جابتها النا بالشقلوب برضه



- a. Panicle corpuscles
- b. Messenir corpuscles
- c. Fusiform

answer: b

21.name the pointed structure:

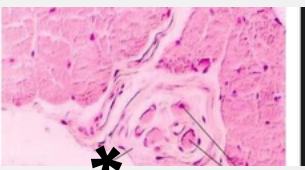


- A. Cercimifential lamellae
- b. Lacuna
- c. Haversian canal
- d. Osteoblast



answer: c

22 . Name the pointed structure:

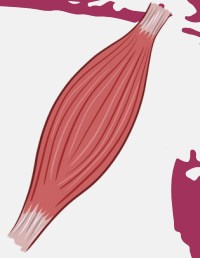

- a. Muscle spindle
- b. Golgi organ tendon
- c. Intrafusal fiber

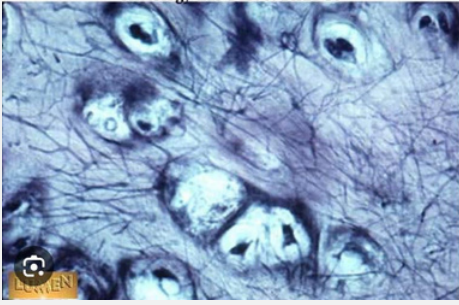
Answer: A



# HISTO



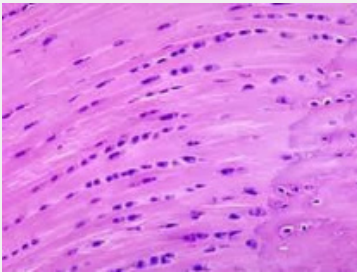
23. Type of this cartilage:



- A. Hyaline cartilage
- b. Elastic cartilage

answer: B

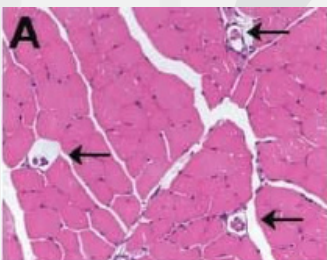
24. Which the following is correct about this structure?



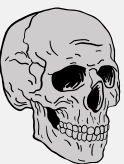- a. Cartilage with acidophilic matrix
- b. Cartilage with basophilic matrix

answer:a

25. Type of mechanoreceptor

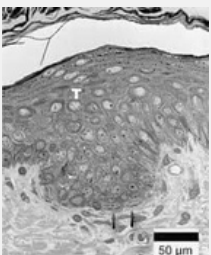


- A. Free nerve endings
- b. Golgi organ
- c. Muscle spindle



answer : c

26 . Name the type of this receptor located in epidermis :

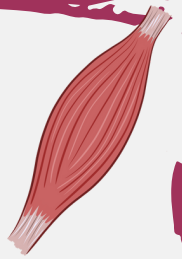


- a. Free nerve ending
- b. merkel cell

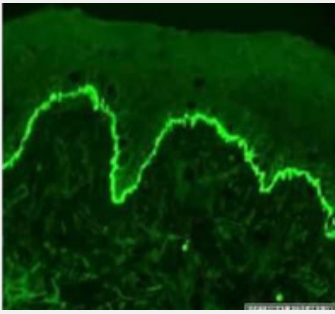
ملاحظة: يوجد اختلاف علاجاتين

Answer: b

# PATHO



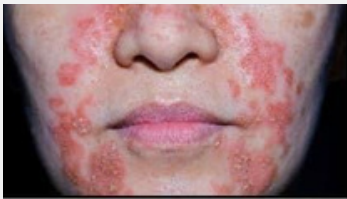27. which of the following related to this immunofluorescent study:



- A. Pemphigus vulgaris
- b. Bullous pemphigoid
- C. Pemphigus foliaceus

answer: B

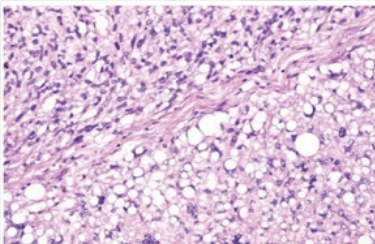
28. The diagnosis of this disease:



- a. photo dermatitis
- b. Allergic contact dermatitis
- c. Primary irritant dermatitis

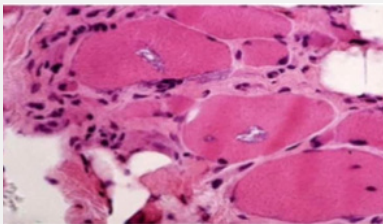
29. This histological pattern related to which disease:

answer:a



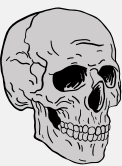- A. Peomorphic liposarcoma

30> all about this pathological findings are true except

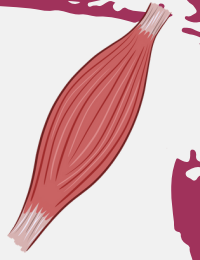

- a. most common in young and children
- b. no response to immunosuppressive drugs
- c. vacuole with granules
- d. inflammation is secondary event

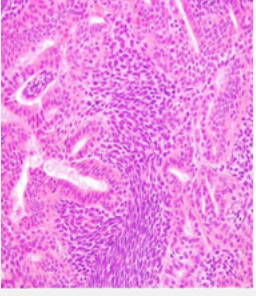
Answer: a



# PATHO



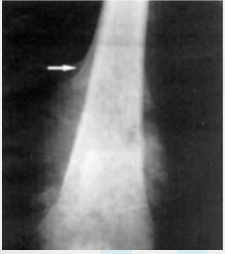31. Regarding this disease the mutation occur in :



- A. SS18
- b. PAX3

Answer: a

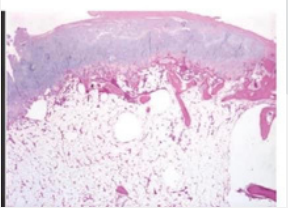
32. 57 years old man with aggressive tumor , all about it true except



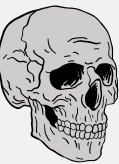- 1) bimodal distribution
- 2) MDM2 and CDK4 less expressed
- 3) CDKN2A shares with other Tumours
- 4) periosteal preserved with sclerotic mass

Answer: 2

33. Can progress to



- 1) osteochondroma
- 2) chondrosarcoma
- 3) osteosarcoma



Answer: 1

34. All of the following are true about osteosarcoma except:

السؤال غير مكتمل

Minimally 10% of cases of osteosarcoma can be diagnosed..

من دخل عليه رمضان وهو مشغول بالدراسة الجامعية والإستعداد لامتحانات وغيرهم، فليحتسب دراسته من جملة أوارد التعبدي وينوي ذلك، لكن لا ينحط عن صلاة التراويح وتلاوة جزء من القرآن، وليجتهد في التفرغ في العشر الأواخر ما استطاع، وليعوض فوائت الأوراد بكثرة ذكر لله أثناء الليل وأطراف النهار؛ فإن للذكر أثرًا فعلاً في تهذيب النفس واستدراك النقص .

- الشيخ محمد بن محمد الأسطل.

فتح لله عليكم فتوح العارفين، لا تنسوا غرة الامة من صالح دعائكم