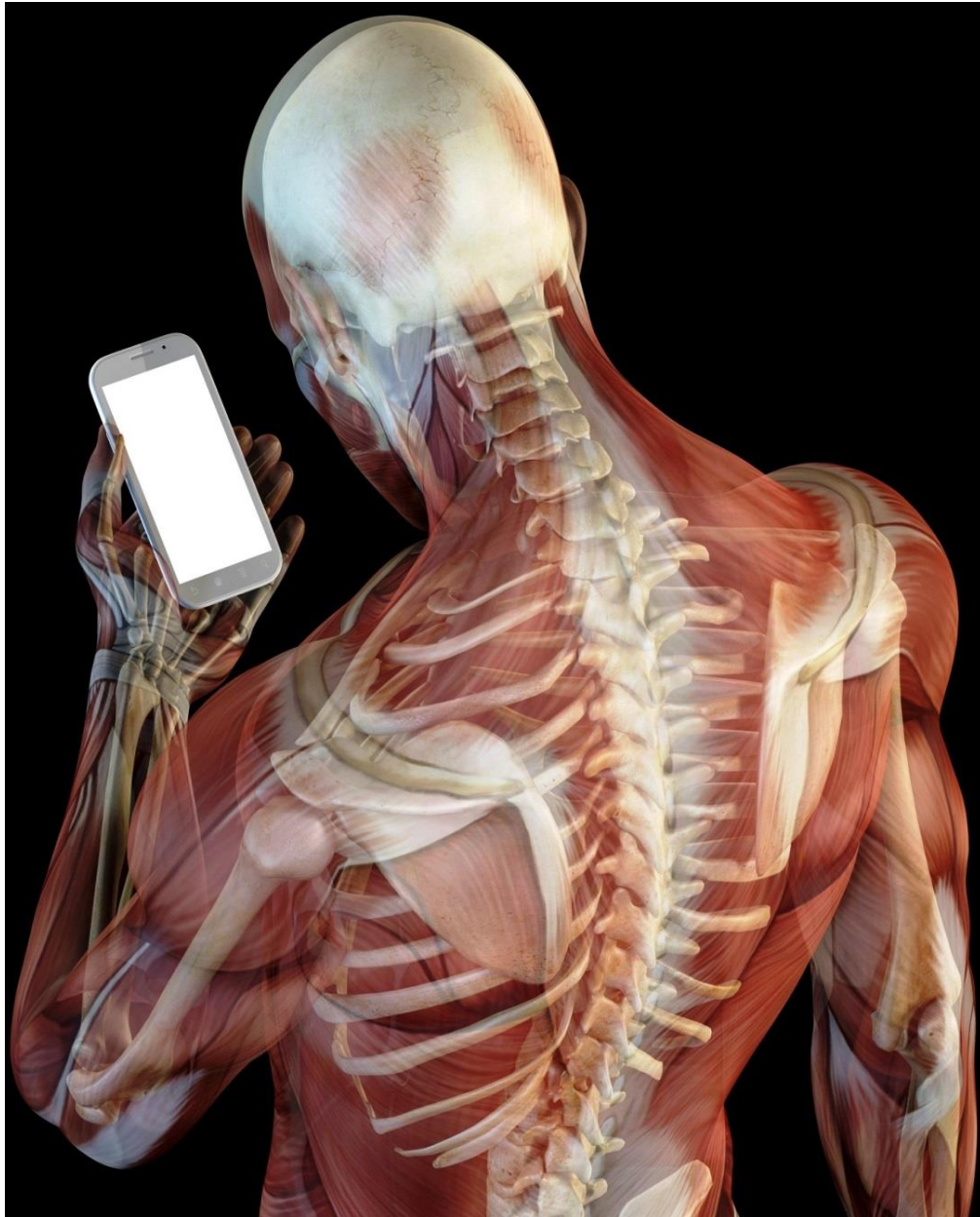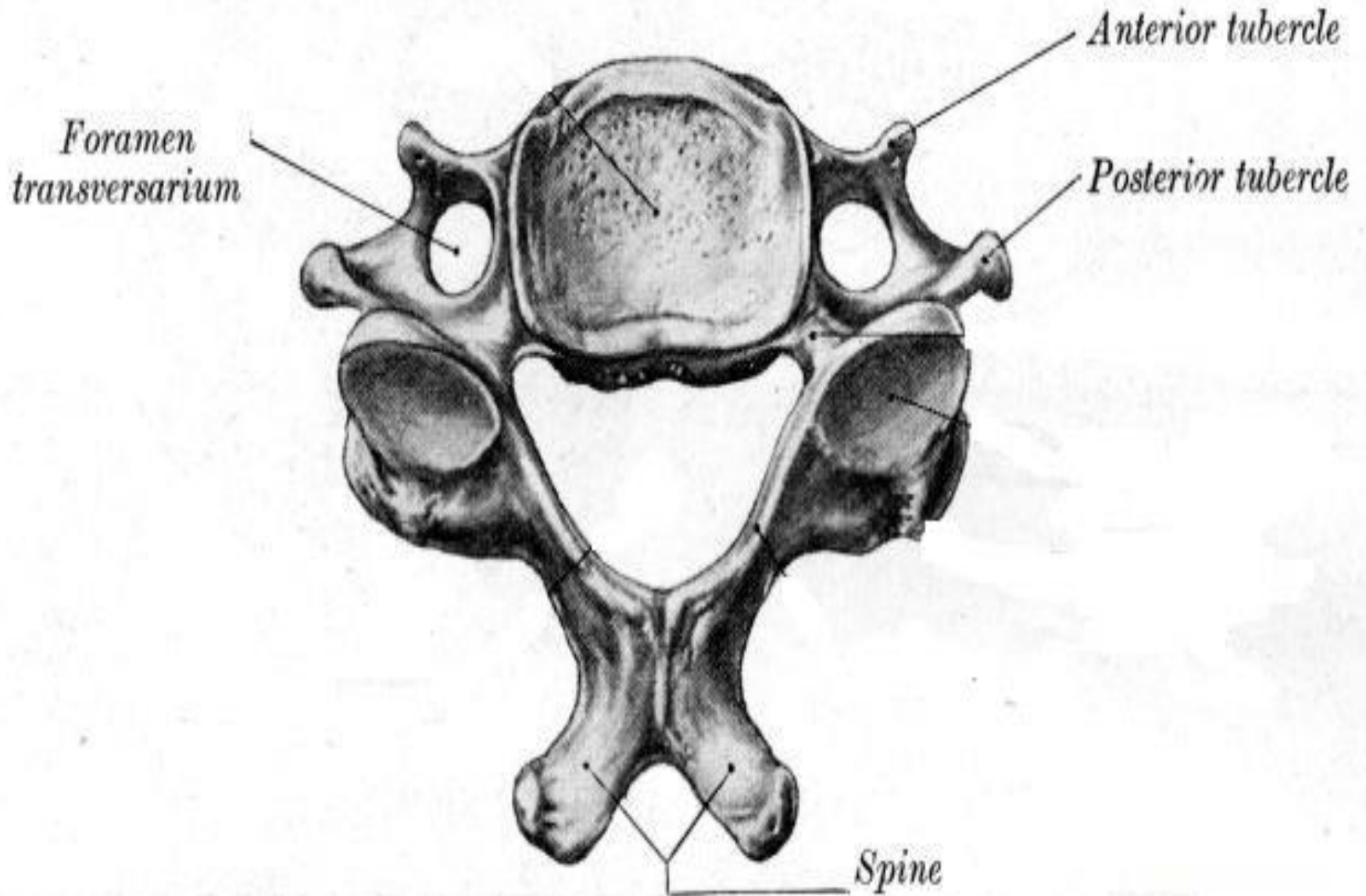


# DEEP MUSCLES OF THE NECK



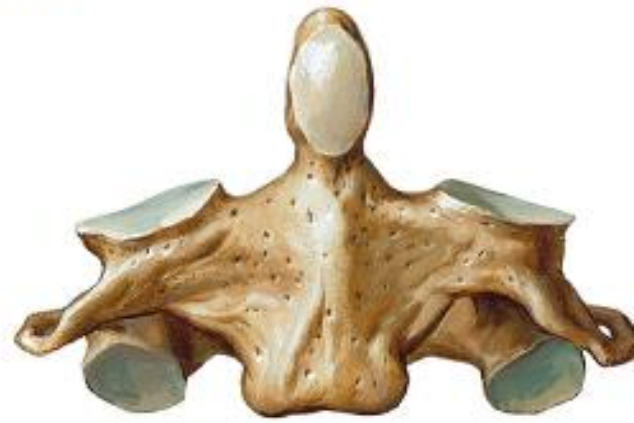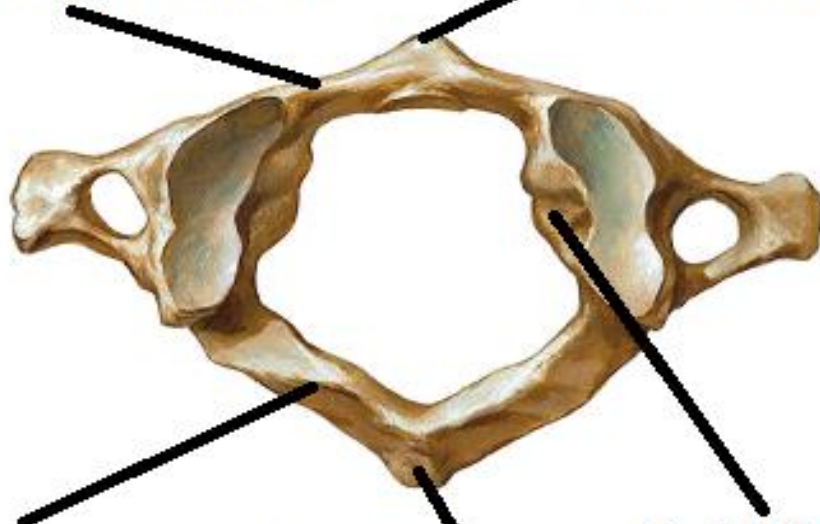
BY  
DR ABULMAATY MOHAMED  
ASSISTANT PROFESSOR  
ANATOMY & EMBRYOLOGY  
MUTAH UNIVERSITY

typical cervical vertebra. Superior aspect.



**ANT.ARCH**

**ANT.TUBERCLE**

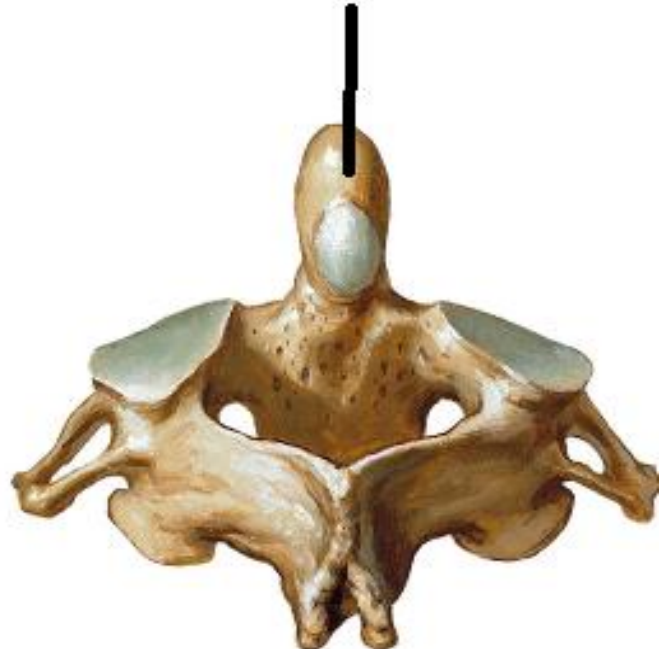
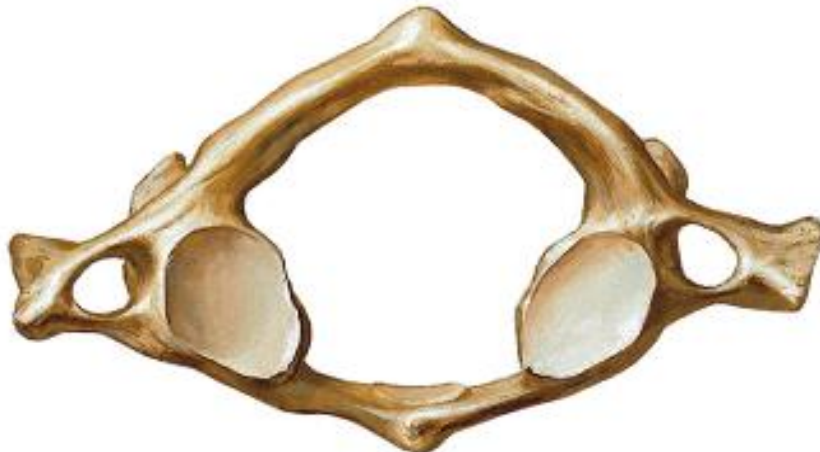
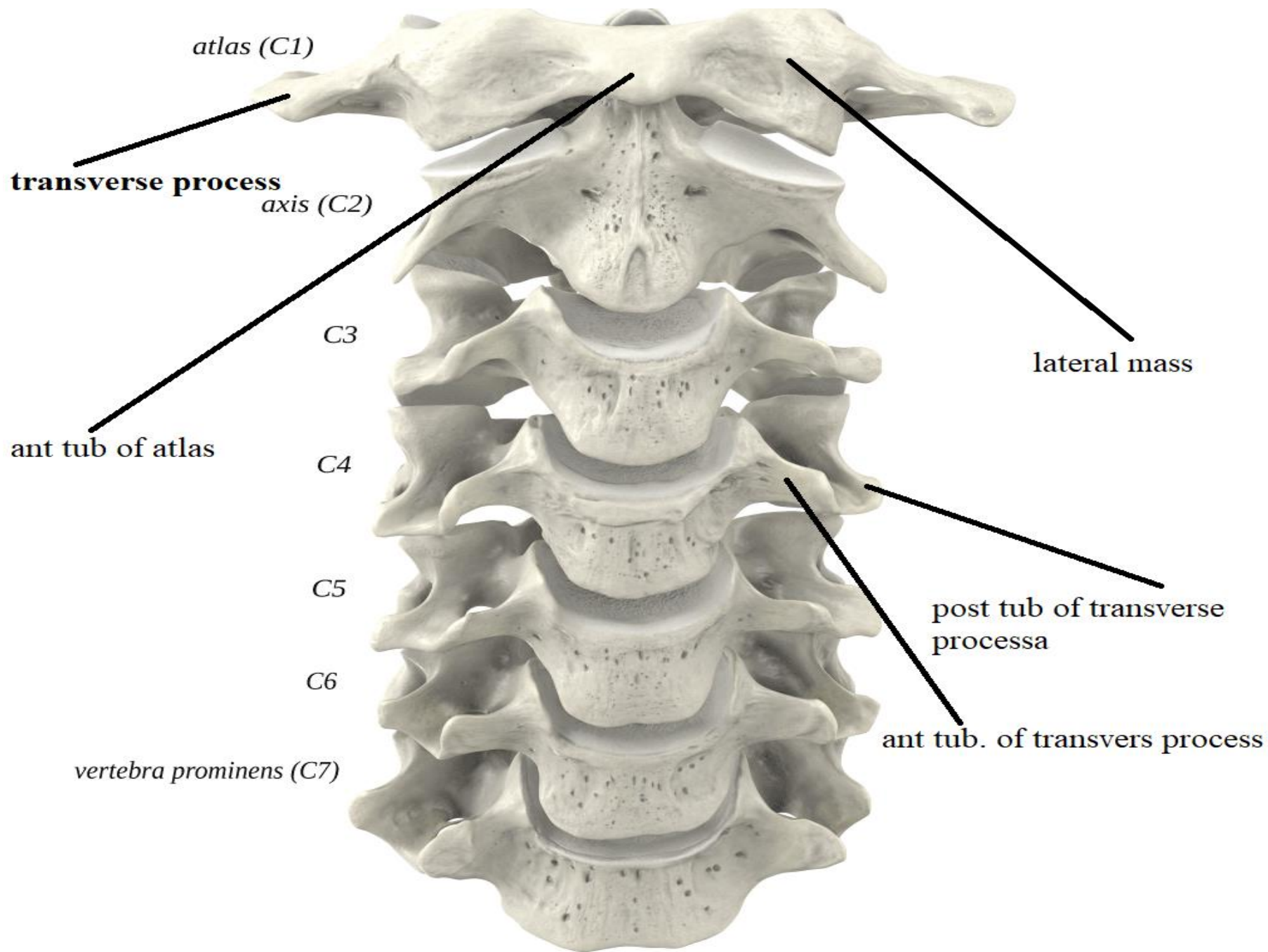
**POST.ARCH**

**LATERAL MASS**

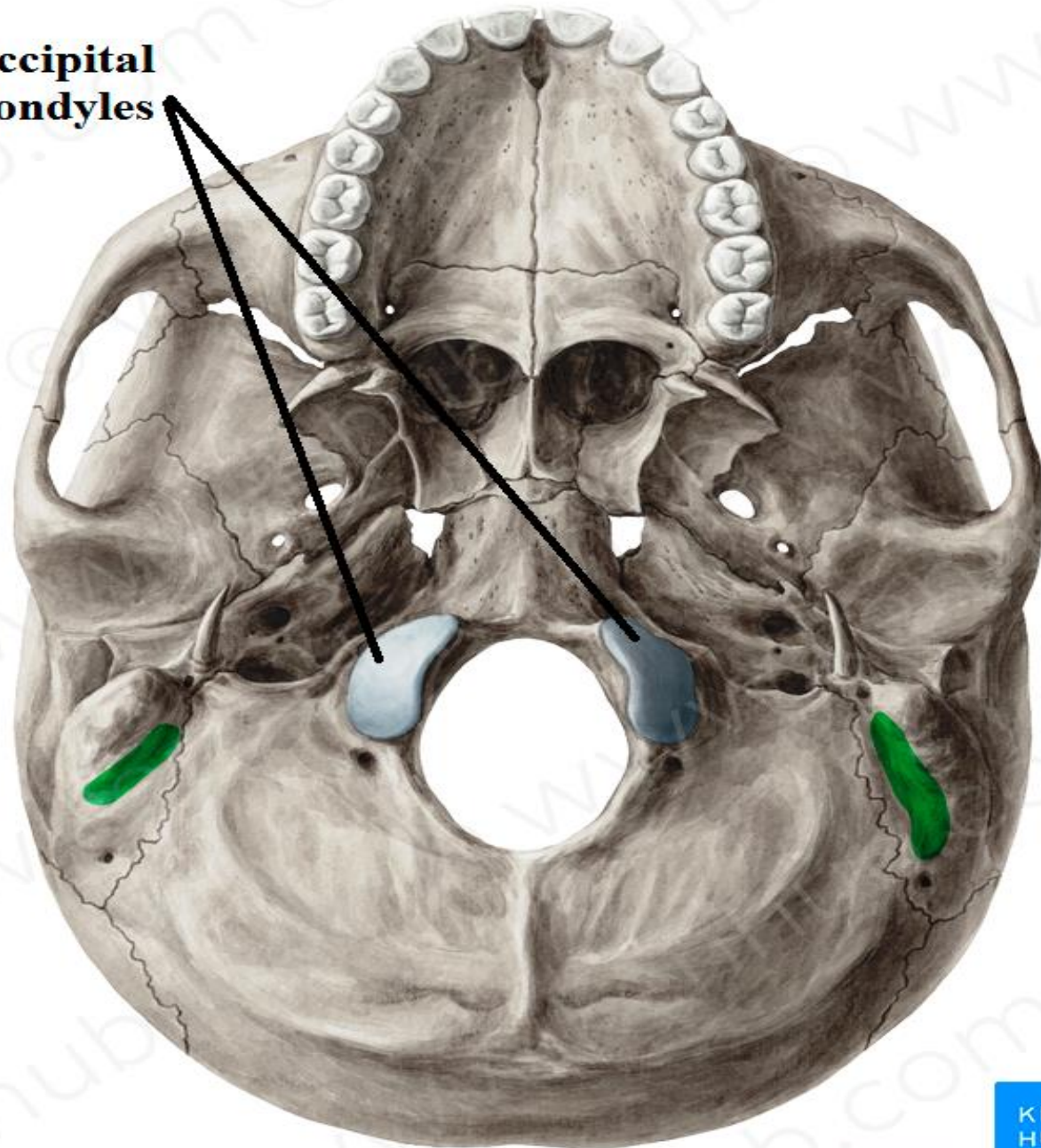
**DENS**

**POST.TUBERCLE**



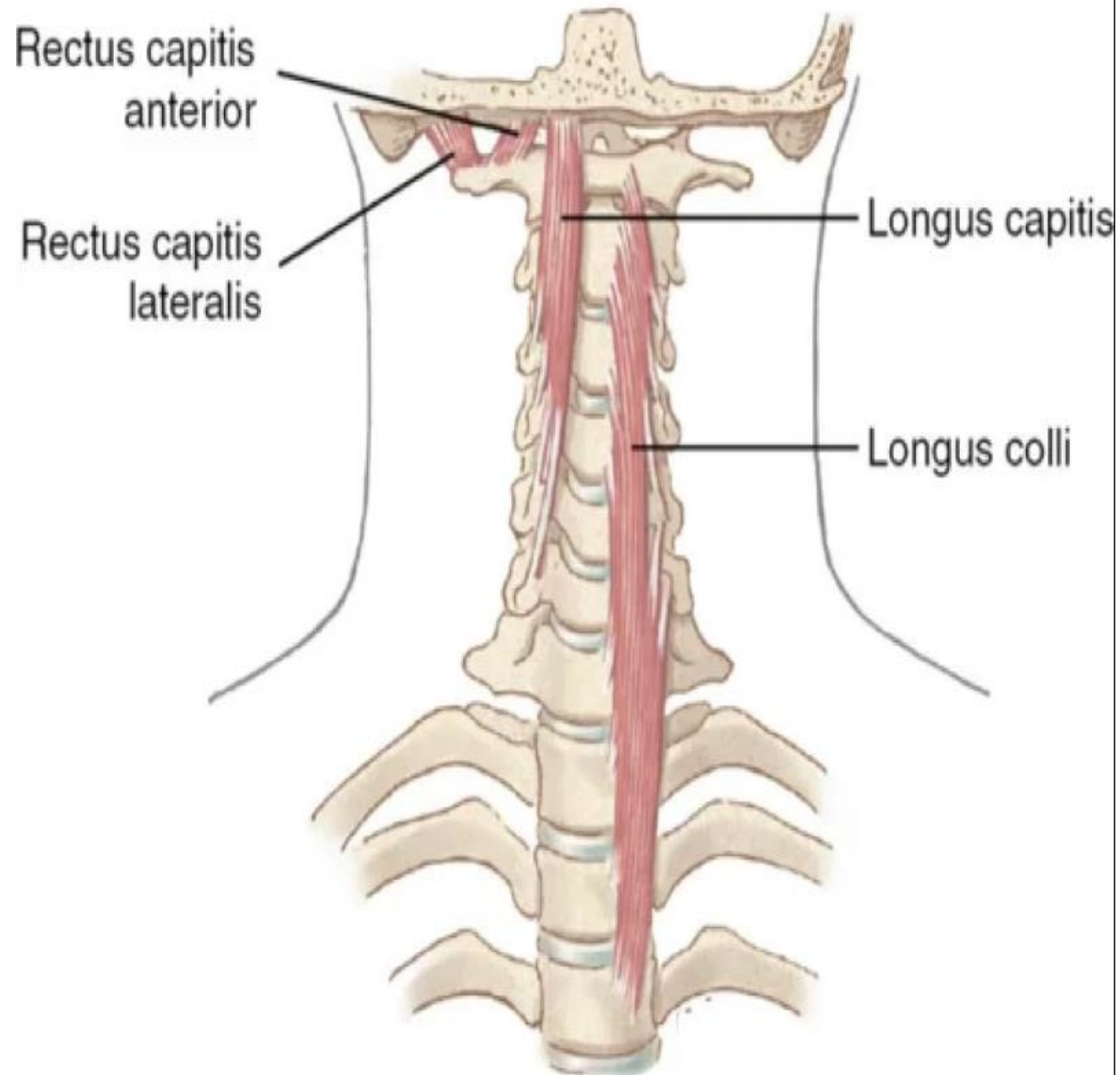


**occipital  
condyles**



# PREVERTEBRAL MUSCLES

- 1- Rectus capitis anterior
- 2- Rectus capitis lateralis
- 3- Longus coli
- 4- Longus capitis



# PREVERTEBRAL MUSCLES

## RECTUS CAPITIS ANTERIOR

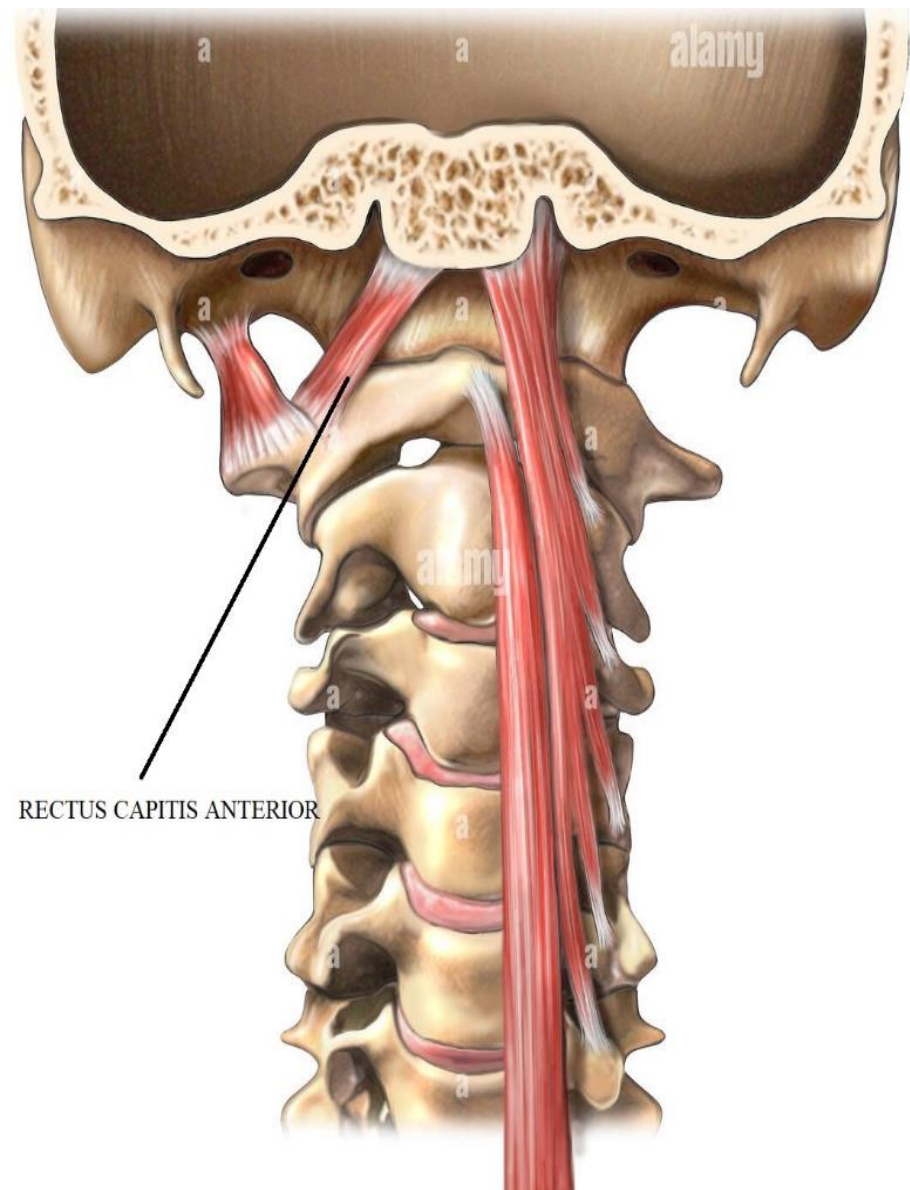
**O.:-** front of lateral mass of atlas

**I.:-** base of skull

ant. to occipital condyle.

**A.:-** flexion of head.

**N.S. :** ventral ramus of C 1 n.



# PREVERTEBRAL MUSCLES

## RECTUS CAPITIS LATERALIS

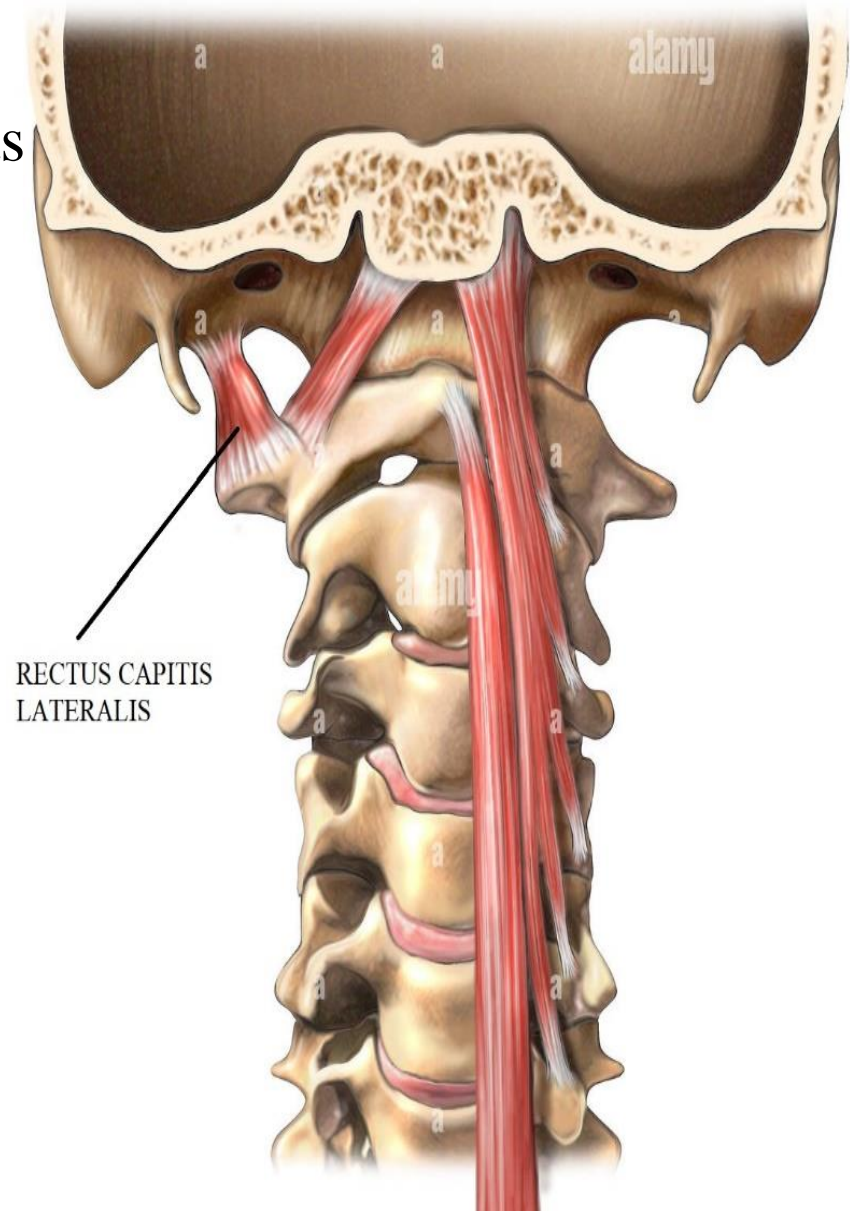
**O.:-** front of transverse Process of atlas

**I. :-** base of skull

lateral to occipital condyle .

**A.:-** lateral flexion of head.

**N.S.:-** ventral ramus of C 1 n.





# PREVERTEBRAL MUSCLES

## LONGUS COLLI (CERVICIS)

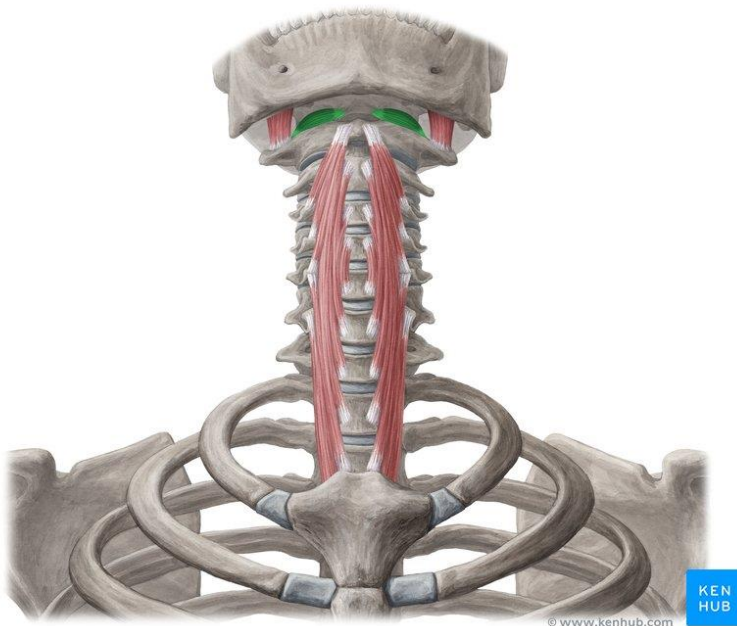
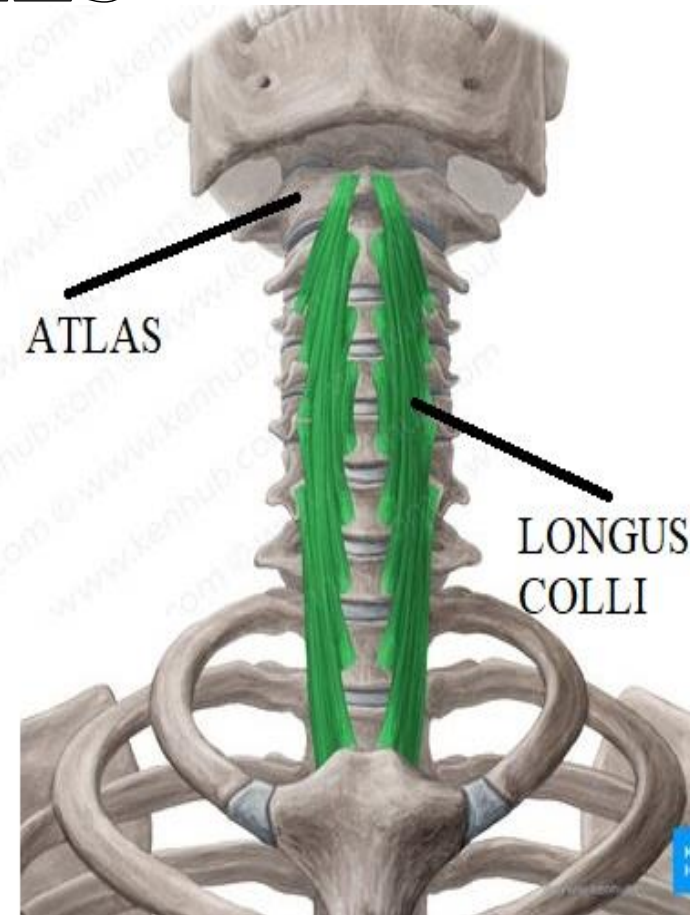
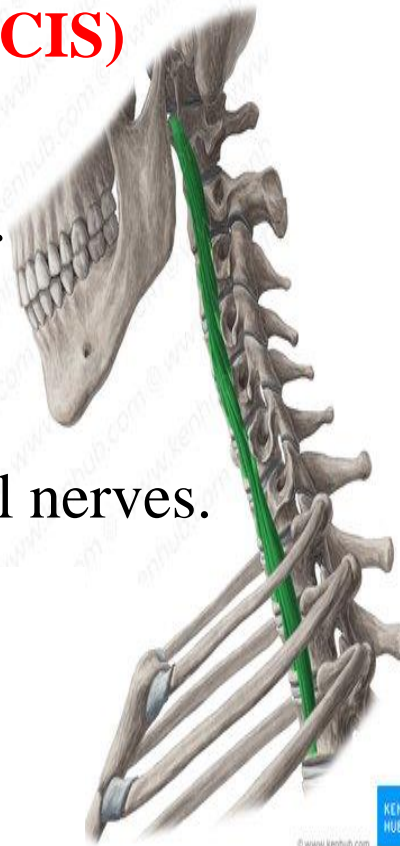
### EXTENT:-

**From:-** 3rd thoracic vertebra.

**To:-** ant. tubercle of atlas.

**A.:-** flexion of neck.

**N.S.:** ventral rami of cervical nerves.



# PREVERTEBRAL MUSCLES

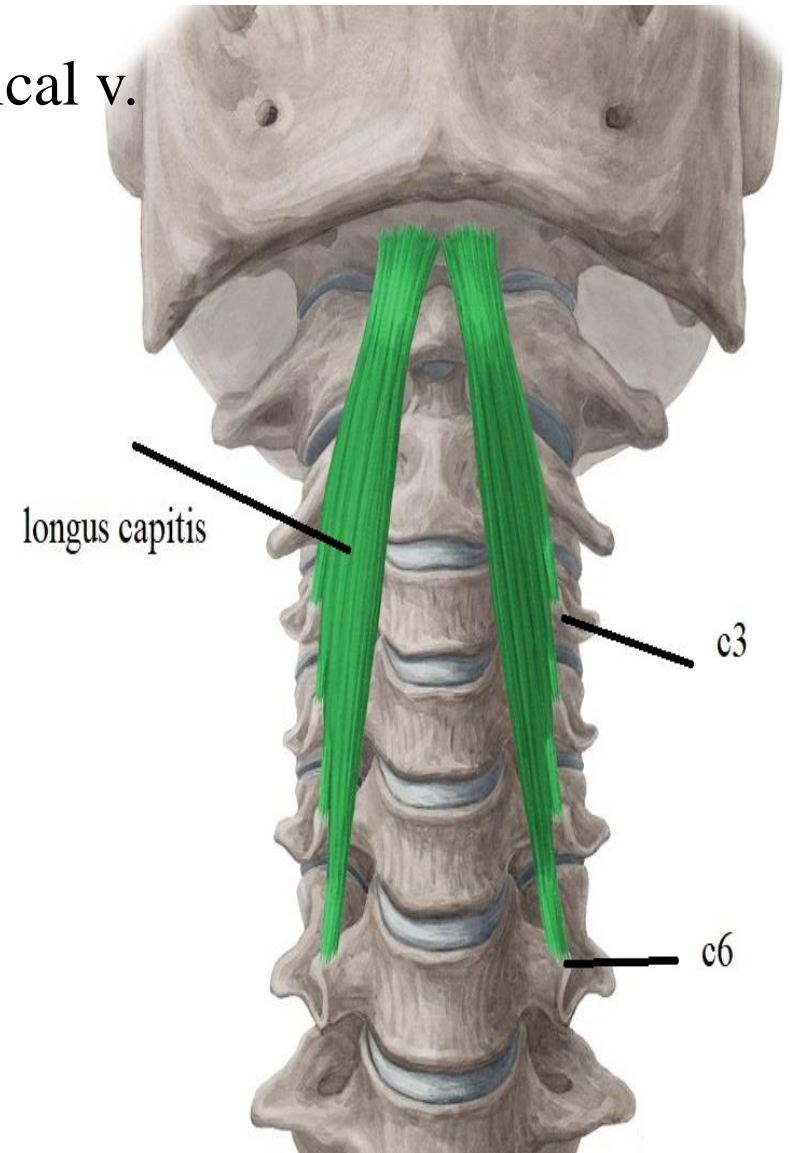
## LONGUS CAPITIS

**O.:-** transverse Processes of typical cervical v.

**I.:-** basilar part of occipital bone

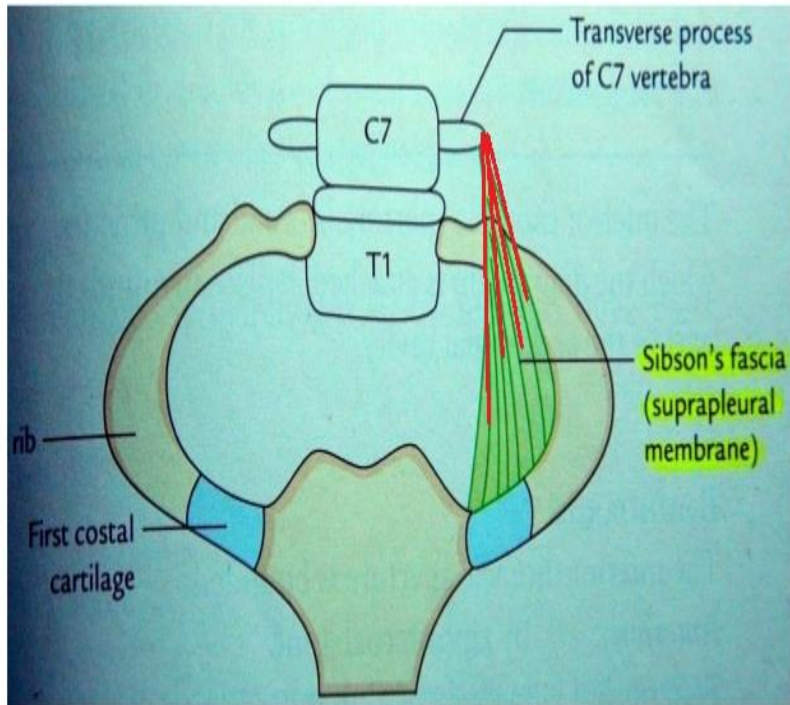
**A.:-** flexion of head

**N.S.:-** ventral rami of cervical nerves

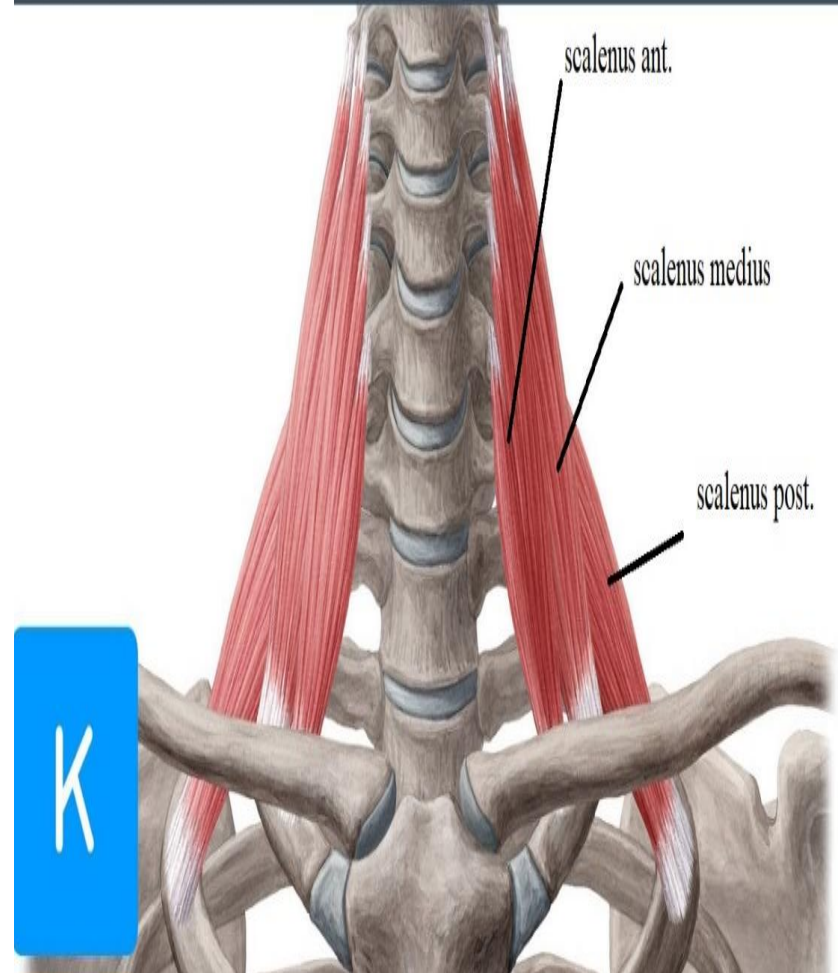


# PARAVERTEBRAL MUSCLES

- 1- Scalenus minimus
- 2- Scalenus anterior
- 3- Scalenus medius
- 4- Scalenus posterior



## Scalene muscles



# PARAVERTEBRAL MUSCLES

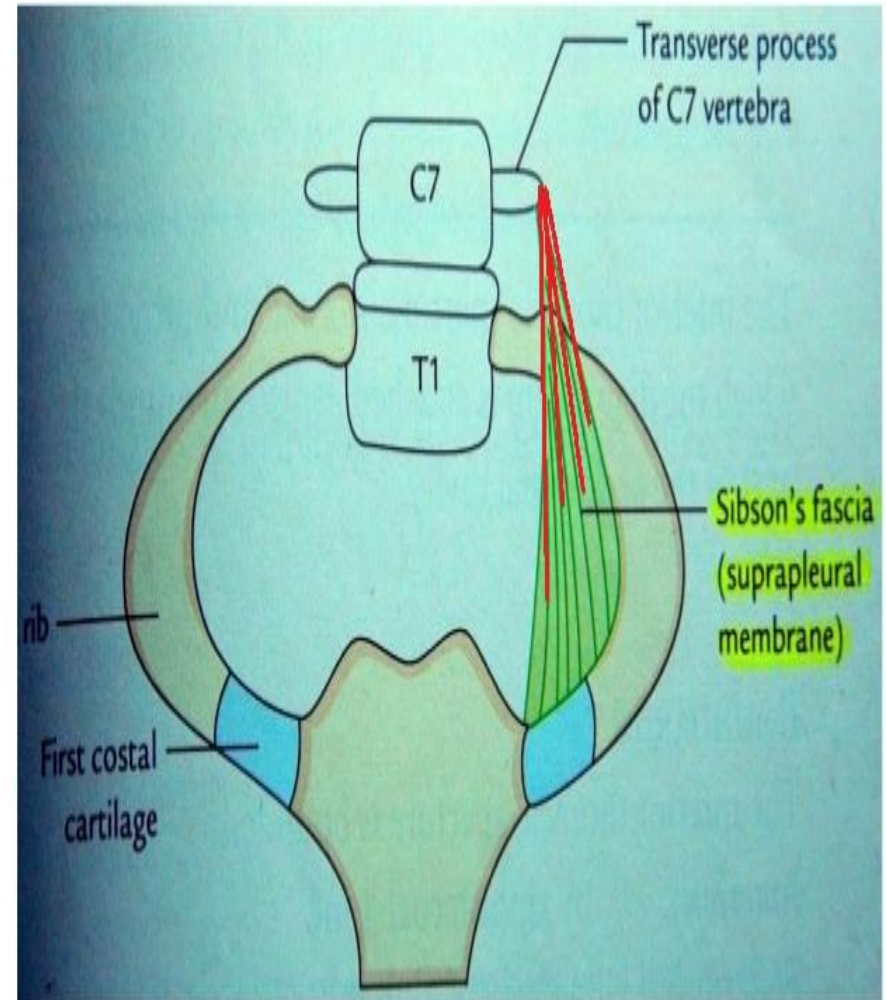
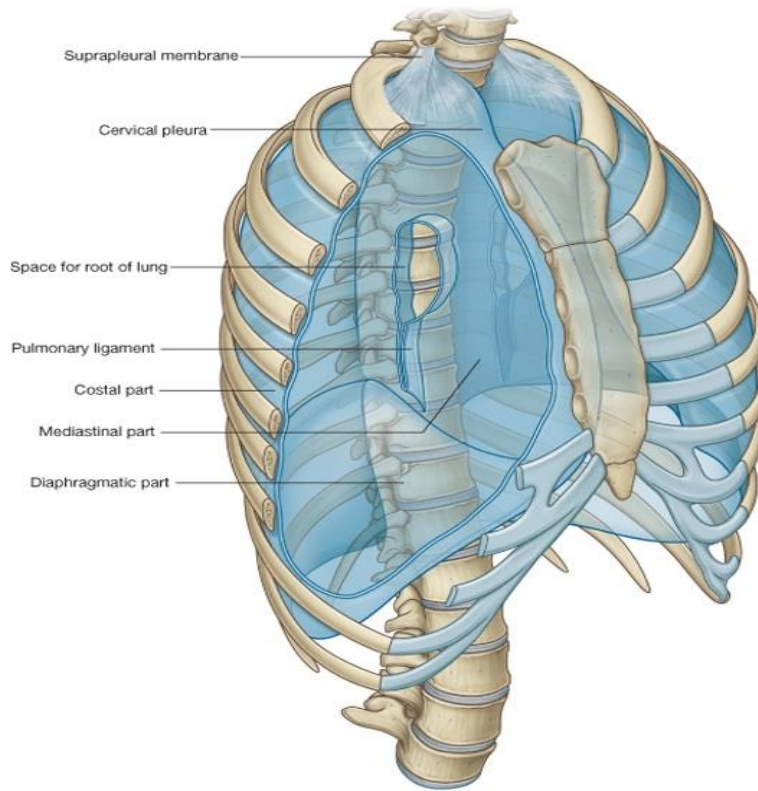
## SCALENUS MINIMUS (PLEURALIS)

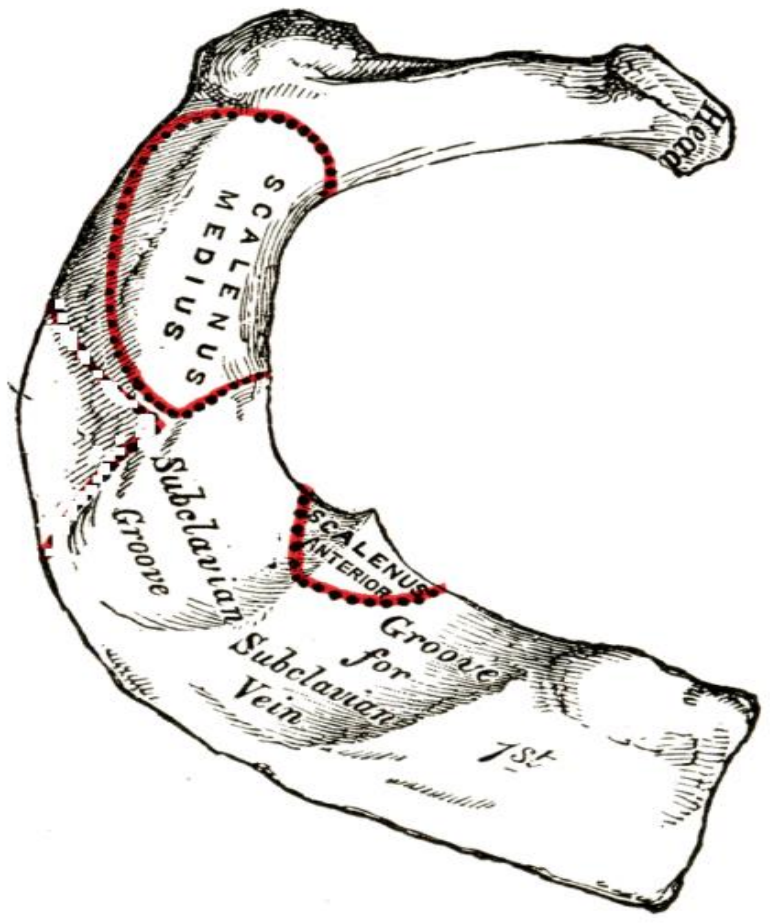
**O.:-** tip of tr. process of C 7 vertebra

**I.:-** suprapleural membrane

**A.:-** tense the suprapleural membrane

**N.S.:-** ventral ramus of C 7 n.





# PARAVERTEBRAL MUSCLES

## SCALENUS ANTERIOR

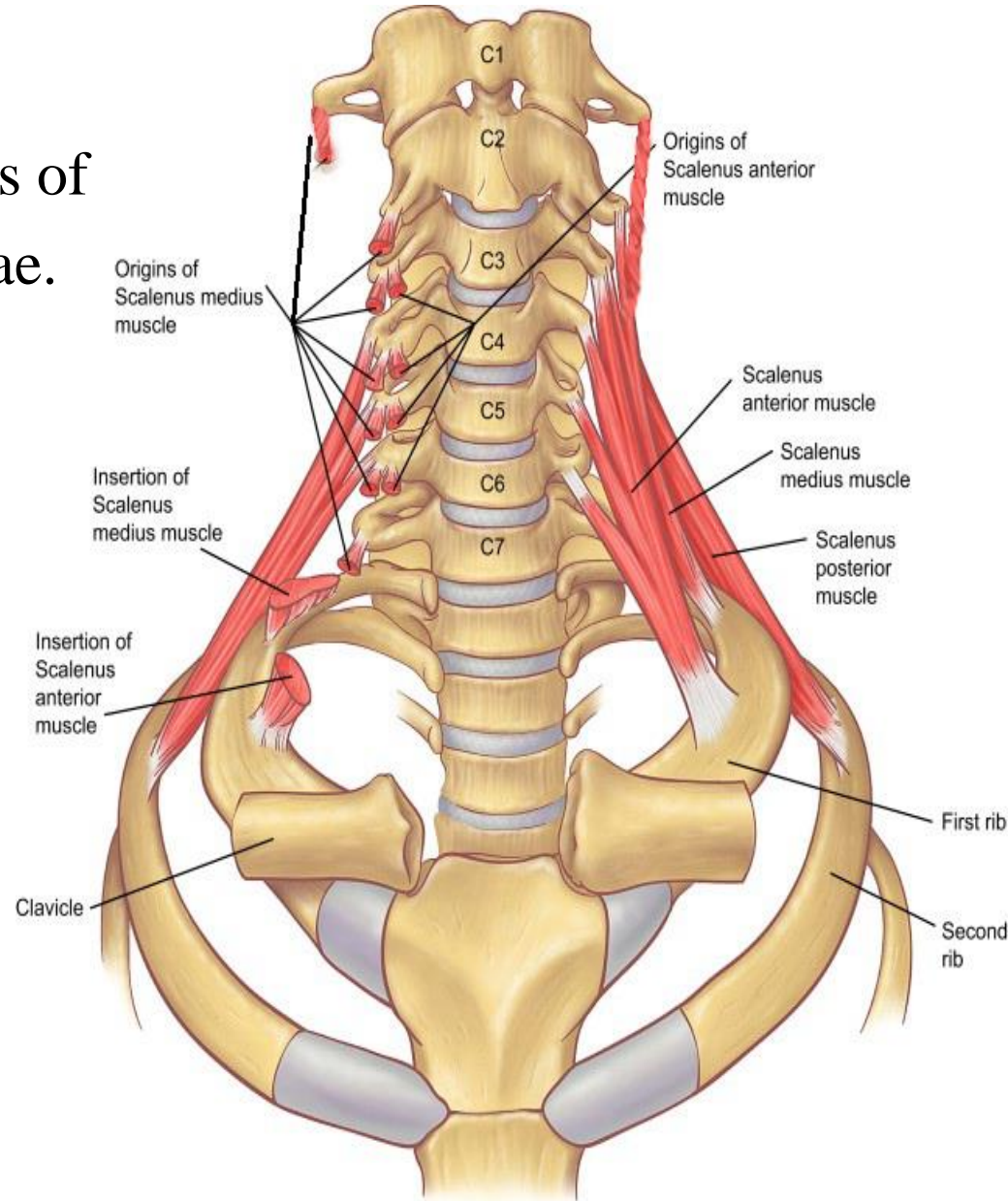
**O.:-** ant. tubercle of tr. Processes of  
3, 4, 5, 6 cervical vertebrae.

**I.:-** scalene tubercle of 1st rib

**A.:-** lateral flexion of neck.

elevation of 1st rib  
in forced inspiration.

**N.S.:-** ventral rami of 4, 5, 6, 7  
cervical nerves.



# PARAVERTEBRAL MUSCLES

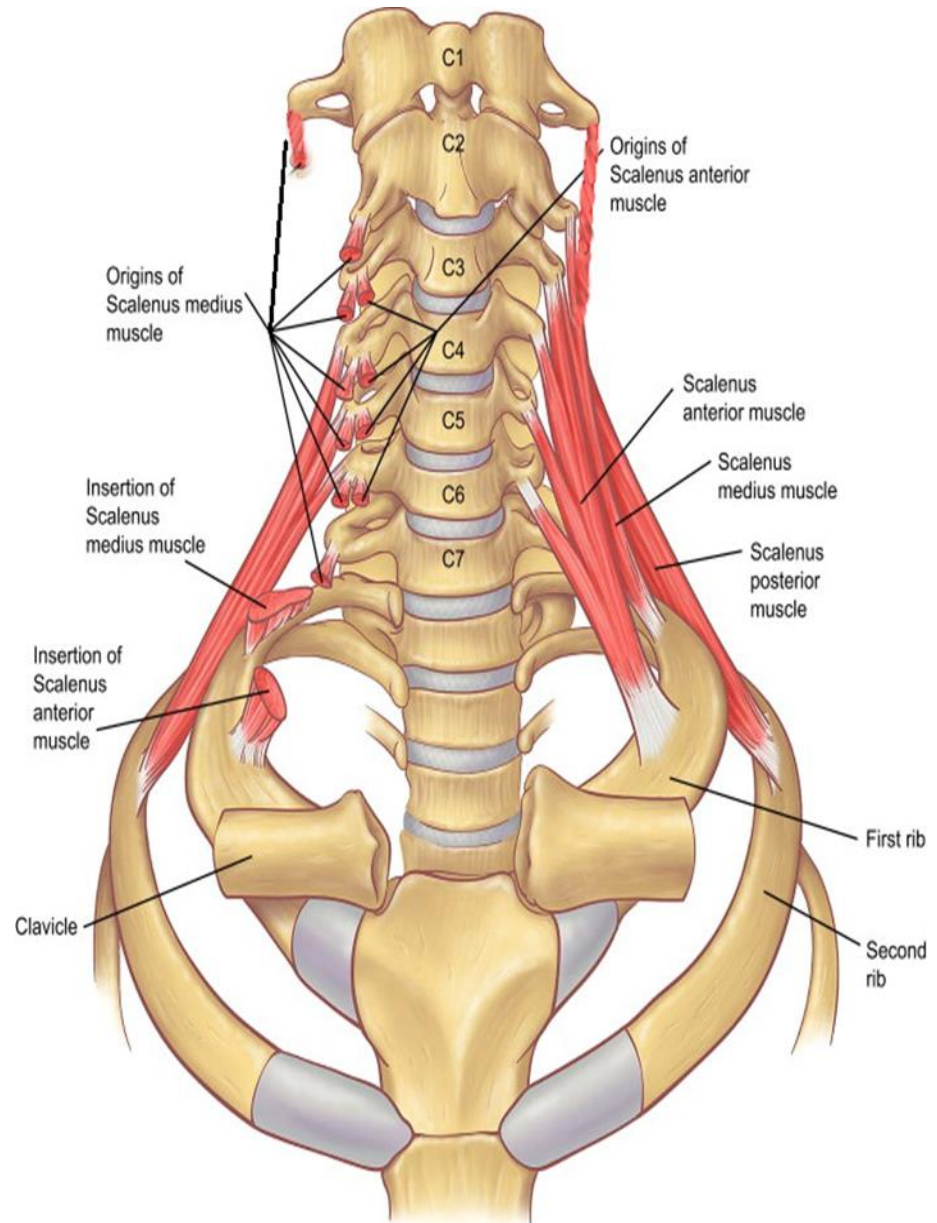
## SCALENUS MEDIUS:

**O.:-** post. tubercle of tr.  
Processes of all cervical vertebrae.

**I.:-** upper surface of 1st rib

**A.:-** lateral flexion of neck.  
elevation of 1st rib  
in forced inspiration.

**N.S.:-** ventral rami of all cervical  
nerves.



# PARAVERTEBRAL MUSCLES

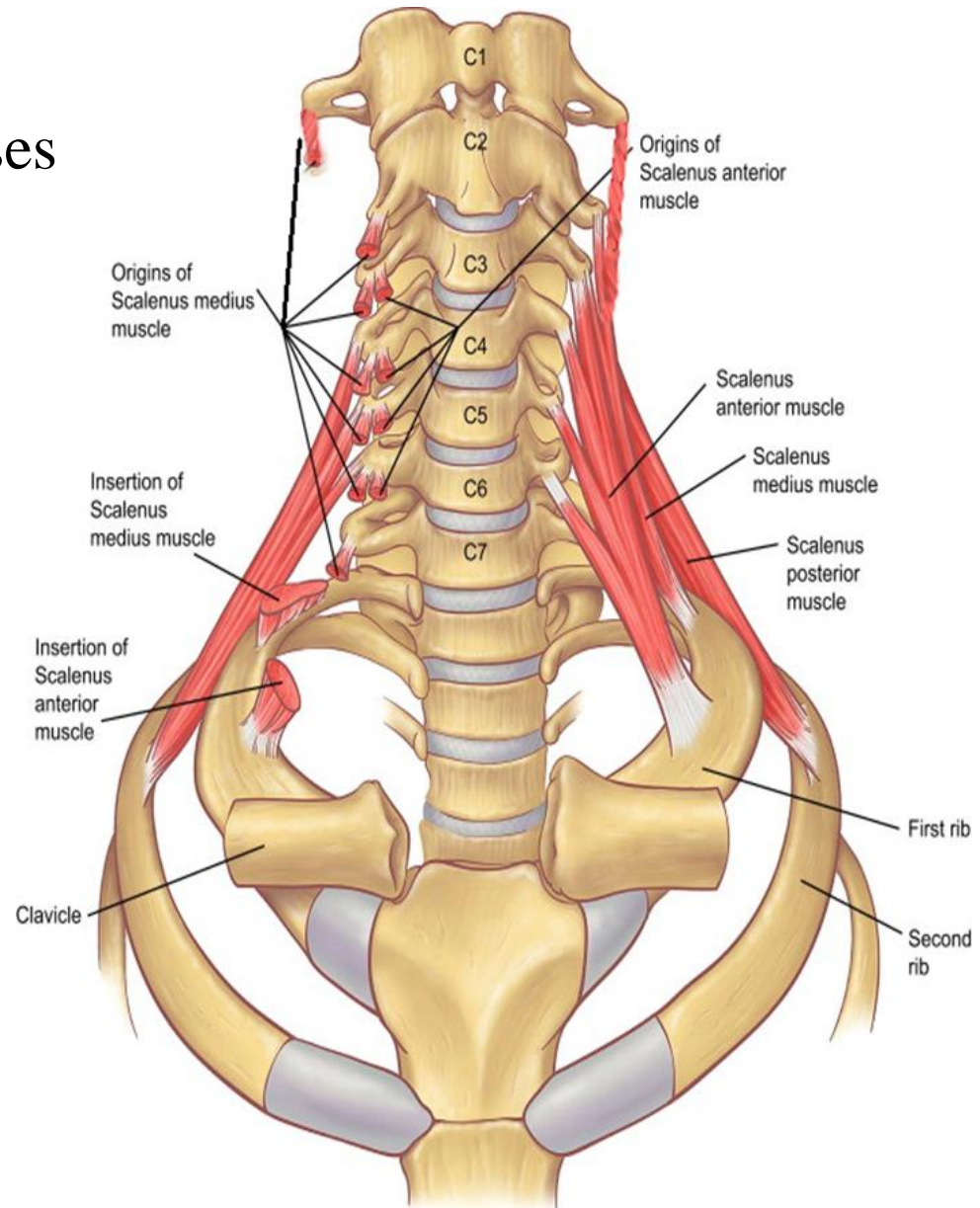
## SCALENUS POSTERIOR:

**O.:-** post. tubercle of tr. Processes of 4, 5, 6 cervical vertebrae.

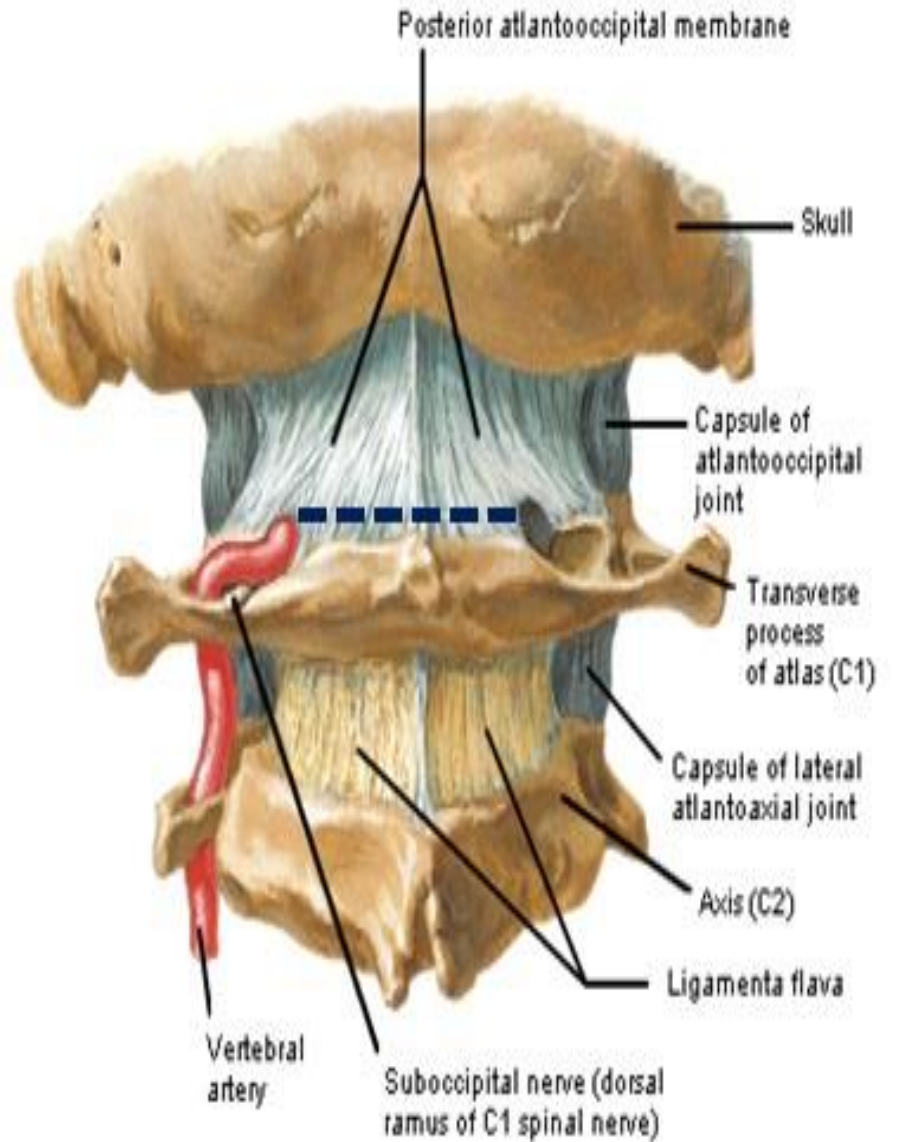
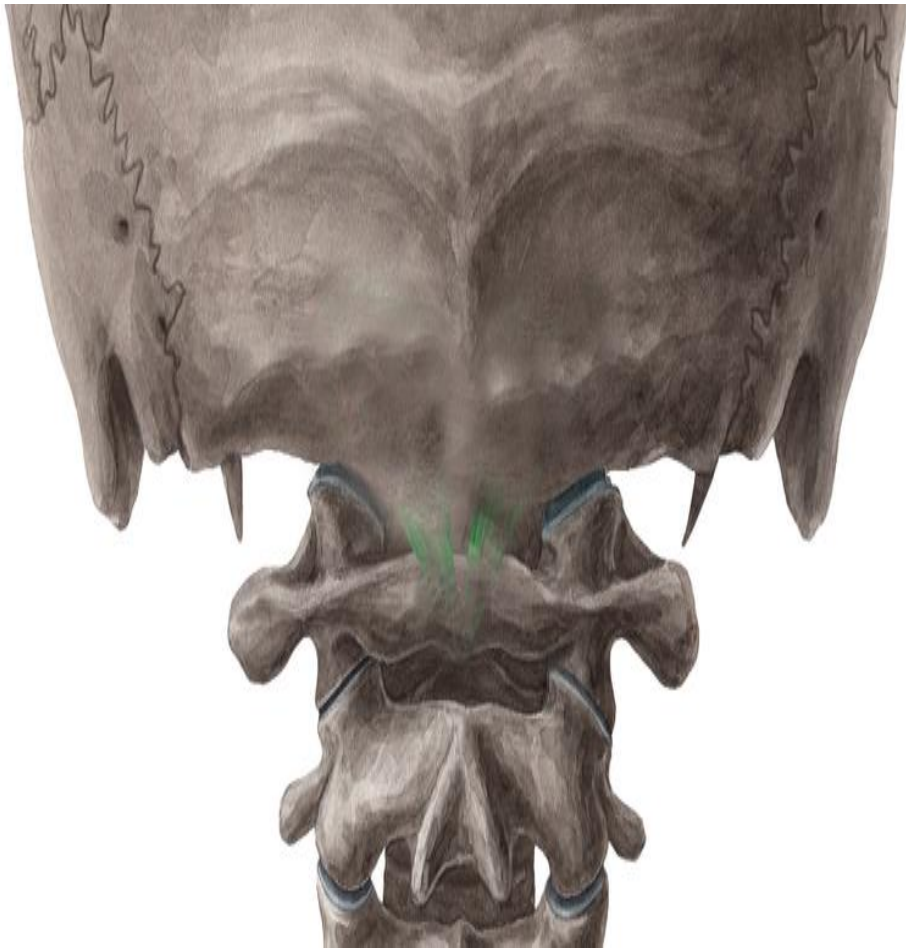**I. -:** 2nd rib.

**A.:-** lateral flexion of neck.  
elevation of 2nd rib  
in forced inspiration.

**N.S.:-** ventral rami of C 5, 6 , 7  
nerves.

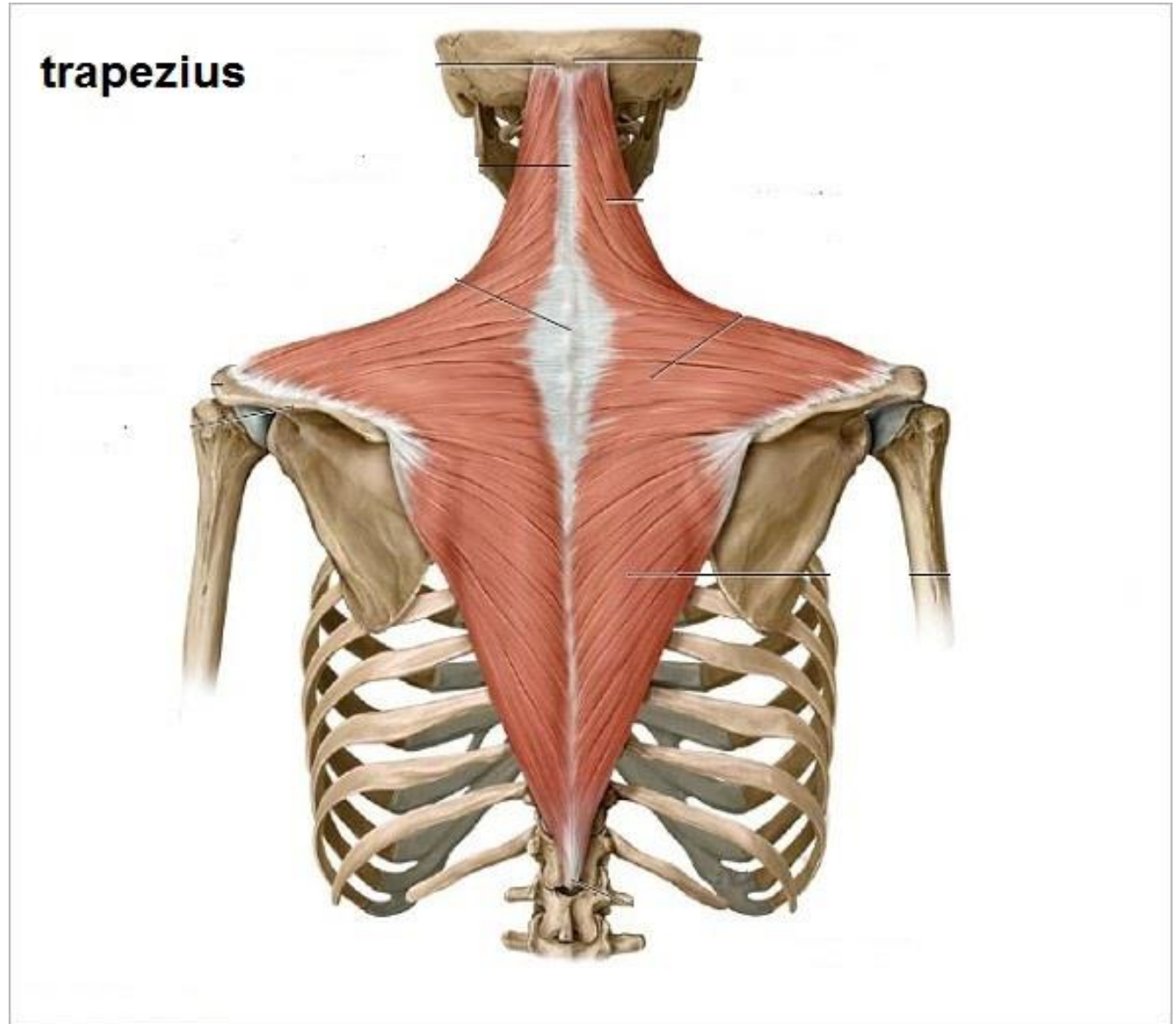






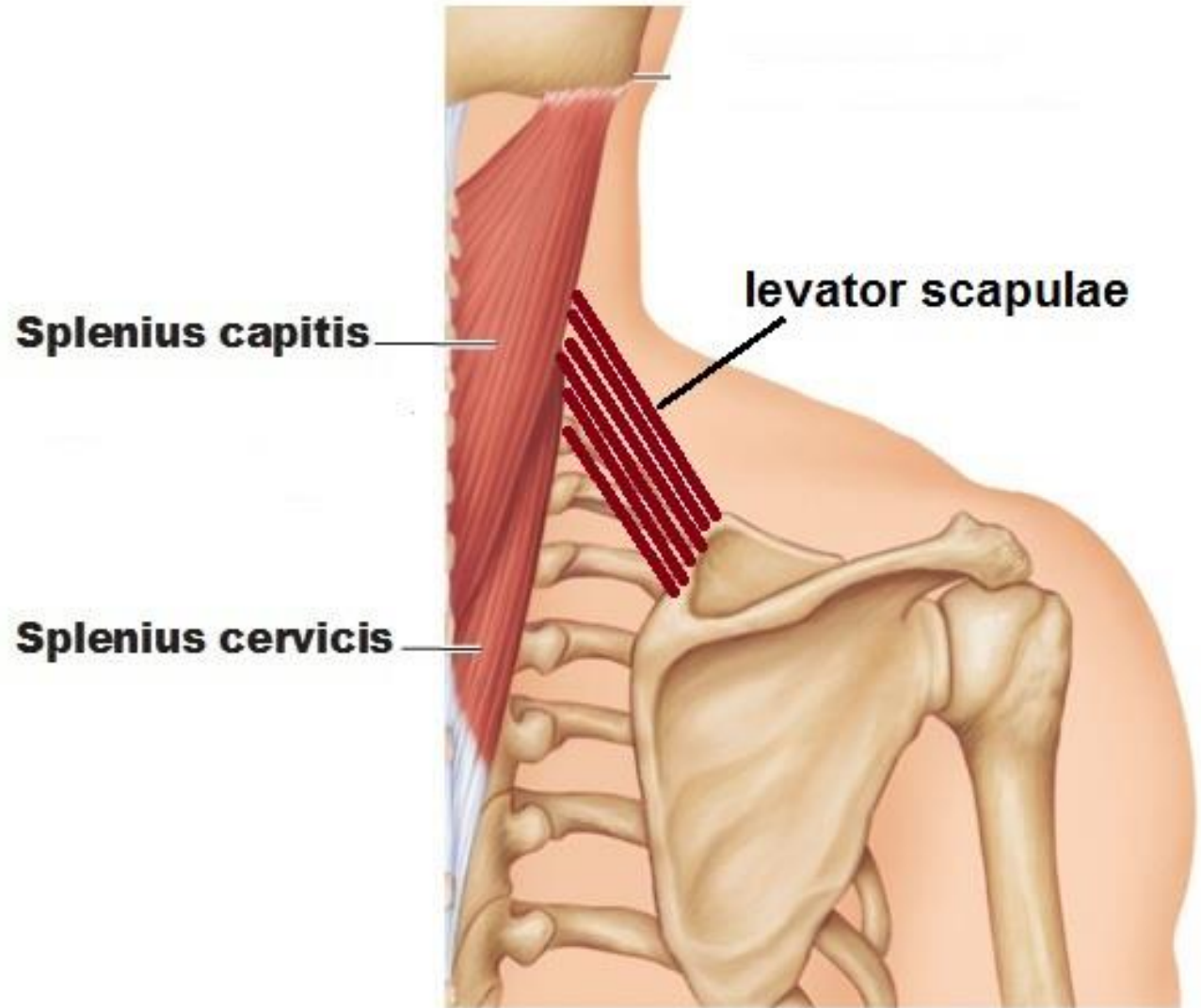
# POSTVERTEBRAL MUSCLES

1<sup>ST</sup> LAYER



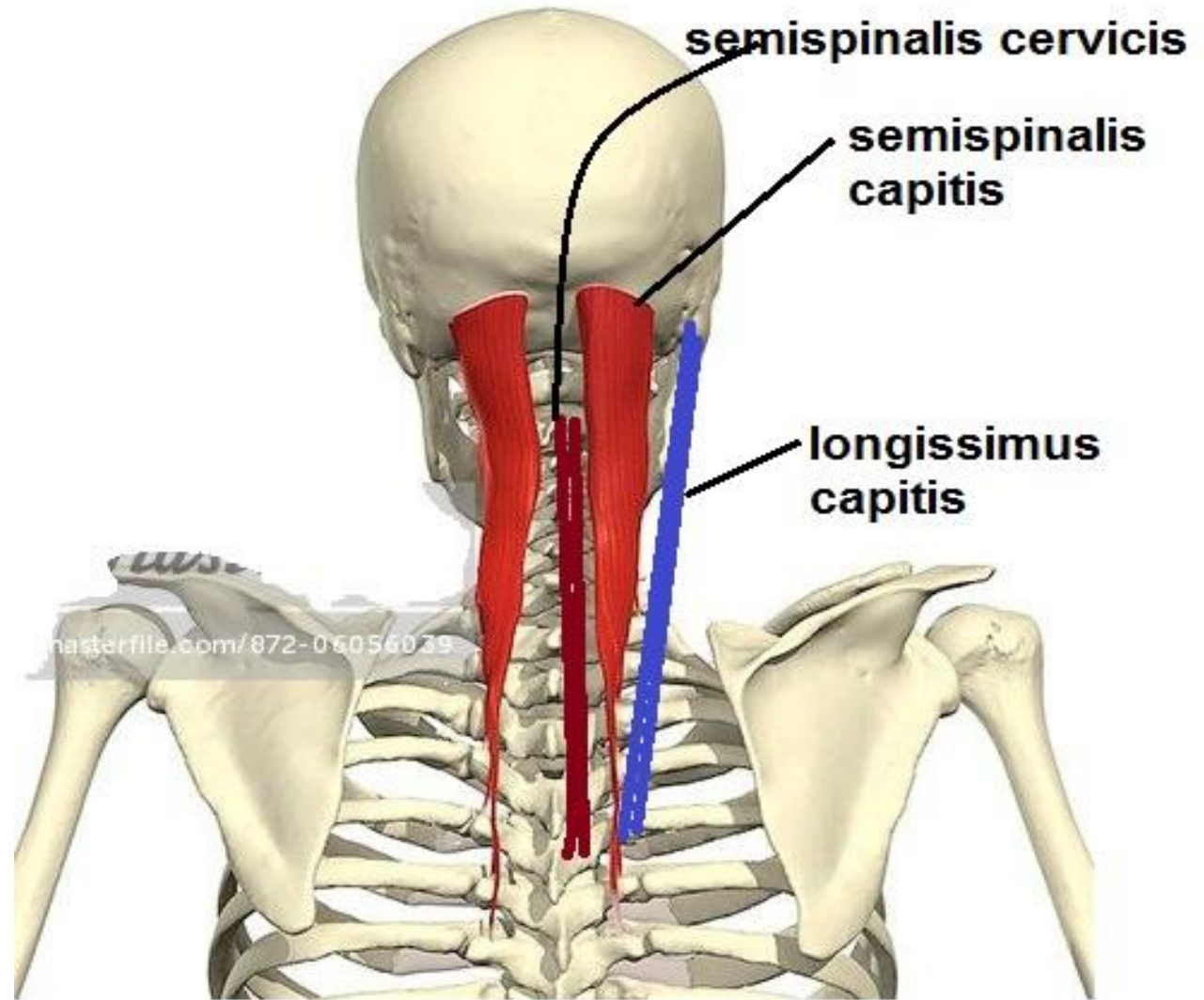
# POSTVERTEBRAL MUSCLES

2<sup>ND</sup> LAYER



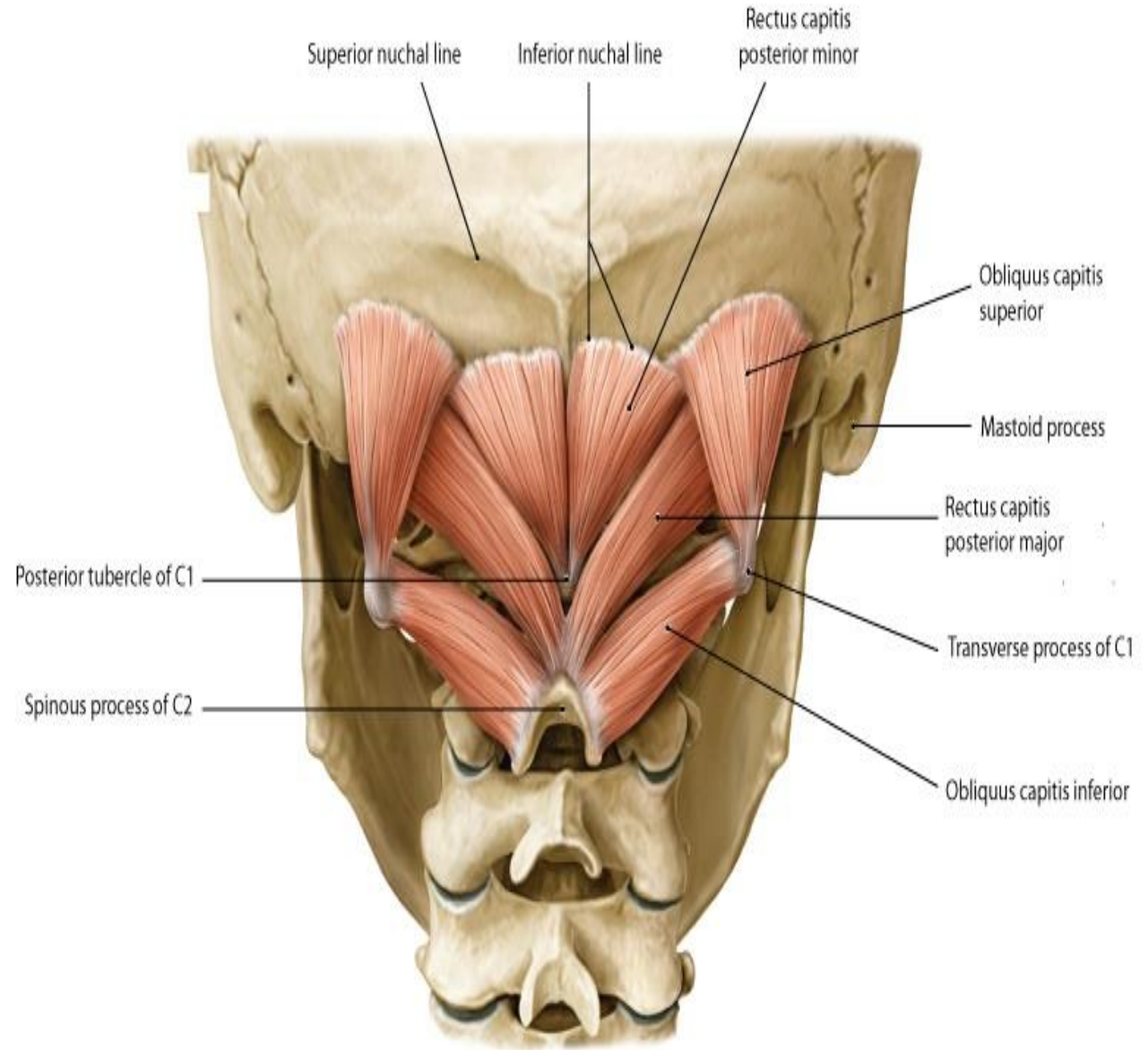
# POSTVERTEBRAL MUSCLES

3<sup>RD</sup> LAYER



# POSTVERTEBRAL MUSCLES

## 4<sup>TH</sup> LAYER (SUBOCCIPITAL MUSCLES)



# POSTVERTEBRAL MUSCLES

## RECTUS CAPITIS POSTERIOR MINOR

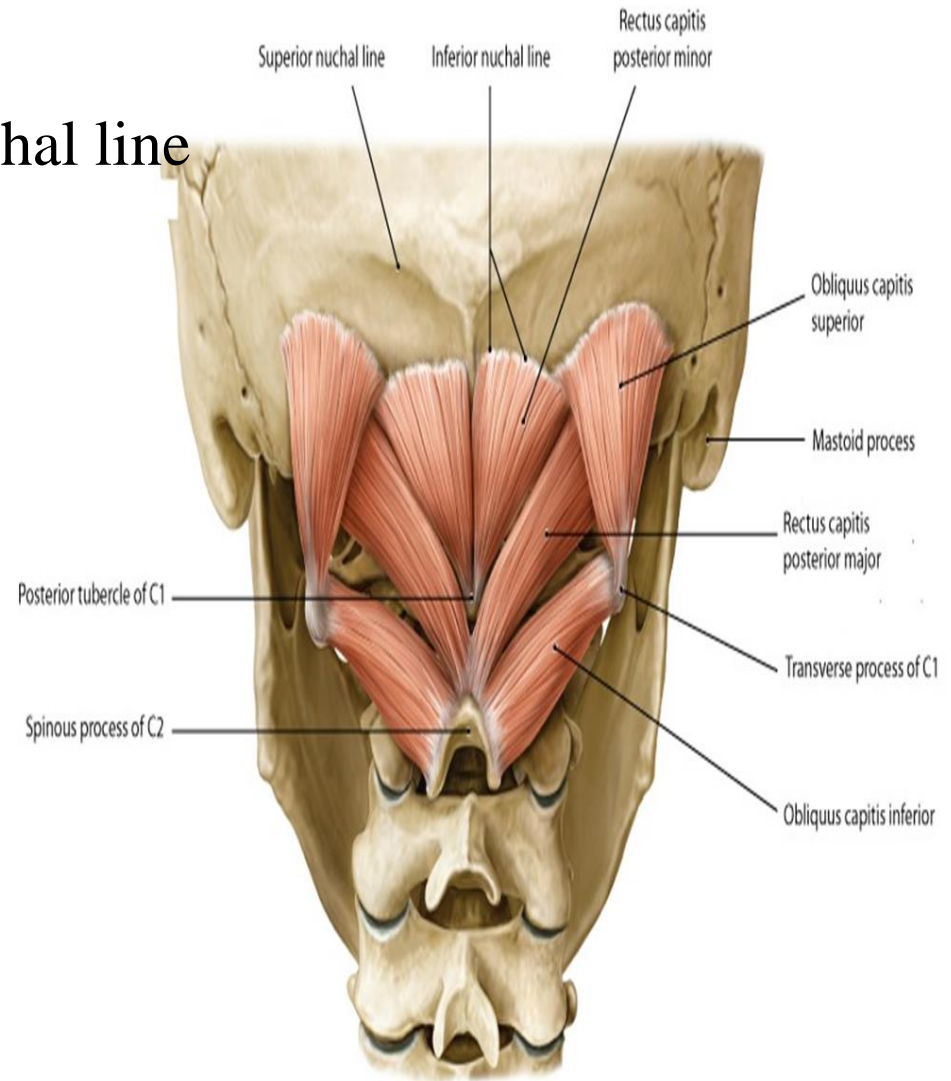
**O.:**-Posterior tubercle of C1

**I.:**- Medial area below inferior nuchal line

**A.** Extends head

**N.S.:**- Suboccipital n.

(dorsal ramus of C1 n.)



# POSTVERTEBRAL MUSCLES

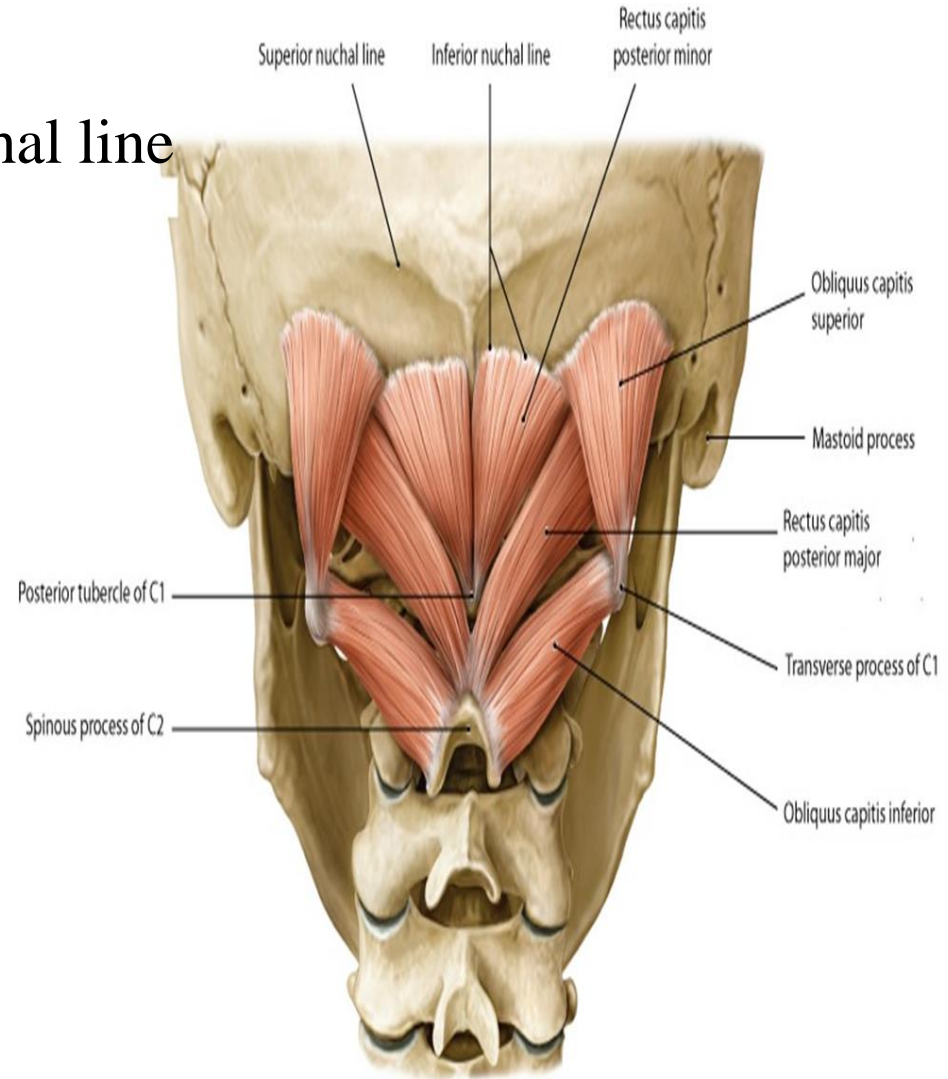
## RECTUS CAPITIS POSTERIOR MAJOR

**O.:-** Spine of C2

**I.:-** Lateral area below inferior nuchal line

**A.** extends head  
turns face to same side

**N.S.:-** Suboccipital n.  
(dorsal ramus of C1 n.)



# POSTVERTEBRAL MUSCLES

## INFERIOR OBLIQUE

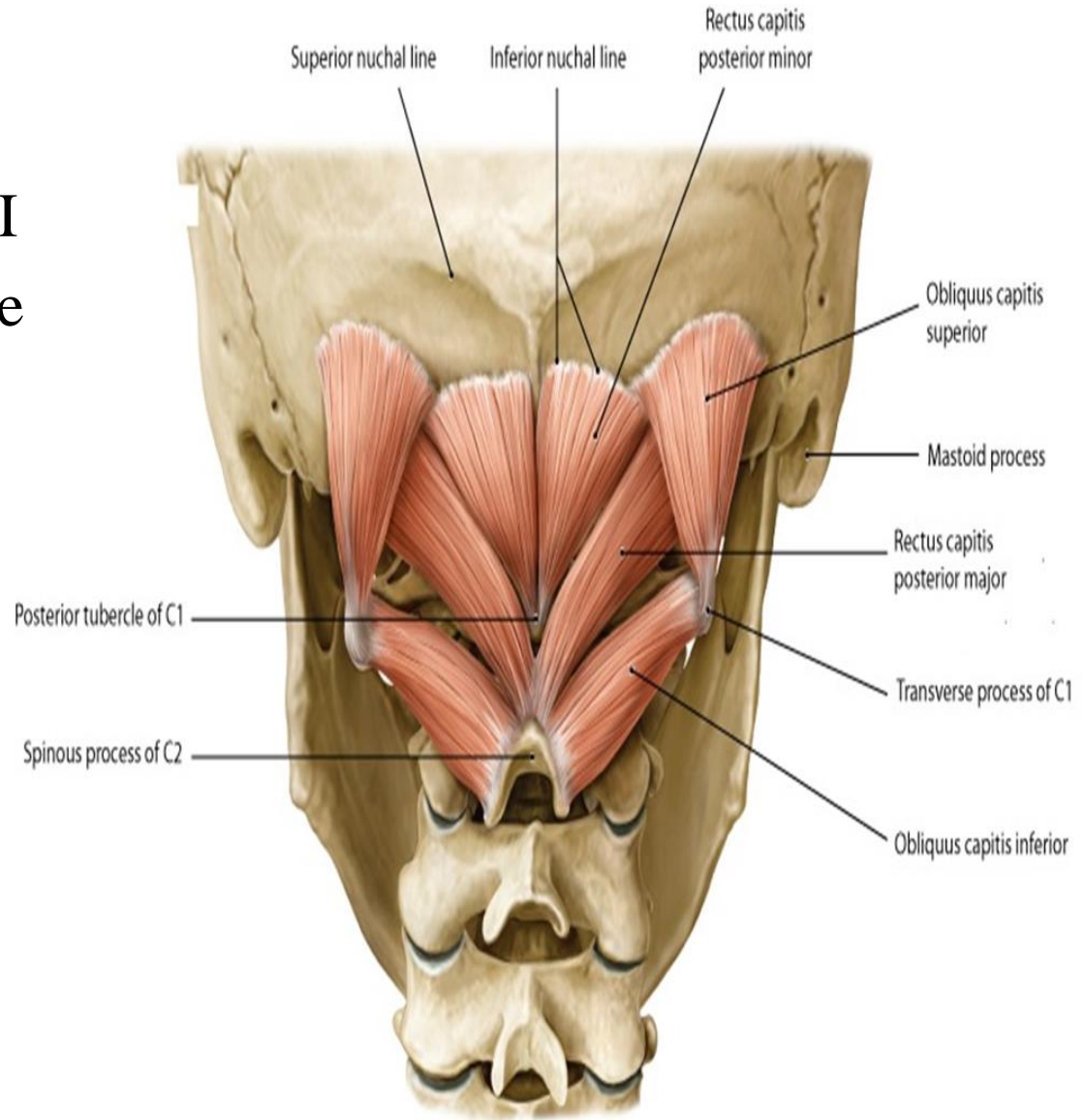
**O.:-** Spine of C2

**I.:-** Transverse process of C1

**A.** Turns face to same side

**N.S.:-** Suboccipital n.

(dorsal ramus of C1 n.)





# POSTVERTEBRAL MUSCLES

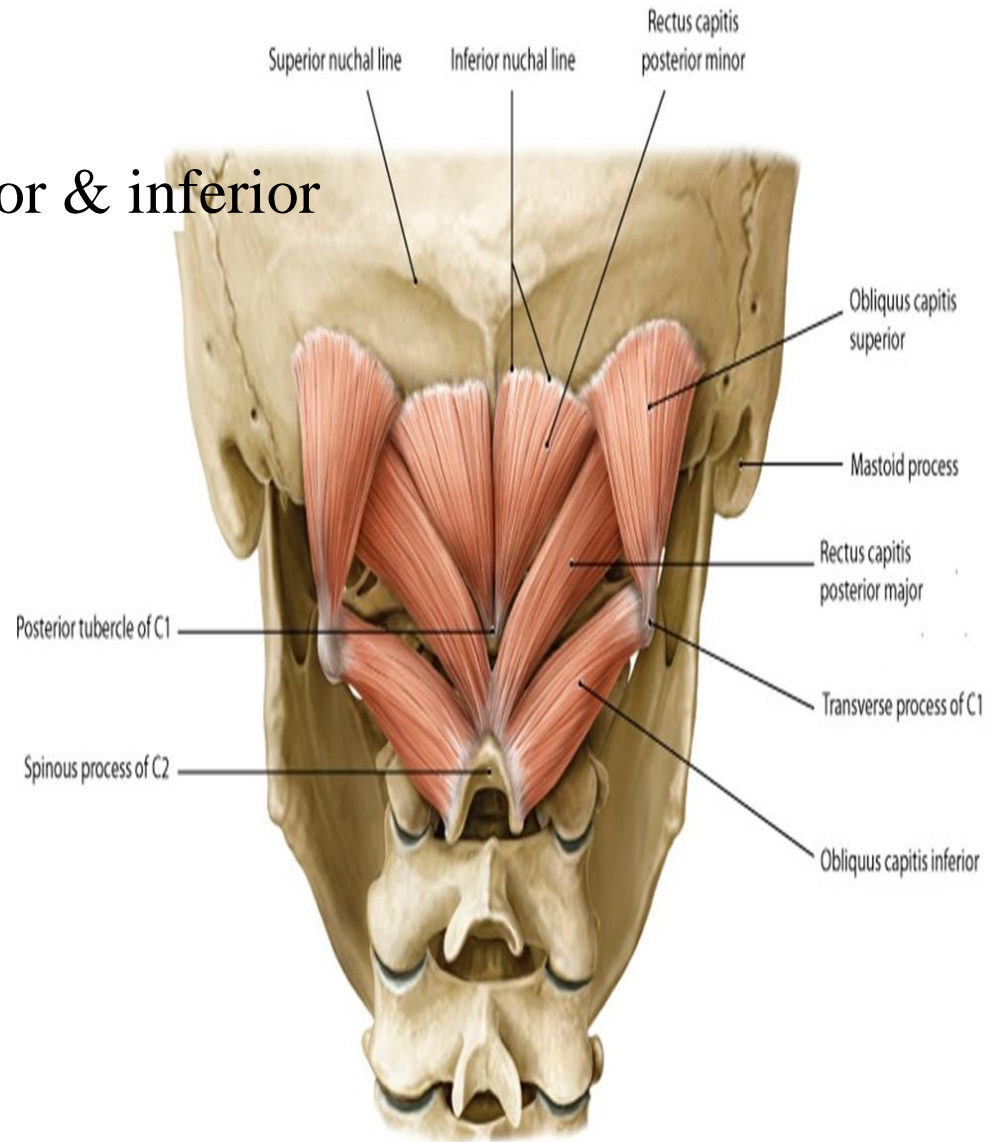
## SUPERIOR OBLIQUE

**O.:-** Transverse process of C1

**I.:-** Lateral area between superior & inferior nuchal lines

**A.** Extends head

**N.S.:-** Suboccipital n.  
(dorsal ramus of C1 n.)



# SUBOCCIBITAL TRIANGLE

## Boundaries:-

**Inferior:** - inferior oblique

**Above & lateral:** - superior oblique

**Above & medial:** -

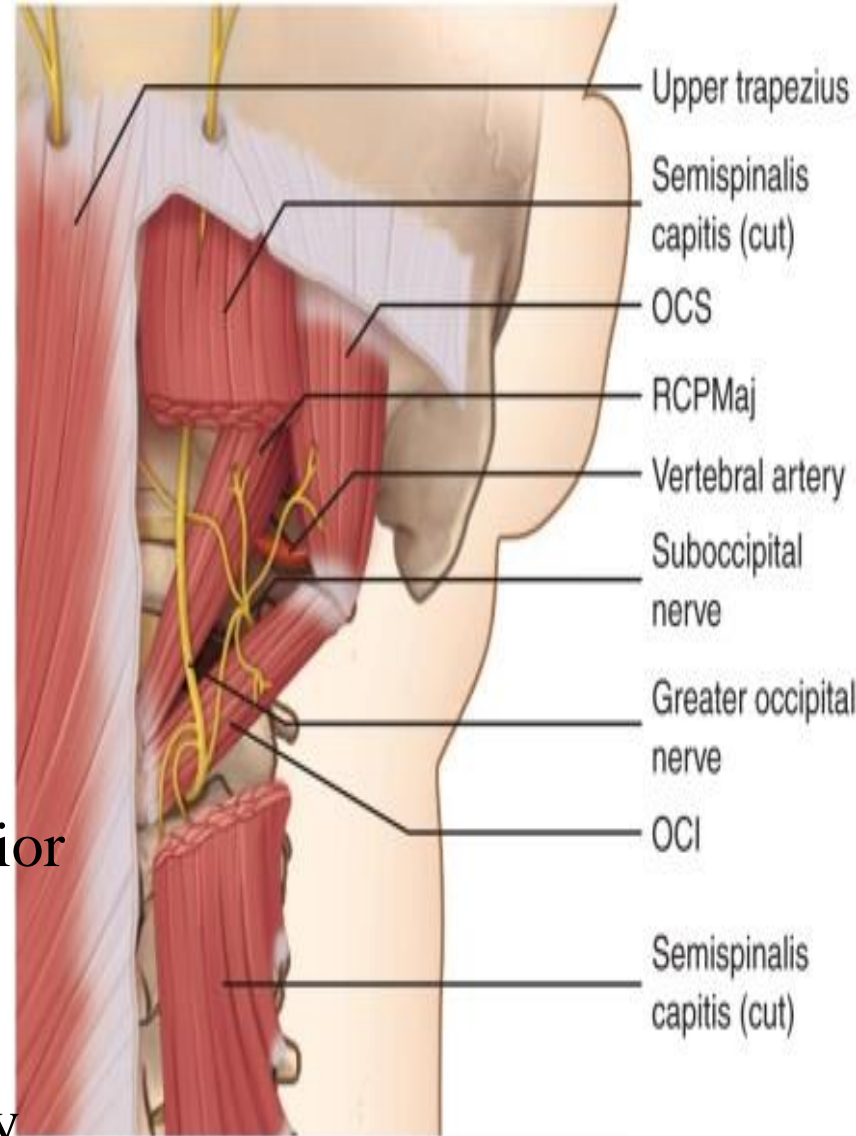
rectus capitis post. Major & minor

**Roof:** -

semispinalis capitis &  
longissimus capitis &  
greater occipital nerve

**Floor:** - posterior arch of atlas & posterior  
atlanto-occipital membrane

**Contents:** - dorsal ramus of c1  
3<sup>rd</sup> part of vertebral artery



THANQ