

وسهلا



أهلا

يُمنع أخذ السلايدات بدون
إذن المحرر واي اجراء
يخالف ذلك يقع تحت طائلة
المسؤولية القانونية
جميع المعلومات للاستخدام
التعليمي فقط

الأستاذ الدكتور يوسف حسين

رئيس قسم التشريخ والأنسجة والأجنة

كلية الطب - جامعة مؤتة - الأردن

دكتورة من جامعة كولونيا المانيا

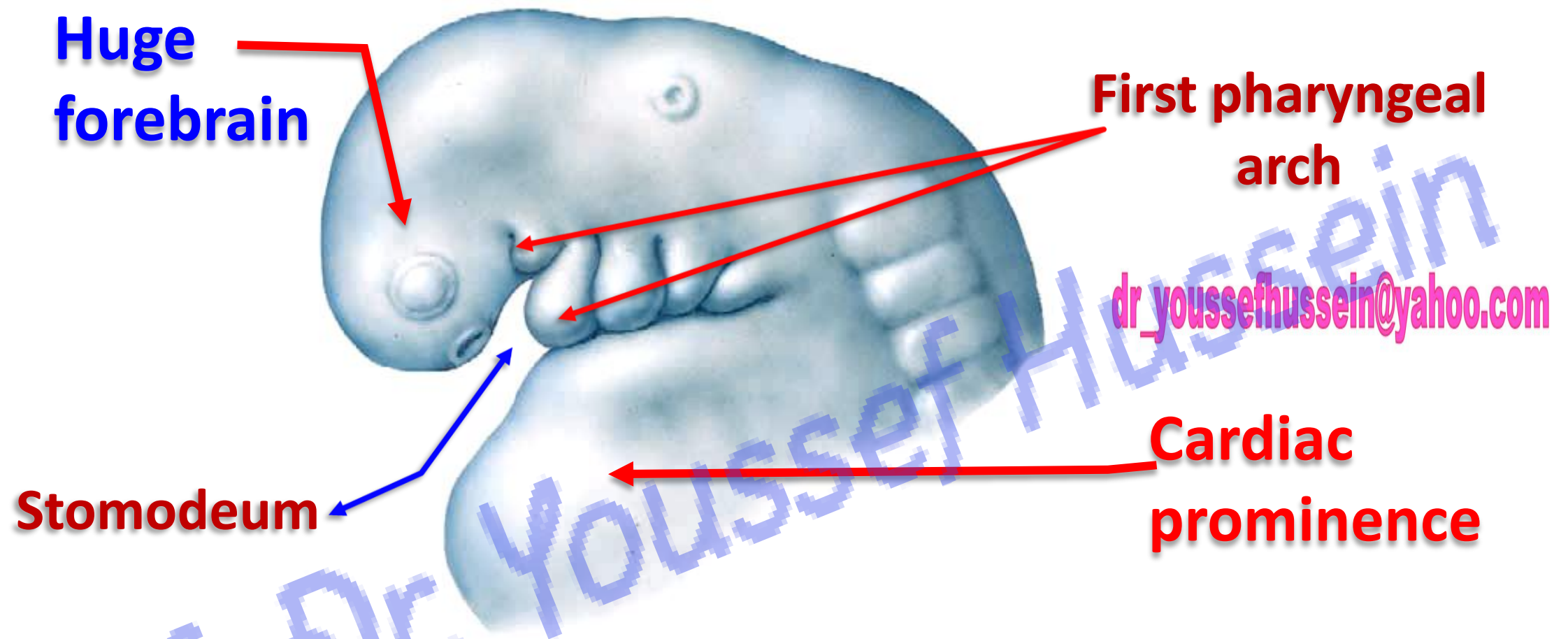
Prof. Dr. Youssef Hussein Anatomy - YouTube

الواتس 00201224904207

dr_youssefhussein@yahoo.com

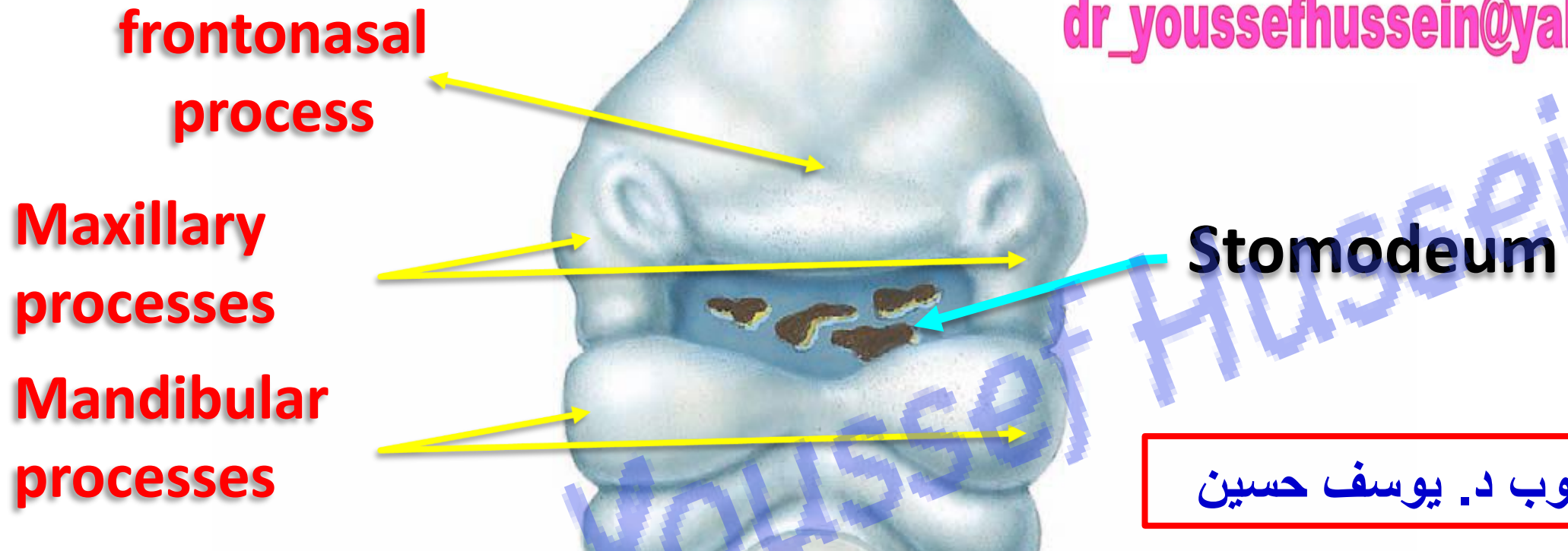
Development of the face

الڤوتڤوب د. ڤوسف حسڤن



- The **face** is dominated by the appearance of the pharyngeal arches
- **Stomodeum**, Primitive oral cavity that **closed by oral membrane** is **ectodermal recess** between the relatively huge forebrain and cardiac prominence .

اليوثيوب د. يوسف حسين



الـيـوتـيـوب د. يـوسـف حـسـين

- The face develops from **5 mesodermal swellings** which appear around **stomodeum**
 - I. Frontonasal process** above the stomodeum.
 - II. 2 maxillary swellings** (above and lateral to the stomodeum) from the 1st pharyngeal arch.
 - III. 2 mandibular swellings** (below and lateral to the stomodeum) from the 1st pharyngeal arch.

Nasal
placodes

Frontal bone

Nasal process

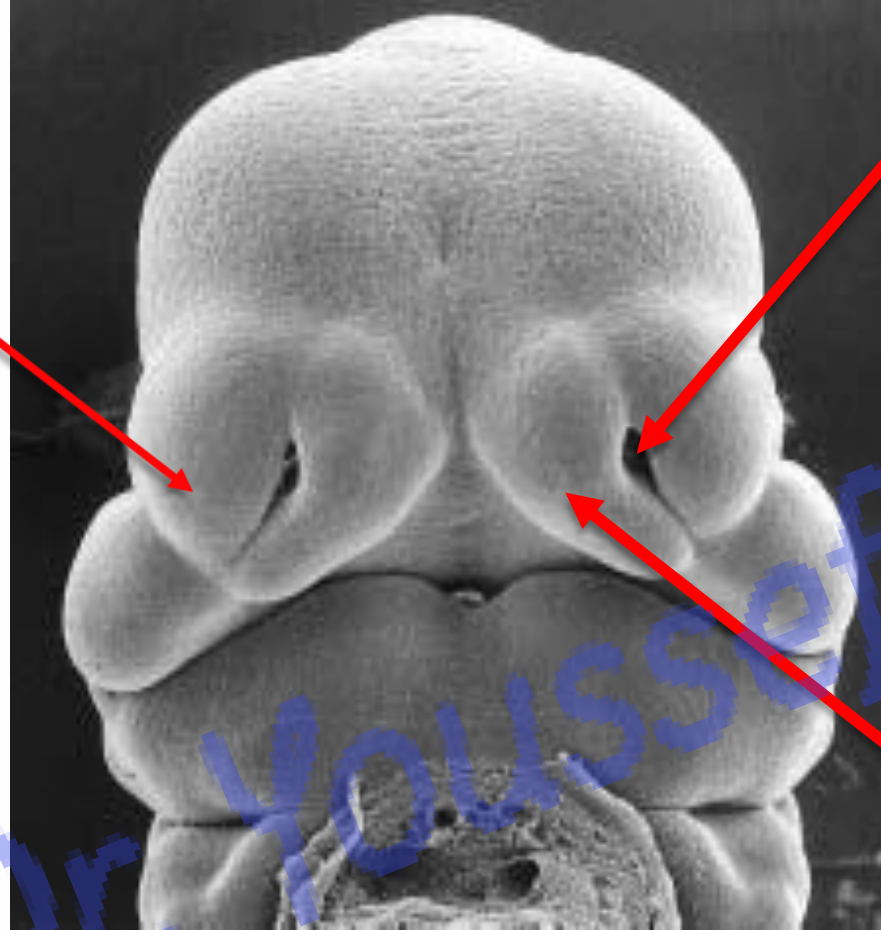
dr_youssefhussein@yahoo.com

**** Development of the frontonasal process:**

- a- The upper part forms the **frontal bone**.
- b- The lower part forms the **nasal process**.
- **Nasal placodes**, **ectodermal swellings** develop in lower border of nasal process.

الـيـوتـيـوب د. يـوسـف حـسـين

Lateral nasal process



Nasal pit

Medial nasal process

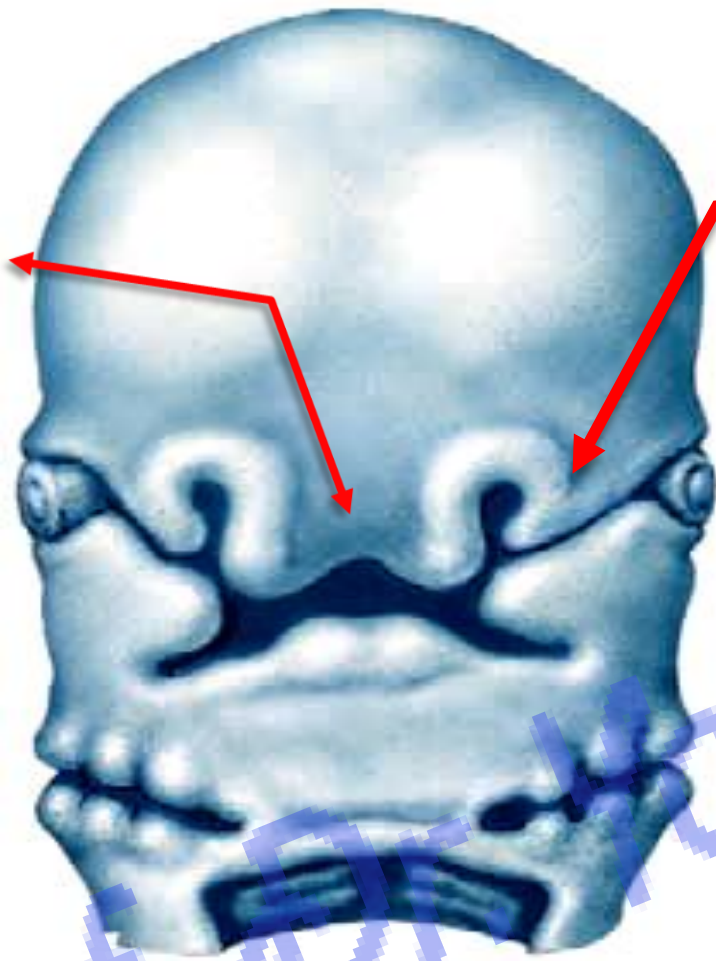
• **Two nasal pits** (nostril) appear in the nasal placode divide the nasal process:

a- Two lateral nasal processes form the ala of the nose.

b- Two medial nasal processes

اليوتيوب د. يوسف حسين

**Median
nasal
process**



**Lateral nasal
process**

dr_youssefhussein@yahoo.com

- Two medial nasal processes unit with each other forming **median nasal process (Intermaxillary segment)**

الـيـوتـيـوب د. يـوسـف حـسـين

Philtrum

Nasal septum

**Premaxilla carries
four incisor teeth**

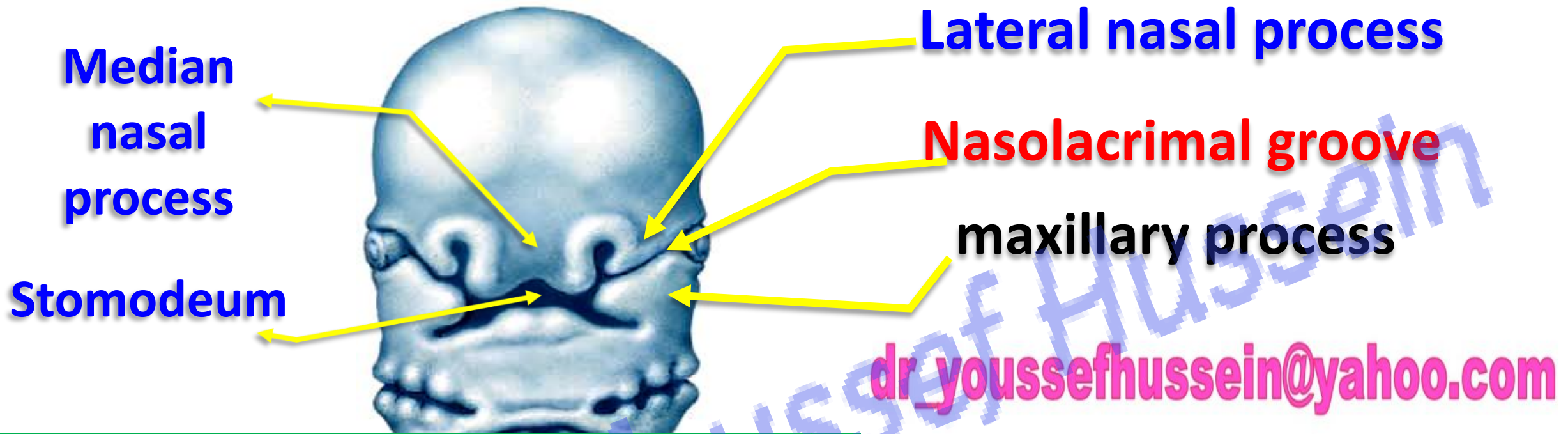
**Triangular primary
palate**



• **Median nasal process gives rise to:**

- 1- Part of the nasal septum.
- 2- Philtrum (middle) of the upper lip.
- 3- Premaxilla (upper jaw that carries 4 incisor teeth).
- 4- Primary palate.

الـيـوتـيـوب د. يـوسـف حـسـين



Development of the maxillary process

- The 2 maxillary processes grow medially above the stomodeum towards the **lateral nasal processes** but **separated from** them by a well developed ectodermal groove called **nasolacrimal groove**.
- The edges of **nasolacrimal groove** fused forming a **solid cord**. Later on; canalized and forms the **nasolacrimal canal**.

اليوتيوب د. يوسف حسين

- The maxillary processes continue to grow medially and **fused with the lateral nasal processes**. Later on; they fused with the margins of the **median nasal process to form the upper jaw**.

- A horseshoe **labiokingival groove** divides upper jaw into
a) Outer part forms upper lip. b) Inner part forms gum.

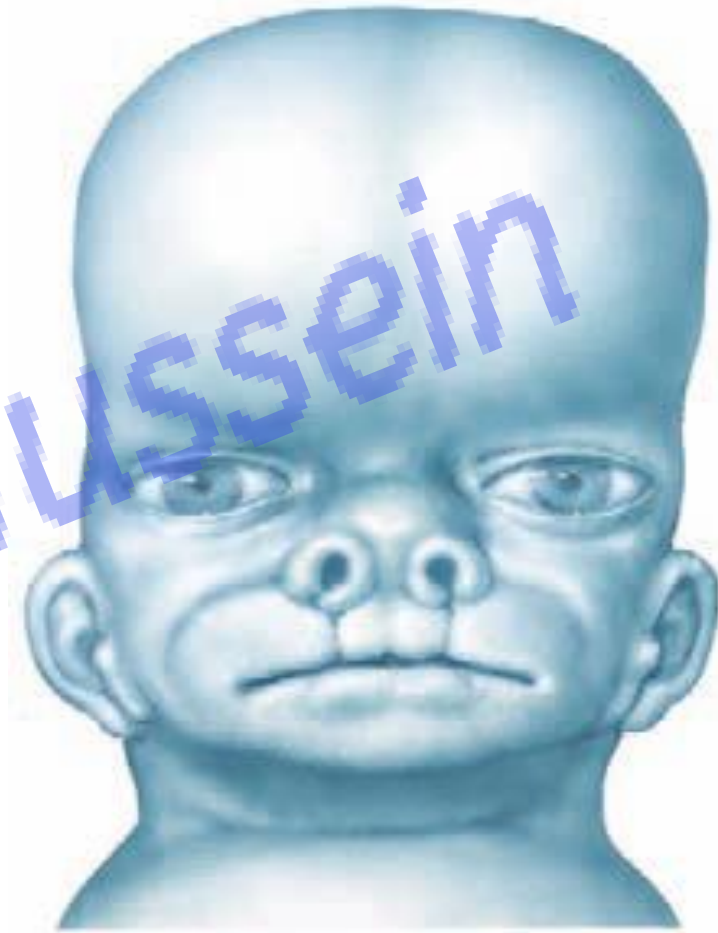**** Development of the mandibular process**

- They grow medially below the stomodeum and fused with each other in the midline forming the **primitive lower jaw**.

- A horseshoe **labiokingival groove** divides lower jaw into
a) Outer part forms lower lip. b) Inner part forms gum.

**** Development of the muscles of the face**

- They developed from the mesoderm of the **2nd pharyngeal arch** (supplied by the facial nerve).

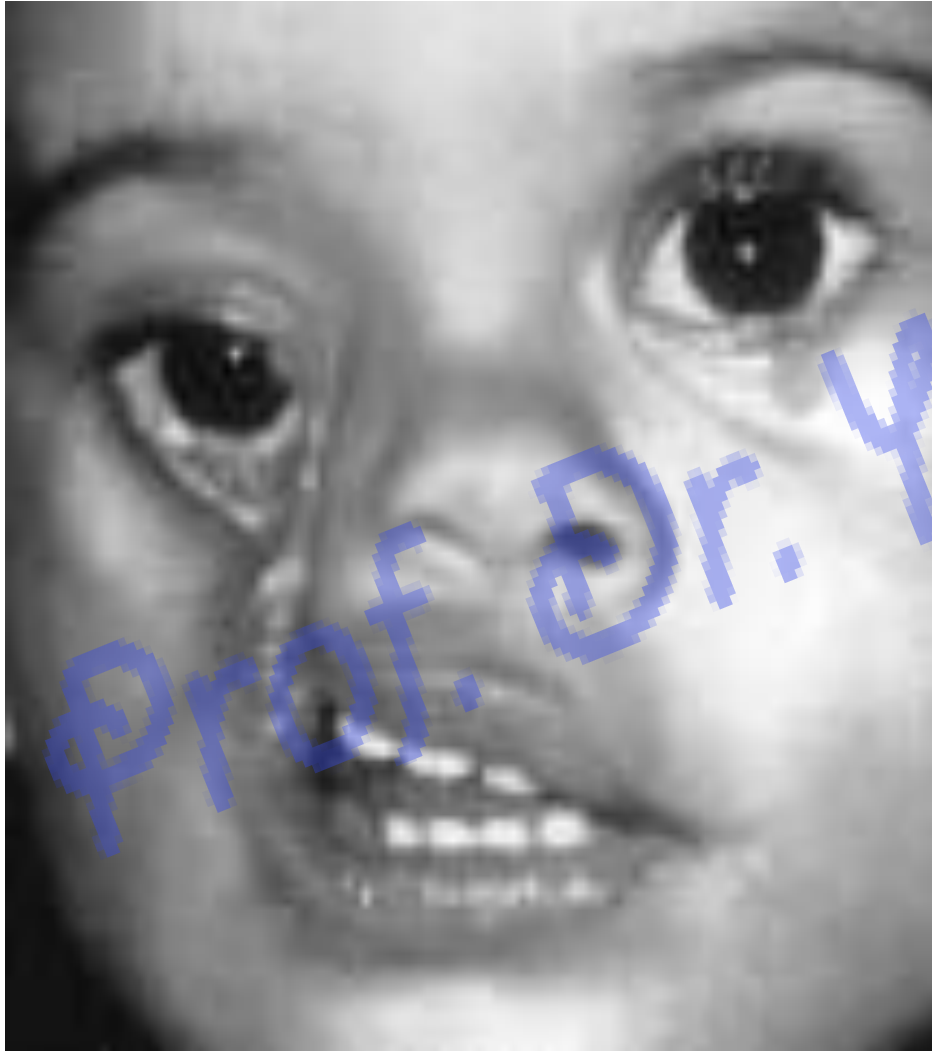

dr_youssefhussein@yahoo.com

Congenital anomalies of the face

الـيـوتـيـوب د. يـوسـف حـسـين

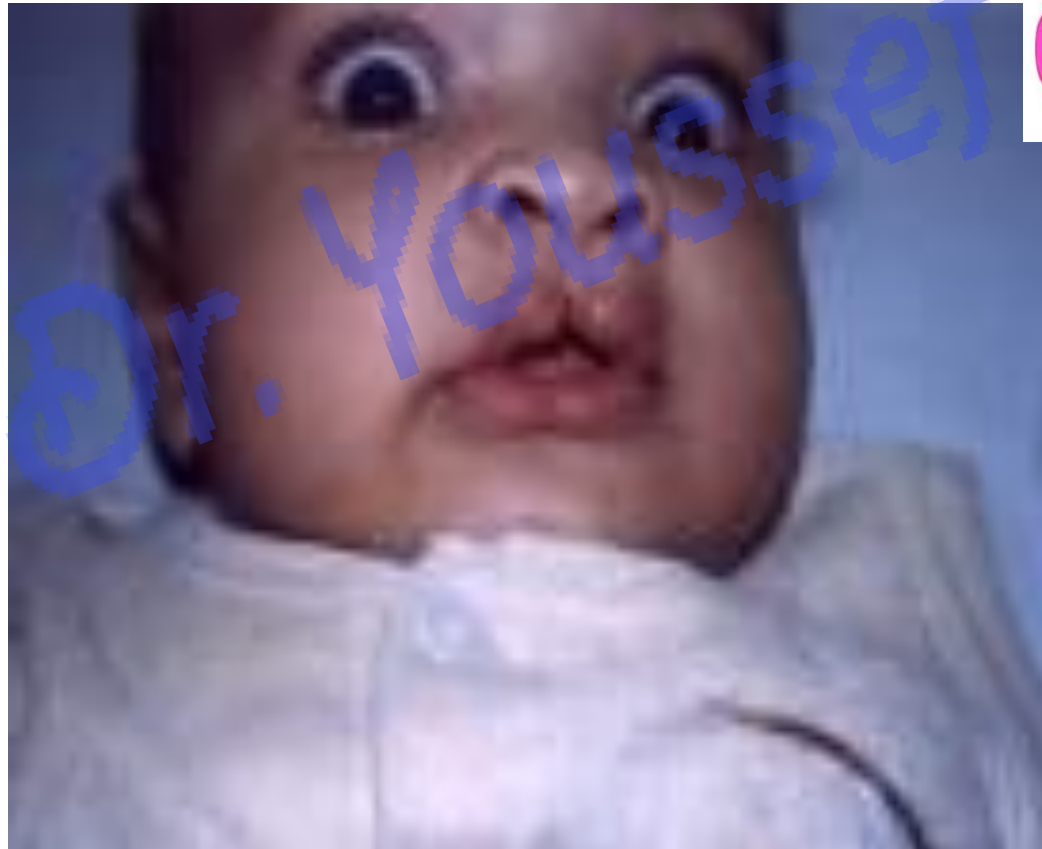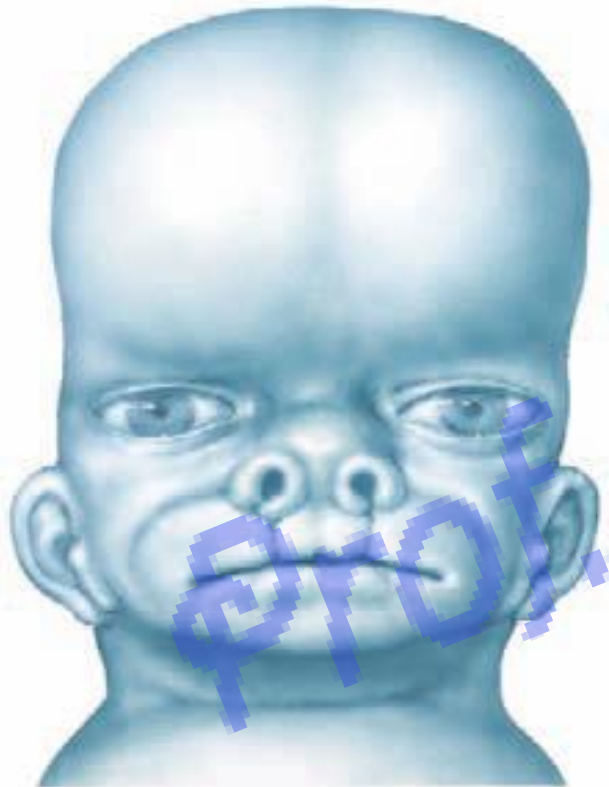- **Oblique facial cleft**: due to failure of fusion of the maxillary processes with the **lateral nasal processes** along the line of the **nasolacrimal canal**.
- **Atresia of the nasolacrimal canal**



dr_youssefhussain@yahoo.com

الـيـوتـيـوب دـ. يـوسـف حـسـين

- **Harelip (cleft):** in the upper lip
 - It may be in the lip only or may be associated with the cleft palate.
 - **Median harelip (cleft)**
- **Due to** failure of fusion of the 2 medial nasal processes (No philtrum).

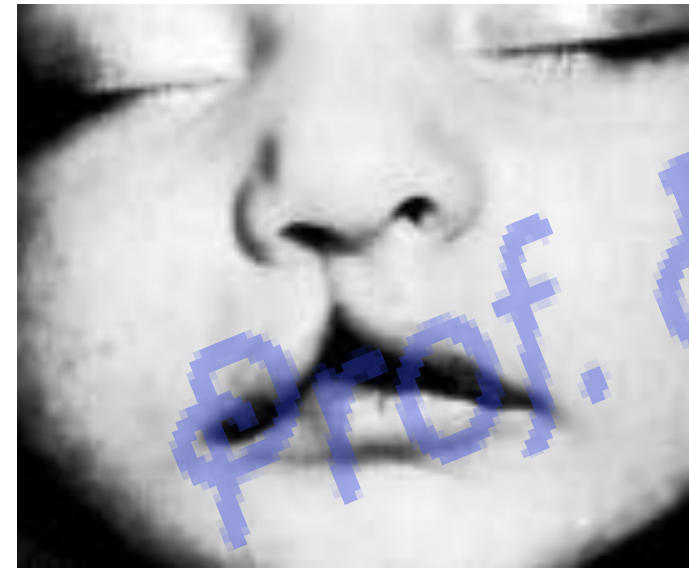

dr_youssefhussain@yahoo.com

اليوثيوب د. يوسف حسين

Hare (cleft) lip

- **Unilateral harelip:** due to failure of fusion between the **maxillary process** and the **median nasal process** (fissure between philtrum and lateral part of the upper lip) **in one side.**
- **Bilateral harelip:** due to failure of fusion between the maxillary processes with the median nasal processes, **on both side.**



Unilateral



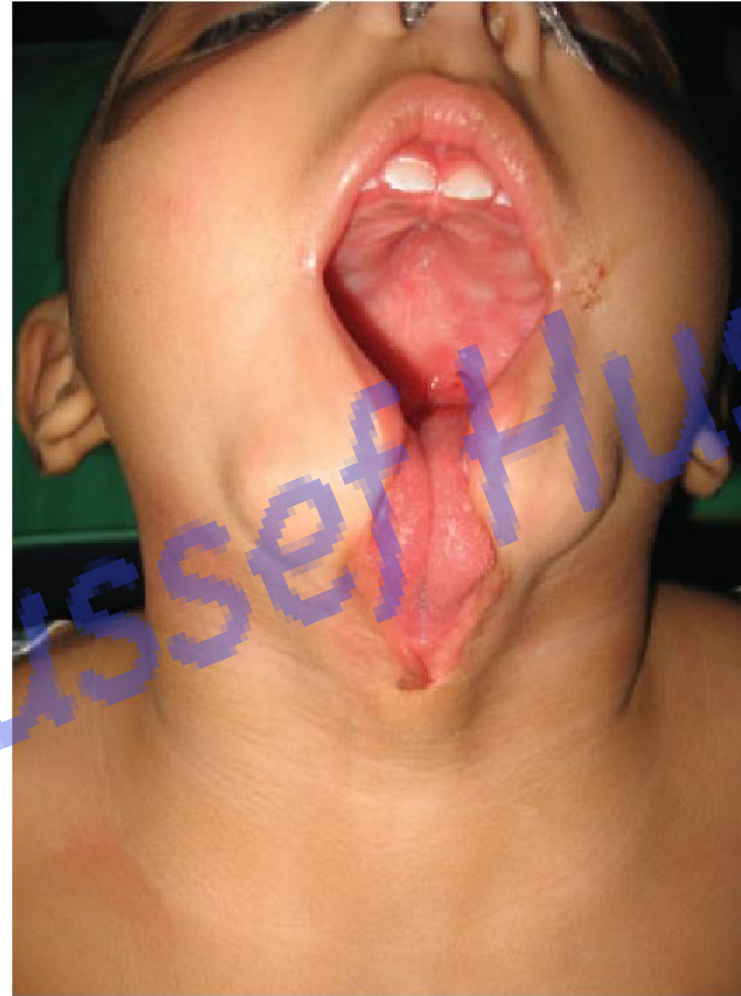Bilateral

dr_youssefhussein@yahoo.com

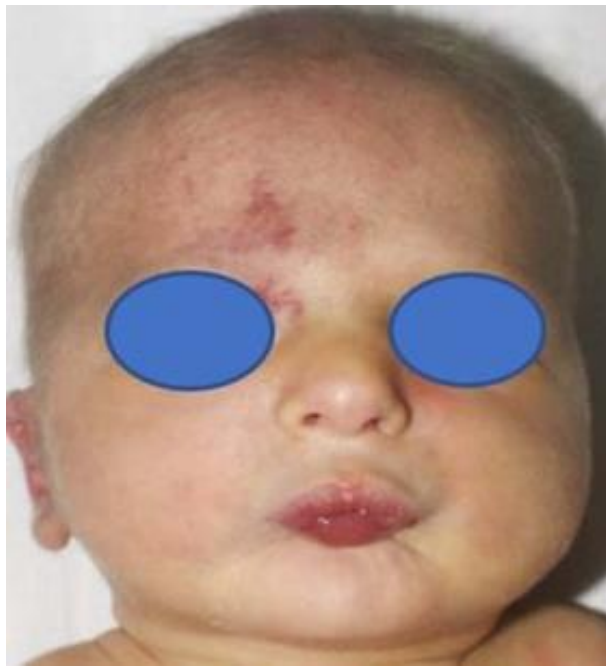اليوتيوب د. يوسف حسين

dr_youssefhussein@yahoo.com

Cleft lower lip due to failure of fusion of **mandibular processes** in the midline.

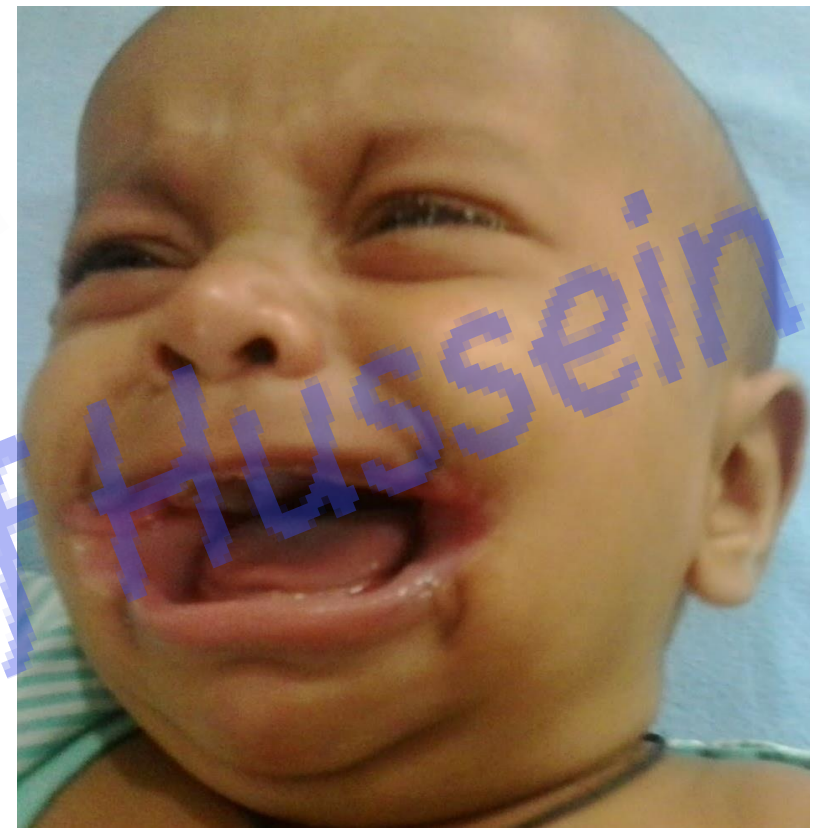

اليوثيوب د. يوسف حسين



- **Microstomia** (narrow mouth opening): due to **excessive fusion** of the maxillary and mandibular processes on each side.

- **Macrostomia** (wide mouth opening): due to **incomplete fusion** of the maxillary and mandibular processes on each side.




اليوثيوب د. يوسف حسين

https://www.youtube.com/channel/UCVSNqbibj9UWYaJdd_cn0PQ

يُمنع أخذ السلايدات بدون
إذن المحرر واي اجراء
يخالف ذلك يقع تحت طائلة
المسؤولية القانونية
جميع المعلومات للاستخدام
التعليمي فقط

اليوتيوب د. يوسف حسين



Thank You

Questions

<https://www.youtube.com/@ProfDrYoussefHusseinAnatomy/playlists>