

وسهلا



أهلا

يُمنع أخذ السلايدات بدون
إذن المحرر واي اجراء
يخالف ذلك يقع تحت طائلة
المسؤولية القانونية
جميع المعلومات للاستخدام
التعليمي فقط

الأستاذ الدكتور يوسف حسين

رئيس قسم التشريح والأنسجة والأجنة

كلية الطب - جامعة مؤتة - الأردن

دكتورة من جامعة كولونيا المانيا

الواتس 00201224904207

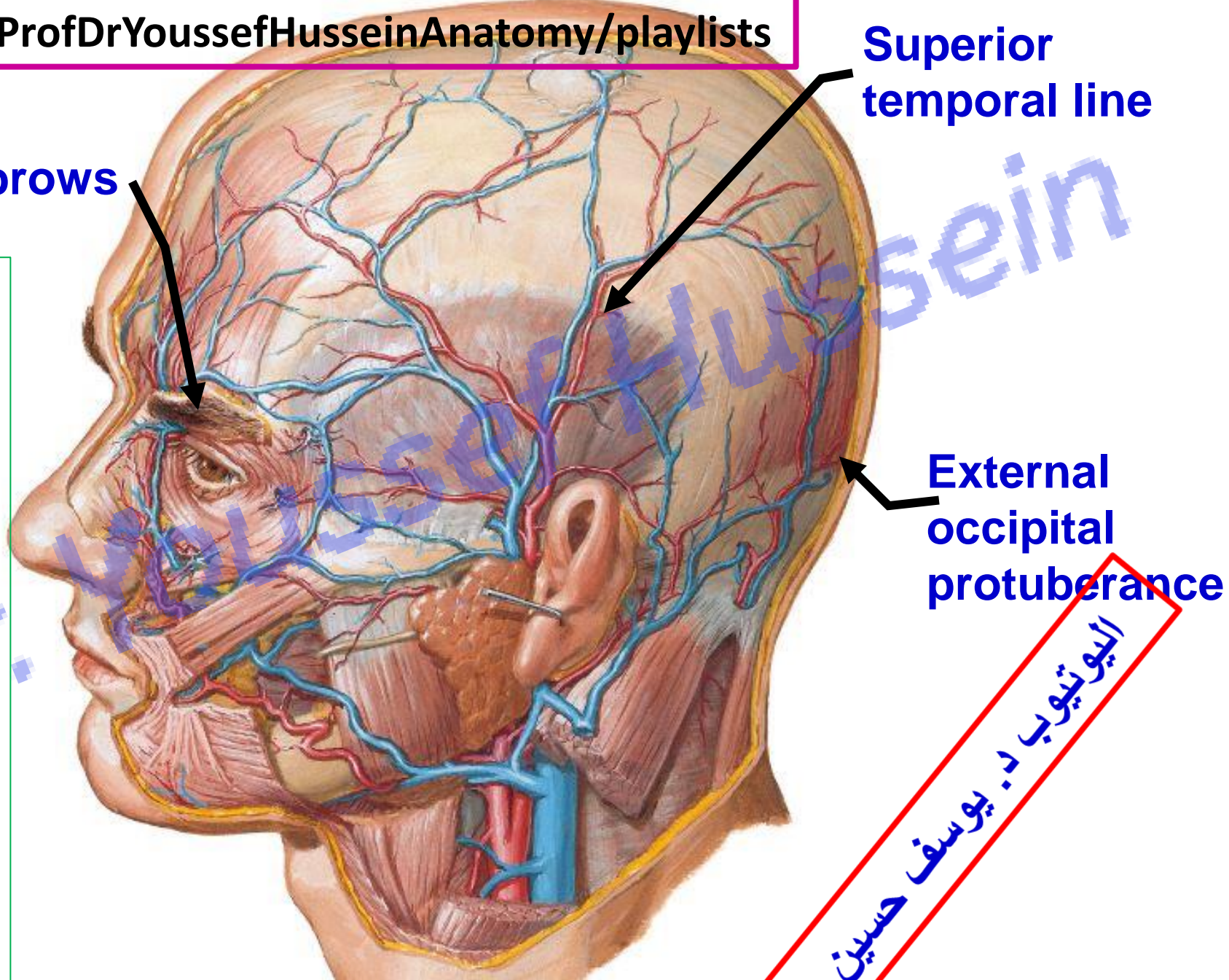
dr_youssefhussein@yahoo.com

Scalp

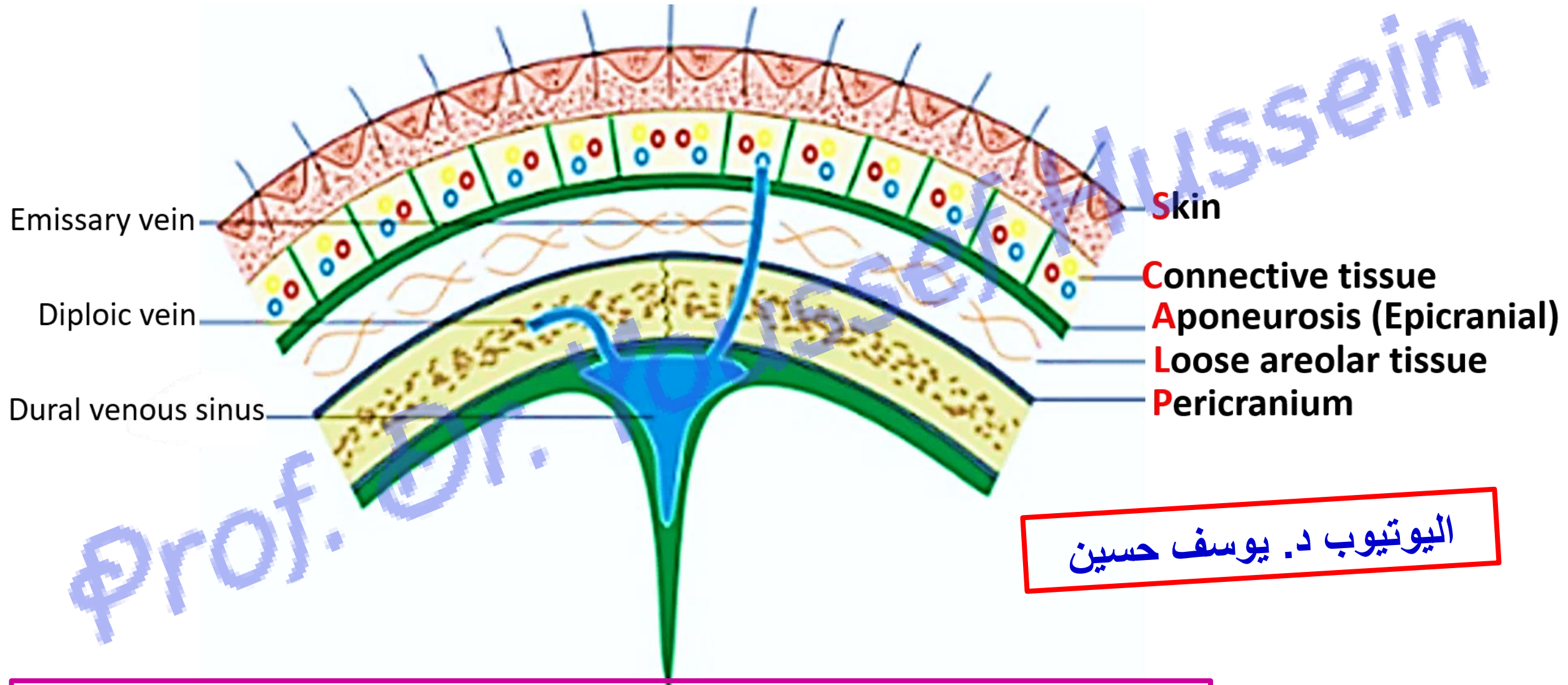
الليوتوب د. يوسف حسين

<https://www.youtube.com/@ProfDrYoussefHusseinAnatomy/playlists>

- **Scalp**
 - The soft tissues covering skull cap (calvaria).
- **Extension**
 - **Anteriorly;** Skin of the eye brows.
 - **Laterally;** superior temporal lines.
 - **Posteriorly;** external occipital protuberance and **highest** nuchal lines.



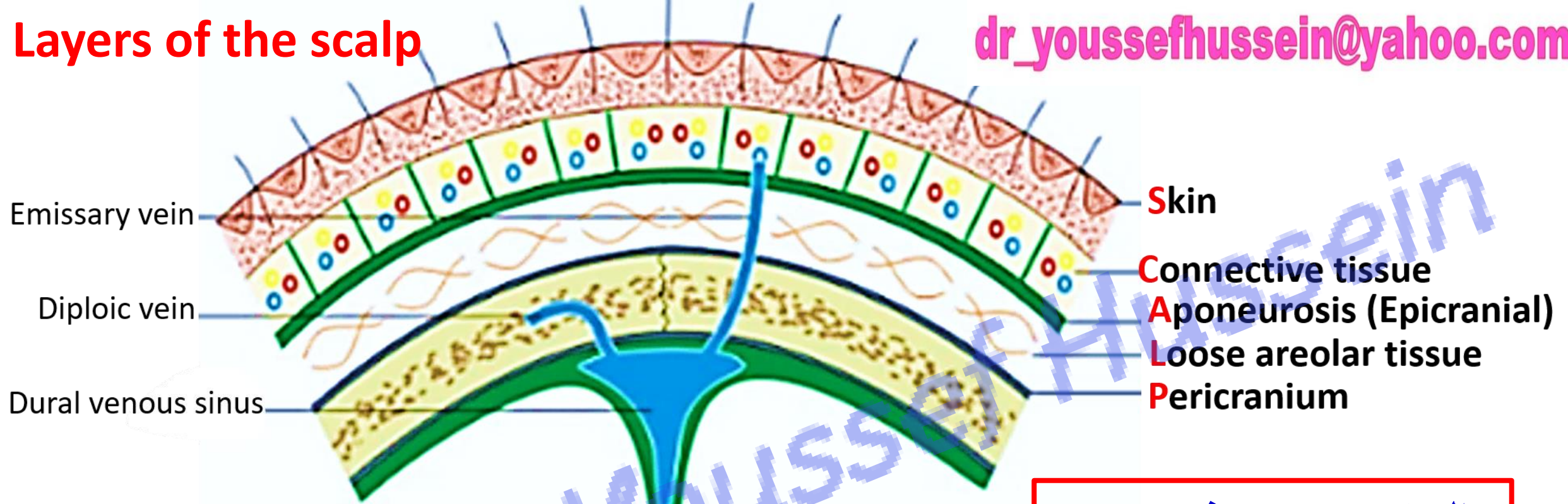
Layers of the scalp : 5 layers (S.C.A.L.P.)



اليوثيوب د. يوسف حسين

Layers of the scalp

dr_youssefhussein@yahoo.com



اليوثيوب د. يوسف حسين

1- Skin: thick, tough and rich in hair follicles, sweat and sebaceous glands.

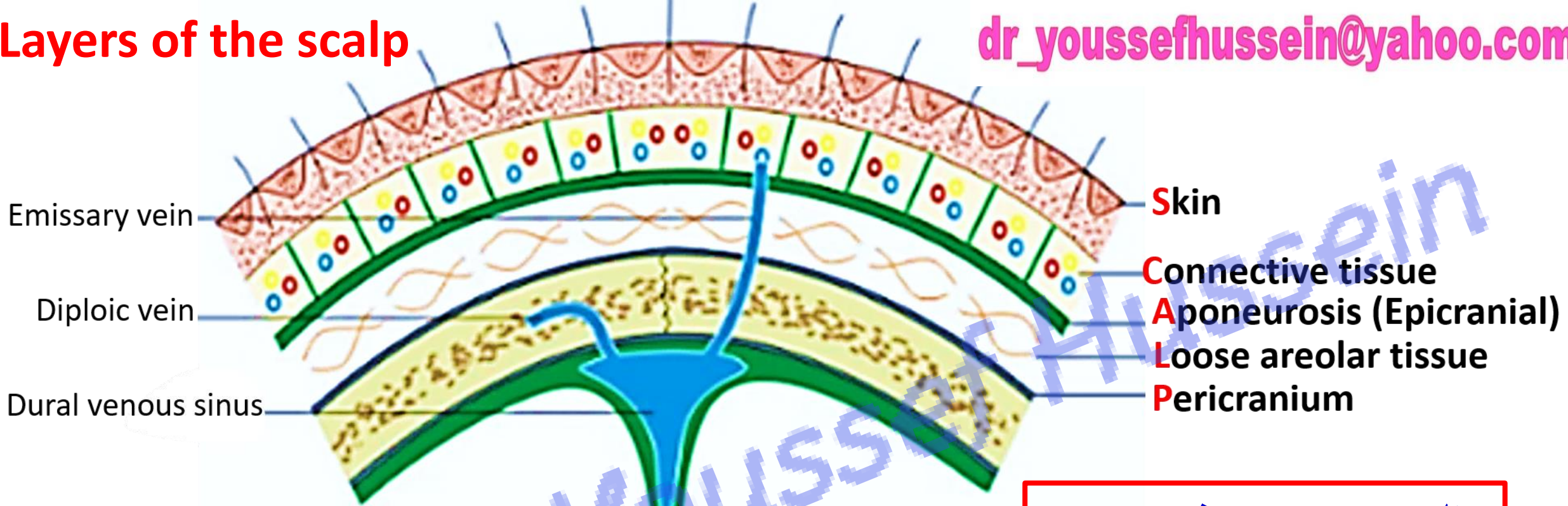
2- Connective tissues: formed of **dense fibrous tissue**, contains blood vessels, nerves and lymphatic.

3- Aponeurosis of occipitofrontalis muscle (*galea aponeurotica*).

- The first 3 layers **attached together** and move on the underlying layer.

Layers of the scalp

dr_youssefhussein@yahoo.com



الـيـوتـيـوب د. يـوسـف حـسـين

4- Loose areolar tissue (dangerous zone): allows **mobility** of the scalp on the skull, site of collection of pus and blood

5- Pericranium (periosteum): it does not adhere to the skull bones but adherent at the **sutures** of the skull by band of the fibrous tissue called **sutural ligaments**.

<https://www.youtube.com/@ProfDrYoussefHusseinAnatomy/playlists>

الڤوتڤوب د. ڤوسف حسڤن

dr_youssefhussein@yahoo.com

Occipitofrontalis muscle

<https://www.youtube.com/@ProfDrYoussefHusseinAnatomy/playlists>

Epicranial aponeurosis

Occipitofrontalis Muscle

Frontal belly

**Skin of the eye
brow and root
of the nose**

Occipital belly

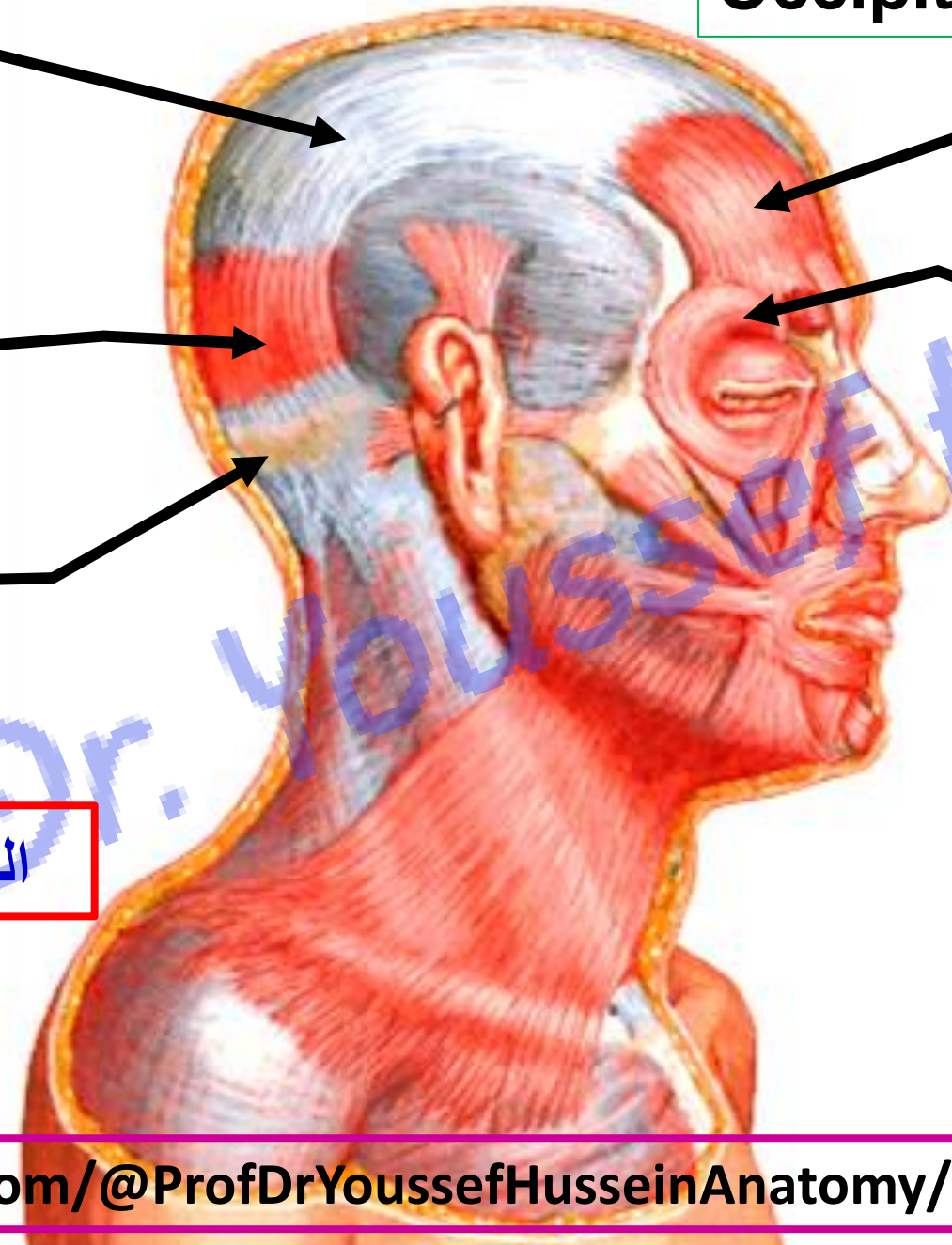
No bony attachment

**Nerve supply is facial
nerve (2nd pharyngeal
arch)**

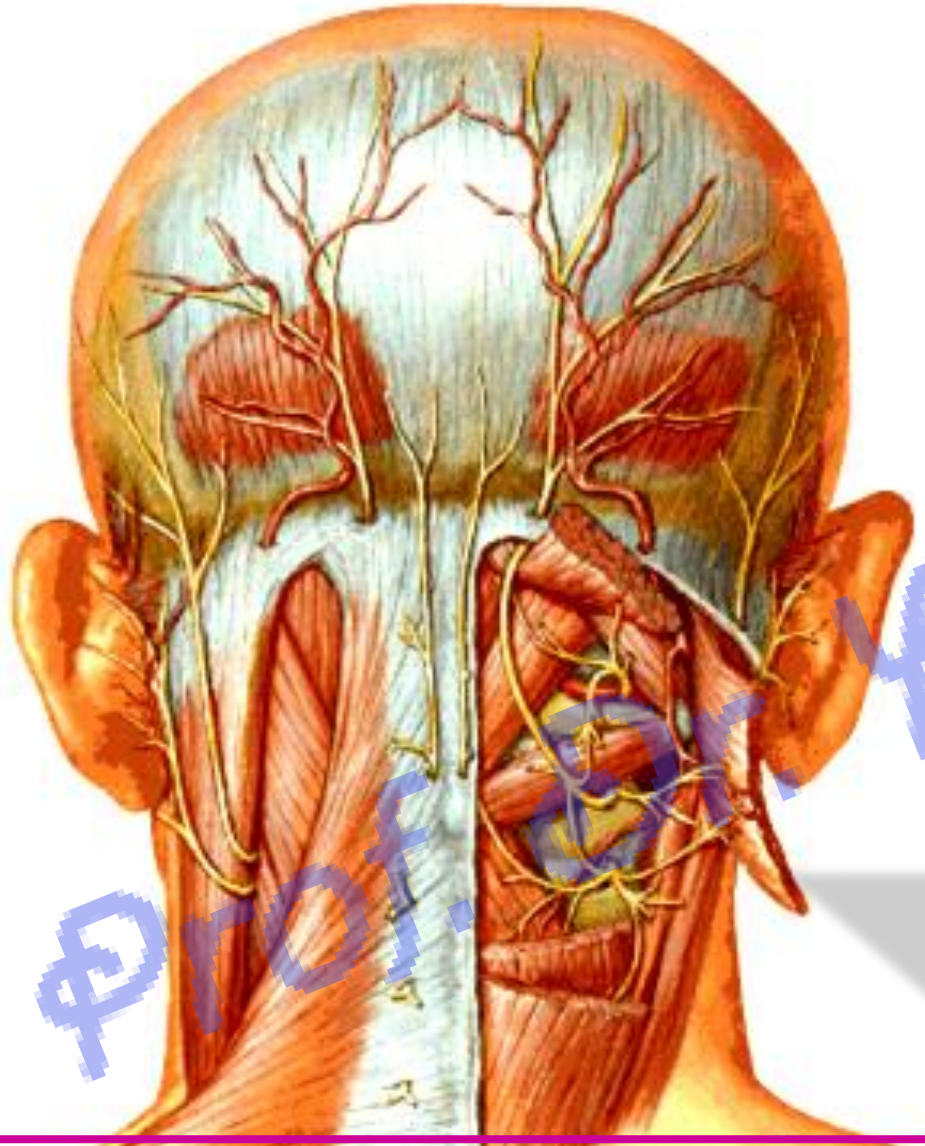
**Highest nuchal
line**

اليوثيوب د. يوسف حسين

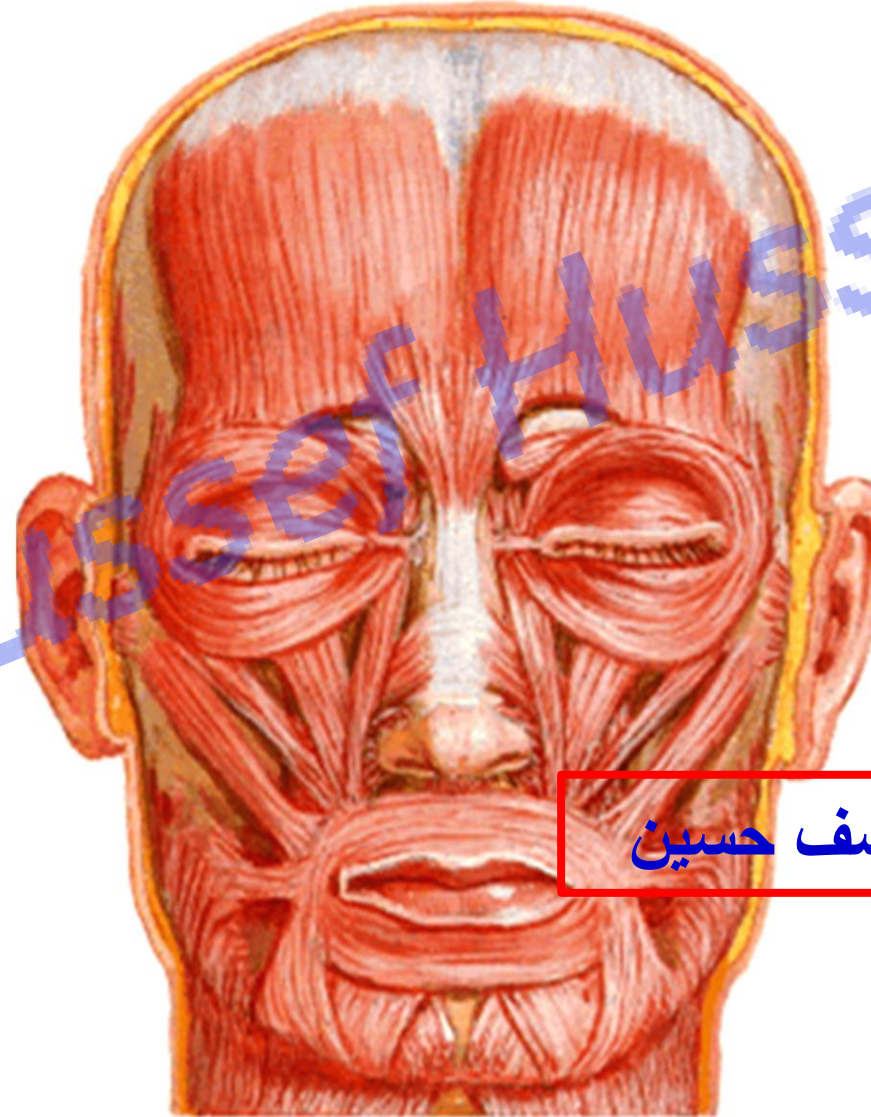<https://www.youtube.com/@ProfDrYoussefHusseainAnatomy/playlists>



Occipital bellies



Frontal bellies



اليوتيوب د. يوسف حسين

* Occipitofrontalis Muscle

- It is formed of **2 frontal bellies and 2 occipital bellies** connected together by the epicranial aponeurosis.
- The two **frontal** bellies are much **larger** than the occipital bellies.
- The two frontal bellies come **close together** in the median plane, while the two occipital bellies are separated by a **gap** of epicranial aponeurosis (***galea aponeurotica***).

<https://www.youtube.com/@ProfDrYoussefHusseinAnatomy/playlists>

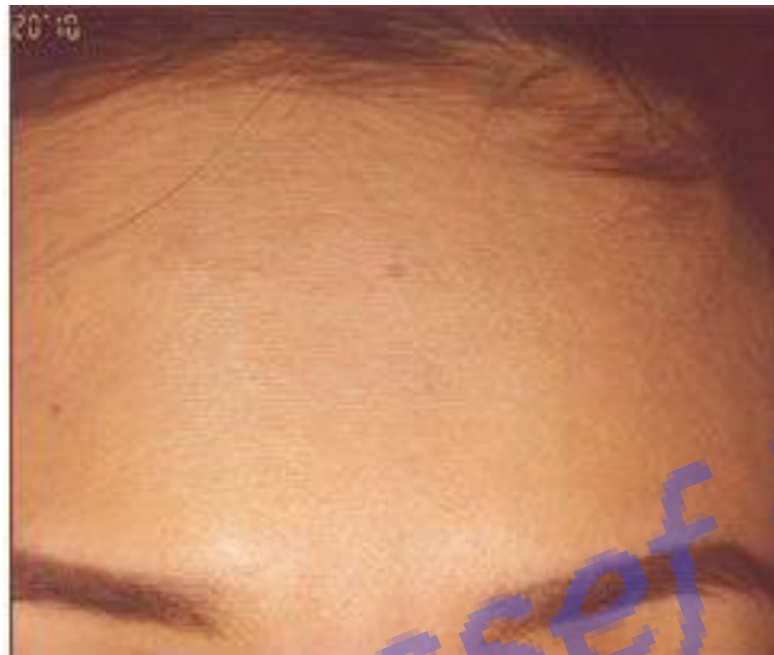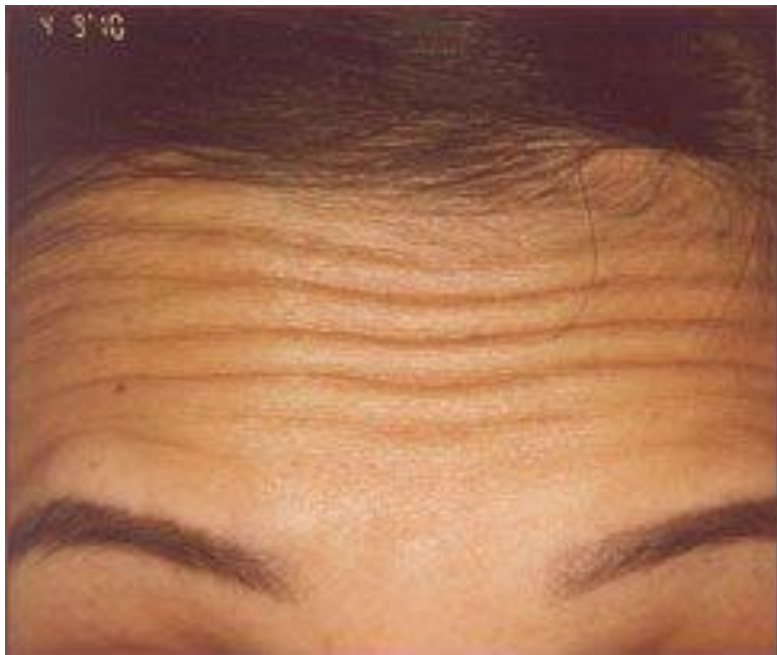
a- The occipital bellies

- * **Origin**; from the highest nuchal lines.
- * **Insertion**; epicranial aponeurosis.
- * **Nerve supply**, posterior auricular branch of facial nerve.

اليوتيوب د. يوسف حسين

b- The frontal bellies

- * **Origin**; from epicranial aponeurosis.
- * **Insertion**; to the skin of the eye brows and root of the nose (no bony attachment).
- * **Nerve supply**; temporal branches of the facial nerve.



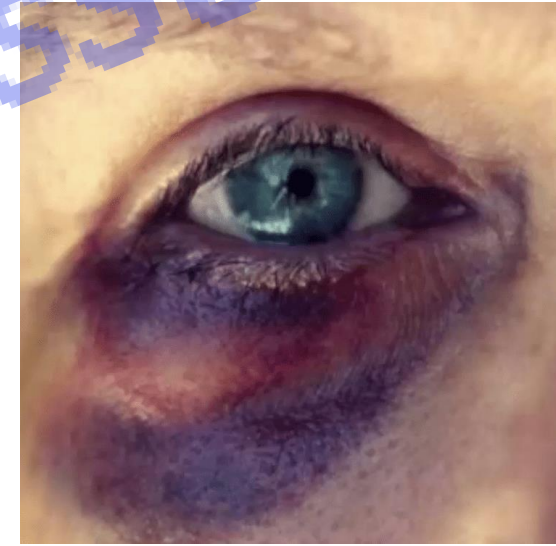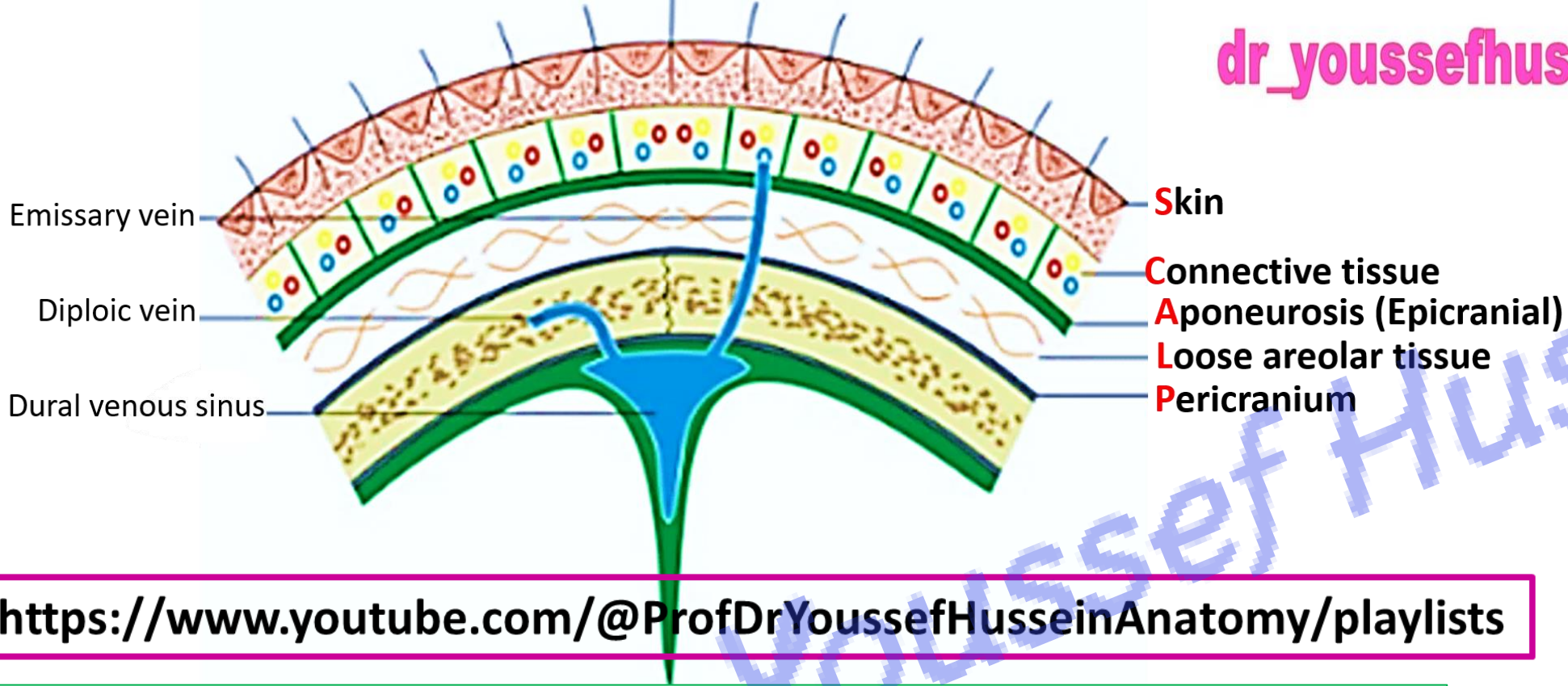
*** Action of occipital belly**
- Pull the scalp backward
leading to smooth skin of
forehead.

*** Action of frontal belly**
- Elevate the eye brows
producing transverse
wrinkles of skin of the
forehead (*expression of*
surprise).

dr_youssefhussein@yahoo.com

اليوثيوب د. يوسف حسين

<https://www.youtube.com/@ProfDrYoussefHusseinAnatomy/playlists>



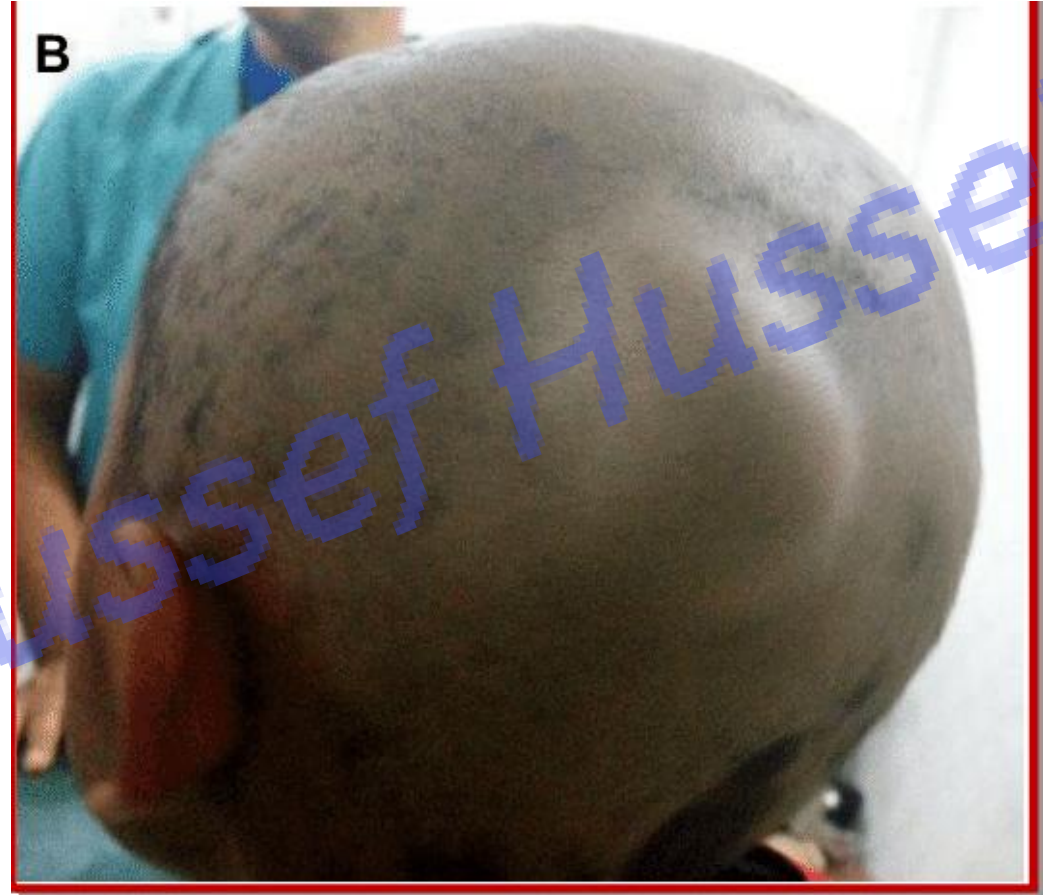<https://www.youtube.com/@ProfDrYoussefHusseinAnatomy/playlists>

اليوثيوب د. يوسف حسين

- The first 3 layers attached together and move on the underlying layer.

- Bleeding under the first 3 layers forms diffuse hematoma extending throughout the scalp and reach the upper eye lids (Black eye).

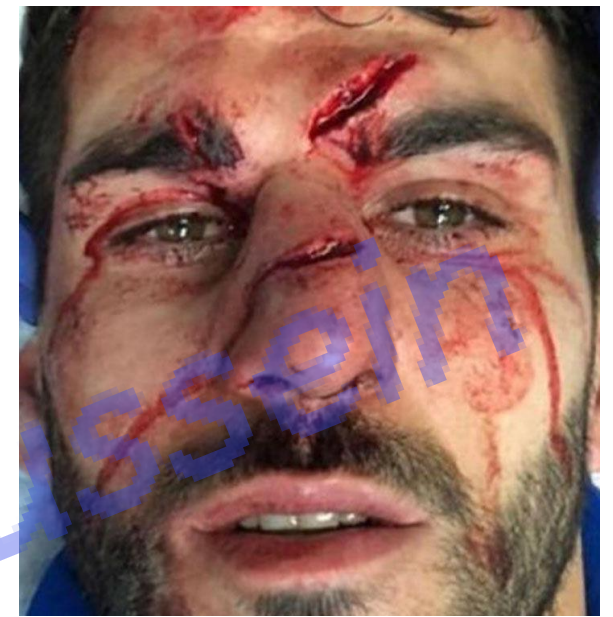- Fracture of the skull bone produces a localized hematoma because the periosteum is firmly attached to the sutures.



اليوثيوب د. يوسف حسين

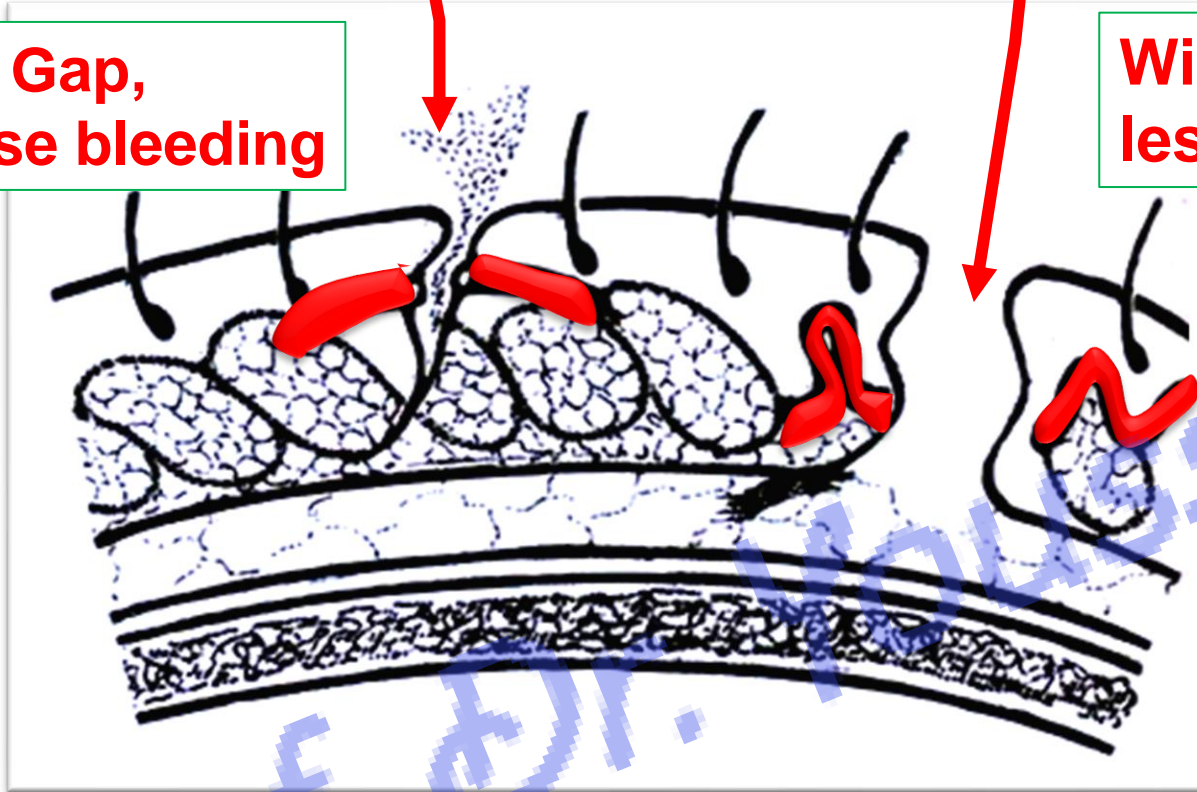
Cut wound in subcutaneous area

Cut wound involving epicranial aponeurosis



Small Gap,
Profuse bleeding

Wide Gap,
less bleeding



Horizontal Cut wound of The front of scalp leading to Wide Gap due to **retraction** of occipitofrontalis muscle

اليوثيوب د. يوسف حسين

<https://www.youtube.com/@ProfDrYoussefHusseainAnatomy/playlists>

- **Clinical anatomy**

- **Wide gap and less bleeding:** when epicranial aponeurosis is cut in **coronal plane** (**Deep wound**), because of **Retraction** of the frontal and occipital bellies of the occipitofrontalis muscle in **opposite directions** (anteriorly and posteriorly) leading to wide gap and close the vessels.
- **Profuse bleeding:** The connective tissue is dense fibrous and adherent to the wall of the blood vessels so prevents their contraction or retraction following injury., The arteries supplying the scalp anastomose freely with each other.
- **Small gap:** Attachment of the skin to the epicranial aponeurosis keeps the edges of superficial wounds together

اليوثيوب د. يوسف حسين

Nerve supply of scalp

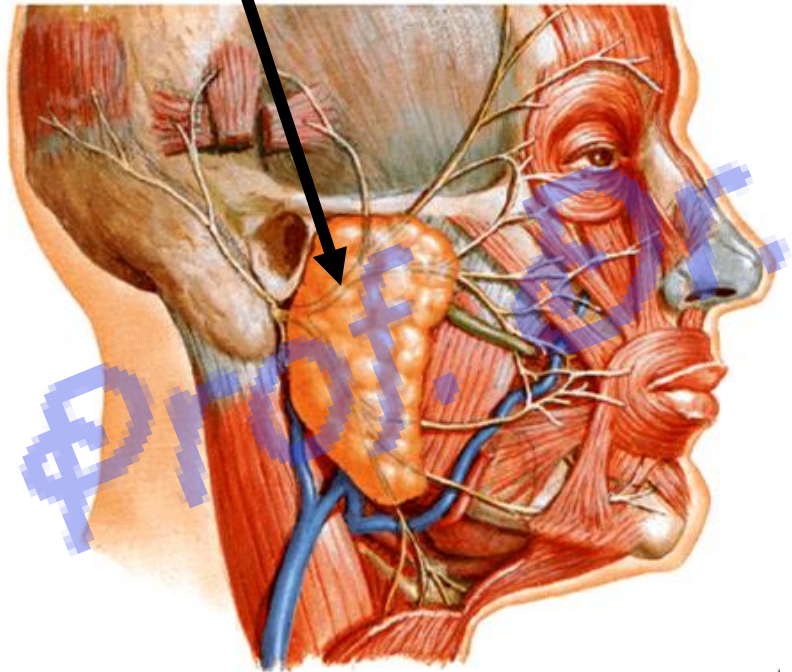
- Scalp is supplied by 10 nerves on each side.
- **Five nerves in front the auricle**
- **Fives nerves behind the auricle.**
- **Each 5 nerves, 4 sensory and 1motor.**

اليوثيوب د. يوسف حسين

Nerves in front auricle

Auriculotemporal nerve S

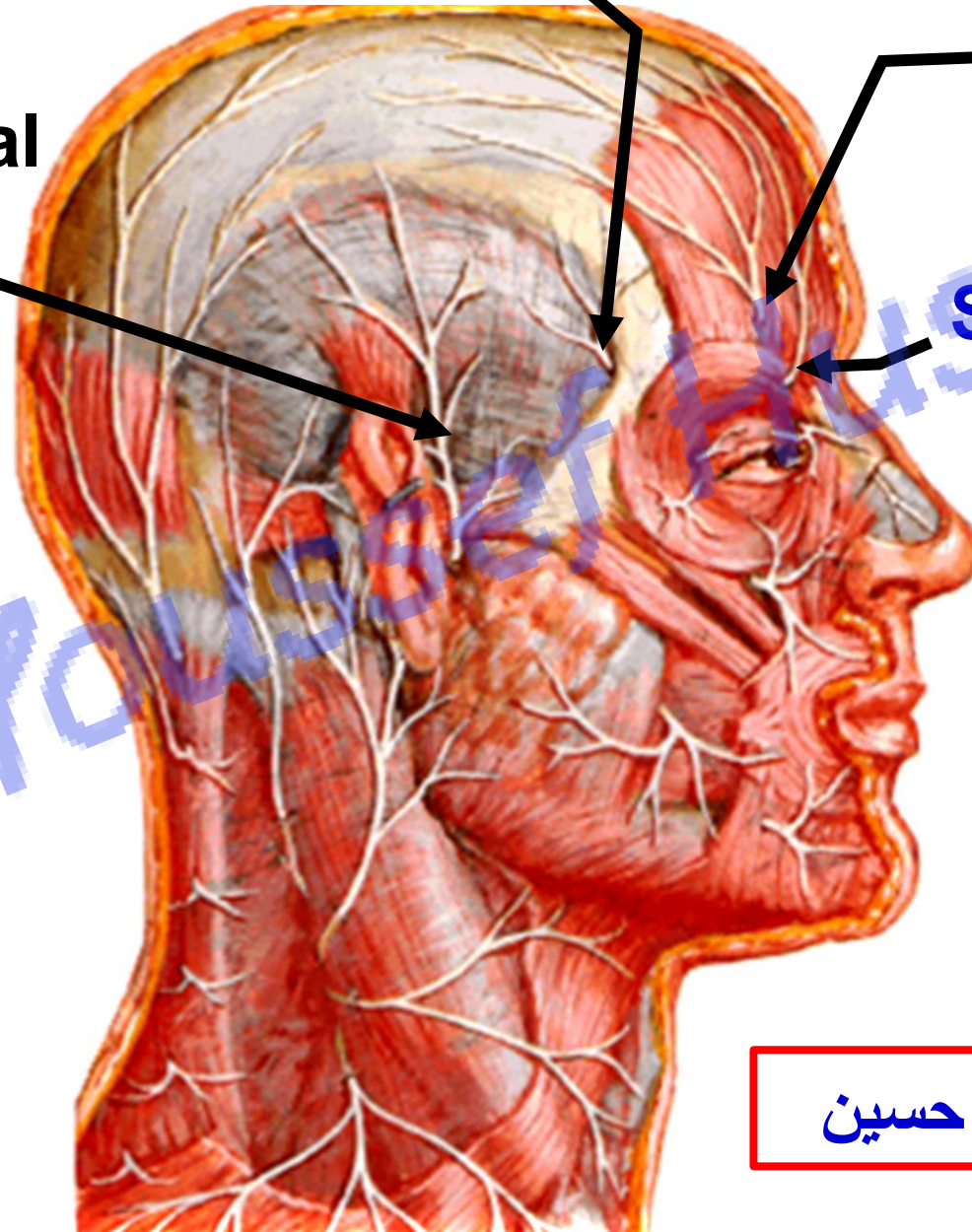
Temporal nerve M



Zygomatocotemporal nerve S

Supraorbital nerve S

Supratrochlear nerve S



اليوتيوب د. يوسف حسين

A- Nerves in front the auricle

A- Branches of the ophthalmic nerve.

a. **Supratrochlear nerve (Sensory)**: leaves the orbit through supratrochlear notch

b- **Supraorbital nerve (Sensory)**: leaves the orbit through supraorbital notch or foramen

B- Branch of the maxillary nerve. - **Zygomaticotemporal nerve (Sensory)**

C- Branch of the mandibular nerve. **Auriculotemporal nerve (Sensory)** enters the parotid gland and leaves it through the upper end to the scalp

D-**Temporal branch of the facial nerve (motor)**:

اليوثيوب د. يوسف حسين

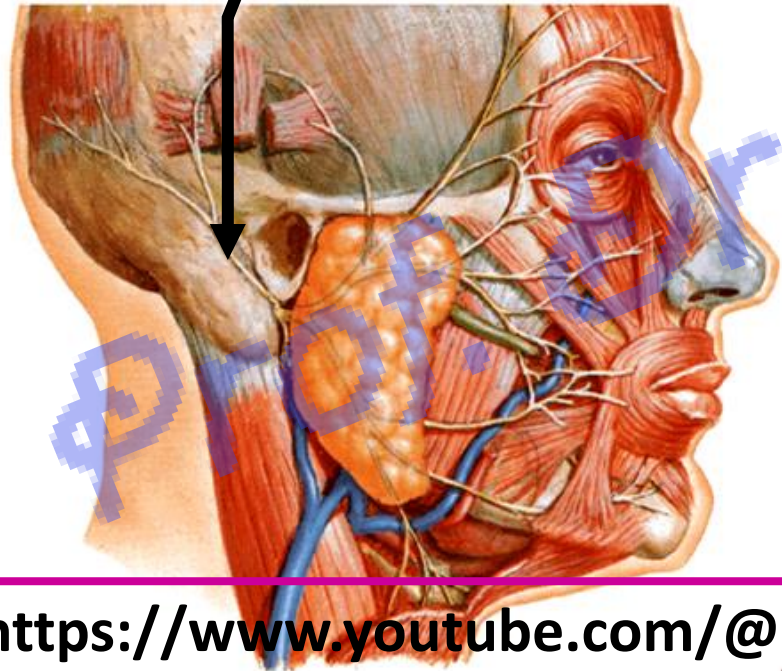
- It leaves the parotid gland through the upper end.

- It supplies **frontal** belly of occipitofrontalis and auricularis muscles.

Nerves behind auricle

S=C2 Greater occipital nerve

Posterior auricular nerve
M



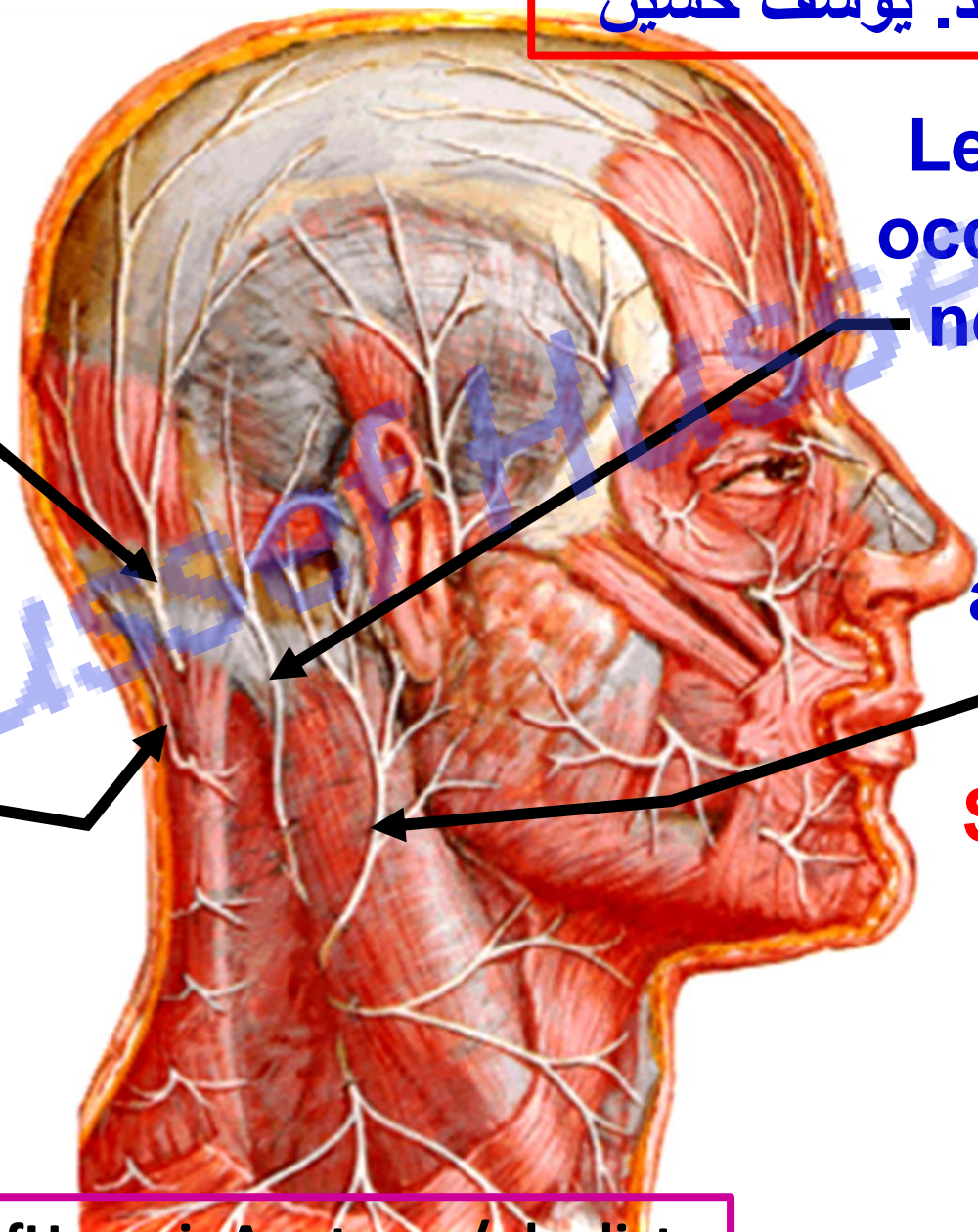
3rd occipital nerve
S=C3

Lesser occipital nerve

S=C2

Great auricular nerve

S=C2&3



B- Nerves behind the auricle

1- Great auricular nerve (sensory): Branch of cervical plexus (ventral rami of C2&3).

2- Lesser occipital nerve (sensory): Branch of cervical plexus (ventral rami of C2).

3- Greater occipital nerve (sensory): Branch of the dorsal rami of C2.

- **The thickest cutaneous nerve of the body**, supplies greater part of the back of the scalp.

4- Third occipital nerve (sensory): branch from the dorsal rami of C3.

5- Posterior auricular nerve (motor): a branch of the facial nerve.

- It supplies occipital belly of occipitofrontalis and auricularis muscles.

اليوتوب د. يوسف حسين

Blood supply of scalp

اليوتيوب د. يوسف حسين

- The scalp is supplied by **5 arteries** on each side.
- **3 in front** of the auricle
- **2 behind** the auricle

Posterior Auricular artery

Supratrochlear artery

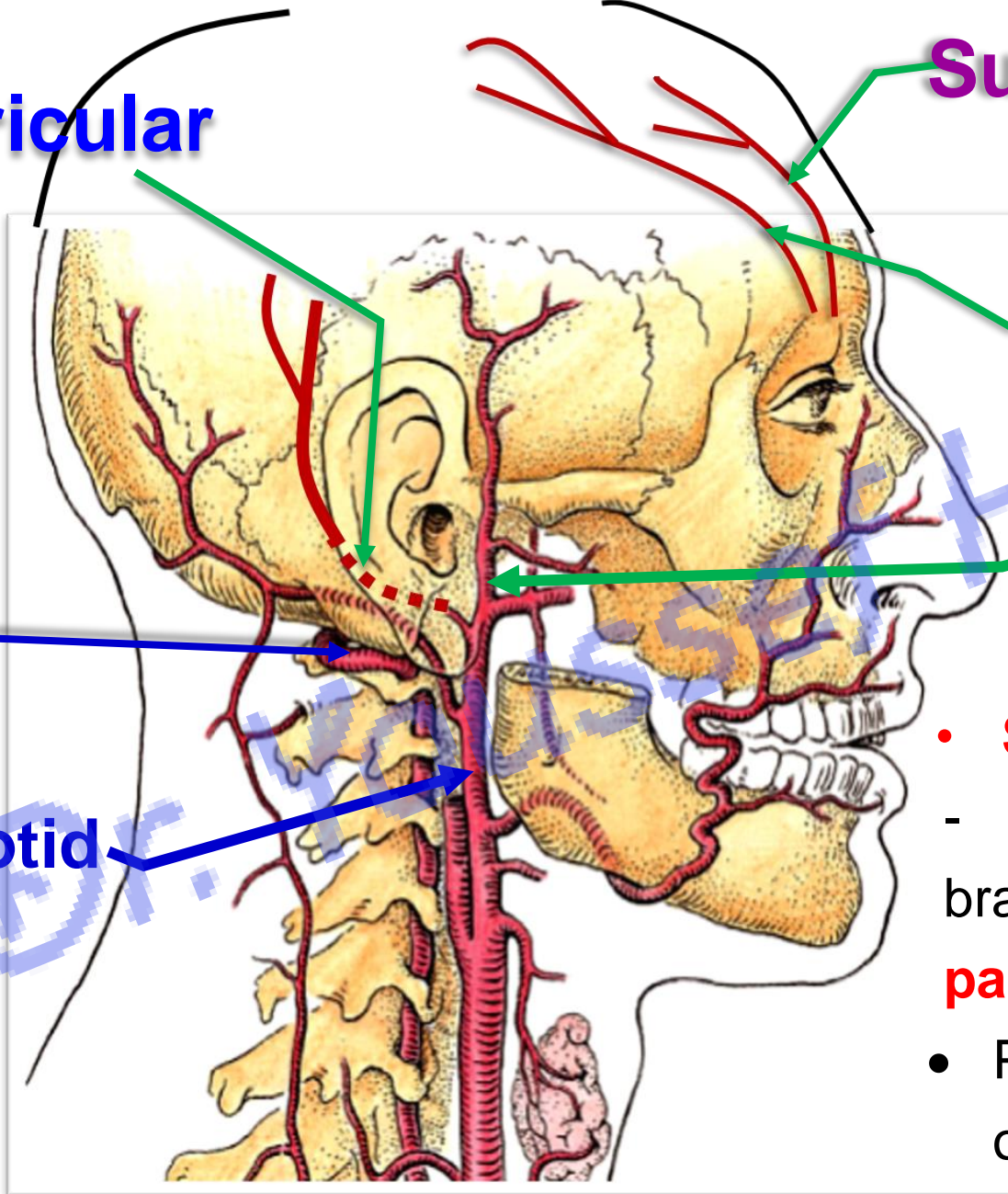
Ophthalmic artery

Supraorbital artery

occipital artery

Superficial temporal artery

External carotid artery



- **Superficial temporal artery:**
 - The smallest terminal branches of ECA **inside the parotid gland.**
 - **Pulsation** can be felt in front of auricle.

Superficial temporal vein

Supratrochlear vein

Supraorbital vein

Retromandibular vein
Inside parotid gland

Maxillary vein

Posterior auricular vein

Facial (angular) vein

Posterior division

Anterior division

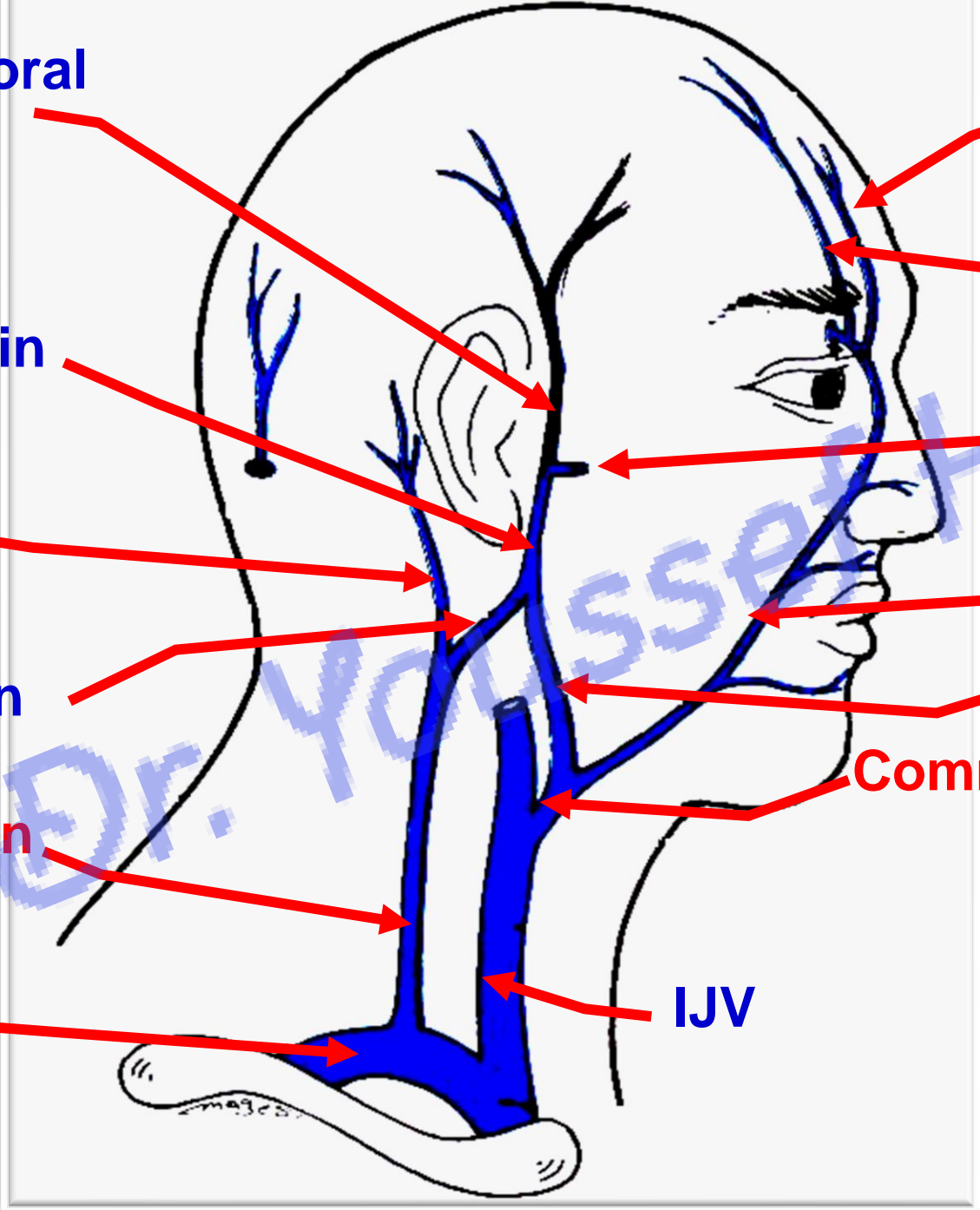
External jugular vein

Common Facial vein

Subclavian vein

IJV

اليوثيوب د. يوسف حسين



- **Veins of the scalp**

1- Supraorbital and supratrochlear veins;

- They unite at the medial angle of eye to form **anterior facial vein (angular)**.

2- Superficial temporal vein; enters the parotid gland.

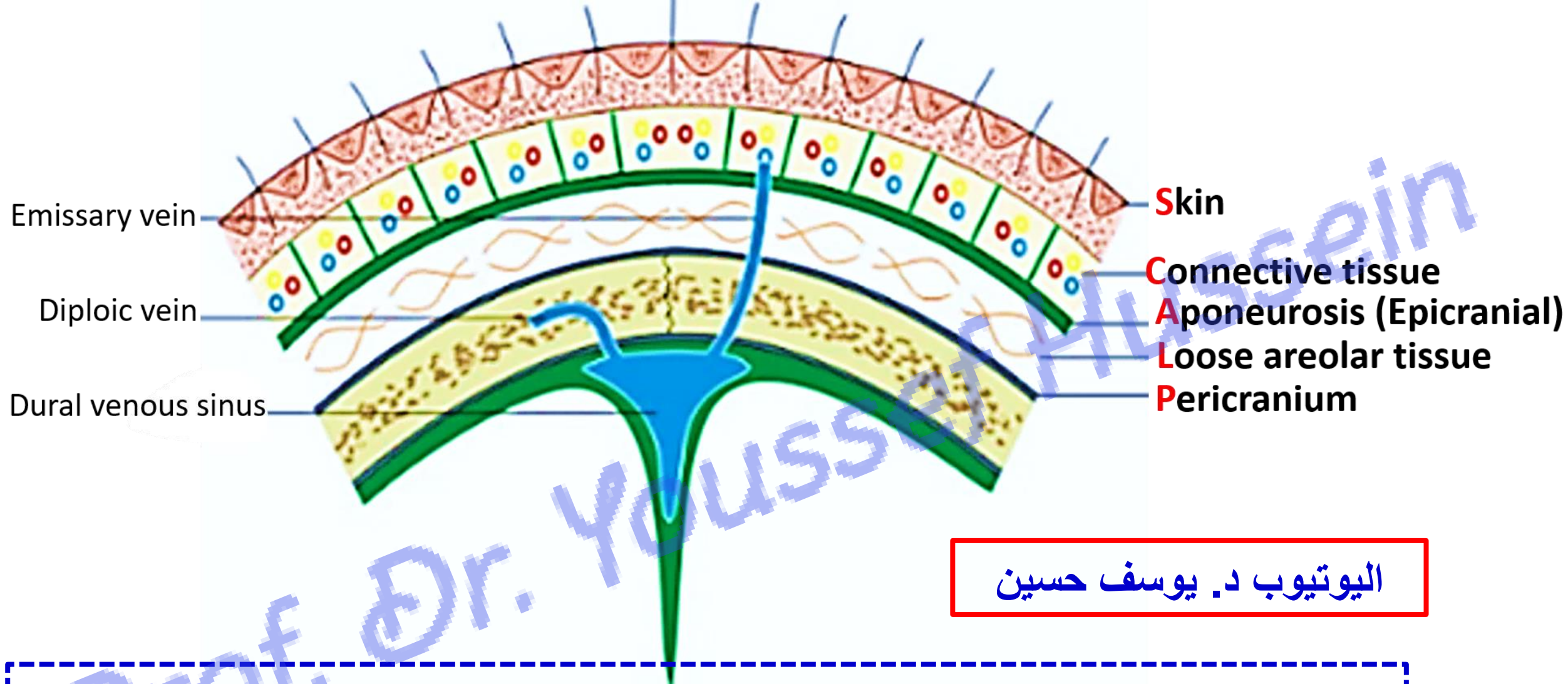
- Inside the gland, it fuses with the **maxillary vein** to form the **retromandibular vein** that divided into anterior and posterior divisions.

3- Posterior division of retromandibular vein unites with **Posterior auricular vein** to form the **external jugular vein** that ends in the **subclavian vein**.

**** Anterior division of the retromandibular vein** unites with the **anterior facial vein** forming the **common facial vein** that ends in the **internal jugular vein**.

اليوتيوب د. يوسف حسين


<https://www.youtube.com/@ProfDrYoussefHusseinAnatomy/playlists>



الـيـوتـيـوب د. يـوسـف حـسـين

- **Scalp infection** localized in the **loose areolar layer** spreads to the intracranial dural venous sinuses through **emissary veins (valveless)**, causing **meningitis** or **septicemia**.

<https://www.youtube.com/@ProfDrYoussefHusseinAnatomy/playlists>



يُمنع أخذ السلايدات بدون
إذن المحرر واي اجراء
يخالف ذلك يقع تحت
طائلة المسؤولية القانونية

اليوتيوب د. يوسف حسين

Thank You

Questions

Prof. Dr. Youssef Hussein Anatomy - YouTube

الواتس 00201224904207