Wondershare EdrawMind

Thyroid gland pathology.

Non neoplastic:

- THYROTOXICOSIS
  - Hypermetabolic state caused by elevated T4, T3. causes :
    - associated with hyperthyroidism
      - primary *the problem arising from thyroid gland itslef
        - diffuse toxic hyperplasia (graves disease)
        - hyperfunctioning (toxic)multinodular goiter
        - hperfunctioning (toxic) adenoma
        - idoine-induced hyperthyroidism
      - secondary *the problem arising from outside the thyroid,usually from pituitary adenoma
        - TSH- secreting pituitary adenoma *rare
    - not associated with hyperthyroidism
      - granulomatous (de Quervain) thyroiditis *painful
      - subacute lymphocytic thyroiditis *painless
      - struma ovarii (ovarian teratoma with thyroid) * teratoma :a neoplastic process arising from germ cell layer
      - fastitious thyrotoxicosis (exogenous thyroxine intake)
- Hyperthyroidism.
  - clinical manifestation
    - hair loss, sweating, enlarged thyroid , irritability, temor of fingers, infertility, muscle weakness ,rapid heartbeat , difficulty sleeping , weight loss , nervousness , warm moist palms , frequent bowel movement , soft nails , bulging eyes , heat intolerance , scant menstrual period
  - Diagnosis:
    - 1. TFT.
    - 2. Radioactive Iodine uptake
- Hypothyroidism.
  - Hypothyroidism is caused by structural or functional derangements that interfere with thyroid hormone production.
  - clinical manifestation
    - dry hair ,puffy face , enlarged thyroid , slow heartbeat, arthritis , cold intolerance , loss of eyebrow hair , depression , dry skin, fatigue , forgetfulness, menstrual disorders , infertility, muscle aches , weight gain , constioation , brittle nails
      -characteristicor typical face of hpothyroidism : apathetic facies , bilateral ptosis , absent eyebrows
  - causes
    - primary
      - -postablative :part of the normal thyroid gland is removed or gone by : surgery, radiotherapy or external irradiation .
        -autoimmune hypothyroidism : hashimoto thyroditis
        -iodine deficiency
    - secondary
      - pituitary failure (rare)
      - hypothalamic failure (rare)
  - CRETINISM
    - Cretinism refers to hypothyroidism developing in infancy or early childhood.
    - common in areas of the world where **dietary iodine deficiency** is endemic.
    - Clinical features: impaired development of the skeletal system and central nervous system,severe mental retardation,short stature,coarse facial features, a **protruding tongue,** umbilical hernia
- Autoimmune Thyroid Disease
  - Hashimoto Thyroiditis .
    - Autoimmune disease characterized by progressive destruction of thyroid tissue
    - -Commonest type of thyroiditis,-Commonest cause of hypothyroidism in areas of sufficient iodine levels
    - F:M = 10 20 :1, 45 65 yrs
      Patient presented with Painless symmetrical diffuse goiter
    - Pathogenesis
      - breakdown in slef-tolerance and induction of thyroid autoimmunity
        - CD8+ cytotoxic T-cell
          - cause T-cell-mediated cytotoxicity
        - CD4+ (TH1 cell)
          - release of INF-γ which activate macrophages and cause thyrocyte injury
        - plasma cell
          - produce anti-thyroid antibodies causes antibody-dependent cell-mediated cytotoxicity examples :anti-thyroglobulin ,antithyroid peroxidase
    - Morphology
      - Gland is a smooth pale goiter, minimally nodular, well demarcated.
    - Microscopic
      - 1-Dense infiltration by lymphocytes & plasma cells 2-Formation of lymphoid follicles, with germinal centers 3-Presence of HURTHLE CELLS ** hurthle cells are bigger and have eosinophilic cytoplasm due to abnormal mitochondria associated with this disease
  - de Quervain Thyroiditis.
    - Also called subacute granulomatous thyroiditis ,Middle aged , more in females. Viral etiology ? *most of the females who diagnosed as de quervain thyroiditis might have some elements of viral infection previous to this presentation
    - Self limited (6 8w)
      Acute onset of pain in the neck , fever,
      ↑ESR * acute phase reactant which elevat in process of acute inflammation ,
      ↑ WBC * leukocytosis
      Transient thyrotoxicosis=* ↑ T4
    - Morphology
      - Destruction of acini leads to mixed inflammatory infiltrate.
        Neutrophils , Macrophages & Giant cells & formation of granulomas.
  - Subacute Lymphocytic Thyroiditis (silent)
    - -Middle aged females & post partum patients
      -Probably autoimmune with circulating AB.
      -May recur in subsequent pregnancies
      -May progress to hypothyroidism* means its not slef limited
    - Morphology
      - -Preserved lobular pattern with follicular destruction.
        -variable lymphocytic infiltrate.
        -rare / no oncocytic change.*means there is no hurthle cells
        -no / focal fibrosis
  - Graves Disease.
    - Autoimmune disease characterized by hyperthyroidism due to circulating autoantibodies against thyrotropin (TSH receptor) that activates the receptor, leading to increased thyroid hormone synthesis and secretion and growth of the thyroid gland
    - -Commonest cause of endogenous hyperthyroidism
      -Age 20 40 y.
      -M: F ratio is 1 : 7
      -More common in western races
    - Associated with * has extrathyroidal manifestations
      - 1-diffuse goiter. 2-infiltrative ophthalmopathy
        3 infiltrative dermopathy , including: -pretibial myxedema
        -thyroid acropachy (extremity swelling, clubbing of fingers and toes due to periosteal new bone formation)
    - Diagnosis
      - clinically by symptoms.
      - presence of laboratory markers of hyperthyroidism. (Increased T3 / T4, increased uptake of radioactive iodine, decreased TSH).
      - presence of serum anti thyrotropin antibodies. (thyroglobulin, thyroid peroxidase, sodium iodide symporter and thyrotropin / TSH receptor).
    - Pathogenesis
      - -Exact cause is unclear.
        -It is believed to involve a combination:
        1-Genetic (Caused by B and T cell mediated immune responses leading to production of autoantibodies to thyrotropin / TSH receptor).
        2-environmental factors (Onset of disease may be triggered by stress, infection or giving birth).
        -May exist with other similar diseases e.g. SLE , Pernicious anemia, Diabetes type I , Addison's dis.
    - Morphology.
      - Diffuse and symmetrically enlarged thyroid gland with beefy red cut surface.
    - Histology
      - •Hyperplastic thyroid follicles with papillary infoldings
        •Colloid is typically decreased, when present shows peripheral scalloping
  - Reidel'sThyroiditis
    - is densely fibrotic inflammatory process involving thyroid gland and adjacent neck tissue,,65% have antithyroid antibodies
      - Clinically resembles carcinoma. * because the fibrosis is not only affecting the thyroid ,the fibrosis involving thyroid will get out and causes thyroid fixation which is a sign of malignant tumor "carcinoma"
    - Morphology
      - Follicles are obliterated or compressed by extensive dense fibrous tissue
- Diffuse and Multinodular Goiter
  - 1-**Goiter** is clinical term meaning enlarged thyroid, which can be either diffuse or nodular (e.g. multinodular or solitary / dominant nodule)
    2- **Multinodular goiter**: irregular enlargement of thyroid gland due to repeated episodes of hyperplasia and involution (degeneration)
    3-Iodine deficiency is most common cause worldwide
    4- 90% of those affected are women (F > > > M)
    5-Variable age; develops more frequently during adolescence and pregnancy.
    6-Increase in TSH secretion is the main cause in iodine deficiency related goiter..
  - types
    - Endemic : 10 % of population have goiter
    - Sporadic : 1- Physiological demand
      2-Dietary intake of excessive calcium & cabbages.
      3-Hereditary enzyme defects
  - Clinical features
    - -neck mass
      -Majority asymptomatic and euthyroid
      -Pressure symptoms due to compression of trachea and esophagus
  - Diagnosis
    - 1-Clinical examination
      2-Thyroid function tests: TSH, T3, T4
      (Usually normal T3 / T4, TSH, normal radioactive iodine uptake)
      3-Thyroid peroxidase antibodies
      4-Thyroid ultrasound
      5-CT or MRI to evaluate extent of goiter
  - Morphology
    - Multinodular goiters are asymmetric, large
      Nodular,bumpy outer surface and variegated cut surface
  - Histology
    - 1-Variable sized dilated follicles with flattened to hyperplastic epithelium.
      2-Nodules may be present.

Neoplastic

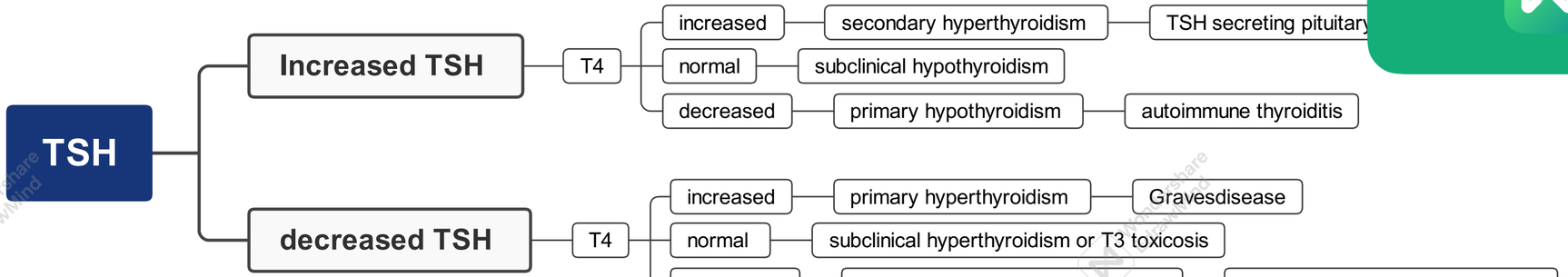

Wondershare EdrawMind