



# الطب والجراحة لبننة

Lab Anatomy – exam

دفعة وٲين 2020

**Q1- The structure with star is :**

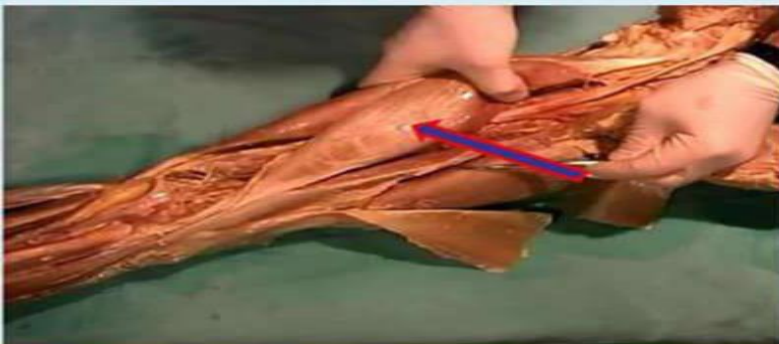


**:Select one**

- a. Radial groove**
- b. Deltoid Tuberosity**
- C. Femur shaft**
- d. Bicipital groove**
- e. Condylar ridge**

**Answer:D**

**Q2- What is the labelled structure?**

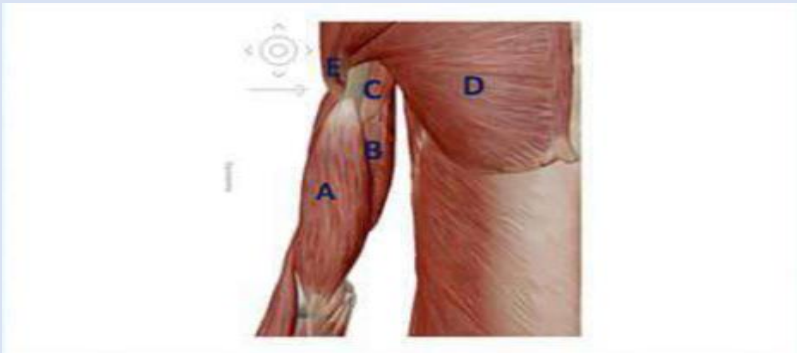

**Select one:**

- a. Semimembranosus**
- b. short head of biceps**
- c. Semitendinosus**
- d. Biceps**
- e. Long head of biceps**

**Answer :E**

**Q3- Which label corresponds to the CORACOBRACHIALIS muscle?**



**Select one:**

- a. A
- b. B
- c. C
- d. D
- e. E

**Answer: C**

**Q4- The blue end of the clavicle in this figure is**

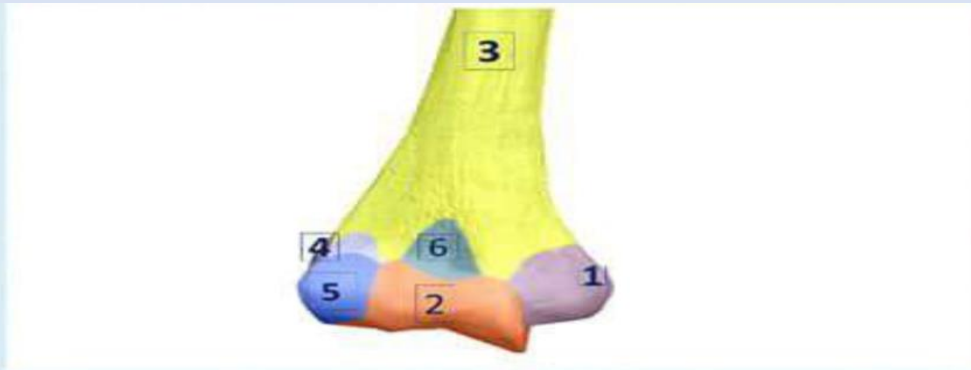

**Select one:**

- a. Sternal end
- b. Lateral end
- c. Acromial end
- d. Superior end
- e. Lower end

**Answer: A**

**Q5- All the labeled structures in the figure related to the Distal end of the humerus EXCEPT:**

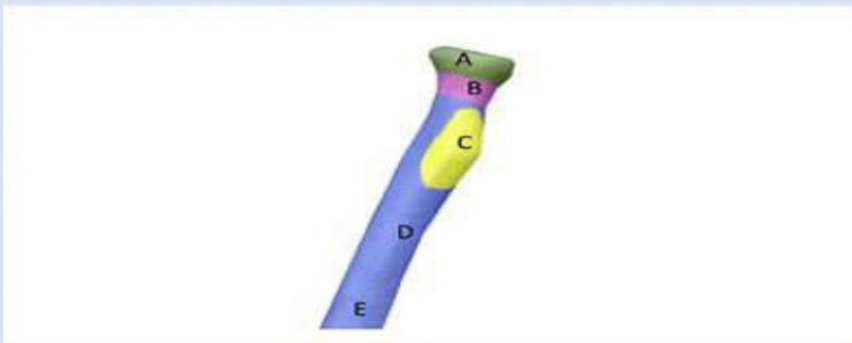


**:Select one**

- a. 1
- b. 6
- c. 4
- d. 3
- e. 5

**Answer:D**

**Q6- Structure B is?**

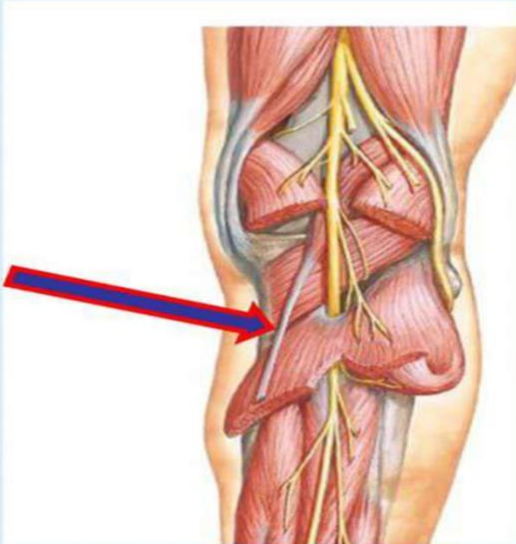


**Select one:**

- a. Neck of radius
- b. Head of radius
- c. Shaft
- d. Radial ligament
- e. Insertion of Biceps

**Answer:A**

**Q7- What is the labelled structure?**

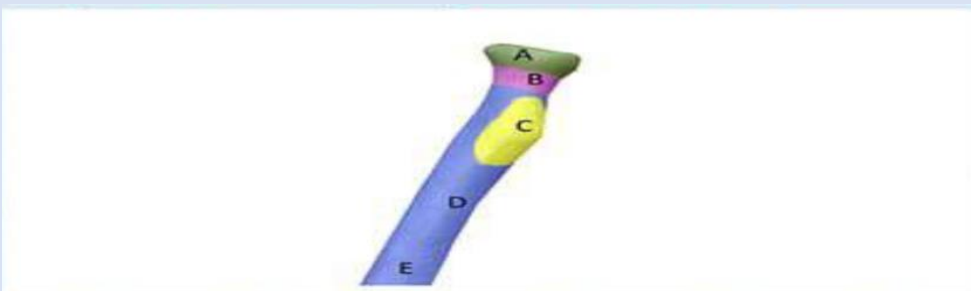


**Select one:**

- a. Soleus**
- b. Plantaris**
- c. Lateral head of gastrocnemius**
- d. Posterior tibial nerve**
- e. Medial head of gastrocnemius**

**Answer:B**

**Q8- Bicipital tuberosity is structure?**

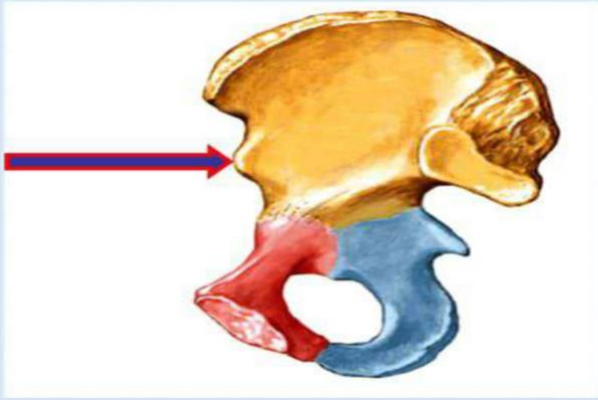


**Select one:**

- a. A**
- b. B**
- c. C**
- d. D**
- e. E**

**Answer:C**

*What is the labelled structure?*

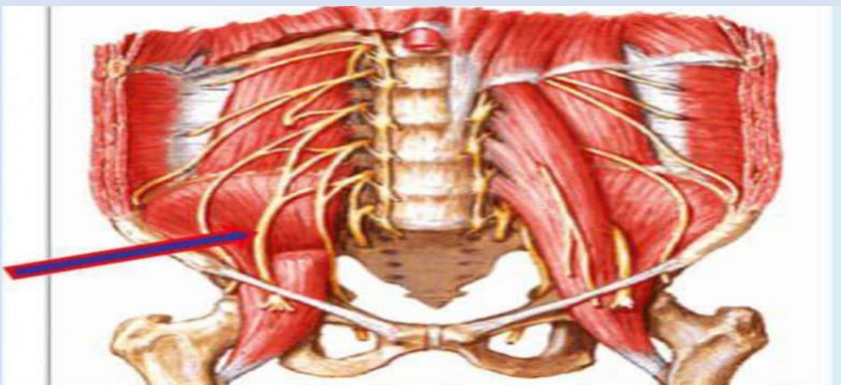


*Select one:*

- a. Posterior superior iliac spine*
- b. Anterior superior iliac spine*
- c. Iliopectineal eminence*
- d. Anterior inferior iliac spine*
- e. Posterior inferior iliac spine*

*Answer:D*

*Q10- What is the labelled structure?*

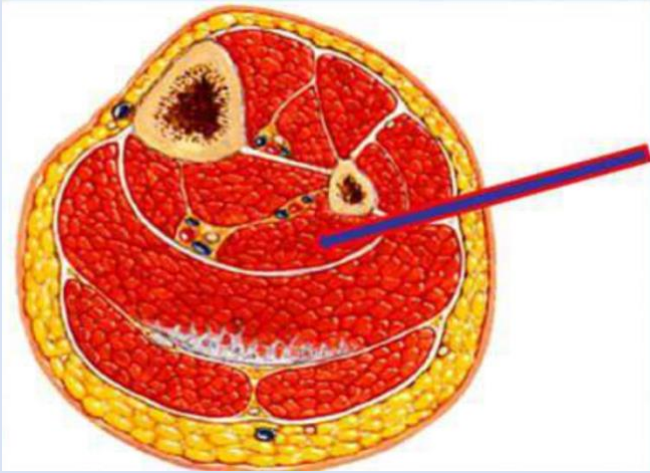


*Select one:*

- a. Femoral nerve*
- b. Lateral cutaneous nerve of the thigh*
- c. Obturator nerve*
- d. Genitofemoral*

*Answer:A*

**Q11- What is the labelled structure?**

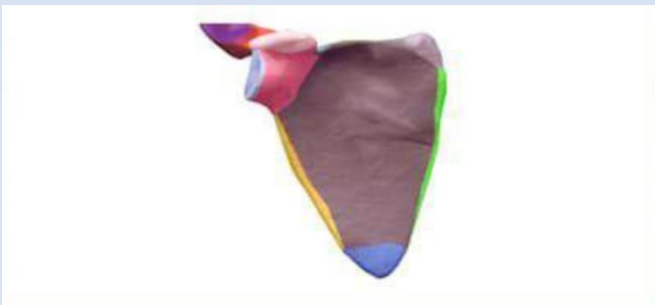


**Select one:**

- a. Tibialis posterior**
- b. Flexor hallucis longus**
- c. Soleus**
- d. Flexor digitorum longus**
- e. Peroneus longus**

**Answer:B**

**Q12- The type of this BONE is**

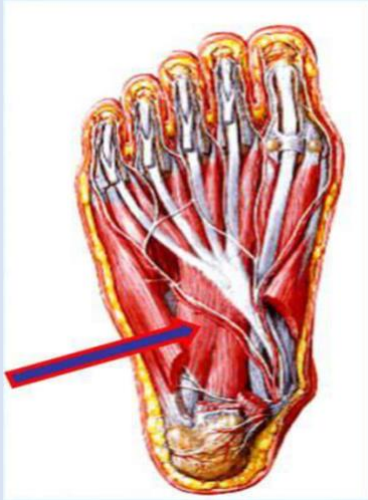


**Select one:**

- a. Flat bone**
- b. Long bone**
- c. Short bone**
- d. Irregular bone**
- e. Sesamoid bone**

**Answer:A**

**Q13- What is the labelled structure?**

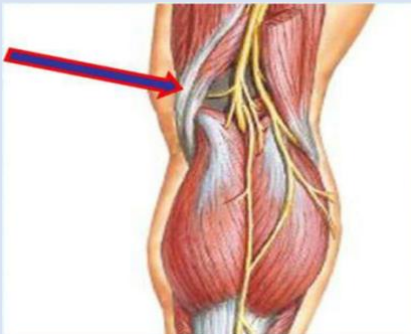

**Select one:**

- a. Flexor digitorum accessories**
- b. Oblique head of adductor hallucis**
- c. Flexor digitorum brevis**
- d. The 2nd lumbricals**
- e. Abductor digiti minimi brevis**

**Answer:A**

**Q14- What is the labelled structure?**



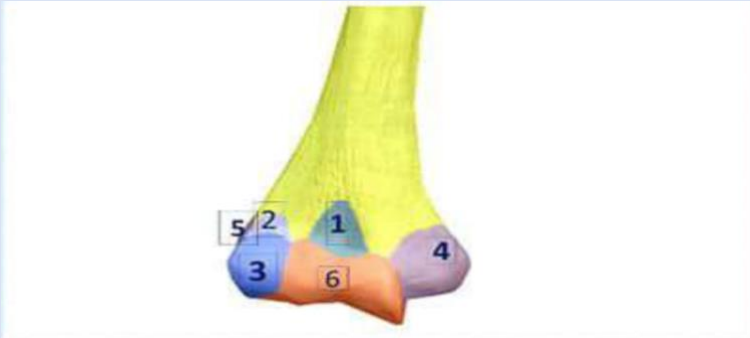**Select one:**

- a. Biceps**
- b. Semitendinosus**
- c. Lateral head of gastrocnemius**
- d. Semimembranosus**
- e. Medial head of gastrocnemius**

**Answer:B**



**Q15- STRUCTURE 1 is:**

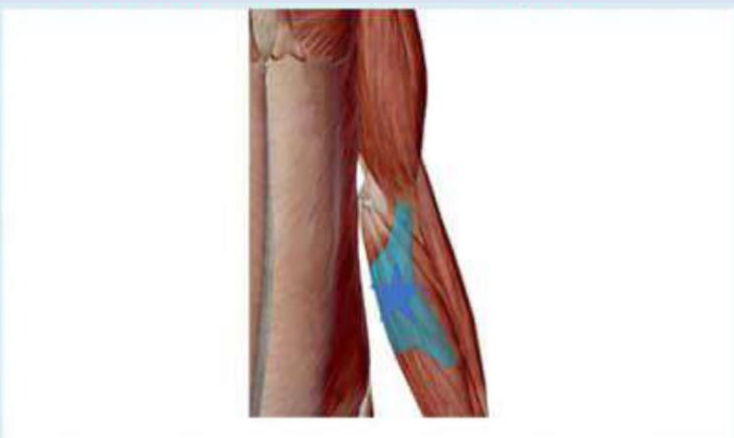

**Select one:**

- a. Coronoid fossa**
- b. Olecranon fossa**
- c. Radial fossa**
- d. Medial epicondyle**
- e. Lateral epicondyle**

**Answer:A**

**Q16- The blue structure (starred) is**

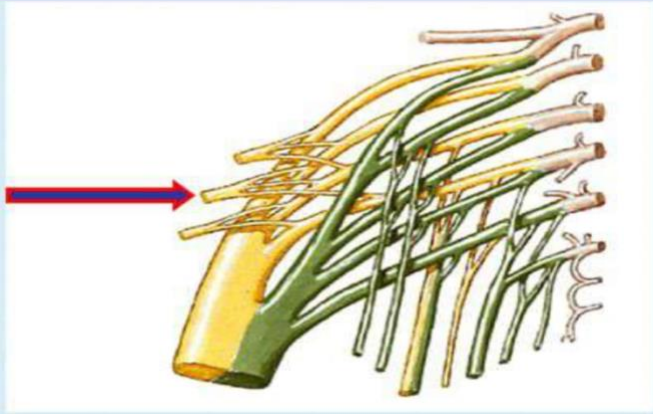


**Select one:**

- .a. Biceps brachii**
- .b. Bicipital aponeurosis**
- .c. Bicipital tendon**
- d. Short head of biceps**
- e. Long head of biceps**

**Answer:B**

**Q17- What is the labelled structure?**

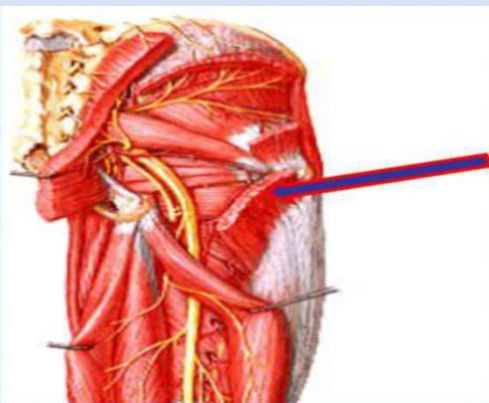


**Select one**

- a. Posterior cutaneous nerve of thigh**
- b. Inferior gluteal nerve**
- c. Nerve to piriform**
- d. Sciatic nerve**
- e. Superior gluteal nerve**

**Answer:B**

**Q18- What is the labelled structure**

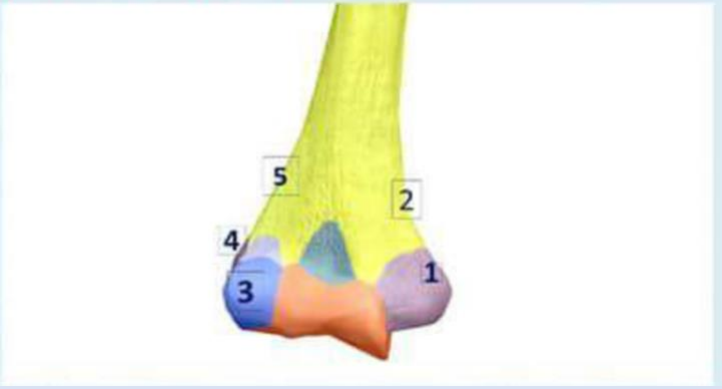

**Select one**

- a. Gluteus maximus**
- b. Superior gemellus**
- c. Gluteus minimums**
- d. Piriform**
- e. Quadratus feomris**

**Answer :A**

Q19- In this figure, MEDIAL CONDYLE of the femur is number



Select one:

- a. 1
- b. 2
- c. 3
- d. 4
- e. 5

Answer:A

لا تنسونا من صالح دعائكم  
بالتوفيق  
لجنة الطب والجراحة