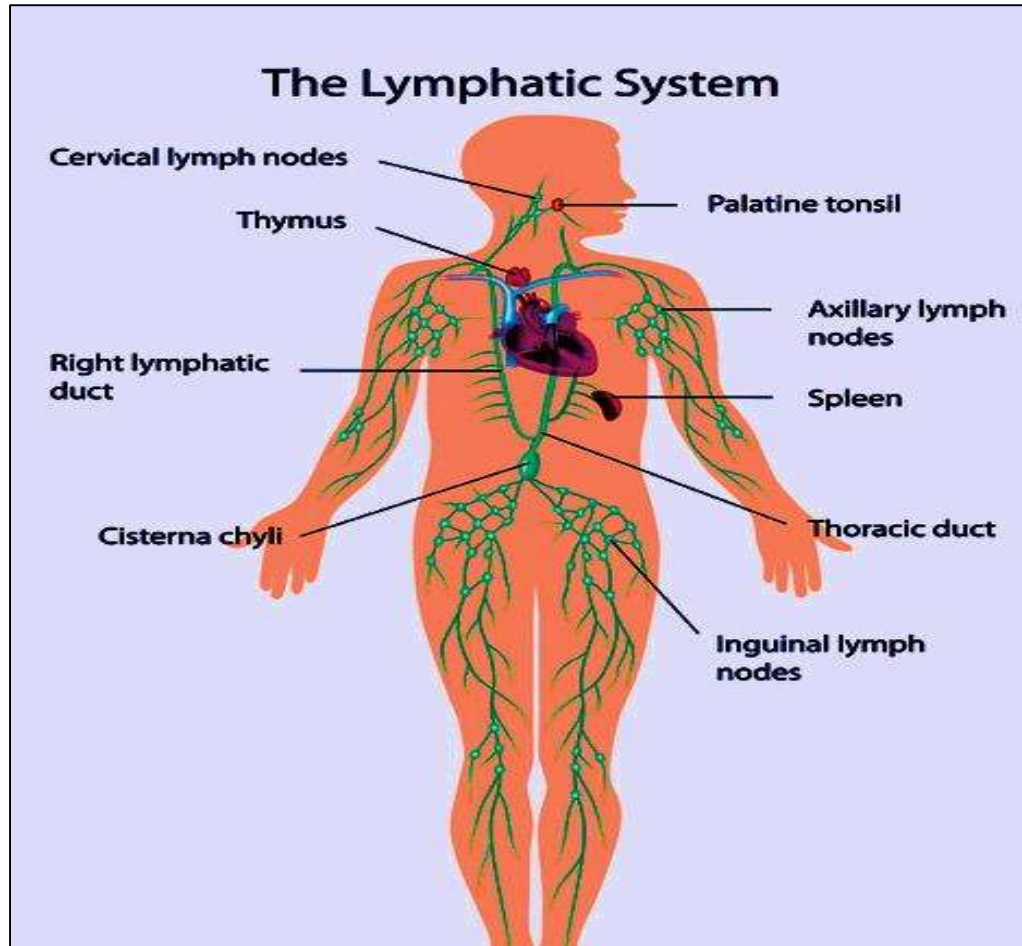


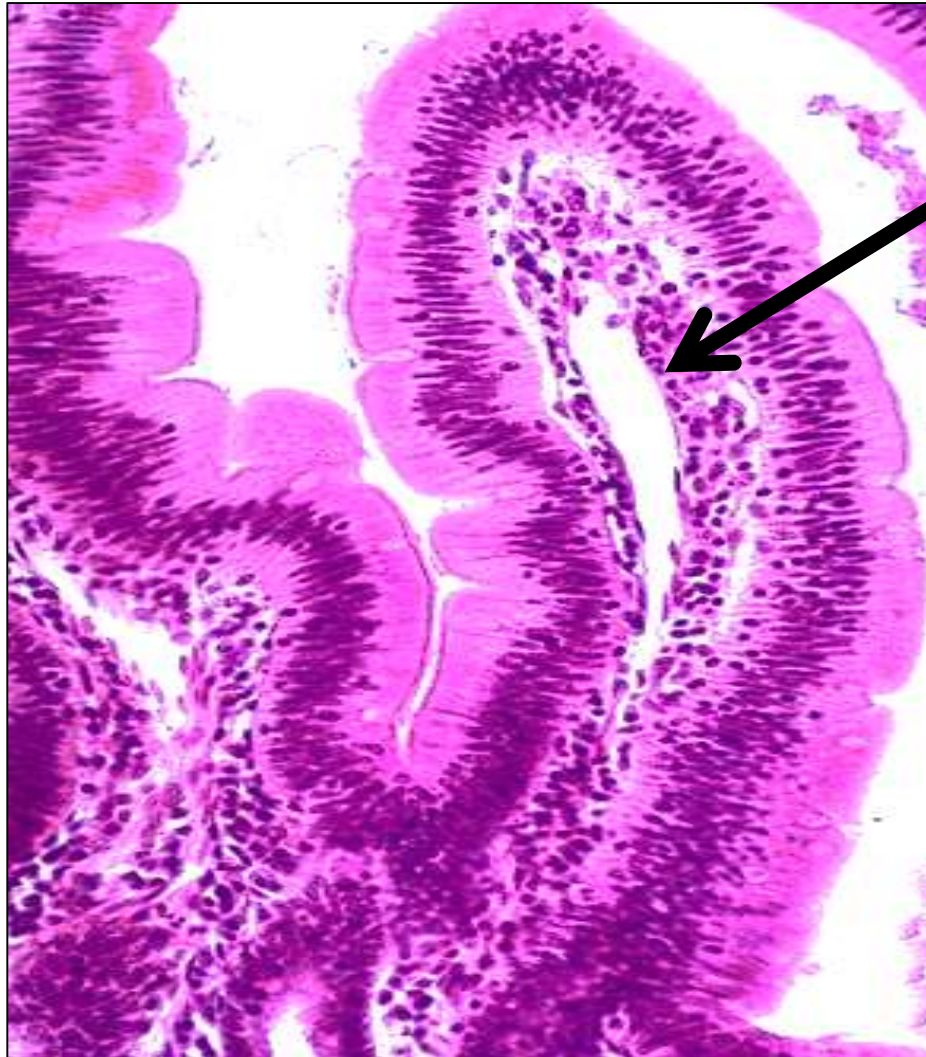
# Lymphatic system practical slides

Professor Dr. Hala El-mazar

2023



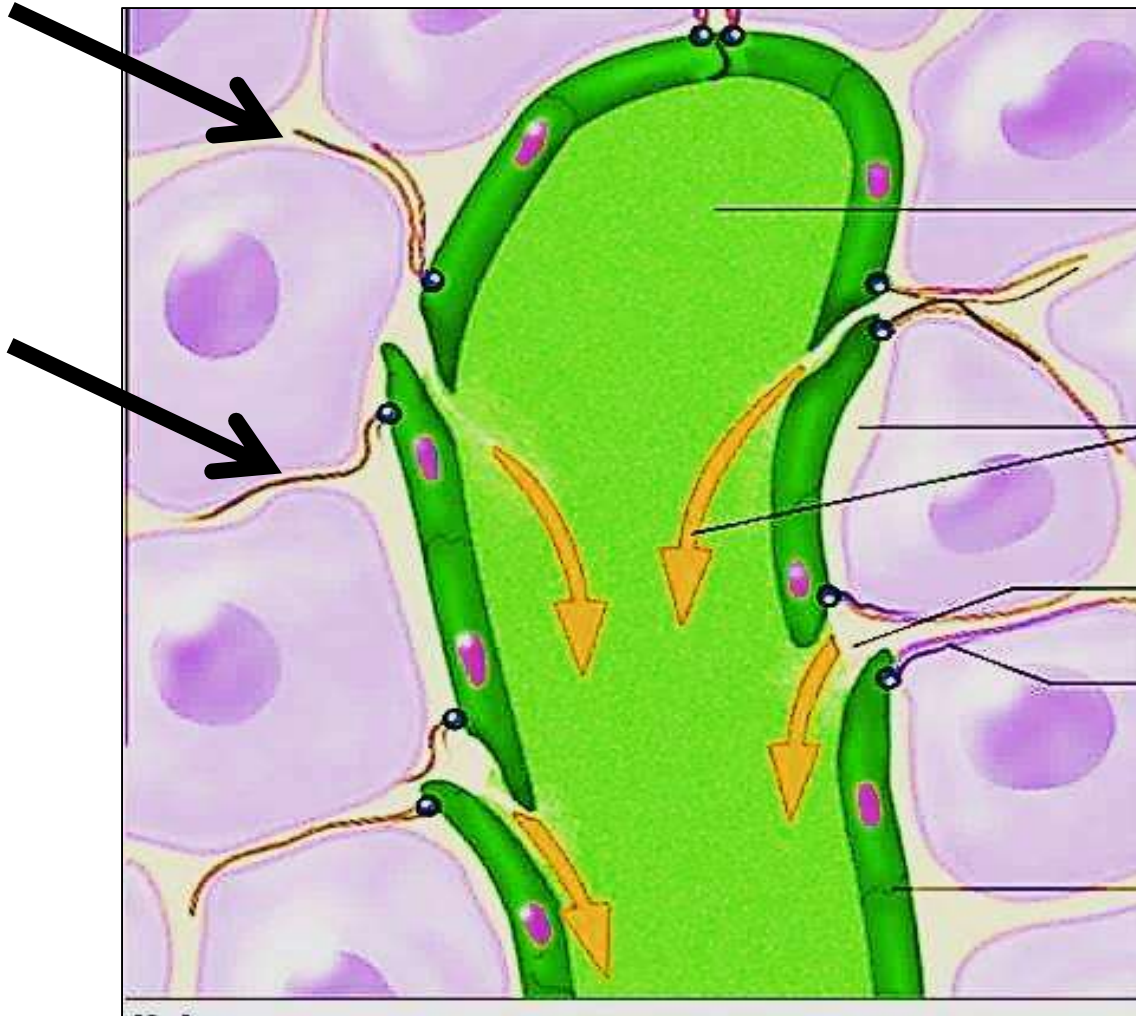
# Small intestine/ villus/ lacteal



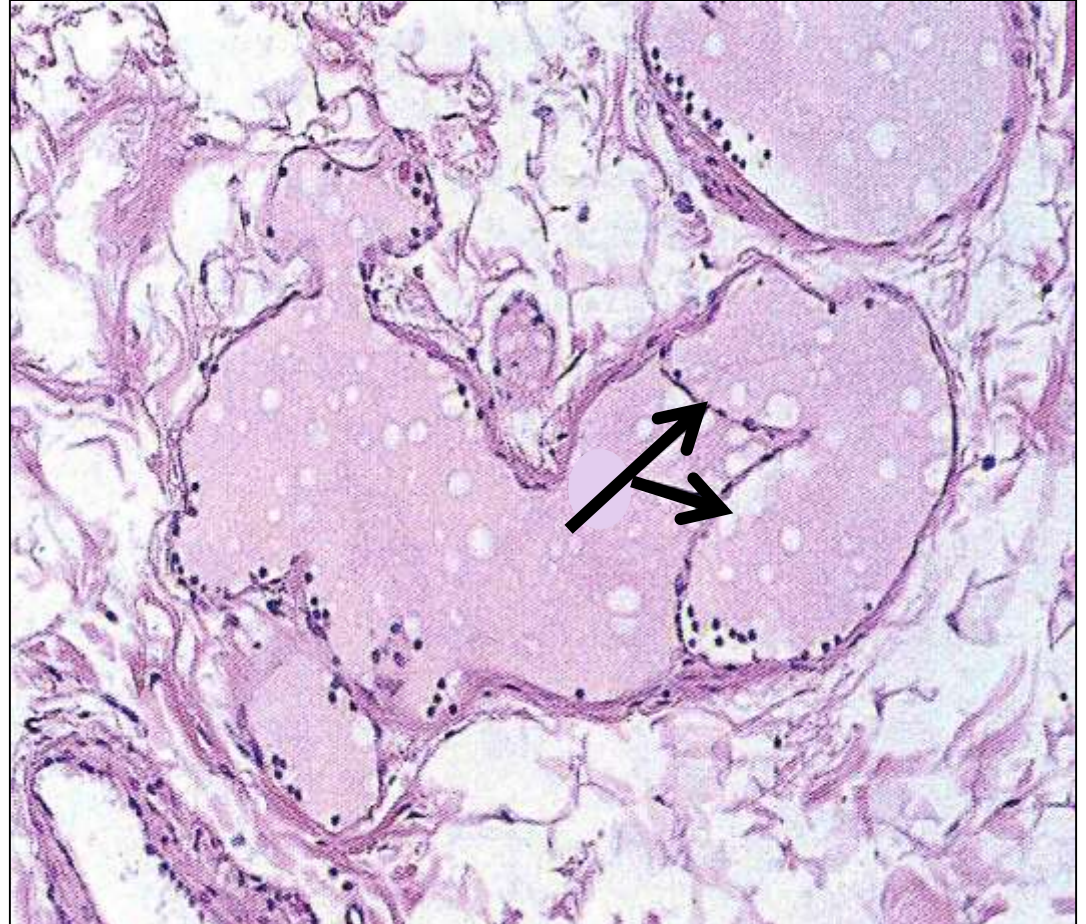
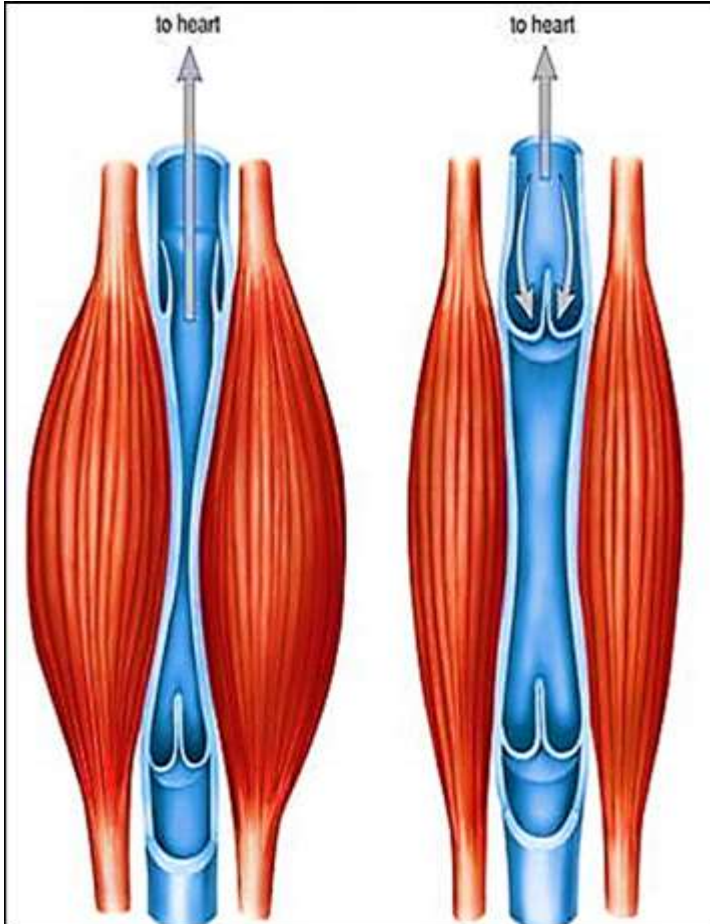
Lacteal  
(lymphatic capillary)



# Anchoring filaments



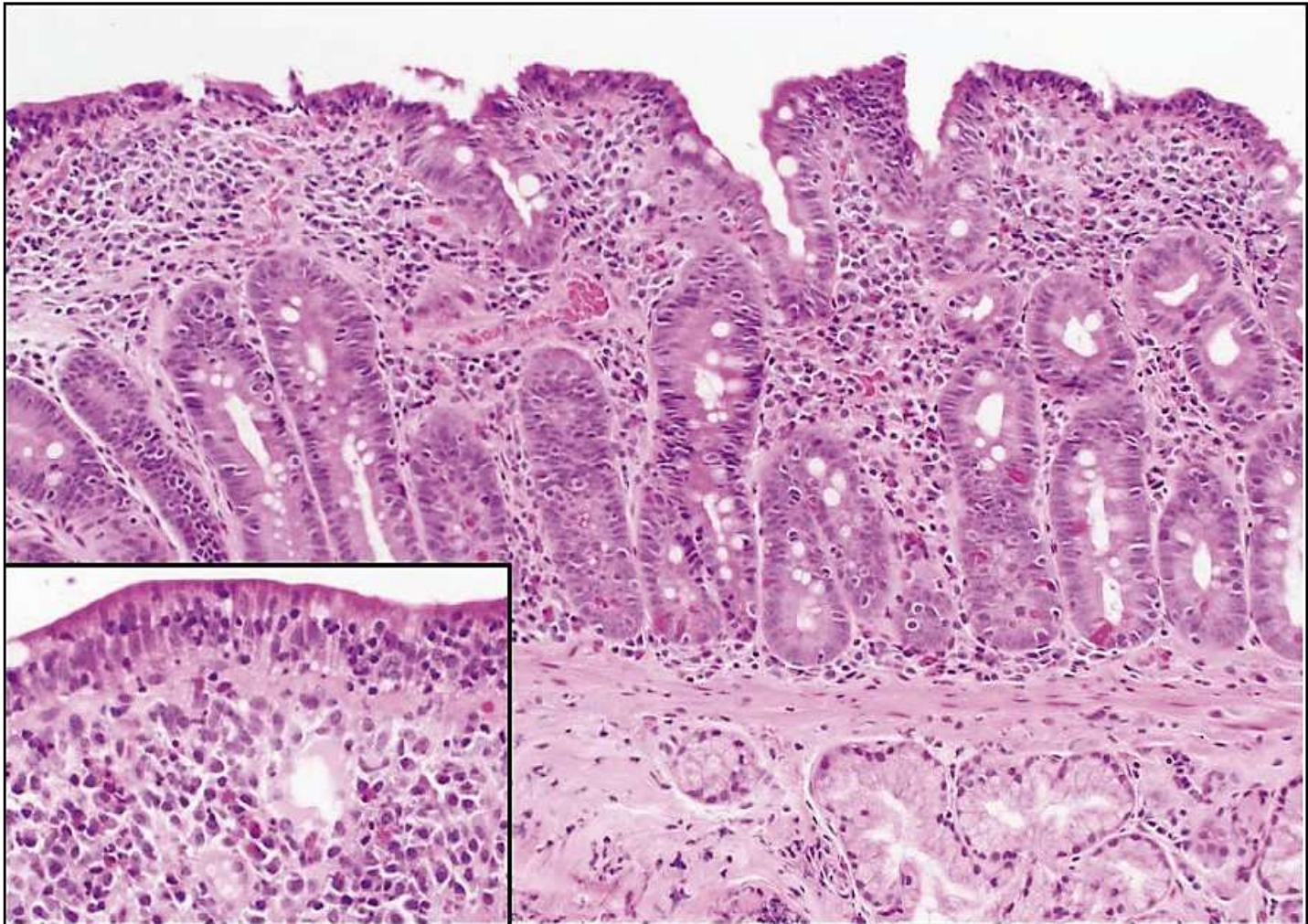
# Section on lymphatic vessel showing bicuspid valve



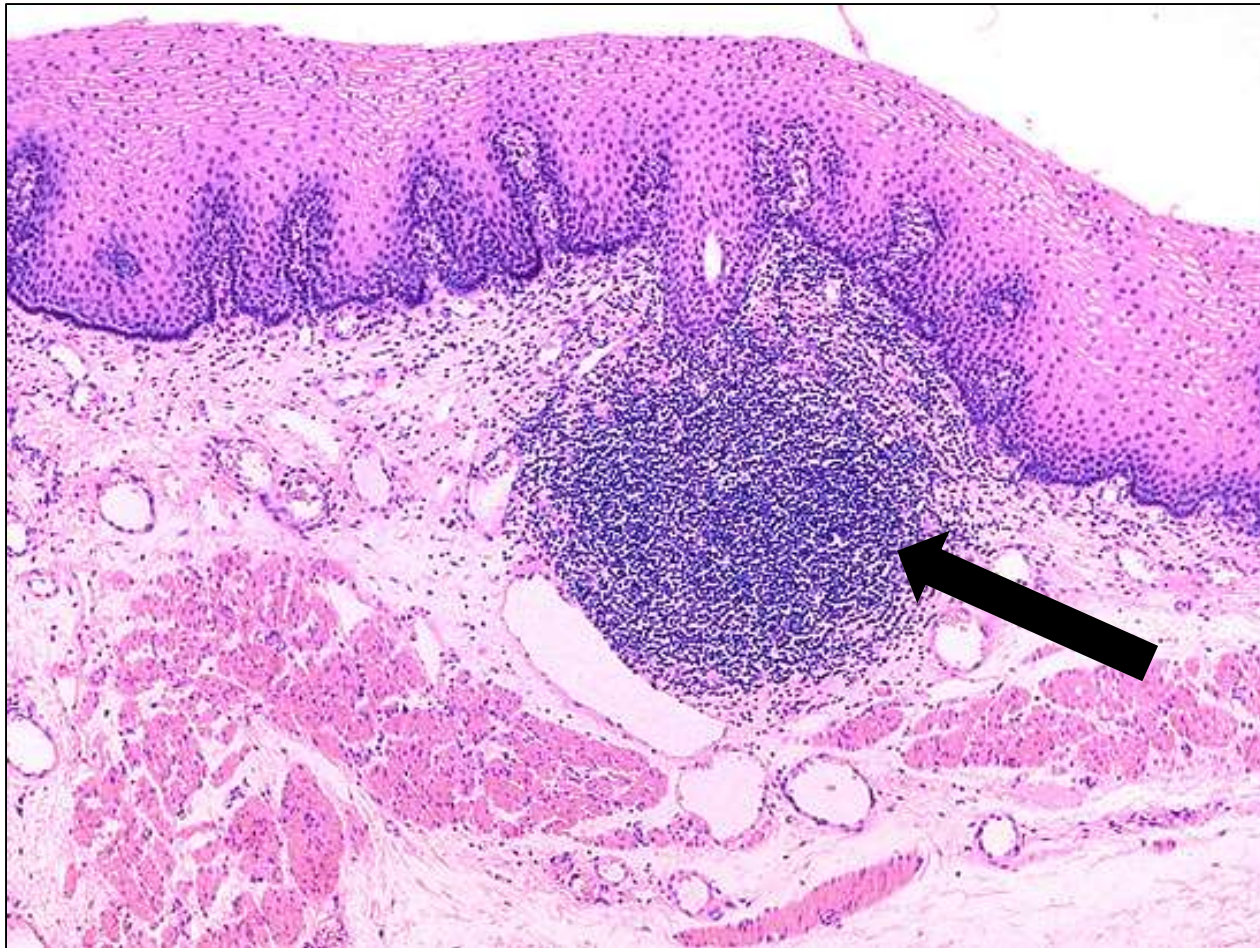**Lymphatic vessels & bicuspid valves**



# Gut associated lymphoid tissue/ GALT/ diffuse lymphoid tissue



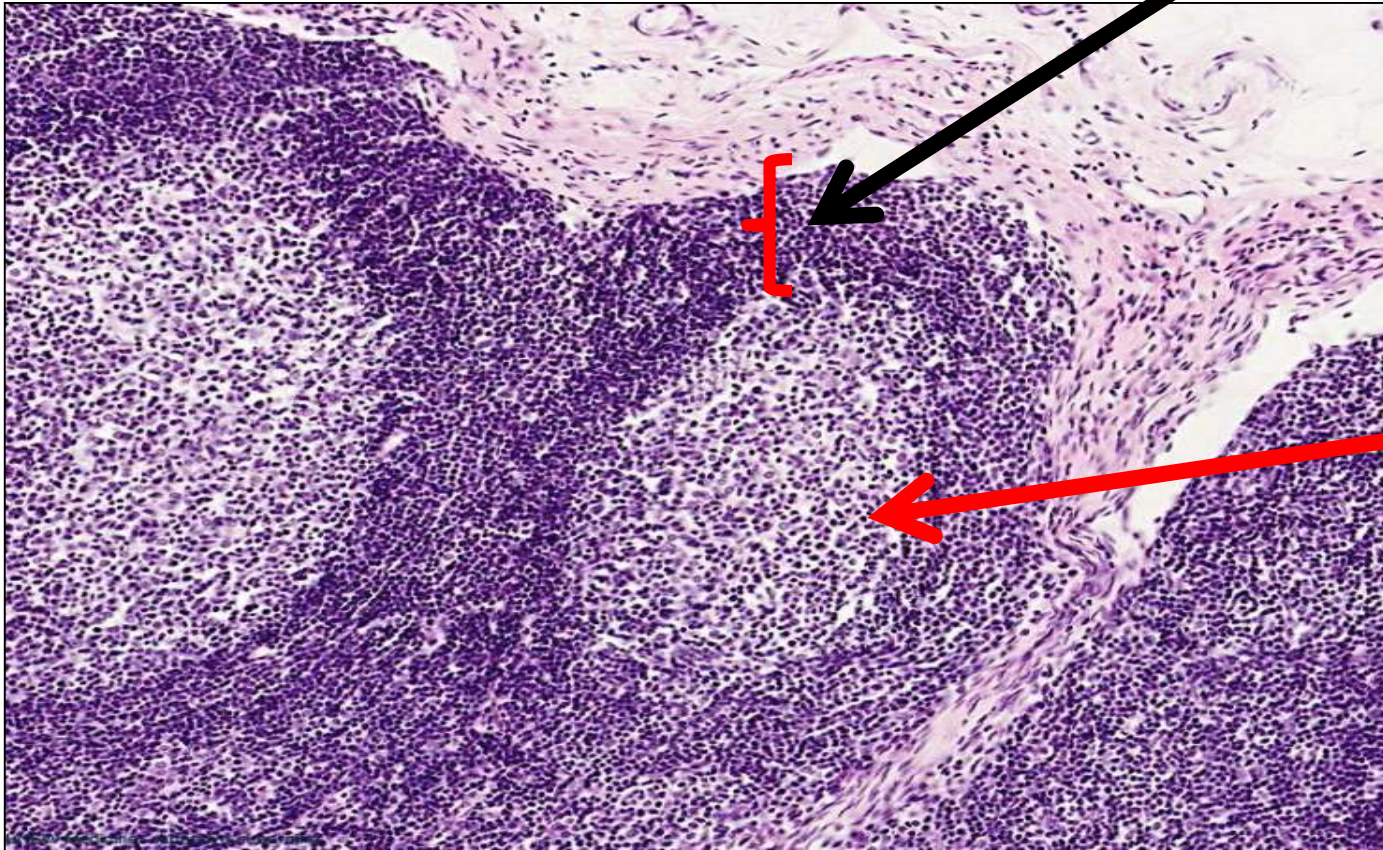
# Esophagus / 1ry lymphatic nodule/ no germinal center



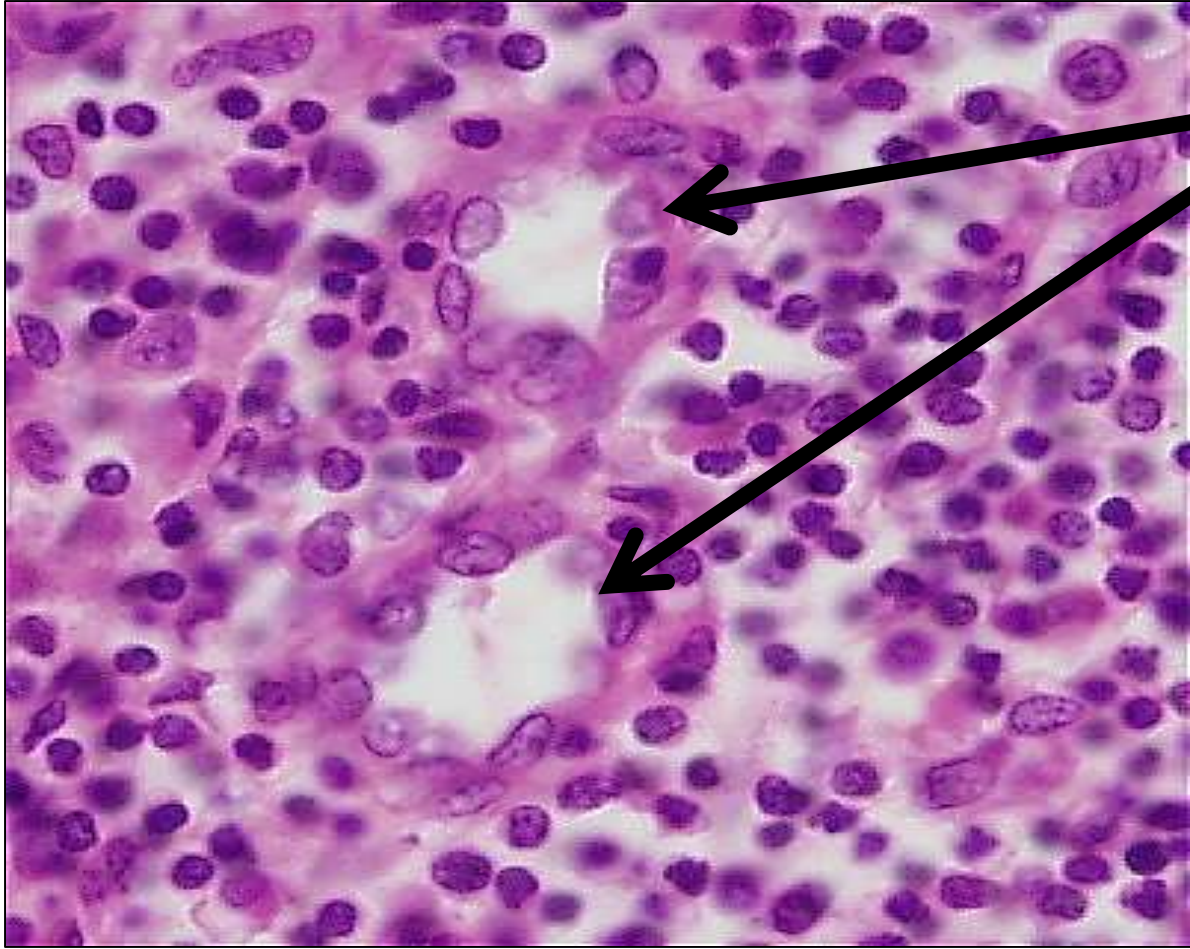
# 2ry lymphatic nodule with germinal center

Mantel zone

Germinal center



# High endothelial venule

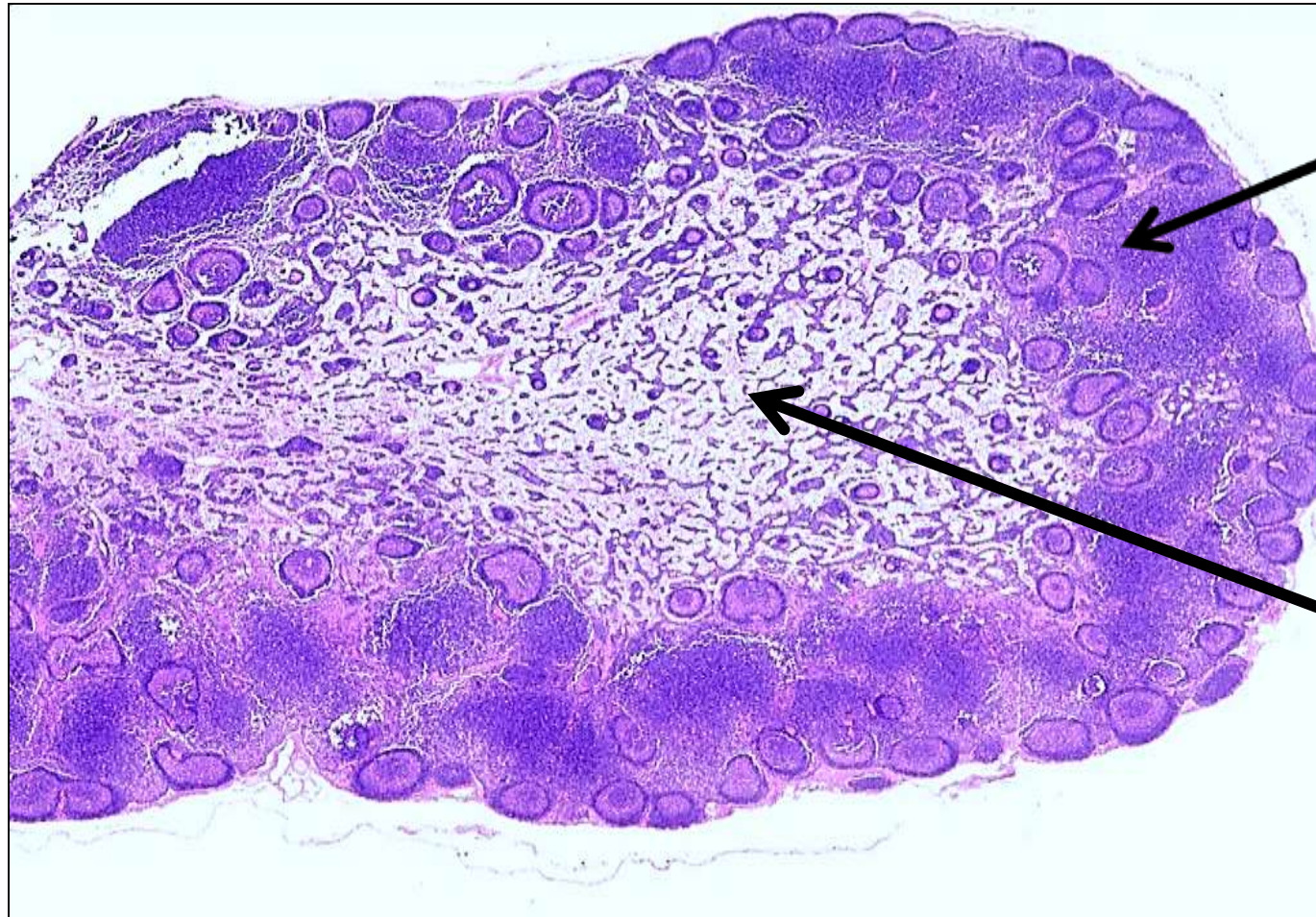


**The lining epithelium is cuboidal rather than the usual flat squamous**





# Section in Lymph node

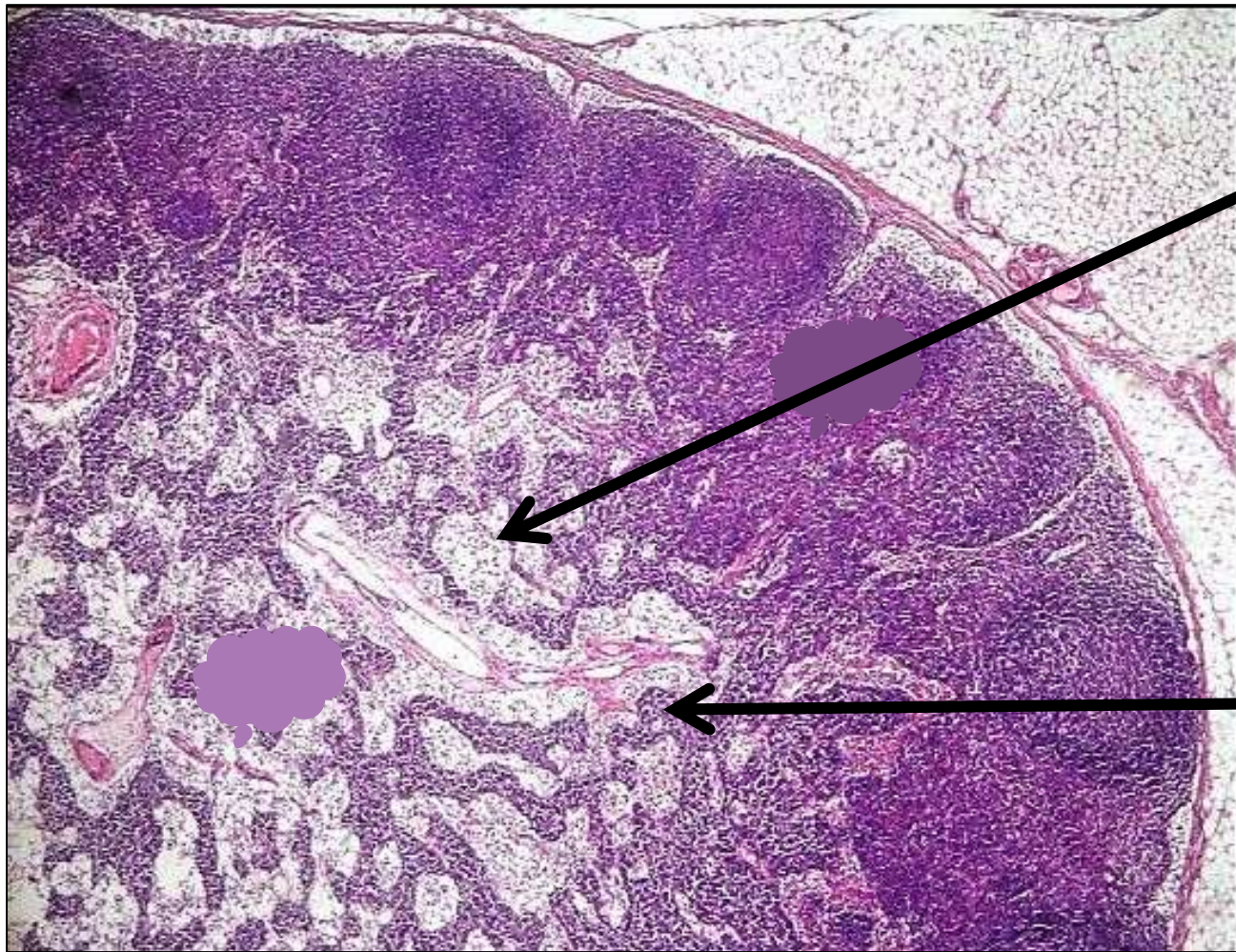


**Cortex**

**Medulla**



# Section in Lymph node showing medullary cords & sinuses

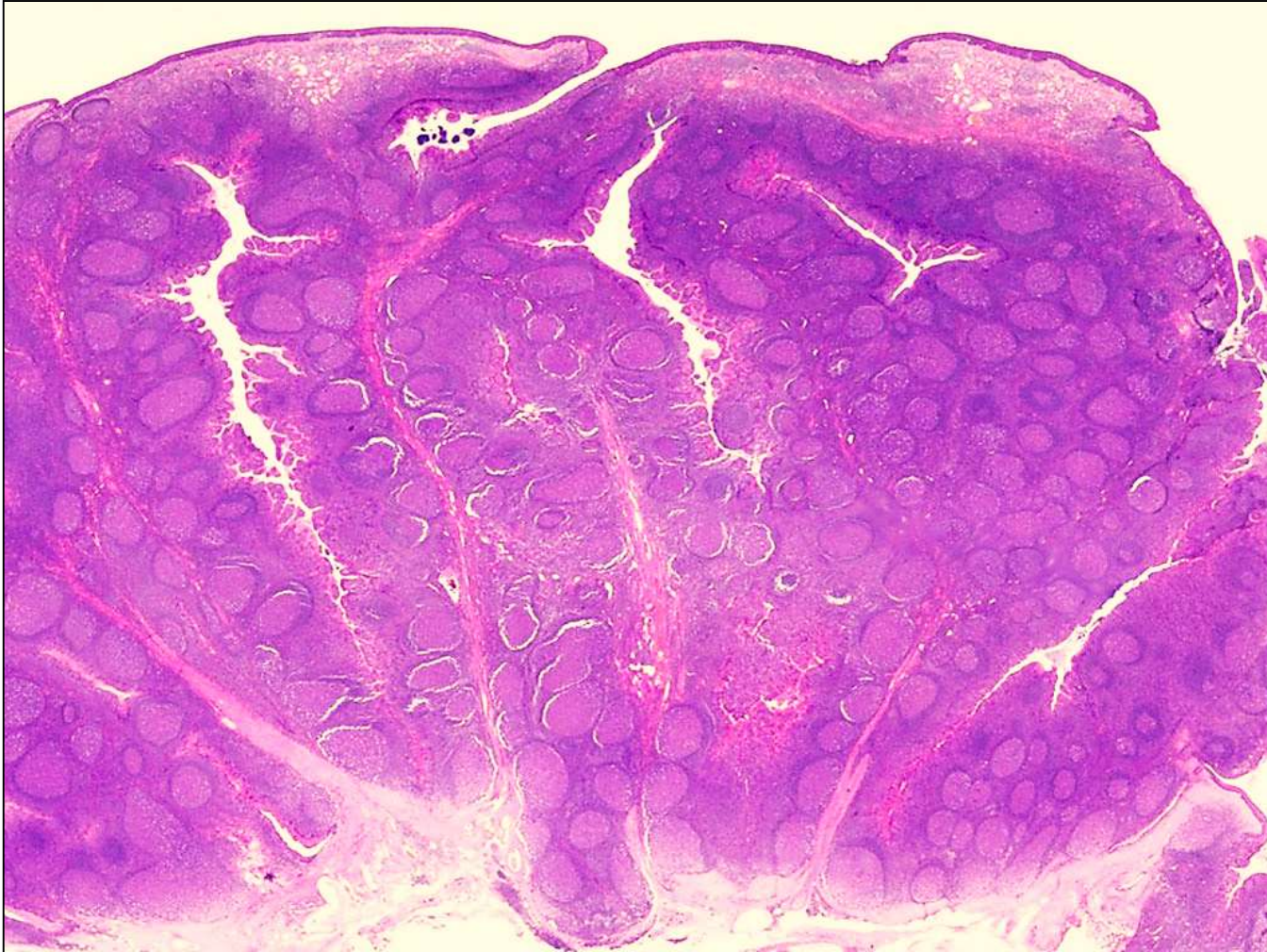

Medullary sinuses

Medullary cord

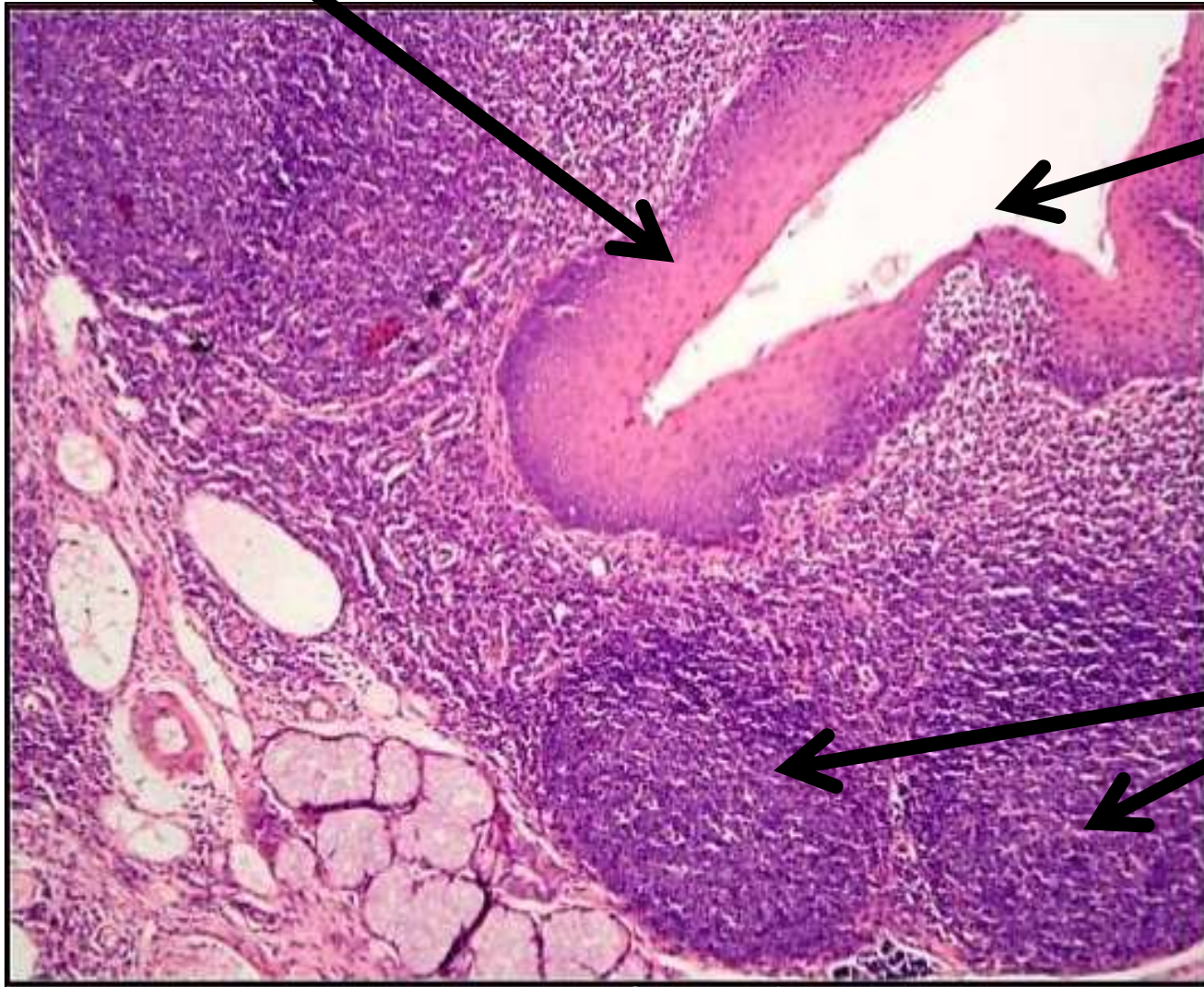


# Palatine tonsil



Non- K stratified  
squamous  
epithelium

# Palatine tonsil

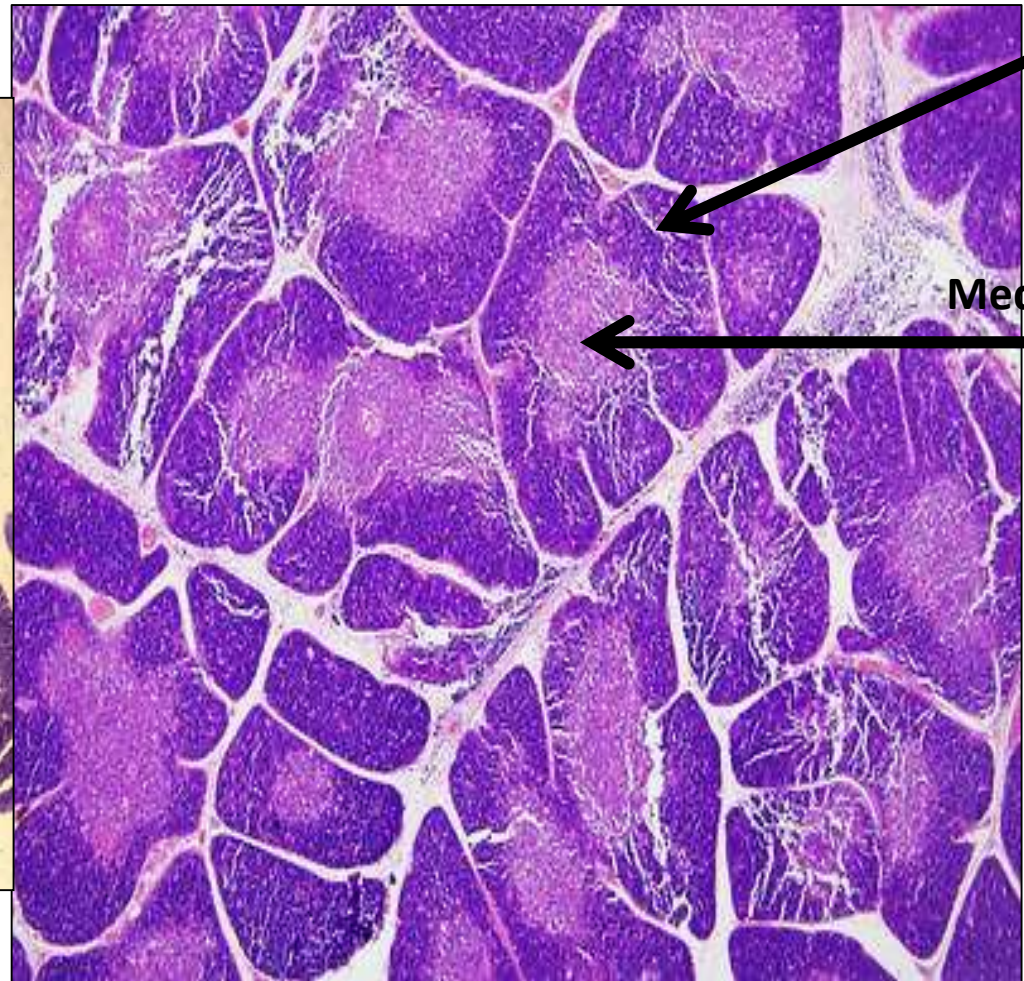
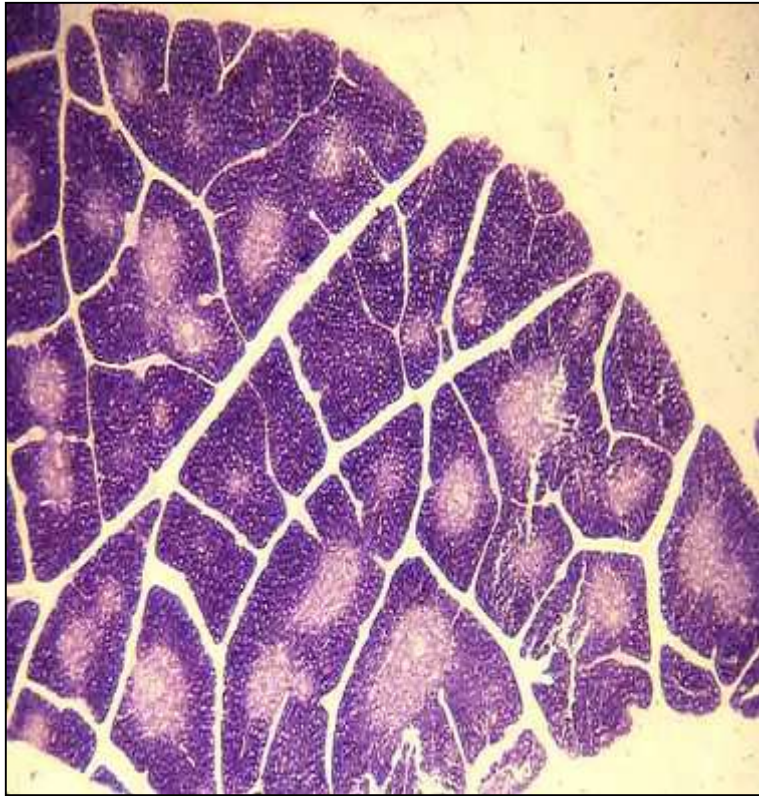


Tonsillar crypt

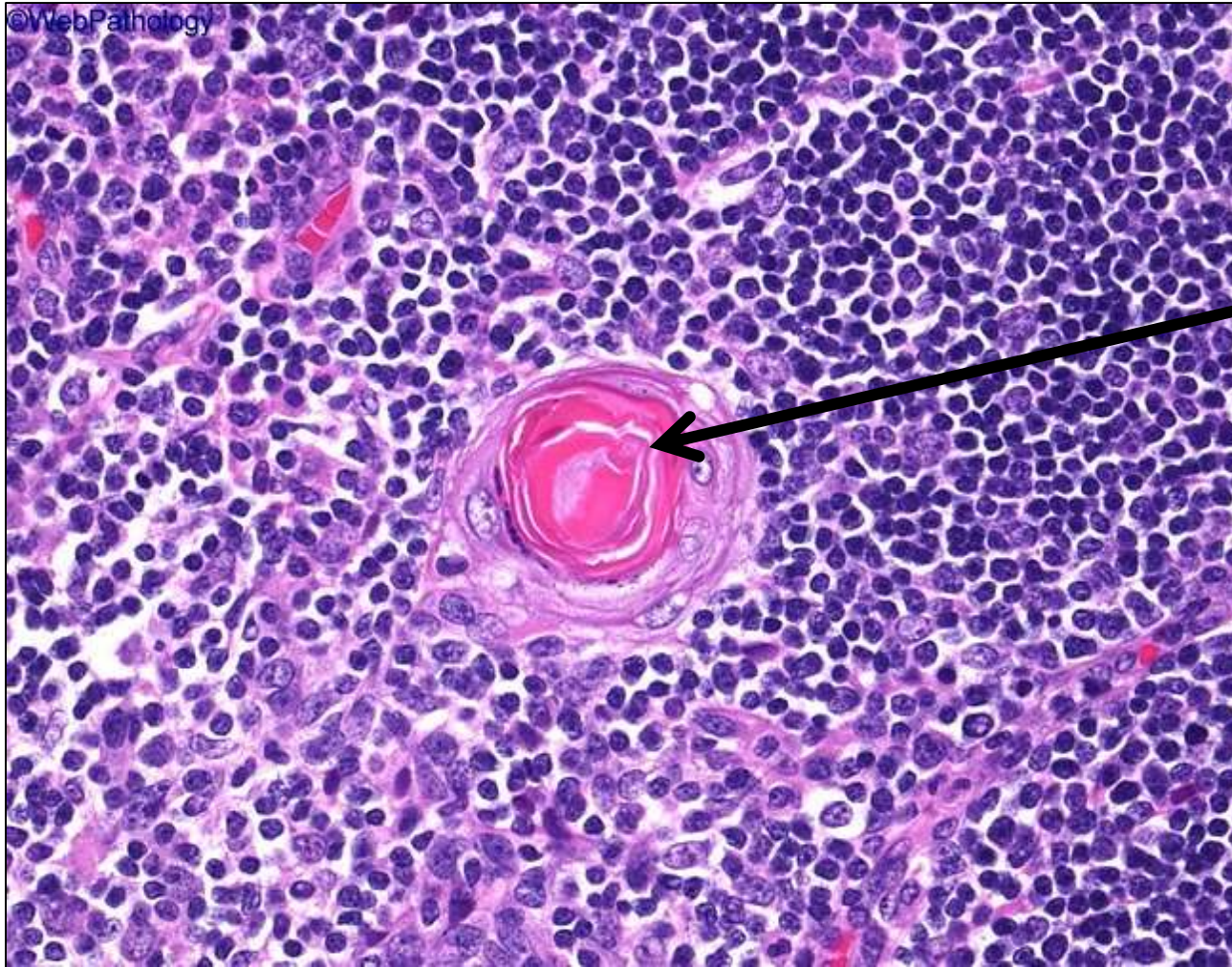
Lymphoid nodules



# Thymus/ lymphoid organ/ gland



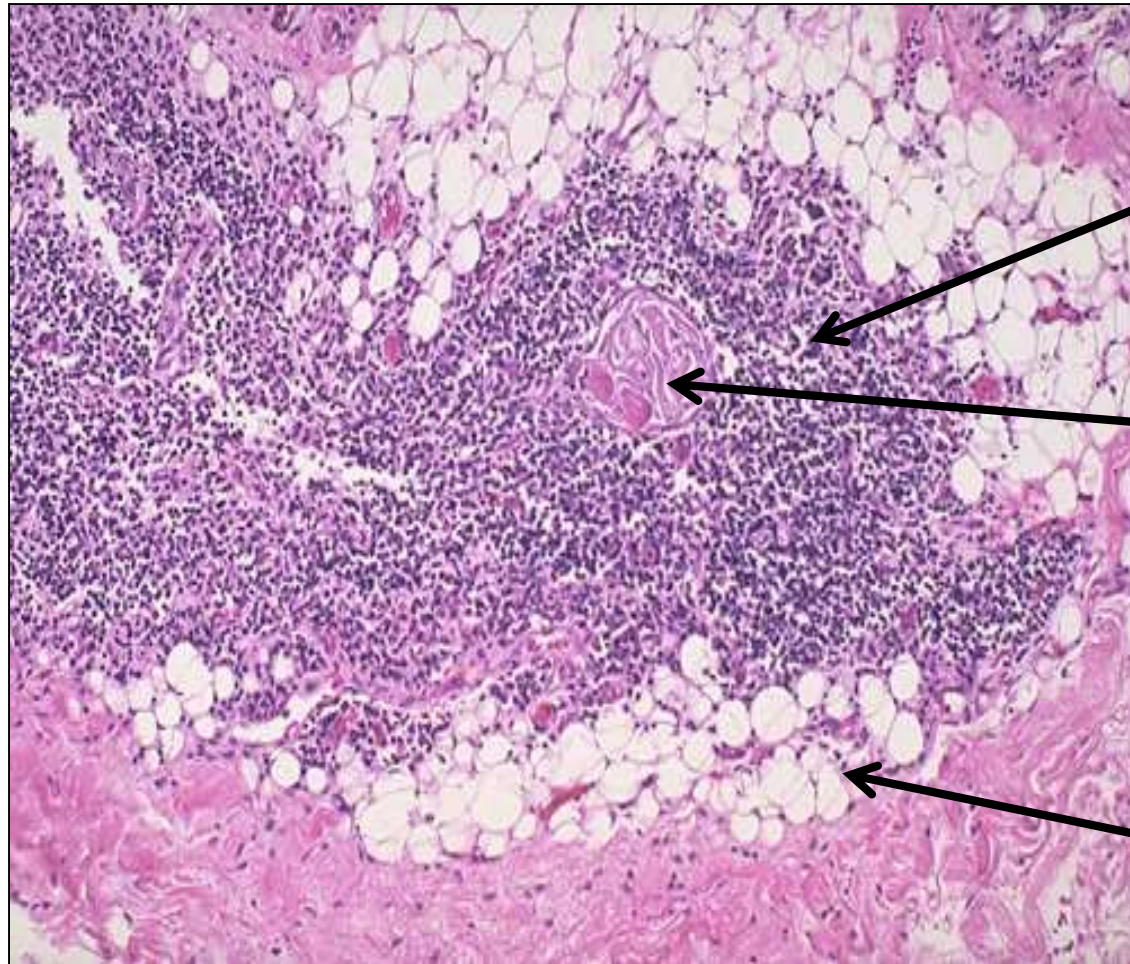
# Thymus/ Hassall's corpuscle



**Acidophilic mass of degenerated reticular cells , surrounded By concentric layers of epithelial reticular cells**



# Adult thymus (involuting)



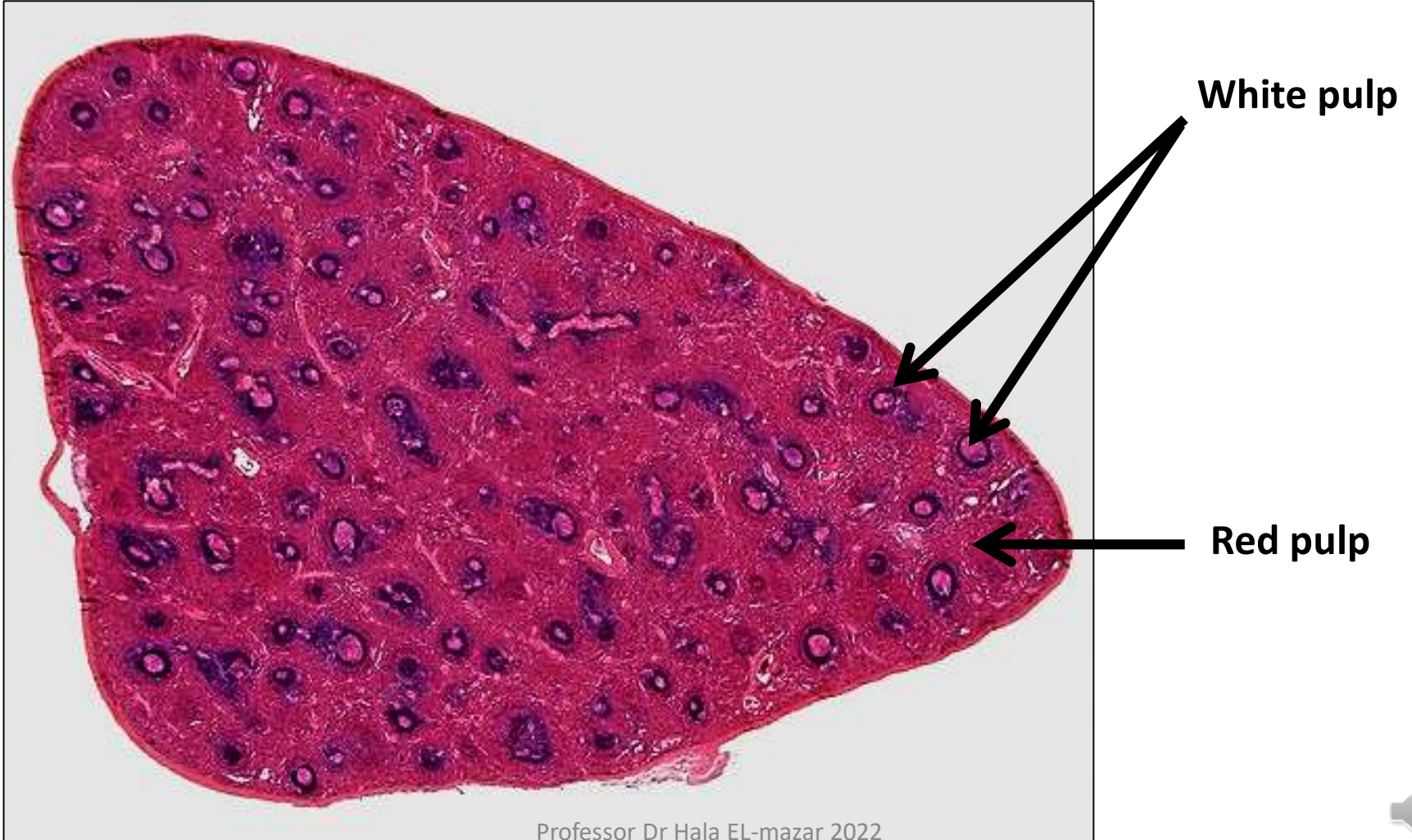
Remnant of thymic tissue

Hassall's corpuscles

Fatty tissue

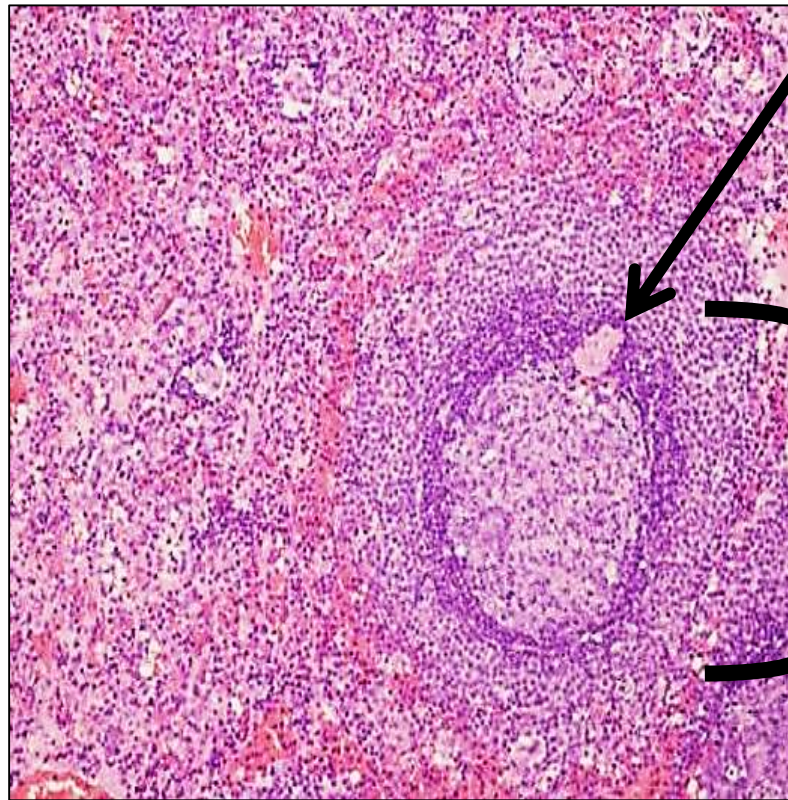
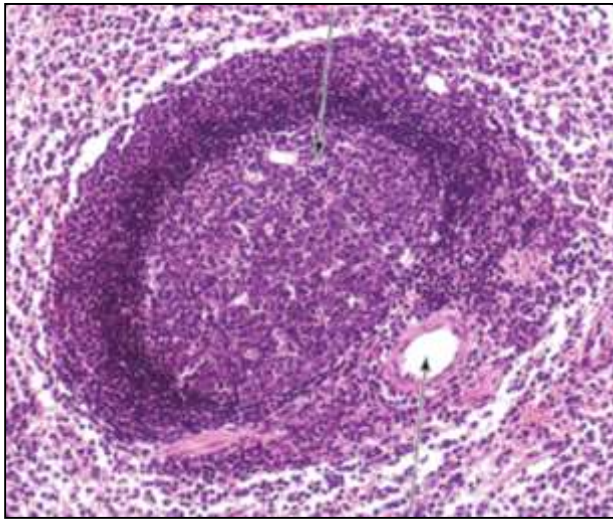


# Spleen showing white & red pulps





# Splenic nodule



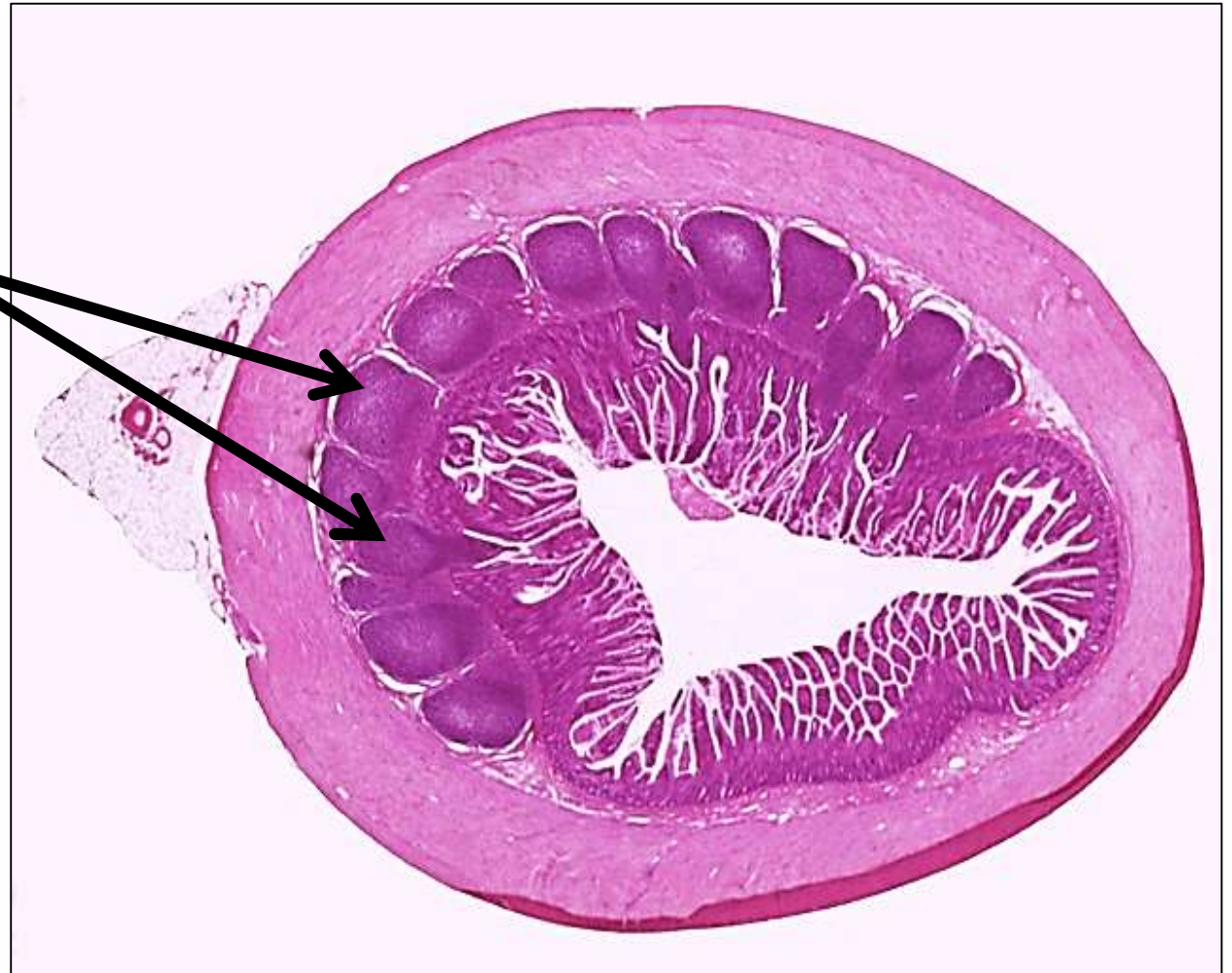
Central arteriole

White pulp  
composed of  
lymphoid  
aggregates  
surrounded with  
red pulp

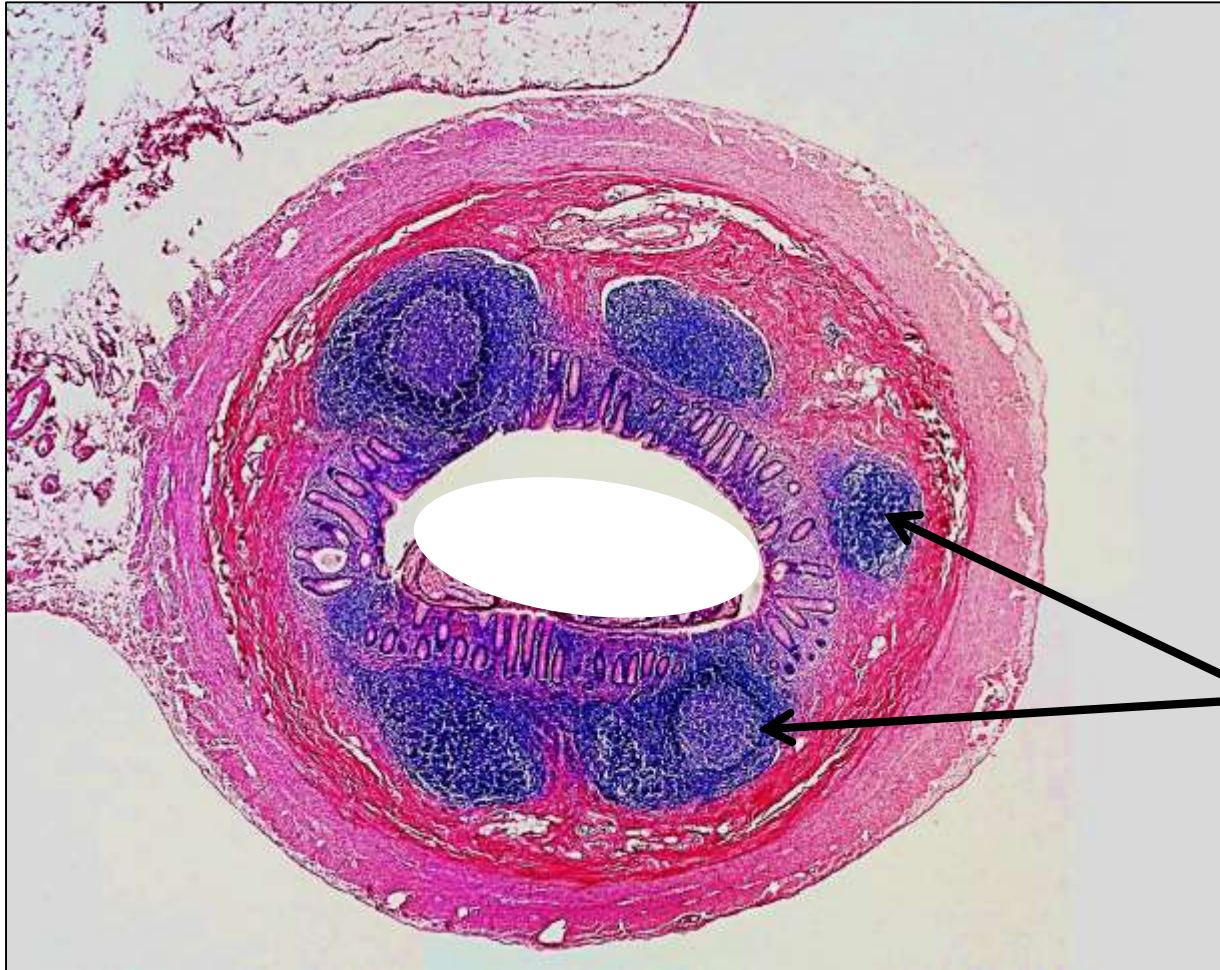

# MALT/ mucosa associated lymphoid tissue/ ileum

Peyer's patches



# MALT/ Appendix



Lymphoid follicles



# Thank you

