

وسهلا

أهلا

يُمنع أخذ السلايدات بدون
إذن المحرر واي اجراء
يخالف ذلك يقع تحت
طائلة المسؤولية القانونية



الأستاذ الدكتور يوسف حسين

أستاذ التشريح وعلم الأجنة - كلية الطب - جامعة الزقازيق - مصر

رئيس قسم التشريح و الأنسجة و الأجنة - كلية الطب - جامعة مؤتة - الأردن

دكتورة من جامعة كولونيا المانيا

جروب الفيس د. يوسف حسين (استاذ التشريح)

Prof. Dr. Youssef Hussein Anatomy - YouTube

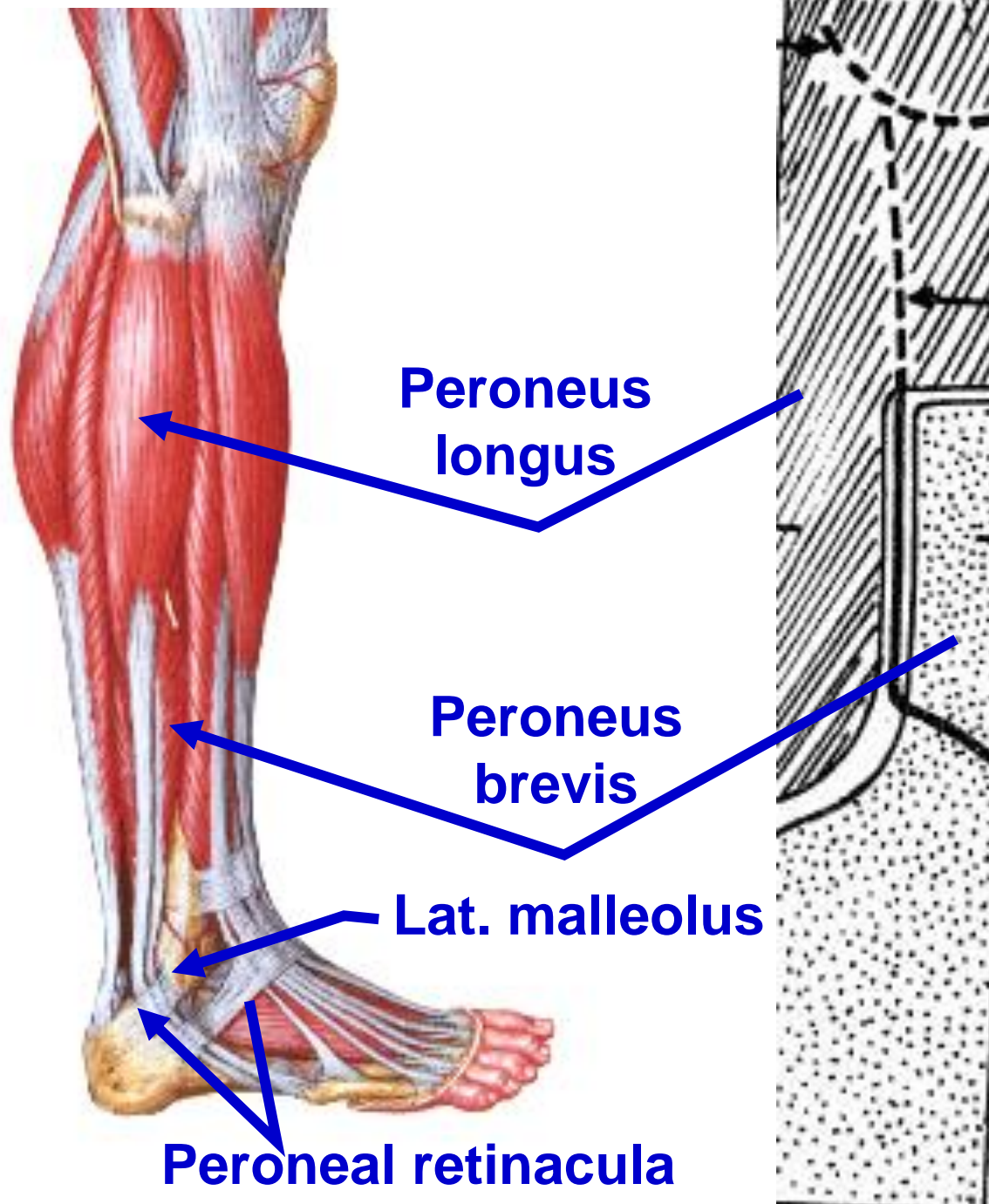
اليوتيوب د. يوسف حسين

<https://www.youtube.com/@ProfDrYoussefHusseinAnatomy/playlists>

Lateral compartment of the leg

الـيوـتـيـوبـ دـ.ـ يـوسـفـ حـسـيـن

<https://www.youtube.com/@ProfDrYoussefHusseinAnatomy/playlists>



- **Peroneus Longus**

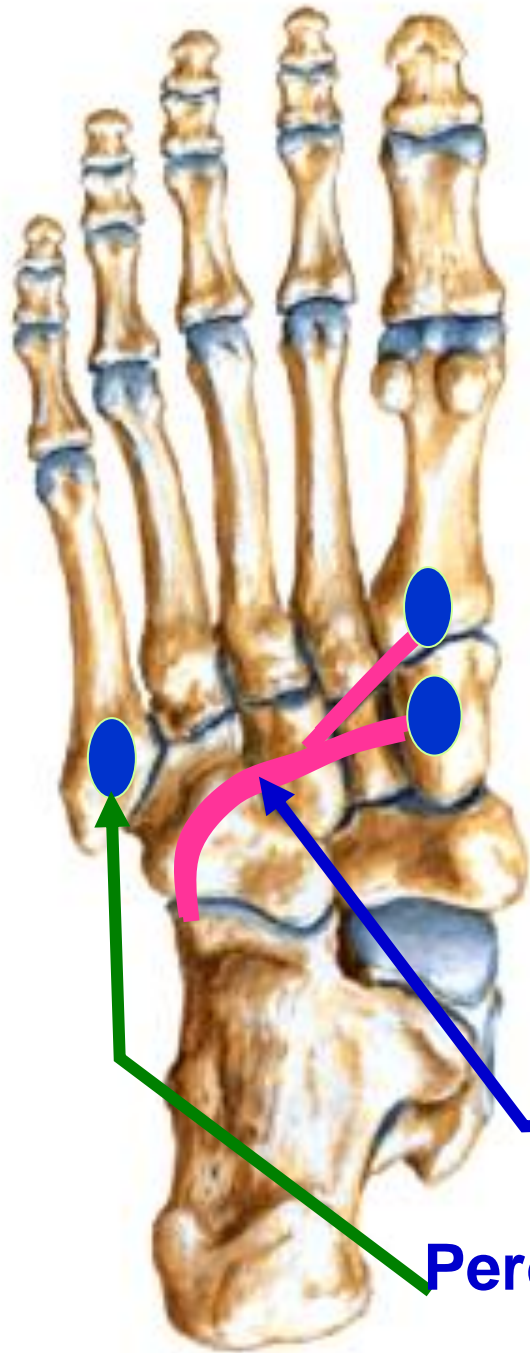
** **Origin:** From upper 2/3 of lateral surface of fibula.

- **Peroneus Brevis**

** **Origin:** From lower 2/3 of lateral surface of fibula.

** Peroneus **longus** passes superficial to peroneus **brevis** **behind** lateral malleolus then **deep** to **peroneal retinacula** inside synovial sheath

اليوثيوب د. يوسف حسين



- **Insertion of Peroneus Longus, crosses sole** of foot from lateral to medial to base of the plantar surface of the first metatarsal bone and medial cuneiform bone.
- **Insertion of Peroneus Brevis into** base of plantar surface of the 5th metatarsal bone.
- **Nerve supply:** Superficial peroneal nerve.

**** Actions:**

1- Plantar flexion of the foot.

2- Eversion of the foot.

3- **Peroneus longus** Plays an important role in supporting **transverse** arch of foot.

Peroneus longus

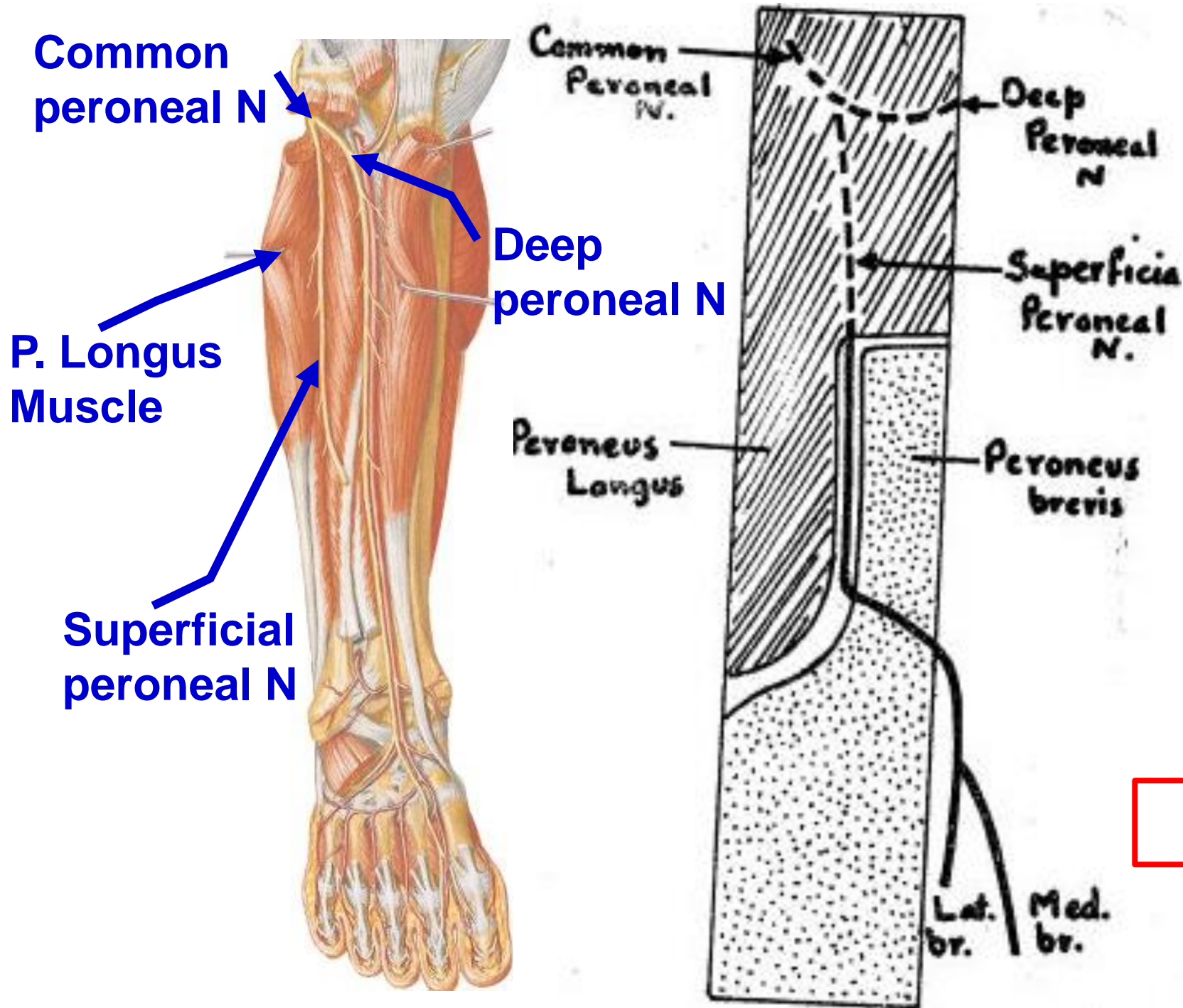
Peroneus Brevis

اليوثيوب د. يوسف حسين

Superficial Peroneal nerve

البيوتيوب د. يوسف حسين

<https://www.youtube.com/@ProfDrYoussefHusseainAnatomy/playlists>



- **Superficial Peroneal Nerve (musculocutaneous)**

- ** It is the smaller of two terminal branches of common peroneal nerve within substance of peroneus longus.
- It descends through substance of peroneus longus.
- Then between peroneus longus and brevis.
- Then, it pierces deep fascia where it becomes subcutaneous.

اليوثيوب د. يوسف حسين

- **Superficial Peroneal Nerve (musculocutaneous)**

****** It divides into medial and lateral terminal branches, descend superficial to extensor retinacula to dorsum of foot.

**** Branches**

A- Muscular branches: two 2 peronei longus and brevis.

B- Cutaneous branches

- 1) The lower part of the lateral side and front of the leg.
- 2) Intermediate part of the dorsum of the foot.

C- Medial terminal division: divides into 2 dorsal digital branches

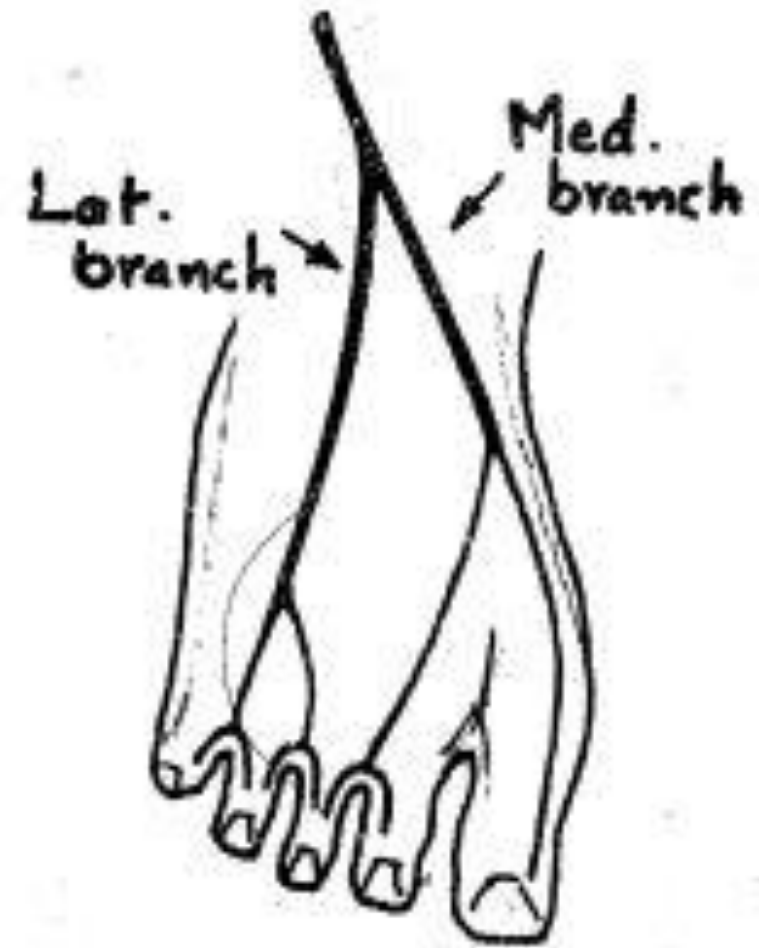
1- Medial branch to the medial side of the big toe.

2- Lateral branch for adjacent sides of 2nd and 3rd toes.

D- Lateral terminal division divides into 2 dorsal digital branches:

1- Medial branch for adjacent sides of 3rd and 4th toes.

2- Lateral branch for adjacent sides of 4th and little toes.

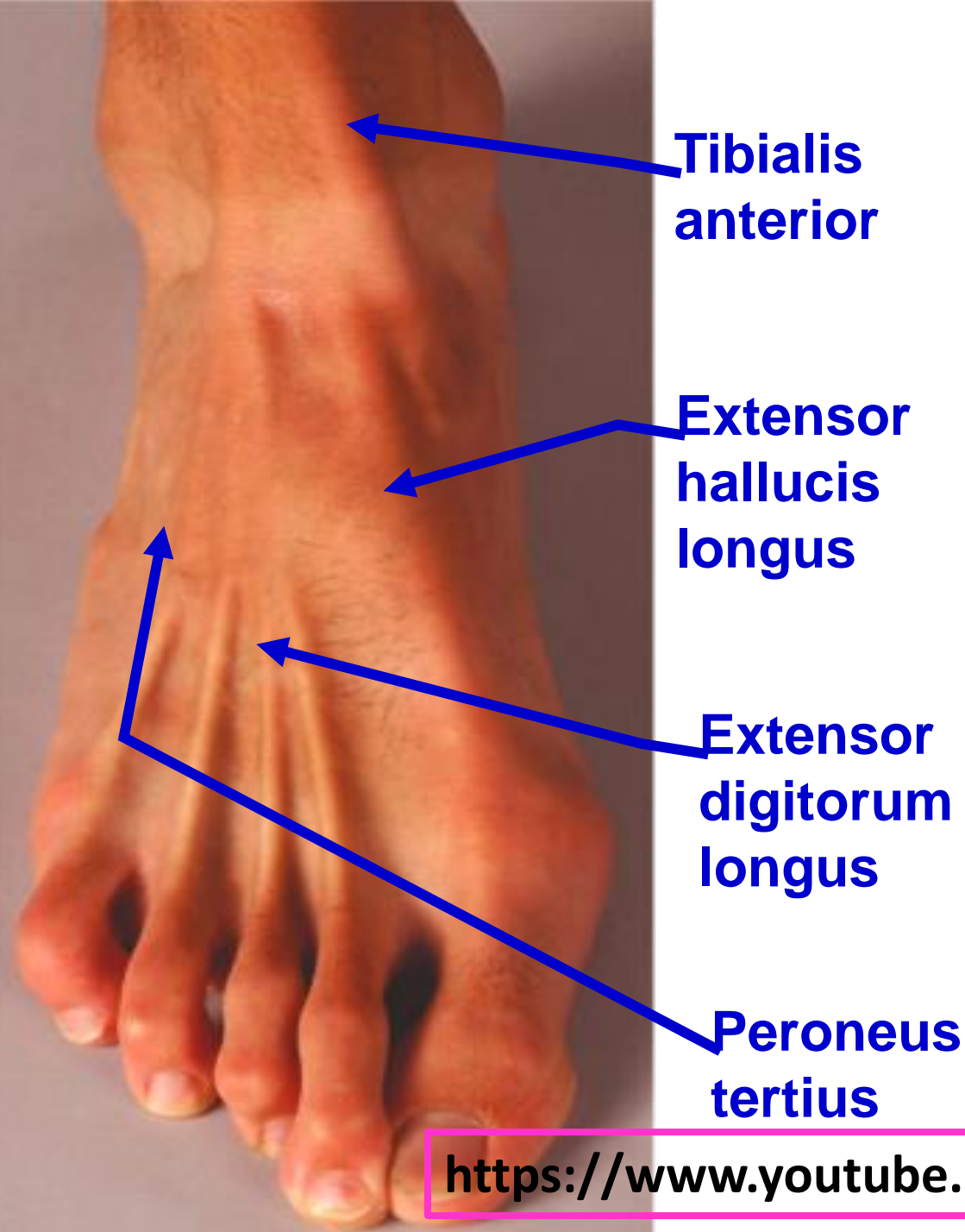


اليوثيوب د. يوسف حسين

Muscles of Anterior compartment of leg

الليوتيوب د. يوسف حسين

<https://www.youtube.com/@ProfDrYoussefHusseinaAnatomy/playlists>



Tibialis anterior

Extensor hallucis longus

Extensor digitorum longus

Peroneus tertius

- **All muscles** of anterior group arise from the anterior surface of **fibula** **except** **tibialis anterior** from lateral surface of **tibia**.

- **Nerve supply: deep peroneal Nerve (anterior tibial Nerve)**

- **Actions: Dorsiflexion of the foot (ankle joint)**

- **Blood supply: Anterior tibial vessels.**

اليوثيوب د. يوسف حسين

<https://www.youtube.com/@ProfDrYoussefHusseainAnatomy/playlists>

** Origin of muscles of anterior compartment

1- Tibialis Anterior

- From the upper 2/3 of the lateral surface of the **tibia**.

2- Extensor Digitorum Longus

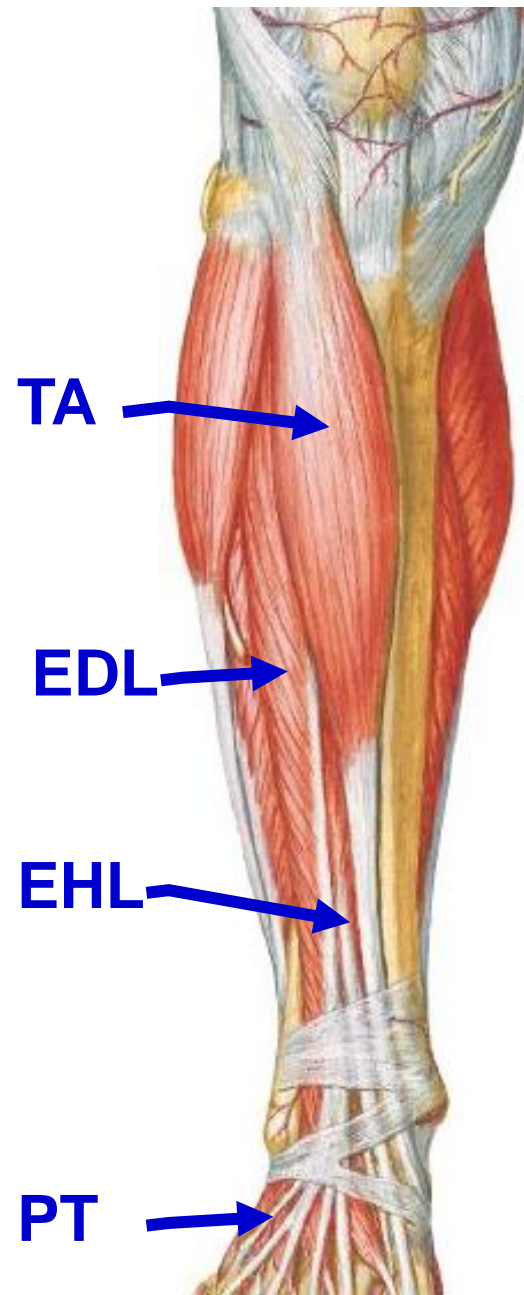
- from the upper 3/4 of the anterior surface of the **fibula**.

3- Extensor Hallucis Longus

- From the middle 2/4 of the anterior surface of the **fibula**.

4- Peroneus Tertius

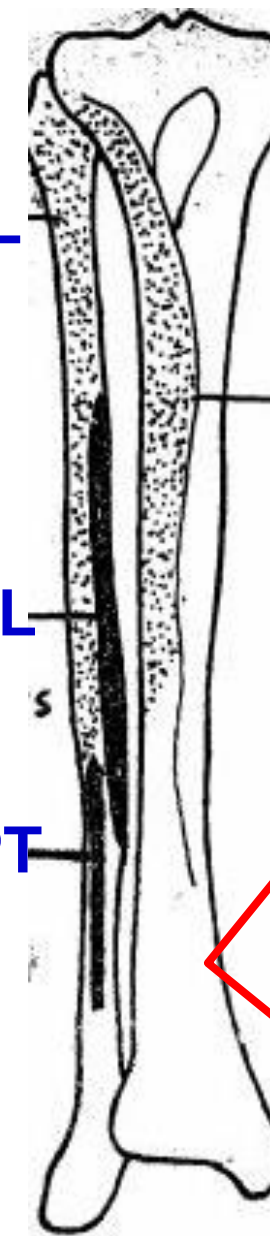
- From the lower 1/4 of the anterior surface of the **fibula**.



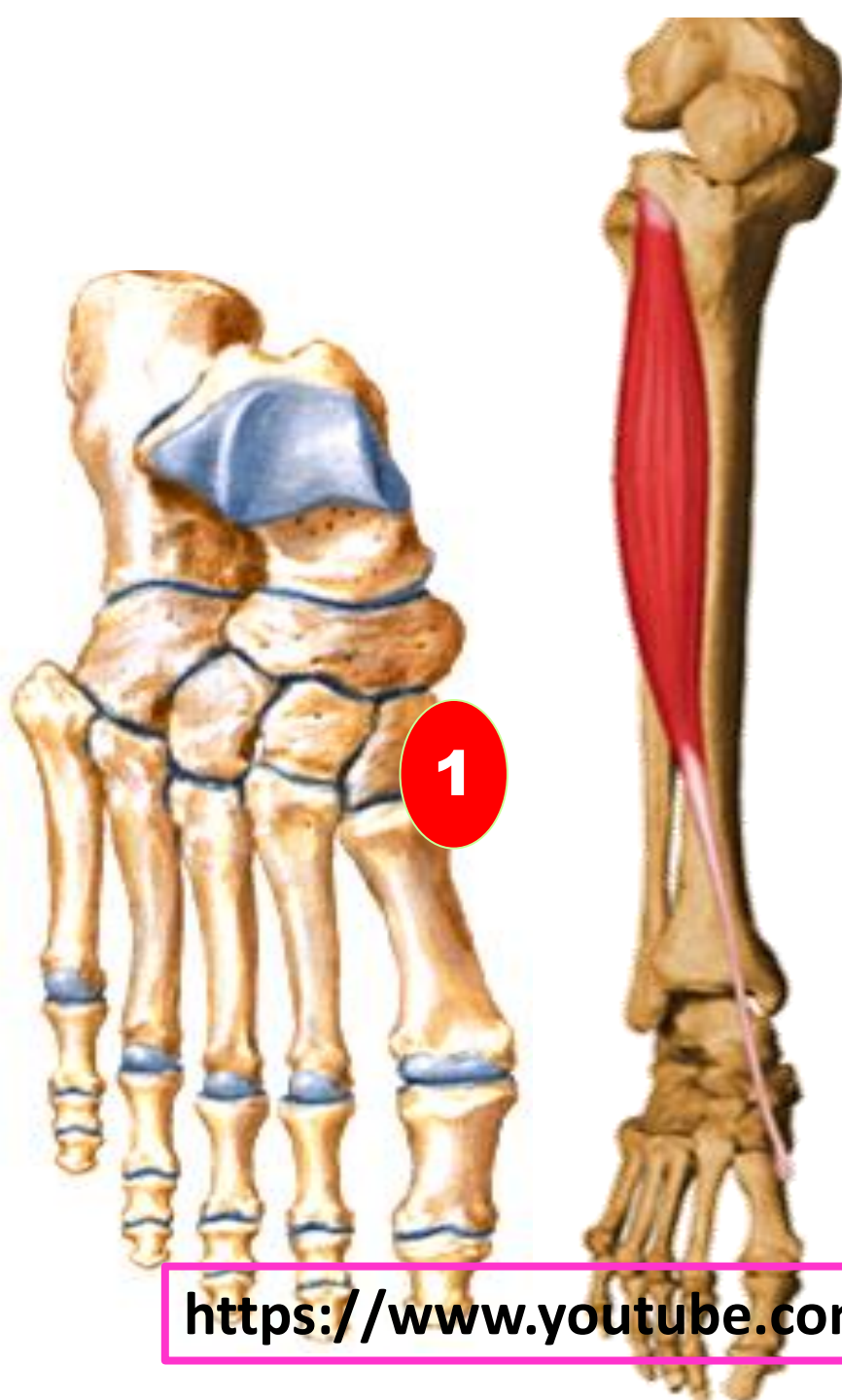
EDL

EHL

PT



اليوتيوب د. يوسف حسين



1- Tibialis Anterior

- ** **Origin:** 1- From the upper 2/3 of the lateral surface of the tibia and interosseous membrane.
- ** **Insertion:** medial surface of medial cuneiform bone and Adjacent part of base of the first metatarsal bone.
- ** **Nerve supply:** anterior tibial nerve (deep peroneal nerve).
- ** **Actions:** 1- Dorsiflexion of the foot (ankle joint).
2- Inversion of the foot.
3- Support and maintain the medial longitudinal arch of the foot.

اليوتيوب د. يوسف حسين

<https://www.youtube.com/@ProfDrYoussefHusseiniAnatomy/playlists>



2- Extensor Digitorum Longus

**** Origin:** from the upper 3/4 of the anterior surface of the fibula and interosseous membrane.

**** Insertion :**

- They join the **extensor expansions** on the proximal phalanges of the **lateral 4 toes**, Then divided into

a- Middle slip into the dorsal aspect of the middle phalanges.

b- 2 collateral slips into the bases of the distal phalanges.

**** Nerve supply:** anterior tibial nerve (deep peroneal nerve).

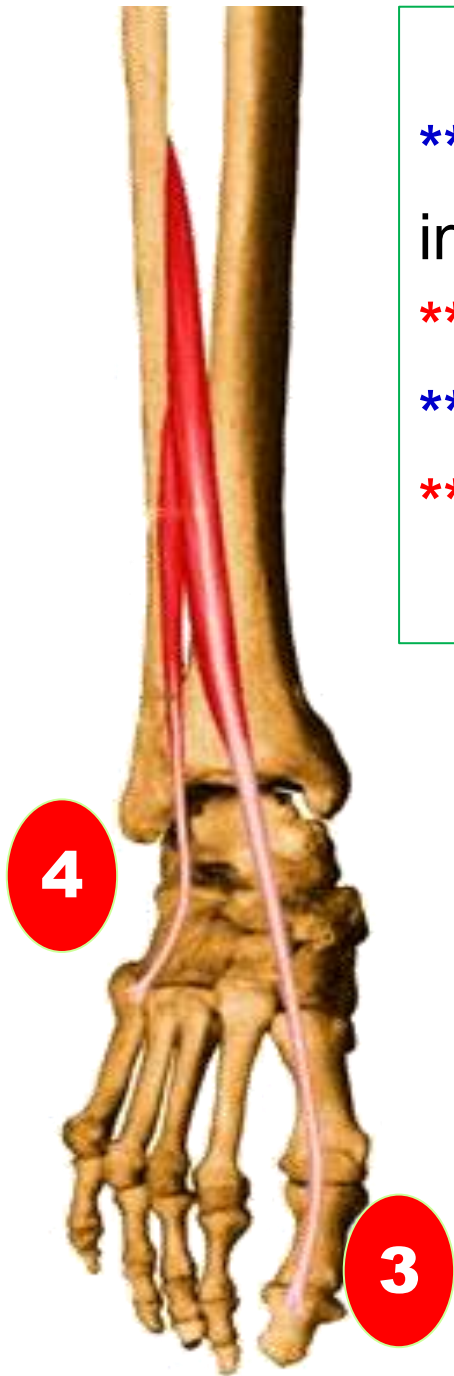
**** Actions:**

1- Dorsiflexion of the foot.

2- Extension of the all joints of the lateral 4 toes.

اليوتيوب د. يوسف حسين

<https://www.youtube.com/@ProfDrYoussefHusseainAnatomy/playlists>



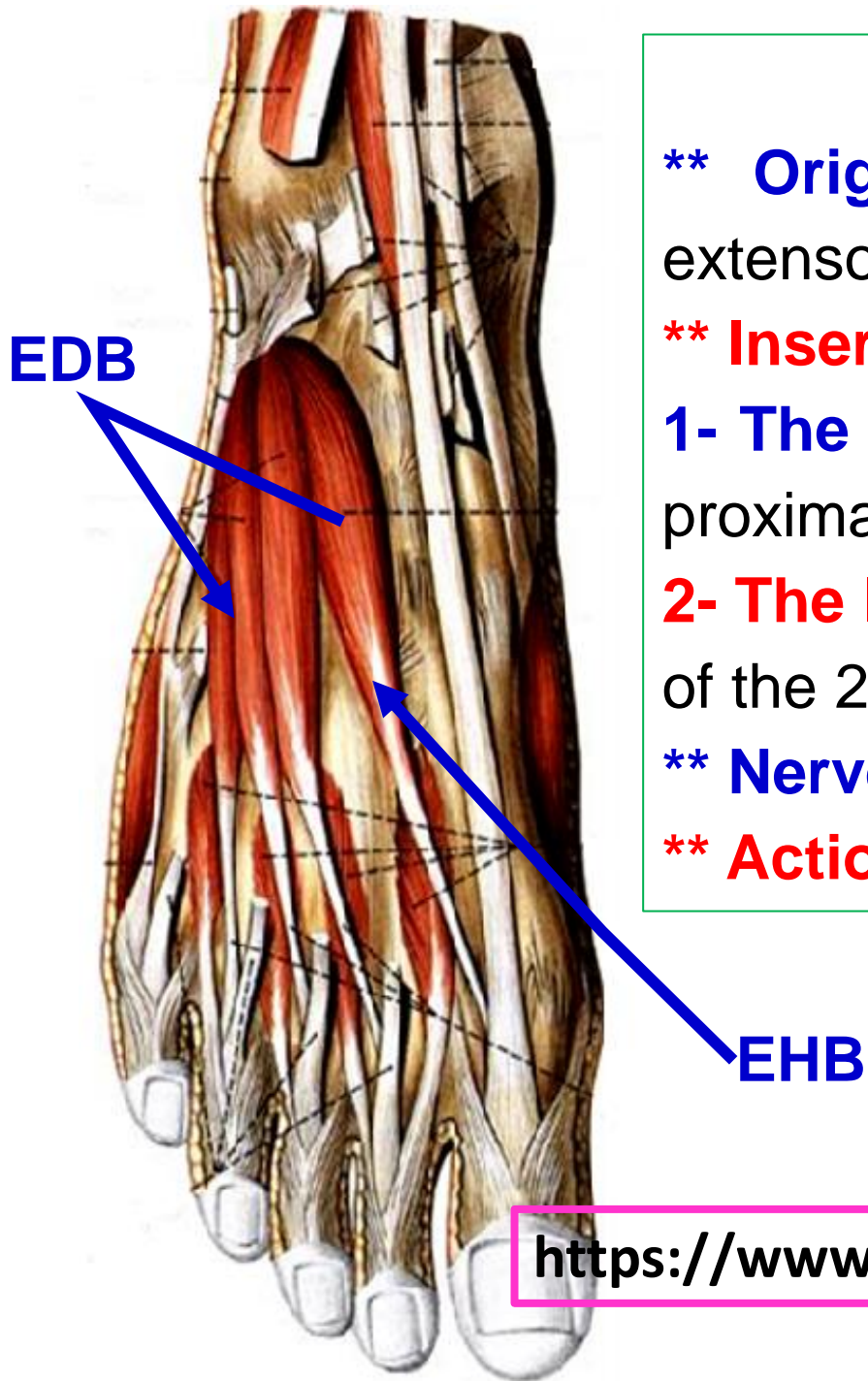
3- Extensor Hallucis Longus

- ** **Origin:** From the middle 2/4 of the anterior surface of the fibula and interosseous membrane.
- ** **Insertion:** dorsum of the base of the distal phalanx of the big toe.
- ** **Nerve supply:** anterior tibial nerve (deep peroneal nerve).
- ** **Actions:** 1- Dorsiflexion of the foot.
2- Extension of all joints of the big toe.

4- Peroneus Tertius

- ** **Origin:** From the lower 1/4 of the anterior surface of the fibula and interosseous membrane.
- ** **Insertion:** dorsum of base of the 5th metatarsal bone.
- ** **Nerve supply:** deep peroneal nerve.
- ** **Actions:** 1- Dorsiflexion of the foot.
2- Eversion of the foot.

اليوثيوب د. يوسف حسين



- **Extensor Digitorum Brevis**

**** Origin;** anterior surface of the calcaneus and inferior extensor retinaculum.

**** Insertion:** It divides into 4 slips for the **medial 4 toes**.

1- The medial slip is inserted into dorsum of the base of the proximal phalanx of the **big toe (extensor hallucis brevis)**.

2- The lateral 3 slips are inserted into the extensor expansion of the 2nd, 3rd and 4th toes.

**** Nerve supply;** **lateral branch** of the deep peroneal nerve

**** Actions,** Extension of the medial 4 toes.

اليوتيوب د. يوسف حسين

<https://www.youtube.com/@ProfDrYoussefHusseinAnatomy/playlists>

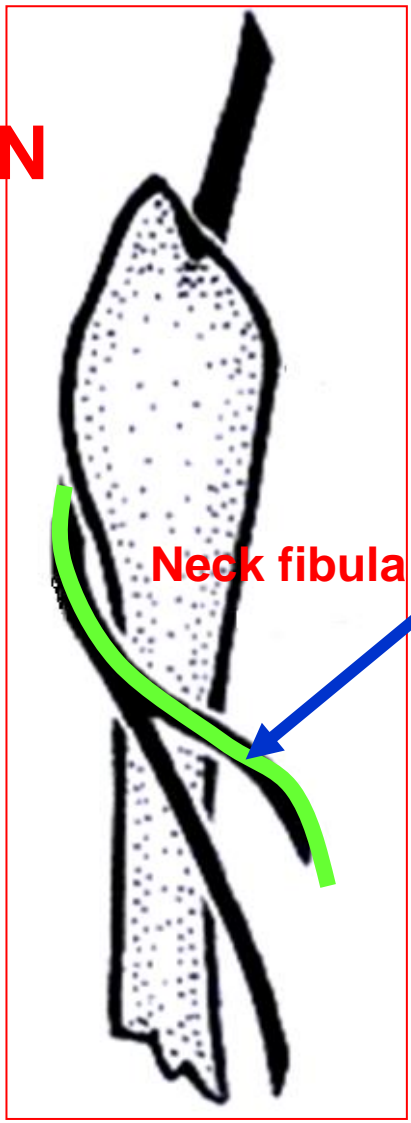
Deep peroneal (Anterior Tibial) Nerve

البيوتيوب د. يوسف حسين

<https://www.youtube.com/@ProfDrYoussefHusseinaAnatomy/playlists>

Deep peroneal nerve

Common peroneal N



Tibialis anterior

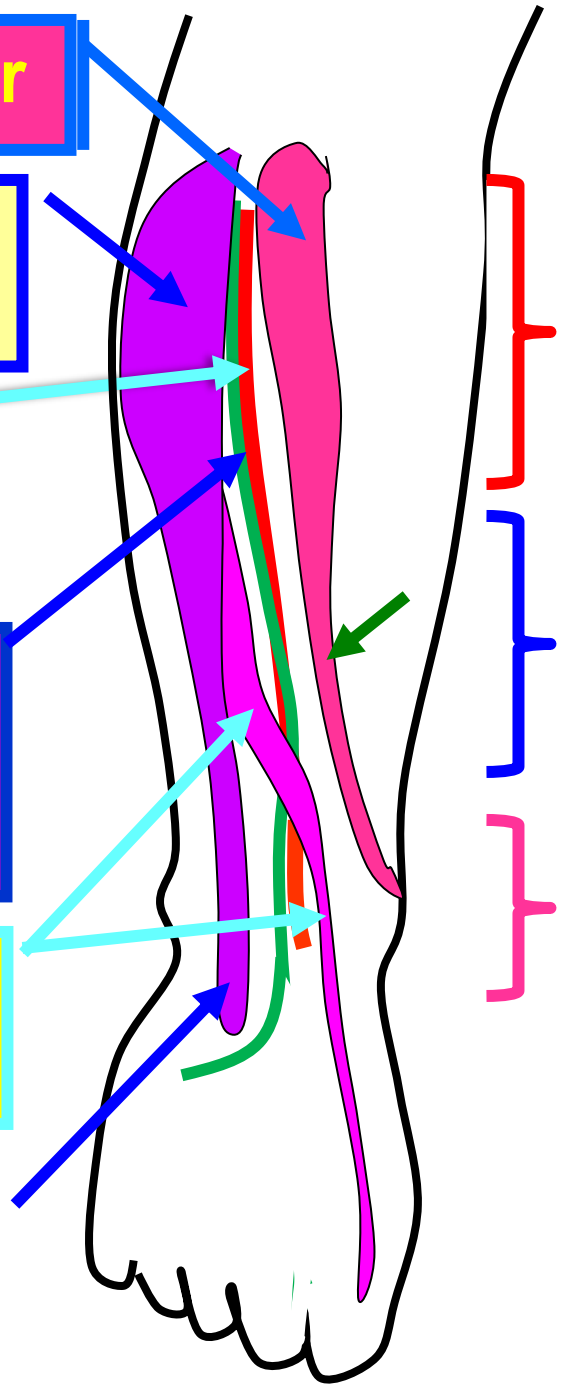
Extensor digitorum longus

Anterior tibial artery

Anterior tibial nerve (Deep peroneal nerve)

Extensor hallucis longus

Extensor digitorum longus



Medial

اليوتوب د. يوسف حسين

- **Anterior tibial (Deep Peroneal) Nerve**

**** Origin:** one of the two terminal branches of the common peroneal nerve, at the **lateral side of the neck of the fibula.**

**** Course and relations in the leg:**

1- It passes through the extensor digitorum longus.

2- Upper part, between Tibialis anterior (**Medial**) and extensor digitorum longus.

3- Middle part, between Tibialis anterior (**Medial**) and extensor hallucis longus.

4- It is crossed by extensor hallucis longus from lateral to medial

5- Lower part, between Extensor hallucis longus (**Medial**) & extensor digitorum longus.

6- Relation of the anterior tibial artery to the nerve,

a- Upper part of the leg, the nerve is **lateral** to the artery.

b- Middle part of the leg, the nerve becomes **anterior** to the artery.

c- Lower part of the leg, the nerve returns **lateral** to the artery.

**** Termination;** by dividing into medial and lateral terminal branches.

<https://www.youtube.com/@ProfDrYoussefHusseainAnatomy/playlists>

**** Branches of deep peroneal nerve**

- 1- Muscular branches** to muscles of the anterior compartment
 - Tibialis anterior, Extensor digitorum longus, Extensor hallucis longus and Peroneus tertius muscles

2- Articular branches: to the ankle joint.

3- Terminal branches in the foot

اليوتيوب د. يوسف حسين

I- Medial terminal branch:

- **Cutaneous** to the adjacent sides of the big and 2nd toes.
- **Articular branches** to the joints of the foot.

II- Lateral terminal branch: ends by **ganglia** and gives

- 1- Muscular** to the **extensor digitorum brevis**.
- 2- Articular** to the joints of the foot.

<https://www.youtube.com/@ProfDrYoussefHusseainAnatomy/playlists>

- **Injury of the deep peroneal nerve**

**** Causes, Fracture neck of the fibula. Stab wound.**

**** Results of injury**

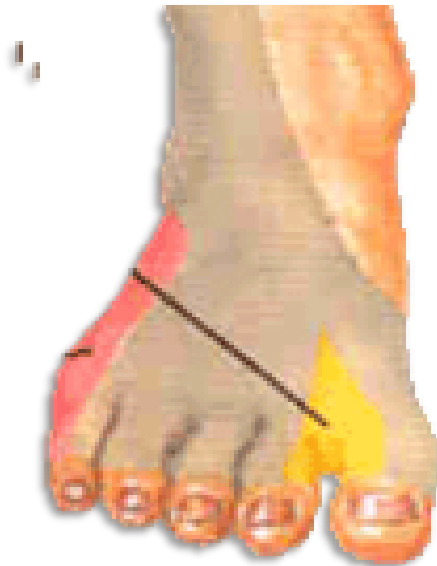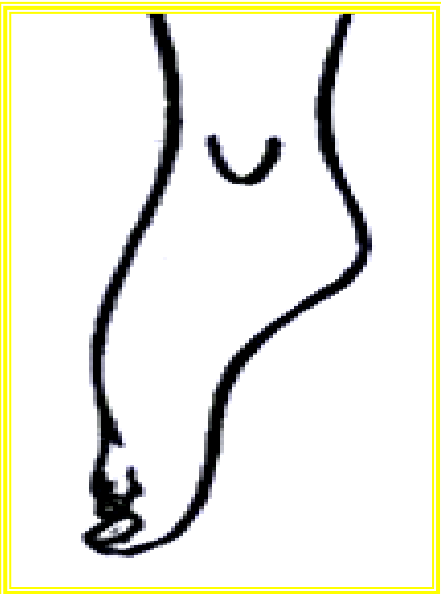
1. Motor affects; paralysis of muscles of anterior compartment leading to

- Loss of dorsiflexion and extension of toes.
- Weakness of inversion of the foot.

**** Deformity, Foot drop**

- **Gait:** high steppage gait.

2- Sensory affects; Loss of sensation of adjacent sides of the big and 2nd toe.



اليوتيوب د. يوسف حسين

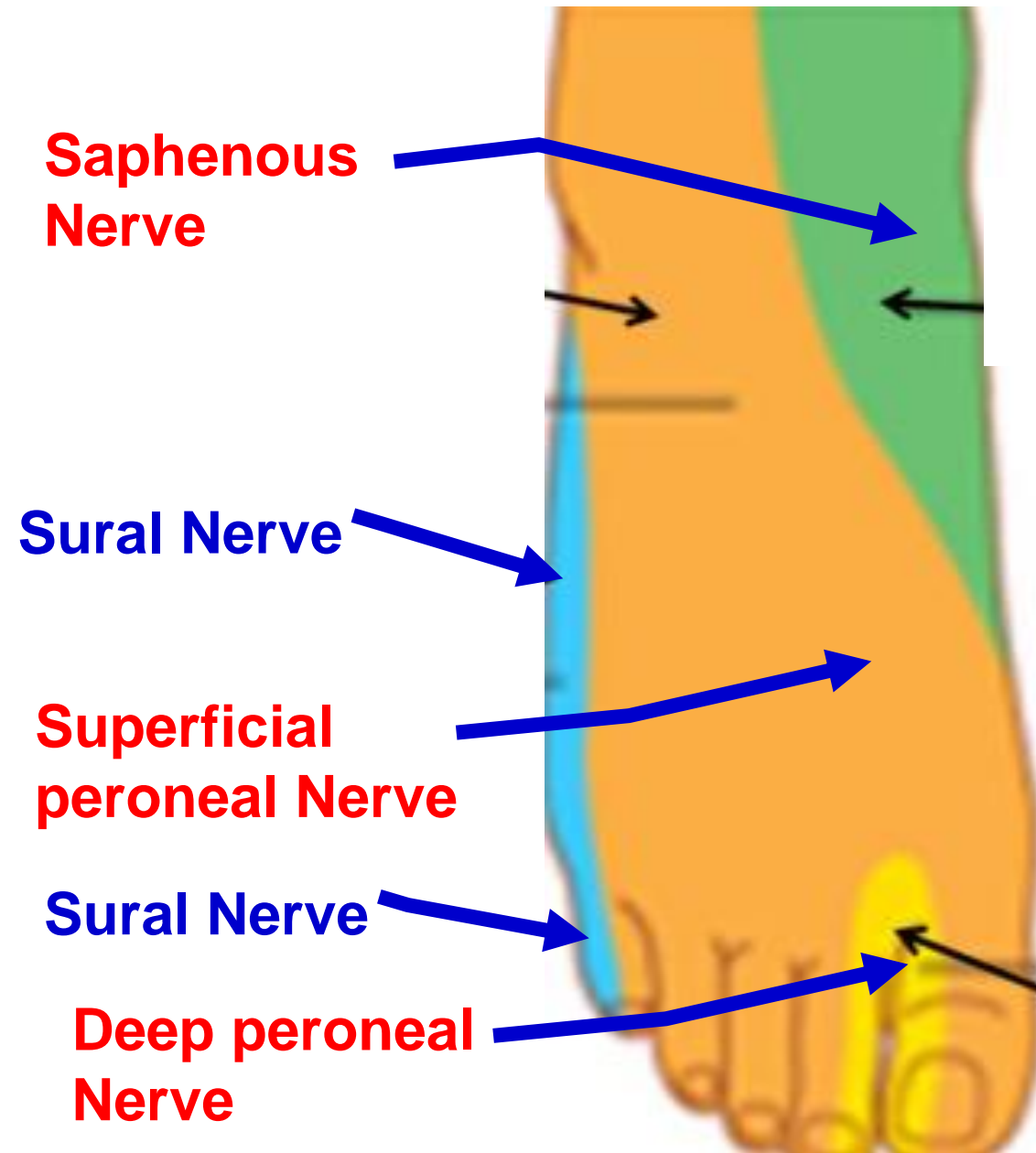
❖ Cutaneous Nerve Supply of Dorsum of Foot

A- Dorsum of the foot.

- 1- **Intermediate** part by superficial peroneal nerve.
- 2- **Medial** by Saphenous nerve from femoral nerve.
- 3- **Lateral** part by sural nerve from tibial nerve.

B- Dorsum of the toes;

- All the dorsum of the toes supplied by the superficial peroneal nerve **except** 2 areas;
- 1- The **adjacent sides** between big toe and 2nd toe by the deep peroneal nerve.
- 2- **Lateral side of the little toe** by the sural nerve.



اليوثيوب د. يوسف حسين

** Injury of the common peroneal nerve

** **Causes:** Fracture of the neck of the fibula (The **commonest site & dangerous position**).

** **Effect of injury:**

اليوثيوب د. يوسف حسين

1- Motor; Paralysis of muscles of the leg

- Anterior compartment (deep peroneal N)
- Lateral compartment (superficial peroneal)

-Deformity: Foot drops


(manifested by plantar flexion and Inversion).

2- Sensory; Decreased sensation, numbness, or tingling and pain on

1) Anterolateral part of the leg.

2) Dorsum of the foot **except** medial side supplied by saphenous nerve (femoral nerve) and lateral side by sural nerve (tibial nerve)

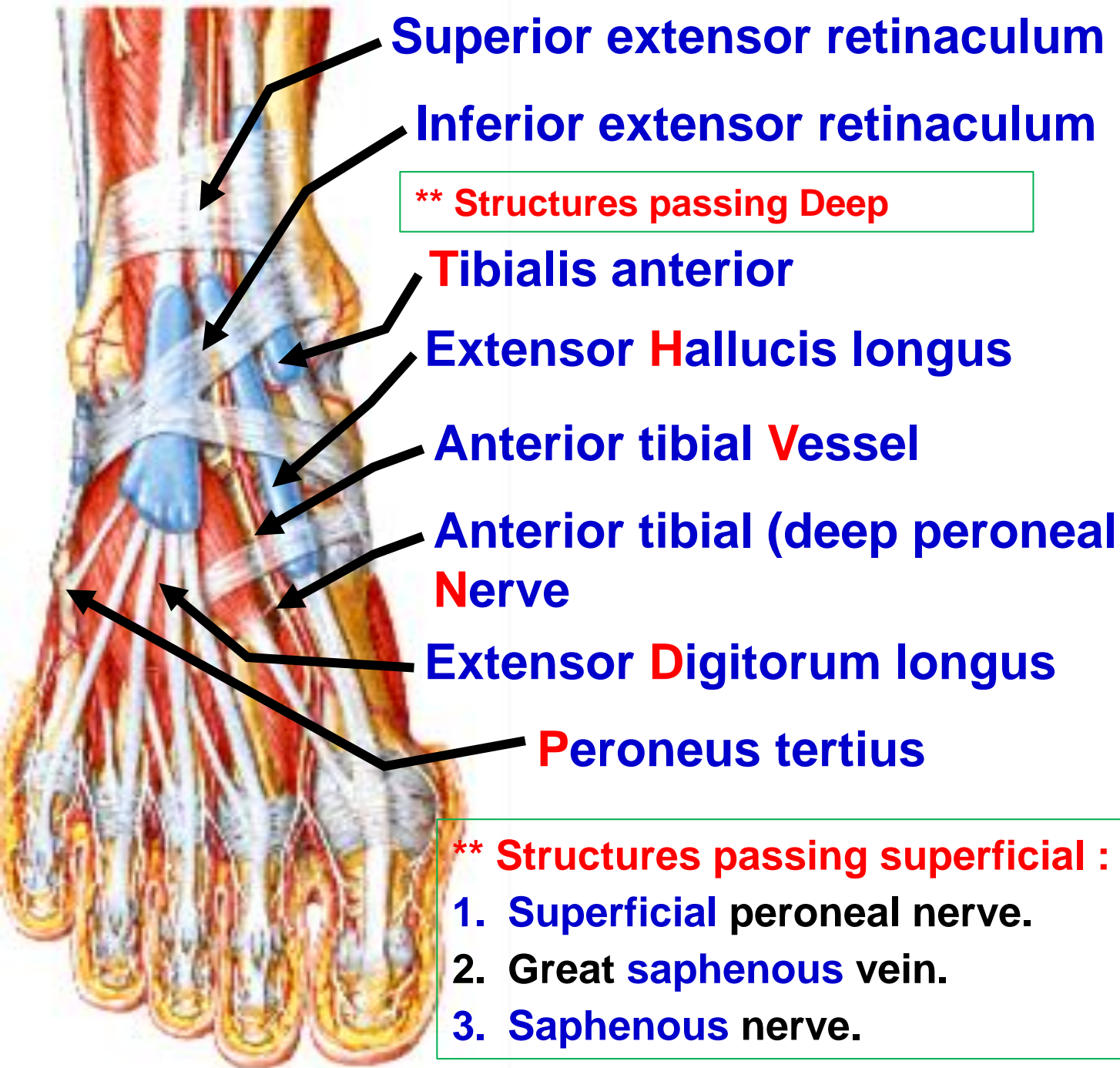
3) Dorsum of toes **except** lateral side of little toe (sural nerve).



Extensor retinaculum of foot

الليوتيوب د. يوسف حسين

<https://www.youtube.com/@ProfDrYoussefHusseinaAnatomy/playlists>




- **Extensor Retinaculum**
Thickened band of the deep fascia
- 1- **Superior Extensor Retinaculum,**
**** Attachment;** lower part of anterior border of fibula (**Lateral**) to lower part of anterior border of the tibia (**Medial**) .
 - 2- **Inferior,** Y shaped band
**** Attachment;**
 - **Laterally, Stem** attached to superior surface of the calcaneus.
 - **Medially,**
 - a- Upper band medial malleolus.
 - b- Lower band fuses with deep fascia of foot.

اليوتيوب د. يوسف حسين

https://www.youtube.com/channel/UCVSNqbibj9UWYaJdd_cn0PQ

يُمنع أخذ السلايدات بدون
إذن المحرر واي اجراء
يخالف ذلك يقع تحت
طائلة المسؤولية القانونية

اليوتيوب د. يوسف حسين



<https://www.youtube.com/@ProfDrYoussefHusseinAnatomy/playlists>