

TUBULOINTERSTITIAL DISEASES

L3

Sura Al-Rawabdeh, MD

May 16 2022

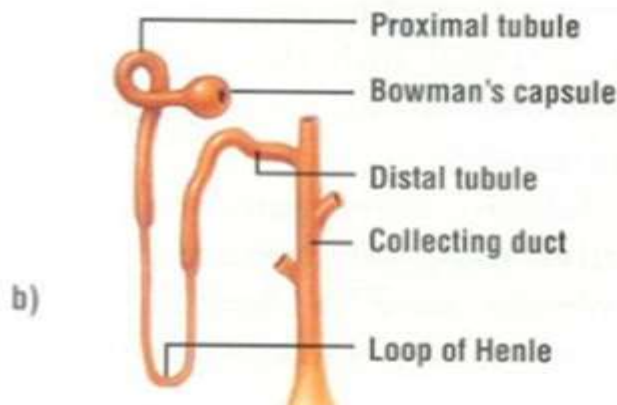
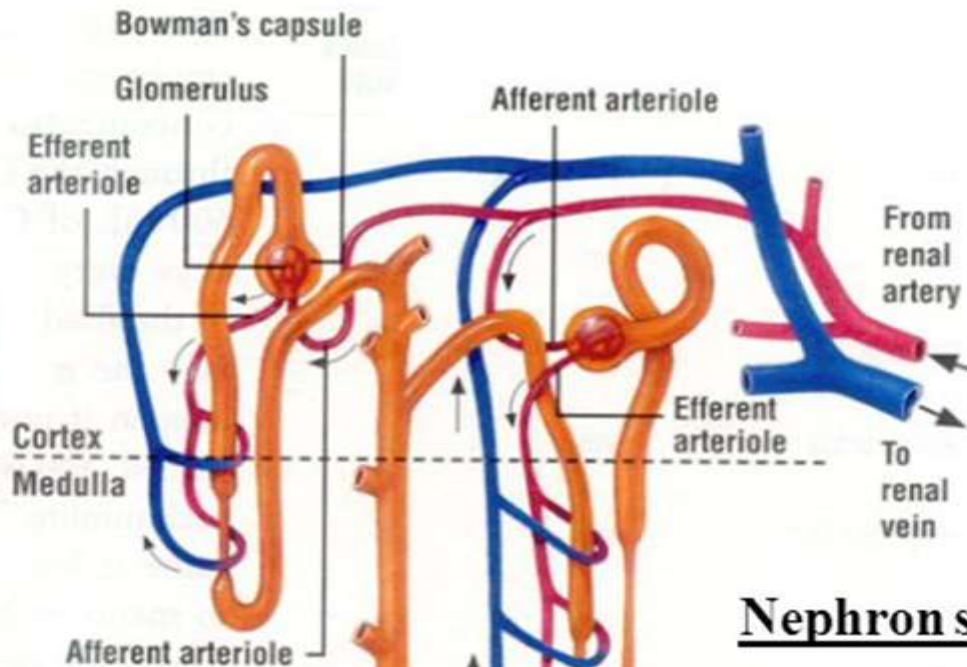
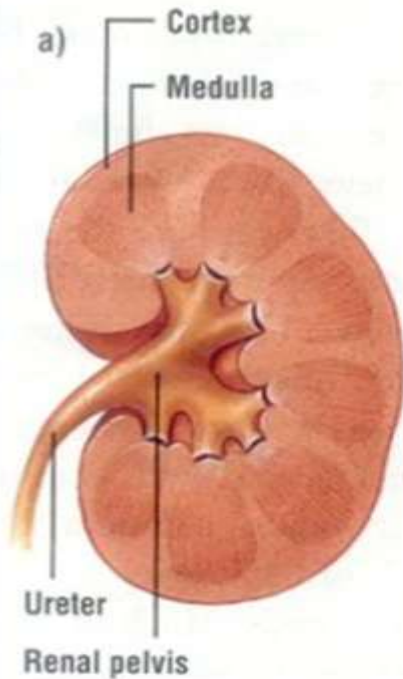
TUBULOINTERSTITIAL DISEASES

- ▶ **Most forms of tubular injury also involve the interstitium**
- ▶ **Presented under this heading are diseases characterized by**
 - (1) inflammatory involvement of the tubules and interstitium (tubulointerstitial nephritis)**
 - (2) ischemic or toxic tubular injury, leading to acute tubular injury and the clinical syndrome of acute kidney injury**

TUBULOINTERSTITIAL DISEASES

- ▶ Acute tubular injury/necrosis
- ▶ Tubulointerstitial nephritis

Each kidney consists of one million functional units: Nephrons



- Nephron structure**
- A) Glomerulus
 - B) Glomerular Capsule
 - C) Renal Tubule
 - proximal convoluted tubule
 - loop of Henle
 - distal convoluted tubule
 - D) Collecting Duct

ACUTE TUBULAR INJURY/NECROSIS (ATN)

- ▶ **Acute tubular injury (ATI) is a clinicopathologic entity characterized by damage to tubular epithelial cells and an acute decline in renal function**
- ▶ **Commonest cause of acute renal failure.**
- ▶ **Two types: Ischemic & nephrotoxic ATN**
- ▶ **Main cause of functional derangement is a profound decrease in the GFR. This is caused by:**
 - ▶ Arteriolar vasoconstriction
 - ▶ Tubular obstruction
 - ▶ Back-leak into interstitium

Ischemic acute renal failure

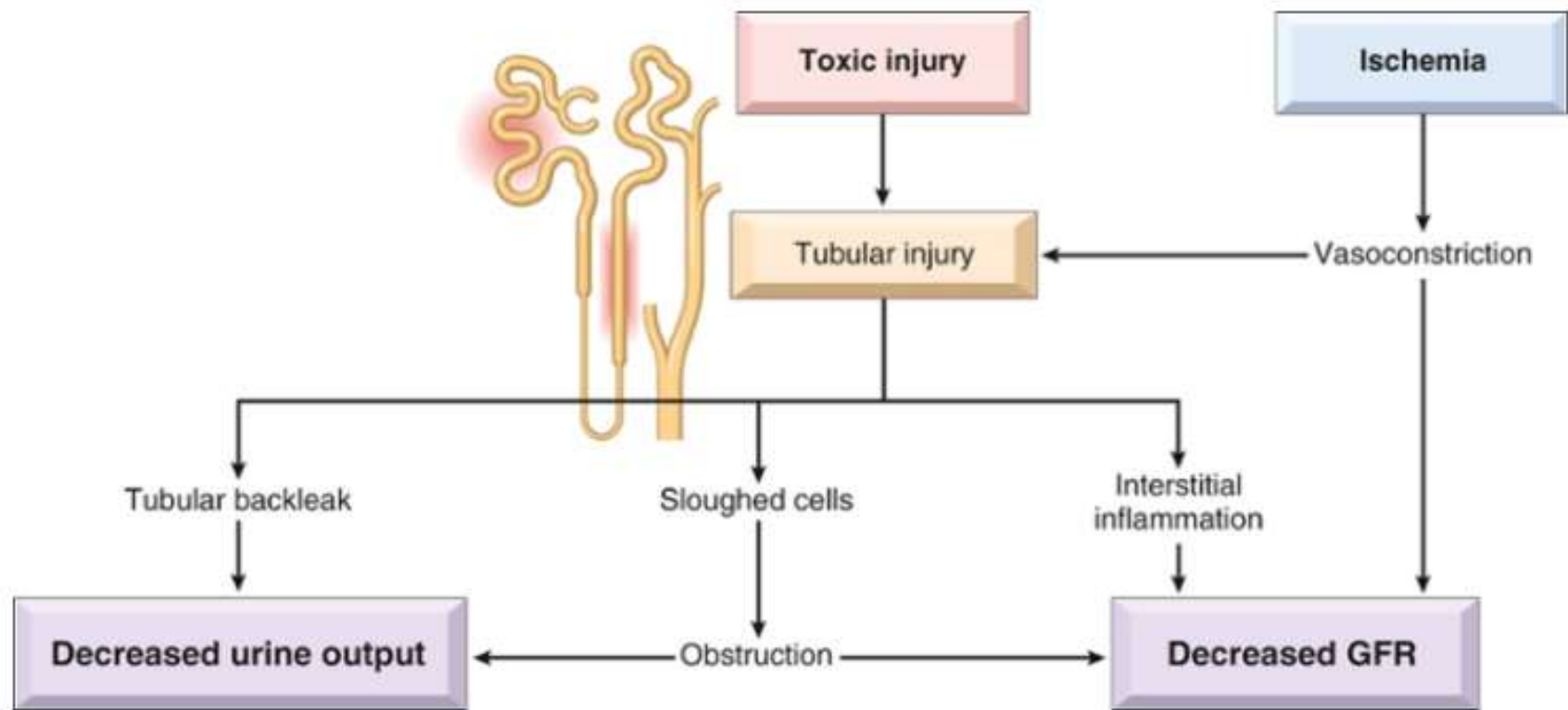



FIG. 14.16  Postulated sequence in ischemic or toxic tubular injury.

Causes of ATN

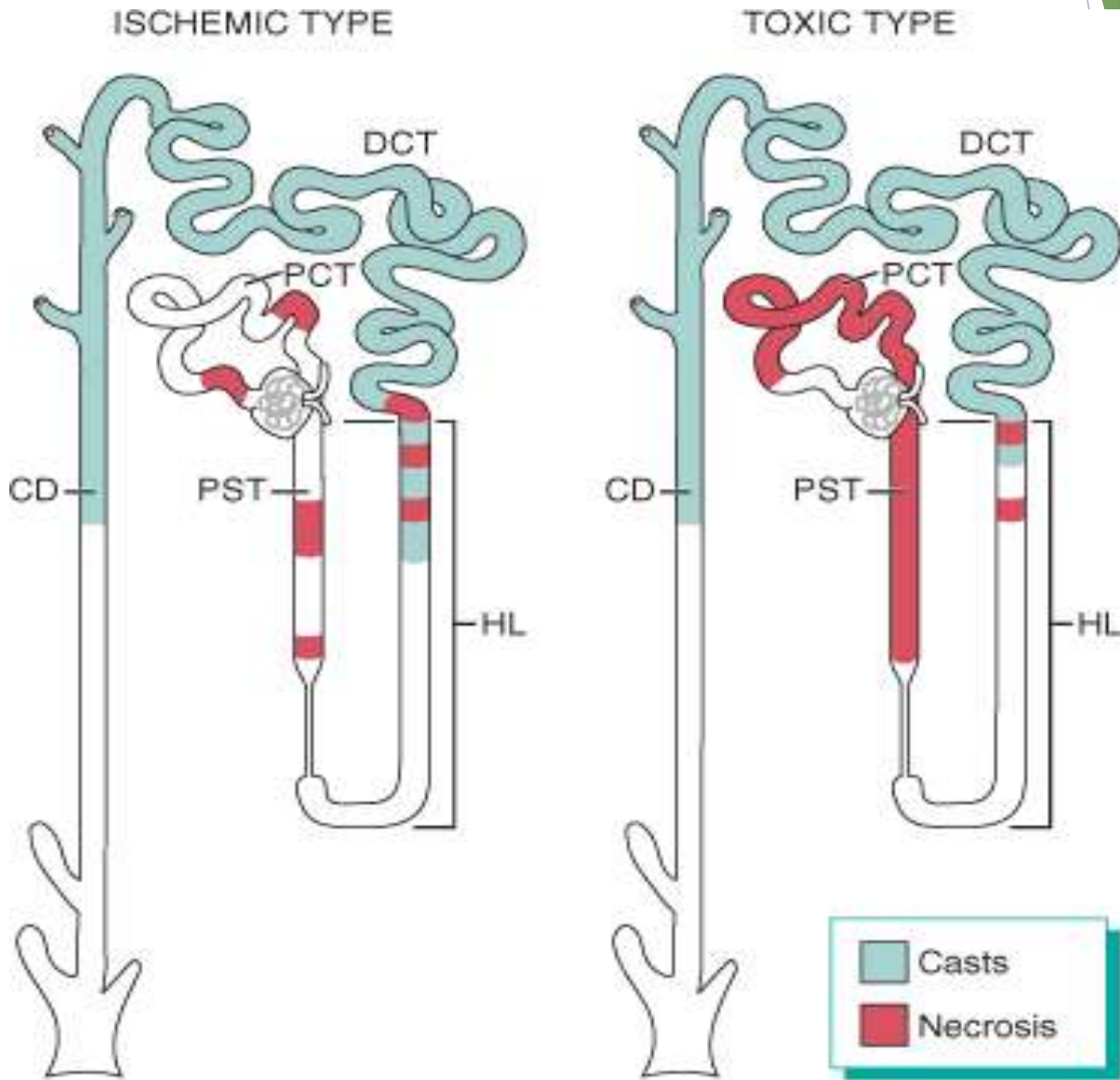
▶ **Ischemic:**

- ▶ **Medical:** Septicemia, gastroenteritis, pneumonia, MI
- ▶ **Surgical:** Multiple injuries, burns, peritonitis, pancreatitis, massive hemorrhage
- ▶ **Obstetric:** Ante-partum hemorrhage, pre-eclamptic toxemia

▶ **Nephrotoxic:**

- ▶ **Drugs:** Gentamycin, other antibiotics, X-ray contrast media
- ▶ **Chemicals:** Organic solvents (CCl_4), metals (mercury & arsenic)
- ▶ **Endogenous products:** Hemoglobin, myoglobin

Patterns of tubular damage in toxic & ischemic ATN



Patterns of tubular damage in toxic & ischemic ATN

- ▶ **Ischemic ATI** is characterized by lesions in the straight portions of the proximal tubule and the ascending thick limbs, but no segment of the proximal or distal tubules is spared.
- ▶ **Nephrotoxic ATI** is basically similar, with some differences. Overt necrosis is usually more prominent in the proximal tubule than in ischemic AT

Morphology of ATN

- ▶ Lesions in ischemic ATN tend to be focal and patchy at multiple points along the nephron.
- ▶ Lesions of toxic ATN predominantly involve the proximal convoluted tubule.
- ▶ Main features include:
 - ▶ Necrosis & apoptosis of tubular epithelial cells.
 - ▶ Occlusion of tubules by hyaline & cellular casts.
 - ▶ Interstitial inflammation.
 - ▶ Epithelial regeneration.

ATN

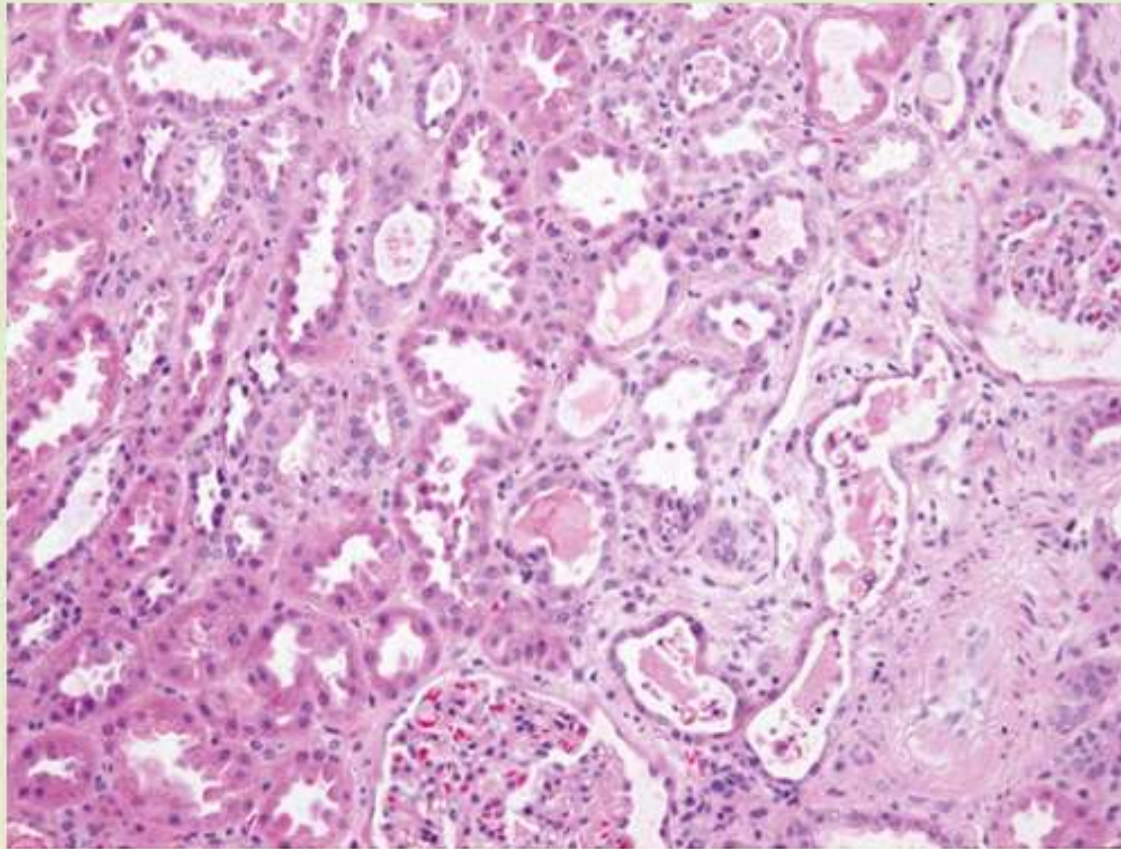


FIG. 14.17  Acute tubular epithelial cell injury with blebbing at the luminal pole...

TUBULOINTERSTITIAL NEPHRITIS (TIN)

- ▶ **TIN produces features of tubular dysfunction rather than features of glomerular injury**
 - ▶ **Polyuria & nocturia**
 - ▶ **Salt wasting**
 - ▶ **Metabolic acidosis**

- ▶ **Main causes are drugs, infections**

- ▶ **Acute TIN: Interstitial edema, WBC infiltration & focal tubular necrosis**

- ▶ **Chronic TIN: Interstitial fibrosis, mononuclear infiltration & tubular atrophy**

DRUG INDUCED TUBULOINTERSTITIAL NEPHRITIS

ACUTE DRUG-INDUCED TIN

- ▶ A hypersensitivity reaction that develops about 2 weeks after exposure to a number of drugs:
 - ▶ Sulphonamides, synthetic penicillins, diuretics & NSAIDs
- ▶ Clinically
 - ▶ Fever, eosinophilia, skin rash (25%)
 - ▶ Renal abnormalities: hematuria, mild PTNuria, leukocyturia
 - ▶ ARF may develop in 50% of patients
- ▶ Histologically eosinophils are often seen and granulomas are sometimes present.

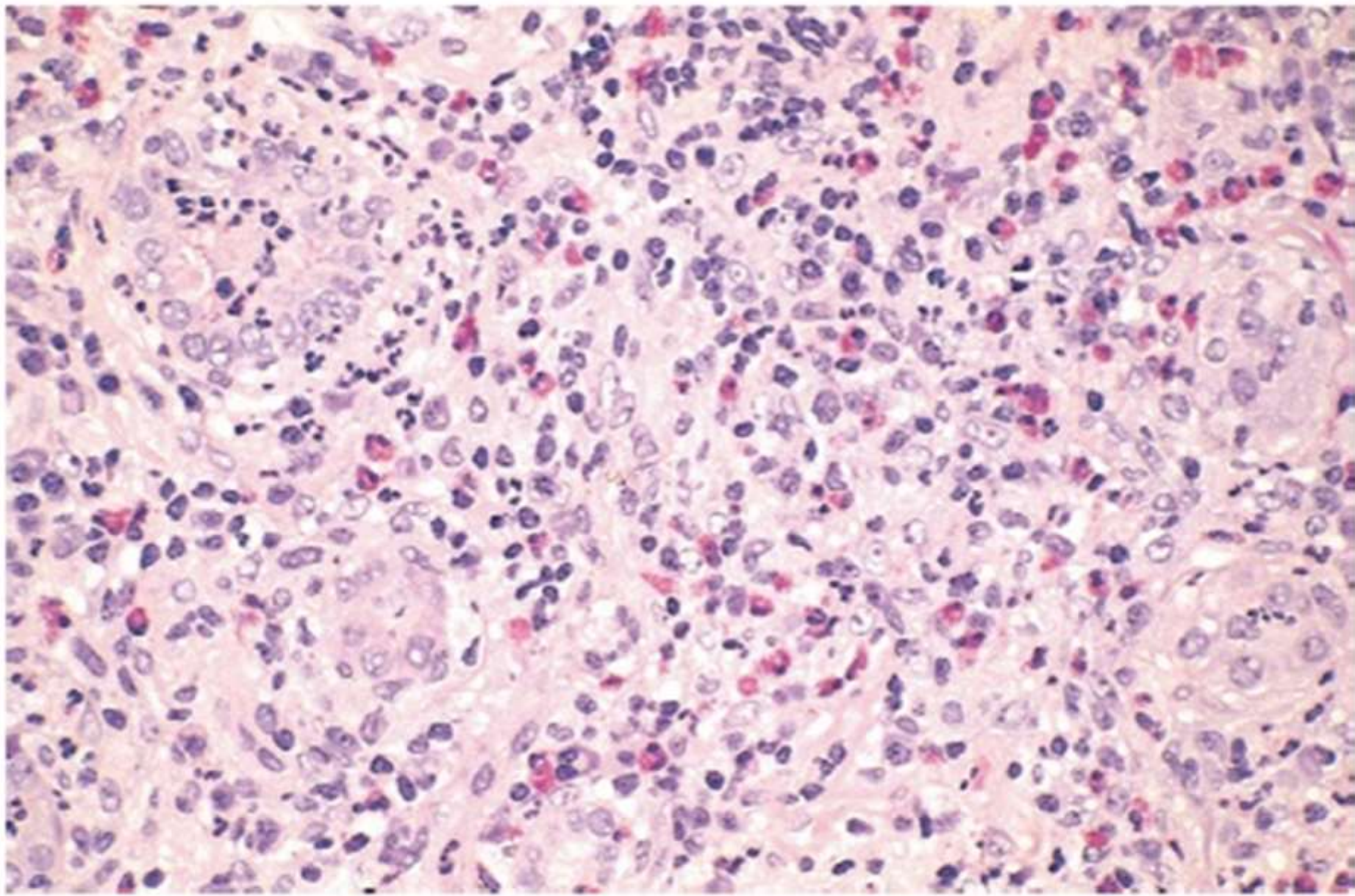


Figure 13-16 Drug-induced interstitial nephritis, with prominent eosinophilic and mononuclear infiltrate.

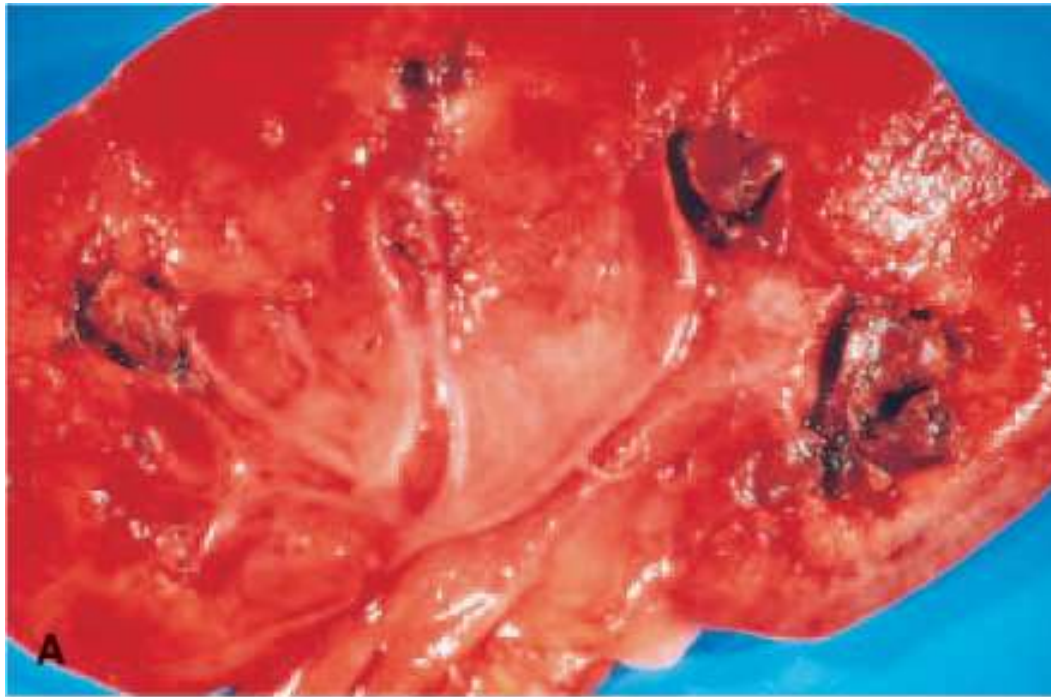ANALGESIC ABUSE NEPHROPATHY

- ▶ Chronic drug-induced TIN with renal papillary necrosis associated with long term use of some NSAIDs:
 - ▶ Phenacetin
 - ▶ Mixtures containing phenacetin, aspirin, acetaminophen
- ▶ A common cause of CRF
- ▶ Primary event is papillary necrosis (**ischemic and suppurative necrosis of the tips of the renal pyramids (renal papillae)**) followed by TIN
 - ▶ Acetaminophen causes cell injury by covalent binding & oxidative damage
 - ▶ Aspirin potentiates damage by inhibiting the vasodilator effect of prostaglandins

- ▶ **Morphology:** Patchy necrotic papillae with atrophy of overlying cortex & chronic TIN
- ▶ **Clinical features:**
 - ▶ Anemia
 - ▶ Hypertension
 - ▶ CRF
 - ▶ Hematuria & renal colic
- ▶ **Complications:**
 - ▶ Urinary tract infection
 - ▶ Transitional cell carcinoma

Other causes of papillary necrosis include diabetes, urinary tract obstruction, and sickle cell anemia

Analegistic nephropathy



© Elsevier 2005

URINARY TRACT INFECTION (UTI) & PYELONEPHRITIS

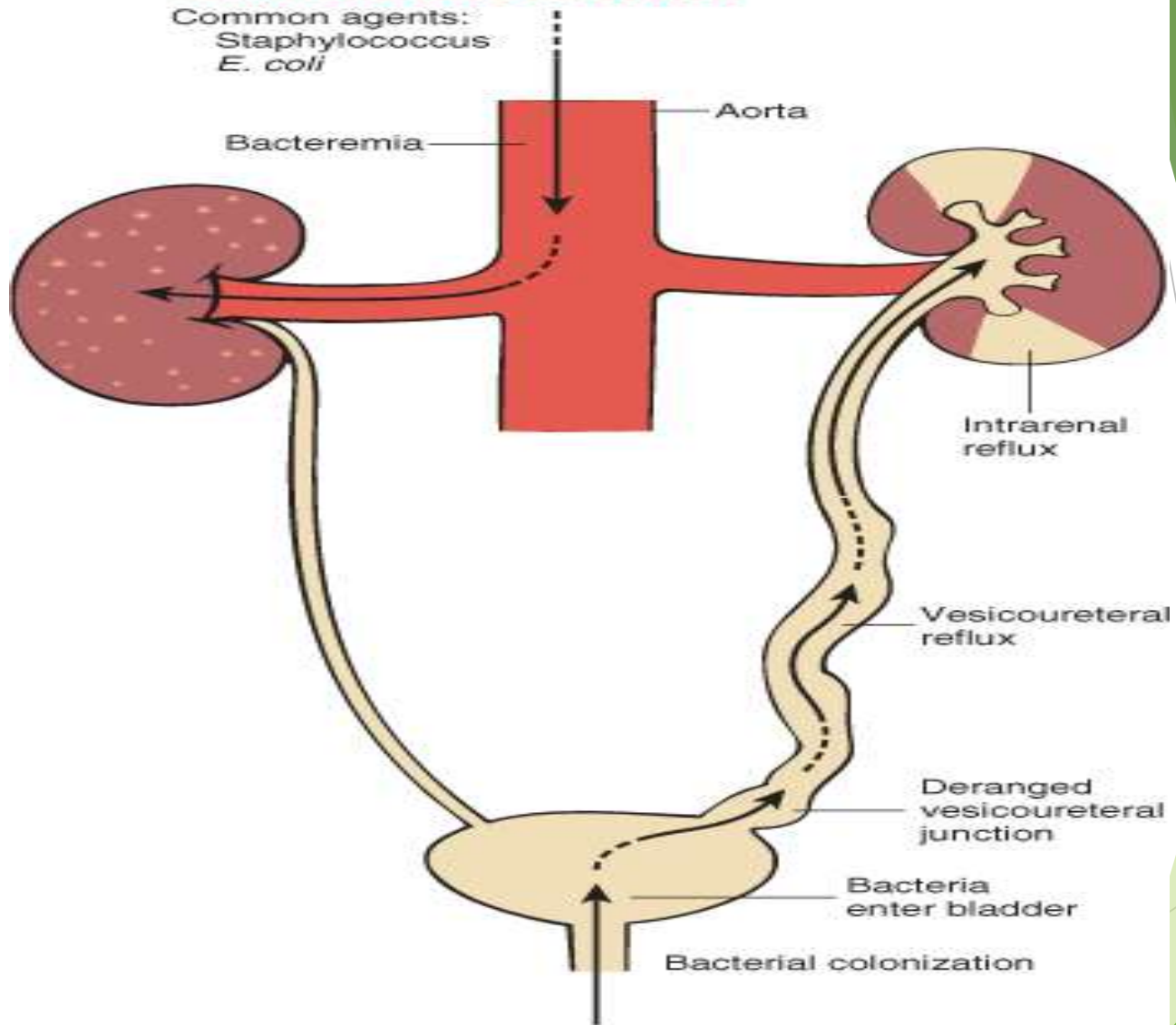
- ▶ **UTI: Presence of bacteria in the urine.**
 - ▶ **Asymptomatic bacteriuria**
 - ▶ **Lower UTI (cystitis, prostatitis, urethritis)**
 - ▶ **Produces frequency, burning micturition & suprapubic pain**
 - ▶ **Upper UTI (Pyelonephritis-[PN])**
- ▶ **Causative organisms:**
 - ▶ ***Escherichia coli***
 - ▶ **Species of *Klebsiella*, *Enterobacter*, *Proteus*, *Pseudomonas***
 - ▶ **Staphylococci & *Streptococcus faecalis***
- ▶ **Infection is either hematogenous or ascending**

Pathogenesis of ascending infection

- ▶ Colonization of distal urethra & introitus.
 - ▶ Attachment of bacterial P-fimbria (pilli) to receptors on urothelium
- ▶ Spread to the bladder.
 - ▶ Females: due to short urethra, urethral trauma, absent antibacterial properties or hormonal changes
 - ▶ Catheterization/Instrumentation
- ▶ Multiplication in the bladder
 - ▶ Lower UT obstruction
- ▶ Spread to ureter & pelvis
 - ▶ due to inherited defect in orifice, infancy, pregnancy, bladder dysfunction or obstruction
- ▶ Spread to renal parenchyma
 - ▶ Intrarenal reflux: due to open ducts at the upper & lower poles

HEMATOGENOUS INFECTION

Common agents:
Staphylococcus
E. coli

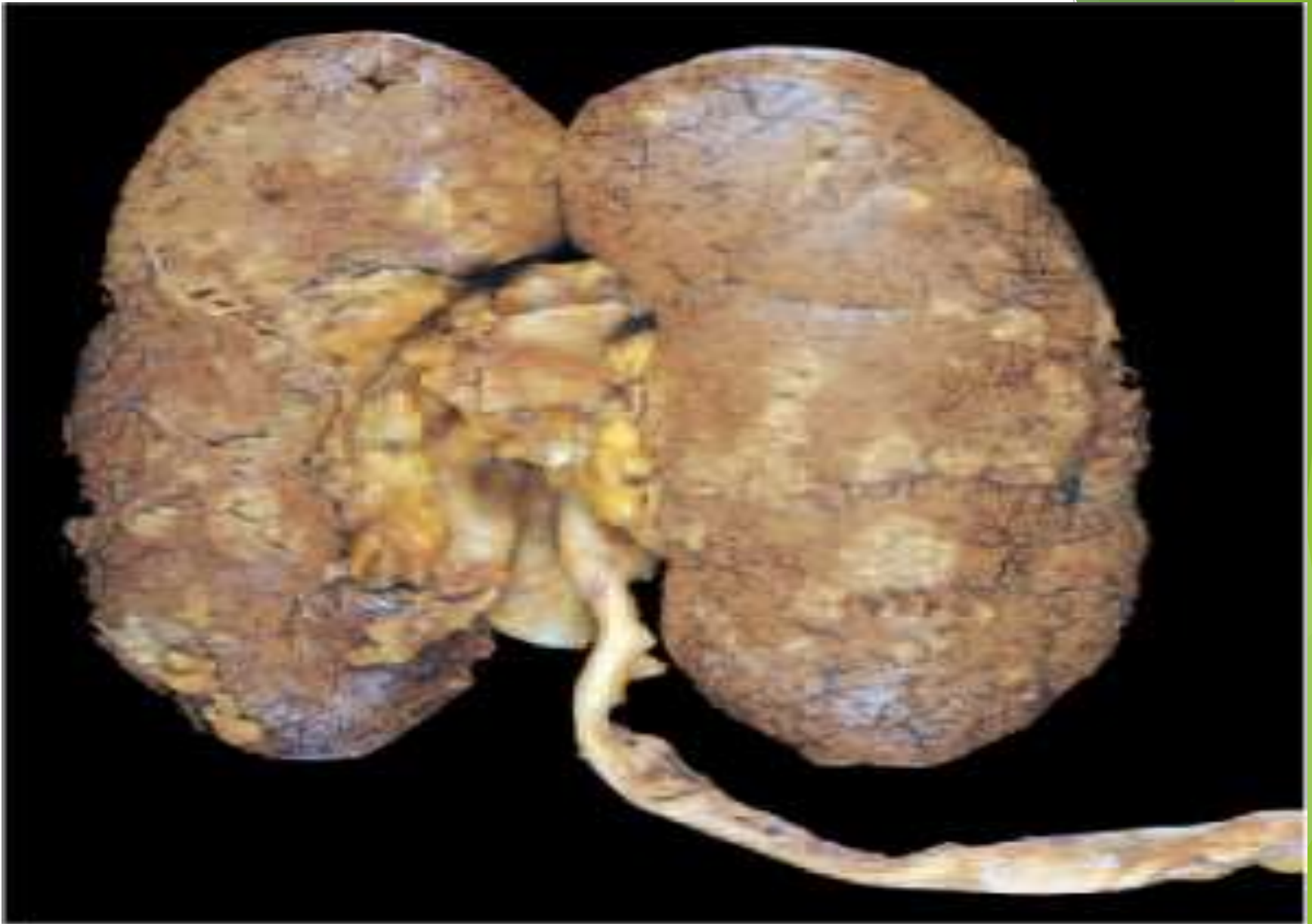

ASCENDING INFECTION

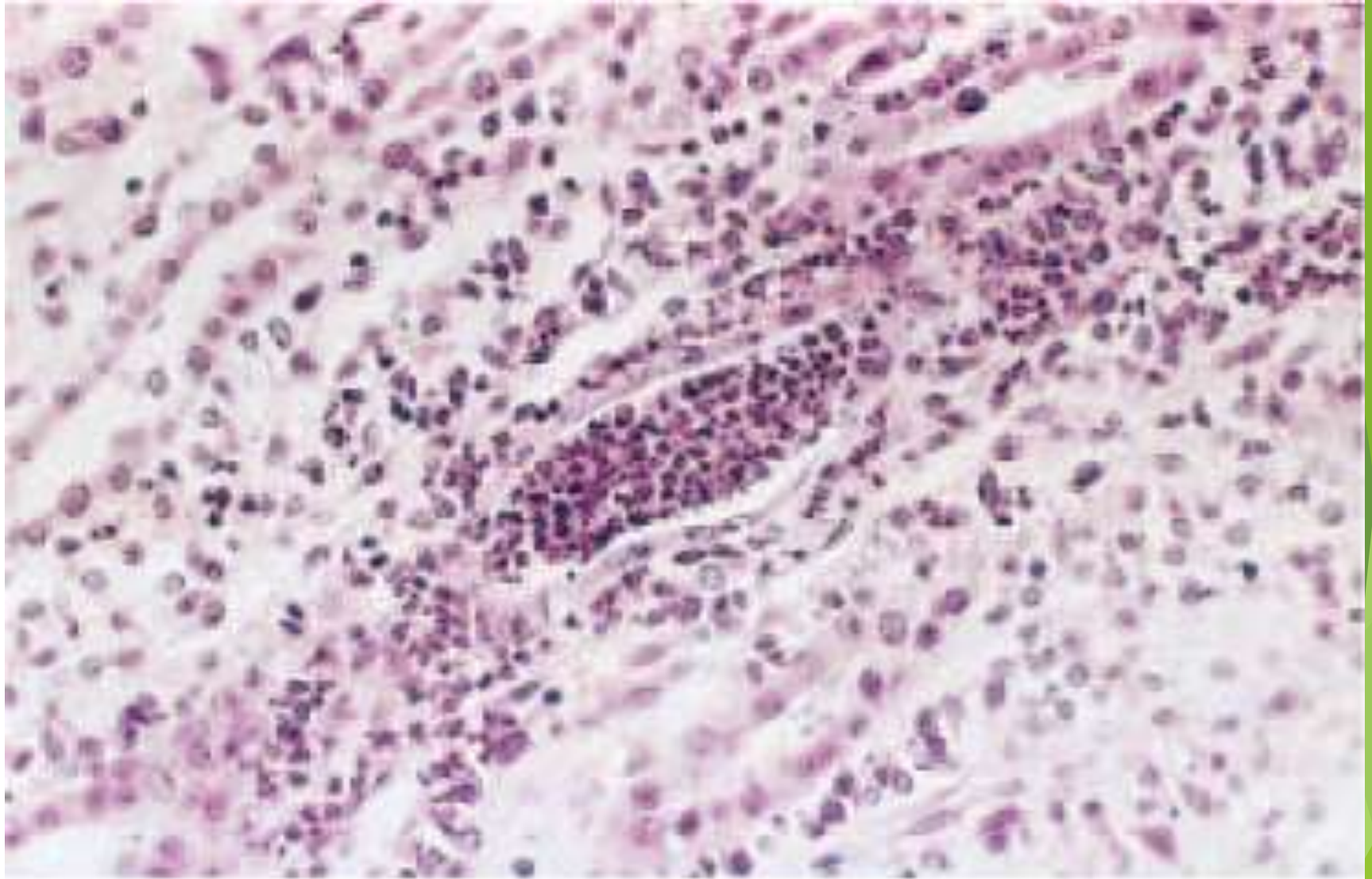
Common agents:
E. coli
Proteus
Enterobacter

ACUTE PYELONEPHRITIS

- ▶ **common suppurative inflammation of the kidney and the renal pelvis, is caused by bacterial infection**
- ▶ Morphologically: Patchy interstitial suppurative inflammation (\pm abscess) and tubular necrosis. \pm
 - ▶ Pyonephrosis
 - ▶ Papillary necrosis
 - ▶ Perinephric abscess
- ▶ Clinically: Fever, loin pain, + LUTI. Self-limited
- ▶ Urinary findings: bacteruria, pyuria, WBC casts



© Elsevier 2005

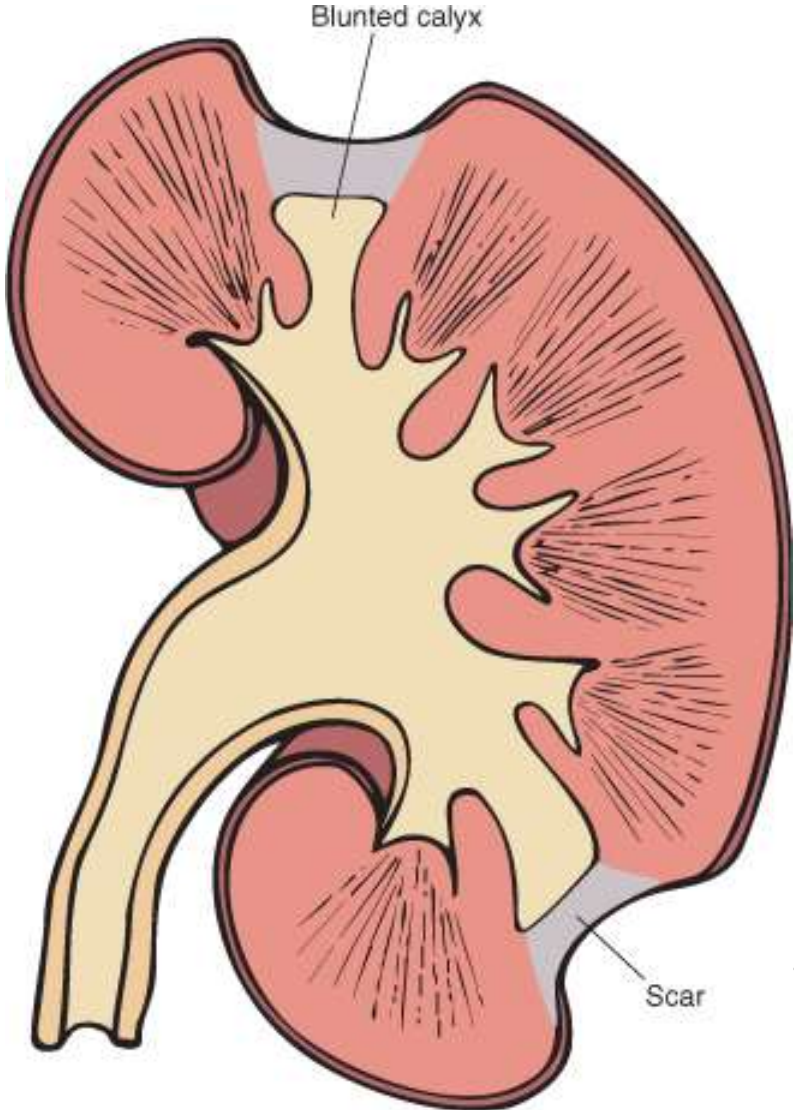


© Elsevier 2005

CHRONIC PYELONEPHRITIS

- ▶ **Chronic TIN + pelvicalyceal involvement. Responsible for 10-20% of CRF. Two forms**
 - ▶ **Chronic obstructive PN & Reflux nephropathy**
- ▶ **Grossly: Irregularly scarred contracted kidney with blunted, deformed calyces. Microscopically:**
 - ▶ **Chronic TIN + Thyroidization ± periglomerular fibrosis & occasionally FSGS**
 - ▶ **Xanthogranulomatous PN: Chronic PN with numerous foamy macrophages**
- ▶ **Clinically: Silent or gradual onset of CRF & hypertension ± proteinuria**

Chronic pyelonephritis



Thank you

The background features abstract, overlapping geometric shapes in various shades of green, ranging from light lime to dark forest green. These shapes are primarily located on the right side of the frame, creating a modern, layered effect against the white background.