

# **SHOULDER JOINT**

**Dr. Dalia M. Biram**

# The sternoclavicular joint

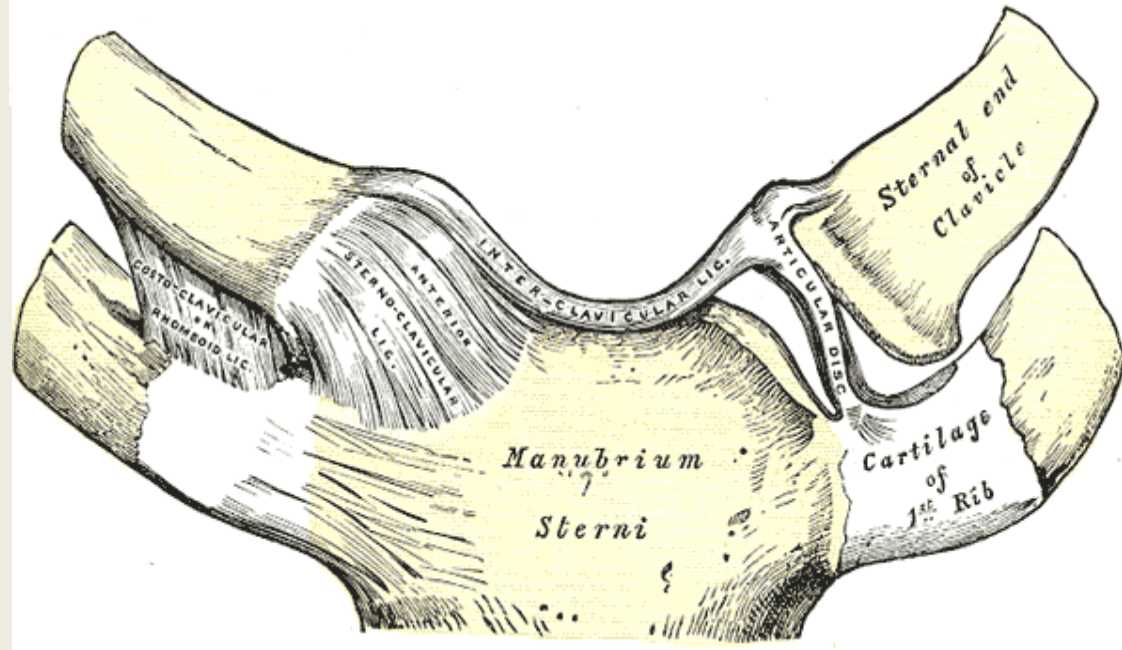
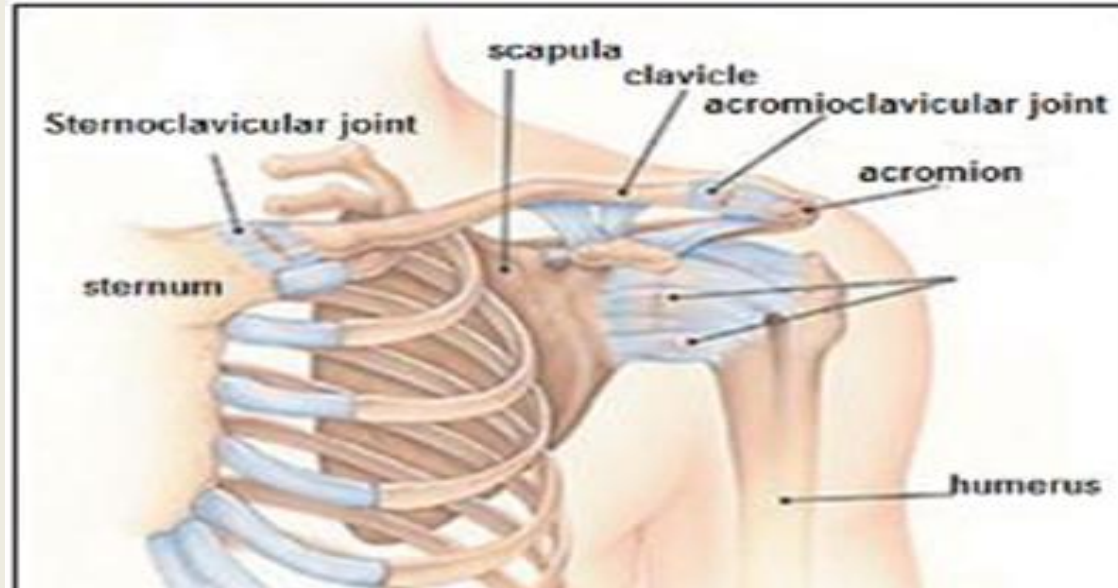
sternoclavicular articulation is a synovial saddle joint between the manubrium of the sternum, and the clavicle, as well as the first rib. The joint possesses a joint capsule, and an articular disk. The joint is reinforced by two intrinsic and two extrinsic ligaments. The costoclavicular ligament is the main limitation to movement, and therefore the main stabilizer of the joint.

## **intrinsic ligaments**

-Anterior and -Posterior sternoclavicular ligaments

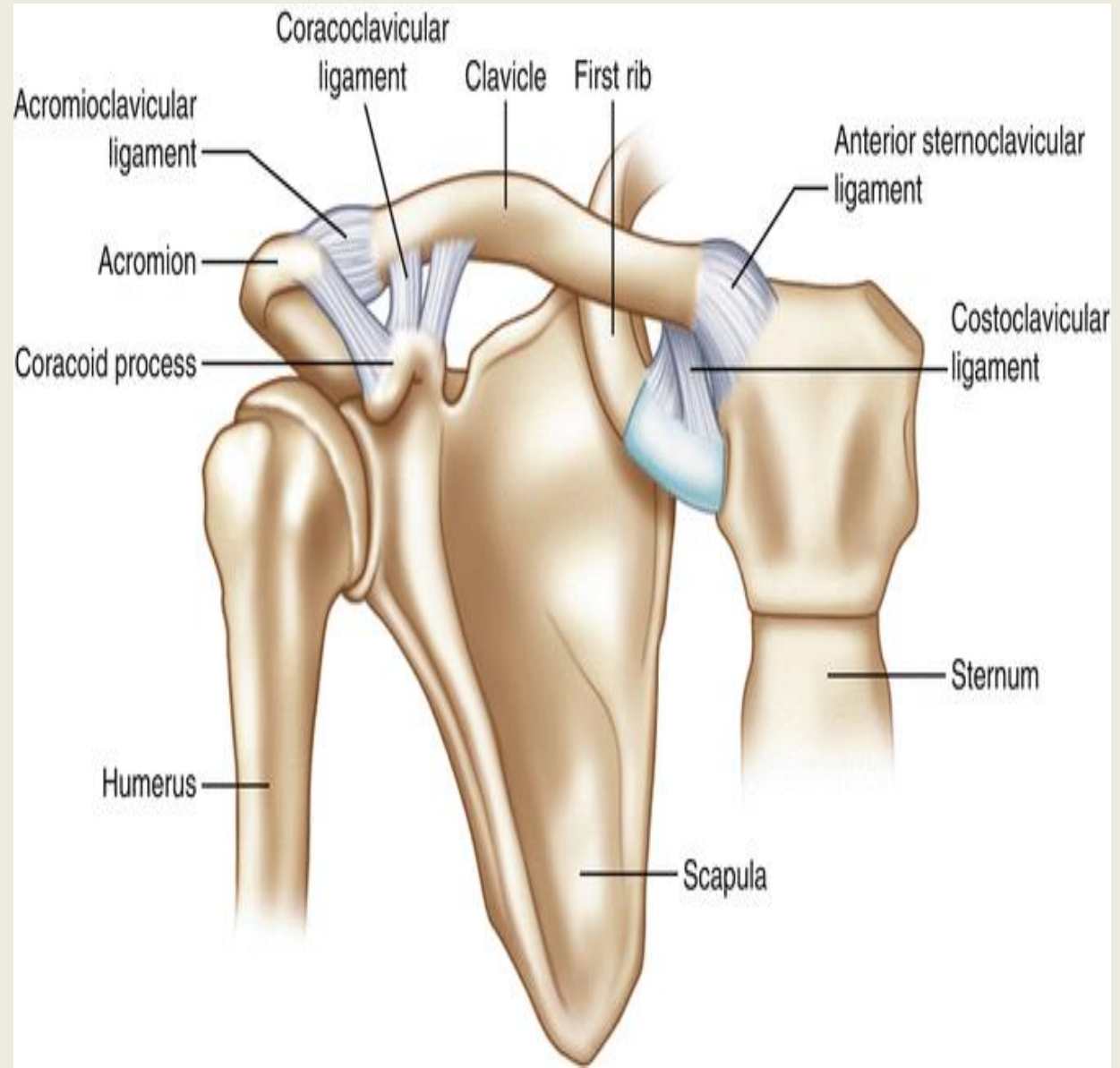
## **extrinsic ligaments**

Costoclavicular ligament and Interclavicular ligament



# Acromioclavicular Joint

The AC Joint is formed by the junction of the lateral clavicle and the acromion process of the **scapula** and is a gliding, or plane style synovial joint.

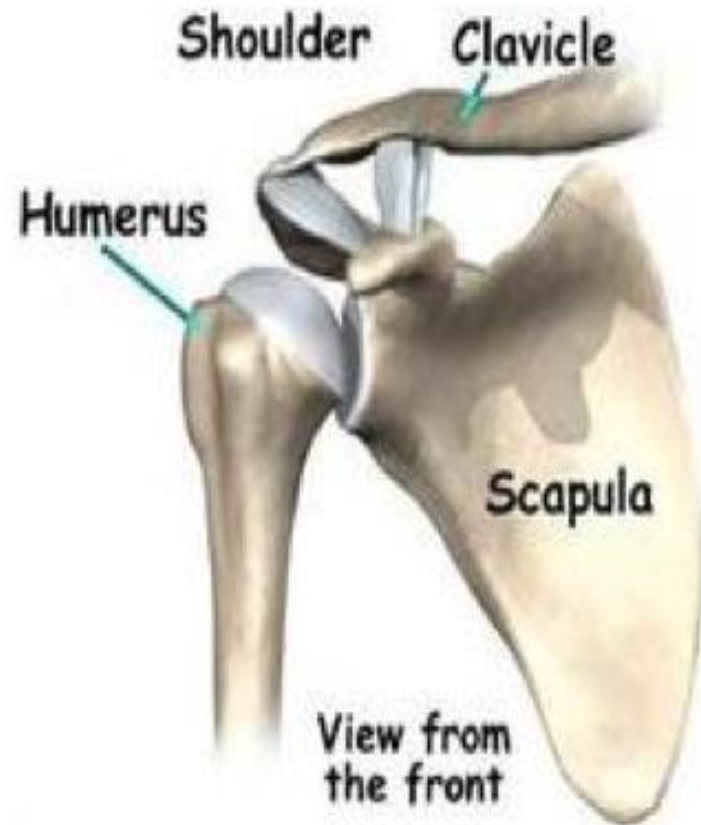


# Shoulder joint

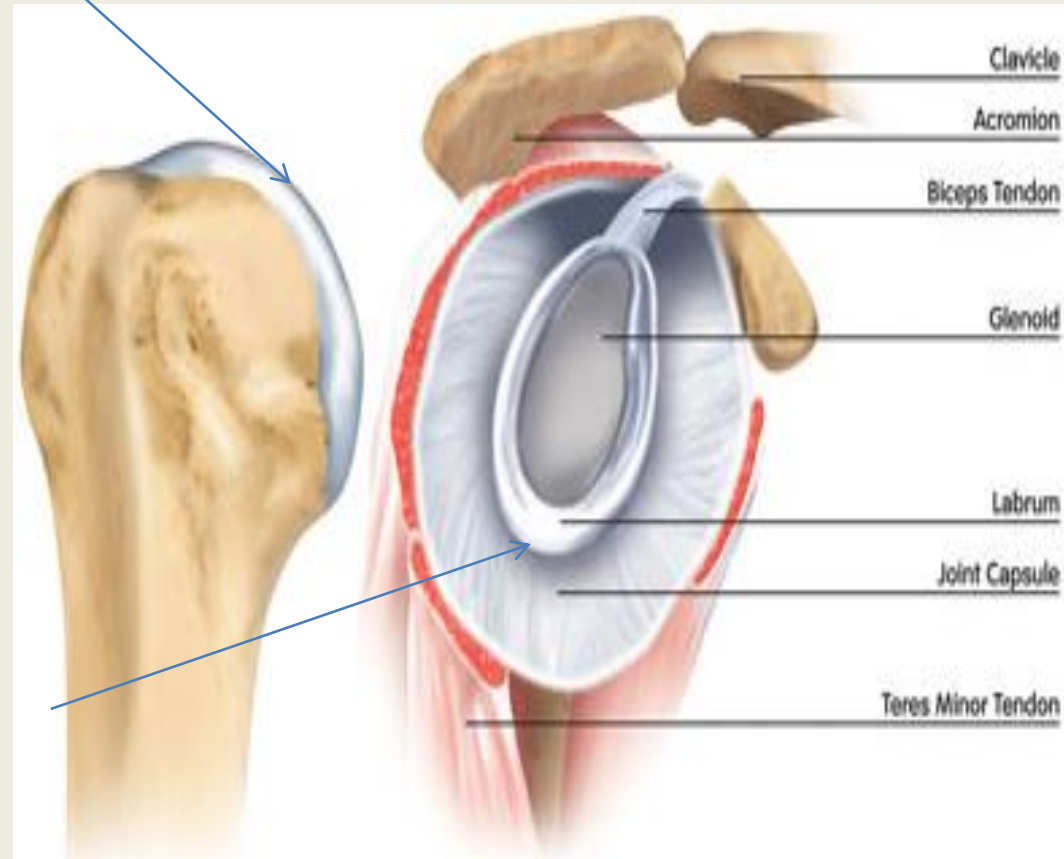
- **Type:**  
Synovial, polyaxial, ball & socket
- **Articular surface:**
  - a) Head of humerus
  - b) Glenoid cavity of scapula

\*Each of the articular surfaces is covered by hyaline cartilage.

\*The glenoid cavity is deepened by a fibro-cartilaginous rim; labrum glenoidal.



- **hyaline cartilage.**

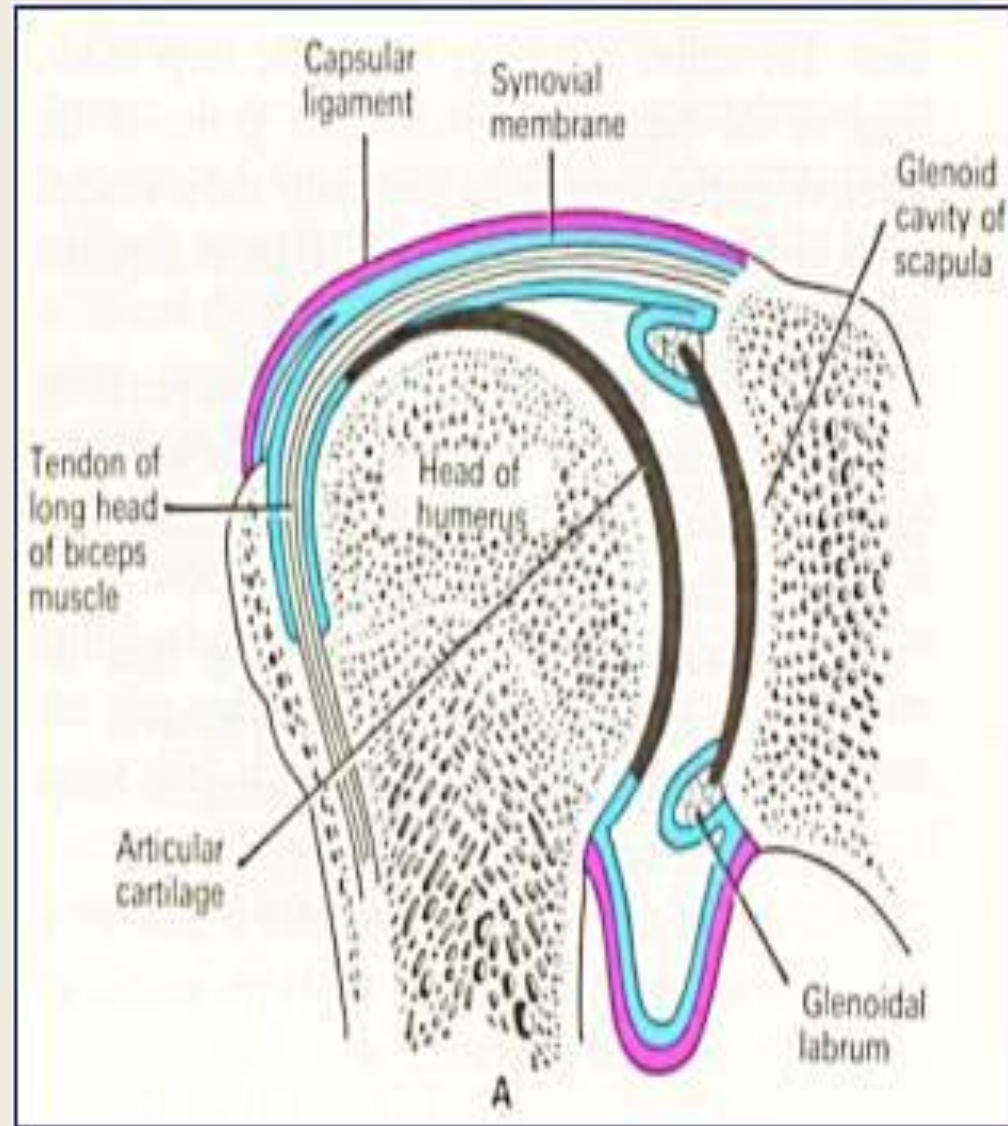


- **labrum glenoidal.**



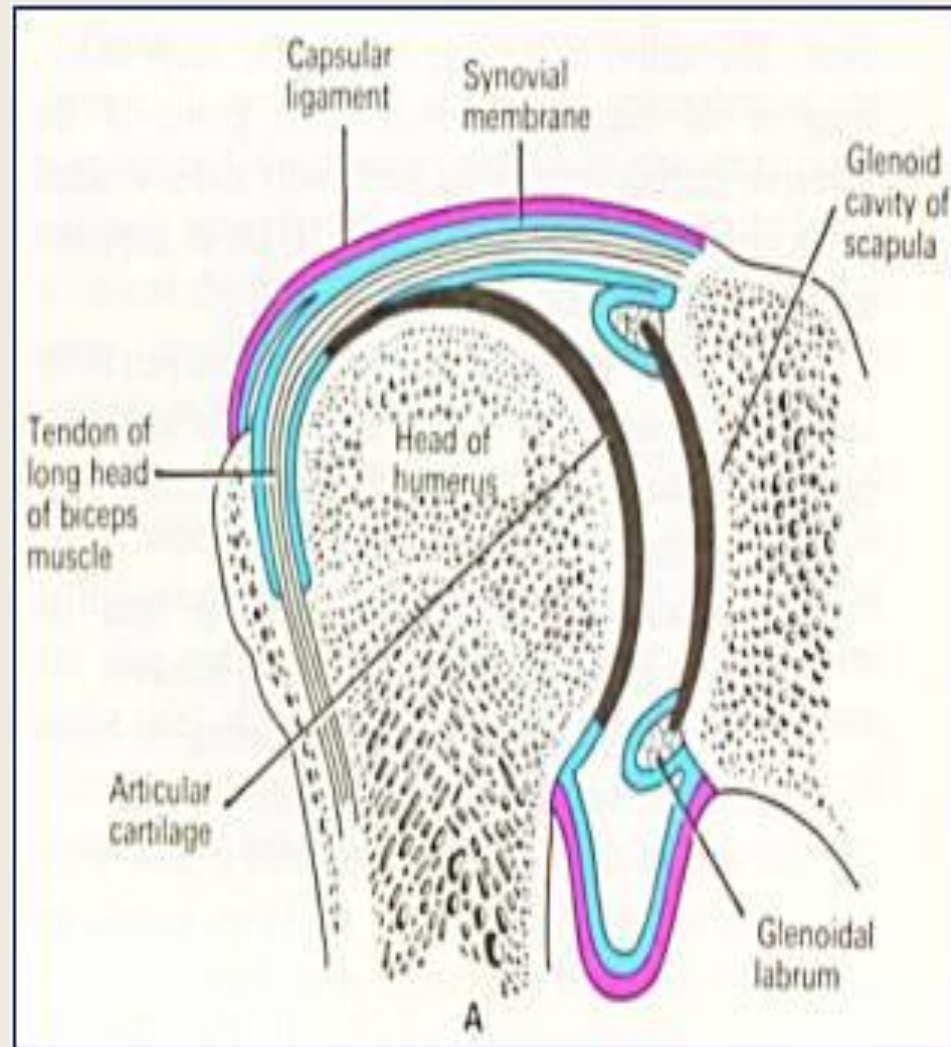
# Capsule

- attached to the margins of the glenoid cavity outside the labrum glenoidal.
- Laterally is attached to the anatomical neck of the humerus, except inferiorly where it extends about 1 cm to the shaft.



# Synovial membrane

- It lines **all the structures inside the capsule** of the shoulder joint EXCEPT the articular cartilage.
- It forms a tubular sheath around the tendon of long head of biceps, so it is an **intra-capsular, extra-synovial structure**.



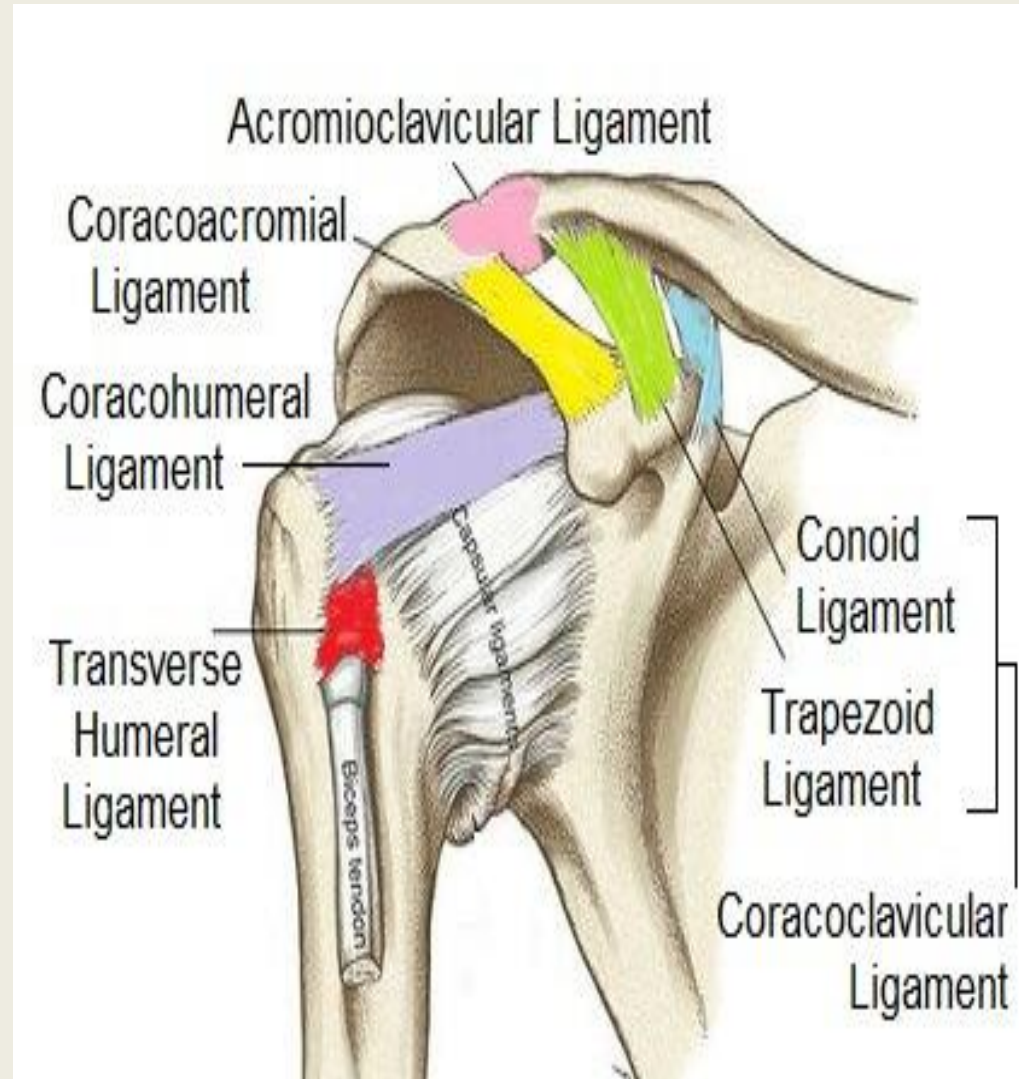
# LIGAMENTS RELATED TO SHOULDER JOINT(---- humeral)

## 1- False ligaments:

glenohumeral ligaments (Thickenings of the Capsule )

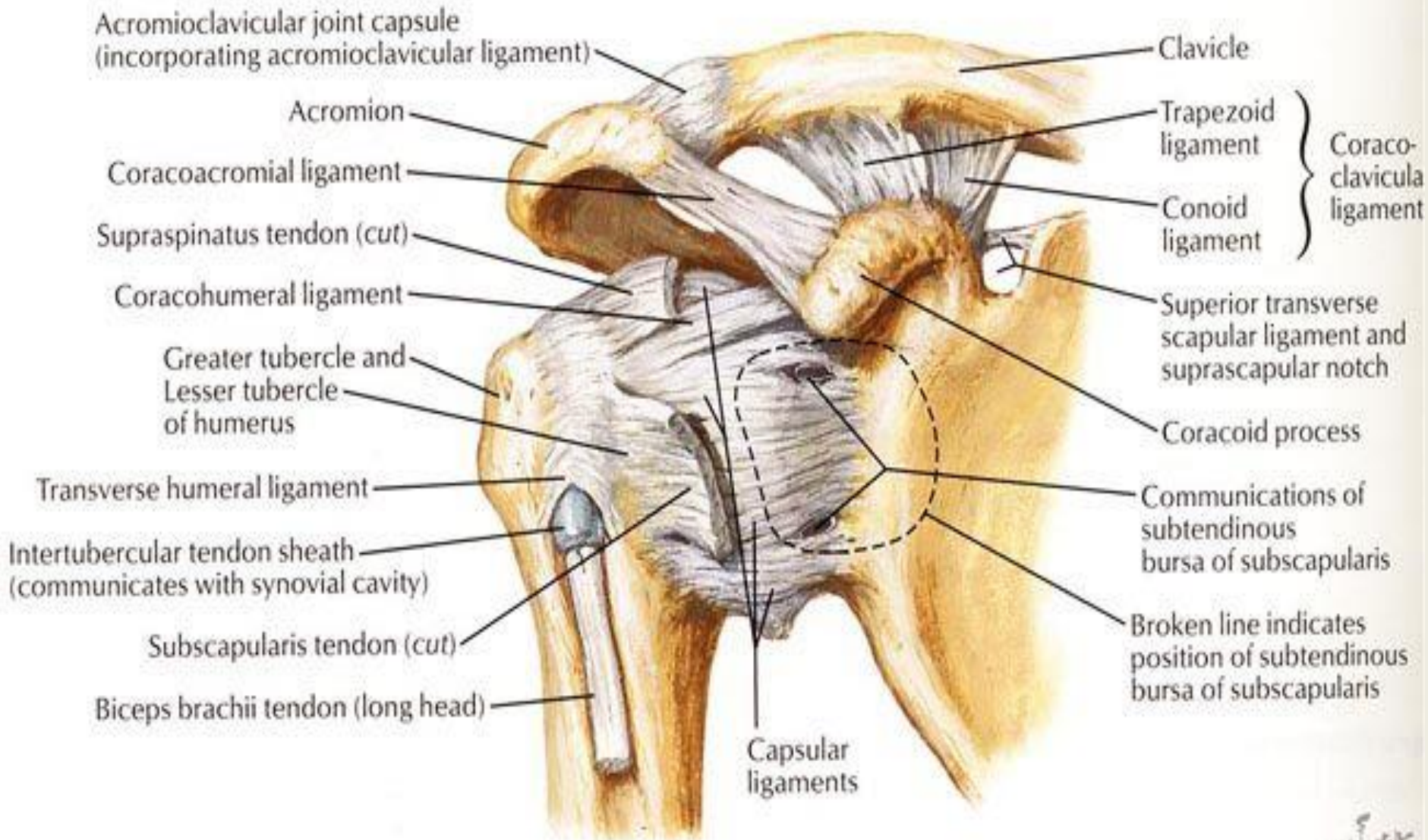
## 2- True ligaments:

- Coraco-humeral ligament.
- Transverse humeral ligament (bridges over the bicipital groove).





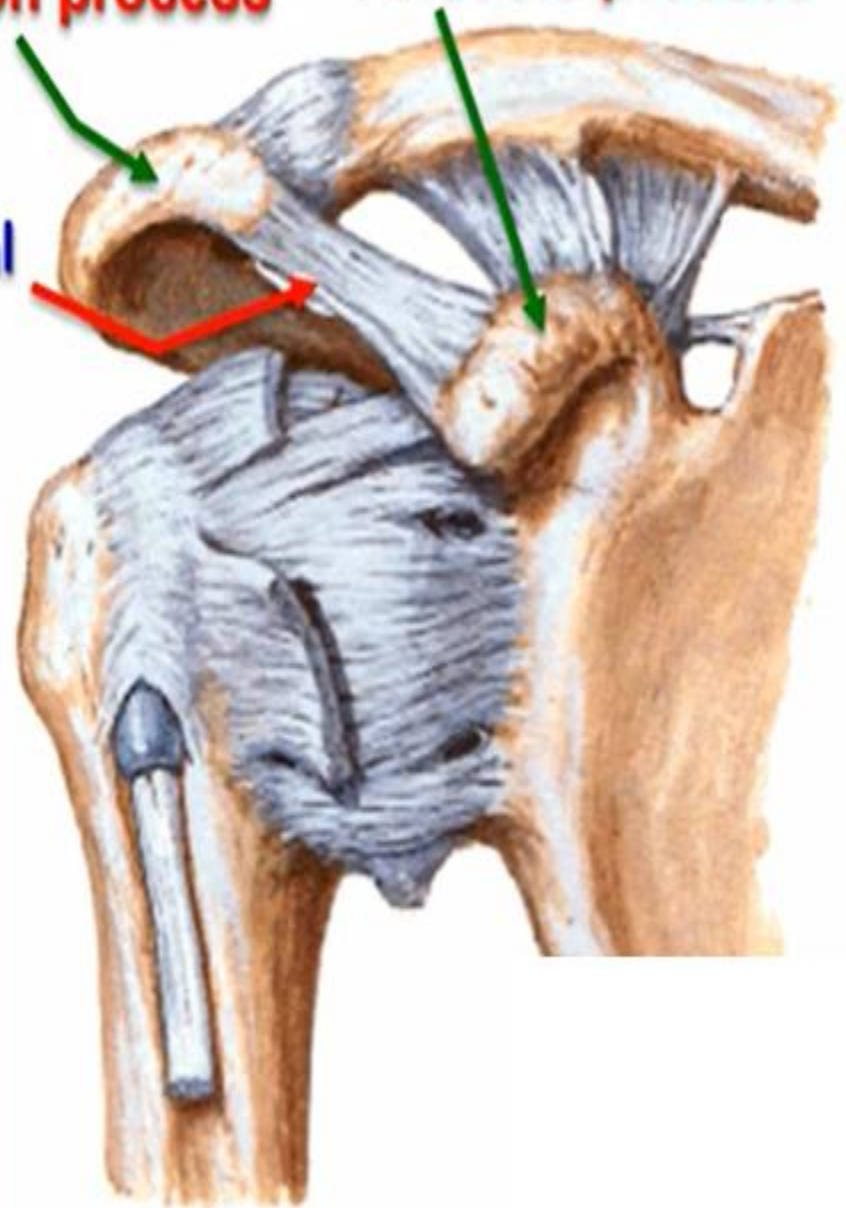
### Anterior view



**Acromion process**

**Coracoid process**

**Coracoacromial ligament**



❖ **Coracoacromial ligament:**

- between coracoid and acromion processes.
- It protects the superior aspect of the joint.
- It prevents superior displacement of head of humerus above the glenoid cavity.
- Ligament, coracoid and acromion processes called **Coracoacromial arch**

# Factors share in stability of shoulder joint

The stability of any joint is an action of 3 factors:

## 1- Bony factor

The shallow glenoid cavity opposite to a relatively larger head is a negative factor in stability of this joint. However the labrum glenoidale deepens the shallow glenoid cavity so it helps in stability of the joint.

Coraco-acromial arch, acts as a second socket for the head of humerus and prevents its upward dislocation.

## 2- Ligamentous factor

Labrum glenoidale.

Coraco-acromial ligament as bridges over the bony arch.

## 3. Muscular factor

It is the main factor aiding to stability of the joint.

Rotator cuff of muscles (they are the 4 muscles that firmly adherent to the capsule of shoulder joint; subscapularis, supraspinatus, infraspinatus and teres minor.

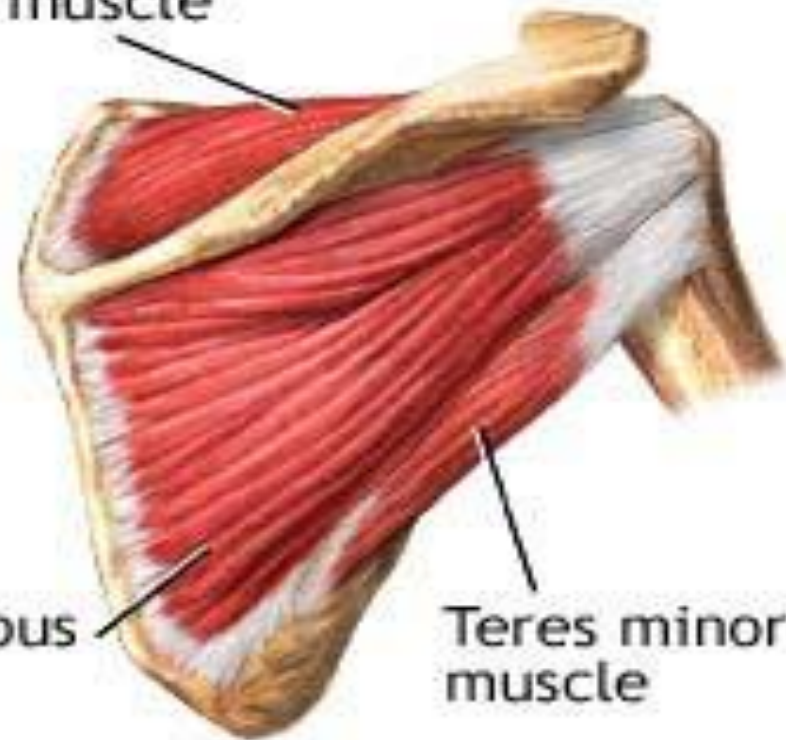
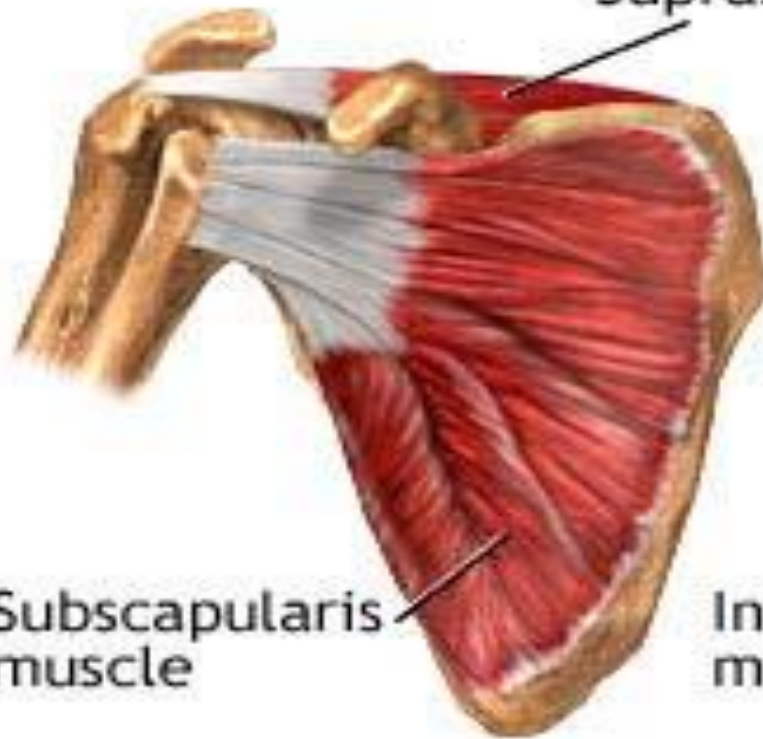
Splinting effect of long heads of biceps and triceps muscles.

Long head of biceps prevents upwards dislocation of the joint.



## Rotator cuff muscles

Supraspinatous muscle



Anterior shoulder

Posterior shoulder

## **\*\* Bursae related to the joint**

**1- Subscapularis bursa;** between the tendon of subscapularis and capsule.

It **communicates** with the joint cavity.

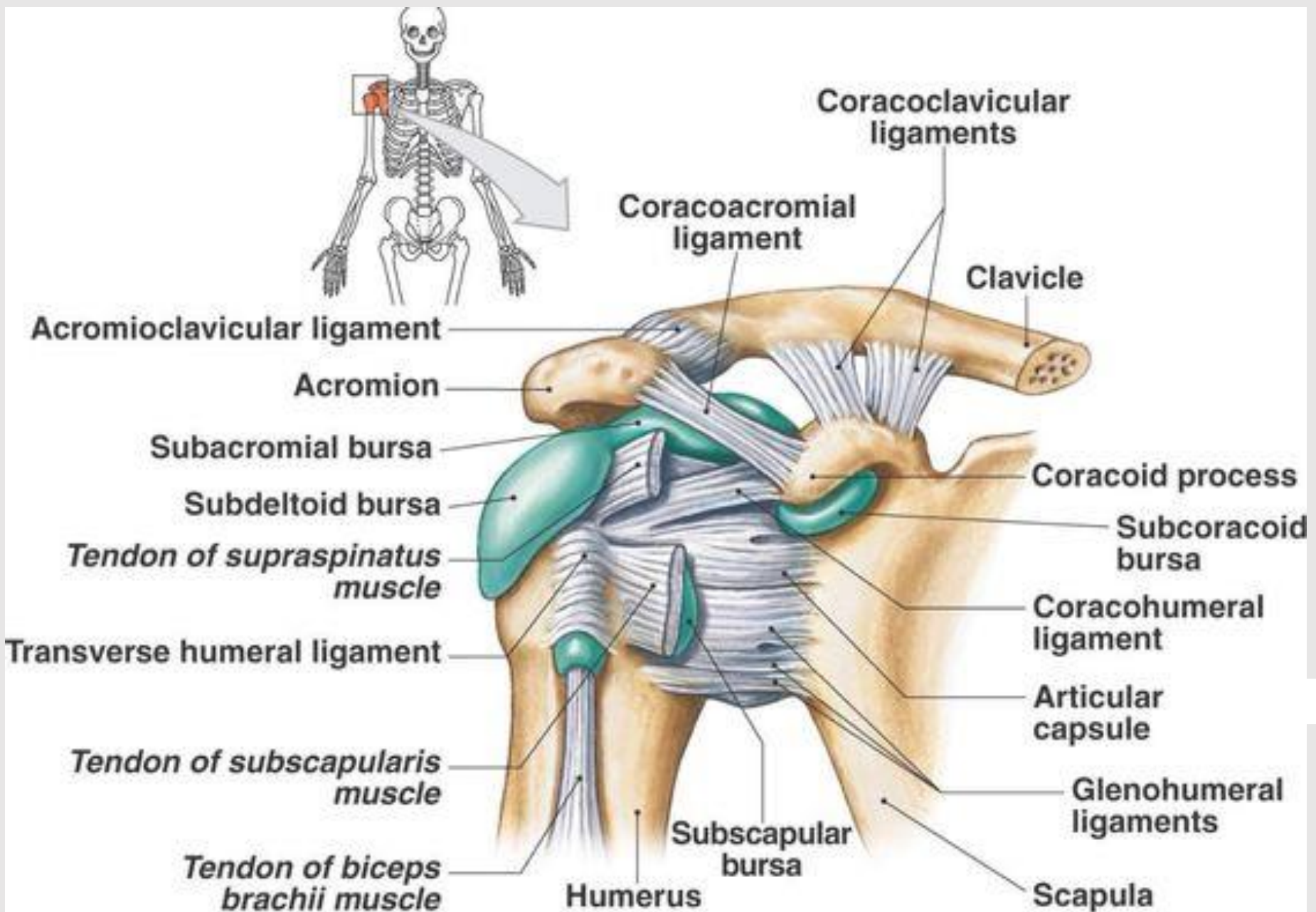
**2- Subacromial bursa;**

- It lies between the coracoacromial arch **above**, and supraspinatus tendon and capsule **below**.
- It continues downwards beneath the deltoid with **Subdeltoid bursa**.
- It is the **largest synovial bursa in the body** and facilitates the movements of supraspinatus tendon under the coracoacromial arch.
- It does not **communicate** with the joint cavity.

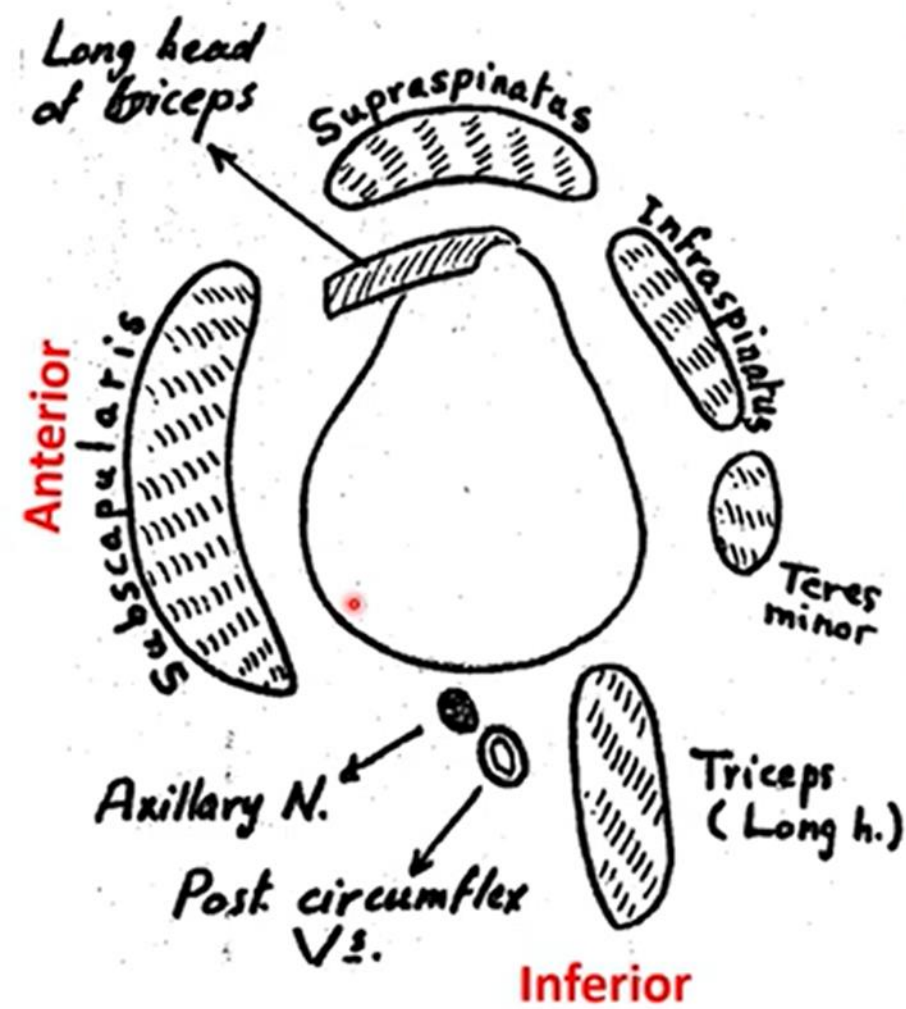
**3- Infraspinatus bursa;** between the tendon of infraspinatus and

capsule





(a) Anterior view



### ❖ Relations of the shoulder joint

- 1) **Anteriorly**; anterior fibers of the deltoid and subscapularis.
- 2) **Superiorly**: middle fibers of the deltoid, supraspinatus, and long head of biceps.
- 3) **Posteriorly**: posterior fibers of the deltoid, infraspinatus, and teres minor.
- 4) **Inferiorly**: Long head of triceps, axillary nerve and posterior circumflex humeral vessels.

# Movements of shoulder joint

**Flexion:** This movement is done by the clavicular head of pectoralis major, anterior fibers of the deltoid and the coracobrachialis.

**Extension:** This movement is done by the posterior fibers of the deltoid and teres major.

**Adduction:** This movement is done by the pectoralis major, teres major and latissimus dorsi.

**Abduction:** This movement is done by the supraspinatus and deltoid.

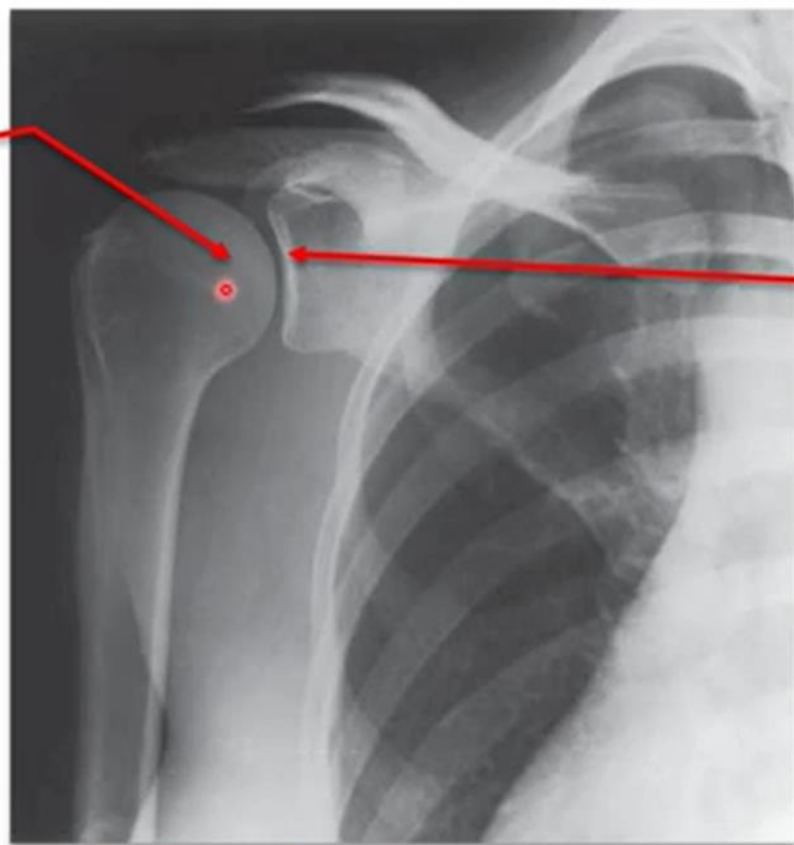
**Medial rotation:** This movement is done by the pectoralis major, teres major, latissimus dorsi, subscapularis and anterior fibers of the deltoid.

**Lateral rotation:** This movement is done by the infraspinatus, teres minor and posterior fibers of the deltoid.

**Circumduction;** a movement of abduction, extension, adduction and flexion in succession.

## Shoulder (Glenohumeral Joint)

Head of humerus



Glenoid cavity of scapula

**X ray of shoulder joint**

# AXILLARY NERVE

- It arises from the **posterior cord** of the brachial plexus.
- It passes backwards through **the quadrangular space** to turn around the **surgical neck** of the humerus.
- **root value** :c5,c6
- **Branches:**
  - a. Muscular branches:** to the deltoid and teres minor muscle.
  - b. Cutaneous branch:** Upper lateral cutaneous nerve of the arm which supplies the skin over the lower half of the deltoid.

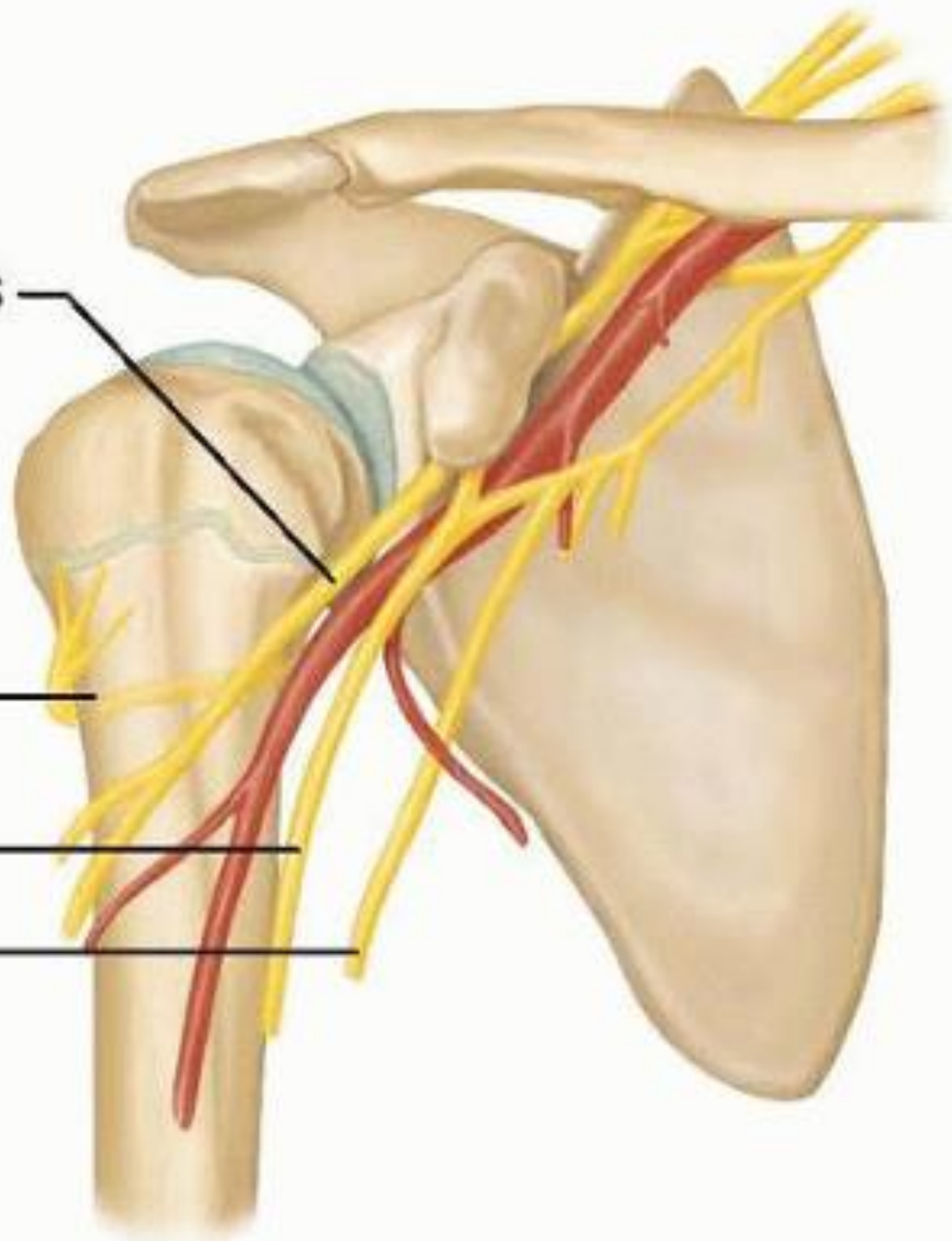


Musculocutaneous  
nerve

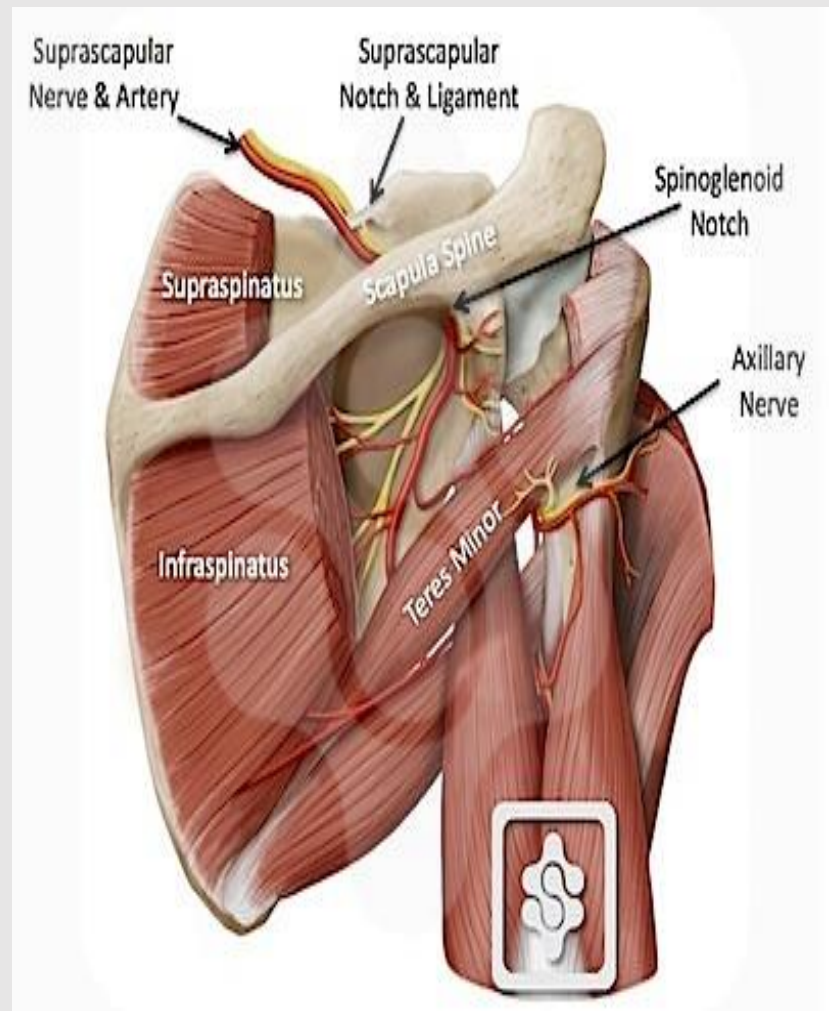
Axillary nerve

Median nerve

Ulnar nerve



- In case of **fracture surgical neck humerus**, the axillary nerve will be injured which will result in:
  - a. Weakness of abduction of the arm.
  - b. Wasting of the deltoid muscle (flat shoulder).
  - c. Loss of sensation over the lower half of deltoid.





*Thank You*