

# Paget disease and Osteomyelitis

**Dr. Omar Hamdan MD**  
**Gastrointestinal and liver pathologist**  
**Mutah University**  
**School of Medicine- Department of Laboratory**  
**medicine & Pathology**  
**MSS lectures 2023**



# Epidemiology

- The condition was initially described by Dr. James Paget in 1877, Also called as Osteitis Deformans.
- Partial or complete involvement of a single or multiple bones by exaggerated rates of resorptive and osteogenic activity leading to bony thickening and deformity.
- It has a predilection for the axial skeleton, But any bone may be affected.
- Paget disease is common in Europe and North America. It is rare in Asia and Africa.

## Paget disease

Is a common, chronic bone disorder characterized by excessive abnormal bone remodeling.

It affects individual over 40 with slight male predilection.

It is common in United Kingdom, Australia and New Zealand.

## Bones commonly affected by Paget's disease

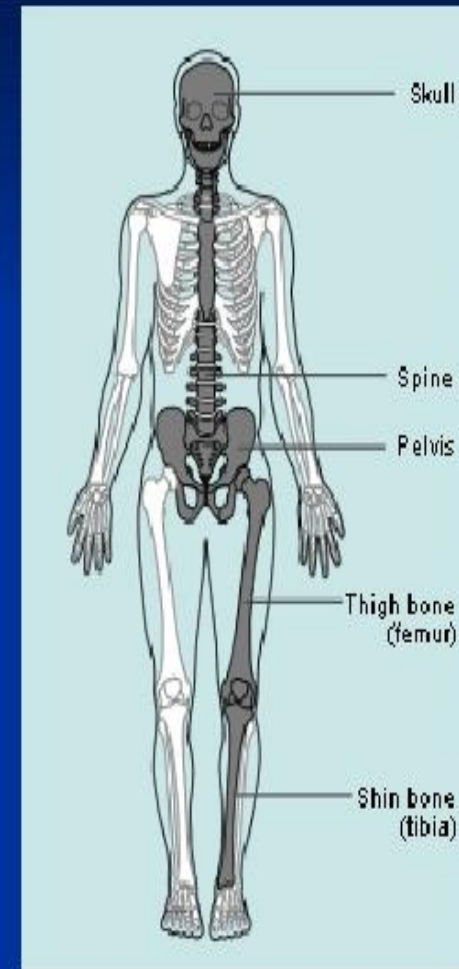
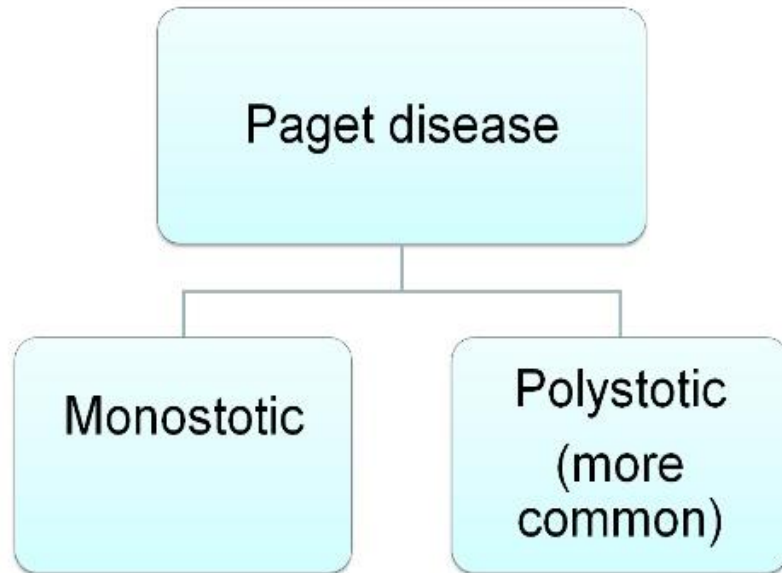


Figure 2. The bones commonly affected by Paget's disease

# ETIOLOGY

- UNKNOWN.
- Occasionally hereditary influence is noted on chromosome 18q.
- On electron microscopy of bone biopsies has demonstrated **nuclear inclusions** similar to those found in viral diseases (Paramyxo viridae family) are found in osteoclasts.

# PATHOPHYSIOLOGY



- Three phases:
  - i) Lytic.
  - ii) Mixed Lytic and Blastic.
  - iii) Sclerotic.
- At a given time, multiple stages of disease may be demonstrated in different skeletal regions of same patient.

# LYTIC PHASE

- Disease begins with lytic phase.
- The bone is resorbed by osteoclasts that are more numerous, larger and have more nuclei (up to 100).
- Bone turnover rate increased as much as 20 times normal.

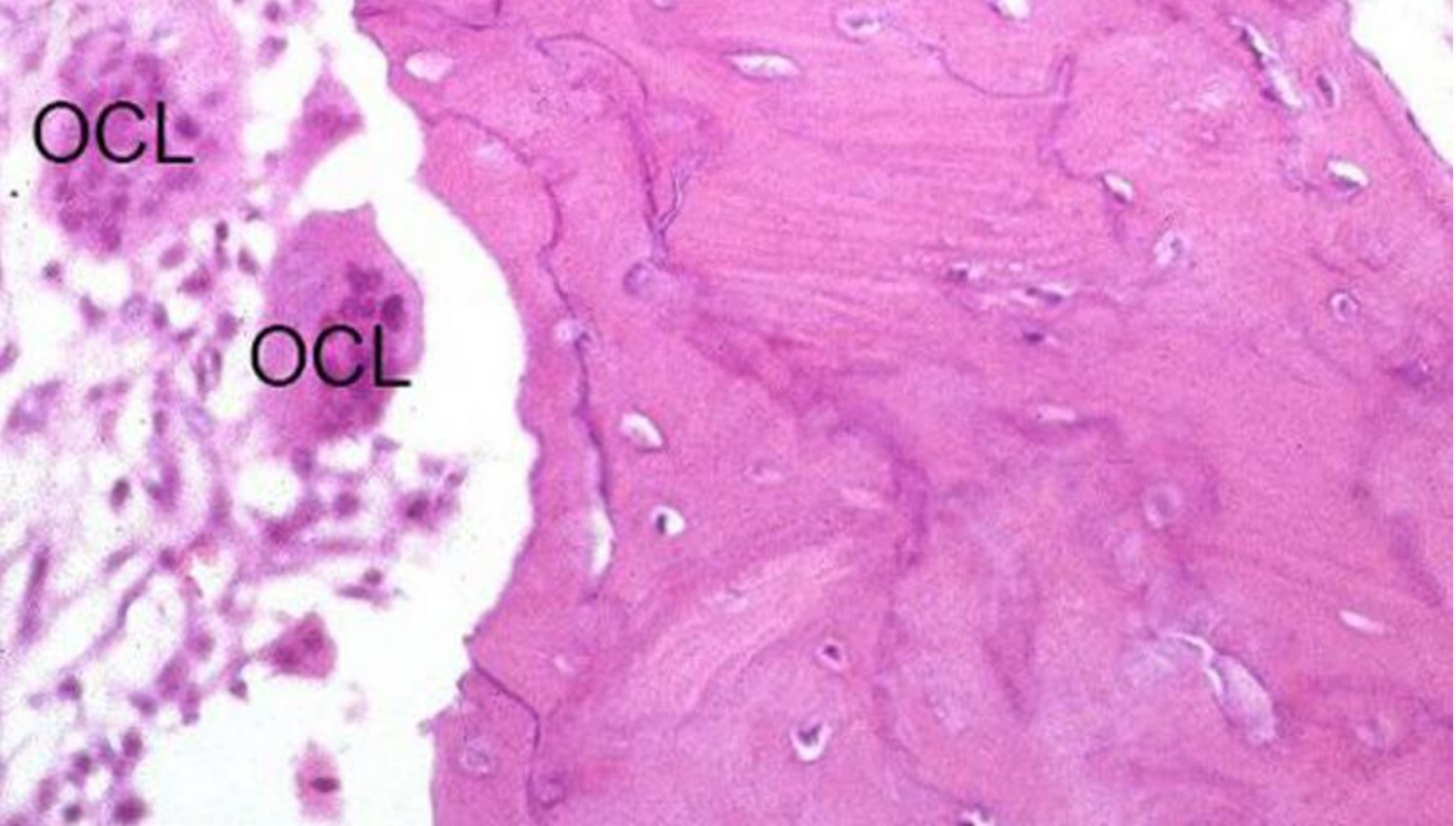
# Mixed Lytic and Blastic phase

- Rapid increase in bone formation from numerous osteoblasts.
- Morphologically osteoblasts are normal. The newly formed bone is abnormal with collagen fibers deposited in haphazard fashion rather than linear. As osteoclastic and osteoblastic activity repeats, high degree of bone turn over occurs.

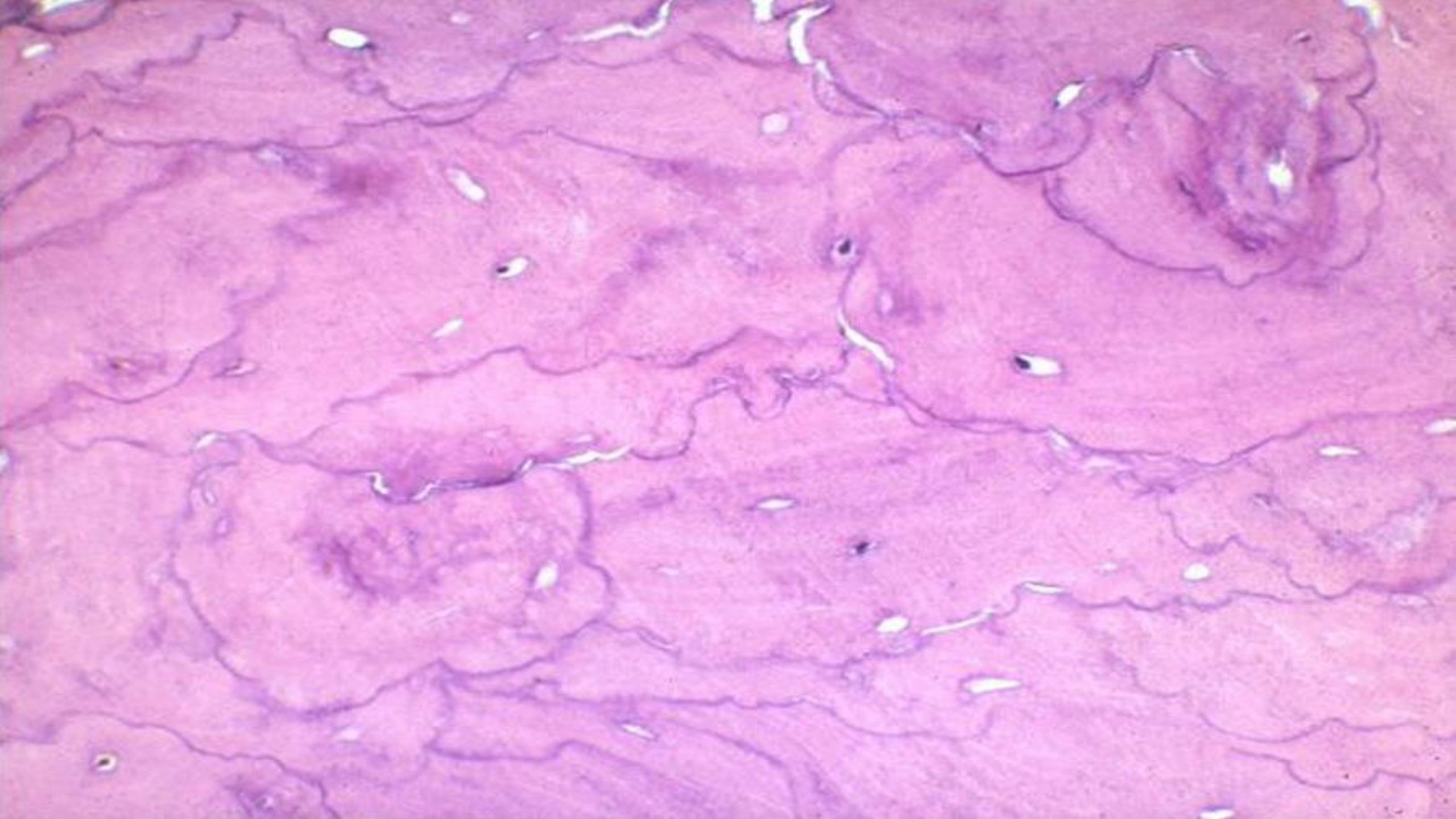
# Sclerotic Phase

- The bone formation dominates and has a disorganized woven pattern and is weaker than normal bone. Woven pattern allows the bone marrow to be infiltrated by blood vessels leading to hyper vascular bone state. Eventually osteoblastic activity also declines and enters a sclerotic or burned-out phase.

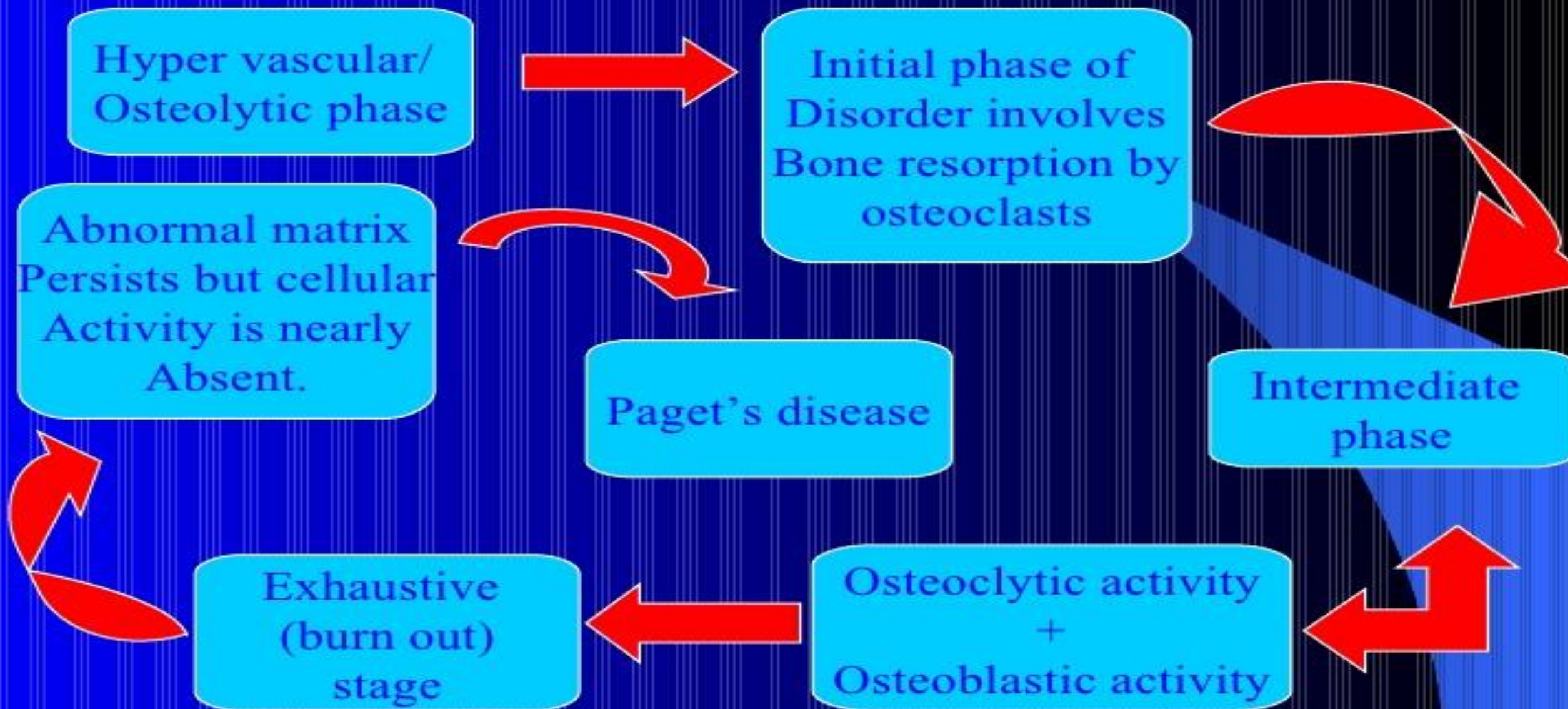








# Pathogenesis





# Clinical presentation

## Asymptomatic

## Non complicated cases

- **Skeletal manifestations:**
- Localized pain, tenderness and increased warmth (due to hyper-vascularity).

## Complicated cases

- **Skeletal manifestations:**
- Bone deformity or pathological fracture.
- **Neurological manifestations:**
- Cranial nerve palsies due to encroachment upon the neural foramina.
- **Cardiovascular manifestations:**
- High output heart failure.

# Complications

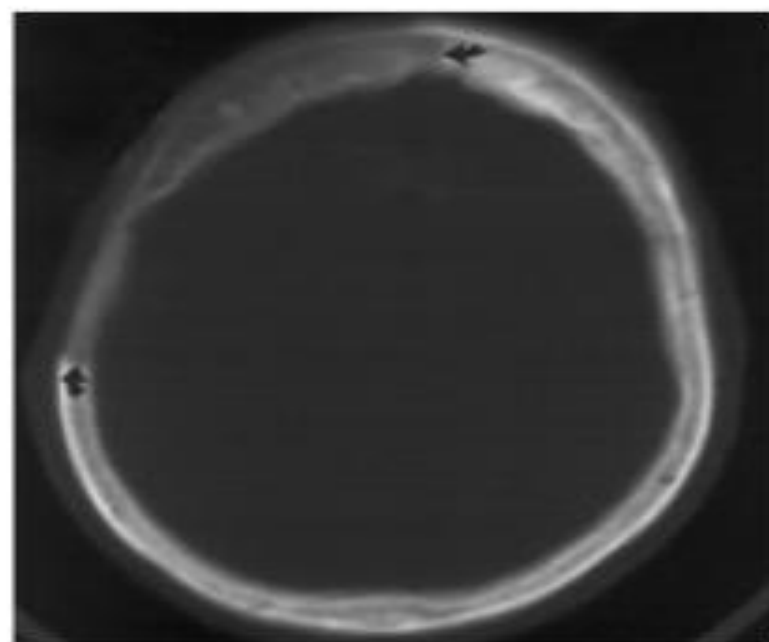
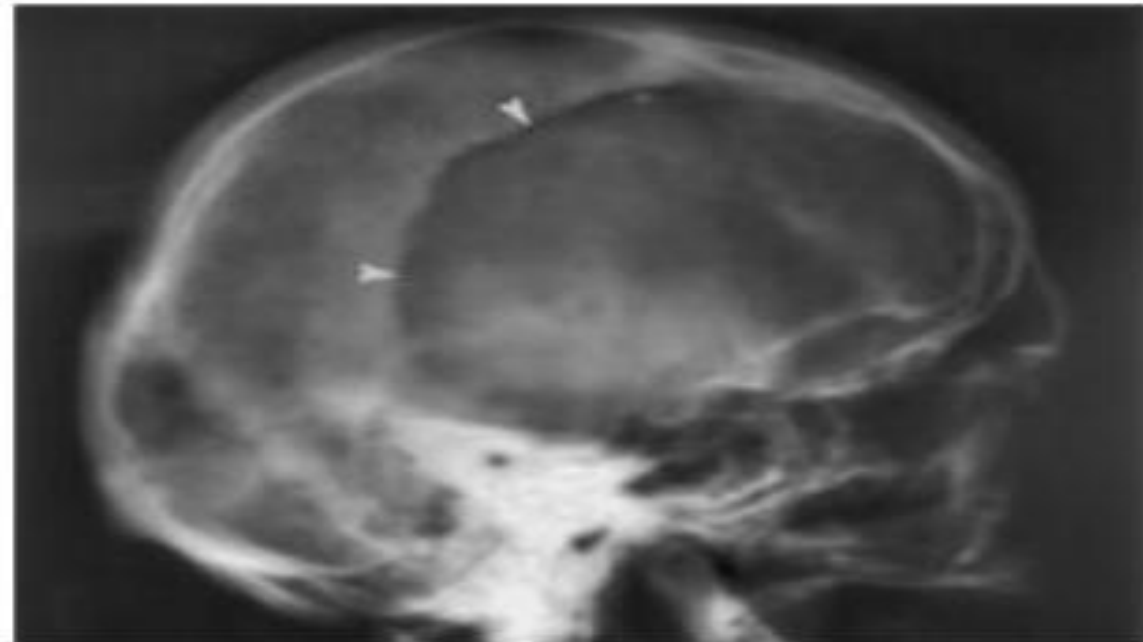
- Fractures and bony deformity.
- Secondary osteoarthritis (when pagets disease around a joint).
- Neurological complications – nerve root compression.
- Skull involvement- deafness and basilar invagination cranial nerve disorders.
- Sarcomatous degeneration – Osteosarcoma.
- Increased bone vascularity – high output cardiac failure.

# Investigations

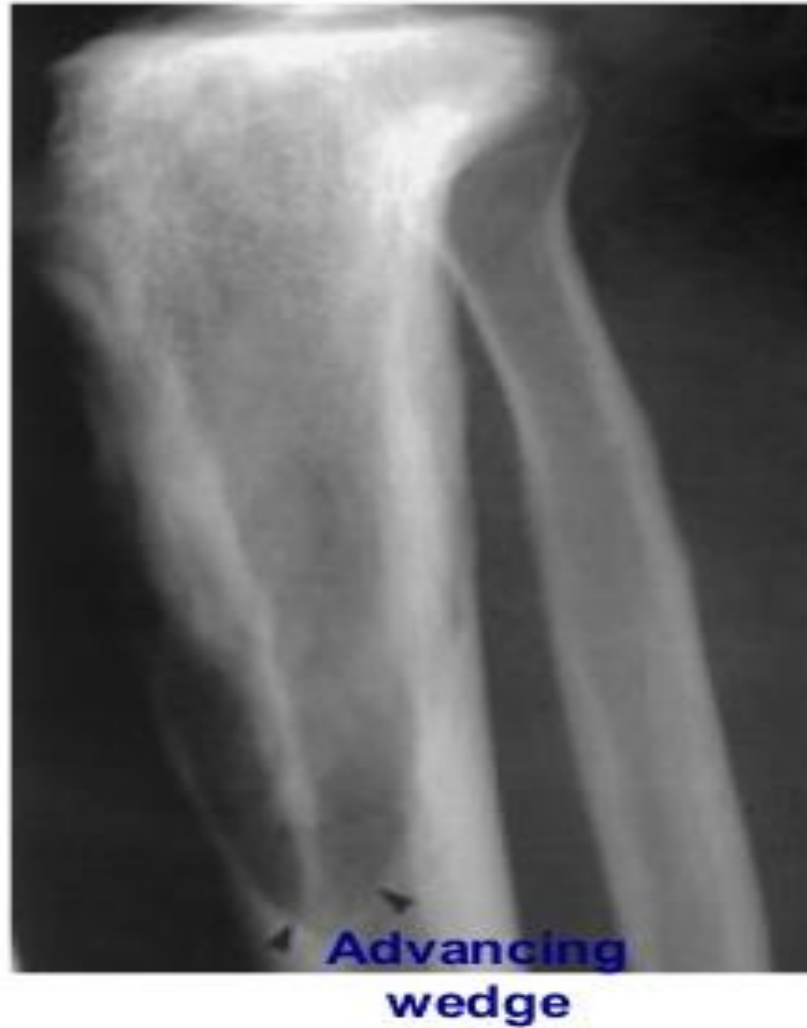- Serum Alkaline phosphatase will be increased.
- Serum calcium and phosphate levels will be normal.
- X-RAYS: Long bones (bowing thickening of cortex, narrowing of medulla or spongy, large dense bone looser's zone of transformation).

# Radiological manifestations

- ***Flat bones:***  
osteoporosis circumscripta.
- There is no surrounding sclerosis (as there is no osteoblastic activity in this phase)



- ***Long bone:***
- candle flame or blade of grass appearance.

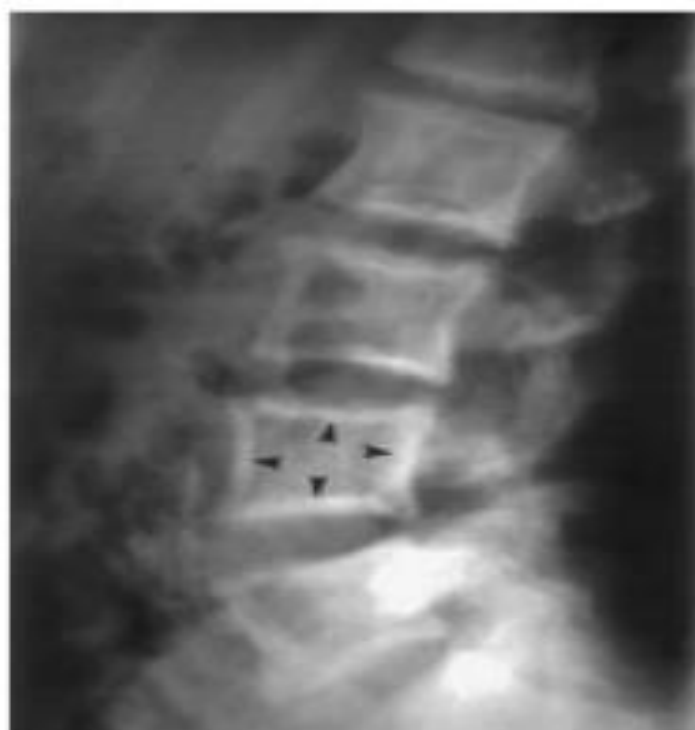



- **Vertebrae:**


**Picture frame appearance**

Cortical thickening.

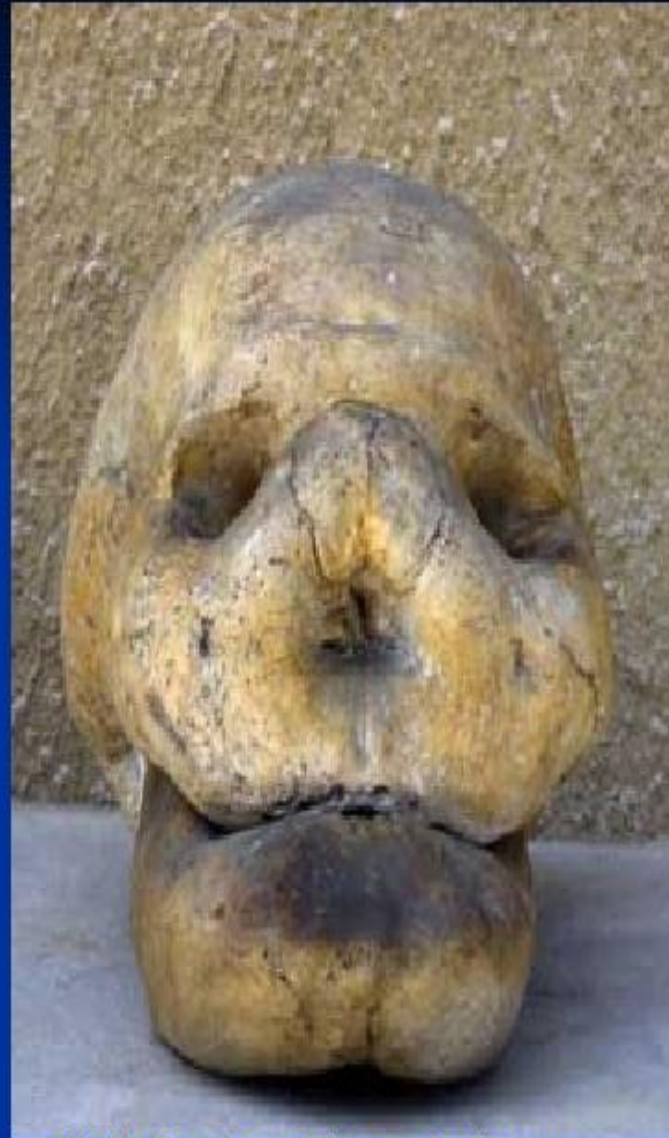
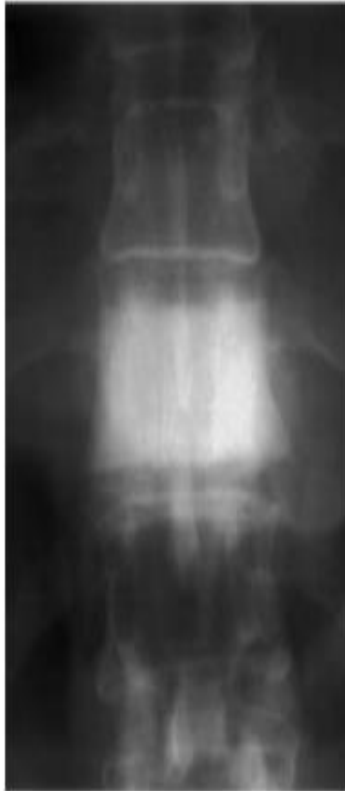
**Cystic spongiosa**

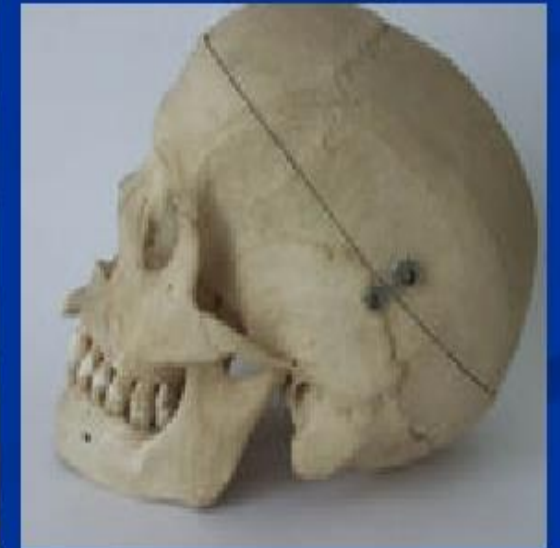Coarse trabecular pattern.



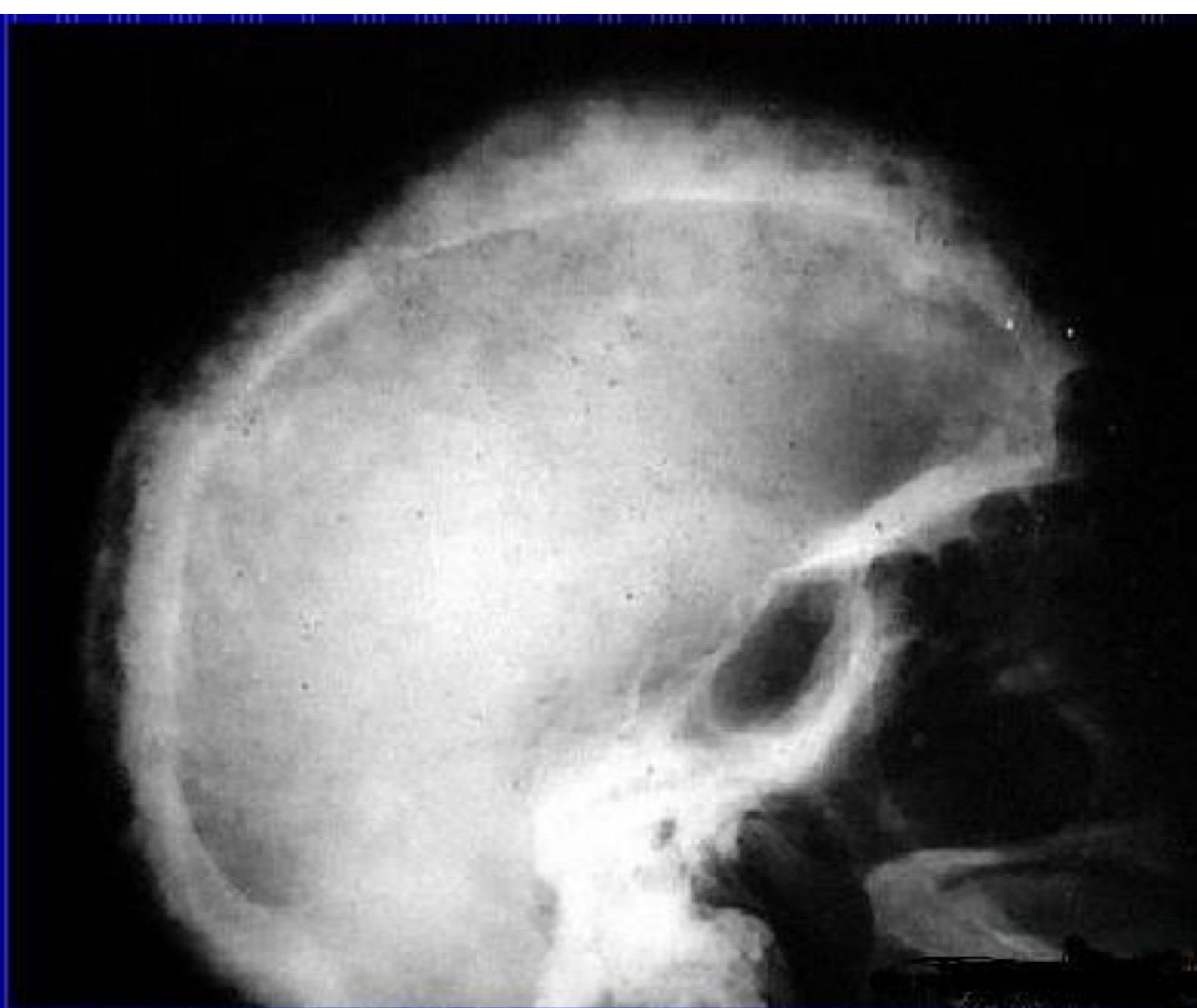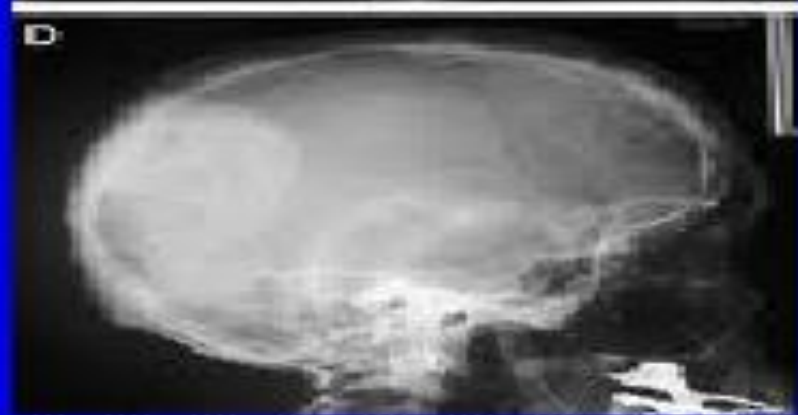
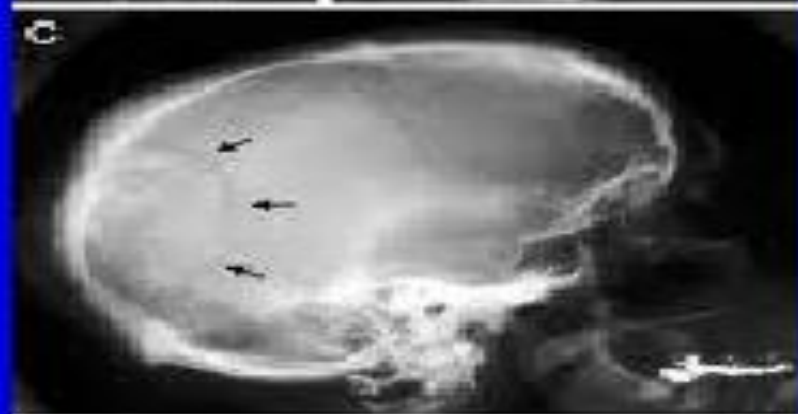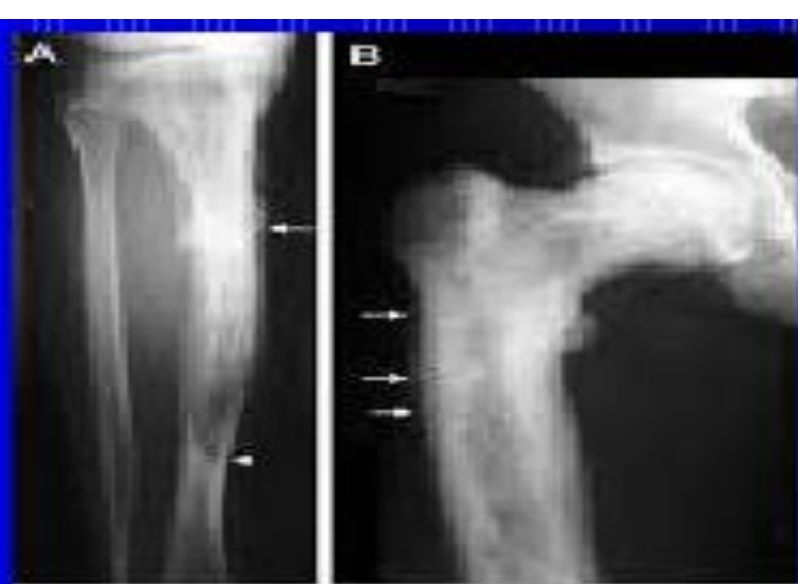
- Spine:
- Ivory vertebra



Skull of patient with paget's disease



normal skull



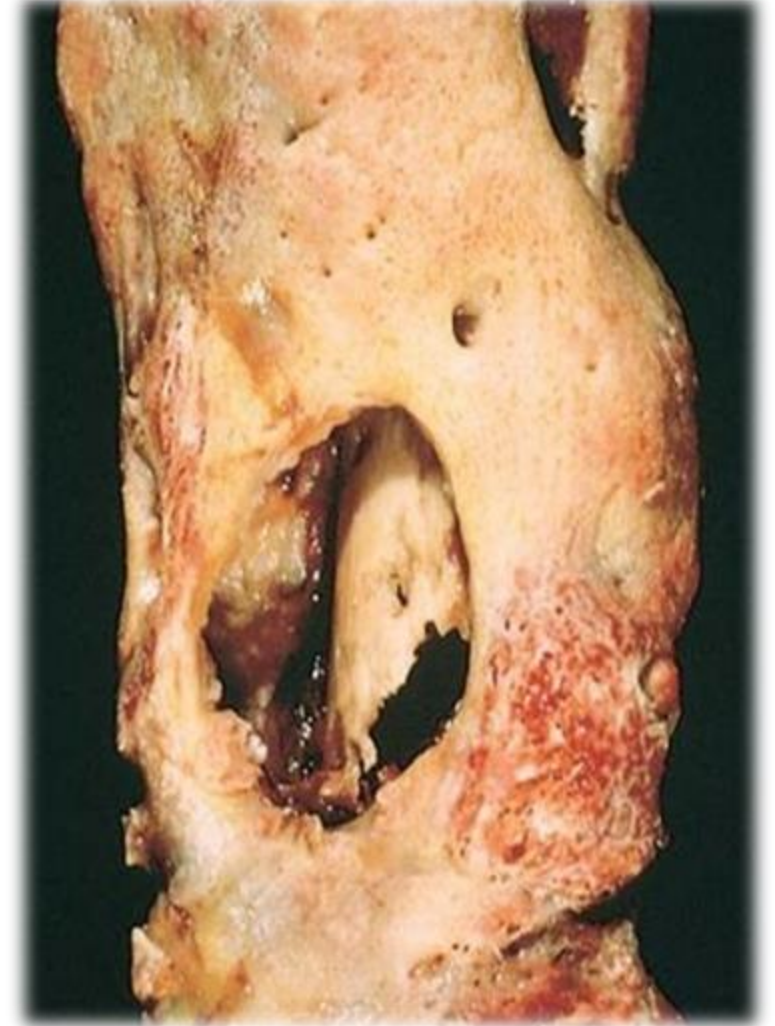# TREATMENT

- At this time there is no cure for Paget's disease, therefore treatment is designed to control the symptoms and prevent complications.
- Goals of treatment: Suppression of Active disease. Relief of Pain  
Prevention of Deformity and fractures. High output cardiac dysfunction. Reducing the Sarcomatous transformation



# Osteomyelitis-Definition

- **Definition:** “ A severe, persistent and incapacitating infection of bone and bone marrow”.
- Osteomyelitis (osteo- derived from the Greek word osteon, meaning bone, myelo- meaning marrow, and -itis meaning inflammation) simply means an infection of the bone or bone marrow.
- Infection mainly involves - Marrow spaces - Haversian canals –Sub-periosteal Spaces



Nelaton (1834) : coined osteomyelitis



# Classification and types

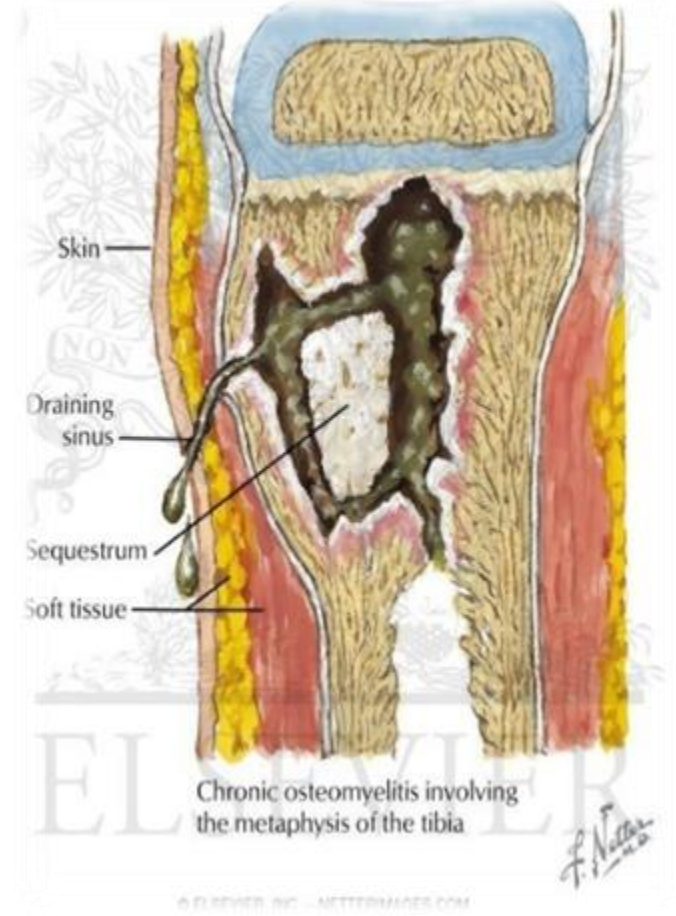
<b>Acute osteomyelitis:</b> 1 in 5000 children.	<b>Childhood osteomyelitis:</b> long bones of the legs and upper arms.	<b>Pyogenic osteomyelitis</b>
<b>Chronic osteomyelitis:</b> 2 in 10,000 adults.	<b>Adults osteomyelitis:</b> bones of the vertebrae.	<b>Tuberculous osteomyelitis</b>

- **Types of osteomyelitis:**

1. Post traumatic osteomyelitis: (47% cases)
2. Osteomyelitis due to vascular insufficiency: (34% cases)
3. Osteomyelitis due to hematogenous spread: (19%)
4. Osteomyelitis post infection of prosthetic joints

# Pathogenesis

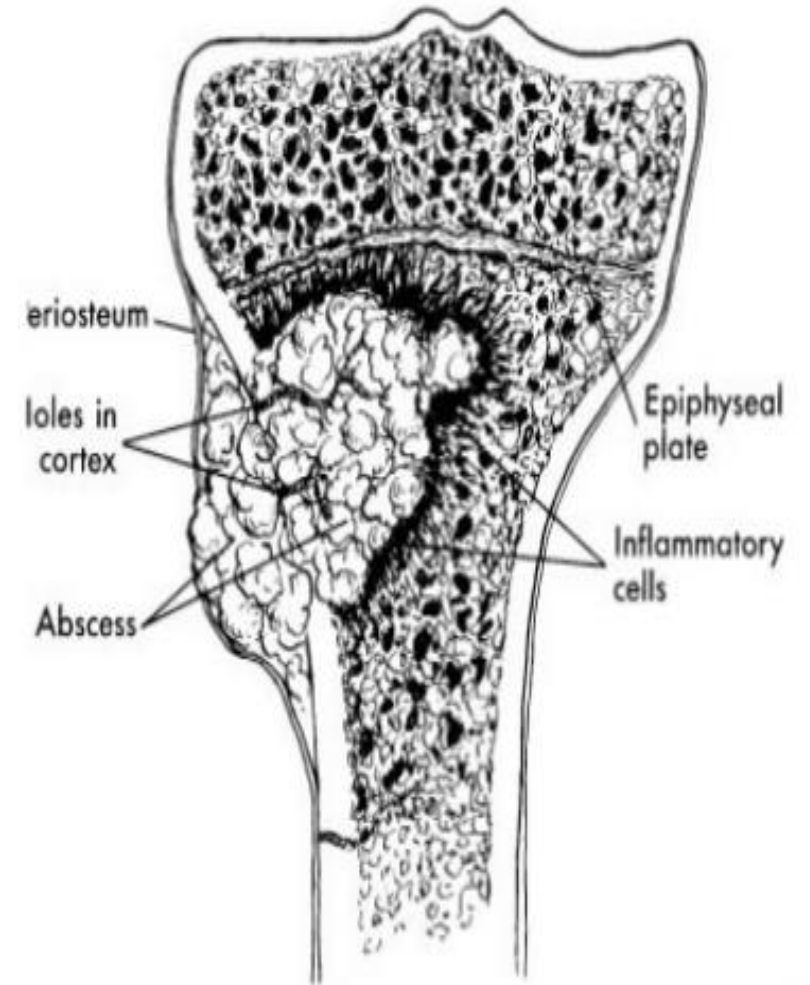
1. Bone is normally resistant to bacterial colonization
2. Bacteria form a biofilm in the metaphysis (**primary focus**)
3. Biofilms protect bacteria from host immune response
4. **Abscess** in metaphysis
5. **Sub periosteal abscess**
6. **Sequestrum** formation (bone death)
7. **Involucrum** formation (New brittle bone formation)
8. Pus perforates periosteum and forms **abscess in soft tissues**
9. Abscess bursts on surface and forms **discharging sinus**





# Pathogenesis

10. **Necrosis:** stage of new bone formation → Involucrum → with sequestrum inside, there will always be a persistent discharging sinus. → pus from bone escapes through multiple hole in Involucrum (Cloacae)
11. Pus spreads into vascular channels → Raising intraosseous pressure → Impairing blood flow → Chronic ischemic necrosis → Separation of large devascularized fragment → New bone formation → (Involucrum)



# Factors affecting pathogenesis

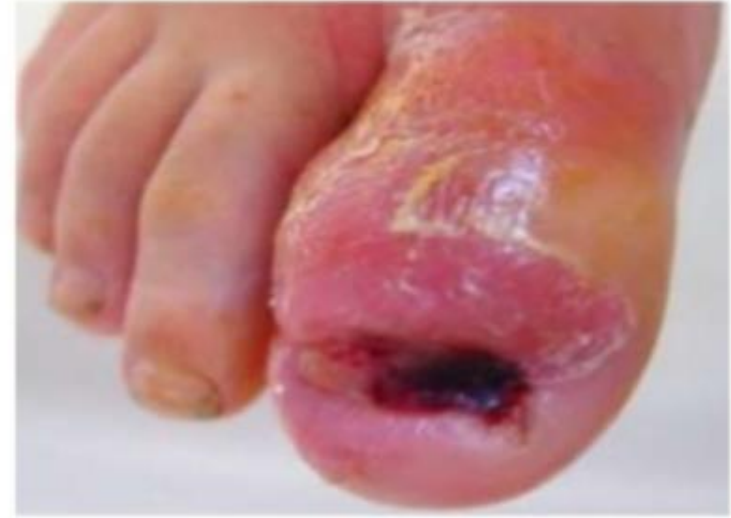1. Virulence of the infecting organism e.g. ( Biofilm: A coherent cluster of bacterial cells imbedded in a matrix—which are more resistant to most antimicrobials and the host defense than planktonic bacterial cells forming bacteria)
2. Underlying disease.
3. Immune status of the host.
4. Type, location and vascularity of the bone.
5. **Factors that compromise bone integrity:** • Trauma • Surgery • Presence of foreign bodies • Placement of prostheses Leads to the onset of bone infection

# Chronic osteomyelitis

- The hallmark of chronic osteomyelitis is infected dead bone within a compromised soft-tissue envelope.
- The infected foci within the bone are surrounded by sclerotic, relatively avascular bone covered by a thickened periosteum and scarred muscle and subcutaneous tissue.
- This avascular envelope of scar tissue leaves systemic antibiotics essentially ineffective.

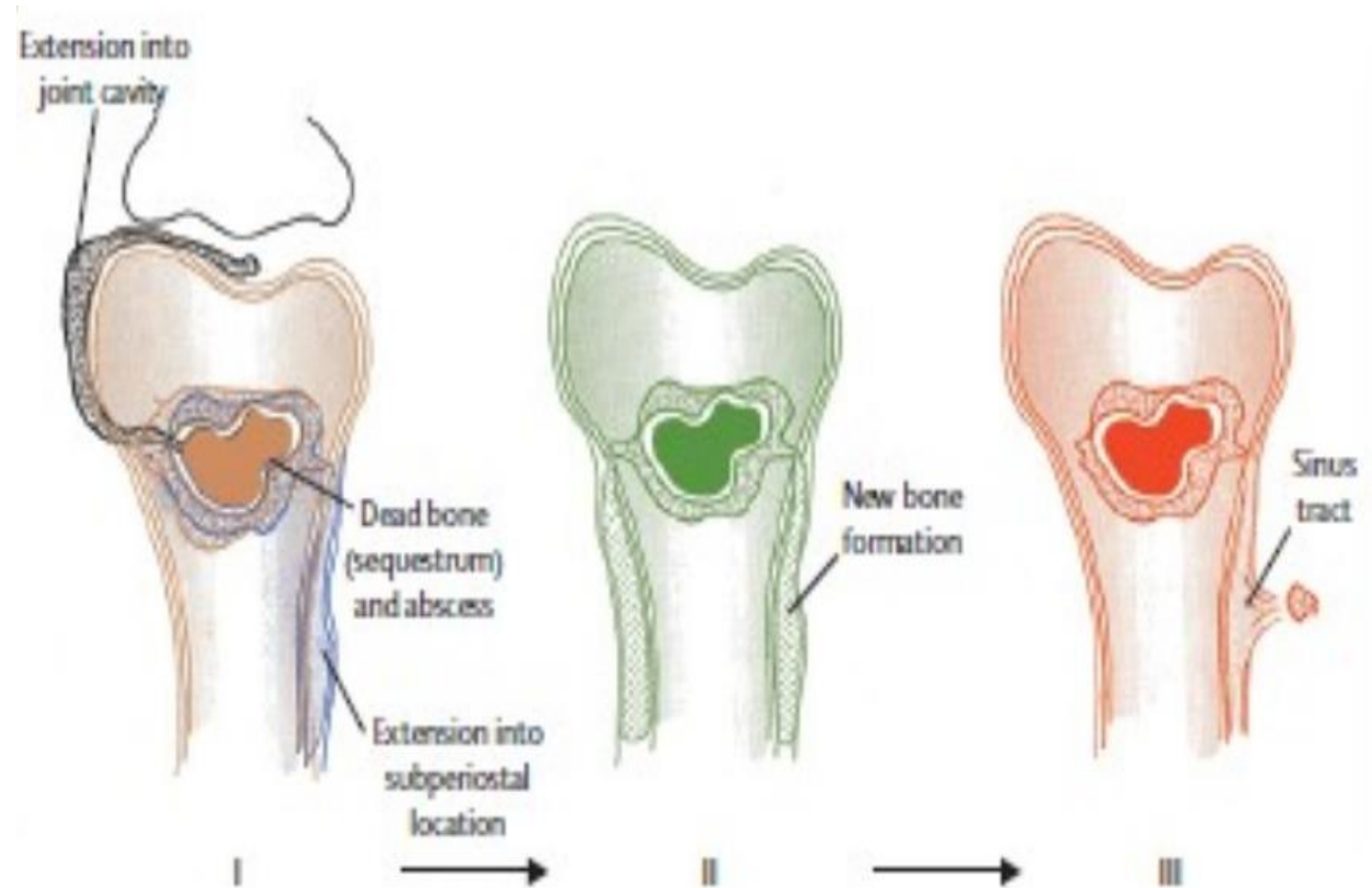
## **Factors leading to chronic osteomyelitis**

- Trauma
- Diabetes
- Prosthetic orthopaedic device
- Peripheral vascular disease
- Chronic joint pain
- i/v drug abuse
- Immunosuppression
- Alcoholism

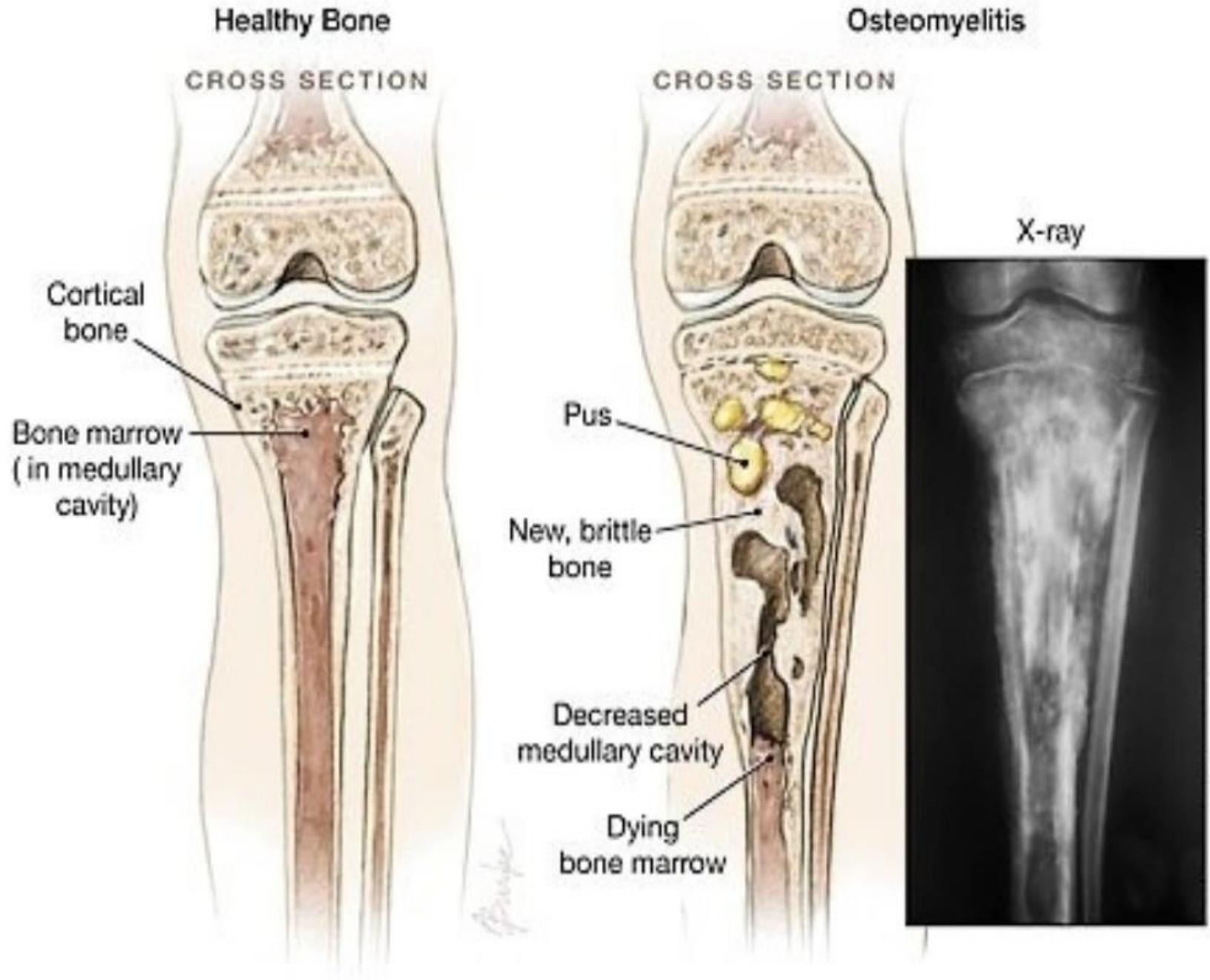


# Steps in progression of chronic osteomyelitis

1. The peculiarity of an abscess in bone is that it is contained within a firm structure with **little chance of tissue expansion.**
2. As infection progresses, purulent material works its way through the harversian system and Volkmann canals and **lifts the periosteum off the surface of bone.**

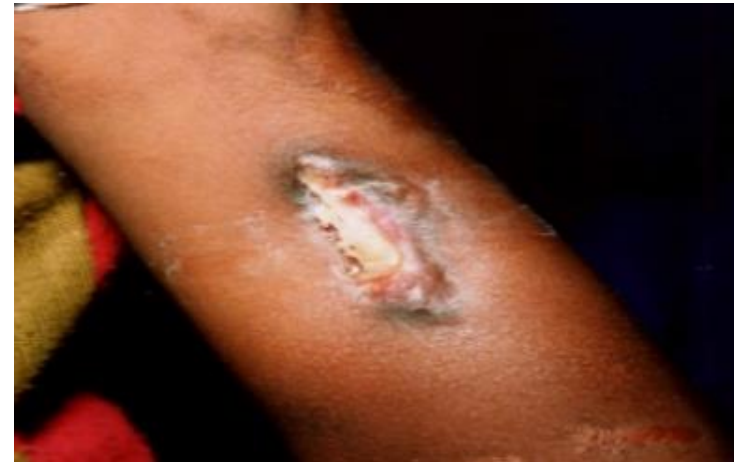
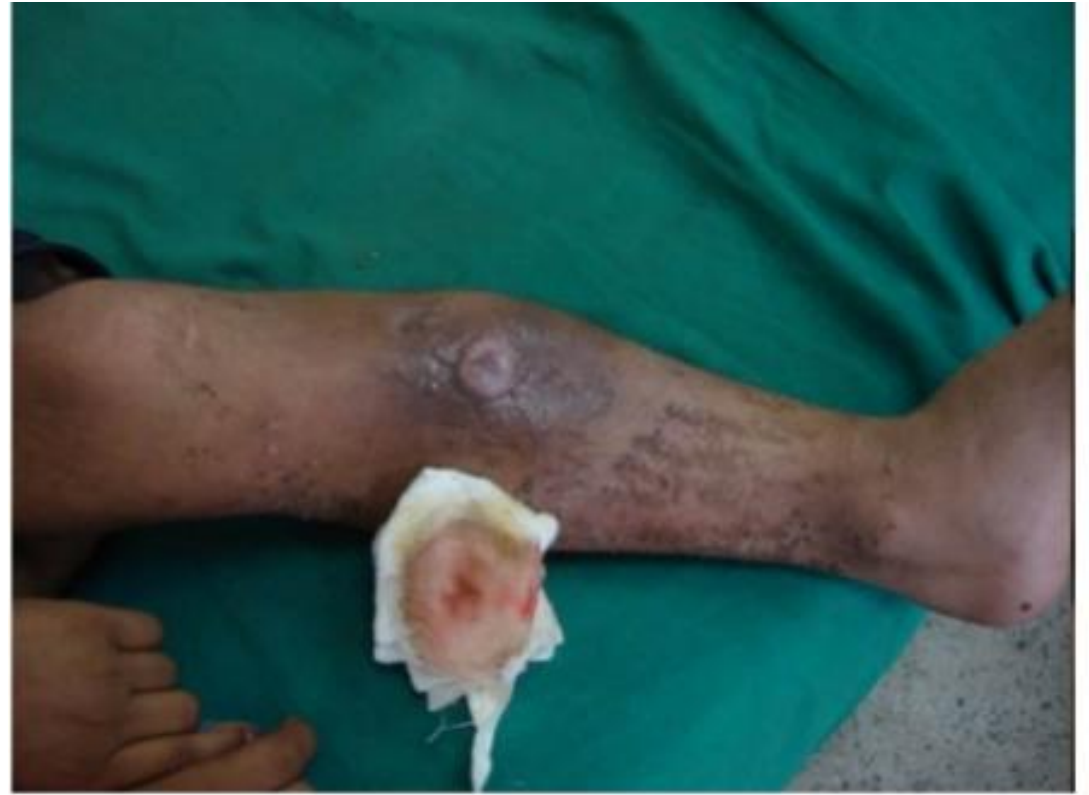
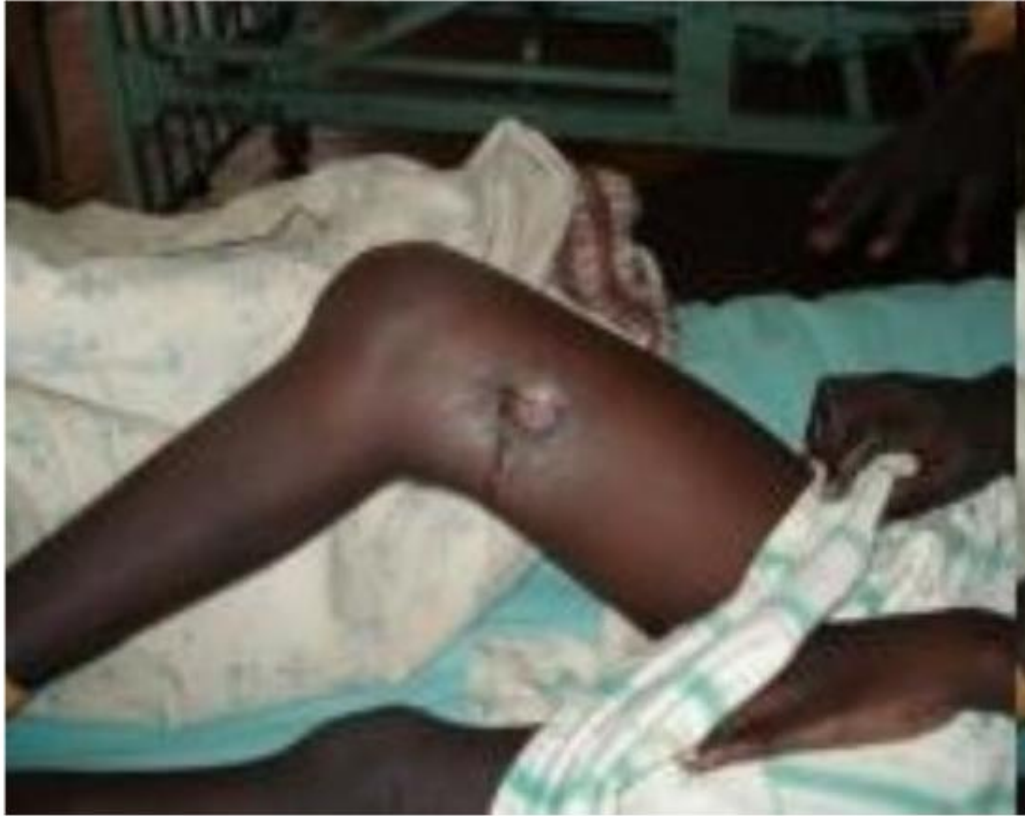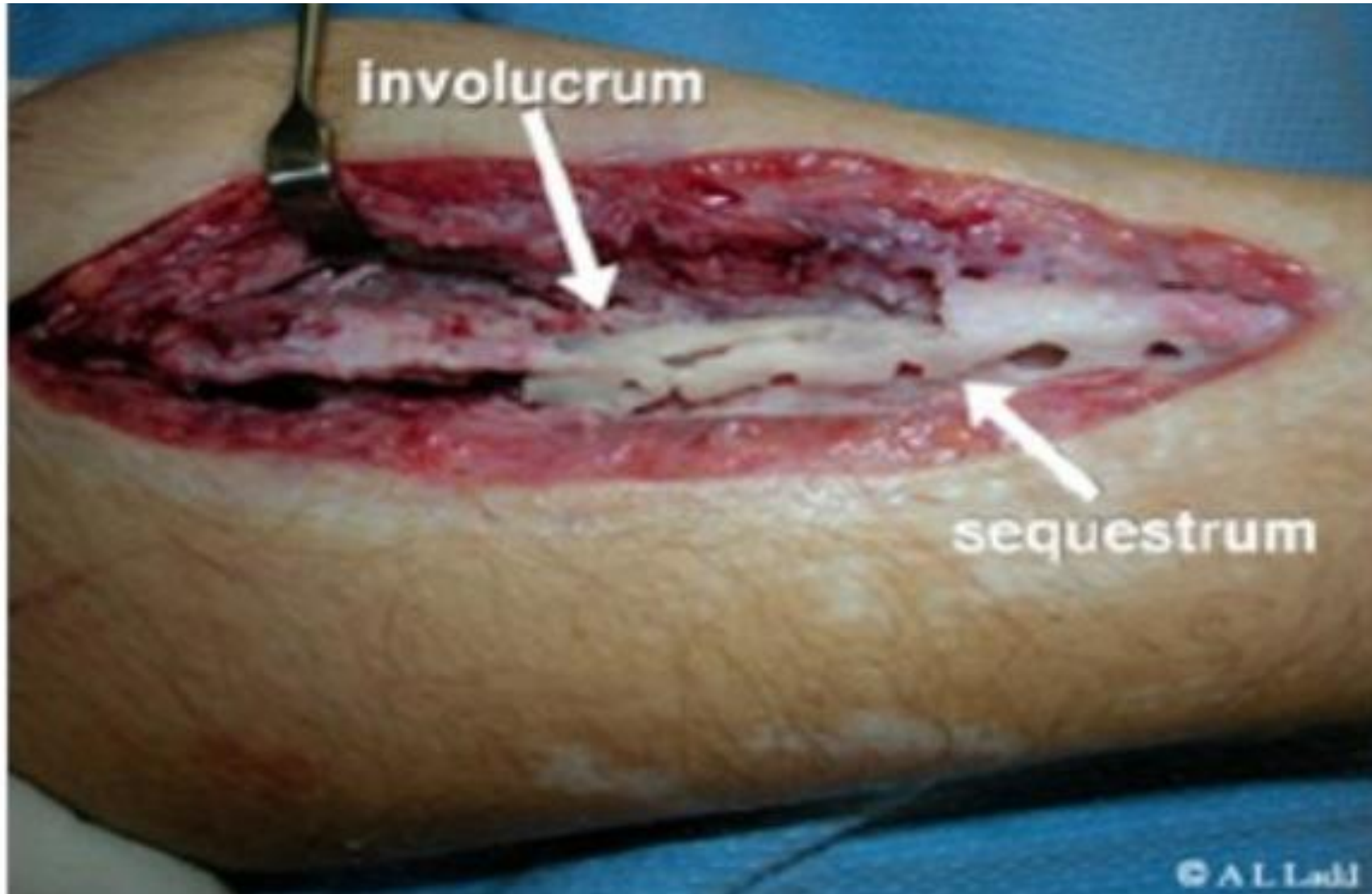
3. The combination of pus in the medullary cavity and in the sub periosteal space causes **necrosis of cortical bone**.
4. This necrotic cortical bone, known as a **sequestrum**, can continue to harbor bacteria despite antibiotic treatment.
5. Antibiotics and inflammatory cells cannot adequately access this avascular area, resulting in **failure of medical treatment of osteomyelitis**





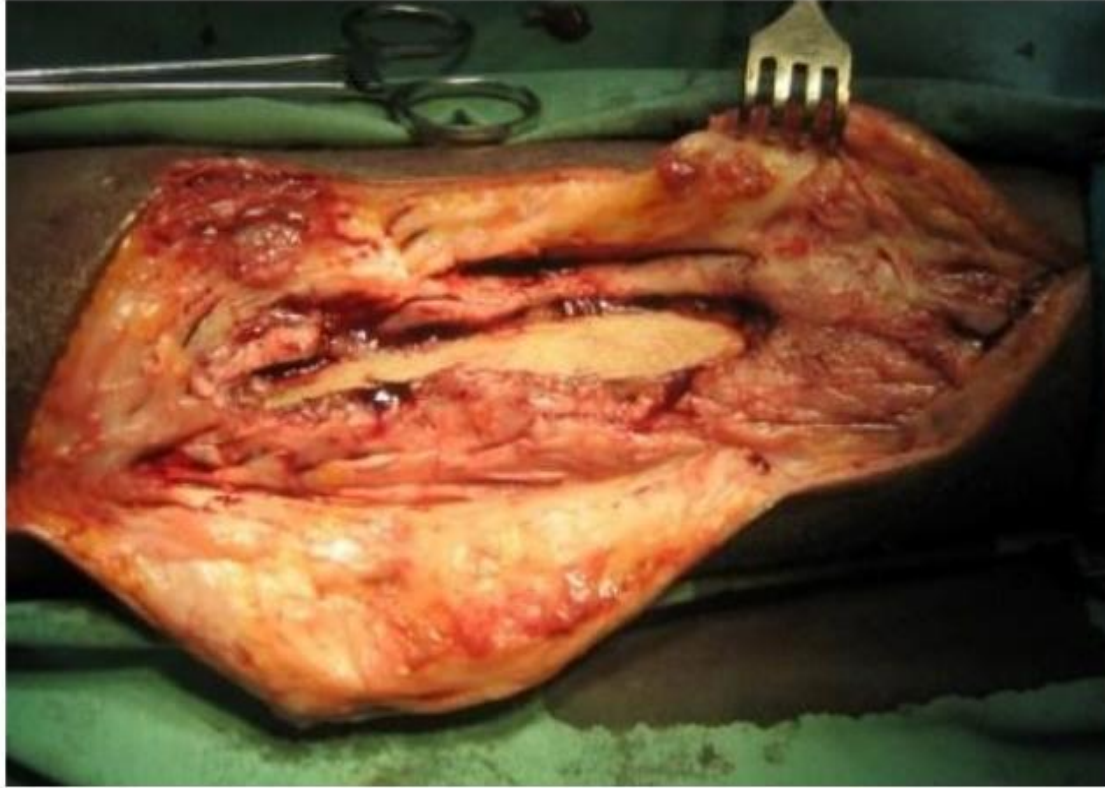
# Discharging sinus



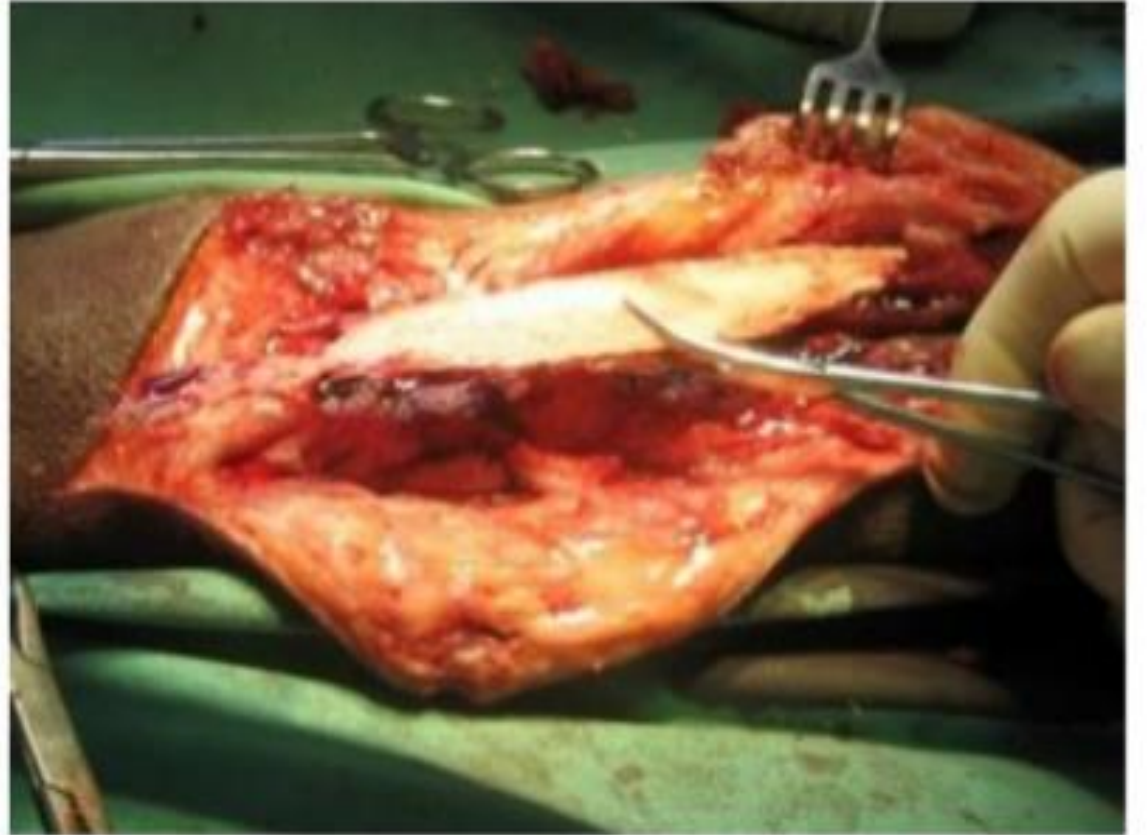




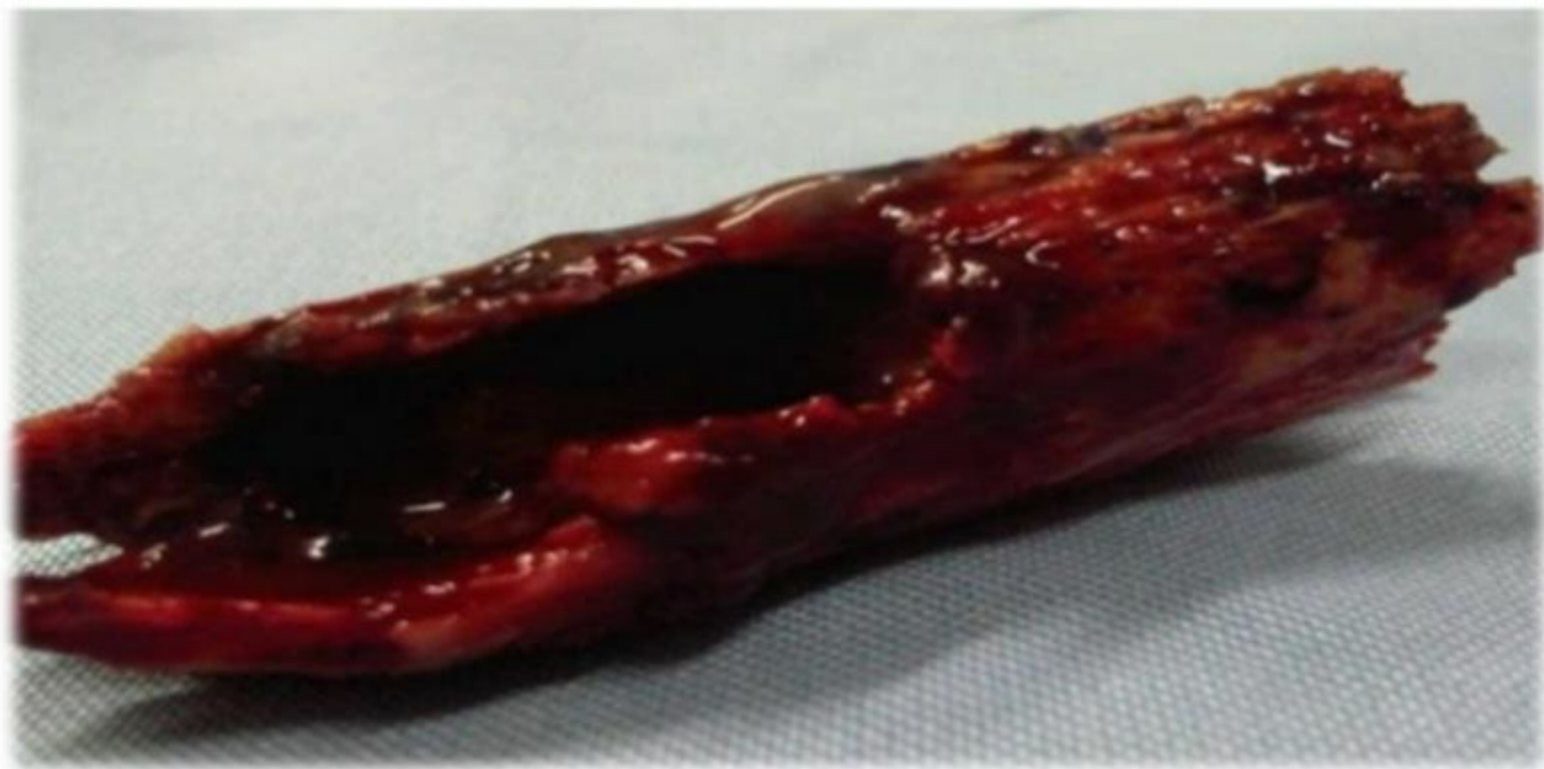
Sequestrum Exposed



Sequestrum Removed

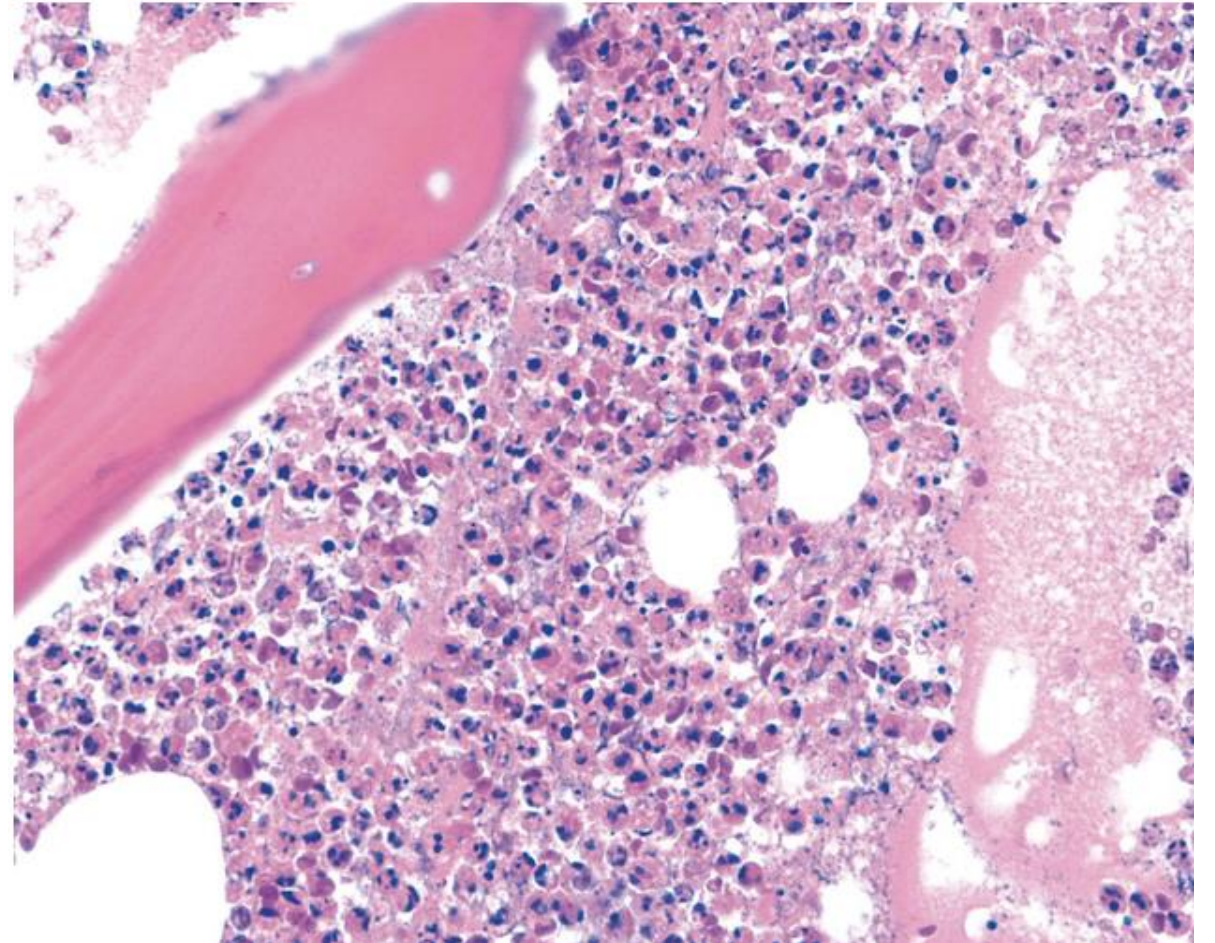
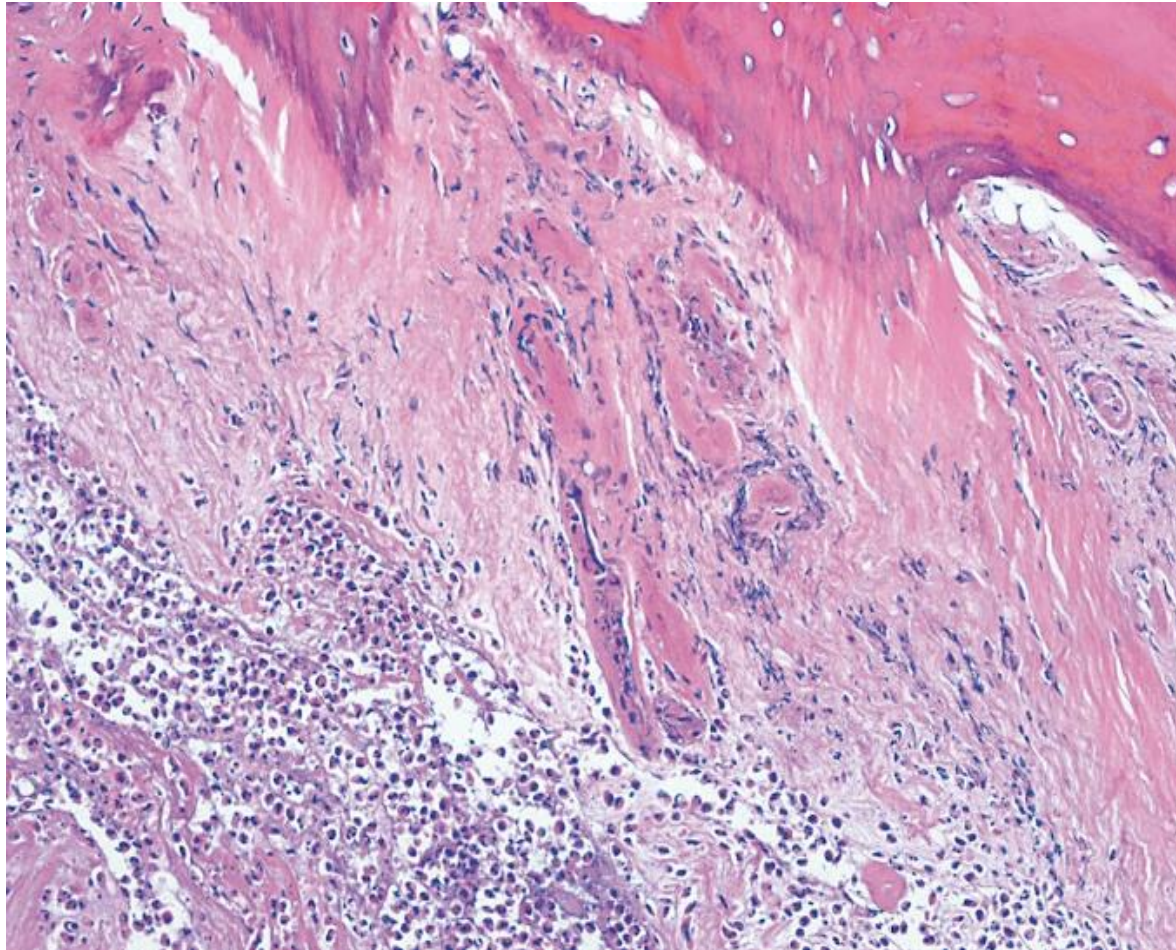


# Sequestrum



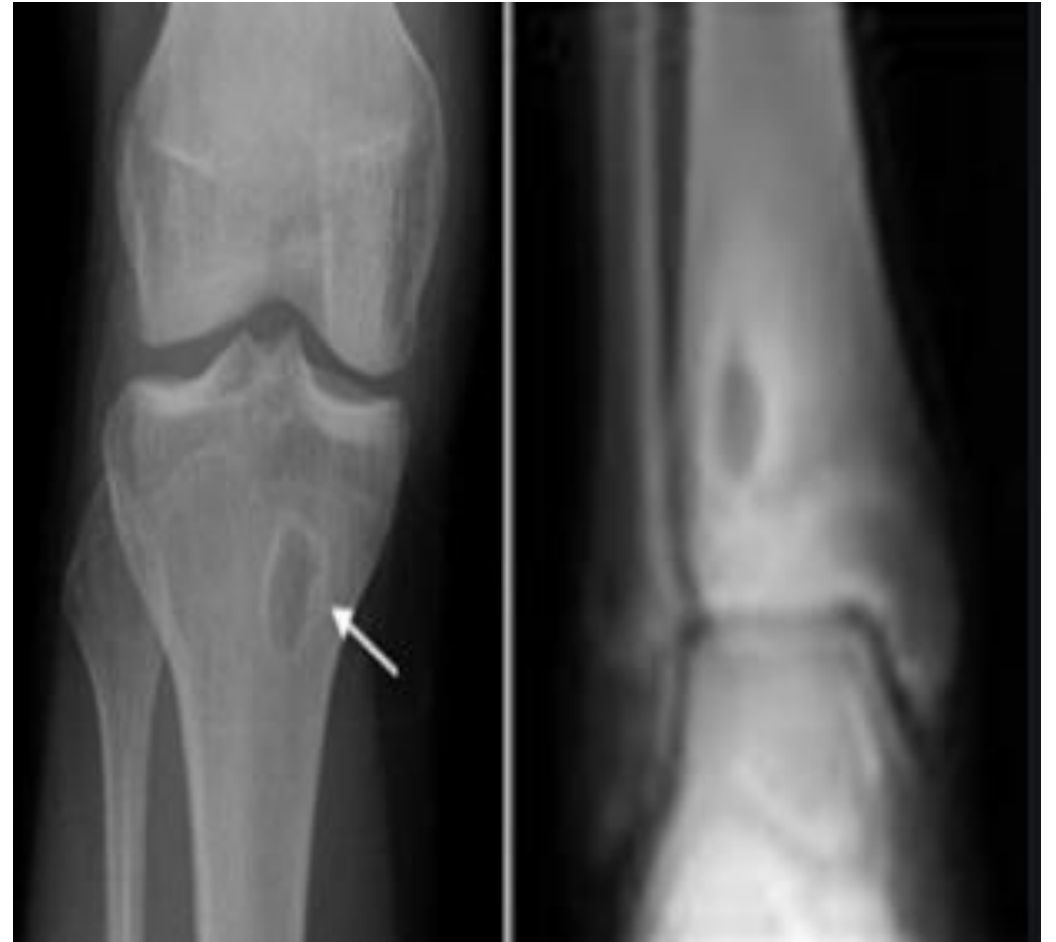

# Microscopic (histologic) description



A small, walled-off intra-cortical abscess is called a Brodie abscess.

**Typical appearance of Brodie abscess is:**  
Lucency within the distal metaphysis with reactive surrounding sclerosis.



# Hematogenous osteomyelitis

**1. Primary hematogenous osteomyelitis:** Most common in infants and children

- Site: long bone metaphysis

(The relative absence of phagocytic cells in the metaphases of bones in children may explain why acute hematogenous osteomyelitis is more common in this location)

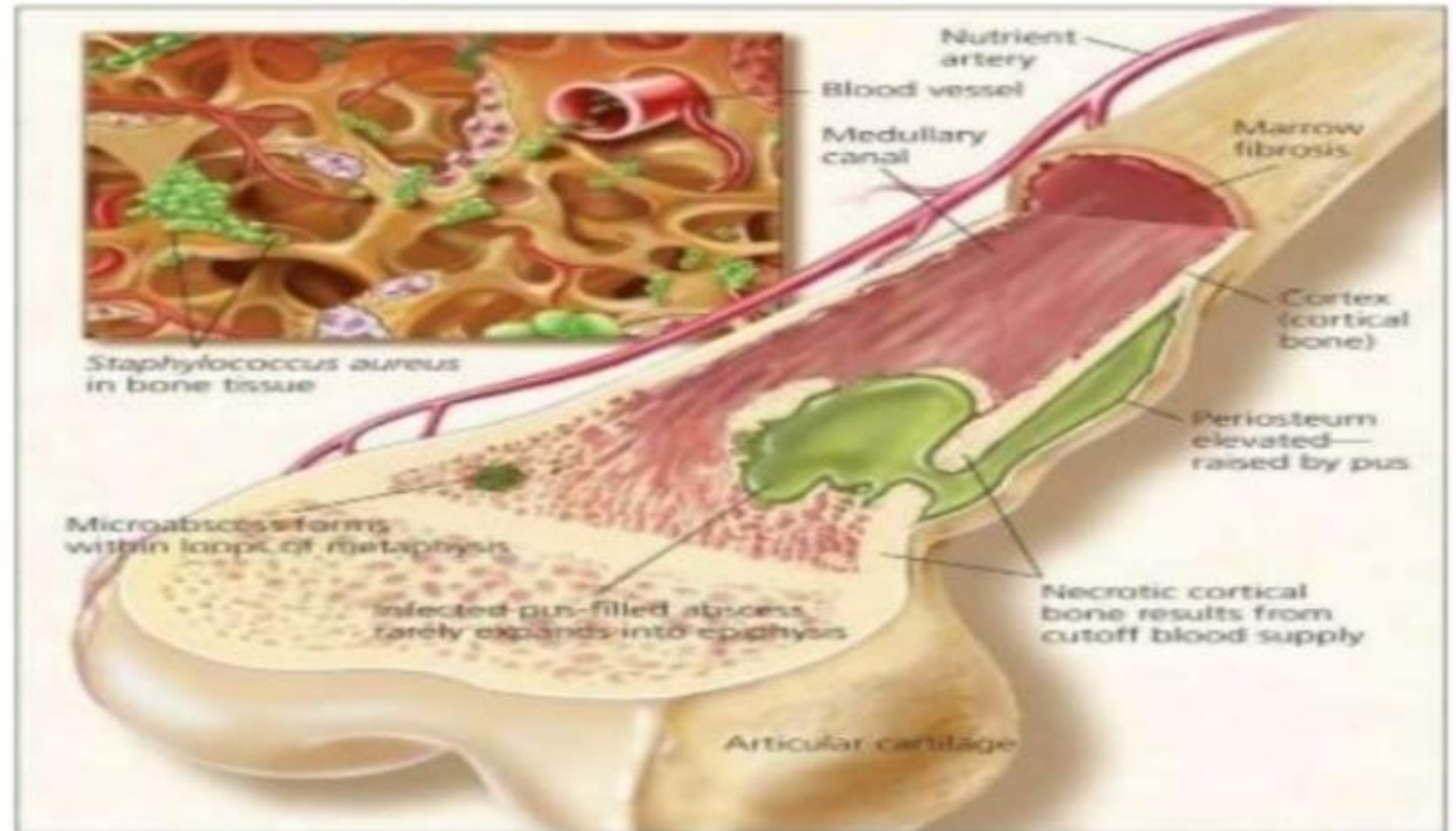
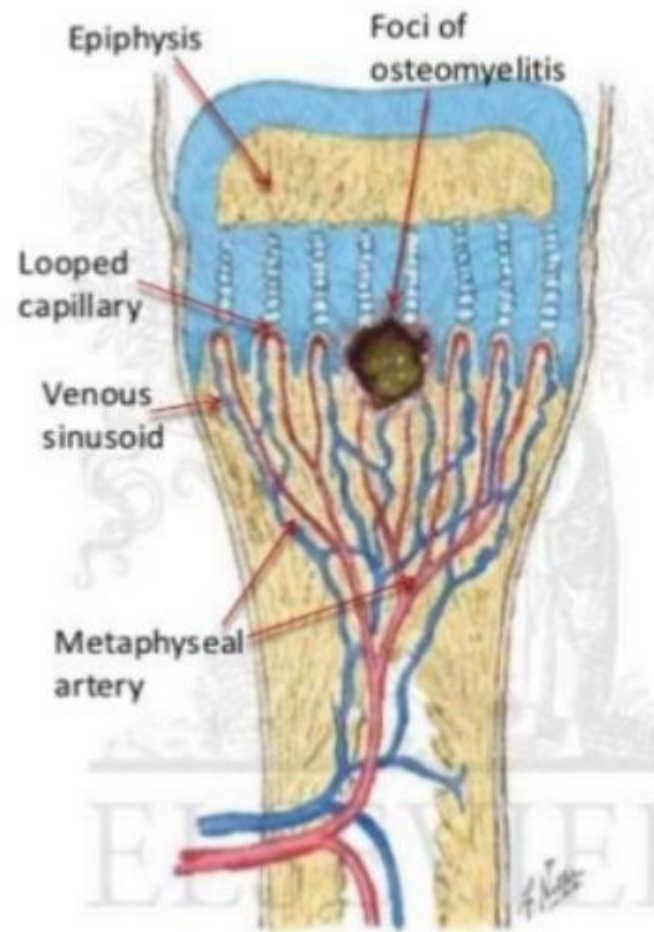
- Sinus tracts may form if infection extends into soft tissue.

**2. Secondary hematogenous osteomyelitis:**

- Occurs when childhood infection is reactivated.
- Occur in Adults.
- Vertebrae (most common), followed by long bones, pelvis, clavicle
- Infections recur and present with minimal constitutional symptoms and pain.



# Haematogenous osteomyelitis of tubular bone in child



Blood flow is slow and turbulent and predisposes to bacterial seeding. Lining cells have little or no phagocytic activity

# Etiology

## Most common:

- *Staphylococcus aureus*
- *Pseudomonas aeruginosa*
- Enterobacteriaceae

## Less common organisms:

- anaerobe gram-negative bacilli.

• Infants



*Streptococcus agalactiae*  
(Group B Streptococci)  
*Staphylococcus aureus*  
*Escherichia coli*

• Children



*Staphylococcus aureus*  
*Streptococcus pyogenes*  
(Group A Streptococci)  
*Streptococcus pneumoniae*  
*Haemophilus influenzae*  
CA-MRSA

• Adults



*Staphylococcus aureus*  
*Staphylococcus epidermidis*  
*Pseudomonas aeruginosa*  
*Escherichia coli*

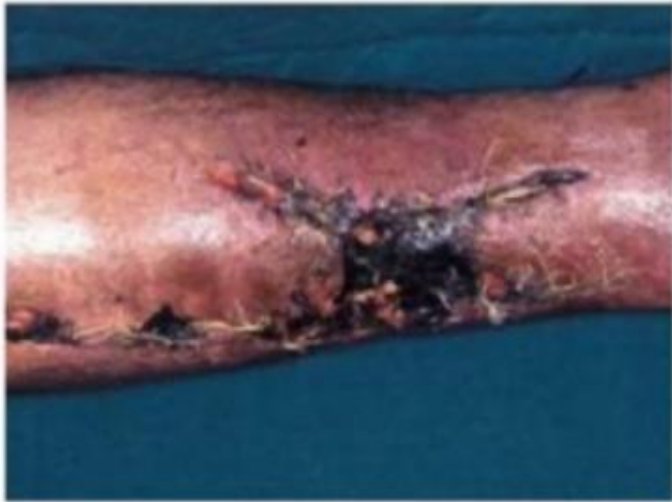# Etiology associated with certain risk factors

- Penetrating wound, open fracture: *Staphylococcus aureus*
- In dwelling prosthetic device: *Staphylococcus epidermidis*
- Intravenous drug users: *Pseudomonas* infections.
- Gastrointestinal or genitourinary infections: *Escherichia coli* & others
- Tooth abscess, gingival disease, dental extraction: *Streptococcus viridans*
- Mycobacterium tuberculosis: **Bone tuberculosis**
- Sickle cell disease: *Salmonella* species in the West  
*Staphylococcus aureus* in Middle East & Africa



# Contagious focus and post traumatic osteomyelitis : Adults

In adults, osteomyelitis is usually a sub acute or chronic infection that develops secondary to an open injury to bone and surrounding soft tissue.



## Common etiology

*Staphylococcus aureus*

*Staphylococcus epidermidis*

Gram negative bacilli

Anaerobes

*Nocardia*- rare

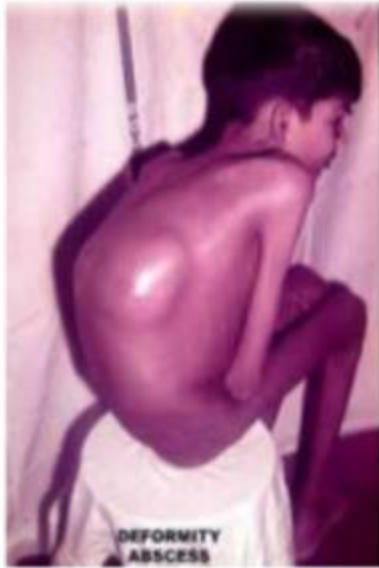# Osteomyelitis in Diabetes mellitus

- Cause: minor trauma to the feet
- Foot ulcers allow bacteria to reach the bone
- Poor glycaemic control.

Patients may not experience any pain because of peripheral neuropathy

Presentation: perforating foot ulcer, cellulitis or an in-grown toenail.

- **Etiology:** multiple organisms
- *Streptococcus* species,
- *Enterococcus* species,
- *Staphylococcus aureus*
- *Staphylococcus epidermidis*
- Gram-negative bacilli,
- Anaerobic organisms (*Bacteroides*)



### Skeletal Tuberculosis (Pott's Disease)

- Painful bones
- The infected bone will begin to weaken and become curved
- Absence of feeling and movement in the diseased bone
- Due to the bone being weakened, it has a high risk of being fractured

<b>Tubercular osteomyelitis</b>	<b>Pyogenic osteomyelitis</b>
<b>Longstanding history of months to years</b>	<b>History of days to months</b>
<b>Presence of active pulmonary tuberculosis</b>	<b>Not present</b>
<b>Most common location: Thoracic spine</b>	<b>Lumbar spine</b>
<b>&gt; 3 contiguous vertebral bodies involved</b>	<b>Two vertebrae and intervening disc</b>
<b>Vertebral collapse : Common (67%)</b>	<b>Less common (21%)</b>

# Osteomyelitis complications

1. **Bone death (osteonecrosis):** An infection can impede blood circulation within the bone, leading to bone death.
2. **Septic arthritis:** In some cases, infection within bones can spread into a nearby joint.
3. **Impaired growth:** In children, the most common location for osteomyelitis is in the softer areas, called growth plates, at either end of the long bones of the arms and legs. Normal growth may be interrupted in infected bones.
4. **Skin cancer:** If osteomyelitis has resulted in an open sore that is draining pus, the surrounding skin is at higher risk of developing squamous cell cancer



# Clinical presentation

- **Signs & Symptoms**
- Fever, chills, irritability, fatigue.
- Tenderness, redness, and warmth in the area of the infection.
- Swelling around the affected bone.
- Lost range of motion.
- The symptoms for acute and chronic osteomyelitis are very similar

# Treatment

- Surgery to remove dead bone (sequestrum)
- Antibiotics; levels in bone may be lower than serum; often Cloxacillin, Nafcillin, third generation cephalosporins; guided by culture and sensitivity reports and drug minimum inhibitory concentration