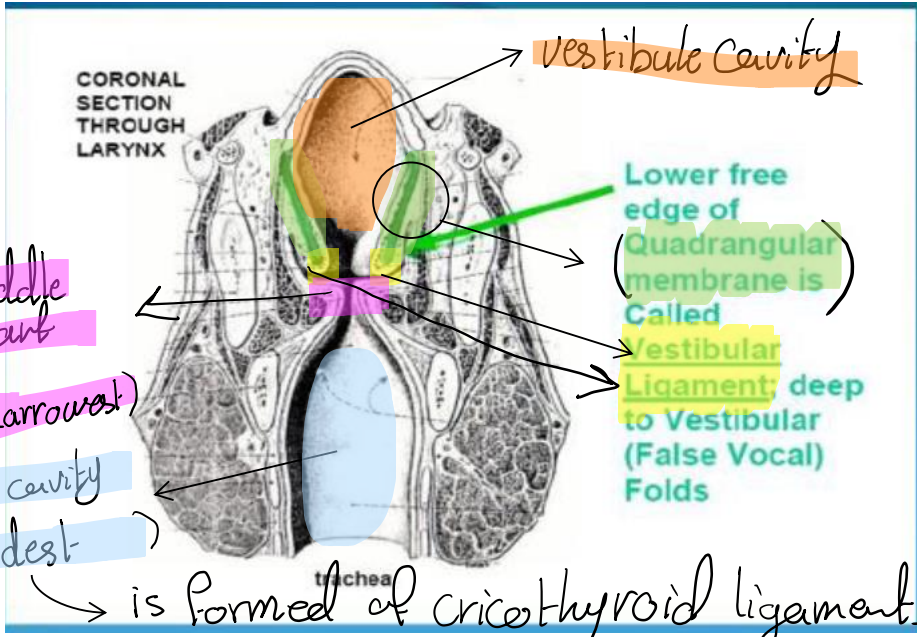
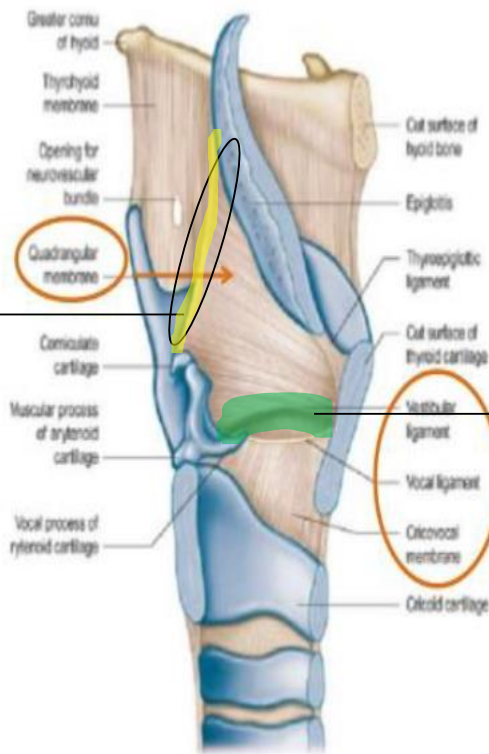
INTRINSIC

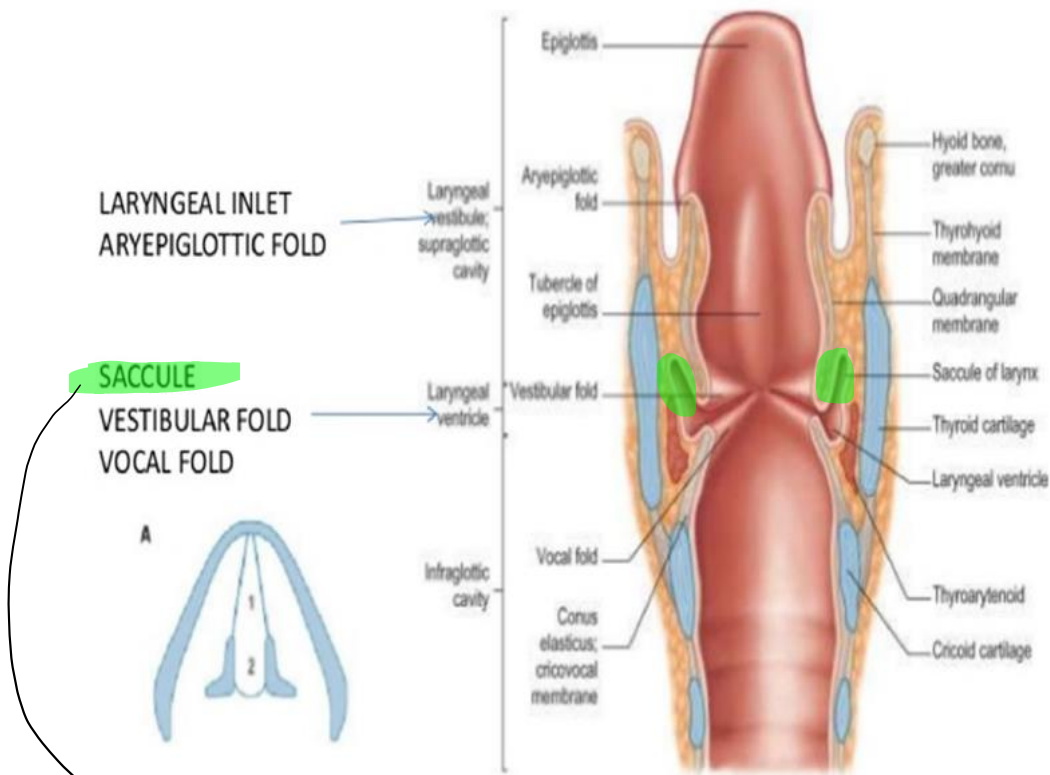
The aryepiglottic fold



vestibular ligament

Sagittal section of left side of larynx showing laryngeal membranes

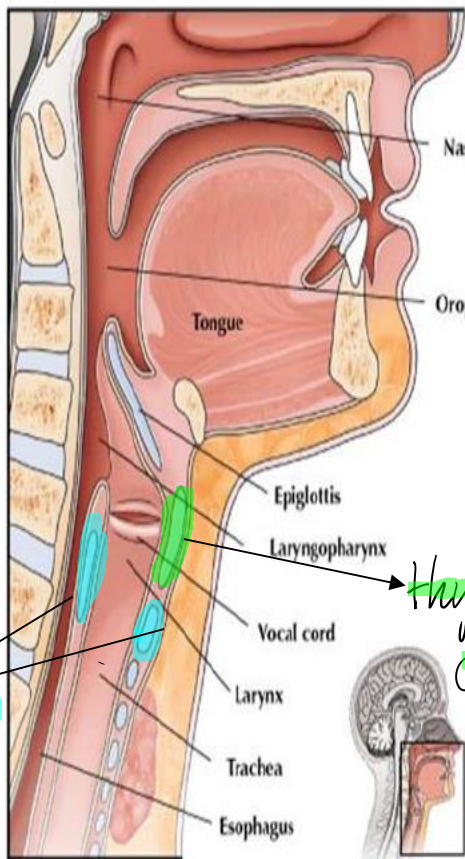
SUBDIVISIONS OF LARYNGEAL CAVITY



Coronal section through the larynx and cranial end of trachea
Posterior aspect

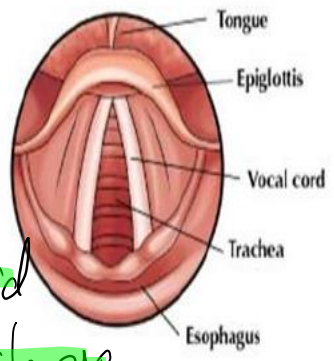
↳ has more mucus glands secretion to soften the vocal under it while moving

ANATOMY OF THE LARYNX



cricoid cartilage

Hyoid cartilage



LARYNGOSCOPIC VIEW

MID-SAGITTAL VIEW

FOR SAMPLE USE ONLY

©2008 TRIALSIGHT MEDICAL MEDIA









