Wondershare EdrawMind

TRACHEA

- **definition**
  - Reeds tube conveys air into & out of the lungs
- **Structure**
  - The wall of the trachea is formed of 16-20 cartilaginous rings connected by fibromuscular membrane
  - The rings are U-shapes, deficient posteriorly where they are replaced by fibromuscular membrane, allowing to allow distention of the esophagus during swallowing
- **size**
  - Length: 10-11 cm
  - External transverse diameter: 2 cm
  - Lumen: 1.2 cm
- **Beginning**
  - at lower border of crivoid cartilage (C6) as continuation of larynx
- **Course**
  - 1-descends in midline of neck (cervical part)
  - 2-Descends in sup. mediastinum (thoracic part) into right hemithorax to the right
- **End**
  - At T4 is divide into RT & Lt main bronchi
  - NB: In the bifurcation ring has a keel like extension called **carina**

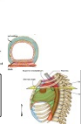
Thyroid gland
Trachea
Esophagus
Carotid sheath
Vertebral column
Longus colli muscle
Longus capitis muscle
Scalenus anterior muscle
Scalenus medius muscle
Scalenus posterior muscle
Sternocleidomastoid muscle
Trapezius muscle
Pectoralis major muscle
Deltoid muscle
Pectoralis minor muscle
Subclavius muscle
Rhomboid major muscle
Rhomboid minor muscle
Latissimus dorsi muscle
Serratus anterior muscle
Ribs
Sternum
Thymus
Superior vena cava
Ascending aorta
Pulmonary trunk
Pulmonary veins
Pulmonary arteries
Bronchial arteries
Bronchial veins
Lymphatic vessels
Lymph nodes
Vagus nerve
Phrenic nerve
Cervical plexus
Brachial plexus
Sympathetic trunk
Thoracic duct
Azygos vein
Hemiazygos vein
Accessory hemiazygos vein
Esophagus
Aortic arch
Ascending aorta
Descending aorta
Superior vena cava
Inferior vena cava

Wondershare EdrawMind

BRONCHI

course

Trachea, divides into:
1)**2 main bronchi (1ry)** then
2)**Lobar bronchi (2ry)** then
3)**Segmental bronchi (3ry)** then
4)**Terminal bronchiole**, (millions) then
5)**Respiratory bronchioles**,
6)**Alveolar ducts** or 7)**Alveolar ducts** that enter Alveolar sac, the7) **alveoli** arise from the wall of alveolar sac as diverticula

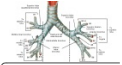

N.B.:-

- the RT main bronchus is wide, short (2.5 cm) – vertical, Before the lung it gives superior lobar bronchus then inside the lung it divided into middle, inferior lobar bronchus
- the **l**. main bronchus is narrow, long (5 cm) – nearly horizontal, Inside the lung it divided into superior, inferior lobar bronchus So inhaled foreign body tends to pass to rt lung

Wondershare EdrawMind

PLEURA

- **definition**
  - serous sac invaginated from its medial side by the lung so it's divided into:
    - visceral pleura - covers the lung & lines lung fissures
    - parietal pleura - lines the thoracic cavity
      - Parts of parietal pleura:
        - 1-cervical-dome/pleural cupula
          - Cover apex of lung & projects into root of neck
        - 2-costal
          - Lines the sides of vertebrae, the ribs, intercostal spaces, sternum
        - 3-diaphragmatic
          - Cover diaphragm
        - 4-mediastinal
          - Cover lateral side of mediastinum & sends a sleeve like extension (called pleural cuff) around root of the lung to be continuous with visceral pleura at hilum of lung. This pleural cuff hangs downward as a blind fold called pulmonary ligament
    - pleural cavity - closed space in between, Contain thin film of serous fluid allow layers to move on each other
      - Pleural recesses:
        - definition
          - parts of pleural cavity at lines of pleural reflection not occupied by lung except in full inspiration
        - sites
          - Costo mediastinal
            - 1-chest wall & mediastinum: marine art border of lung
          - Costo diaphragmatic
            - 1-chest wall & diaphragm: inverse inf. border of lung. It is the 1st part to be filled in pleural effusion.

- **Nerve SUPPLY**
  - Visceral pleura - Autonomic nerves (pulmonary plexus)
  - Parietal pleura: Somatic nerves (sensitive to pain)
    - costal & peripheral part of diaphragmatic: supplied by intercostal nerves
    - mediastinal & central part of diaphragmatic: supplied by phrenic nerves

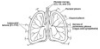

- **Blood SUPPLY**
  - Visceral pleura - bronchial arteries
  - Parietal pleura - intercostal, internal mammary (thoracic), musculophrenic vessels
- **Lymphatic drainage**
  - Visceral pleura - Bronchi pulmonary LN
  - Parietal pleura - intercostal, parasternal, diaphragmatic, posterior mediastinal LN