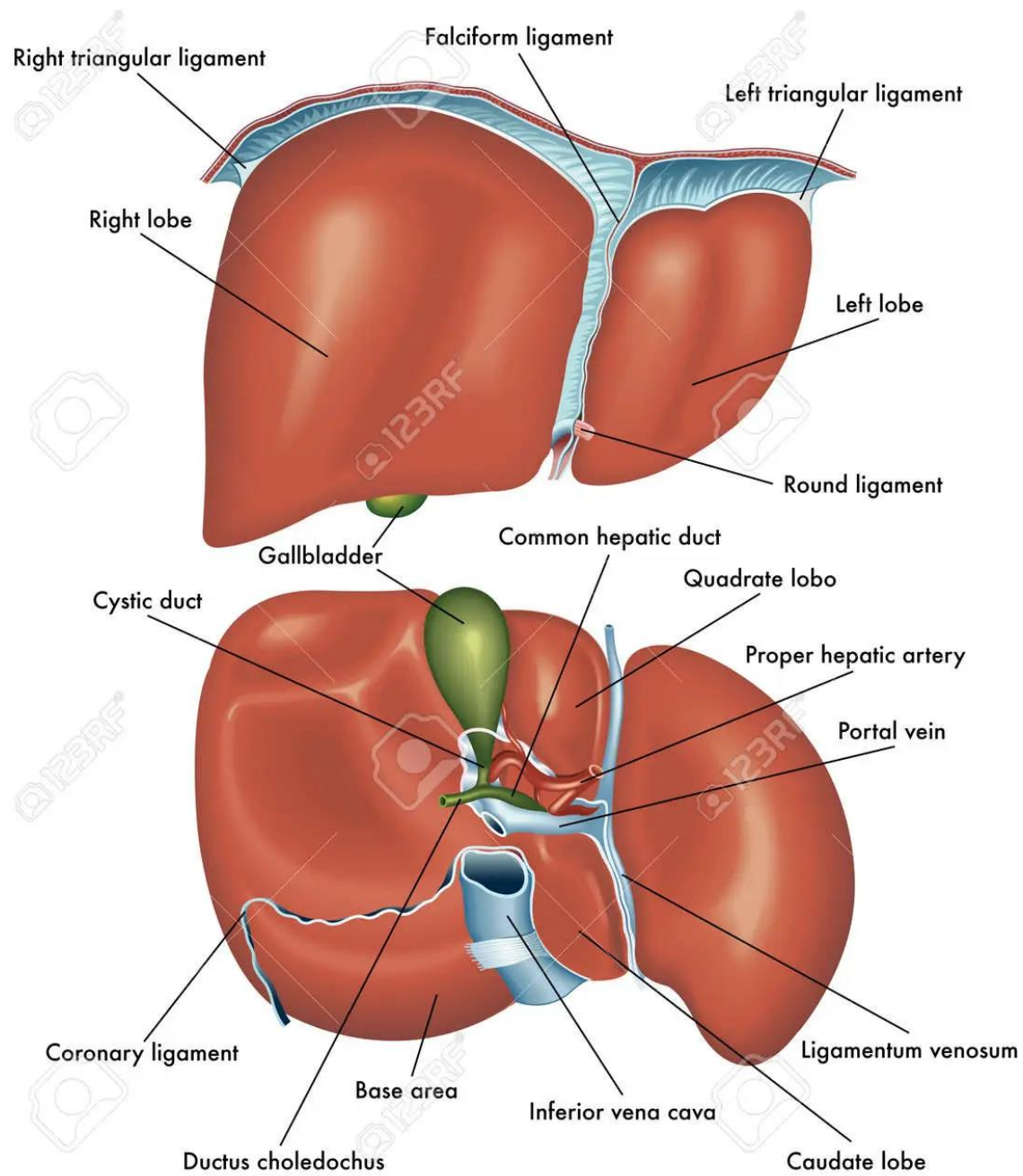
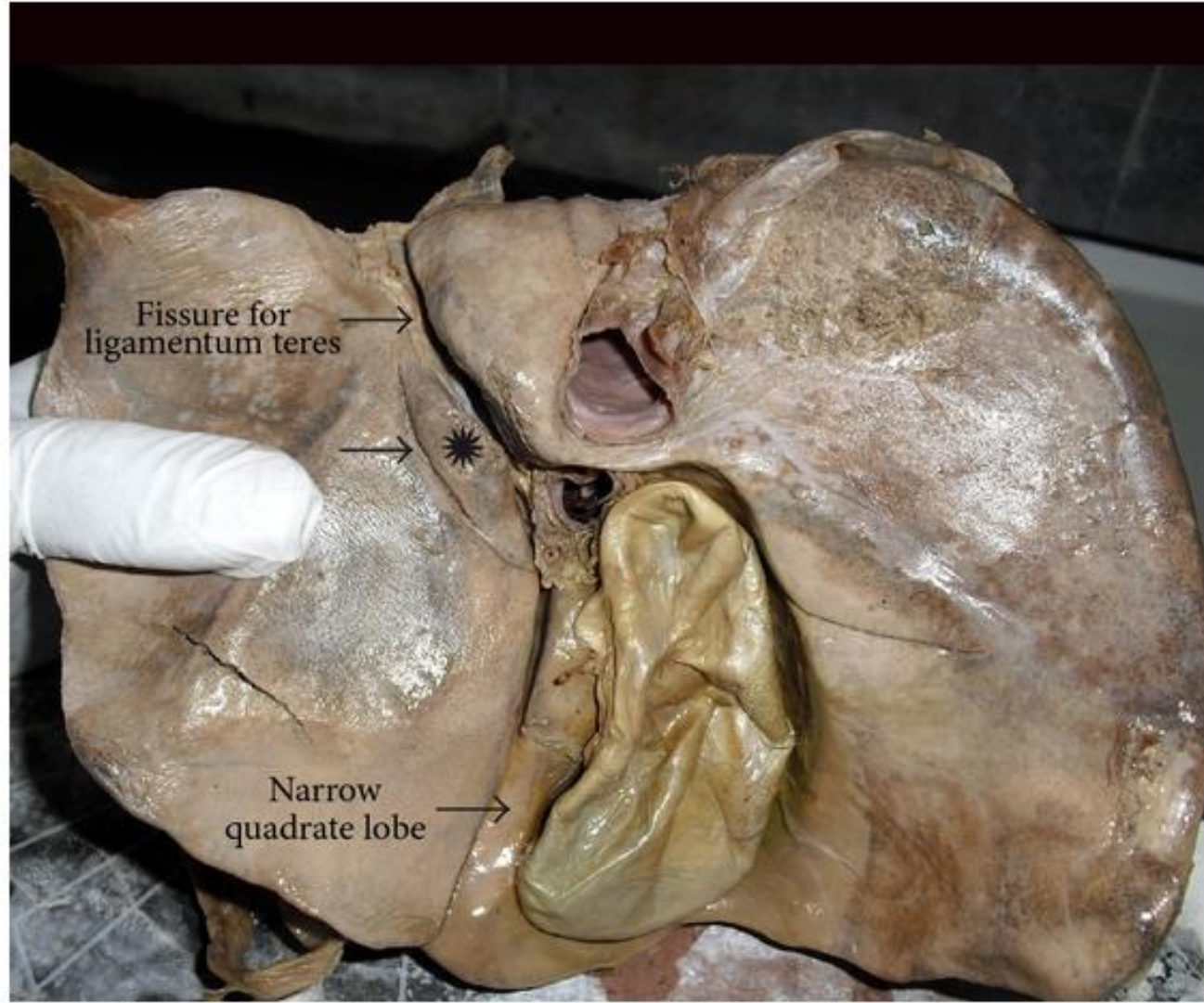
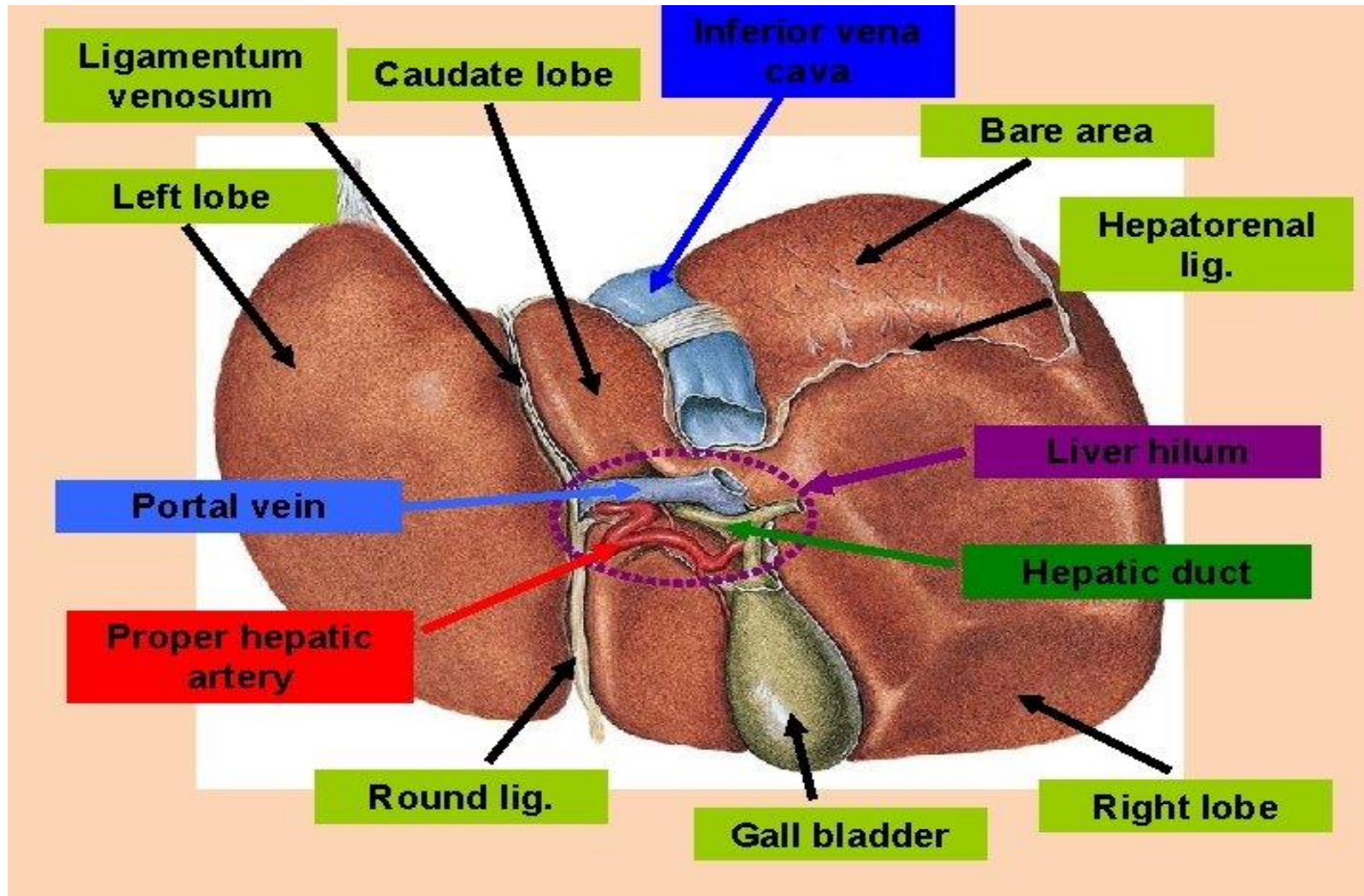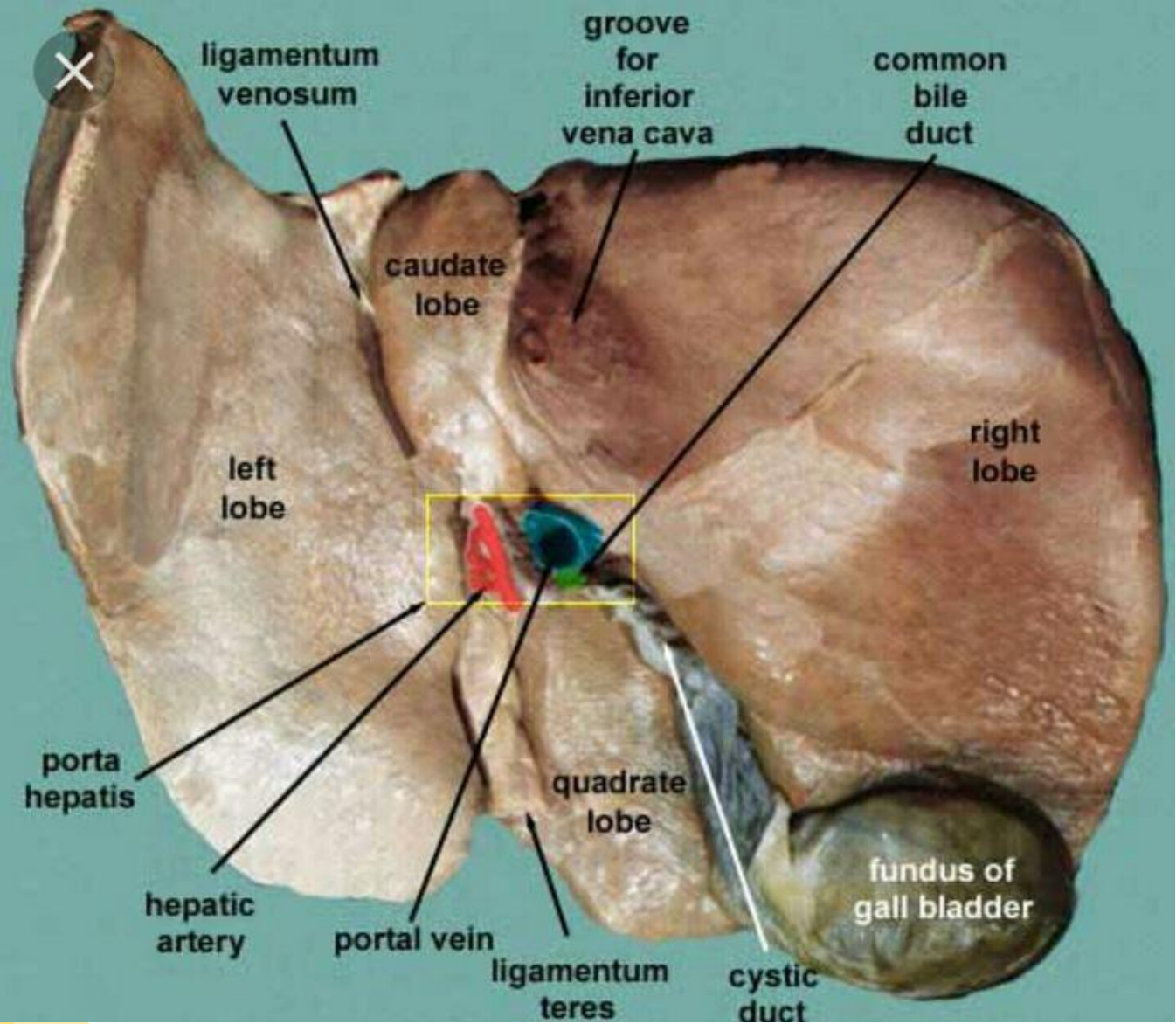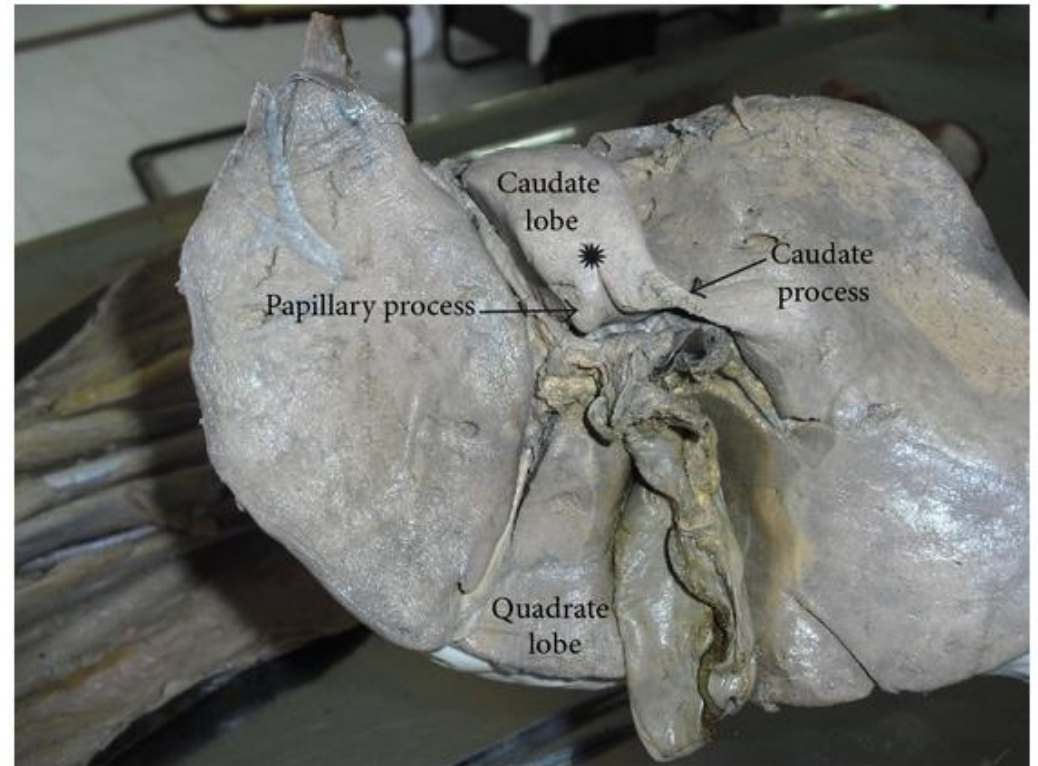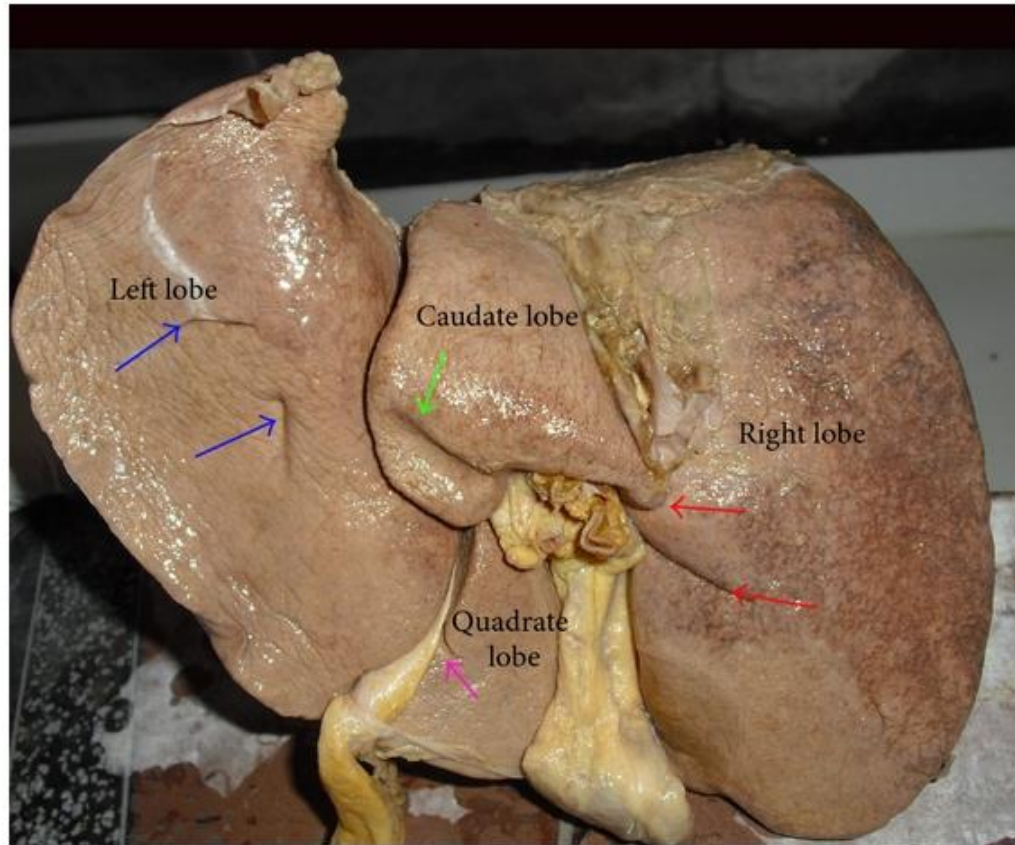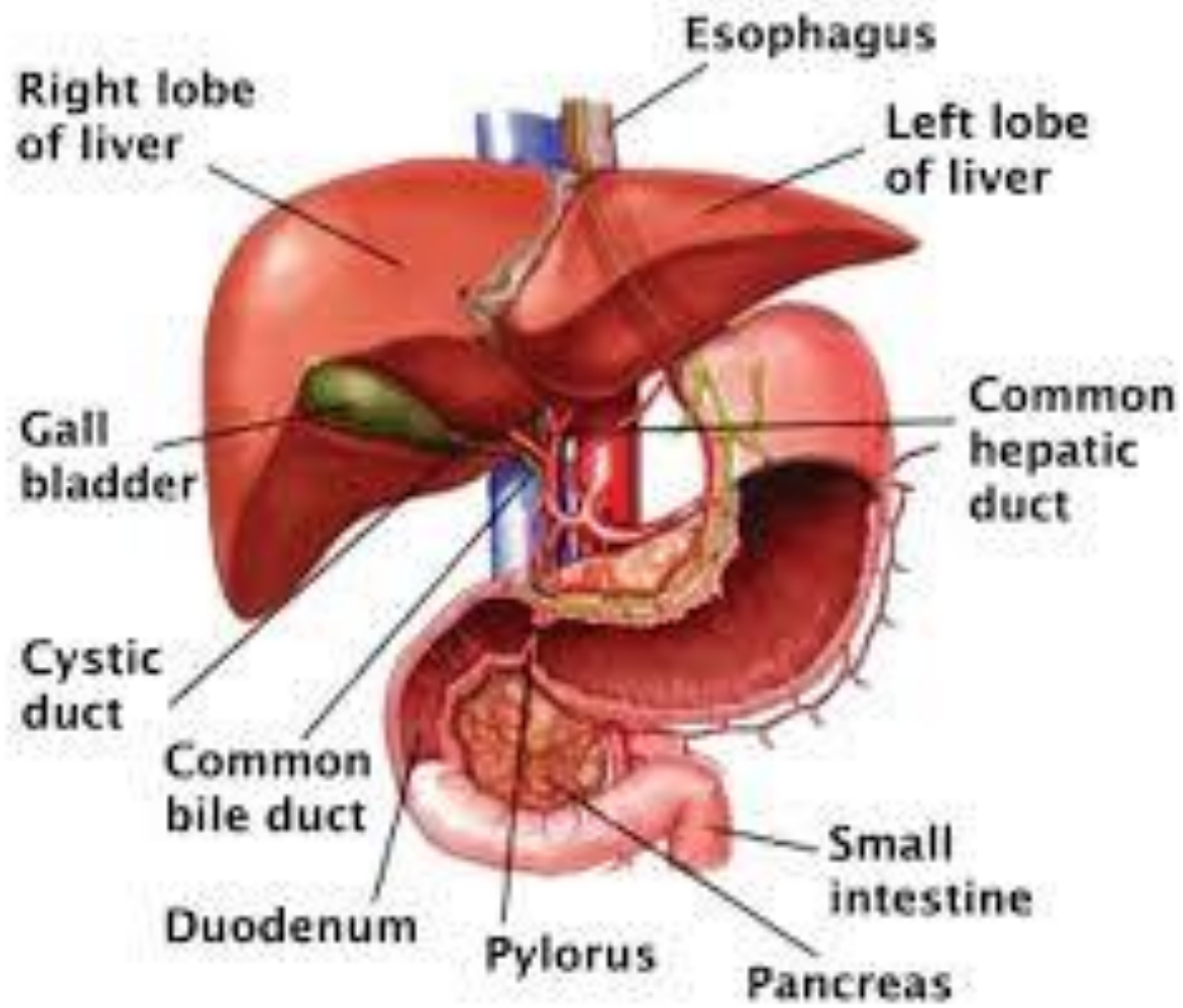**Foramen of
Winslow**

Liver

Gall
bladder

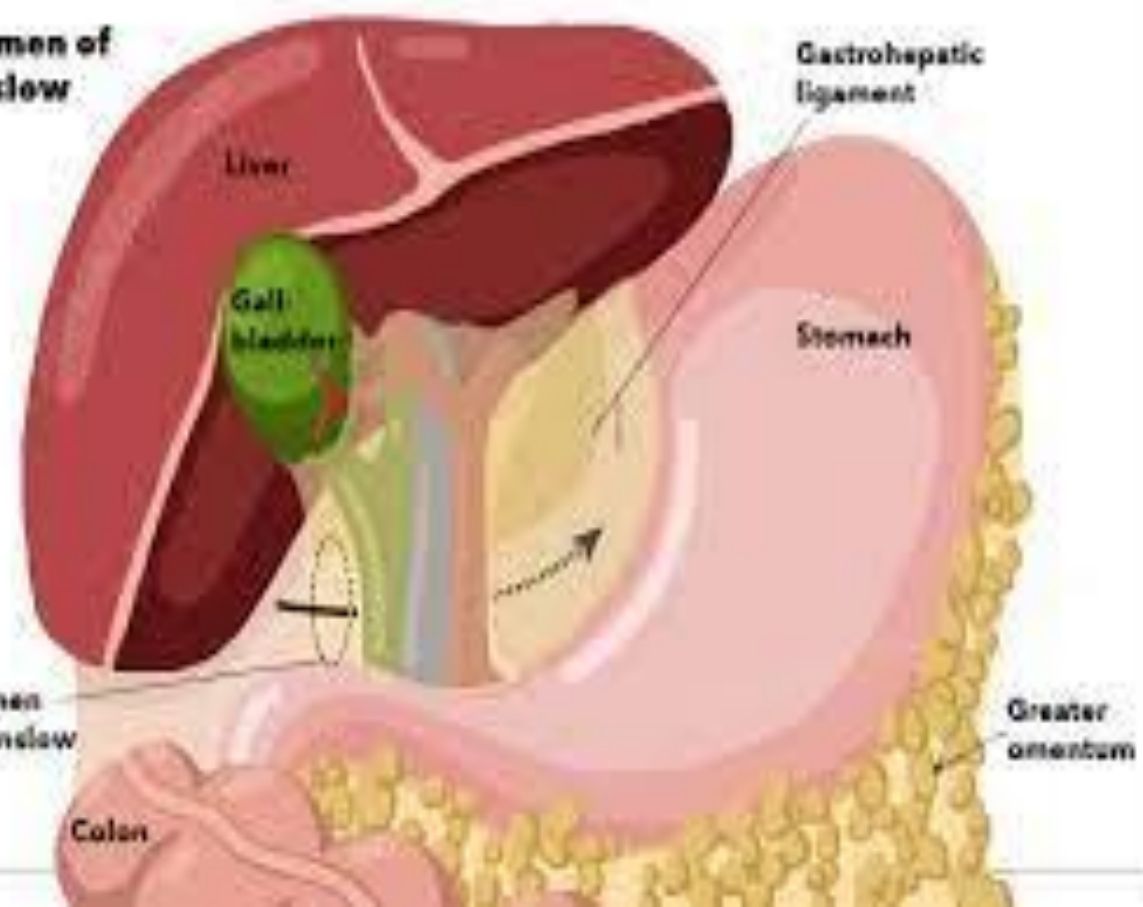
Gastrohepatic
ligament

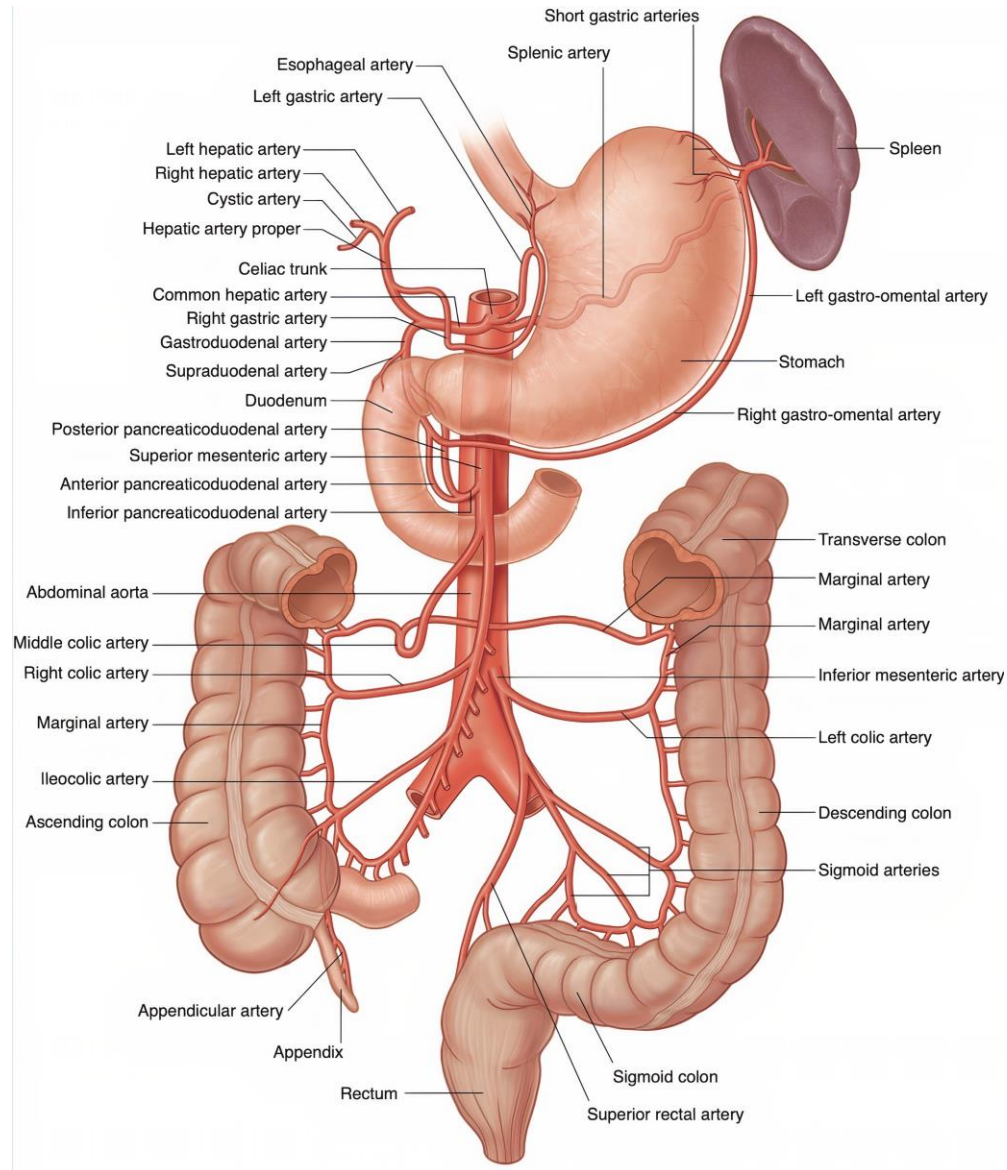
Stomach

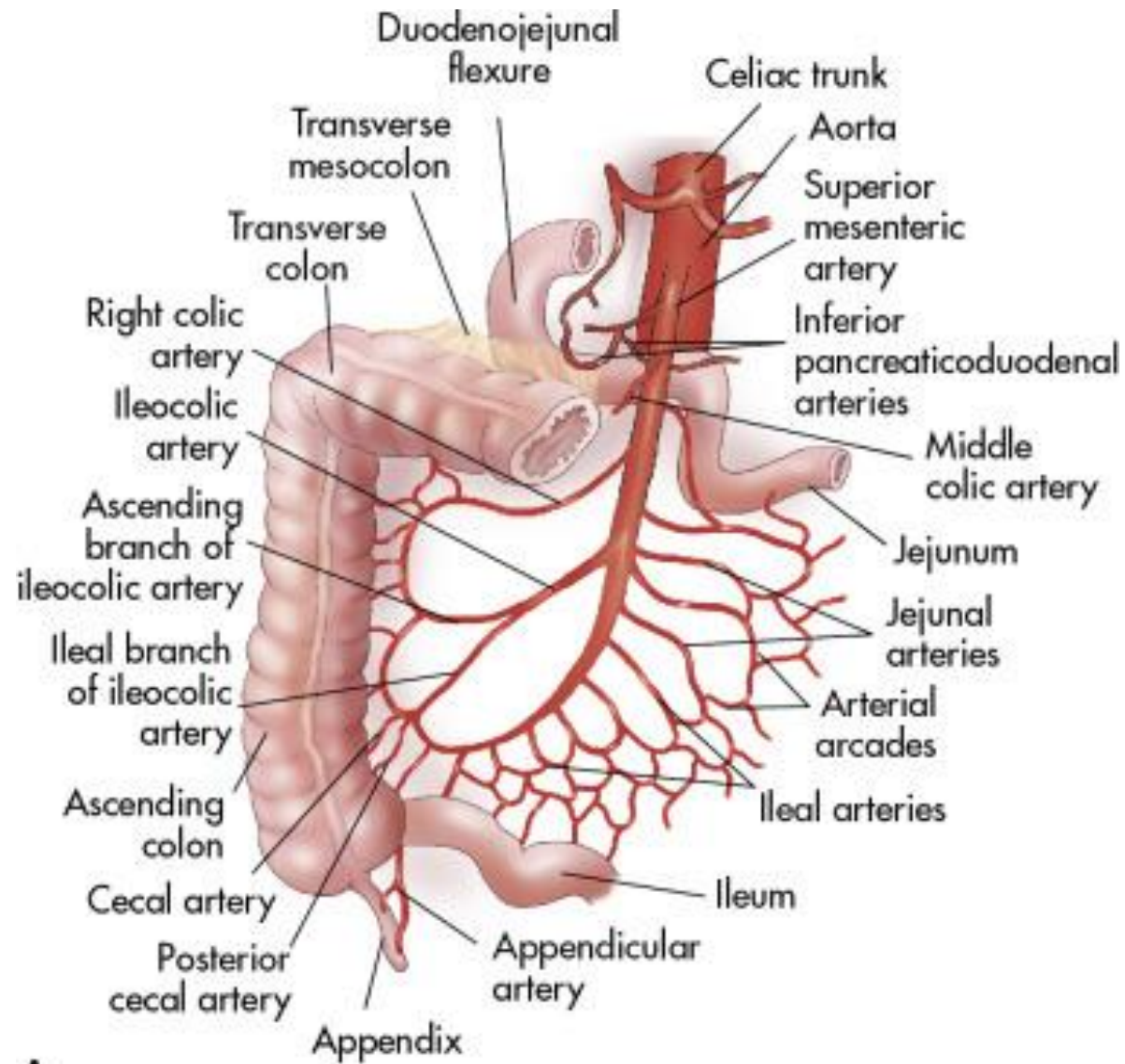
Foramen
of Winslow

Greater
omentum

Colon

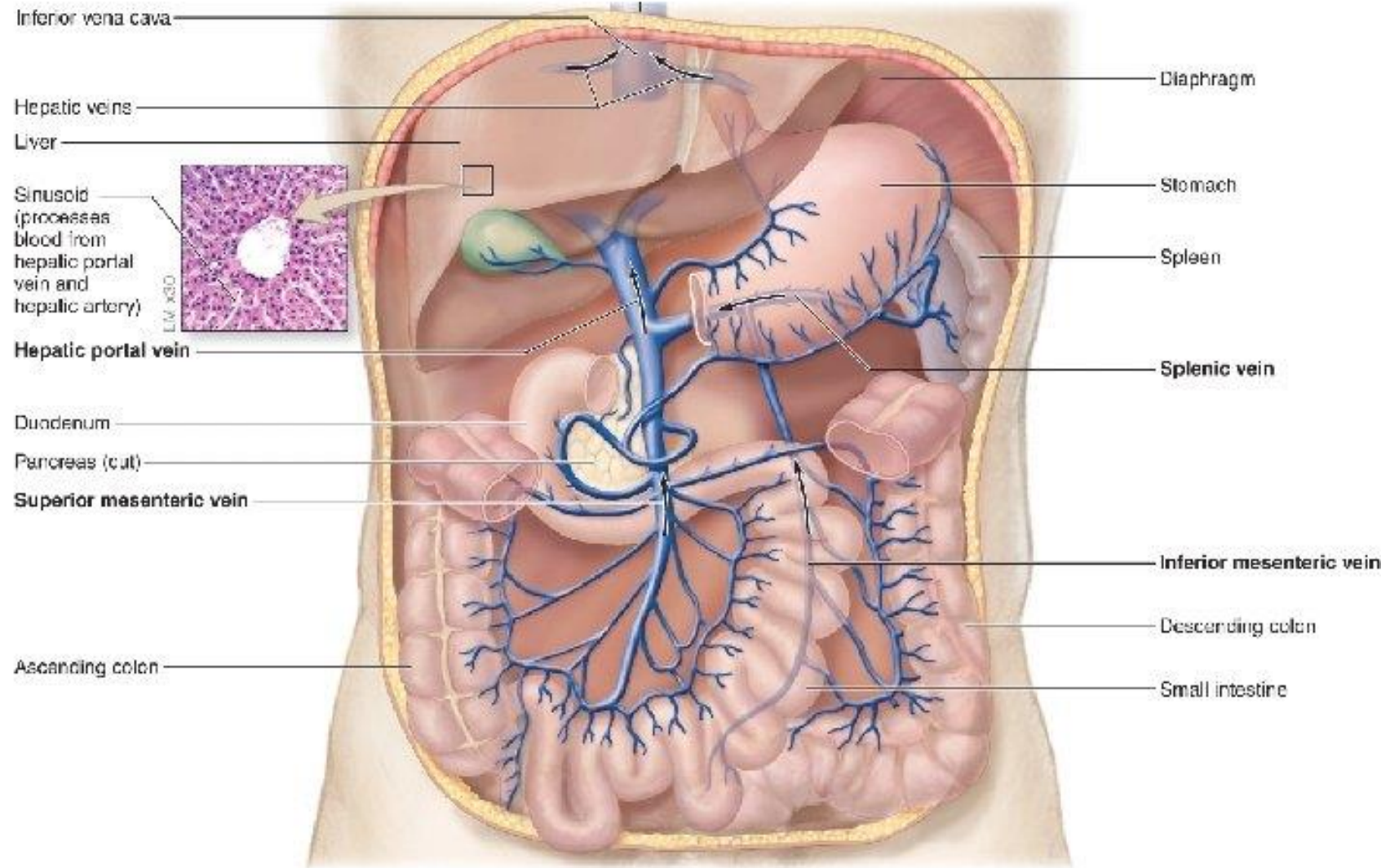






A

Major Veins of the Abdominal Region



© Victor P. Froshenko

